

## 2.

### *Secondary Rhinoplasty*

IN a 1994 Gillies memorial oration to the Association of Plastic Surgeons of India, N. Pandya noted that 60 million Americans do not like their nose and 40 million Americans do not like their chin. I wonder how many Americans do not like their *operated* nose.

Simultaneous with its rise in status, corrective rhinoplasty has achieved great public popularity and is in increasing demand. Unfortunately, not all who do this work are adequately trained. As a result, more and more postoperative deformities are being produced. The opportunity for discrepancy is three-fold and three-dimensional, for its surgery has but a slim allowable margin of error: artistic judgment is an intangible, postoperative healing unpredictable. No matter how well trained, experienced, careful, artistic, or lucky a surgeon may be, however, he or she will have some secondary deformities.

#### PROGNOSIS

The prognosis of a corrective rhinoplasty operation is influenced by several factors: (1) The condition and degree of

the original nasal deformity, (2) the training and skill of the operating surgeon, (3) the postoperative course and healing of the patient, and (4) unexpected or unknown circumstances labeled "luck." The latter factor may be a late unexpected hematoma, a low-grade infection, necrosis of tissue in invisible positions, and other subtle and unusual reactions secondary to the surgery that result in unexpected deformities.

Secondary rhinoplasty by definition means some degree of failure. It may be inability to interpret or fulfill the patient's desires. It may be miscalculation or inadequate execution by the surgeon. This can occur in a minor or major degree involving one or multiple layers influencing a portion of the nose or the entire nose.

## DIAGNOSIS

### *Aesthetic Surgery*

Before treatment can be considered a diagnosis of the deformity must be determined. If the problem is simply inadequate execution of the standard corrective rhinoplasty procedure, which has left too much or unequal alar cartilages, or a residual hump, too much length of anterior septum, the nasal bones still spread or asymmetrically positioned or too much flare to the nostrils, then by secondary rhinoplasty the surgeon can return through the old scars to revise any or all discrepancies. He must simply *redo* the rhinoplasty. This is within the realm of the aesthetic surgeon.

Although I personally prefer to gain exposure through the previous endorhinoplasty incisions, this is a condition where I can sympathize with those who feel more confident when using an open rhinoplasty approach for increased exposure.

### *Reconstructive Surgery*

When the cause of the secondary deformity is due not to too little reduction but to too much or there has been an unexpected complication of necrosis or infection or both, which compounds the error in one or more layers, then it falls into

the realm of the reconstructive surgeon or the aesthetic surgeon with reconstructive training.

Treatment involves determining what is displaced, distorted or actually missing and what is in excess. This is necessary before adequate action can be planned. The Robin Hood principle is invariably useful taking what is not needed to make up what is missing. Replacement of the missing portions with similar tissue in kind is essential.

The nose is composed of skin and subcutaneous tissue of varying degrees of thickness as cover, an elongated tripod of bone and cartilaginous support, and two cavities of mucosal lining. Any occurring secondary deformity that is of concern will be reflected in the cover, support, or lining. It may involve only one, a combination of two, or it could include all three. Diagnosis of which of the three is involved deserves first priority. Once this decision has been made, then the standard techniques of reconstruction must be employed to achieve the correction.

Secondary problems range from difficult to insurmountable and usually present limited potential. If the secondary deformity is our own, we have already done the very best we could; if it is another surgeon's result, then often he has discarded what we would leave and has retained what we must take. This is particularly true if the primary surgeon's main focus has been on the airway and his radical submucous resection has removed all cartilage, which can be a trump card in a secondary reconstruction.

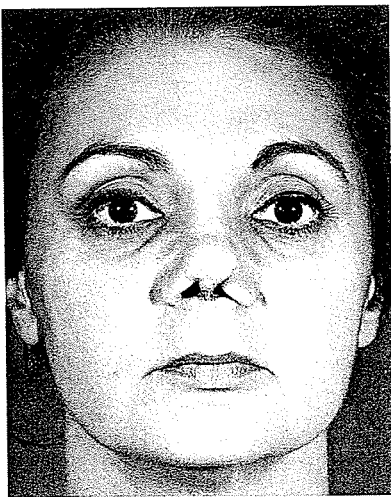## COMPLICATIONS

Once the nose goes wrong, too often an irreversible chain reaction is set in motion as the surgeon frantically operates again and again. The first operation offers the best chance for success. In certain cases, one secondary procedure may be required or even predicted preoperatively. The third attempt carries with it a more gloomy prognosis; if this fails to achieve improvement, then a halt should be called or the baton passed on.

The indomitable spirit portrayed in “If at first you don’t succeed try, try again” can be disastrous in an untrained surgeon. Too often when a complication occurs the inexperienced surgeon may panic and, in his frantic effort to recover, multiply the damage. Secondary deformities occurring regularly after the primary procedure are *cause* for *pause*. There is an established 6-month minimal waiting period (and preferably one year) required for healing before re-operation is justified. It has been expressed in the procrastination “Never do today what can be put off until tomorrow.” To ignore this safety rule is dangerous. In 1969 B. O. Rogers emphasized the importance of “delay” in timing secondary and tertiary correction of post-rhinoplastic deformities. In 1983 H. Kleinert re-emphasized the importance of this waiting period in the hand which is applicable also to the nose.

Scar tissue (fibroplasia) is not mature for 6 months. When scar does form, avoid additional secondary operative procedures whenever possible at the same wound location for at least 6 months, thus permitting scar to mature. Early operation (under 6 months) in the presence of immature scar does stimulate marked fibrous tissue proliferation at the wound site and is to be avoided.

When the surgeon persistently goes back again and again, a catastrophe may be in the making. Here hope is triumphant over *experience*, to the repeated detriment of the injured. It is imperative to know when to stop. I remember one otolaryngologist who was turning out deformed noses, and several by chance found their circuitous way to my office. A history divulged that they had had one primary and as many as six secondary procedures. One of the patients came in with a necrotic columella which her surgeon had assured her would eventually “granulate and fill in.” I took a forceps and removed the mummified center of her columella. Closer scrutiny revealed two scars, one at the tip join of the columella and the other at the columella base. Obviously the surgeon forgot or ignored his first scar of open rhinoplasty when he made the second cut and shoved in a silastic strut for



tip support that sloughed the entire intervening unit. This patient's reconstruction will be described later in the reconstruction section under columella.

Subsequently I phoned the surgeon responsible for this columella problem and informed him of this patient's progress, ending with this warning:

If you feel driven to do rhinoplasties without proper training (he had had a 2-week course) and you get secondary deformities, which I might add we all get occasionally, I suggest you limit your secondary corrections to no more than two. After that refer them to someone more qualified to handle them. If another case comes to me in distress from you with a history of seven operations, I am coming after you.

He must have taken me seriously for good or bad, I never saw another of his cases . . .

#### PAINTED INTO A CORNER

When H. D. Gillies and C. Straith had little interest in secondary rhinoplasty I was honored to accept the challenge and got some invaluable experience during my early training. Part of the challenge is sparked by the fact that there has been previous partial failure. Primary corrective rhinoplasty demands *consistent* aesthetic technique but secondary rhinoplasty requires imaginative use of principle with indepth diagnosis of the defect being essential before any chance of obtaining an aesthetic solution.

Once it is known you are willing to take on these problems patients will seek you out and if you continue to accept them and even express pleasure in the joust, the trickle will become a flood. My operative schedule probably carries more secondary rhinoplasties than any other single problem, which, plus time, explains why I have faced so many secondary nasal deformities. Lest this be misconstrued as evidence of superior skill let me note that I charge less for secondary procedures than for the primary operation. Of course, the fee should reflect the severity of the deformity and the time required to correct it and thus may vary somewhat. The reduction in fee

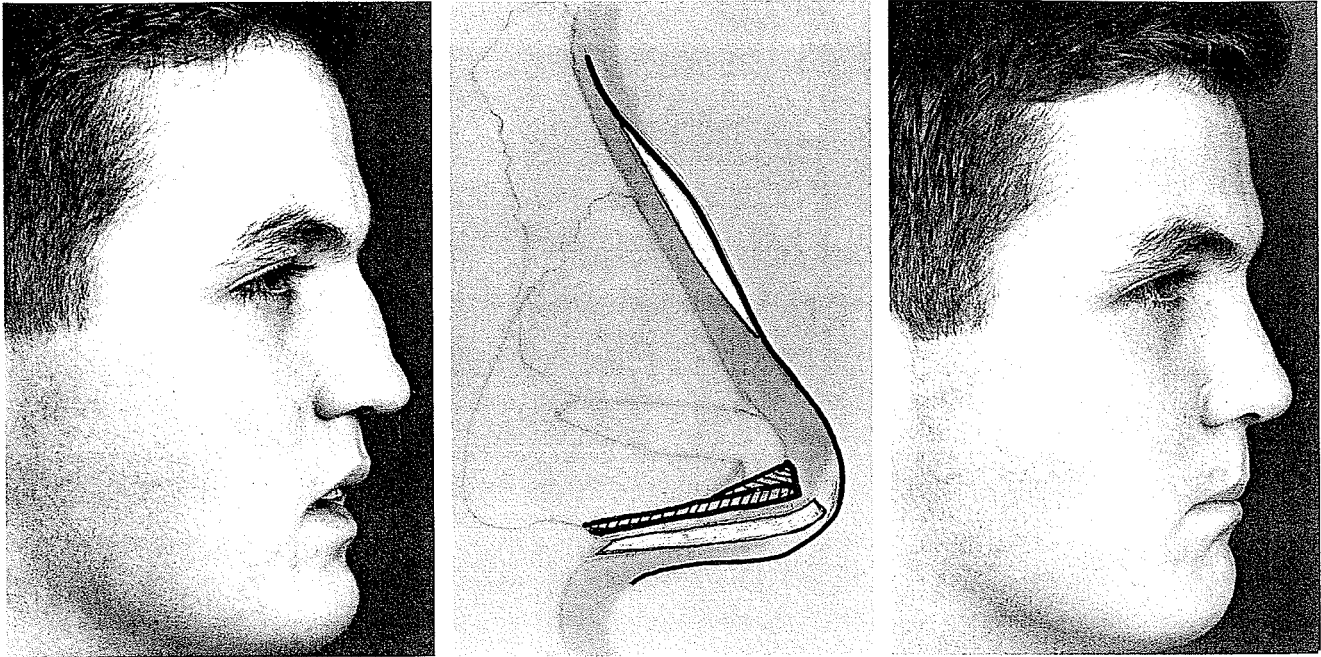
is not to attract more patients which it undoubtedly does. The spirit of this approach is based rather on the fact that the patient already has paid a good fee to someone for what they expected to be a success. I feel the specialty owes it to the patient to help in the climb back.

When seeing a patient with a secondary nasal deformity in consultation for the first time, be kind to the patient and the previous surgeon. You do not know for certain the preoperative conditions so do not be too critical of the work. First it keeps your relationship on a higher level and gracefully gives the previous surgeon the benefit of the doubt. Remember also that he may very well be seeing one of your postoperative cases at the same time that you are seeing his! It happens!

#### MINOR DISCREPANCIES

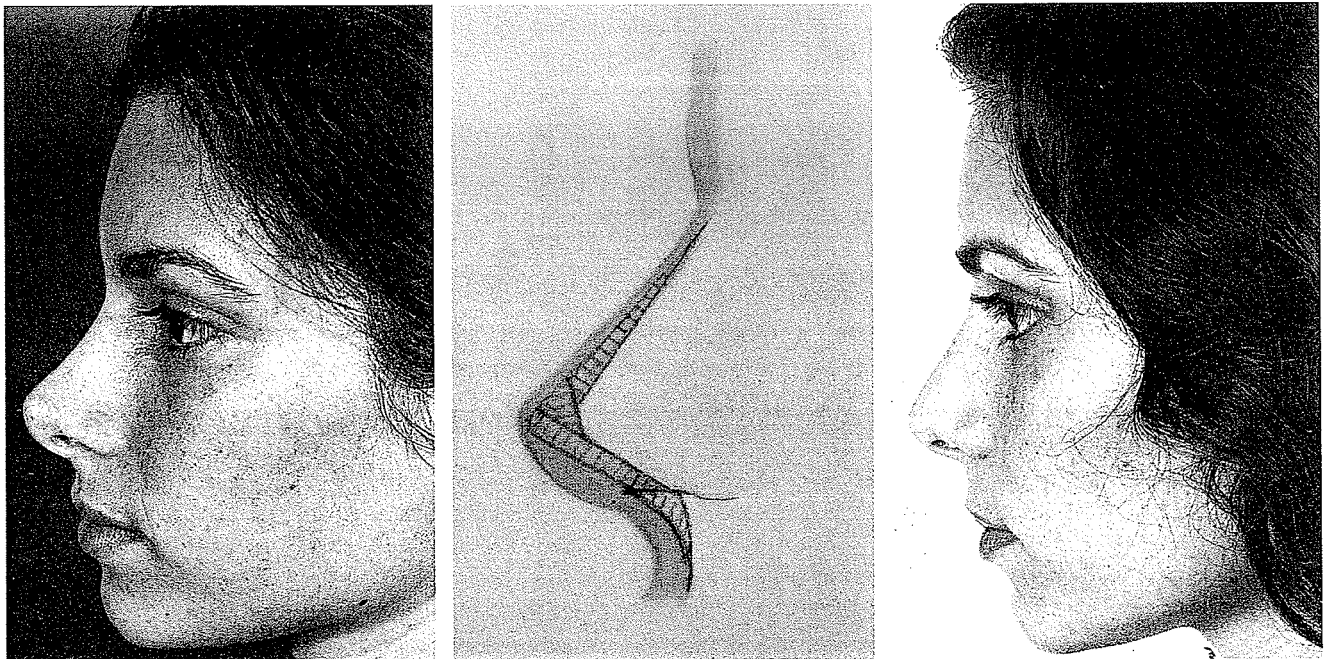
Remember that this work is done by hand and eye. No matter how careful the surgeon may be when shaping three layers of living, bleeding tissue along three planes, it is inevitable that minor discrepancies will occur. A difference in skin cover thickness may give a slight depression of contour. Residual loose pieces of cartilage or bone can give a visible interruption in profile or a roughness to the touch. Shortness of lining, misplaced interruption of cartilage integrity, or the pull of one stitch can cause kinking along the alar rim. The lowering of the bridge without reduction of the alar bases can give a relative widening of the nostrils. Reduction of the nostrils can produce slight asymmetries. The mere process of narrowing a nose with an adequate airway can encroach just enough on the passages to become bothersome even in the absence of a deviated septum or enlarged turbinates. Depending on the degree of these minor discrepancies, the amount of overall improvement already achieved, and the contentment and stability of the patient, action is determined. Under suitable conditions, whatever is not perfect deserves improvement, provided there is a maximum chance of correction, with minimal chance of compounding the problem. For instance, a slight hump can be used to support the tip and fill out the

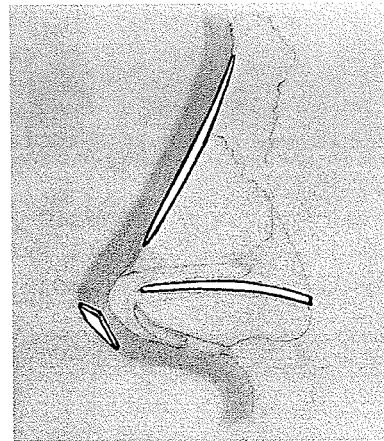
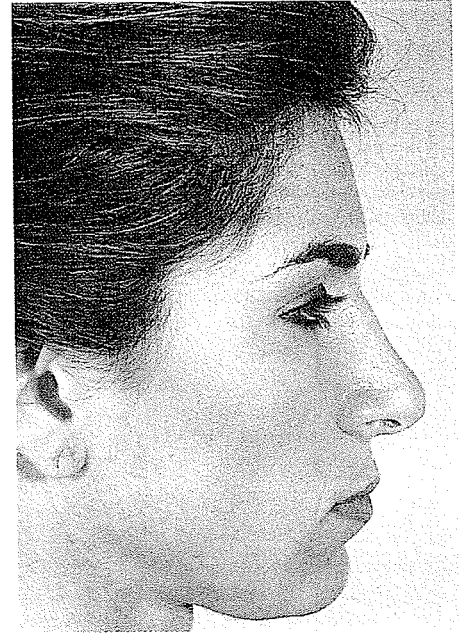
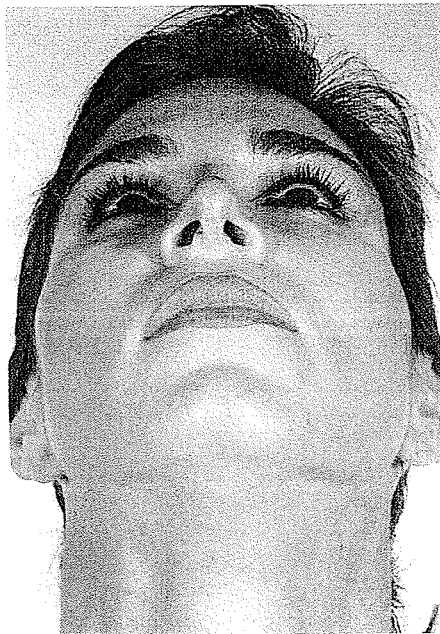
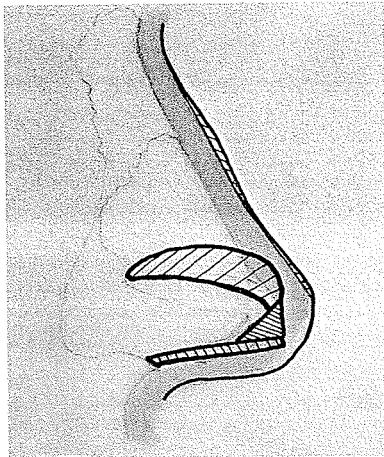
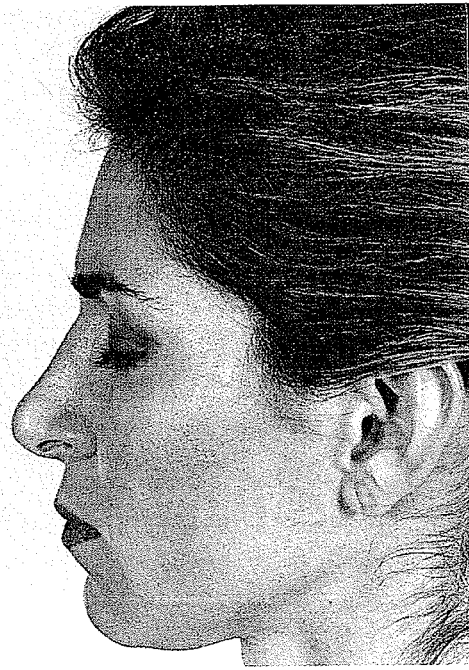
moderately retracted columella following removal of too much anterior septum. Here is an example of this Robin Hood trade off:



#### *Inadequate Reductions*

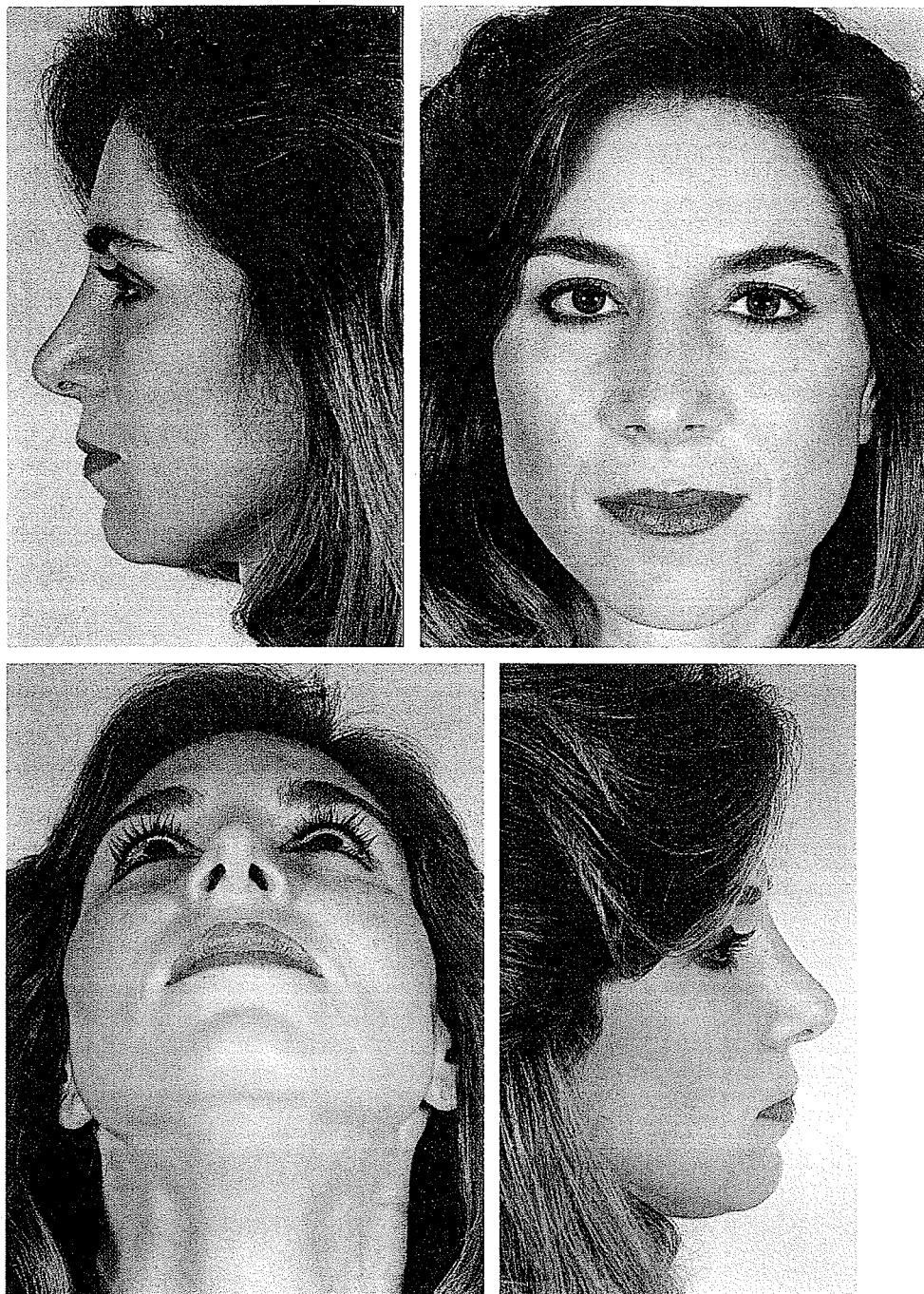
1. Four years after rhinoplasty, a patient requested secondary correction. The excess profile was improved by lowering the bridge and reducing the anterior septum and nasal spine.





Two-thirds of the remaining alar cartilages were resected. The bridge was lowered with a chisel and scalpel. A thin rectangle was resected along the anterior septum including a golden triangle at the tip. Alar base wedge resections reduced the flare. Through a submucous septal resection enough cartilage was harvested to insert one piece along the concavity of the left bridge, another in the crease of the left ala to support the valve collapse and finally a diamond shaped graft was inserted for tip definition.





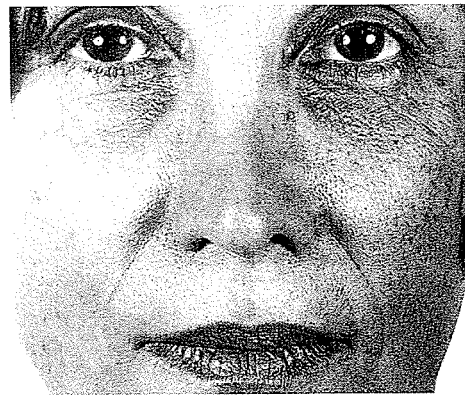
Maintenance of some intact alar cartilage to support the alar rims is as sacrosanct as maintenance of an L-shaped cartilage frame to preserve the nasal profile. Peck has emphasized the importance of an intact alar cartilage. There are two circumstances where this rule need not be rigid. One is in a case where the alar cartilages are so deformed or deficient that it is better to scrap what is inadequate and replace it with a more normal cartilage graft. The second circumstance is in the sec-

ondary nose when the alar cartilages of the tip and alae have been previously dissected and resected so that they are locked in scar. The secondary surgery can be more radical in resection of these cartilages with some impunity because of the buffer of the scar.

When there is no respect for intact alar cartilages, lack of skill with skin dissection and arrogant disrespect for the 6 month healing phase, real trouble is brewing.

#### *Postoperative Furrowed Nasal Skin*

This patient had a rhinoplasty and 4 years later a secondary rhinoplasty. Three years later she presented nasal skin grooves, a short wide one on the right and a longer one on the left. Other minor discrepancies were corrected such as shaving the bridge and narrowing the bones with infractures before treating the furrows. Then through alar marginal stab incisions the skin of the furrows was undermined with a scalpel and custom shaped strips of auricular cartilage were threaded into the pockets to smooth the external contour. Result seen after a year.



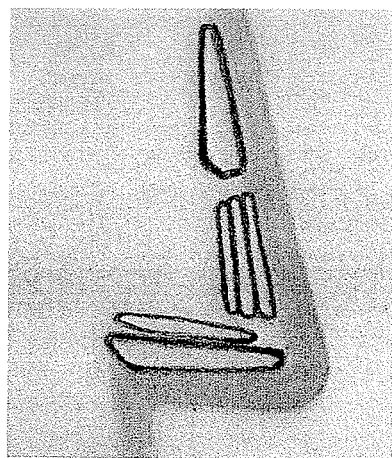
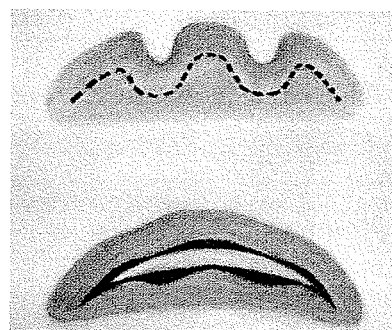
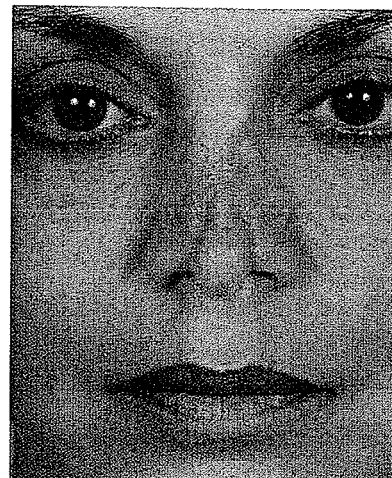A similar procedure was used in this irregularly grooved tip.

An unfortunate 50-year-old woman underwent a reduction rhinoplasty in January. A suprahump that developed in her bridge shortly after the operation stimulated the same surgeon to operate again in March of the same year. Then he operated again in April in a frantic attempt to correct the recurring irregularities, depressions, creases, and collapse


with loss of the airway patency. *In time of a complication, the embarrassment of the surgeon's ego, the disappointment of the patient, and the impatience of both precipitate too much secondary surgery too soon, and insult is added to injury.* In this specific case it is difficult to guess what created such a catastrophe. The radical excisions of ala cartilaginous framework provided slack skin cover which if dissected irregularly with repeated violations of the dermis could account for skin depressions, rucking and grooving without external skin scars. Too early surgery into unhealed tissue exaggerated by inevitable low grade infection had matted the mass. There was collapse of the bridge, septal perforation, nasal tip grooves, and bilateral notching of the alae with collapse of the airways.

When seen in consultation I explained to the patient the difficulty of her correction and that more than one procedure probably would be necessary admitting there was some doubt in my mind how much I could help her. I explained, evidently effectively, why she needed at least six months' rest. She returned after one year.

The key to correcting this deformity seemed to be primarily in smoothing out the irregular grooved skin surface and secondarily supporting the bridge and alae. It was tempting simply to try to insert cartilage into the grooves and had there been but one or two short ones this might have been attempted as is shown in the previous cases. Merely freeing by undermining the furrowed skin and adding supporting framework would have been of some benefit but logic pointed to an approach which might tax a Swiss watchmaker's patience but offered slightly better potential. The best plan seemed to be first to develop a skin cover of near equal thickness and then beneath it fill out the cartilaginous deficiencies with cartilage. Thus through alar margin incisions the skin was carefully elevated out of the various depressions, dipping deeper in the furrows to carve the skin and scar thicker in its thinned areas thus equalizing the general thickness of the entire dorsal skin covering. Autogenous conchal cartilage was




harvested and cut into specific pieces. One was placed along each alar margin to splint the notched rims. The remaining pieces were used strategically to correct the depressions in the dorsal tip. Bilateral osteotomy with infracture improved the nasal base. The patient was allowed to heal for 6 months and then a costal cartilage strut was inserted on the bridge and another smaller piece into the columella. The patient was reasonably satisfied and returned only once with a minor request.



## THE BIG THREE

There are three post-rhinoplasty secondary deformities that occur commonly enough to have been awarded comical nicknames. They are the ski jump, the parrot's beak, and the pig's snout, all characterized here and all out in the cold. These common three may appear separately or in varying combinations with each other. They may be accompanied by other secondary deformities that further complicate the problem.



## SKI JUMP

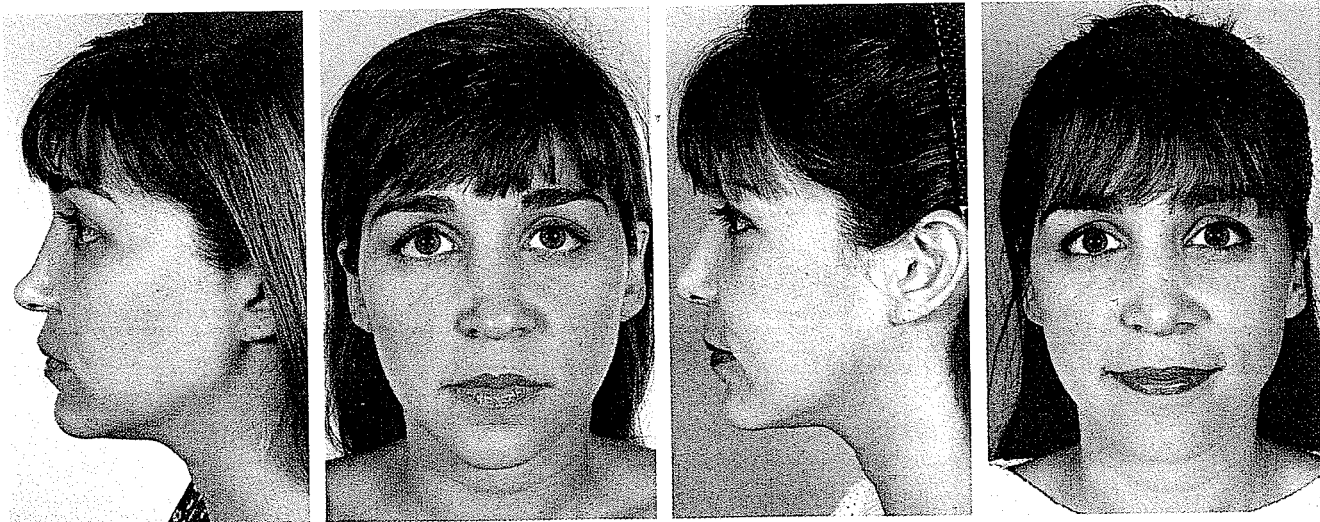
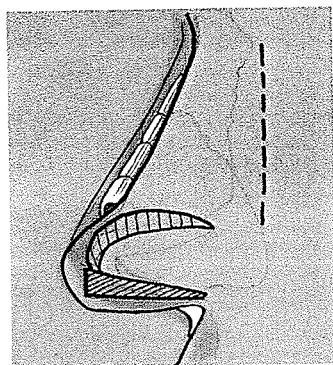
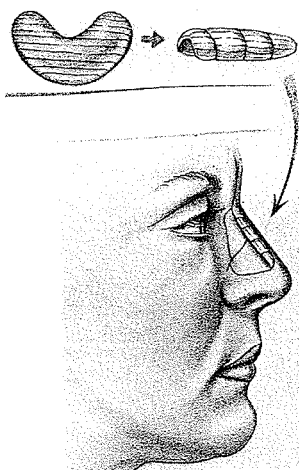
The character of a face and the pride of a nose depend in great part on the graceful height and relative straightness of the nasal bridge. Minor degrees of scooping the bridge to make it retrousee are sought by some and can be attractive in certain women. When carried beyond ideal, the bridge lowering becomes a deformity requiring elevation and straightening. Regardless of whether the deformity has been caused by traumatic or surgical removal of the bridge itself or is indirectly the result of loss by trauma, surgery, or infection of the septal support, the bridge will require additional onlays. Minor to moderate bridge correction can be achieved with an autogenous septal strut or tiered struts. If the discrepancy is minimal to moderate with no septal cartilage available and if the skin cover is in good condition, then an auricular conchal or costal cartilage graft may be indicated. Since the nasal bridge

is an area where the implant can lie quietly without need of a work load, a suitable strut of shaped hard silastic will often achieve the correct effect and lie in place silently without serious reaction or threat of absorption.

### *Conchal Cages*

Supplemental contouring of the nasal bridge when the fundamental support is sound can be achieved with auricular cartilage grafts as described by J. H. Sheen and later by M. Constantian. Here the basic nasal skeletal structure is nearly adequate and only increased contour is desired. As designed by Sheen, large conchal grafts with the natural curve already built in are curled by scoring and fixed with 6-0 nylon sutures into conchal cages, and the hollow is filled with free pieces of extra cartilage. These bridge grafts have enjoyed some popularity and have shown early apparent success. What will happen over the years with the aseptic necrosis of the loose cartilage pieces and partial uncurling of the cages is left to be seen.

Here is a secondary deformity of the bridge that I treated with an auricular conchal cartilage cage. The alar cartilages were reduced and the septum shortened. A septal cartilage graft was inserted at the retracted base of the columella to improve the re-entrant nasolabial angle. An auricular conchal



cartilage was made into a cage and inserted on the bridge to correct the profile line.

### *Saddle Nose*

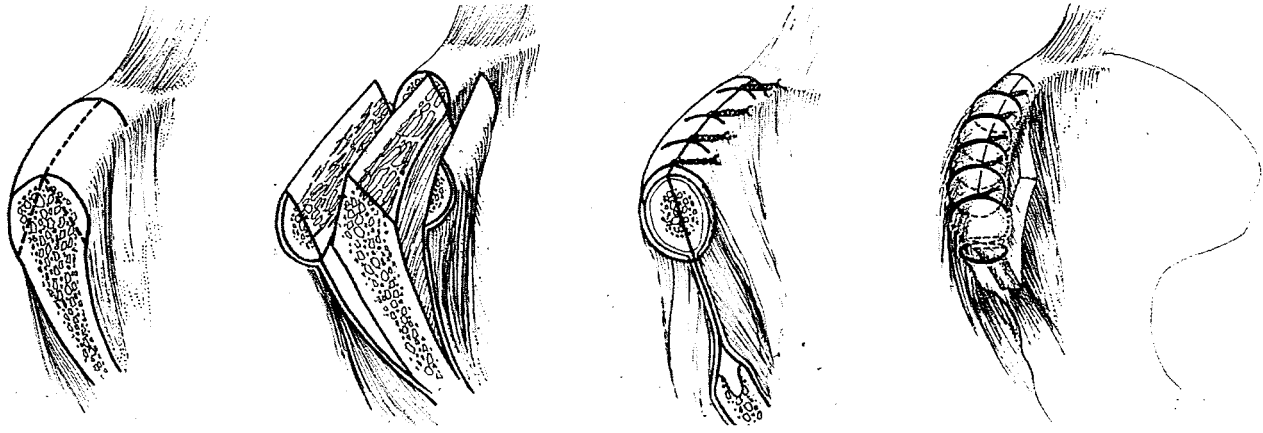
A severe degree of ski jump is the saddle nose. This may be the result of trauma, disease, excessive surgery, or any of the above followed by severe chondritis. Adequate treatment of this deformity calls for serious nasal skeletal replacement.

Tissue used for skeletal support of the nose should follow the principle of lost tissue being replaced by similar tissue in kind—bone for bone, cartilage for cartilage. This may not always be possible but when it is, the rule should be respected. A nose with mainly the bony nasal bridge flat, as seen after severe crushing injuries, can best be treated first by bilateral osteotomies and infracture. Since there has been partial pulverization of the bone with little hope for return to normal bridge height, an onlay bone graft is ideal as it replaces bone for bone on bone.

There are aesthetic aspects to nasal bone grafting. It is not enough just to shove a large piece or pieces of bone under the skin and fix them to what remains of the nasal bones. Ideally the nose should be supported so that the effect is graceful and natural. It is important to prepare the nasal bridge platform to receive the bone graft and avoid a slanted, hooked, Roman, or unaesthetic nose.

### **CHOICE OF BONE**

There are several excellent choices for nasal bone grafting. Full thickness or split thickness costal bone is easily obtained, provides good bulk and strength, and the remaining periosteal tunnel of the donor area will regenerate new rib bone. For a thick block of cancellus bone the iliac crest is an excellent donor site provided the surgeon understands how to lift the crest, take the required bone, and then wire the crest back in place to reduce notching defects and postoperative disability and discomfort. This technique has been described in de-



tail by S. A. Wolfe. The most popular bone graft for nasal support at this time is cranial bone.

### *Cranial Bone Grafts*

In 1892 Ollier first used cranial bone in rhinoplasty when he included a piece of frontal bone attached by periosteum to a forehead flap to reconstruct a nose. In 1982 P. Tessier began popularizing cranial bone grafting. It is true that cranial bone grafts have much to commend them. The donor area is hidden and the donor scar is usually unnoticeable. Membranous cranial bone seems to show less resorption, especially when stabilized by miniplate or screw fixation. Most bone grafts, when placed in a vascular bed and securely fixed, will survive especially in the area attached to bone.

In craniofacial surgery when a coronal incision and nasal root exposure are already present cranial bone for nasal as well as other facial bone grafting is expedient and logical. Although exposure for inserting miniplates is facilitated by the coronal approach, dissection of a pocket over the nasal bridge all the way to the tip can be slightly awkward, leading to the possibility of the graft slanting off center.

All bone grafts to the nose do not deserve a coronal incision. The bone can be inserted into a subperiosteal pocket through an internal vestibular incision or a columella splitting incision which heals to invisibility. Fixation of the bone with screws, when necessary, can be accomplished through a 1/2 cm incision in the skin at the root of the nose.



Long bone grafts on the nasal bridge do not follow the principle of replacing lost tissue with similar tissue in kind. The only bone in a normal nose is in the upper third, and the rest of the profile is maintained by septal cartilage along with alar cartilages in the tip. Introducing a rigid piece of bone from nasal root to tip does not recreate a natural effect. In fact, it looks like a bone grafted nose, it feels like one, it breaks like one, and in time the portion extending into the soft tissue may resorb like one.

In cases where loss of bone is the primary cause of the deformity then cranial bone is the replacement material of choice.

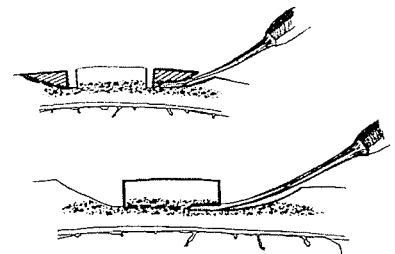
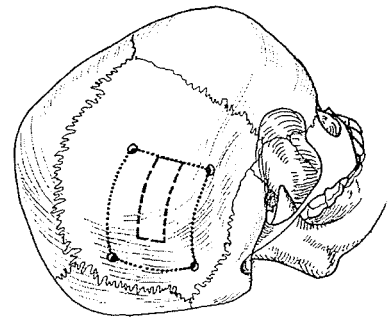
As S. A. Wolfe is an expert in cranial bone grafting, I requested that he describe how he harvests the bone:

“The usual donor area, most people being right-handed, is on the right parietal occipital region (this being the non-dominant hemisphere) behind the posterior attachment of the temporalis muscle. The bone is generally thickest in this area and there is usually a good diploic space which is important to harvesting an outer table graft. One, two, or three segments can be removed, as required.

The procedure can easily be done under local anesthesia. Patients have no sensation in the skull itself after the periosteum is anesthetized.

The approach is through a zig-zag incision without shaving any hair. The area to be removed is scored with the oscillating saw in the bleeding bone (carefully!) and the bone around the periphery of this area is taken off with an osteotome and saved.

Once the diploic space has been entered and clearly identified and the peripheral bone removed enough to permit an almost completely tangential placement of a thin curved osteotome, then the outer table segment is carefully removed. Once the first segment is removed, it is usually easier to remove the second and third if necessary. If the inner portion of the inner table is inadvertently removed and the dura ex-



posed, this is not a problem and several little fragments of bone are placed over the dura.

If there is any possibility that the dura was injured, the defect should be enlarged with a Kerasin rongeur and the dural defect inspected and repaired.

The peripheral fragments of bone that were removed are placed back into the donor area to help minimize the contour deformity. A piece of gel foam is applied over this and the wound closed with a drain which is taken out the next morning.

The bone that is removed has the perfect curvature for a nasal bone graft. If two or three tiers are going to be used, they are fixed together with several micro-screws into a counter sunk hole. The titanium screws, if any of them become palpable, can be burred down since titanium is a soft metal.

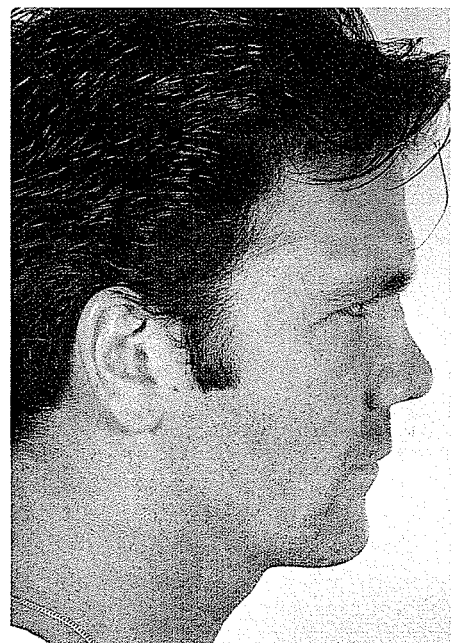

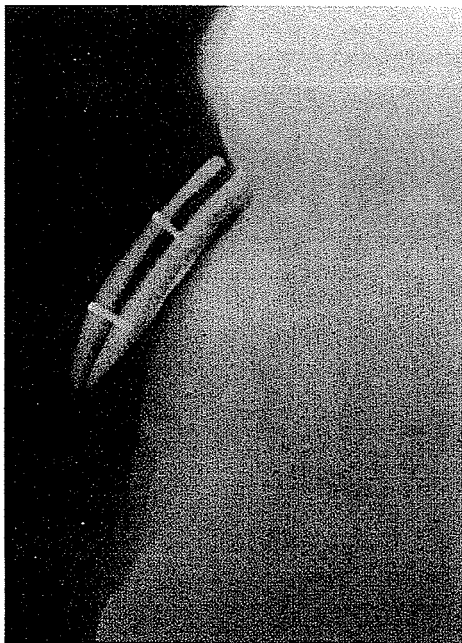
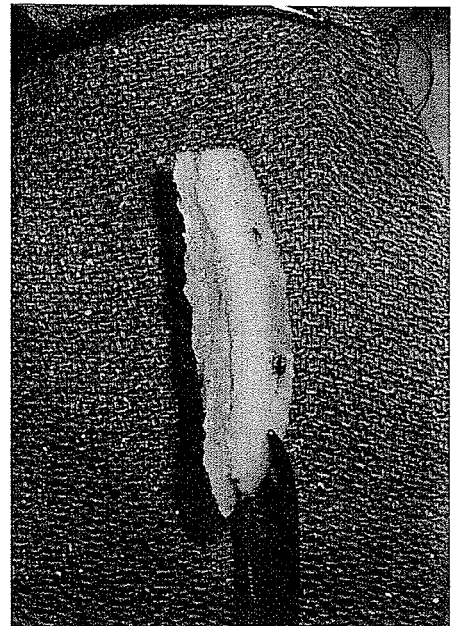
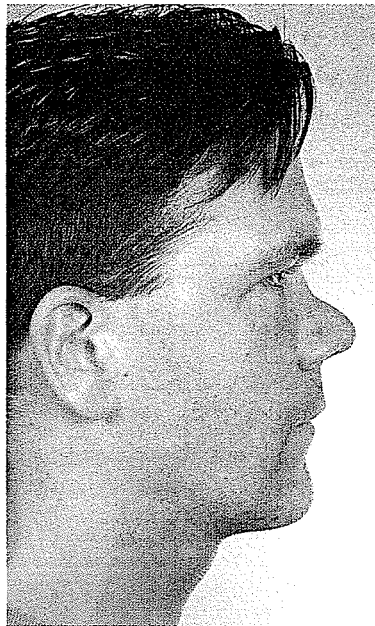
The recipient area for the bone graft is usually freshened with a rasp or burr. It is important to be sure that the under-surface of the bone graft to be inserted is flat so that it does not tilt. The lateral contouring of the graft is important because if there are sharp edges they can be seen through the skin. If the nasal bones are substantially narrow and a bone graft is supplied to the dorsum, it is necessary to place several layers of this diploic bone over the nasal bones themselves to give an adequate broadness to the upper portion of the nose.

It is usually not necessary to fix the bone grafts to underlying nasal bones with a screw or K-wire unless the nose is originally crooked.

The bone graft is thinned and tapered as it goes into the area of the upper lateral cartilages and probably acts as a spreader graft to a certain extent since patients usually experience improvement in their breathing. We try not to run the bone graft into the nasal tip since it is hard and is going to either resorb or come through the skin."

This case by Wolfe has an ideal defect for cranial bone. A 27-year-old male with the history of a childhood infection of the nose presented a dorsal bridge collapse. Two attempts at

conchal cartilage grafting of the dorsal defect had failed. Under local anesthesia Wolfe harvested two segments of cranial bone from the right parietal region. These two struts were held together with a microscrew and the edges burred for appropriate contour. Bilateral transvestibular incisions provided access to the nasal dorsum allowing insertion of the two-layered cranial bone graft. The incisions were closed carefully and healed excellently with replacement of like tissue with similar tissue in kind.



It should be noted that the scalp scar, if straight, will show as a parting in the short-haired male. Even with a zig-zag incision which partially confuses the hair, in the short-haired patient the scar may be apparent.

For serious total nasal bridge and tip support I prefer costal cartilage and have been using it for 40 years. It is essential, however, to understand the nature of this material.

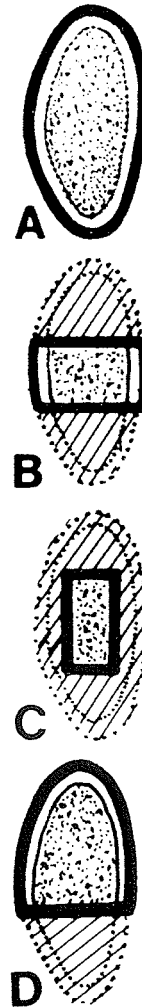
#### HOW TO CARVE CARTILAGE FOR NASAL GRAFTS

Living autogenous cartilage does not absorb, but it earned a bad reputation by warping after implantation. A number of surgeons experienced postoperative curvature of their cartilage grafts. This prompted T. Gibson and W. B. Davis to perform in vitro experiments to determine the cause of autogenous cartilage warping. The cartilage used for study was obtained during operations or from young, fresh cadavers. (Cartilage cells have been found still viable 72 hours after somatic death.) Gibson and Davis reported some interesting findings in 1958. It was noted that an immediate curvature occurred when a thin slice is pared from the surface of an intact rib segment, the curve being concave toward the perichondrium. If the perichondrium is first scraped from the surface, then slices bend in precisely the same way. If serial slices are cut, only the most superficial one bends, the underlying pieces remaining flat. If a series of incisions is made across the concave surface, all tendency to bend is abolished and the slice becomes flaccid. Similar incisions on the convex surface merely accentuate the curve. It was deduced from this that it is not perichondrium that is responsible for the bowing of the cartilage, rather it is due to a difference in tension between the outermost layers of cartilage and the inner zone. They likened a cartilaginous rib segment to a tight-skinned sausage, the skin representing the outer cartilage layer. Microscopic examination of a cross-section of rib cartilage shows that the peripheral chondrocytes are flattened in a plane par-

allel to the surface, and this may well indicate lateral stresses in this situation. Rib cartilage grows by proliferation of peripheral cells in a centripetal direction and also by cell division in the central zone itself. There is therefore a tendency toward increased tension in the central zone, and this is restrained by the tautness of the outer layer. An intact rib segment has these forces nicely balanced and its shape is stable. When cut or carved the matrix tends to expand while the outer stretched layer contracts; thus warping occurs.

In their search for a method of obtaining stable grafts, Gibson and Davis found four basic balanced cross-sections.

- A. An intact surface layer surrounds the cartilage.
- B. The surface layers are removed from two opposite sides, leaving the remaining cartilage balanced.
- C. The surface layers are removed from all four sides of the graft. Although it is not advised that a complete rod should be cut in this way, this is a useful cross-section for certain parts of the graft, particularly the ends.
- D. Cartilage is removed from one side only of the rib segment, leaving a deep D. At least one-half may be removed before bending occurs, but the amount varies with the cross-sectional shape; more may be excised from a flat rib than from a rounder section. Taking a similar mass from the flat surfaces of a rib segment invariably results in the distortion of the remainder. To retain stability it is essential that every cross-section of a cartilage graft should conform to one or another of these basic patterns.

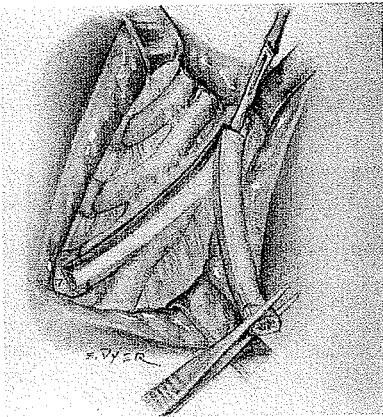


Gibson and Davis reported on 46 grafts carved in accordance with their rules and inserted as support for whole nasal bridges. Over a period of up to 3 years no graft twisted or absorbed.

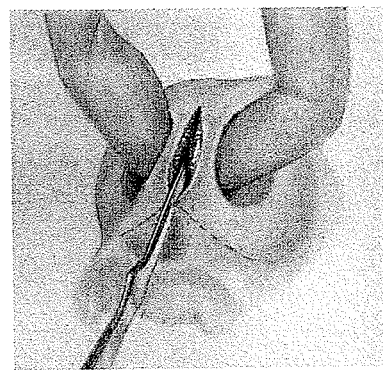
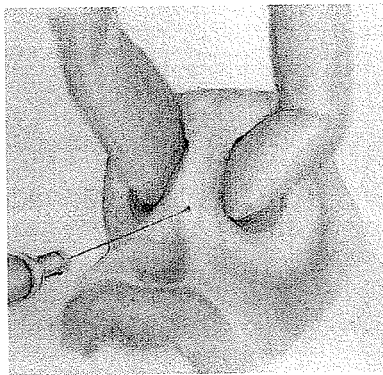
These findings established the basic truth that cartilage will curl away from any area where its surface tension has been released. In 1968 H. J. H. Fry adopted the same scoring

procedure to septal cartilage with correction of deviations and shaping of grafts. Many surgeons have adopted this same principle in otoplasty, the first being A. M. Cloutier in 1961 and V. Chongchit in 1963. Furthermore, when using septal or auricular cartilage in rhinoplasty this same principle should be constantly in mind and use. Of course the morsellizer is the great equalizer of cartilage surface tension and may explain its popularity when preparing amorphous auricular cartilage grafts for the nasal tip.

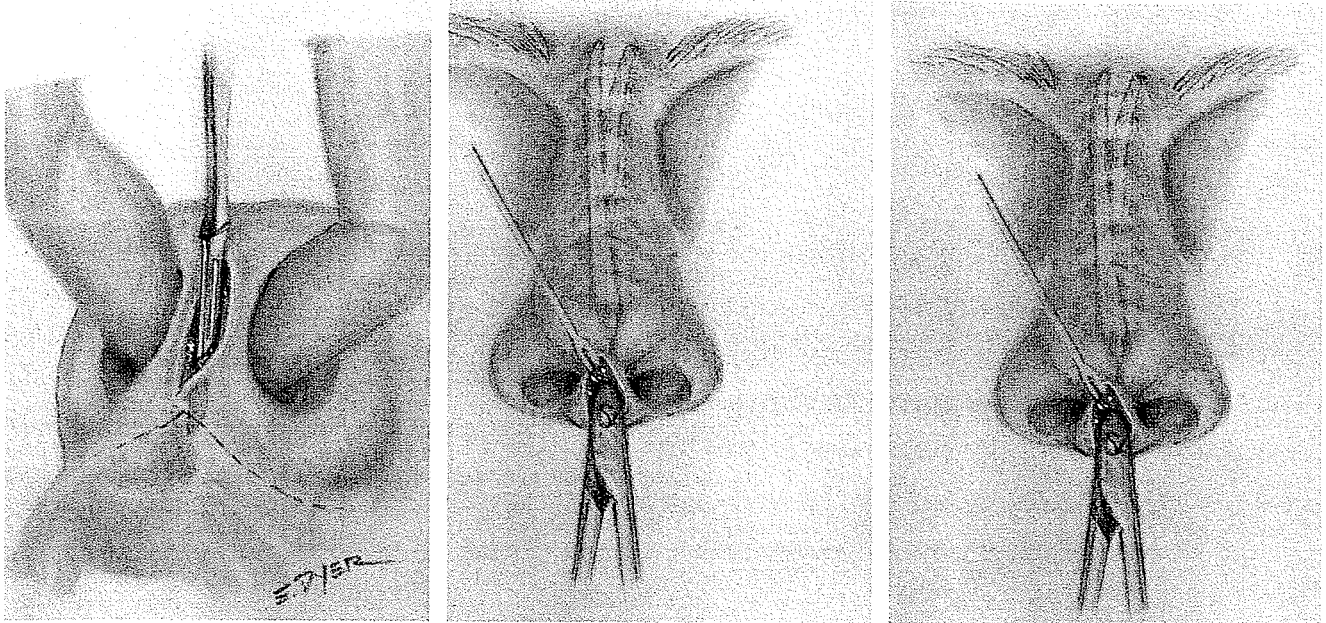
### *Hinge Graft*



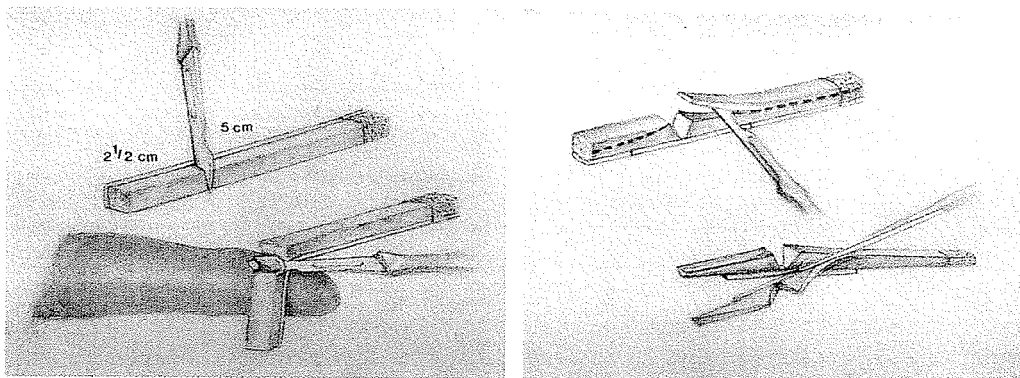
When the entire nose requires overall skeletal support and the lining and covering are sufficient and elastic enough to rise to the occasion, then my preference is a costal osteochondral perichondrial hinge graft. The principle of the hinge graft was conceived by H. D. Gillies and described by him and me in 1957. I have added a bony portion to complete the principle of "like tissue" and have found the technique an asset in several types of skeletal deformity where the bridge is flat and the total nasal profile deficient. This graft is true to the principle providing bone to approximate the nasal bones but also extends the rest of the way as a flexible cartilage cantilever ending with a perichondrial hinge at the tip providing a distal propped cartilage strut for the columella, enforcing a graceful lift in the nasal tip.



This hinge graft is best introduced through a columella splitting incision. First the columella is expanded with local injection and then is taken between thumb and index finger. A vertical incision can be used to split the columella, taking great care not to perforate either side. Once the pocket in the columella is deep enough to house the distal strut and allow it to rest upon the nasal spine, then the dissection is carried along the bridge to the nasal bones. Here a periosteal elevator is used to expose fresh bone for a bed for the bony part of the bridge graft. The pocket dissection is extended up on to the glabella for practical reasons.


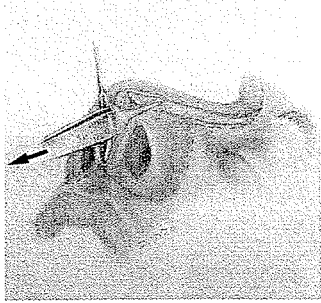


Ideally the costal graft should be taken one-third bone and two-thirds cartilage. The perichondrium is preserved over the last 5 cm of cartilage so that when a wedge is cut from the under surface of the cartilage the hinge joint is maintained by the tough perichondrium. Once the graft has been carved to




specifications of length and cartilage shape of Gibson's D to balance surface tension, its introduction takes a little care in technique. With the bony part first the graft is inserted into the split columella and guided into the pocket prepared on the bridge. The graft is pushed beyond its final destination up into the glabella area so that the 4 cm or less distal hinged strut in an open angle can be eased through the split columella and down to the nasal spine. Then with Adson forceps

carefully catching the sides of the graft just proximal to the hinge, the graft is slid down into a normal position with the hinged joint in the tip and at 90 degrees. The upper bony part of the bridge graft can be fixed with an external pin or through a 1/2-cm incision with a screw to the underlying nasal bone or it can be left to rest on the bone. This osteochondral perichondral hinge graft as a propped cantilever is efficient in both bridge and tip support. The bone will attach to bone and the remainder of the cartilage graft will retain normal flexibility in the distal bridge and tip.



As a child this patient stuck a pencil in his nose and broke it off. The imbedded lead evidently resulted in a chondritis that dissolved his total septal cartilage. This not only caused failure of normal projectile growth but allowed gradual flattening and spreading of the entire nose.


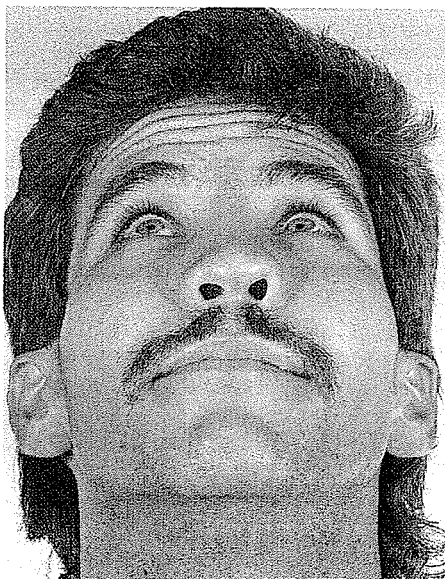

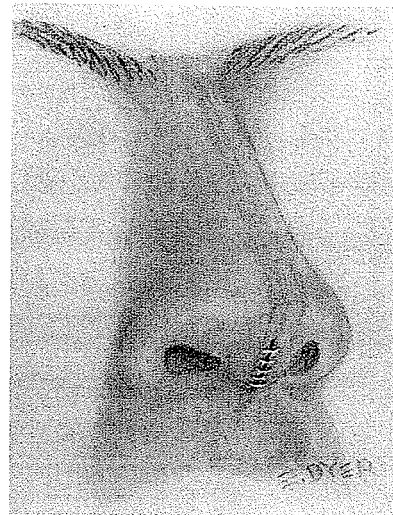
The patient had a bone graft placed on his bridge at age 18 years without great benefit.



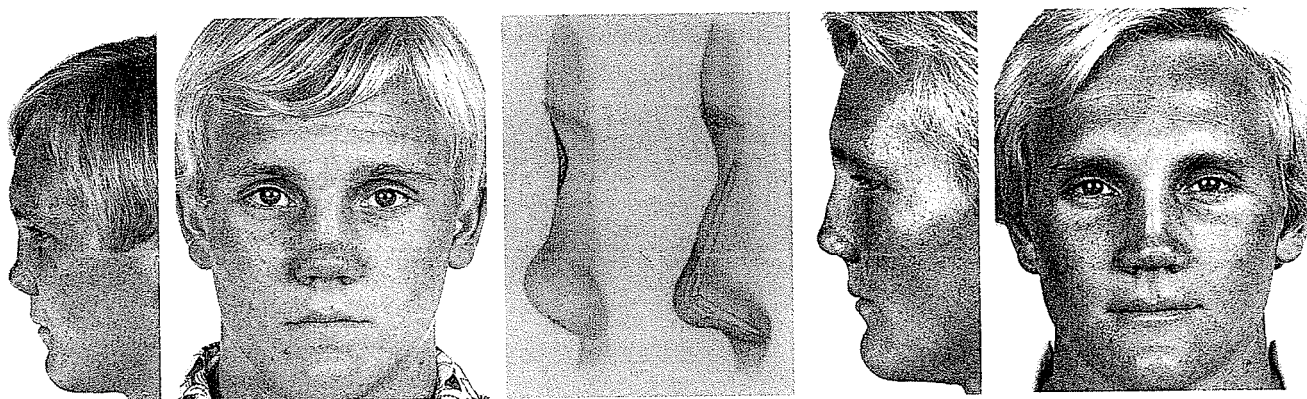


When seen at age 36 years he had a flat, wide nose. Through a columella splitting incision a pocket was developed along the bridge and down the columella to the nasal spine. The pocket was over-extended up to the glabella area to allow insertion of a hinge graft. The old bone graft was removed.

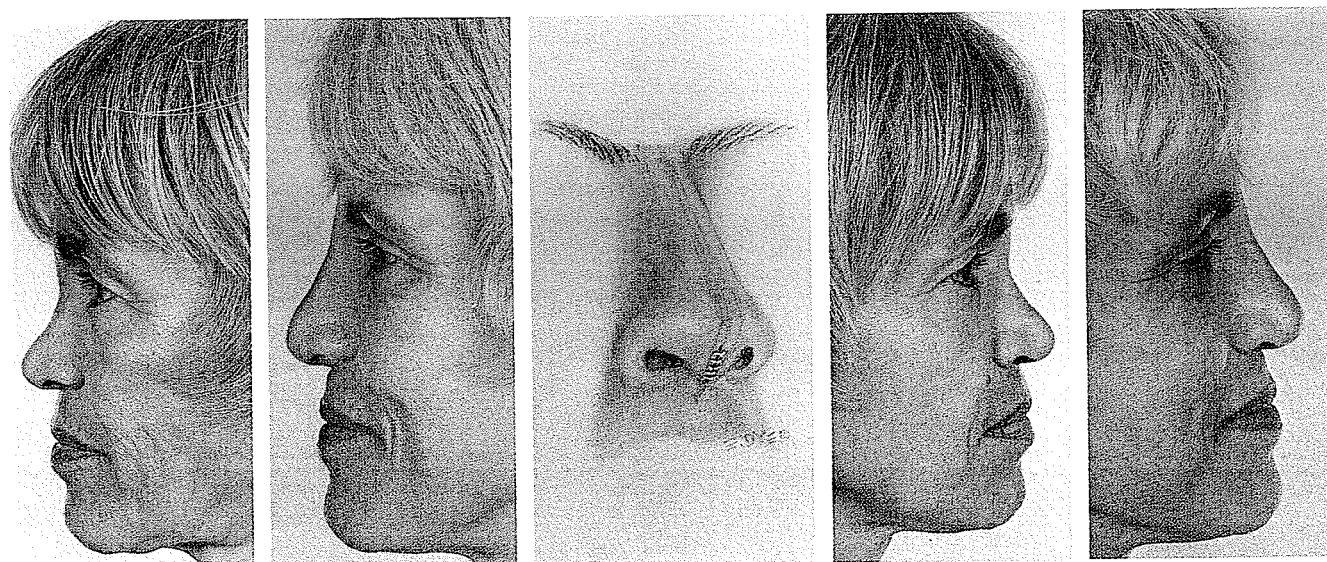
From the patient's seventh left rib an osteochondral perichondral hinge graft was carved to specific shape, 5 cm bridge, 3 cm columella. The graft was inserted along the bridge up to the glabella to allow the columella strut portion to be eased down the columella to the nasal spine. Then the graft was grasped just proximal to the hinge and pulled down so that the point of the hinge joint was projecting in the tip as a propped cantilever. The columella split was closed with subcutaneous sutures of 4-0 catgut and 6-0 silk to skin. The excessive alar flares were reduced by alar base wedge resection.



This case shows that when the injury occurs early in life and retards normal growth then the surrounding structures such as skin and lining are never stretched sufficiently. Thus the result of adding only support has some limitations as seen in this male who suffered a crushing injury in early childhood. By shaving down the upper bony root of the nose a hinge graft could sit reasonably well and improve the profile.

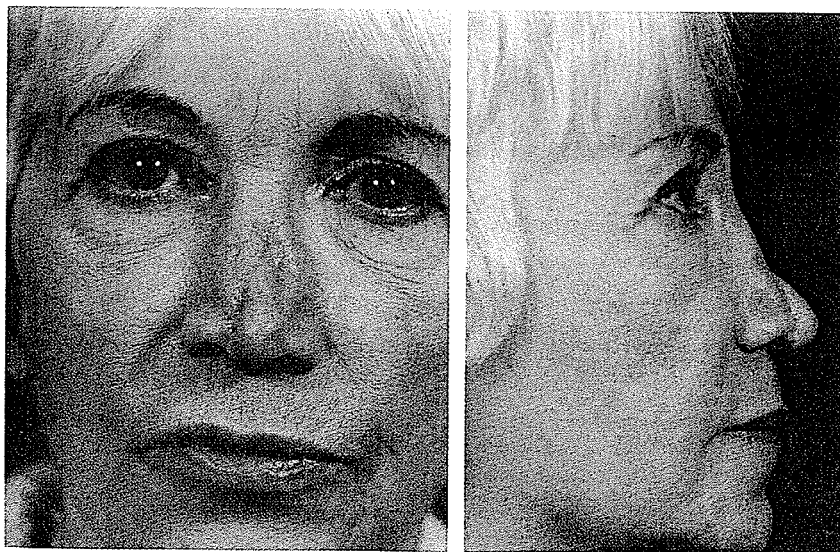

This 52-year-old woman had had a rhinoplasty 30 years before with loss of an important part of her nasal bridge. An osteochondral hinge graft inserted through a columella splitting incision brought back the integrity of her nasal profile.




This 57-year-old woman had a small lesion of the skin near her right medial canthus. She requested the surgeon shorten her nose at the same time he removed the lesion. Excision of the basal cell carcinoma was reported inadequate and her nose healed with asymmetries. Three months later the lesion was completely excised and the nose reoperated, including a submucous septal resection and anterior septal resection. As this still did not correct the problem a silastic implant was inserted. Infection, septal chondritis, and cartilage dissolution ensued, resulting in nasal collapse with multiple furrowing of the skin covering.

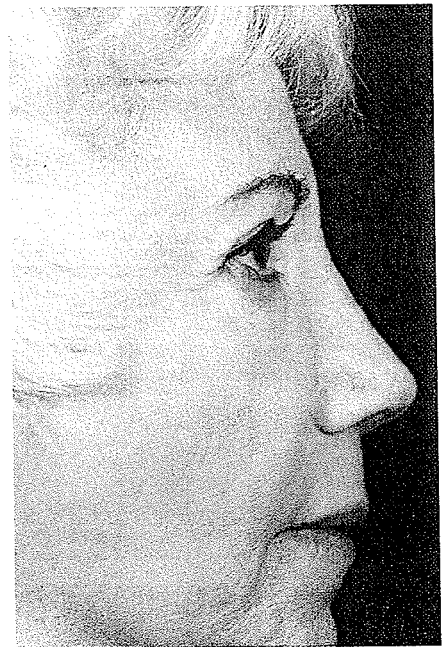
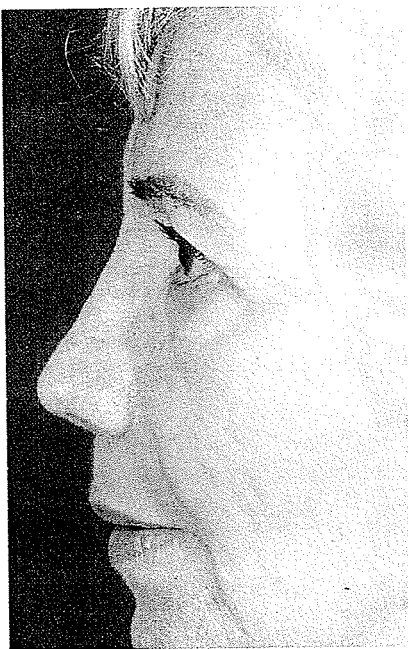In principle, in the presence of a possible malignancy, it is better not to combine tumor excision with a cosmetic correction—unless the reduction facilitates an otherwise difficult to impossible defect closure. As it turned out here both the primary excision and the corrective rhinoplasty were unsuccessful and both required repetition. The secondary rhinoplasty, three months after the initial procedure, was too early for radical work; the insertion of a foreign body as a “last ditch” effort is often done, but rarely successful. The infection that followed was unfortunate and devastating, but almost predictable. The patient was forced to wait a full six months for healing.



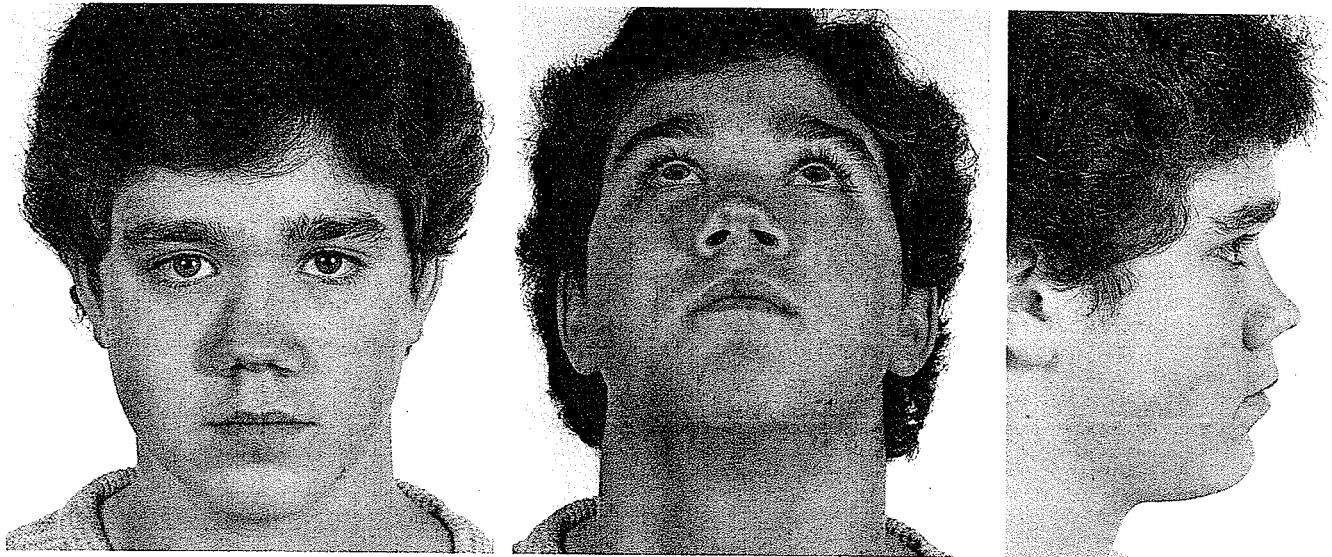
It was obvious that more than one operation would be necessary. The first procedure was designed to set the stage for the repair. Through anterior vestibular incisions, the alar cartilages were reduced and the irregular skin covering was freed from its scar adhesion taking a bit of deep tissue with the skin in the areas of furrowing as previously described. A large nasal lining defect had to be replaced with an upper labial sulcus mucosal flap brought up into the nose to replace the missing lining. This smoothed the skin moderately but one severe anterior skin furrow required direct excision. Osteotomies with in-fractures narrowed the nasal base.



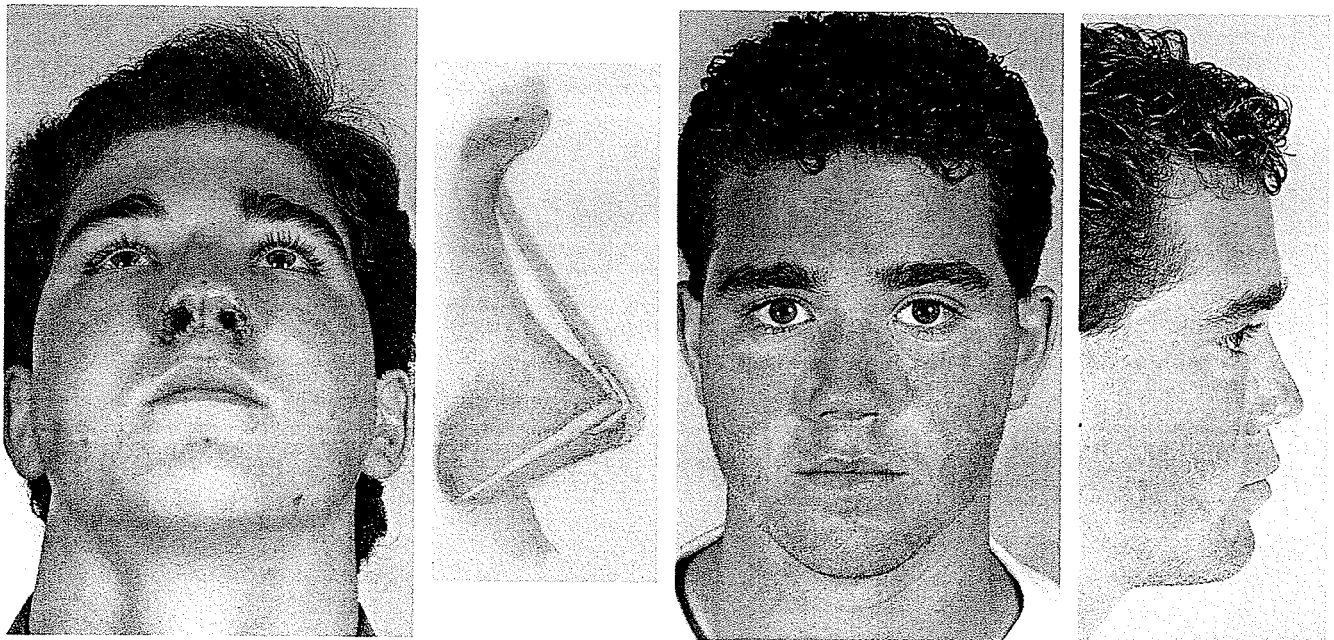
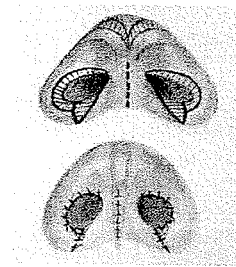
Eight months later, through a columella splitting incision, a costal osteochondral hinge graft was inserted. This reconstituted the classical L support and opened the airways. Several minor alar margin and base excisions completed the secondary reconstruction.



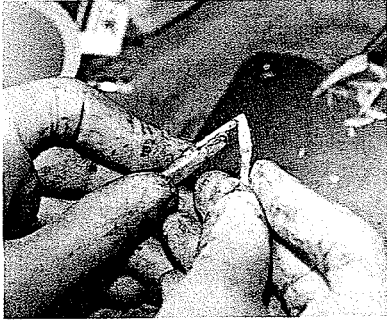
This 16-year-old male patient suffered a severe injury to his nose complicated by infection at the age of nine. The failure in nasal growth left the tip asymmetric, the alae flared and the bridge flat.



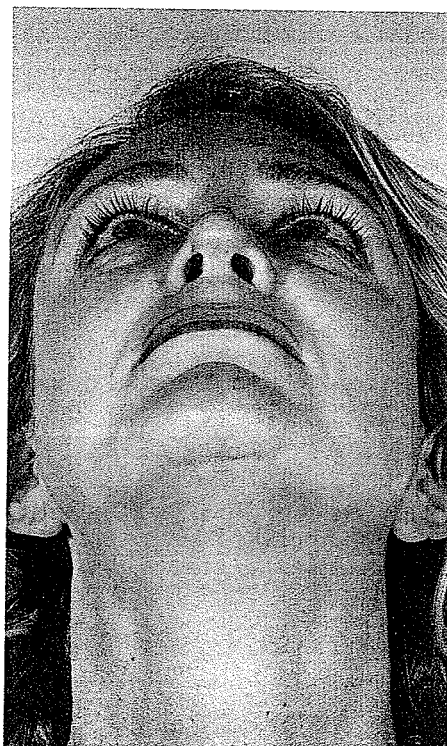
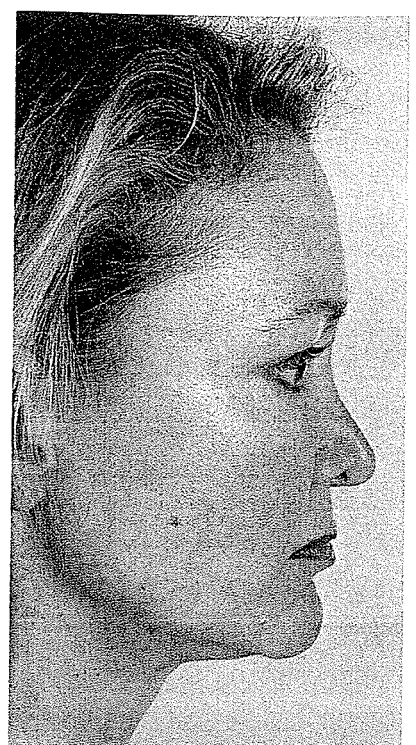
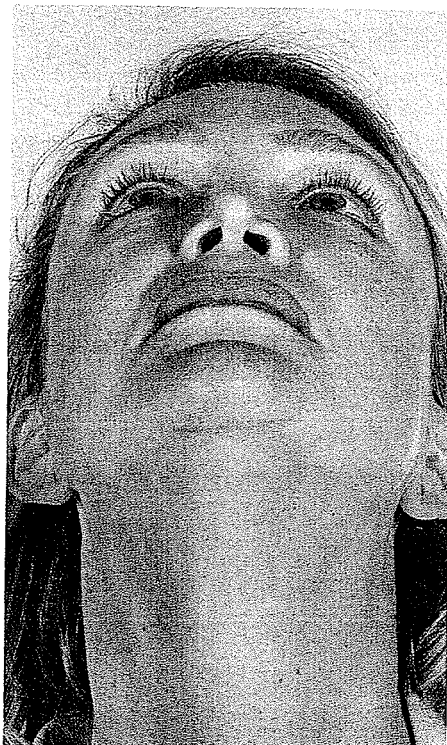

First stage reconstruction involved alar cartilage reductions, submucous septal resection of obstructions, and bilateral osteotomy with in-fracture. One year later a costal osteochondral hinge graft was inserted through a columella splitting incision to correct the bridge and tip. Alar margin sculpturing along with alar base reduction of the flare improved the result.



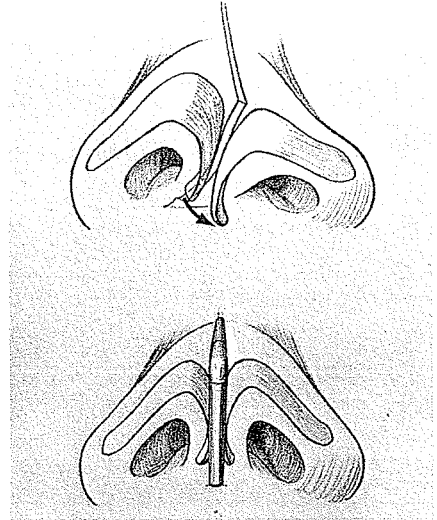
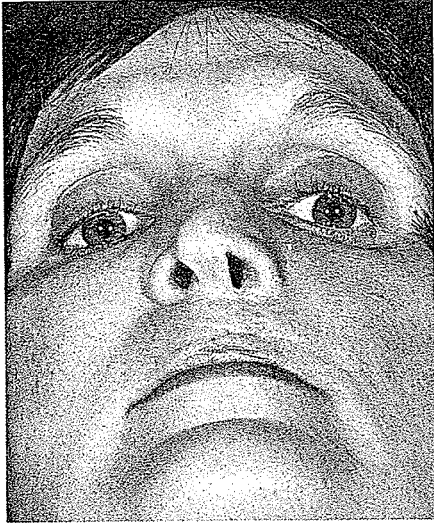
This 32-year-old female suffered blunt trauma to her nose with nasal fractures and injury to her septum. She underwent two rhinoplasties, including radical submucous resection of the deformed septal cartilage. The result of these multiple traumas was a partially collapsed nose with a depressed bridge, pinched tip, retracted columella, and difficulty with breathing.



The general sag of this nose is the result of loss of skeletal support; the proverbial L is insufficient in its peripheral dimension. Thus the best overall solution seemed to be a costal osteochondral hinge graft 5 cm for bridge and 3 cm for columella introduced through a columella splitting incision. This supplied the extra lift to the entire nose through the L-shaped propped cantilever. The profile was elevated, the columella and tip supported, and the breathing improved. Note the invisibility of the columella splitting incision, a far better scar than the popular transverse scar across the columella.




A hinge graft can be used to camouflage a severe nasal deformity in a cleft patient. This 41-year-old female who had a LeMesurier lip closure in infancy presented such a severe nasal distortion that the usual procedures were by-passed.

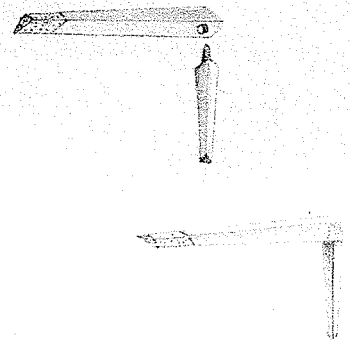




The septum was partially straightened to improve breathing. Then through a columella splitting incision a costal osteochondral hinge graft was inserted on the bridge and down the columella to camouflage the deviations beneath by onlay contour.



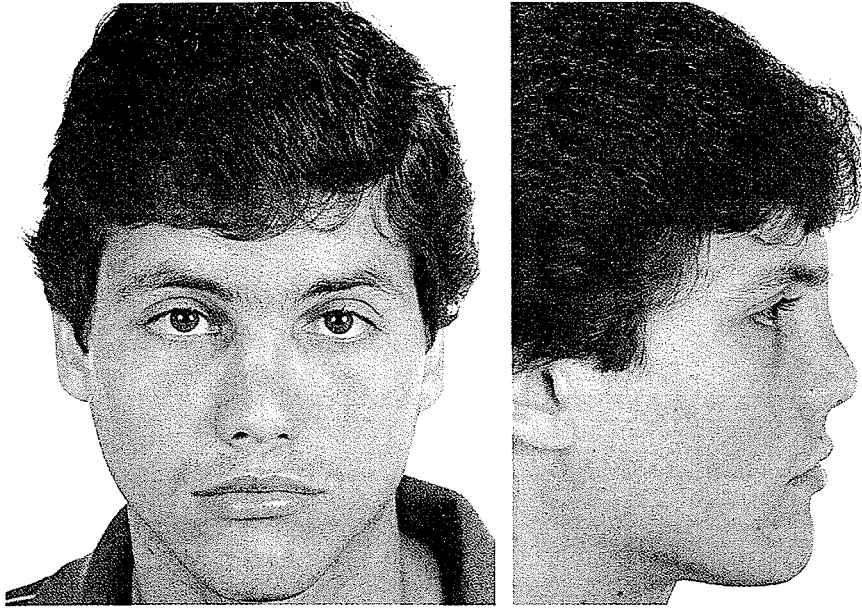Of course there are occasions where simple cartilage grafts will suffice. A distal bridge support or a columella strut or the combination of both may be required. In these cases septal cartilage may be adequate, and, if not, then costal cartilage is available. An even more maneuverable propped cantilever can be constructed with a 5 cm costal cartilage bridge piece with a hole drilled under the distal surface. This will accept and interlock with a 3½-cm pointed costal cartilage strut in the columella.



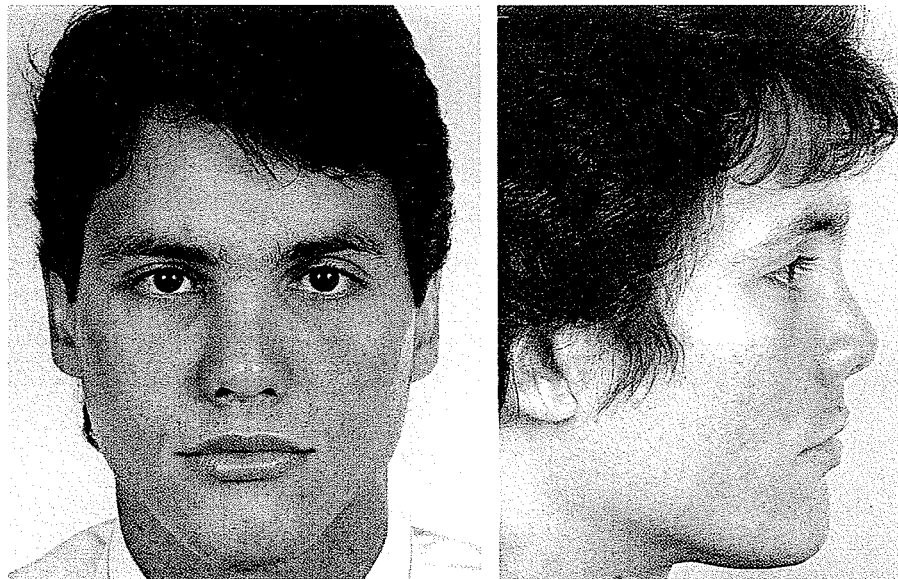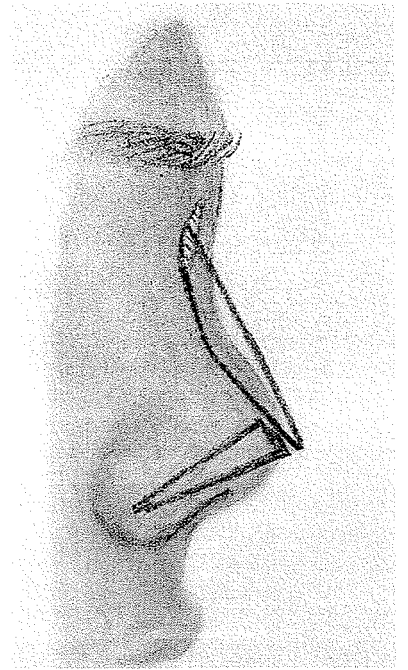
This 25-year-old Cuban male had a history of nasal trauma. The septum was deviated and the bridge was high, coming off the forehead in the Roman style. I planned a submucous septal resection and conservative correction of his bridge line.



The next time I saw him was after an ENT surgeon had radically removed his septum and lowered his bridge. In time with the loss of support the nose had settled and shrunk with gradual contracture of the skin and lining, rendering it resistant to correction.



After one year of healing, a two-piece costal cartilage graft was used to improve his skeletal support. Through a stab at the base of the columella a pocket was dissected up the membranous septum to the nasal tip. Into this tunnel a costal cartilage strut, which was wider at the top to force the nasal tip to tilt down slightly, was inserted. Through an anterior vestibular incision a pocket was dissected under the skin of the bridge. The excess bone of the nasal root was reduced with a chisel. Then a specifically shaped costal cartilage strut was inserted as an onlay for the bridge, resting on the flat top of the columella strut.



It is interesting that in 1994 R. K. Daniel advocated for secondary rhinoplasty a two-piece costal cartilage graft, one in the columella and one on the bridge. He suggested that where the two ends meet in the tip that they either not make contact or they be locked to each other in a tongue-in-groove. Neither is as effective in tip lift as the hinge graft. He executes this procedure through open rhinoplasty. It is far better to introduce these cartilage struts through a columella splitting incision as it is safer and more efficient. When the skin surface tension from lip through columella to the tip is kept intact, the tissues are better able to respond normally to the upward stretch of the columella strut.

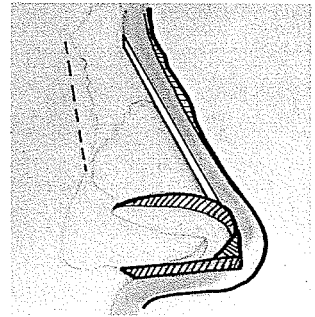
#### SEPTAL CARTILAGE TO BRIDGE

Septal cartilage for nasal bridge augmentation is excellent when the depression is not too great. It is effective as an onlay to disguise multiple irregularities and produce a clean profile line.

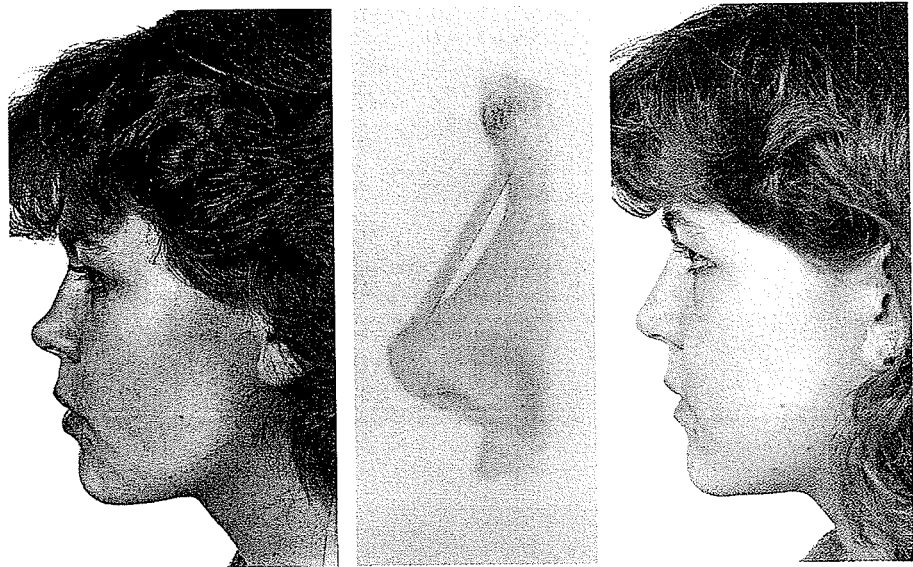
This 34-year-old man had severe trauma to his nose with bone fractures and septal crushing. This was followed by a rhinoplasty which resulted in irregularities of the tip cartilage, deviation of the septum, and an irregular bridge line. The nose was also too long.



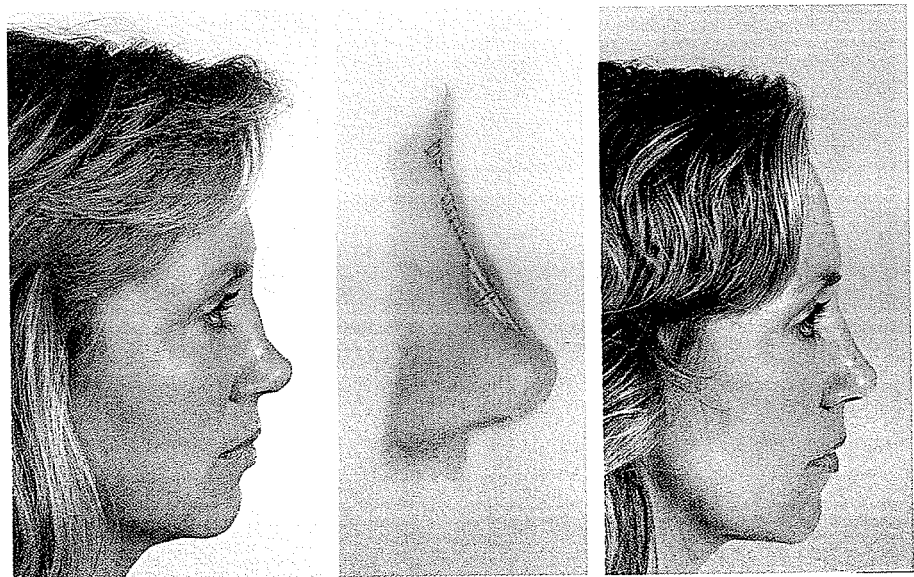
The alar cartilages were equalized by specific resections. The anterior septum was shortened by resection of a rectangle and then a golden triangle. The bridge was smoothed to level the playing field. A submucous septal resection supplied cartilage for a long bridge strut which when sutured in position improved the height and straightness of the profile line.



This secondary bridge deformity revealed too much resection of the septal bridge and too little bony resection. The correction required shaving the bony excess and augmenting the septal ski jump with a septal cartilage strut.



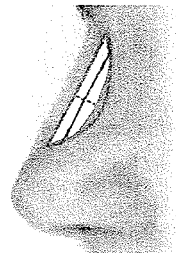
This 44-year-old female is seen after reduction rhinoplasty with excessive bridge reduction. A two-tiered septal cartilage graft was inserted on the bridge with definite improvement.



This is the typical supratip exaggerated by over-excision of the bony hump. First the tip deserves more alar cartilage

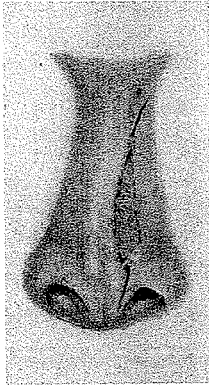


reduction and the distal bridge deserves lowering. Then following a submucous septal resection a two-tiered cartilage graft along the bridge brings some harmony back to this nose.

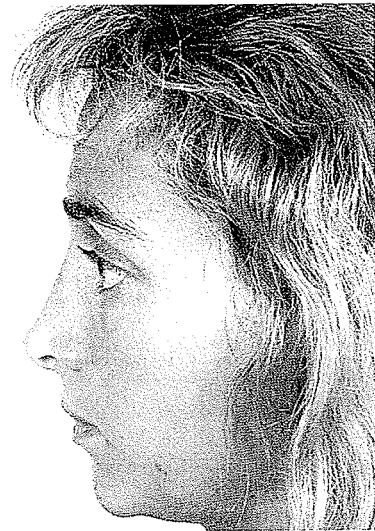

*Asymmetric Grafts for Symmetry*

This 28-year-old female had an injury to her nose which several months later was treated with a rhinoplasty and submucous resection. Twelve hours postoperative she was struck from the left side with the resultant asymmetric deformity.



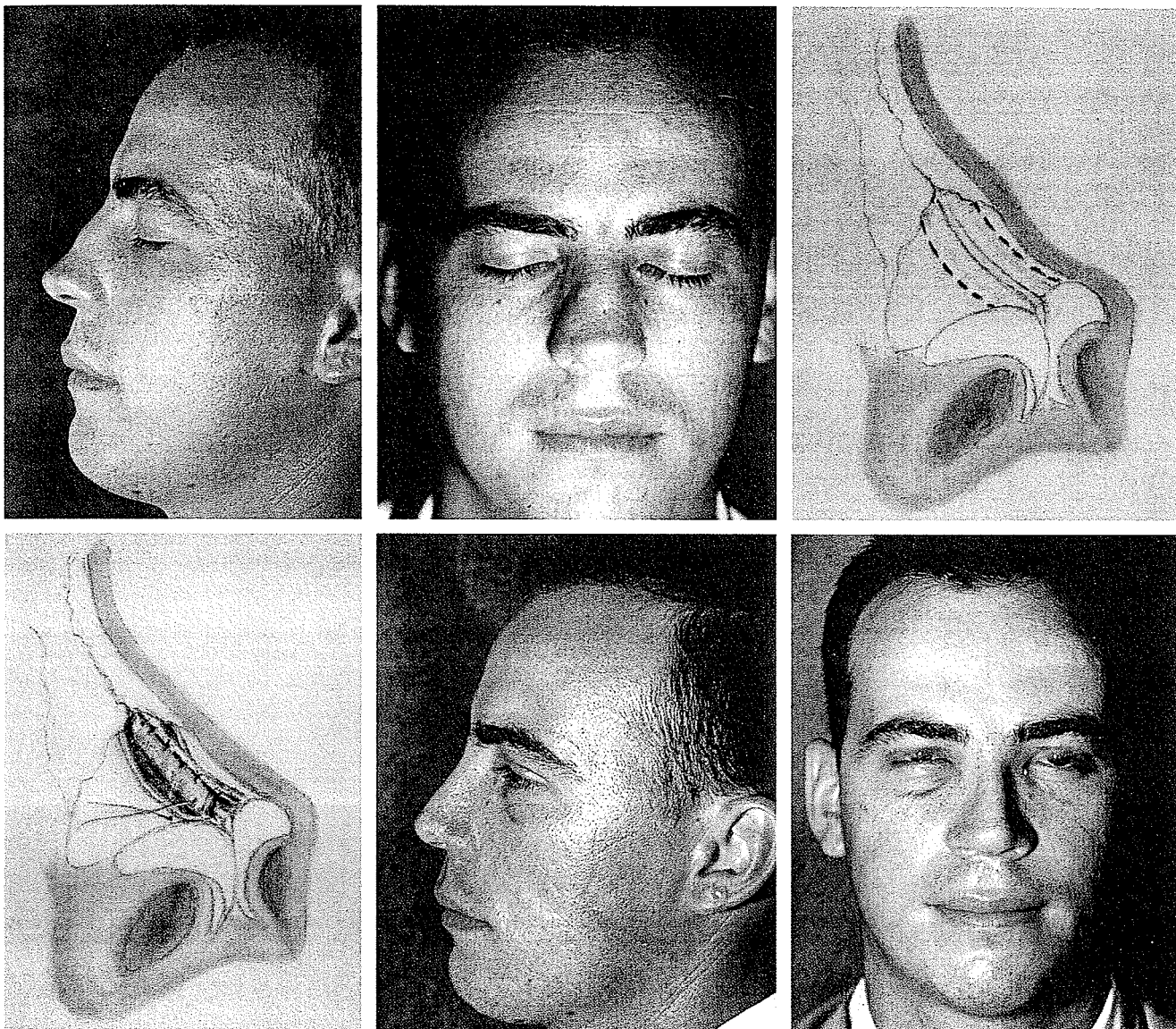
A submucous septal resection obtained cartilage and reduced the obstruction but the septum was too scarred to allow perfect straightening of the nose. A septal cartilage graft was inserted along the left side of the bridge. A right septal chondromucosal flap based superiorly and denuded of epithelium for 0.5 cm was threaded across the septum and into a left lateral anterior vestibular incision to bolster this flatness. Bilateral osteotomies with infracture improved the overall effect.





*Using Local Tissue for Bridge Enhancement*

In a rare case the turn-up of sidewalls may give bridge enhancement. This young male had a flat bridge in the supratip area. The mucosa and upper lateral cartilages were divided, turned up and sutured to each other and the lateral walls allowed to advance medially. The early result was good but I

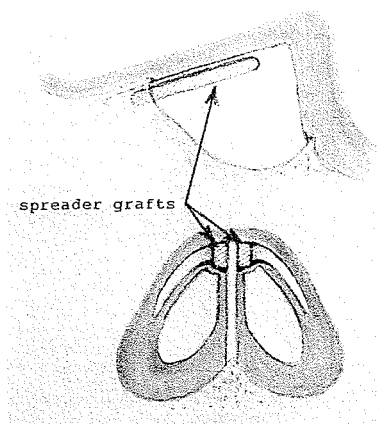


never saw the patient again and he was operated 44 years ago. Could he be that pleased?!

*Spreader Graft*

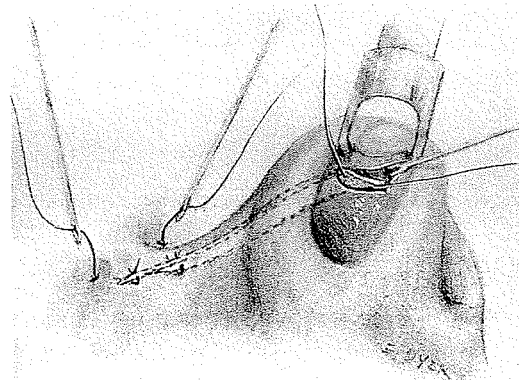
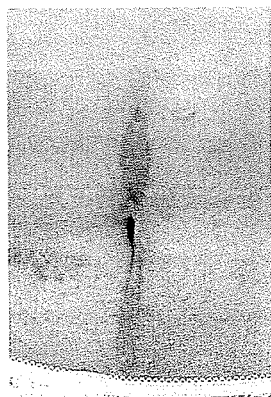
There is an inverted V deformity associated with middle vault collapse occurring when its roof has been over-resected. In

1987 J. H. Sheen proposed the spreader cartilage graft to counter the effects of an excessive dorsal resection. Although Sheen presented this method originally for primary rhinoplasty he soon found it also useful in secondary rhinoplasty. He warned that the bridge should have sufficient height and there should be adequate tissue along the anterior septal edge to allow dissection of an appropriate pocket and enough autogenous material for the grafts. I have not had occasion to use this graft more than a couple of times but it certainly has merit. There is a chance that these grafts may cause the bridge to be a little too broad. The inverted V deformity can usually be effectively treated by adjusting the bridge and moving the bony sidewalls medially into better position with in-fractures.



#### *A Dermal Overlay*

This 26-year-old female is seen after several rhinoplasty procedures. The keel effect of the bridge was too acute and skeletal looking. The patient had an abdominal scar so a dermal scar strip 6 cm × 2 cm was fashioned and inserted with external fixation sutures to cloak the keel bridge. The dermal graft cushioned the sharp bridge ridge as seen after two months



and again at one year. This is a procedure to cover a sharp skeletal line when the skeletal structure is adequate to make



further contouring unwise. This dermal graft could *cloak the sharp edge* that often is seen after *cranial bone* grafting.

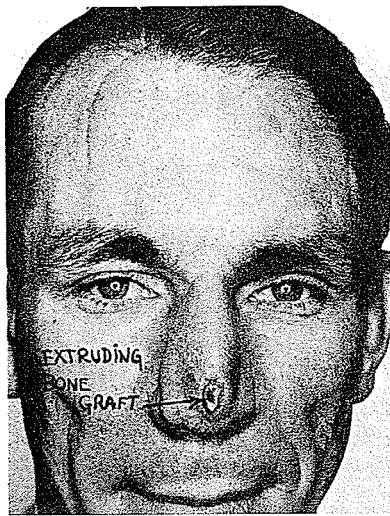
#### SILASTIC NASAL BRIDGE IMPLANTS

Although I favor autogenous grafts over foreign body implants to the nose there are certain circumstances where silastic may be first choice. I probably use one silastic for every 20 autogenous grafts.

The advantages of the inert silastic implant are its dependable straightness after carving, absolute lack of absorption, absence of reaction, easy obtainability, and avoidance of secondary donor morbidity, deformity, and scars. Its use bypasses guy wires, aseptic necrosis, and conchal deformities. Yet the rules governing the use of silastic foreign body implants must be rigidly followed.

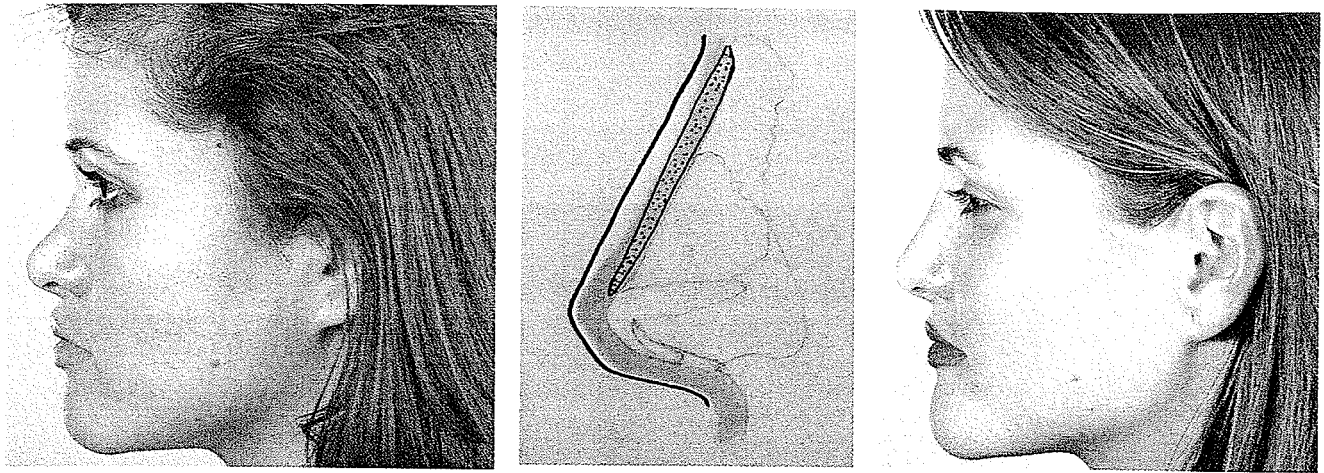
This implant should be used only as an impassive contour provider. The platform onto which it is placed should be level or corrected so to accept the implant. This ensures that the implant will lie quietly on its bed without chance for see-sawing motion. The cover should be normal skin and subcutaneous tissues. The pocket for the prosthesis should

be dissected straight with tailored accuracy for a snug fit and not haphazardly undermined to allow shifting. The external entrance of the pocket for the silastic implant should be at least 1 cm and preferably 2 cm distal to the implant itself to allow soft tissue closure of the entrance to the prosthetic pocket. This prevents later extrusion or exposure and infection. Yet this necessary extra longitudinal length of the pocket does make it possible for the implant to slide up or down. Thus it is wise to fix it with one suture of 4-0 Prolene.

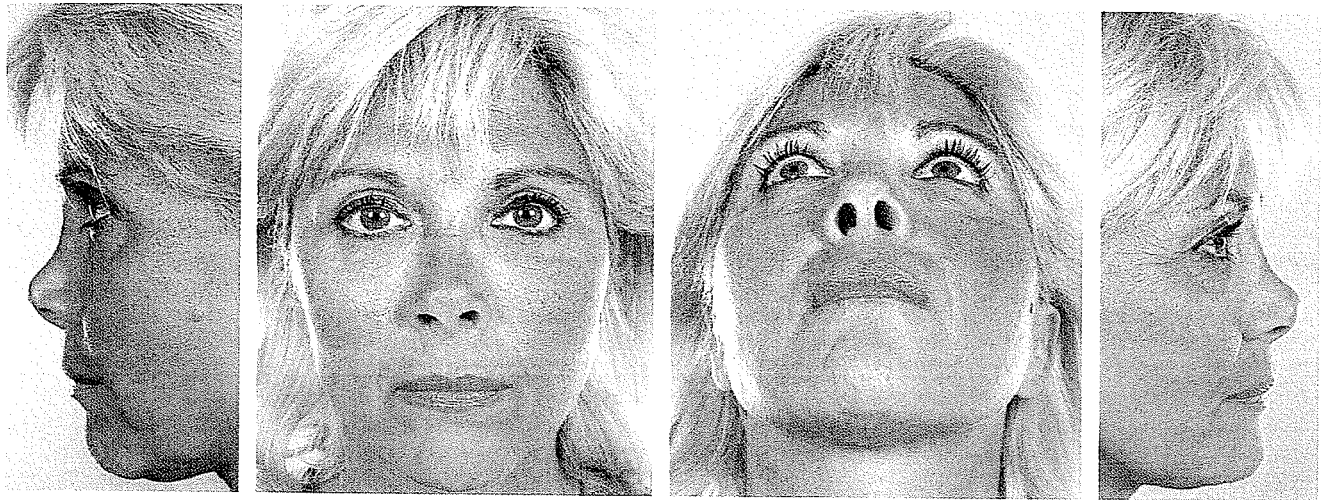


The silastic implant should not be asked to do any work such as active tip support! Any rigid strut in the columella to lift the nasal tip is treacherous and even when autogenous cartilage is being used the surgeon must be on the lookout for the danger signal of a persistent white (avascular) pin point in the tip skin caused by too much thrust pressure. Here is an example of a rigid bone graft inserted in the columella to lift the flat nasal tip in a World War I case. The bone had penetrated the nasal skin. This undoubtedly has happened many times since 1918, and certainly modern silastic can be a silent enemy here that eventually will appear through a skin tip perforation. The thin tissues of the columella and the usual scarring which is partly responsible for the tip depression in the first place do not provide a happy bed for a silastic implant and therefore in my opinion should *not* be attempted. To avoid this I have used a combination of silastic to the bridge and autogenous cartilage to the columella-tip area.

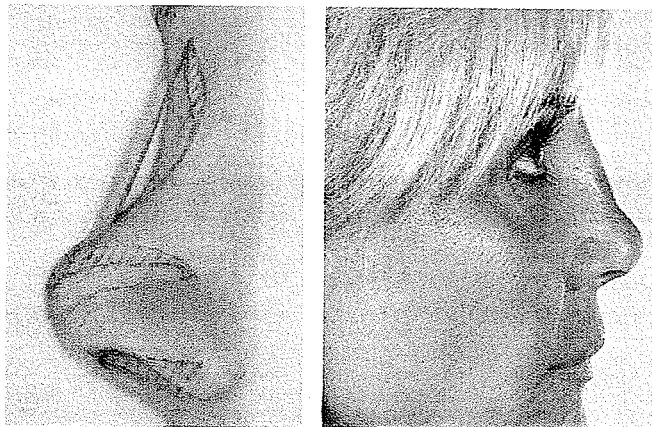
This 24-year-old female two years after corrective rhinoplasty including submucous septal resection revealed excessive loss of bridge. The over-zealous hump reduction destroyed the character of this nose. It was corrected with a specifically shaped 3.2-cm silastic implant inserted through a small vestibular incision just anterior to the point of the septum.



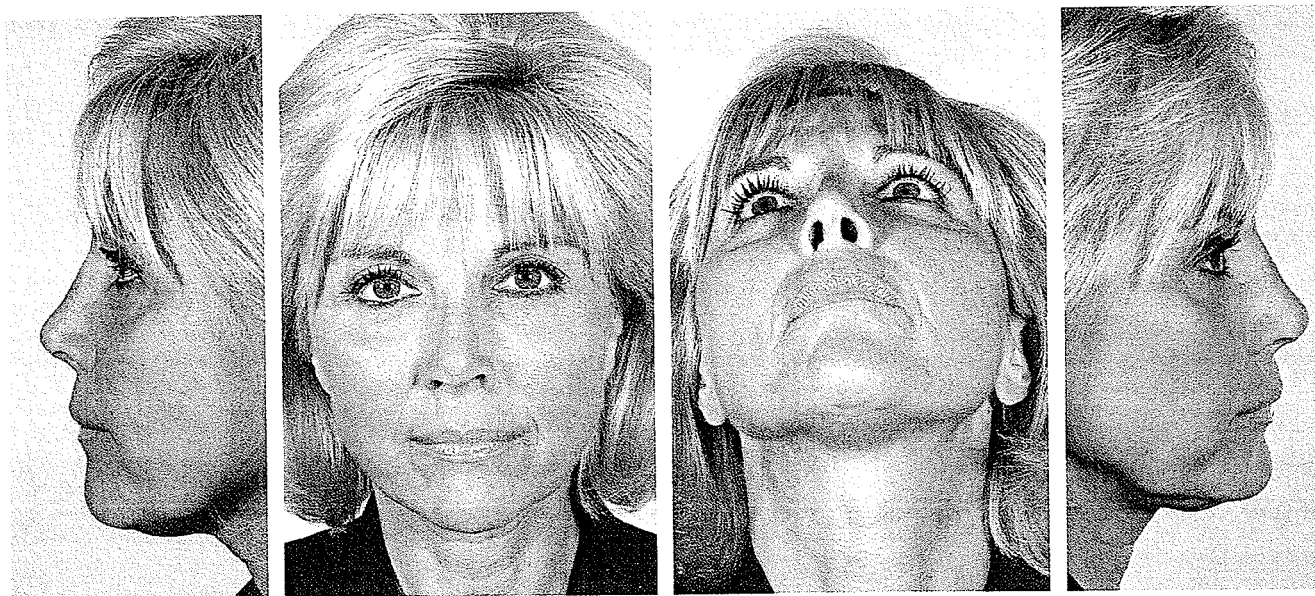
This 44-year-old female following rhinoplasty revealed a ski jump bridge with moderate pig snout tip tilt. Reduction of the excess alar cartilages tailored the tip and alar base



wedge resections narrowed the nostril flare. First insertion of a silastic strut was squeezed by constricting scar out of ideal position. Removal of silastic implant, reshaping and reinsertion



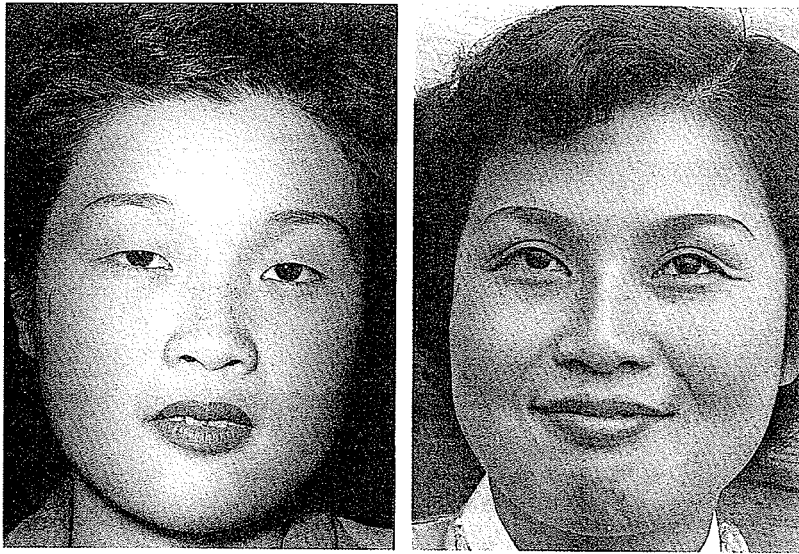tion with fixation to the septum with a Prolene suture corrected the deformity.



Thus, first it is important to pick the place for silastic implants and in my opinion, as already explained, only the bridge should be considered. Then it is advantageous to consider those cases I have found to be most adaptable to this approach. Those races often showing some flatness to the nasal bridge are the Oriental and the Black. Here there is usually no scarring, a good platform, and normal covering tissue. The simple insertion of a silastic implant to the bridge is effective and safe. Flat noses offer less septal cartilage anyway and the use of silastic costs only the price of the implant without the need to disturb a distant donor area.

#### *Foreign Body Implants 40 Years Apart*


In 1954 as chief plastic surgeon to the First U. S. Marine Division in Korea, I had the opportunity to carry out rehabilitation surgery on the natives. Among my patients was the wife of an international businessman who wished his wife to be Occidentalized, which he hoped would help in his trade relations. I created the upper eyelid double fold and inserted a homologous costal cartilage graft I carried in a bottle of Merthiolate to her nasal bridge.



In time I found that it took about ten years for the body to absorb homologous cartilage and so I turned to silastic implants. In 1994 an outstanding Japanese Fellow in plastic surgery training with us requested nasal bridge augmentation. A silastic implant was inserted on to her bridge and mentum.



Currently, there are several silastic implants available. I prefer the R. Straith implant but usually amputate the extended prong. For improvement in contour of the racially flat nose Korean plastic surgeon Ki-Il Uhm has an excellent model with a tip lift. Odd bridge problems can be treated with specially tailored silastic in rare cases.



Silastic implants placed on the nasal bridge in selected cases have served well. I recall several that slipped or drifted off center and had to be repositioned. This occurred because the rules outlined here had not been followed. I do not recall more than one or two of my silastic implants getting infected, but I have removed several placed by other surgeons that had become exposed in the vestibule:

I usually prefer to avoid silastic to the nasal bridge of the young patient, especially males involved in sports, for purely practical reasons. Here the activity over a long term may be more demanding, increasing the chance of injury with complications. In the older patient or those with a more sedentary life-style the odds for a continued happy result are improved.

Further examples of silastic implants inserted on the nasal bridge will be presented in the specific conditions where they have served well.


#### PARROT'S BEAK

The convex curve of the bridge and tip hooking like a parrot's beak is a rather common sequela of corrective rhinoplasty. Numerous causes of this deformity, each with its champion, have been conjectured and any or all can and do play a part. The most obvious cause is the failure to carve the septal bridge correctly, leaving a curved distal hump. Another cause is the piling up in this area as the thick skin of the nasal tip telescopes on itself when the nose is shortened. Aufrecht suggested extra scooping of the cartilaginous bridge in this area to accommodate the inevitable excess skin humping.

Safian blamed the overlap of the freed chondromucosal sidewalls on top of the septal bridge.

Peck has emphasized the importance of maintaining at least some intact rim of the lower lateral alar cartilages to ensure tip prominence over the septal bridge line.

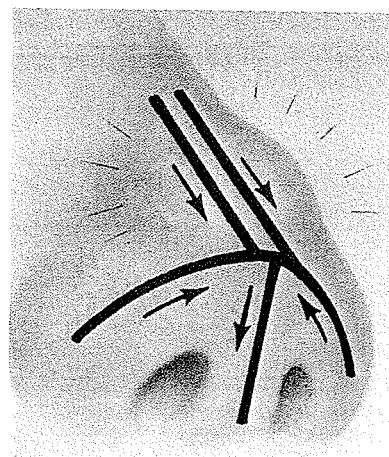
Rees accused the piling up of granulation and the following fibrosis in the supratip area. As the free edge of the septum can bleed severely, a postoperative hematoma with subsequent fibrosis is also a possibility.





It is important to note that this supratip deformity rises near the point of convergence of five incisions, and this indeed may offer further clarification. First, there is the vertical membranous septal incision which diverges bilaterally as vestibular incisions, either anterior vestibular or intercartilaginous. The dorsal skin undermining is a proximal extension of the vestibular incisions. Then when the sidewall lining is divided on either side of the septum two further incisions are made. If, instead of two anterior vestibular incisions, the surgeon used intercartilaginous and marginal incisions, he adds an extra two for a total of seven converging scars.

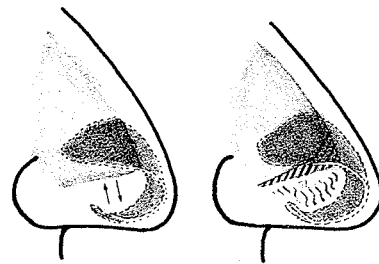
Whenever even three incisions meet at one point the scarring is usually exaggerated. In endorhinoplasty the hidden incisions are at different angles, converging to a central point, and, with contracture of each incision, a humping at the center could be expected. The membranous septal incision contracts, pulling the tip down, the lateral incisions contract, pulling the sidewalls toward the septum, and the sidewall incisions with the usual haphazard approximation add greater areas of humping granulation and subsequent fibrosis.

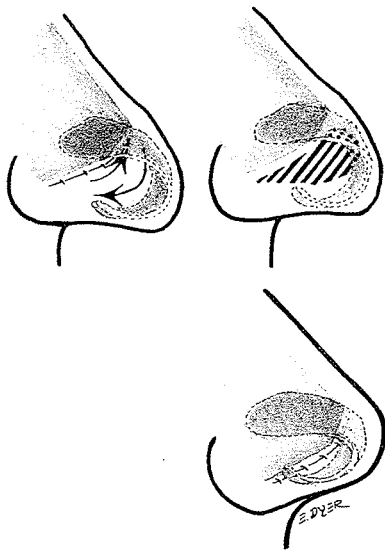


Our present modification of the maintenance of the "French Connection" (Eitner and Anderson) preserves the lateral mucosal attachments to the septum, while the septal cartilage of the bridge and upper lateral cartilages are shaved and tailored. This avoids two scars and the granulation and contracture associated with them. Under this regime the early postoperative tip swelling is definitely less and the amount of supratip swelling and humping has been impressively reduced.

#### *An Added Factor*

There is a greater tendency of hooked noses to "re-droop" postoperatively even after septal shortening. One reason is the preservation of too much membranous septum, which allows soft tissue play during laughing and crying with pull-

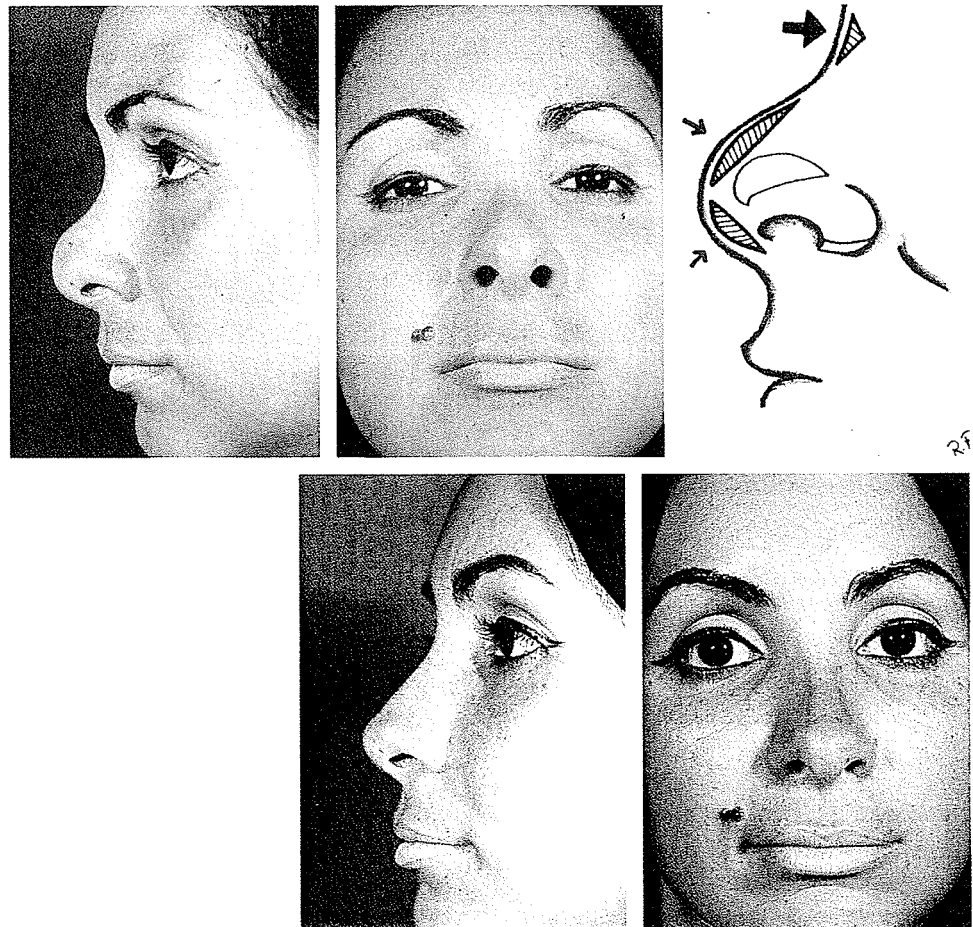




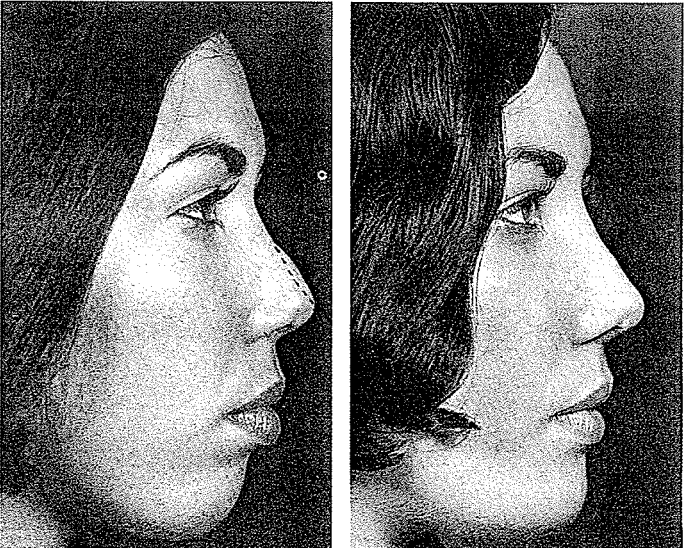
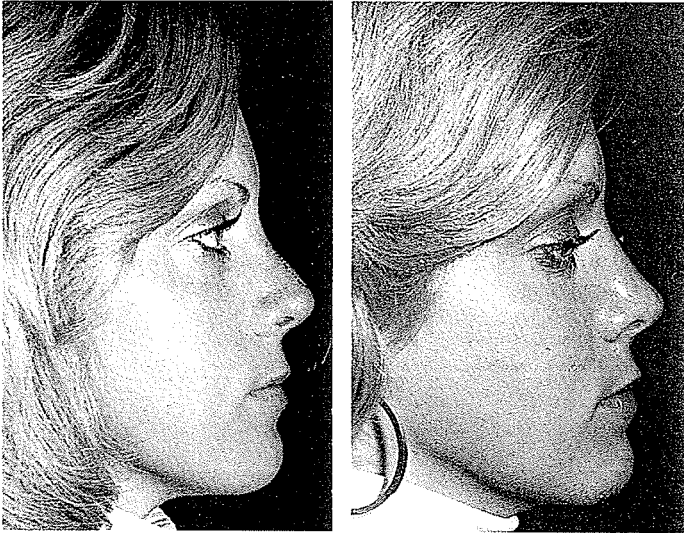
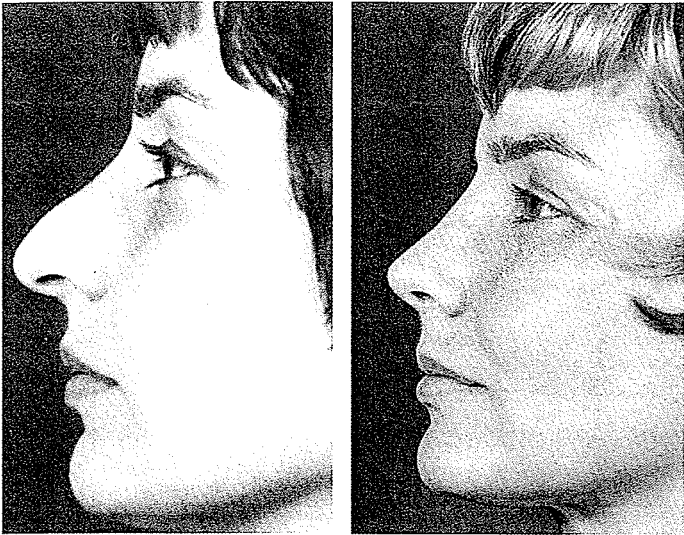down of the tip as the upper end of the distal septum presents in the supratip area. By resecting a reasonable portion of membranous septum along with what septal cartilage is indicated, one leaves only a modest play between the caudal end of the septal cartilage and the medial crura of the lower lateral cartilages. When the membranous septal excision heals, the tip will maintain its corrected position. Too often orthopedic through-and-through stitches from columella to septum are used in an almost frantic attempt to over-correct tip depression, but of course, when the sutures are removed, if there is too much membranous septal play, the tip will droop again.

Most of the parrot's beak secondary deformities I have treated can be corrected satisfactorily by tailoring the remaining excess of septal and alar cartilage.

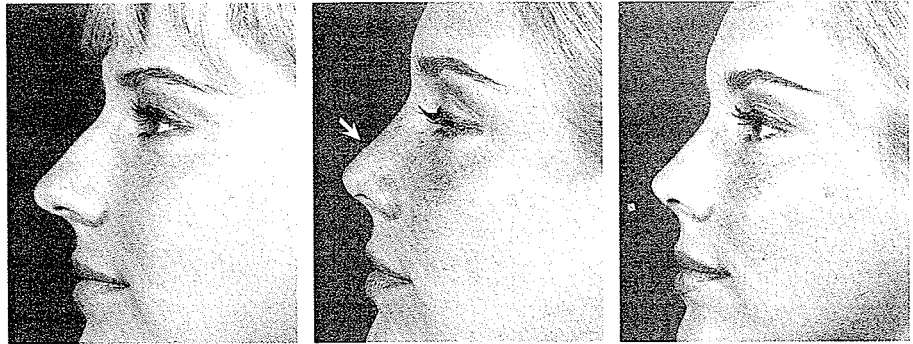
This parrot's beak of comic proportions was improved by further bridge and septal resection.



Again bridge and septal revision corrected these parrot's beaks.



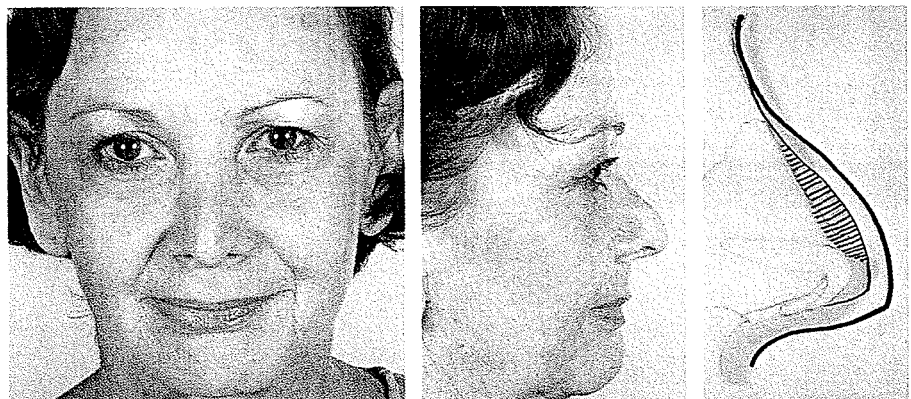Here, a series in which the primary rhinoplasty left a suggestive parrot's beak (arrow) that was improved by shaving the

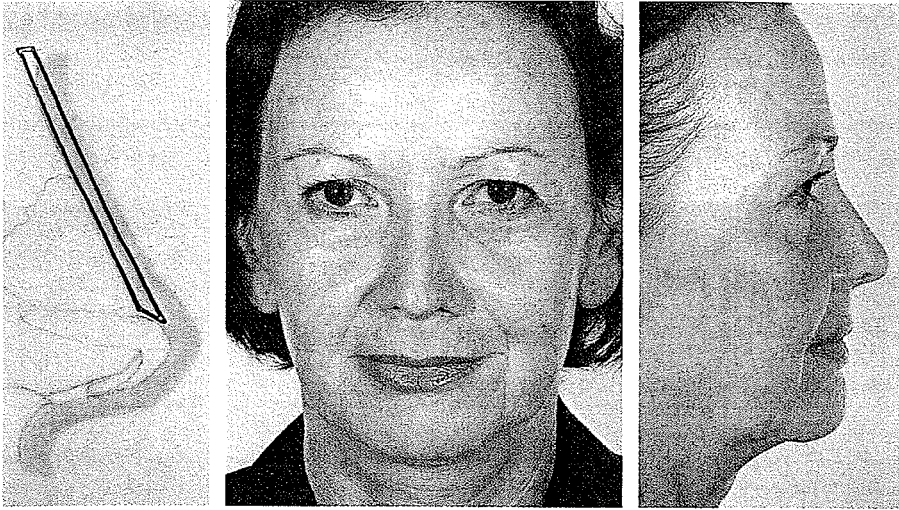

slight convexity. So often the primary rhinoplasty may show a residual supratip excess which deserves secondary shaving.

Sheen has long advocated that excessive removal of the upper nasal bridge is often responsible for the supratip. He advocates auricular conchal cages to augment the depressed upper bridge rather than scooping the supratip. He has presented some fine results, but for me many of these bridges are too high.

Here is a case where I found the combination of tailoring the septum and augmentation of the upper bridge beneficial. This 57-year-old female had two rhinoplastic procedures, ending with a classical parrot's beak deformity. Through a membranous septal incision extended as anterior vestibular incisions the nasal skin was freed from the supratip area so that the excess cartilage could be excised. A triangle of anterior septum was also resected. A spare piece of this discarded cartilage was grafted in the pinched tip on the left to produce better symmetry. A pocket was dissected over the depressed nasal bridge and into this pocket was inserted a specially

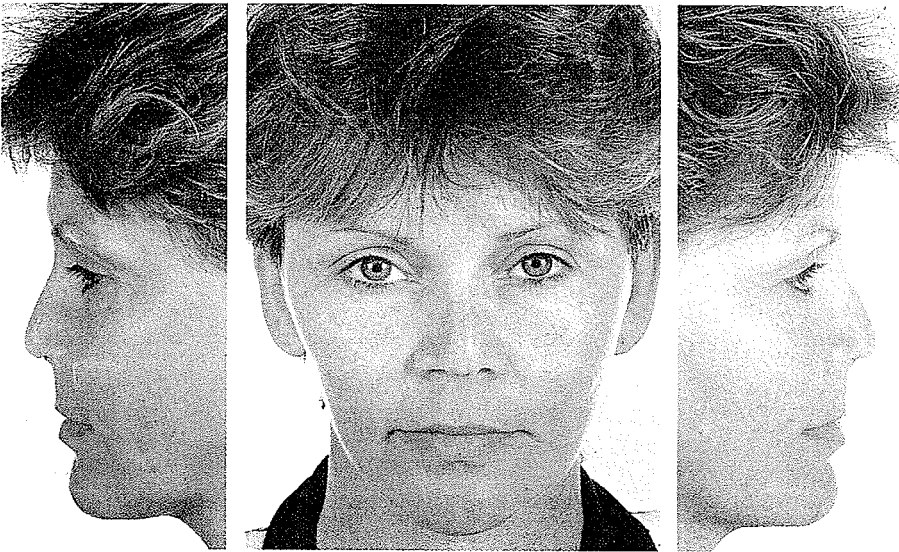



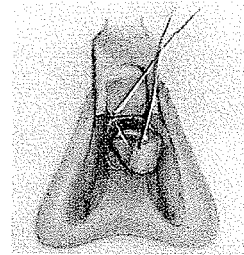
carved silastic implant. The nose healed well and the silastic implant has served admirably.

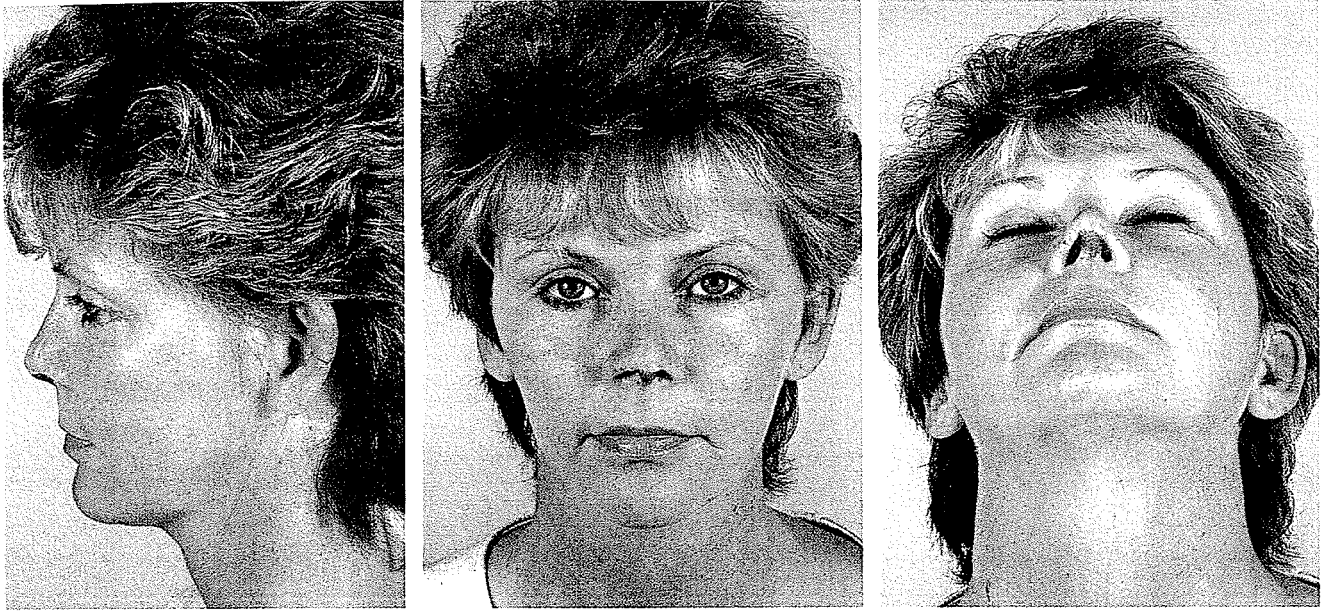*Parakeet's Beak Following Open Rhinoplasty*

This 37-year-old female had an open rhinoplasty by a competent ENT surgeon who somehow managed to collapse the col-

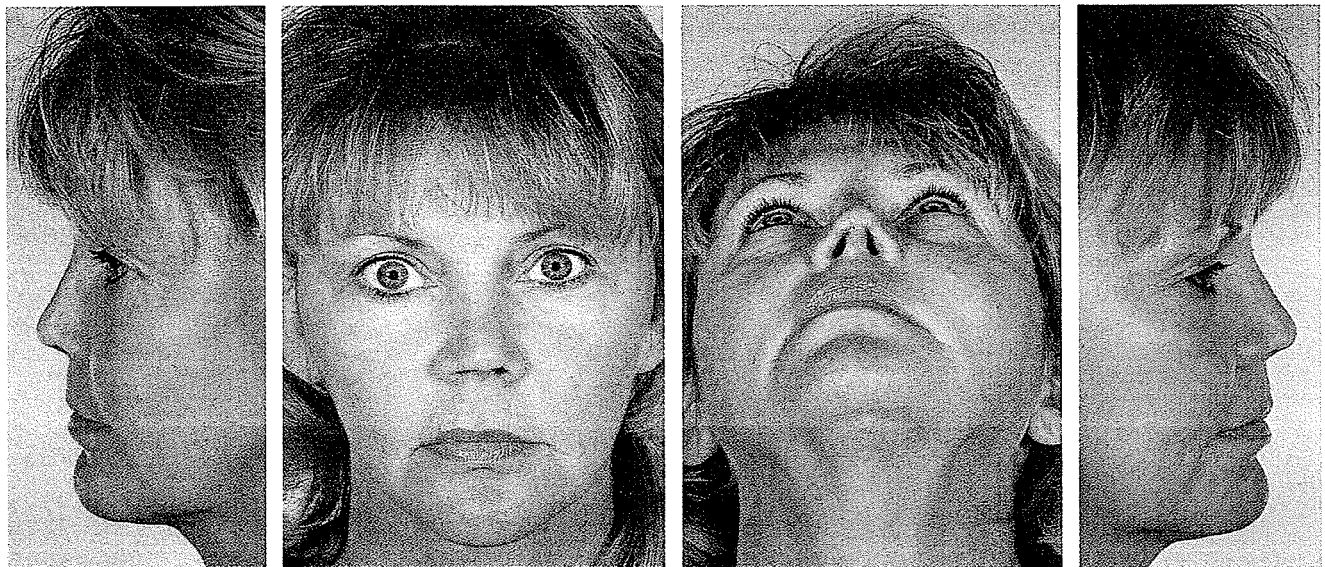

umella join with the tip. Either the scar was too close to the tip or there was resultant necrosis of tissue in the area. This resulted in loss of tip projection with hooking associated with a crinkling retraction of the distal columella. Excision of the transverse columella open rhinoplasty scar released the depressed tip. Into this defect a composite auricular graft was inserted and sutured. The improvement was dramatic with





correction of the unusual parrot's beak. Minor revisions were necessary over a year later.



#### PIG'S SNOUT

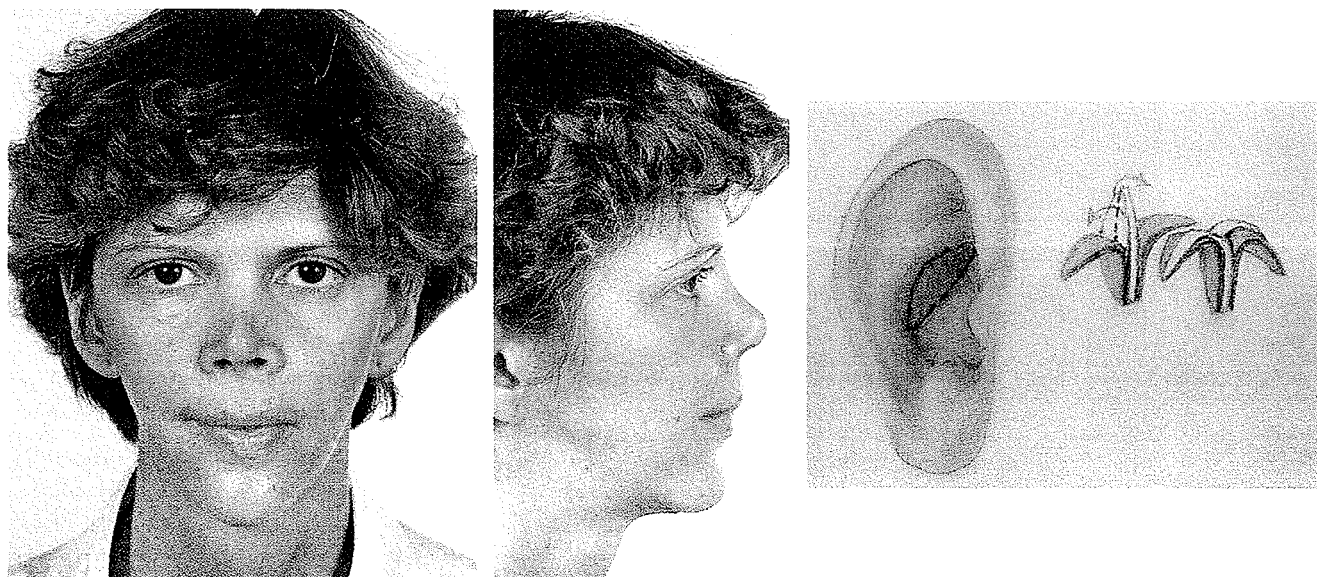
This is a secondary deformity that terrorizes the layman and is not particularly easy for the secondary surgeon to correct. It is usually caused during over-enthusiastic anterior septal resection accompanied by too generous sidewall reduction of lining and cartilage: chomp! chomp! chomp! This action not only shortens the nose but also tilts it upward, exposing the nostrils. Since septal shortening has the most direct effect on

the nasal entrance, usually there is also a quality of columella retraction in the deformity. Regardless of whether the sidewalls are long and thick in the original nose or have become relatively long after septal shortening, the effect is a flat, double-barrel nasal entrance not unlike a pig's snout.

Here, as always, diagnosis must direct the method of correction.

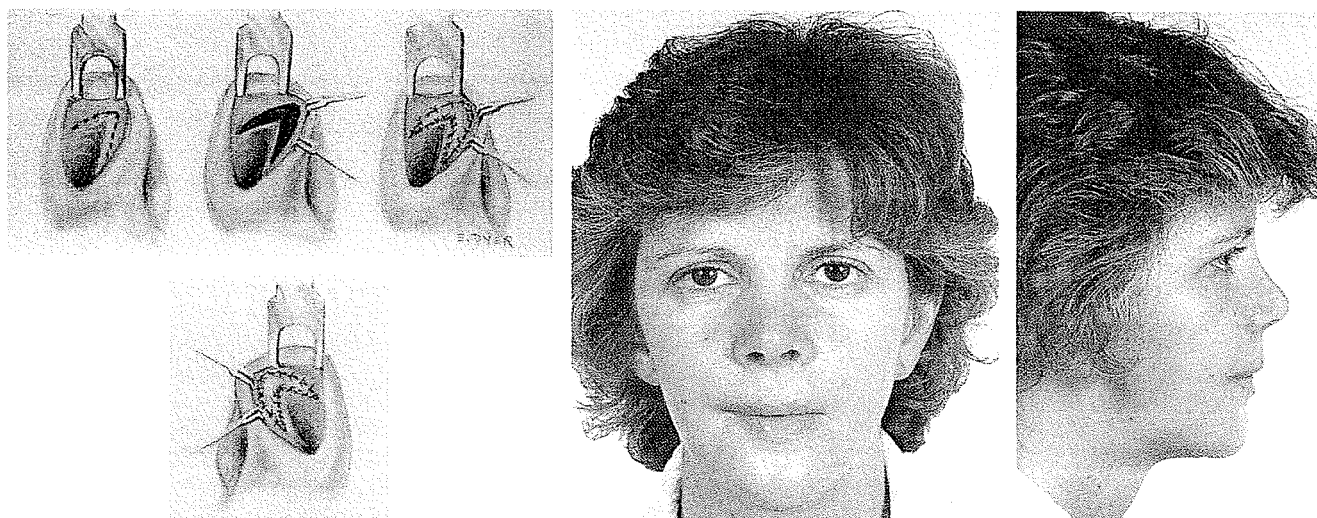
If the entire nose is snubbed, then there is shortness of the septocolumellar component as well as the sidewalls; relief of this condition requires release of all three with the insertion of a free graft. It can be split skin or full thickness skin for the sidewall release but it will require a composite graft for the membranous septal defect. Dingman's auricular banana-split chondrocutaneous graft seems to be one way of satisfying the entire three axis of the defect.

An example of this composite graft is seen in this 39-year-old female who, after a rhinoplasty and an attempt at bone graft to her nose revealed a snubbed, pinched, retracted nasal tip.



Through a releasing membranous septal incision carried bilaterally as anterior vestibular incisions leaving an intact cartilage rim anteriorly, it was possible to free the nasal skin over the dorsum to bring the nose down and forward moder-

ately. A composite auricular graft  $3/4$  cm wide by 3 cm long was taken from full thickness left concha as described by R. Dingman. It was bisected like a banana split for half its length. This was achieved by dividing the cartilage down the center, but, when peeling the skin on each side, half of the cartilage was left attached to the skin so two composite wings were created. The intact half of the composite graft was inserted into the membranous septal defect and the split half pieces were inserted into the lateral releasing incisions. The graft was sutured into position carefully with chromic catgut stitches. The early result of this procedure was encouraging, but one problem with the graft is the possible contracture over time. The patient never returned from her home in another country.



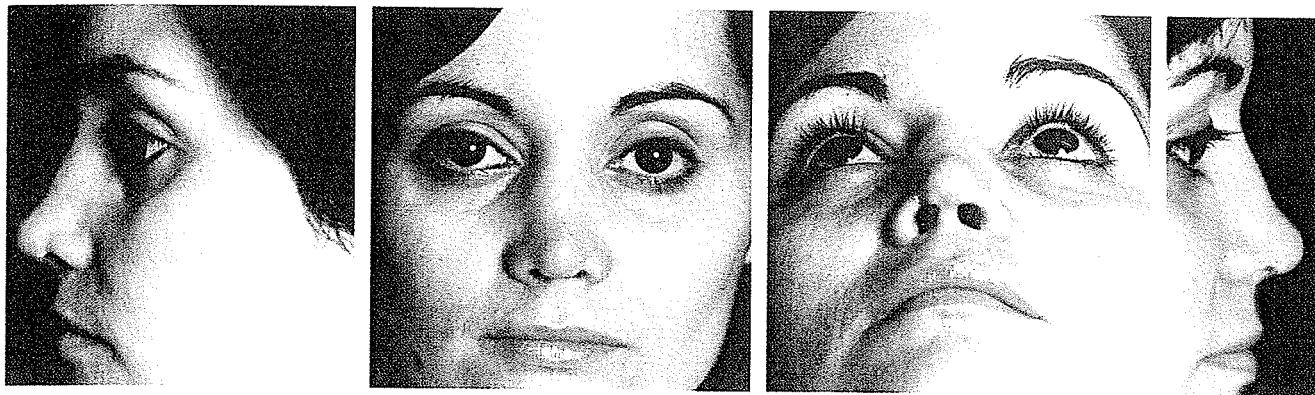Unfortunately I do not have great faith in the long-term benefit of a complicated composite graft inserted into a scarred area of membranous septum. It is probably safer to use a simple composite graft to the septum and separate free skin grafts to the lateral lining. The following case is an example.

There are cases with in-depth discrepancies that cannot be cured with onlay cartilage grafts only. Often it is the subtle and out-of-sight absence of lining that is compounding the distortion. Diagnose before treating!

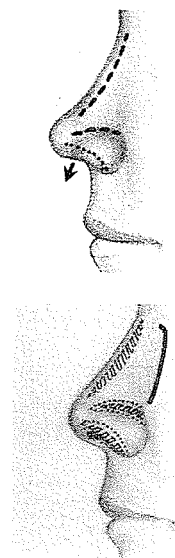
This 22-year-old female had had a submucous resection and rhinoplasty which was complicated by a staphylococcus

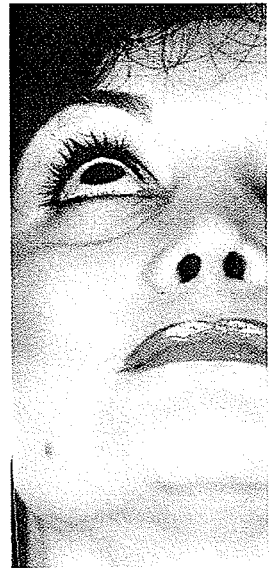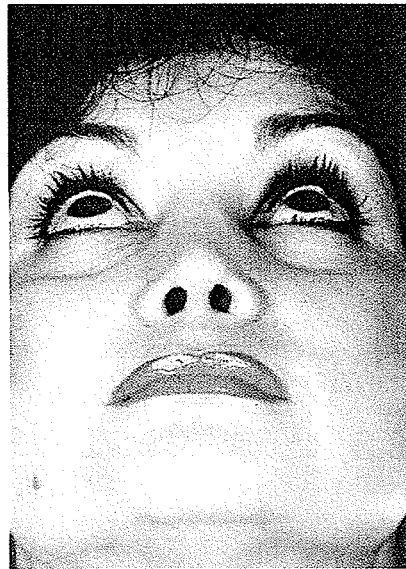


infection. A secondary procedure resulted in spread of the nasal bones, depressed nasal bridge, retracted columella, notching of the alar margins and a pinched tip. It was indeed a “banged up” nose.



The actual key to the correction of the deformity was diagnosis of lining shortness. A membranous septal incision extended bilaterally as anterior vestibular incisions allowed the skin to be freed from the bridge with release of the alae and the columella. Bilateral osteotomies with in-fracture narrowed the nasal base. A chondrocutaneous graft from the concha of the ear with skin on both sides and cartilage in the center was grafted into the anterior membranous septal defect. Separate full thickness auricular skin grafts filled the lateral vestibular defects. The small alar margin webs were corrected by marginal excisions. A  $1.5 \times 4.0$  cm auricular cartilage strip was grafted on the bridge but, as so often happens with extensive undermining, some of the bridge graft was absorbed. A year later a second auricular cartilage was inserted into a separate pocket all its own on the bridge to complete the contouring.





## NASAL CHONDROMUCOSAL FLAPS

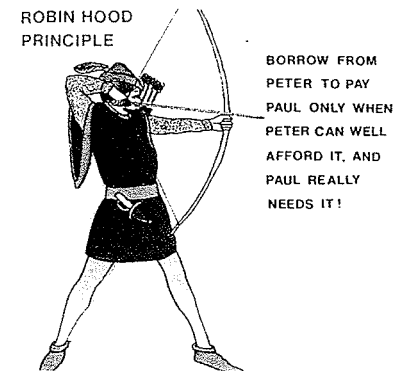
The nasal chondromucosal flap was first described by me in 1963, using it as bilateral vestibular flaps to release several retracted columellas and to line a nasolabial flap for reconstruction of a total columella. The versatility of a chondromucosal flap in the nasal vestibule was presented in 1973 with several interesting cases. Since then it has been found valuable in secondary problems.


The use of these flaps epitomizes the Robin Hood principle in a double plus where the donor area needs to give up what the recipient area craves to receive. It also represents the extremes of the principle. In some cases the contribution of the flap from a (rich) hanging sidewall to release a (poor) snubbed nose and retracted columella is advantageous to both parties. In other cases where there is no true excess but the required flap is specifically essential for columella reconstruction or retraction correction, the lateral vestibular sidewall can be asked to give up the flap. Under these circumstances these defects should not be closed directly but rather aided by the insertion of a thick split skin graft.

The chondromucosal flap is “on the spot” for repairs in this part of the nose, available immediately for a “one-shot” reconstruction, and it has acrobatic maneuverability. It enjoys vascular dependability far beyond any predictions based on its width-to-length ratio—and in spite of scars which may be near or in it. Best of all, it brings nasal lining with adherent cartilage to the area without too much increase in bulk.

The use of these flaps does not interfere with the usual rhinoplasty maneuvers. In fact, the flaps can be developed at the beginning of a rhinoplasty and give better exposure—or, if the future position of the flaps is noted, the actual cutting of them can be delayed until near the end of the rhinoplasty.

The standard flap is a relatively narrow 1/2- to 3/4-cm strip of mucosa of the lateral nasal vestibule, together with a corresponding adherent strip of alar cartilage. It is usually four times longer than it is wide. Its pedicle base is superiorly





and anteriorly placed high up under the nasal tip above the front point of the septum.

To cut the flap, one extends the membranous septal incision laterally in the usual manner along the intercartilaginous line as far as the length of the flap. The tip of the flap is developed and then the incision comes back parallel to the first incision along the anterior vestibular line. The flap is freed from the overlying skin with right-angled scissors.

As the columella is released and advanced anteriorly, these bilateral flaps will ride forward with the tip and can be swung medially into a releasing gap between the columella and septum. As the "wings fold in," the cartilages of the flaps come together with the lining on the outside. As the sidewalls of the nose are longer than the central septum, these flaps will reach and easily correct a retraction extending as far down as the nasal spine.

#### *Good Vascularity*

The vascular dependability of these flaps is remarkable, considering the hazardous width-to-length ratio. The near 100% success in 100 flaps is probably due to the flap being backed by cartilage, which acts as a splint to prevent collapse or kinking of the vessels in the attached mucosa.

An ordinary skin flap of near dangerous width-to-length proportions and without a specific vessel, when cut and allowed to shrink, may turn bluish on its end due to collapse of its vascular channels. If left like this for a time, even though it is restretched later and sutured, the distal portion may have been lost from thrombosis. With cartilage backing, however, this collapse is prevented and the tendency to thrombose is bypassed. Scars near, in, or across the flap do not seem to prevent its use if sufficient time for revascularization has elapsed.

#### *Economical*

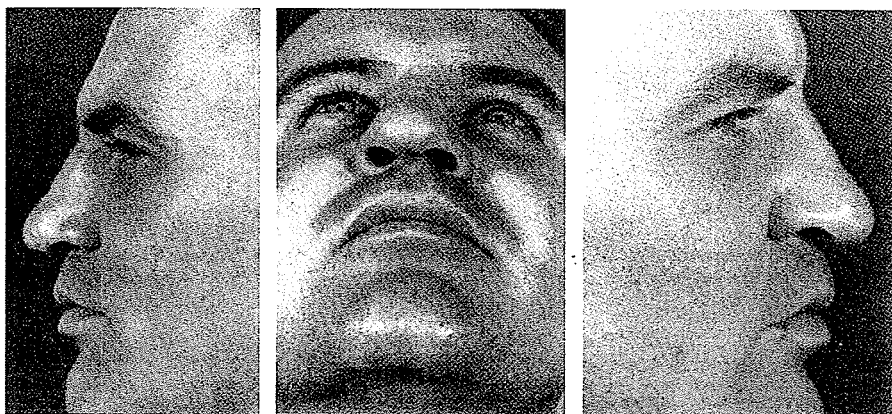
It is an economical flap, composed of tissue that is often discarded during a standard reduction rhinoplasty. Even after a reduction rhinoplasty, this flap is often still available. When taking the flap it is important to leave behind an anterior thin

strip of alar cartilage intact. Both the donor area and the recipient site of the flap are out of sight within the nasal vestibule: only the effect of its transposition is visible. There are multiple uses of this flap.

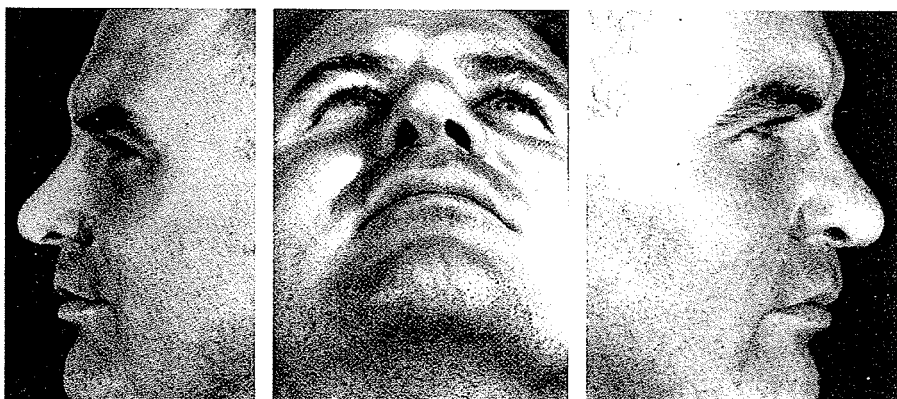
### *Bilateral*

The chondromucosal flap is most commonly used as a bilateral procedure. The typical indication is a retracted columella with relatively long and overhanging sidewalls. The twin transposition of these chondromucosal flaps has a double effect. The columella is released as the sidewalls are lifted.

This 39-year-old man had a long, bulbous nose with severely retracted columella from previous football injuries and submucous septal resection.



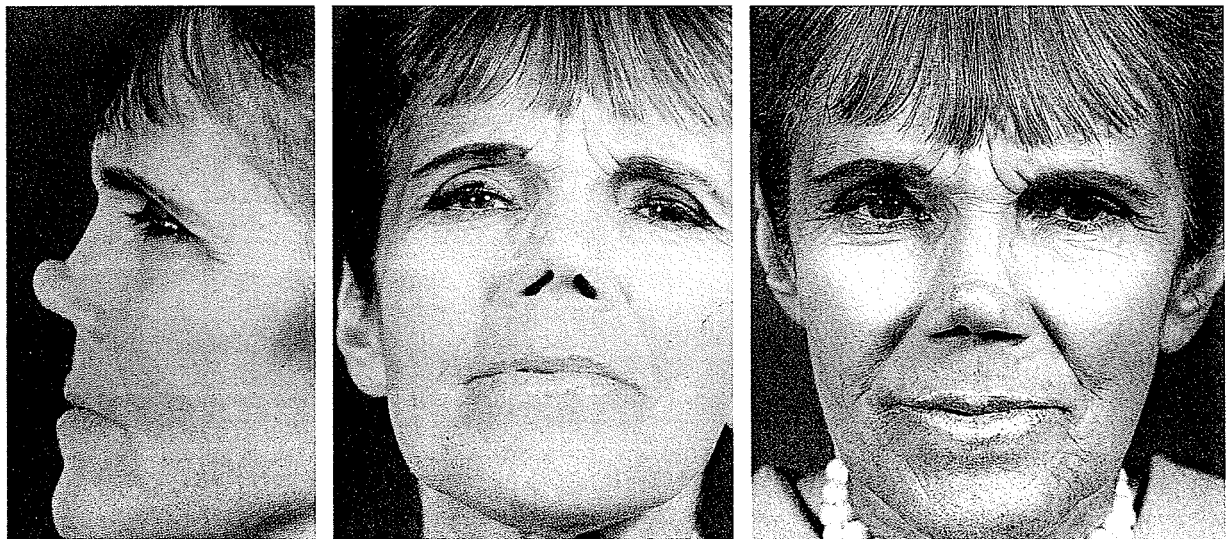
The columella was freed from retraction by a membranous septal incision. Bilateral alar chondromucosal flaps swung down and in, coming together in the membranous septal gap with maintenance of the correction as well as reduction of the tip length and bulk.



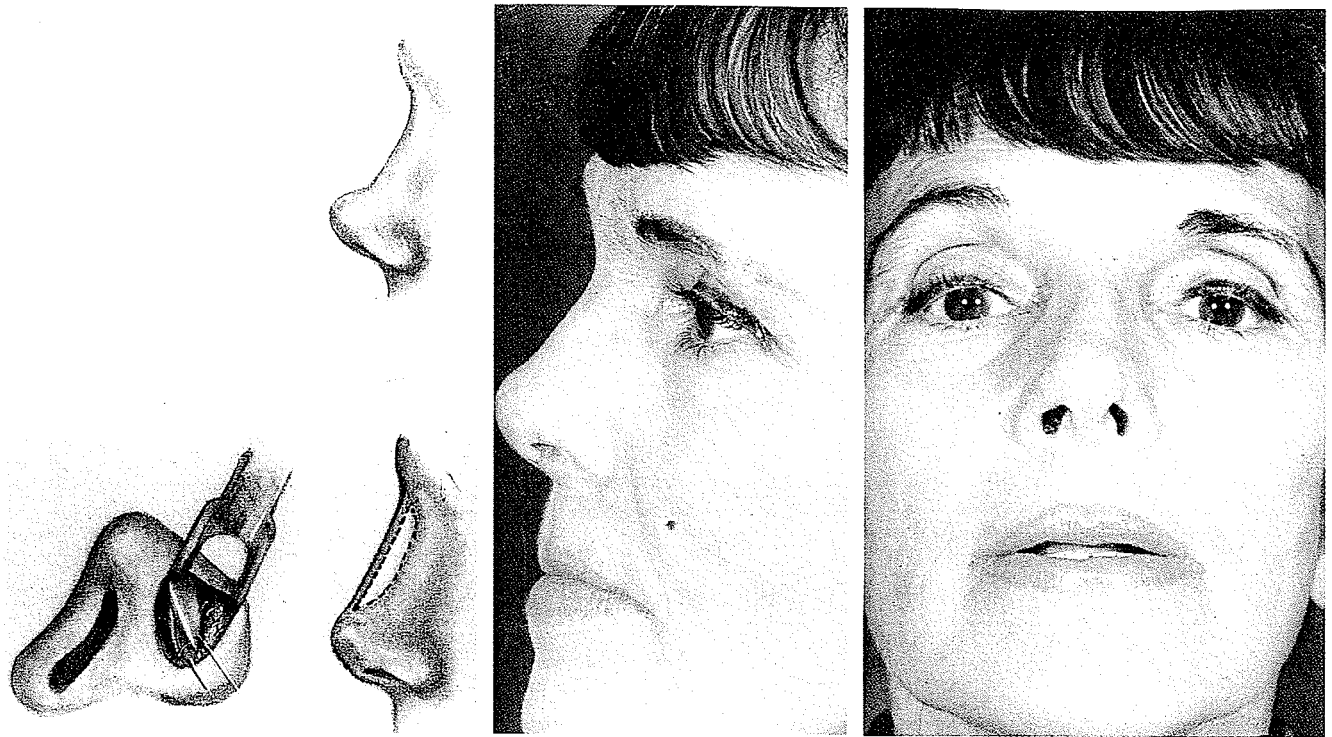Here is an example in which a reduction rhinoplasty left the tip too long and caused the surgeon to resect too much anterior septum in his second operation. Bilateral vestibular chondromucosal flaps corrected the columella retraction, hanging sidewalls, and depressed nasal tip.



This 49-year-old woman had been operated on by a famous plastic surgeon who was not particularly skilled in rhinoplasty. She had a bulbous tip, retracted columella, depressed nasal bridge, and asymmetrically collapsed alae in knock-kneed position obstructing her airway. She had lived with this deformity for 20 years.

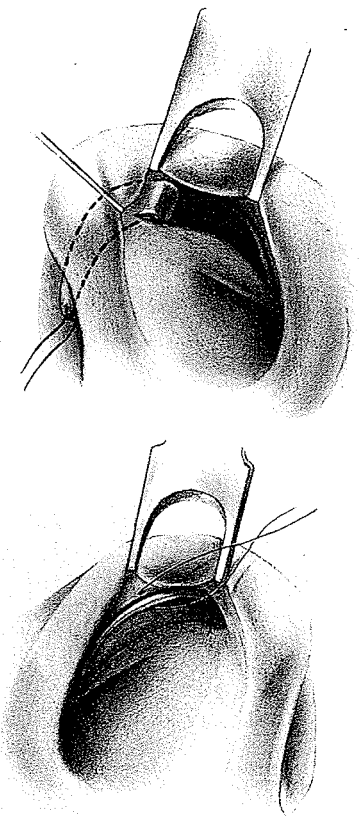


Lateral vestibular chondromucosal flaps were transposed into a releasing membranous septal incision which achieved simultaneous reduction of the tip, shortening of the sidewalls, and correction of the retracted columella. A silastic implant was inserted into a special pocket over the bridge to improve the profile.



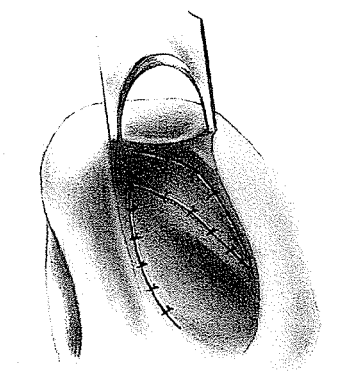
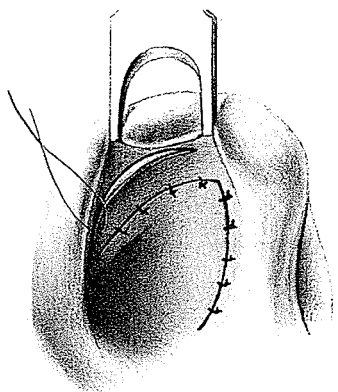
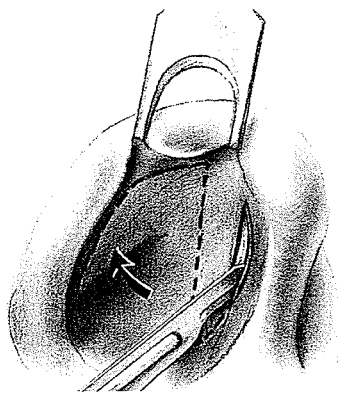
*Unilateral*

The flap can be used unilaterally when there is a difference in the length of the sidewalls, taking it from the long side. The septum is bypassed by slipping the flap over it at the tip. The flap is then inserted into a gap produced by a relaxing incision on the opposite side. The epithelium on the flap's base, which crosses the septum, maintains a small fistula. When the flap has become well vascularized in its new site, the base is simply excised. To bypass this second stage 1 cm of the base can be denuded of epithelium.



### *Flap in Reverse*

The similar procedure can be done in reverse. The same general area for the base of the flaps is used. The chondromucosal flaps are taken from the area of the membranous septum including the posterior portion of the medial crus of the alar cartilage. If necessary, an anterior portion of the septal cartilage can be incorporated in one of the flaps. The key is to get some cartilage in each flap.

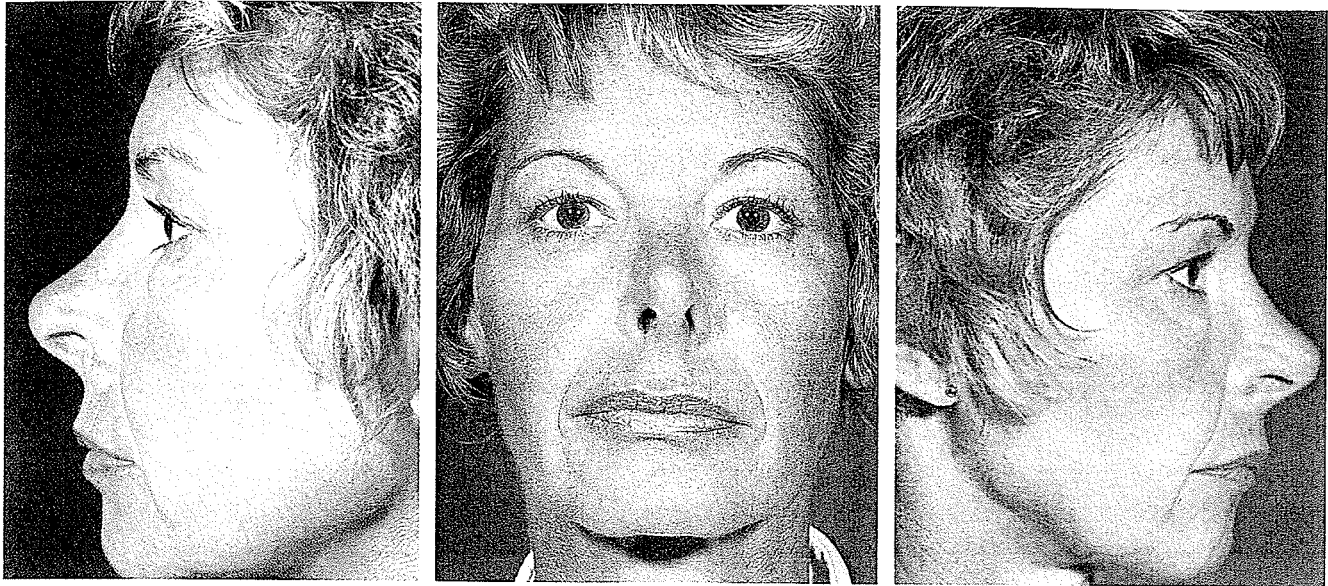

**BILATERAL.** The reversed application of this method is usually a bilateral procedure. It is most effective in cases where the combination of deformities includes (1) a hanging columella or a projecting septum and (2) ugly retraction of the lateral sidewalls with (3) collapse of the alar margins and obstruction of the nasal airway.

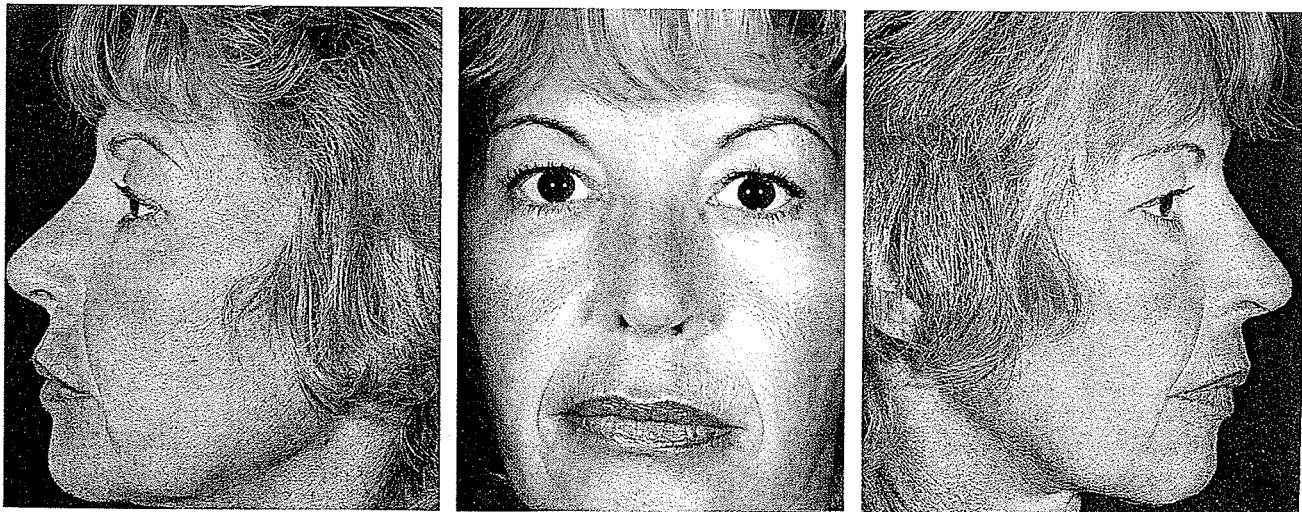By taking the excess chondromucosal tissue from between and including various portions of the columella and the septum, this part of the deformity is corrected. It is important not to take more than can be spared in this membranous septal area because the new secondary deformity could be worse than the old one. Transposition of these flaps in a “wing spreading” maneuver places both support and additional lining into the area produced by lateral releasing incisions inside the vestibule and parallel to the alar margins. Not only does this let the retracted rims down, but the added support to the flail sidewalls opens the airway and maintains the improved apertures.



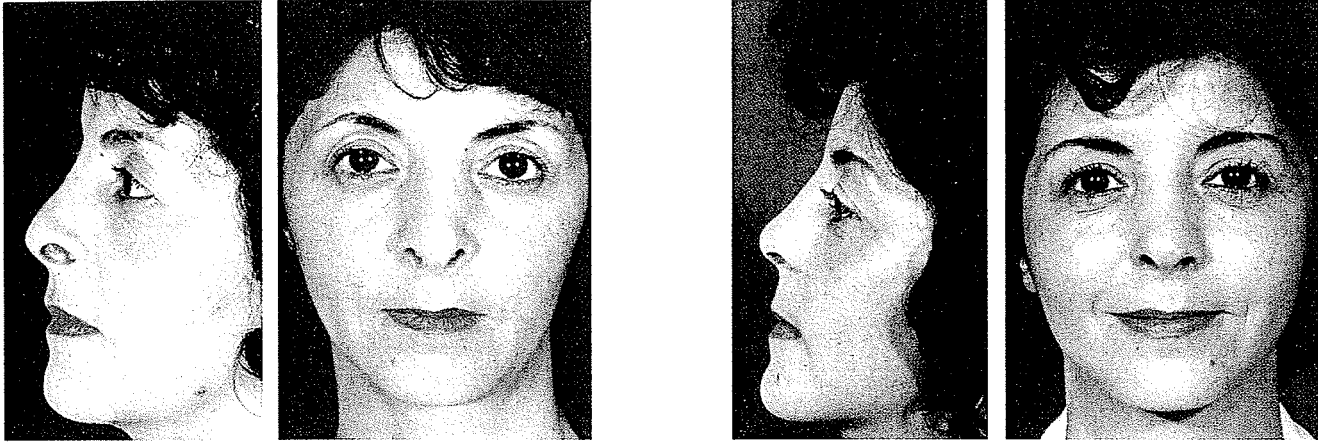Here is a patient who, unfortunately, had a rhinoplasty by a surgeon trained in another specialty. The operation resulted in a comical bridge line, retracted sidewalls, and a hanging columella. There was also an asymmetry of the nostrils with varying degrees of collapse intermittently obstructing her air-



ways. Correction was performed by use of chondromucosal flaps taken from the general area of the membranous septum. Each included either a portion of the medial crus of the alar cartilage, or a piece of septal cartilage. They were transposed bilaterally into releasing incisions in the lateral walls of the vestibule. This lifted the columella, released the alar rims, and splinted the sidewalls to correct the collapse and prevent airway obstruction.



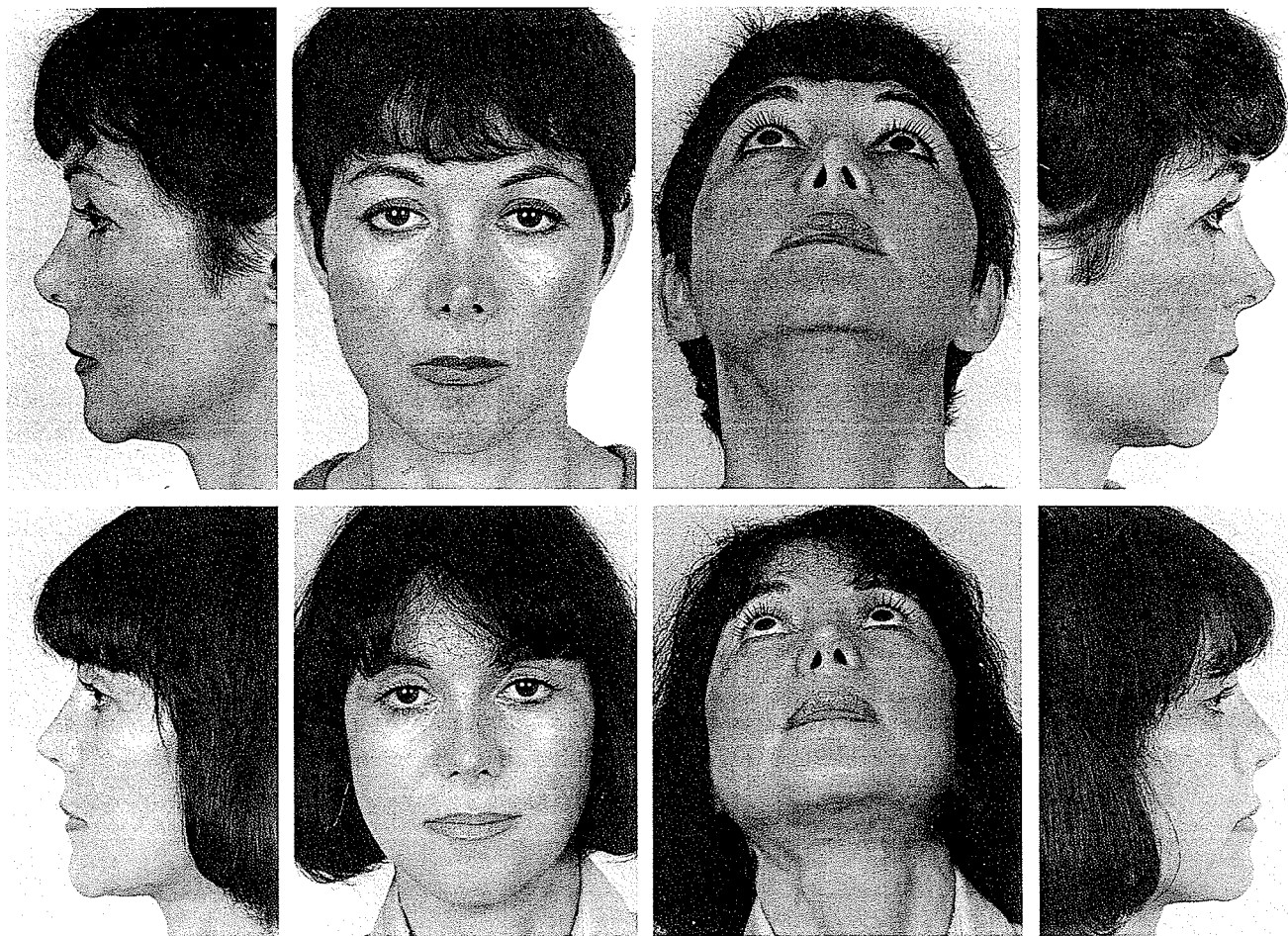
This secondary deformity with the typical hanging columella and retracted sidewalls occurs more commonly than would be expected and is difficult to correct by standard procedures. Again the bilateral chondromucosal flaps transposed bilaterally solved the problem.



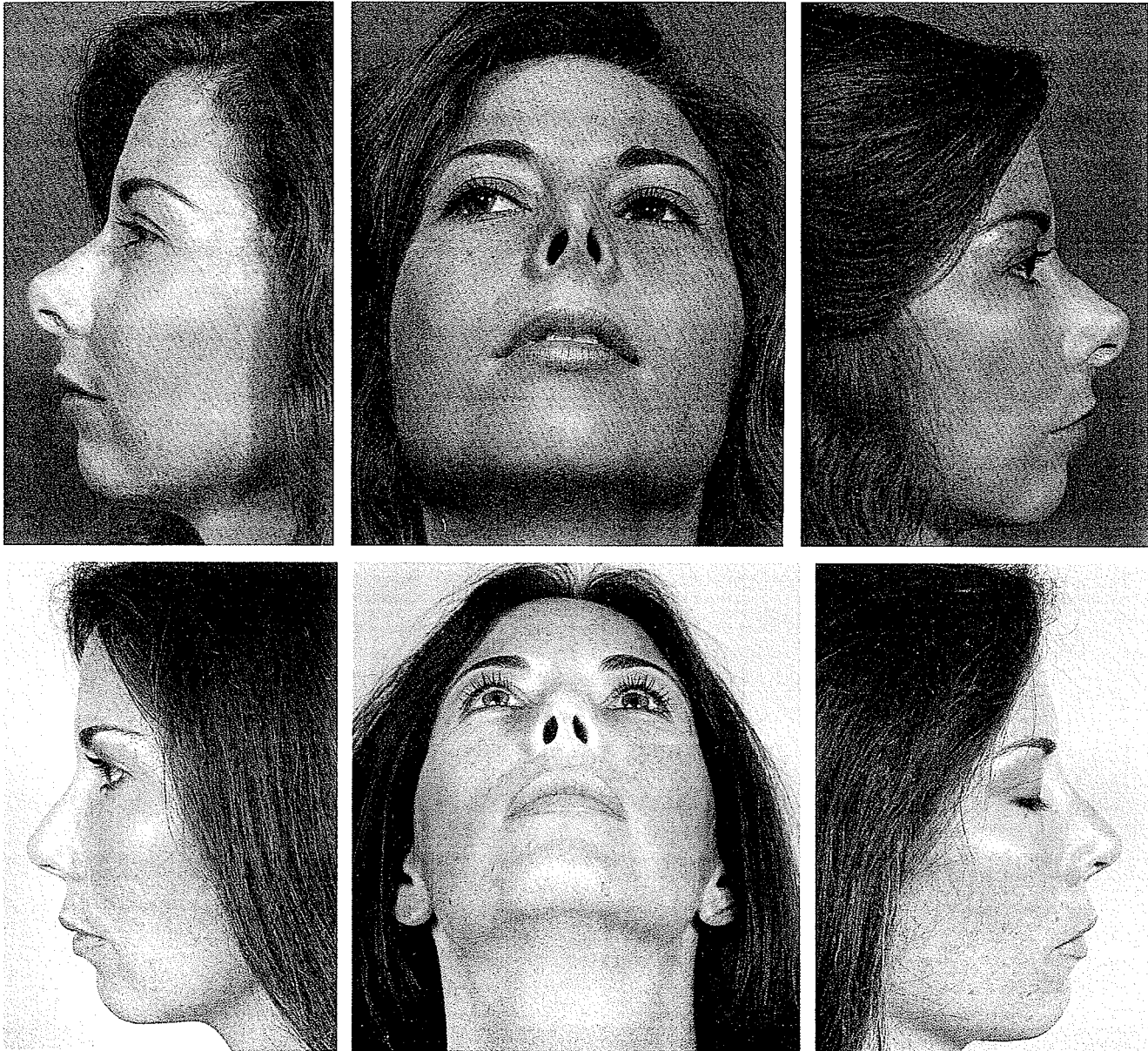
This 28-year-old woman after rhinoplasty and one secondary procedure revealed moderate hanging columella and retracted alae. Bilateral chondromucosal flaps from the anterior septal area were transposed into releasing incision in the lateral vestibular lining of the alae. Alar base wedges and cartilage graft to the tip completed the correction.



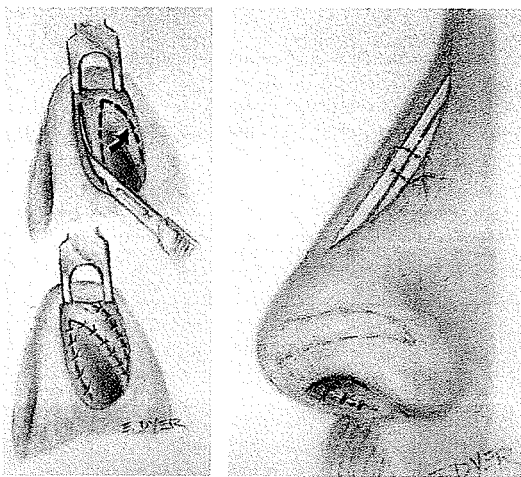

Here is a more subtle example of this deformity with a pinched tip effect. Conservative bilateral chondromucosal flaps relieved the lateral retraction and was further benefitted by tip and bridge revisions.



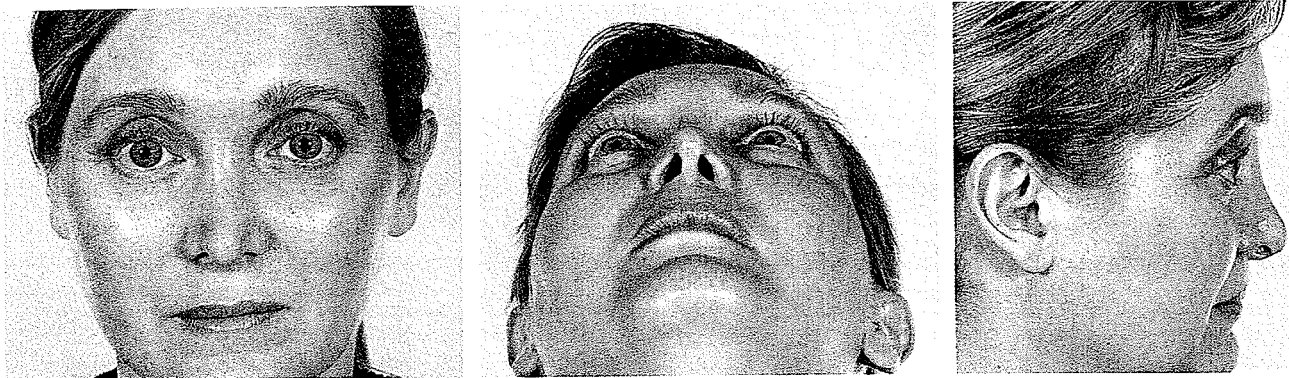
This strange nasal deformity seen at age 25 is the result of a rhinoplasty at age 15. The snubbed tip, retracted alae, and hanging columella were corrected by first lowering the distal bridge. Then the transposition of two membranous septal chondromucosal flaps (the left one carrying medial alar crus and the right one carrying a sliver of septal cartilage) were inserted into lateral vestibular releasing incisions.



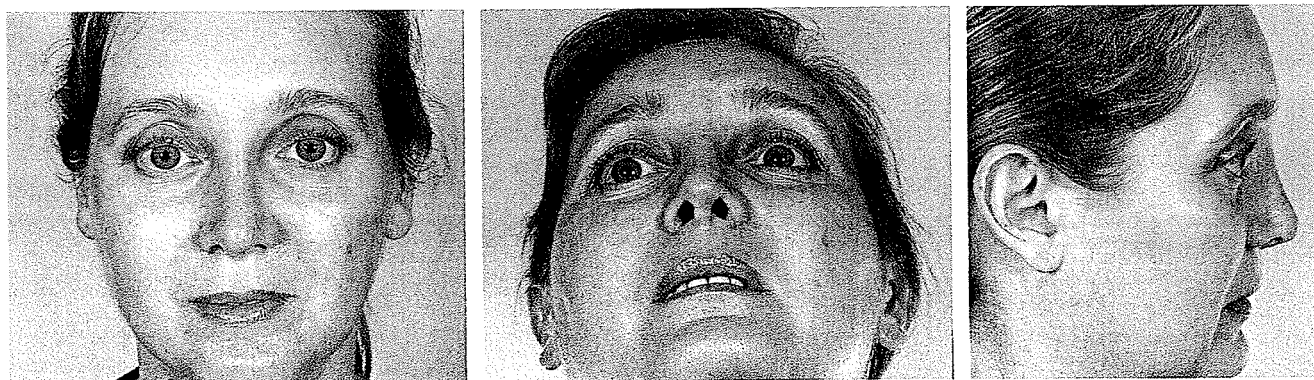
The first rhinoplasty surgeon took too much from the bridge and the lateral lining and not enough from the anterior septum. Improvement was achieved with a two-tiered septal cartilage graft to the bridge and the transposition of bilateral chondromucosal flaps from the anterior septal area to releasing incisions in the lining of the retracted alae.



This 45-year-old female had had several rhinoplasty procedures and at least one open rhinoplasty which had resulted in a scooped bridge with a supratip curve, pinched tip with retracted alae, and a hanging columella.

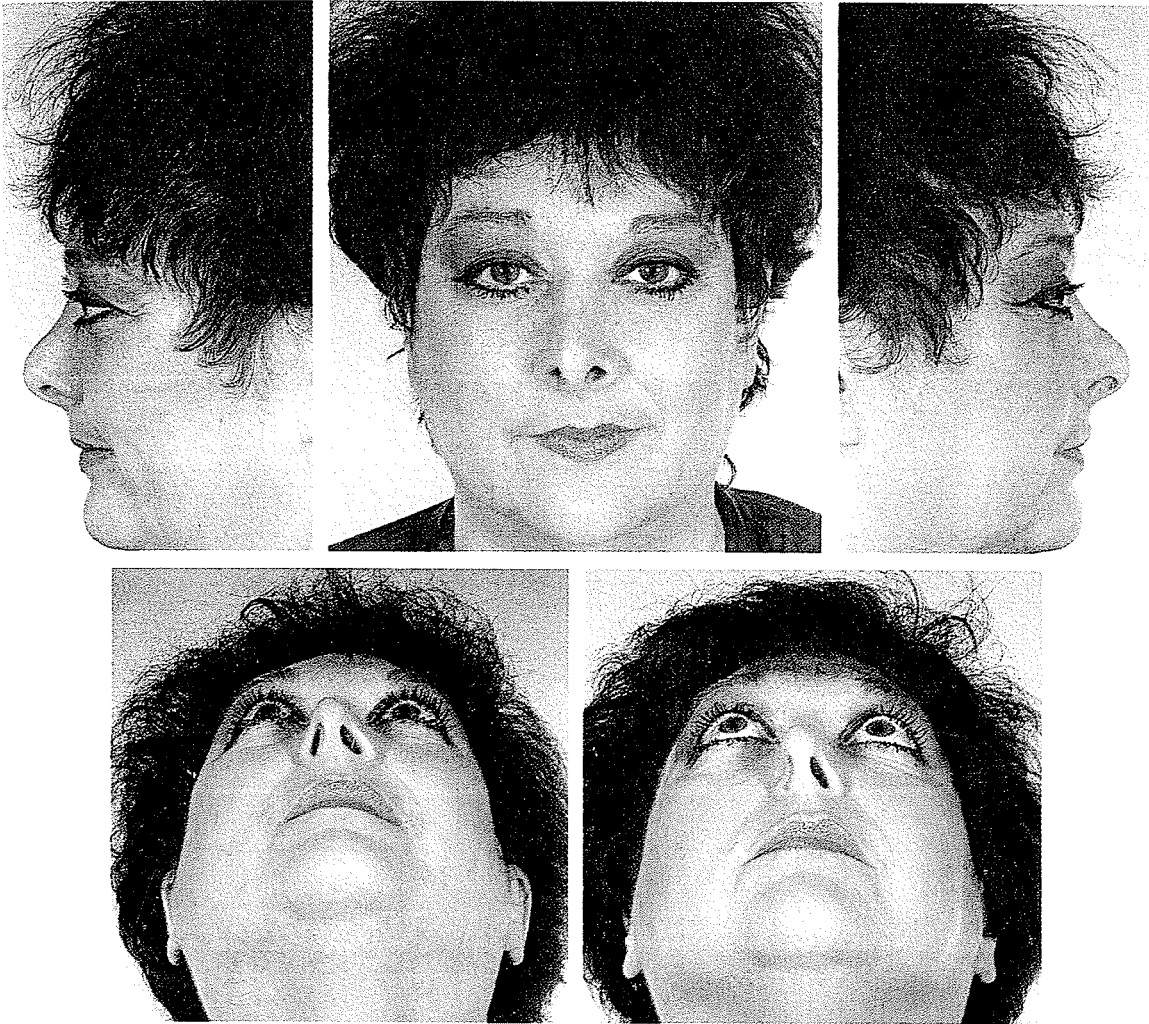

Bilateral chondromucosal flaps were taken carefully and with some difficulty because of the scars of open rhinoplasty in this area. It is likely that the opening scars did delay the flaps with that slight advantage. These flaps, taken from the membranous septal area incorporating thin slivers of cartilage, were transposed into releasing incisions in the lateral alar lining to correct the retraction and excess creasing. This shifting of tissues also corrected the hanging columella. The distal bridge was straightened and the depressed middle bridge was augmented with auricular cartilage.

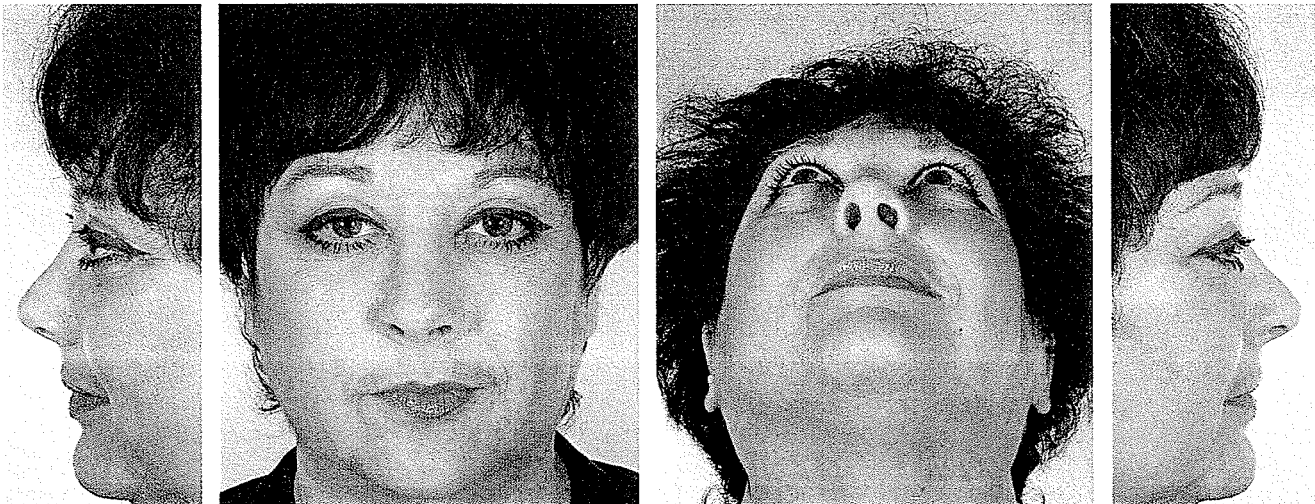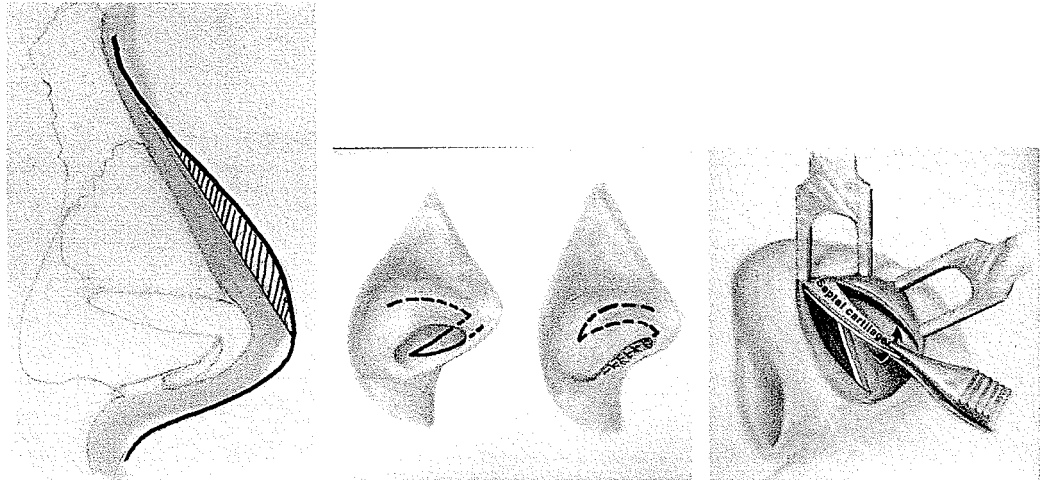


*Airway Collapse*

This secondary deformity is classic. It had the parrot's beak, the hanging columella and irregular retracted alae. On inspiration the flail right alar and sidewall collapsed, completely obstructing her airway.



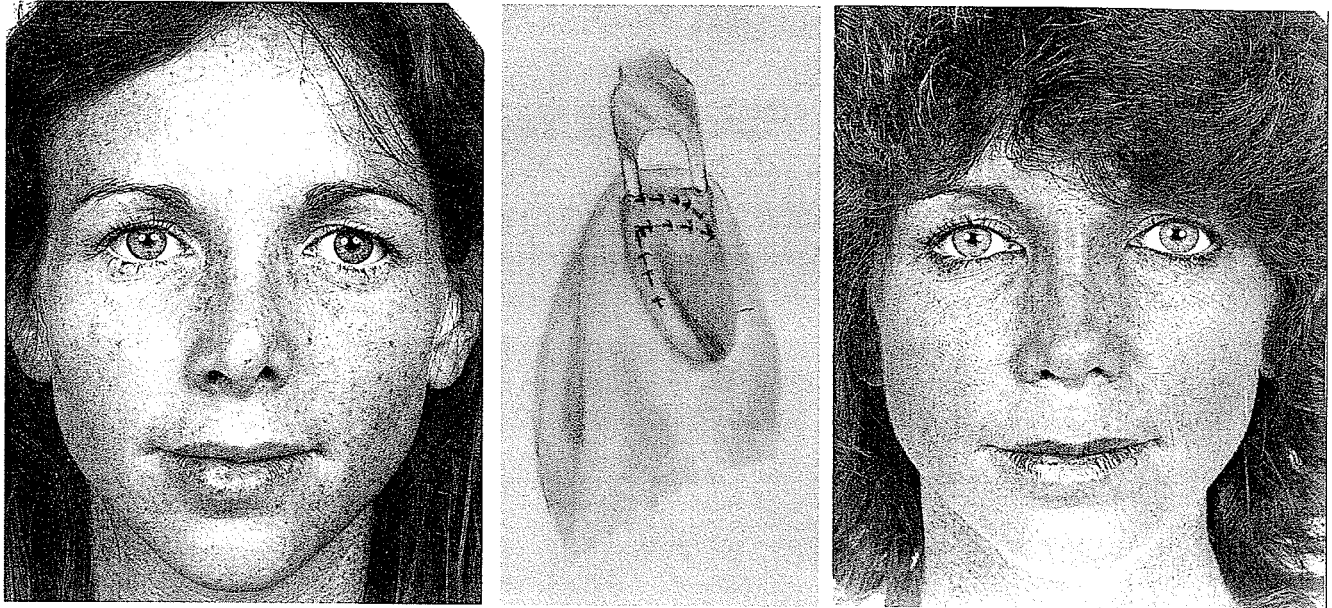
The bridge was straightened by shaving down the excess septum in the supratip area. Bilateral chondromucosal flaps, taking bits of cartilage from the medial crura and the septum, were transposed into releasing incisions in the lateral vestibule which not only lifted the columella and lowered the alae but put some support in the sidewalls to prevent collapse. She is inhaling in the postoperative nostril view.





### *Unilateral Flap*

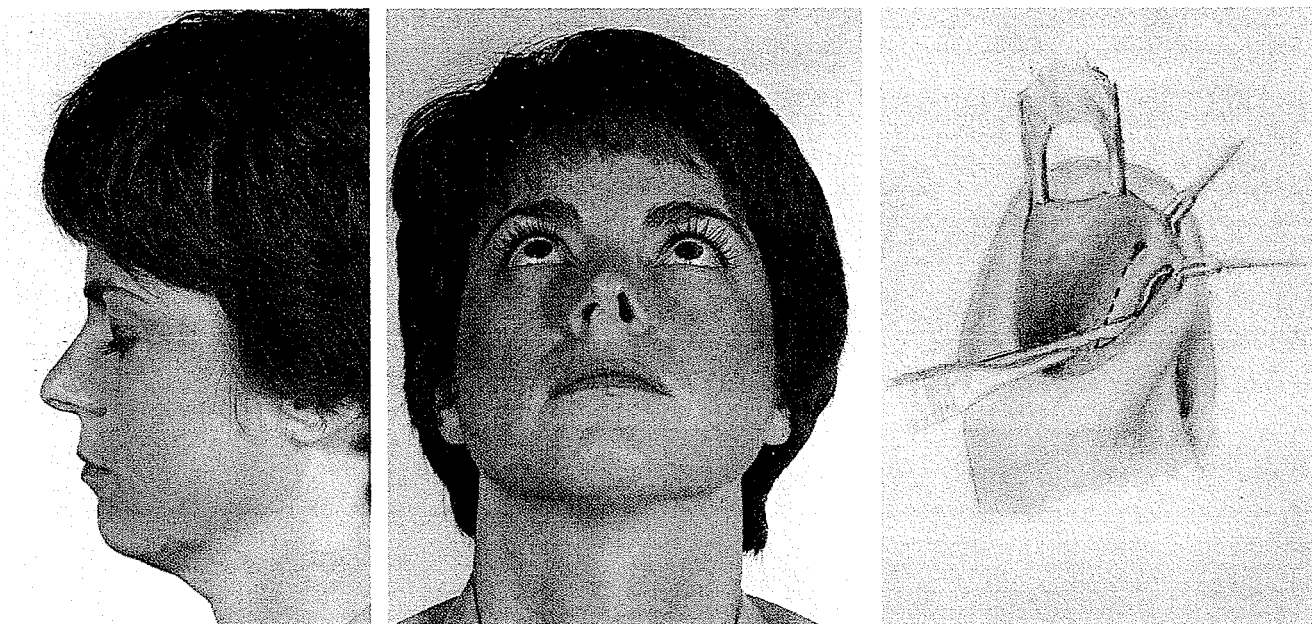
This 25-year-old female revealed a retraction of the left ala following rhinoplasty. A left chondromucosal flap taking medial crus of the alar cartilage along with mucosa of the membranous septum was transferred into a vestibular releasing incision parallel with the alar margin. A cartilage tip graft added definition to the alar balance.



The use of nasal vestibular chondromucosal flaps can also be as useful in alar reconstruction, as they are in reconstruction of secondary deformities following rhinoplasty.

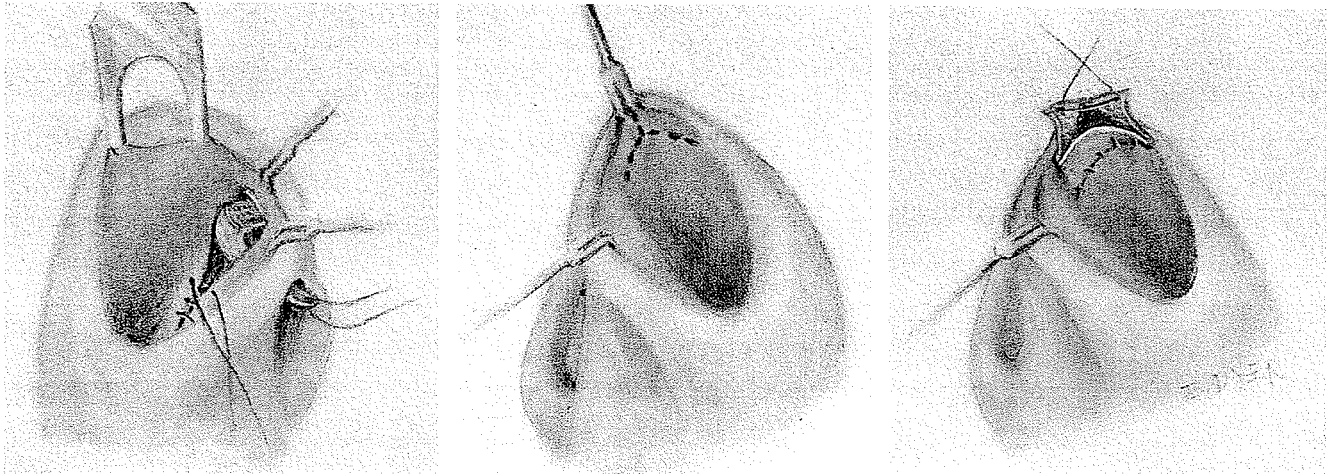
*Alar Notch*

This 36-year-old female had a rhinoplasty with complications that resulted in loss of the normal ala-columella web, resulting in a rather odd and startling notched effect. The septum was deviated to the right.

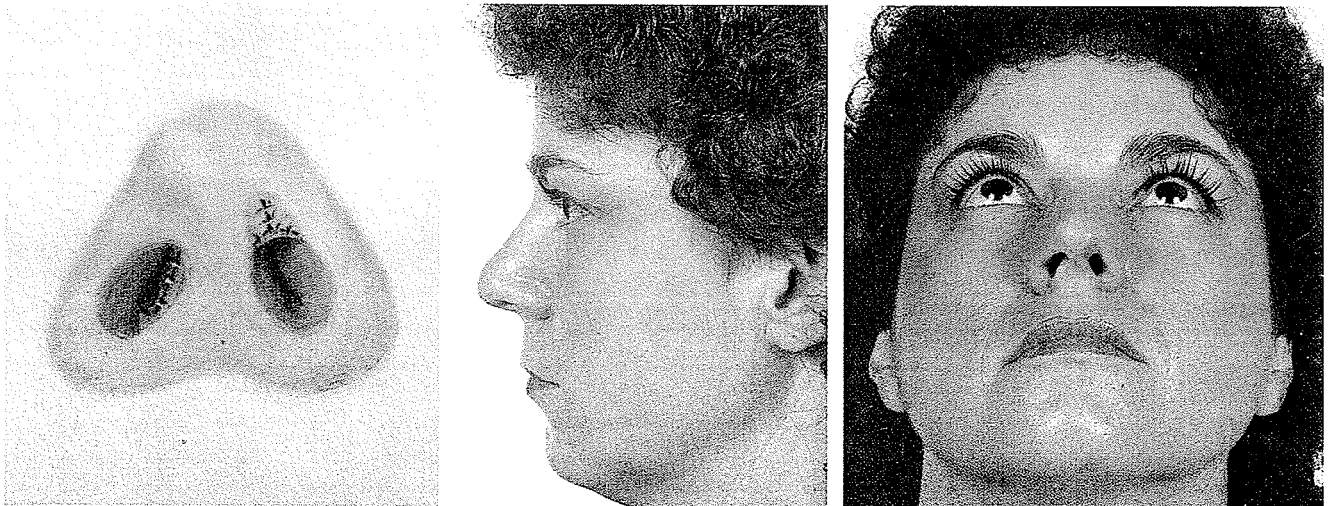

A membranous septal chondromucosal flap taking a portion of the prominent medial alar crus on the right was elevated with its base anterior on the upper columella. This

provided exposure for septal cartilage freeing, scoring, and better midline positioning. The skin hugging the upper left columella was turned out as a flap as was the skin lining the ala in the notched area. These two flaps were sutured together to reform the skin web arching the upper extremity of the nostril. Then the chondromucosal flap denuded carefully of epithelium for 1 cm of its base was passed behind the upper columella and brought out into the left upper nostril to line

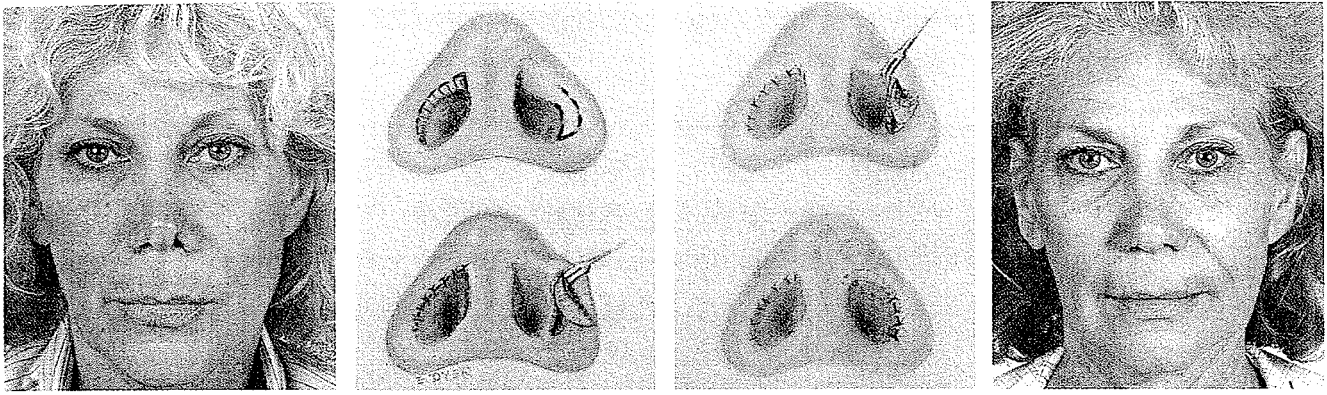


and support the out-turned skin flaps. Minor marginal revisions completed the reconstruction as seen after one year.

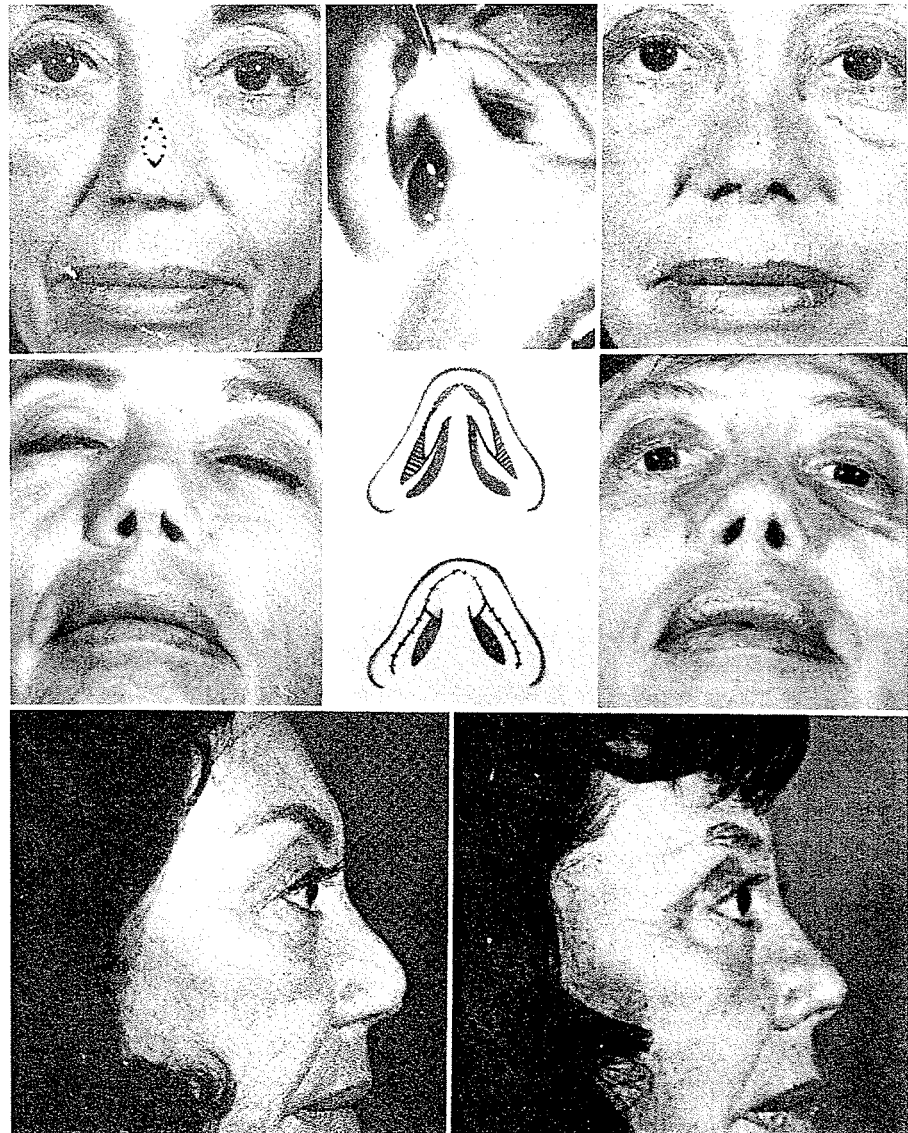


### *Take Whatever is Offered*

Here is a strange combination of notching of the left ala with excess left alar base. In a Robin Hood switch the excess alar margin was taken as a flap, denuded of epithelium and inserted under the skin of the notched area to correct both deformities.



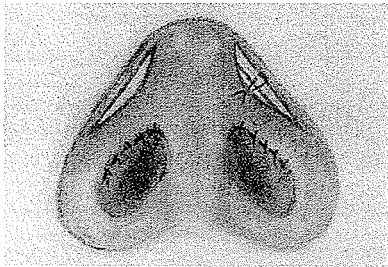
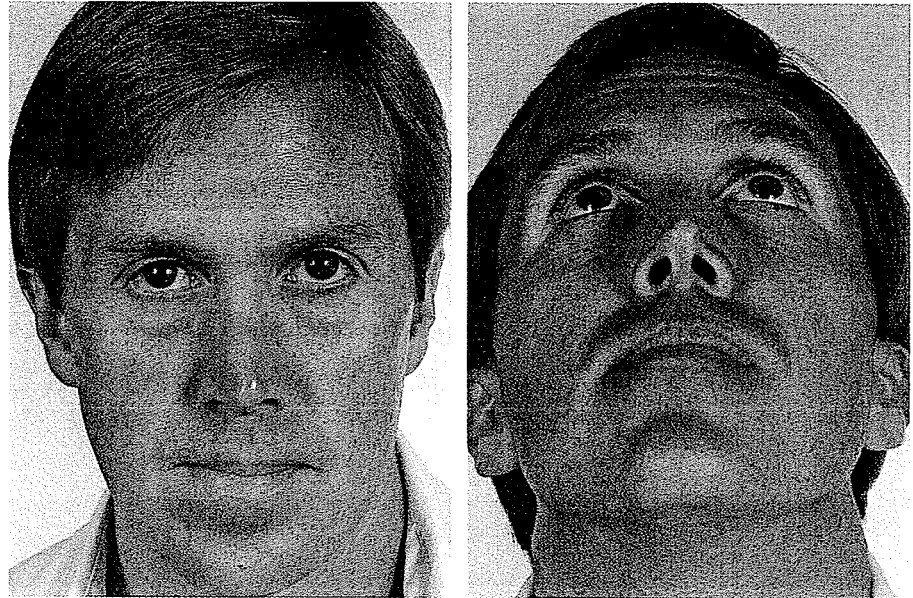
When the soft triangle is violated various secondary deformities occur. When the nostril arch has collapsed to an acute angle bilateral alar margin flaps can be transposed from above to round out the nostril curve.



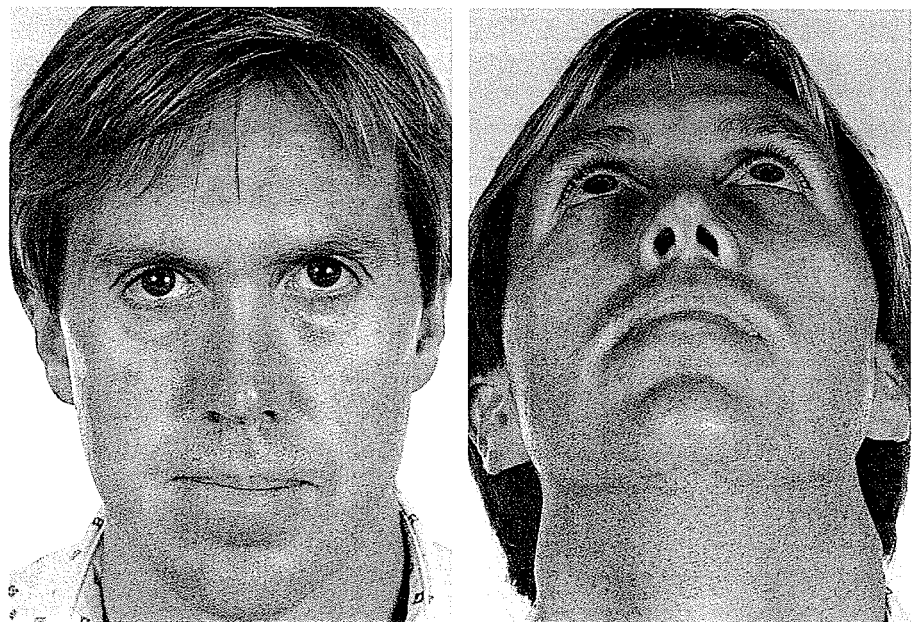
## PINCHED TIP

The pinched nasal tip is an eye-catching deformity because it is so up front. It is usually caused by the enthusiastic excision of alar cartilage along with too much vestibular lining. Often there has been interruption of the integrity of the alar cartilage arch. The combination of all of these excesses destroys the natural flow of the tip into the ala and columella, often leaving the tip too full or too isolated from the ala by cartilage notching. The alar creases extend too far forward into the tip, and the alae often show asymmetric retraction due to lack of lining and insufficient alar cartilage support. The multiple and varied deficiencies create a mirage that makes specific diagnosis difficult. Yet even partial replacement of lost tissue with similar tissue can be beneficial.

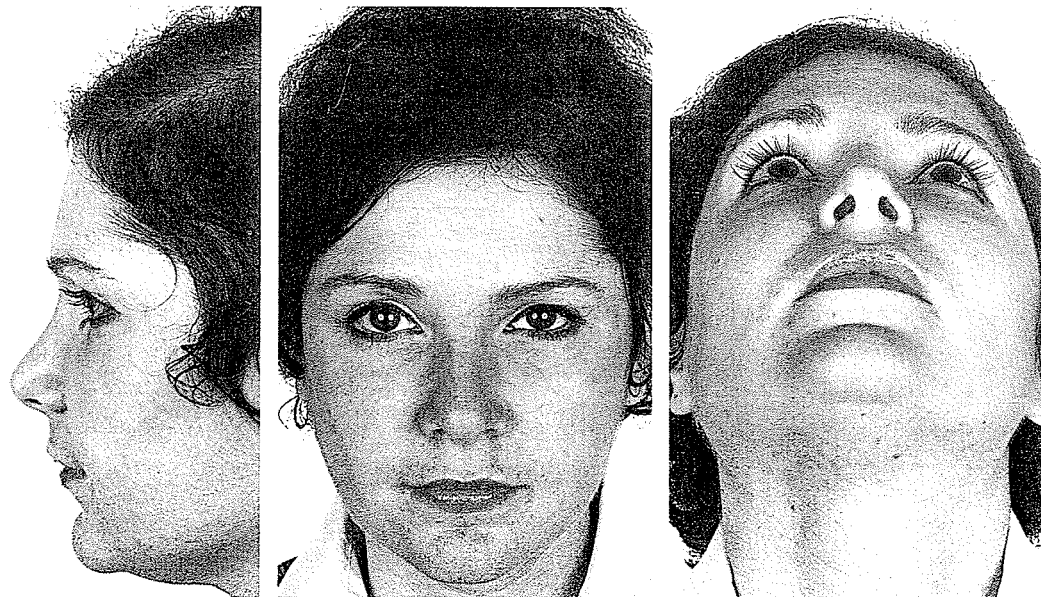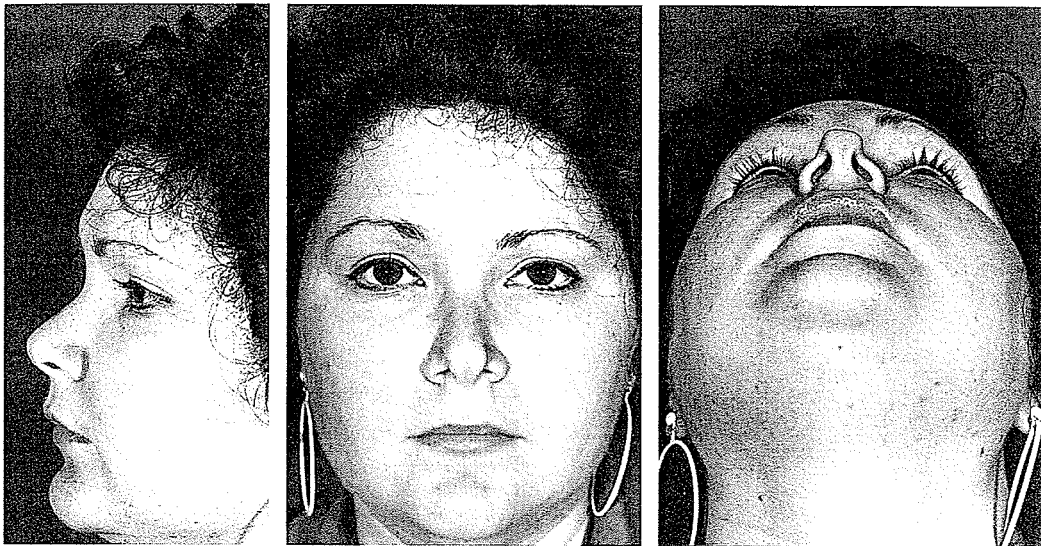
This 34-year-old male had a reduction rhinoplasty that evidently removed too much alar cartilage and interrupted the integrity of the alar arch. The pinched tip caused moderate alar collapse with reduction in the airway. Septal cartilage



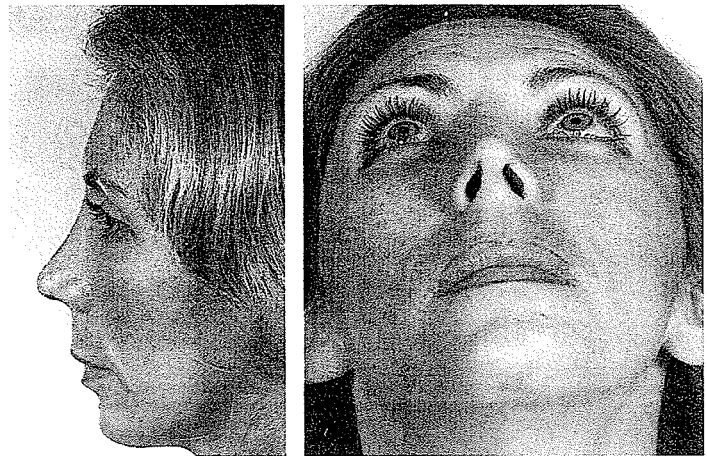
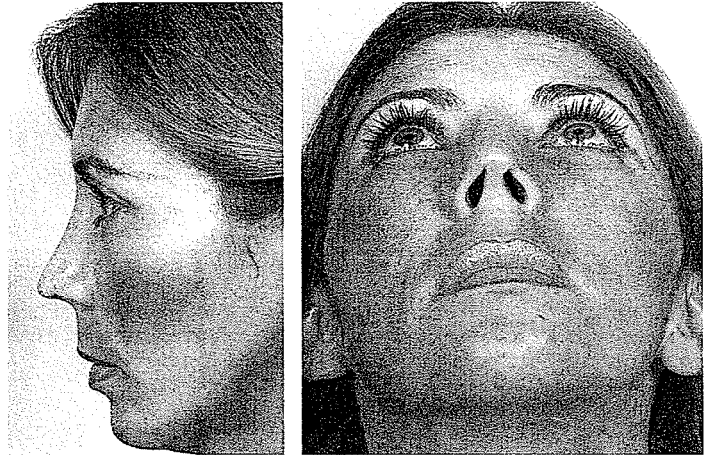
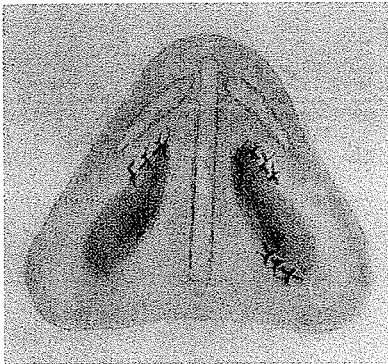
struts taken during a submucous septal resection were shaped to fill out the depressions on either side of the tip. A two-tiered graft was used on the left. These cartilage struts were inserted through marginal incisions to bridge the hollows. A bilateral osteotomy with infractures improved the width of the nasal base, and alar base wedges reduced the flare.



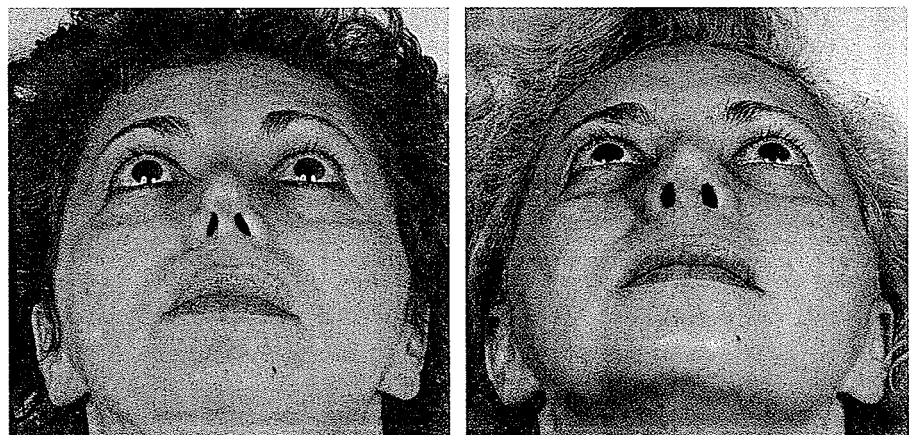This patient had suffered interruption of her alar cartilages, resulting in collapse of the alar arch. Her bridge had been lowered too much. Thus, replacement of what is missing required a two-tiered septal cartilage graft to the bridge. Reduction of the remaining excess alar cartilage, plus splinting of the collapsed sides with septal cartilage struts, brought back some of the naturalness to her nose.



Here is an asymmetric pinching of the tip that required septal cartilage strutting of the columella into the tip and splinting of the collapsed alae with onlay cartilage struts.



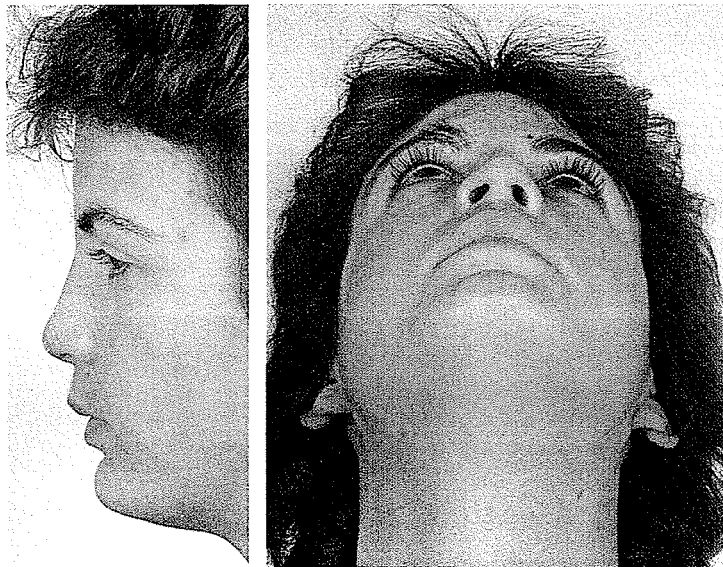
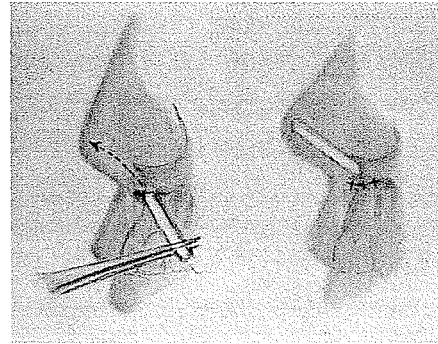
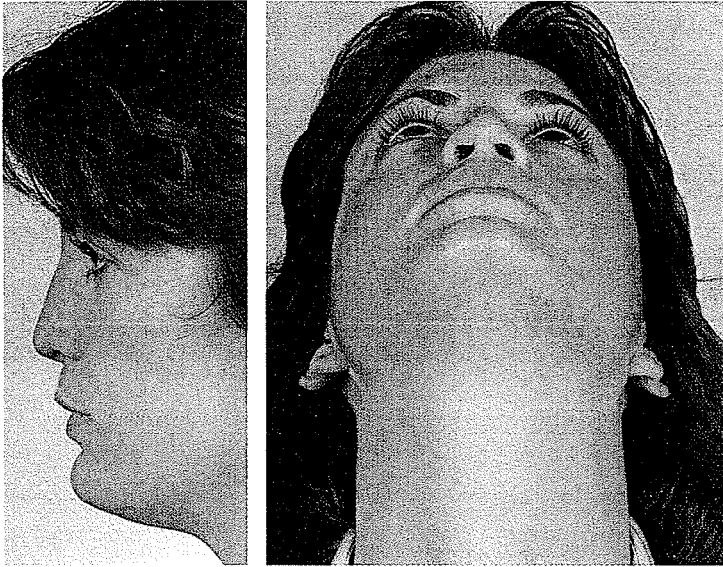
This unusual pinching beneath a bulbous tip was improved by reduction of the alar cartilage bulge and defining the tip with a cartilage strut up the columella and into the tip.





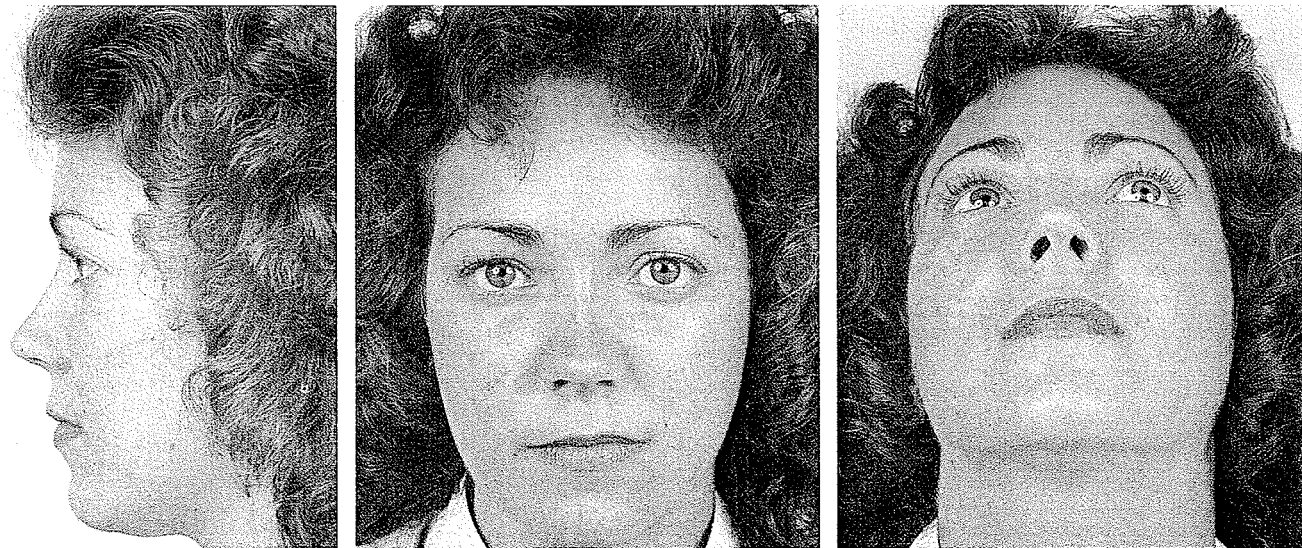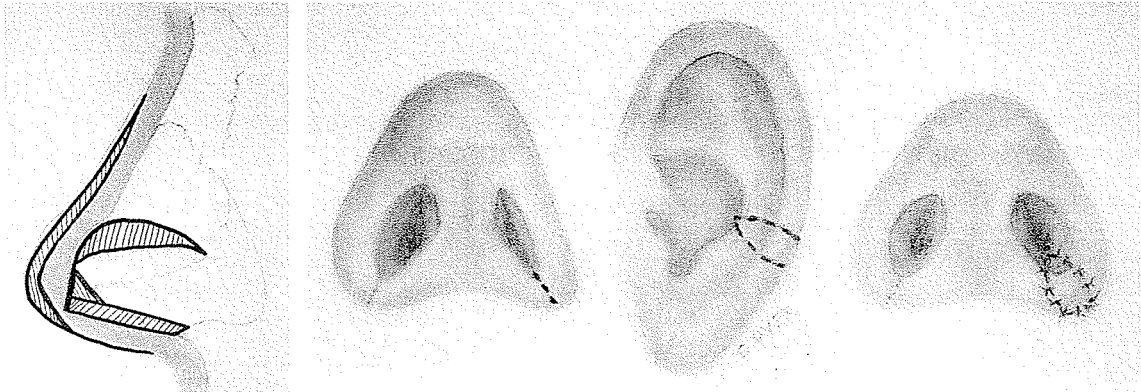
### *Depressed Tip*

There are rare incidences of postoperative depressed tip that can be improved with a septal cartilage strut inserted through the upper buccal sulcus the length of the columella and into the tip. This strut corrects columella retraction and gives projectile authority to the nasal tip.



*Other Asymmetries*

This 25-year-old female had undergone an amateurish rhinoplasty in which much had been left that should have been taken and too much removed during the left alar base resection. This required a redo of the rhinoplasty which included bridge, anterior septal, and alar cartilage re-reduction. Then a composite ear graft released the collapsed left ala.

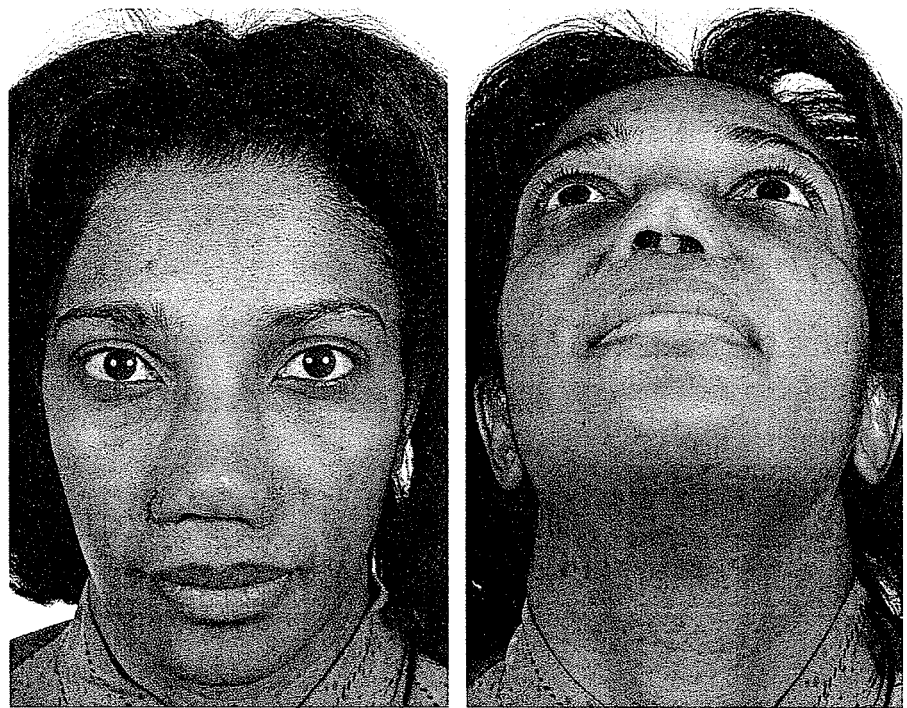

## A SECONDARY QUINELLA



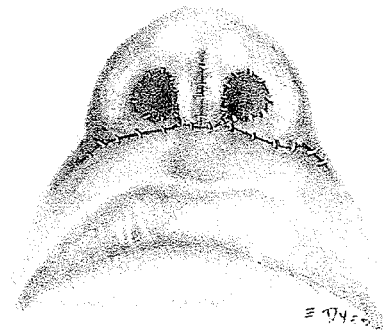
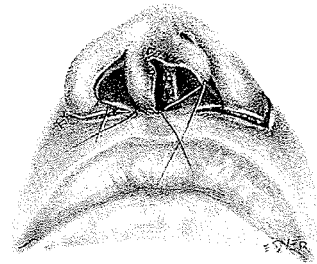
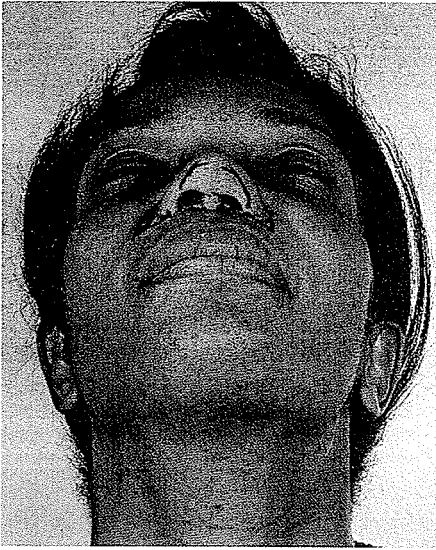
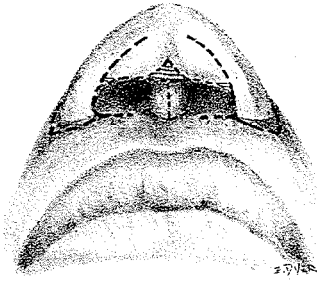
A Black nose, which is known for the difficulties it presents against refinement, was treated by all the latest rhinoplasty fads including open rhinoplasty and cartilage grafts to the tip.

This intelligent black female reminisced that she once had a reasonable nose which was not as refined as her siblings. She sought plastic surgery and received several operations. The patient recalls at least eleven operations with slight improvement only after the first two. A second surgeon started using the open rhinoplasty approach and she marked this point as the beginning of trouble. She recalled several cartilage grafts. The patient was referred to several surgeons including G. Burget, who described her case as one of the worst he had seen in his practice.

The patient was first seen by me in 1992. She was 40 years of age and had a nose that seemed to have been lengthened and flattened into a Picasso masterpiece. The short retracted columella had two transverse scars, one at the base and one at the tip. Both alae had been shortened—the left more than the right—and there was absence of alar bases and nostril sills, obviously from the injudicious use of alar base excisions. There was severe reduction in nostril skin and asymmetric distortion of the nostril apertures. There was a vertical midline scar in the tip and absolutely no definition in the tip or alae. The nasal bones were wide, but the profile line was not grotesque. As usual, the scars of the nose had healed well but this is to be expected even in the Black race.



The corrective design used the Robin Hood principle to its fullest. The overhanging alar margins were marked as flaps based medially at the tip to be transposed to each other to onlay the retracted and scarred columella. This opened and re-shaped the nostrils, effecting a shortening of the nose. The alae, in spite of their associated scars at the bases, were lengthened by a V-Y extension along the upper nasolabial line. These alar extensions were transposed at a 90-degree angle to the nostril sill position. In one procedure the transformation was encouraging. All nasal scars healed well. Unfortunately, the patient developed hypertrophic scars in the nasolabial area. These were excised and treated with Interferon by dermatologist Brian Birman.

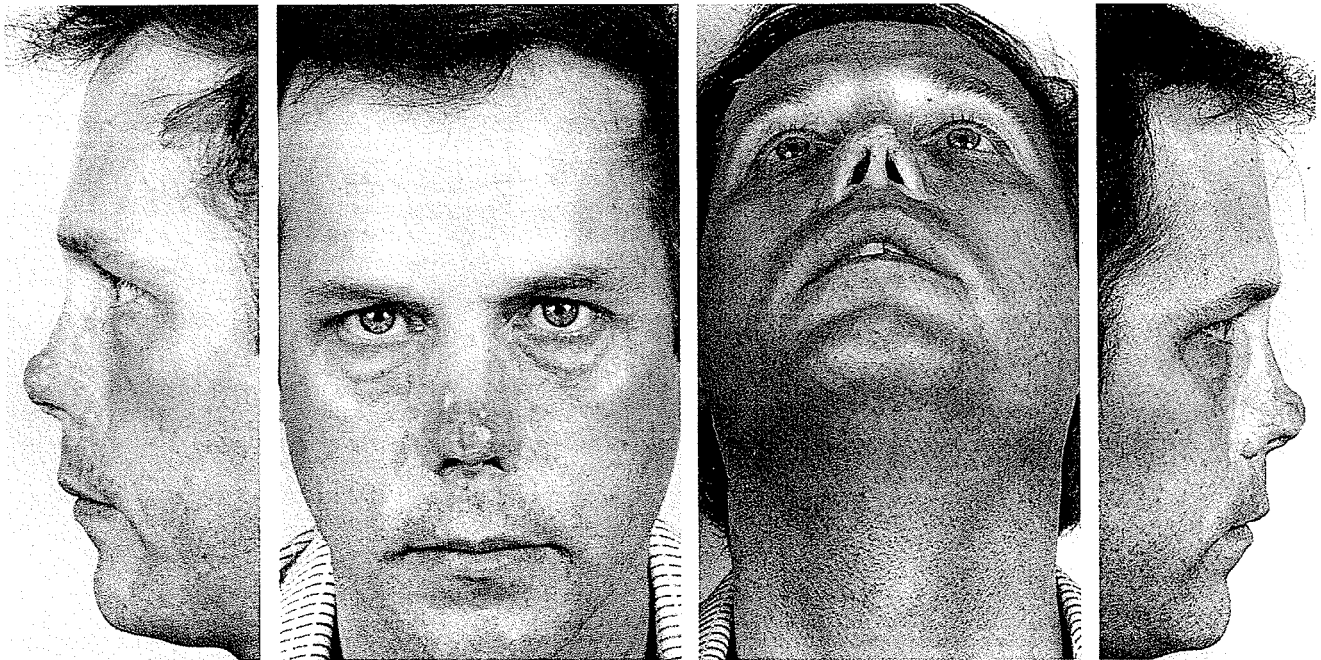




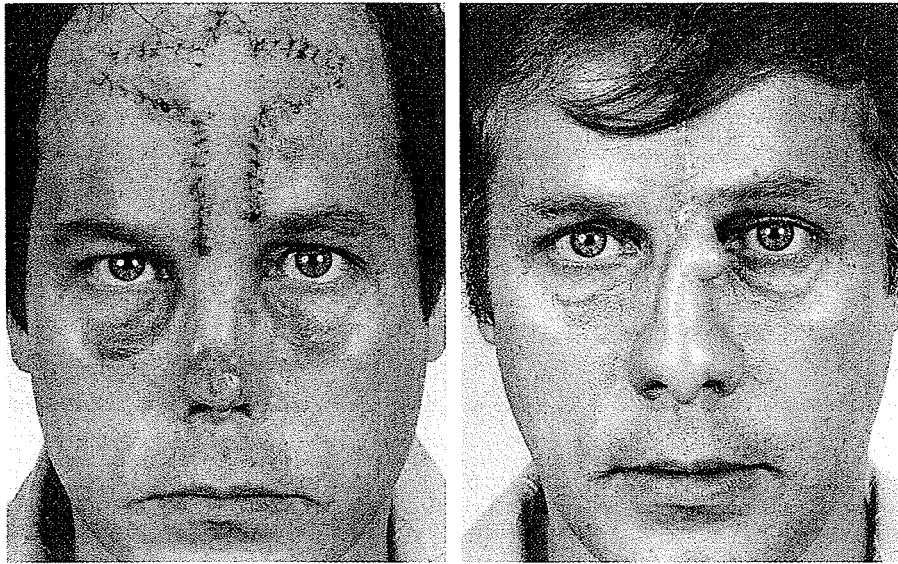## GENERALIZED SCARRING AND SHRINKAGE

Occasionally the damage done during a rhinoplasty and subsequent secondary rhinoplasties complicated by infection can be disastrous, necessitating radical reconstruction.

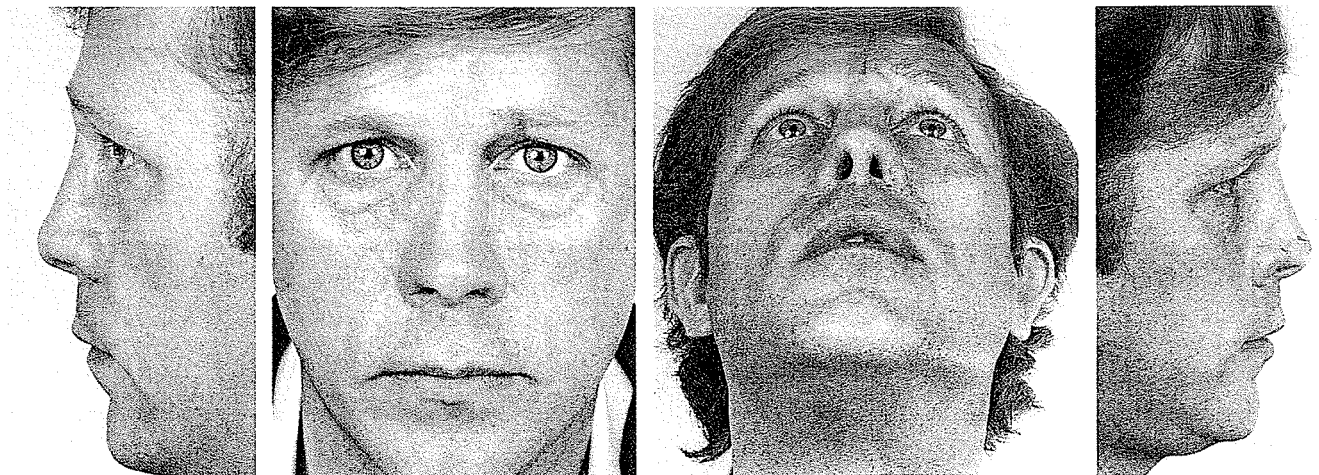Here is a secondary case of a male who evidently started with only a moderately large nose. His primary reduction rhinoplasty probably was too radical and several frantic secondary procedures using auricular cartilage and skin grafts had truly complicated the problem. The patient, an actor from a southern European nation, expressed in a letter his great expectations and was strongly discouraged from coming to Miami. He came anyway and revealed, as feared, tight, scarred skin over the entire nose with loss of length and contour and no possibility of regaining his profile by insertion of support under the contracted skin. Not only was the skin of the nose irreversibly scarred but there was also loss of landmarks, units, subunits, relationships, and symmetry, as well as a distressing lack of normal rolls, creases, and highlights.



It was explained to the patient that to regain length, height, contour, natural color and textured cover for his contracted nose, a seagull forehead flap was indicated. From the look in his eyes I expected the patient to take the next plane back home. He was given time to consider this drastic step. Quite to my surprise he returned and submitted to a forehead flap delay and subsequently to a resurfacing of his nose with a thinned forehead flap and a T closure of the forehead donor area.



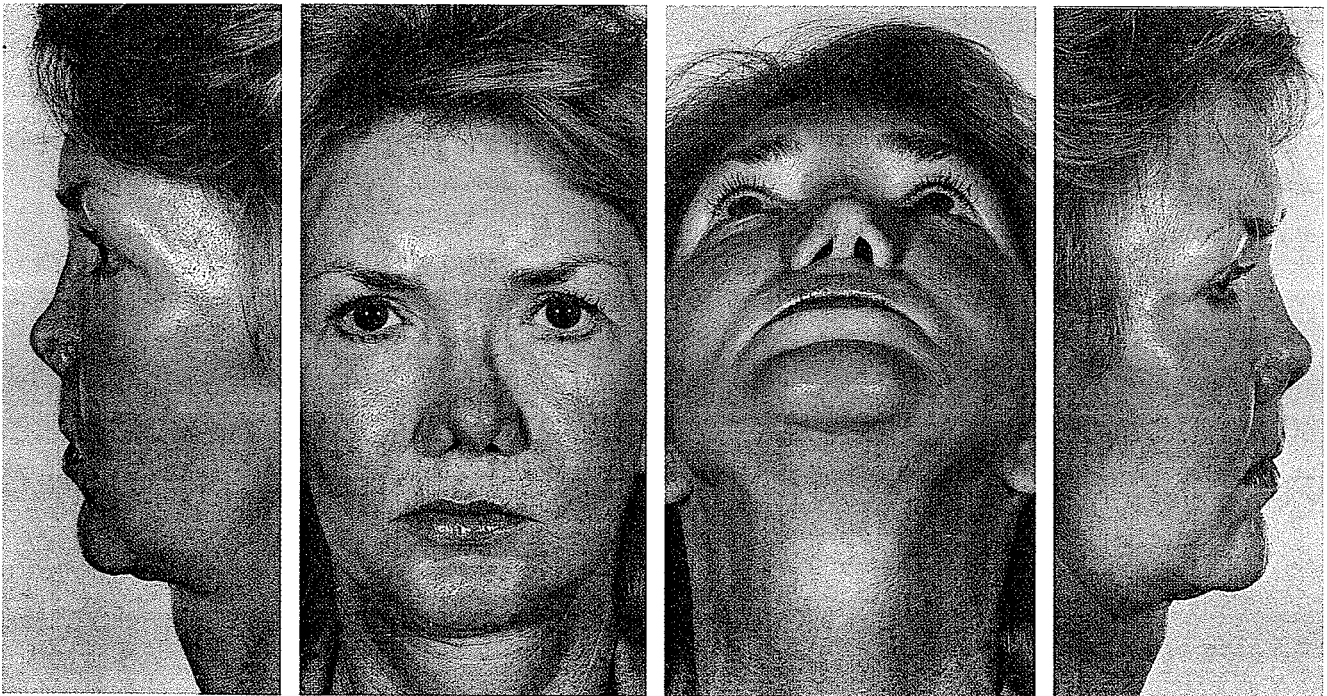
After three weeks the skin pedicle was divided, preserving the vascular bundle and replaced in the glabella-brow area. He finally returned for minor secondary sculpturing of the contours and in the end expressed satisfaction with his nasal reconstruction. He even returned years later for bilateral blepheroplasties but made no further request about his nose.



## ANOTHER RADICAL SECONDARY CORRECTION

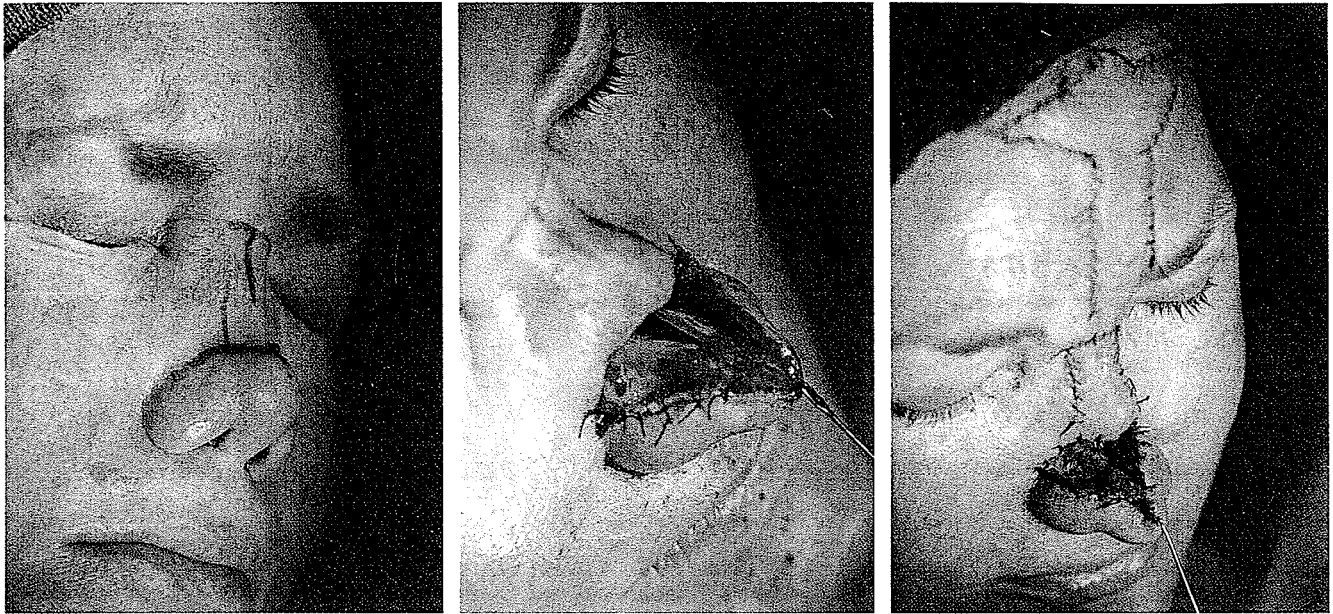
This 55-year-old female fractured her nose at the age of 12 and was operated at that time in an attempt to open her airway and straighten her nose. Although she had a well trained plastic surgeon, the surgery was not successful so at the age of 17 she was re-operated and her nose was shortened. This was also unsuccessful, so at the age of 29 another surgeon removed much of her nasal bones. At age 36 she had a silicone implant inserted and at age 52 she had the silicone implant removed and replaced with costal bone. A year later another surgeon attempted another bone graft.

When first seen at the age of 55, as would be expected the patient presented a short, flat, constricted nose with asymmetric collapse and such tense scarring that the skin envelope would accept no more structural support. What was even more amazing the patient did not seem bitter but was cheerfully willing to accept extra scars in an attempt to regain an unsubbed nose and more normal profile.



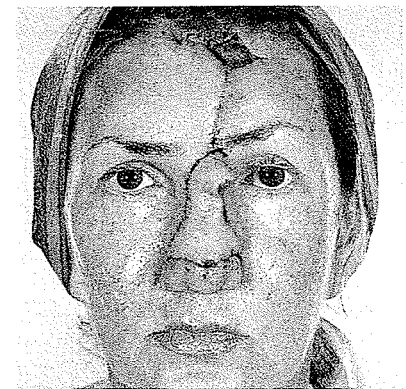

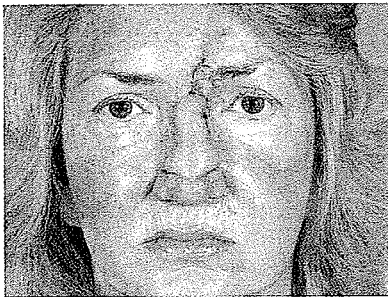
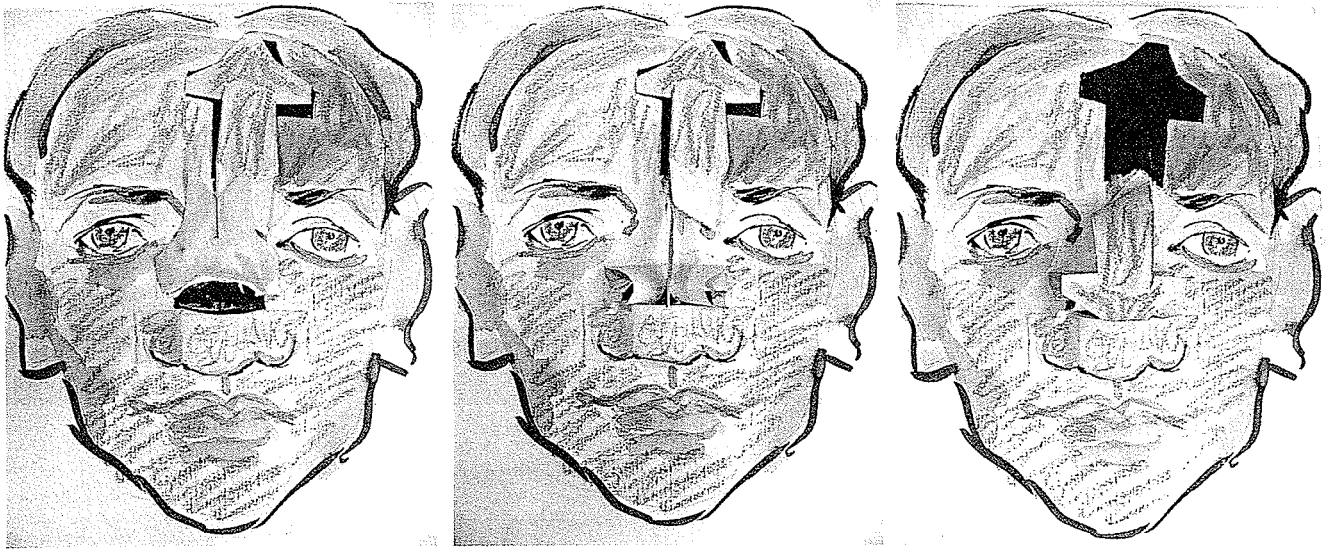
Just proximal to her tip a through and through incision released her snubbed tip and skin was sutured to mucous membrane around the margins of the defect. Her bridge skin was delayed with circumsccribing incisions and a small, falcon-shaped vertical forehead flap based on the left supratrochlear vessels was delayed with incisions.



Three weeks later the bridge flap was turned down and split to fill the lining defect. A rib cartilage graft was fixed over the bridge, the forehead flap brought down to complete the cover, and the forehead defect was closed except for a small diamond.

Two thousand years ago in China, soon after paper was invented, the original Oriental art of paper folding was developed. Khoo Boo-Chai with I. Tange in 1970 duplicated the facial cleft problem in paper and then created origami models to facilitate the study of the deformity and its surgery. R. Picard has adopted this approach to help students visualize the shifting of flaps in nasal reconstruction: first release of the tip and delay of the lining flap and the forehead flap, second turning the split lining into the defect, and finally bringing the forehead flap in for cover.





After one month the pedicle was divided and replaced in the glabella area to release the left brow. After a healing phase the flap was trimmed.

