

VIII. Evaluation and Habilitation

56. Evaluation of Velopharyngeal Closure and Speech

A comment by Kilner on his approach toward judging palate speech results is interesting:

In the past, surgeons were satisfied if they could exhibit completely closed palate defects and much ingenuity has been shown in developing ways and means of obtaining such results. Today the tongue depressor and torch should play no primary part in the examination of repaired palates. If the patient can speak clearly and naturally, if he can snort (Wardill) and if he can blow up a balloon or extend a "carnival blower," it is obvious that he possesses efficient naso-pharyngeal sphincteric control and no visual examination is needed to indicate whether the repair operation has been successful.

B Z O C H

In 1977 Bzoch of the University of Florida wrote:

The evaluation of velopharyngeal adequacy or inadequacy following primary palatal surgery does not appear to be as complicated as many of our research colleagues in the field of speech pathology indicate. It can be undertaken between 12 and 18 months of age following primary closure as a routine. Palatal valving is adequate for speech when it can be demonstrated to support normal syllable speech production. Therefore, clinical tests focusing directly on speech behavior with observations of the frequency of normal or abnormal nasal emission occurrence while impounding the breath stream for simple speech utterances, such as the word *puppy* or *paper*, provide one important index of palatal adequacy and can be obtained even with very young children. The second important direct index is a count of nasal

2. Counting to 20
- Voice quality sounds normal
 - Voice quality slightly nasal
 - Voice quality very nasal

If normal, you can stop here

3. Production of /a/ "Ah"
- Visual observation of palate
- Good movement—closure
 - Moderate movement—appears short
 - Slight movement—appears short
 - No movement
- Auditory impression
- Sounds normal
 - Sounds nasal

4. Production of /pa/ "Pah"
- Visual observation of palate
- Maintains closure
 - Palate appears to drop when the /a/ "Ah" is produced
- Auditory impression
- Sounds normal
 - "Ah" sounds nasal
 - Nasal emission of air on /p/

5. Production of /ta/ "Tah," repeated rapidly
- Sounds normal
 - Slight nasal emission of air
 - Nasal snorts

6. Production of /f/, prolonged
- Sounds normal
 - Slight nasal emission of air
 - Nasal snort

- /fa/ "Fah," repeated rapidly
- Sounds normal
 - Slight nasal emission of air
 - Nasal snorts

7. Production of /s/, prolonged
- Sounds normal
 - Slight nasal emission of air
 - Nasal snort

- /sa/ "Sah," repeated rapidly
- Normal
 - Slight nasal emission of air
 - Nasal snorts

Bensen noted that if speech is normal during conversation there is no need for further testing. Observation of the velopharyngeal mechanism through the open mouth during *ab* will reveal palate movement, and, during *pab*, if the palate rises and is making a downward excursion on the *ab*, the patient probably has the potential for closure. Further palate surgery is necessary if there is distinct sound of "cleft palateness" plus no observable movement. Speech therapy should produce near-normal speech when there is good observable movement of the palate, no nasal

emission on plosives, some nasal escape on the fricatives. Speech therapy may help, but additional surgery is probably necessary when there is nasal escape on fricatives and some plosives, with the palate appearing short and motion sluggish and nasal speech during conversation and counting.

HOOPES

Dedicated John E. Hoopes of Johns Hopkins Hospital, Baltimore, Maryland, at present divides his life between plastic surgery, training residents and occasionally escaping the former two by going sailing, "deriving an exquisite pleasure from celestial navigation." In 1977 Hoopes wrote:

My interest in cleft palate and resultant speech began in approximately 1964, and was stimulated by the plethora of non-information and personal opinion extant in the literature. It seemed clear that there existed no objective assessment of the results of palatal repair other than listener judgment and it seemed clear that listener judgment could not be compared between institutions; therefore, truly objective assessment of the results of palate repair was not available.

In 1968 in *Plastic and Reconstructive Surgery*, with Jacob Fabrikant, Hoopes noted that methods for objectively demonstrating velopharyngeal function had contributed valuable information, but all had been proved to have certain limitations. They discussed the various methods:


Direct Inspection

Direct observation of the soft palate, through a defect secondary to orbital exenteration, was first described by Wardill and Whillis (1935); similar observations were made by Calnan. . . . Although this information has been of value in speech research, there is minimal correlation between the appearance of the velopharyngeal structures and the speech which they are capable of producing.

Radiography. . .

Cephalometry. . . The limitations of the procedure are related to the single film, sagittal plane technique.

Tomography. Hage and Brauer utilized tomography to determine the length gained by palate pushback procedures. . . .



John Hoopes

First was
Hilton, 1836.

Cineradiography. . . . Cineradiographic evaluation of velopharyngeal function offers the advantage of direct and measurable visualization of palatal excursion during speech. There exists strong positive correlation between measurements of velopharyngeal closure by the cineradiographic technique and speech ratings. The addition of synchronous sound recording by Bjork is a refinement contributing to the value of the procedure. The major limitation of the technique is that, at present, motion can be observed only in one plane. . . .

Nasal Air Escape

Measurement of the quantity of air escaping through the velopharyngeal orifice during speech has played a significant role in the continuing search for a satisfactory method for evaluating speech objectively. Kymographic tracings of nasal air escape were reported by Biebendt in 1908. This area of investigation was pursued by Buncke and Chase. Sophistication of the technique by Warren has allowed the precise calculation of velopharyngeal orifice size. A number of objections have been raised regarding the value of the technique. Spriestersbach demonstrated radiographically that 38 of 47 patients used the tongue and palate, rather than the velopharyngeal sphincter, to valve for puffing. . . . Calnan reported on a group of 225 patients, all of whom exhibited palato-pharyngeal incompetency during phonation, but 85 of whom achieved closure during blowing. McWilliams emphasized . . . speech demands velopharyngeal behavior that is physiologically different from that required for blowing. . . .

Acoustic Analysis

The technique of analyzing speech acoustically has been applied to cleft palate subjects only to a very limited degree. Bjork suggested that analysis of sound spectrograms, synchronized with cineradiographs, might form an important basis for assessing speech results postoperatively. . . . Weatherley-White utilized a prototype instrument. . . .

Electromyography

Electromyography still remains, at this time, a basic research tool without demonstrated clinical applicability.

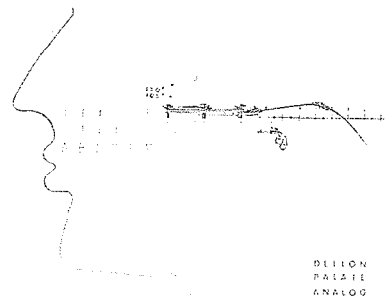
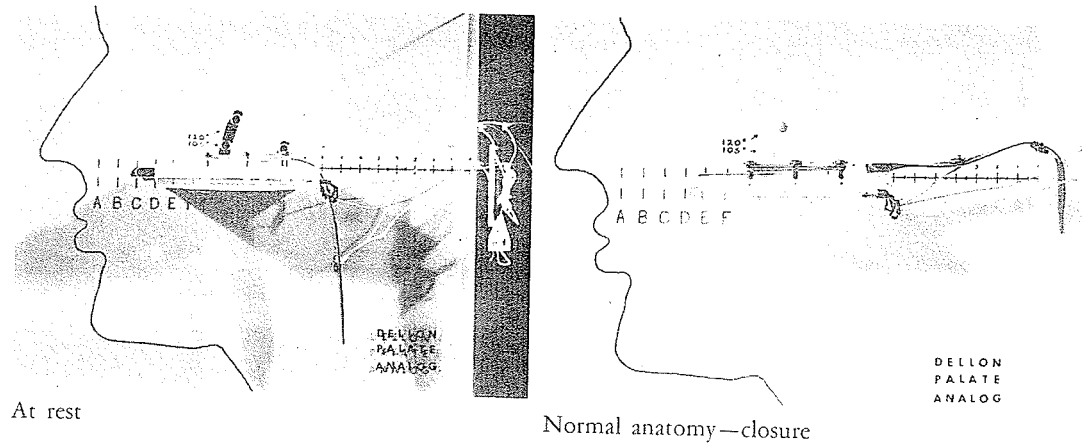
THE BIONIC PALATE

Through the work of Hoopes and Fabrikant and Yules, Northway and Chase, functional velopharyngeal relationships were being defined more precisely by means of cineradiography.

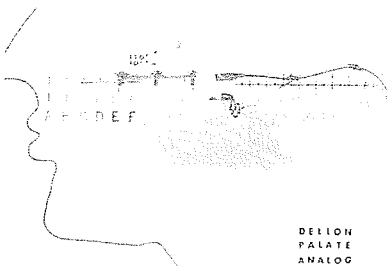


Lee Dellon

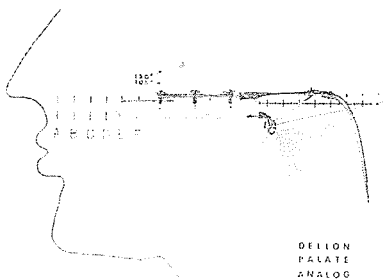
Meaningful interpretation of data within the total framework of the pertinent functional anatomical variables called for the construction of a functional mechanical model of a velopharynx. Lee Dellon, with the assistance of John Hoopes, at Johns Hopkins Hospital, constructed a *palate analogue*.



Short velum—no closure



Deep nasopharynx—no closure



Anterior levator insertion—no closure

As noted by Dellon and Hoopes in the *British Journal of Plastic Surgery* in 1970:

The palate analogue gives dynamic representation only to the levator and tensor veli palatini muscles and the palatopharyngeus muscle. . . .

The hard palate is represented by a rigid plate which is variable in position with respect to the posterior pharyngeal wall. The soft palate is represented by a flexible elastic structure which is variable in length. The posterior pharyngeal wall is represented by a fixed rigid plate. Three muscles: (1) levator veli palatini, (2) tensor veli palatini, and (3) palatopharyngeus are represented bilaterally by silk ligatures which are variable in length, i.e., can be "contracted". The levator insertion is variable in position throughout the length of the soft palate.

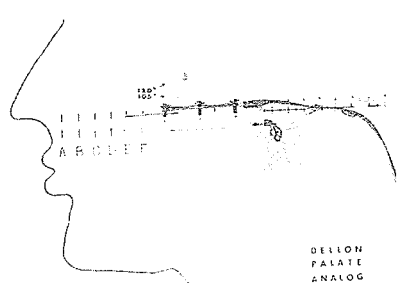
The palate analogue is claimed basically to be

a manual analogue computer which is "programmed" to "read out" visually in terms of velopharyngeal incompetence and type of closure after being "fed" such data as levator insertion, depth of nasopharynx, and soft palate length.

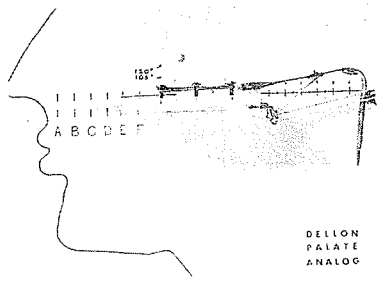
Dellon and Hoopes stated:

At the anatomical level, the palate analogue provides a dynamic view of the relationships between structure and function. At the speech pathology level, the palate analogue provides a powerful instructional tool capable of

visually demonstrating the aetiology of hypernasality and nasal emission on the basis of anatomical variables. At the surgical level, the palate analogue provides an objective rationale for the selection of specific surgical techniques best suited to the individual case. With regard to this latter explanation, a patient's cineradiographic data can be converted to palate analogue scale and plotted . . . to illustrate graphically which of the anatomical variables are abnormal and to what degree surgical correction is required. Decisions regarding palate lengthening procedures and/or surgical augmentation of the posterior pharyngeal wall can be entered into with precision.



Anterior levator insertion—compensated closure vs. adenoids




Anterior levator insertion—compensated closure after posterior pharyngeal implant or pharyngoplasty

AERODYNAMICS OF THE VELOPHARYNGEAL ORIFICE

Spriestersbach

Duane C. Spriestersbach, dean of the graduate school at the University of Iowa, has had his pioneering work in cleft palate speech pathology facilitated by a remarkable ability to work with, but without threatening, other specialists of his team. In 1977 he recalled the beginning:

While a young, new assistant professor in speech pathology in a department with a long-standing research tradition, the senior member of the faculty responsible for cleft palate resigned, and suddenly I had a great deal of learning to do. My mentor, Wendell Johnson, advised me to concentrate in depth on some aspect of speech production and soon I would identify more questions than I could ever answer. I tried to follow his suggestion and have never run out of questions. Dean Lierle, the head of the Department of Otolaryngology, gave me an appointment in his unit and started me on my way working in interdisciplinary environments.



Duane Spriestersbach


A colleague in our department had developed a detailed, systematic interview technique for studying the *families* of children who stuttered. This was adapted to the study of families of children with clefts, and on the third try, N.I.H. agreed to support an extensive study of the psychosocial aspects of the "cleft palate problem," which included medical, dental, speech, audiometric, radiographic and psychological examinations. Previous speculation about effects of poor physical development of the child with a cleft questioned respiratory supply and control. A wet spirometer gathering dust in the laboratory was mobilized for measurements and the patients, of course, had to hold their noses. We took measurements both with the nostrils closed and open and later began to see a relationship between the ratio of closed and open measures and the adequacy of speech articulation. Out of this effort, not unlike the fortuitous roasting in Lamb's *Dissertation on Roast Pig*, grew the development of the oral manometer with a "bleed" that provides a clinical measure of the efficiency of the velopharyngeal valve used today.

Since our psychosocial study was long-range, we found ourselves dealing with peripheral data and were embarrassed for ourselves and others for the unwarranted assumptions about the homogeneity of cleft populations in previous research. Our growing insight about this reality caused us to look for better specifications of the physiological requisites for adequate speech, appreciating the variances that could exist within the functions of the several structures responsible for the total speech mechanism.

Frequently, when one asks a surgeon (or dentist or speech pathologist) how he or she accounted for a particular superior result, the answer is, "Well, in my hands. . . ." This is not where the communication should end. Clinical research is difficult but no less inherently scientific than basic research; every clinician is a researcher who should communicate, test and validate. The consequences of such an approach improve our chances for expanding the body of knowledge on which the quality of our lives, and perhaps our survival, depends.

Warren

Donald W. Warren, chairman of the Dental Oncology Department, University of North Carolina School of Dentistry, was brought up in the Flatbush section of Brooklyn and went south to the University of North Carolina at age 17 with his belongings packed in a laundry bag. During his dental school days, he married a young lady with a love of horses. After he learned to ride, he became interested in fox hunting and ended up president of the Red Mountain Foxhounds out of Rougemont, North Carolina. As he says:



Donald Warren

After a hard day at the orifice (velopharyngeal, that is), I usually take off on my horse for a few hours of unwinding. Erle Peacock told me it was an adolescent trait that would not last. However, the last time I saw Erle, he mentioned that he bought a horse and now rides off into the sunset around the mountains of Tucson.



While studying at the Lancaster Cleft Palate Clinic, Warren became interested in palate studies. Using measurements of airflow through the nose and air pressure in the mouth in a ratio, he developed a formula that can predict the size of the velopharyngeal port. In 1977 he wrote his thoughts on this in cleft palate:

The effect of cleft palate on the respiratory components of speech was recognized long ago and a number of crude devices have been developed to provide a gross assessment of palatal function. These devices include, among others, U-tube manometers, mirrors which record nasal fogging, and various blowing devices which, at best, provide a gross indication of nasal escape.

The use or abuse of assessment tools depends to an extent on the clinician's understanding of the effects of palatal incompetency on speech performance. Complete separation of the nasal and oral chambers should occur for all consonants except *m*, *n*, and *ng*. However, normal voice quality and intelligibility can still be achieved in the presence of very, very small openings. Studies indicate that some normal speakers may have palatal openings of 1–3 mm.² for non-nasal consonants during speech. Usually, however, the sphincter is tightly closed.

In cleft palate individuals, the upper limit of velopharyngeal adequacy is approximately 20 mm.², although in most instances it is as small as 10 mm.². The reason for this variation is that many other factors affect speech performance besides palatal closure. For example, in the range of 10 to 20 mm.², the position of the tongue and mandible during phonation influences the amount of air which leaks into the nose. High tongue position impedes airflow through the nose and mouth and since air will flow through the region of least resistance, this results in greater nasal emission through the palatopharyngeal opening. Similarly, greater effort during speech also increases nasal emission of air, regardless of the size of the palatal opening. While the range of adequacy varies up to 20 mm.², greater than 20 mm.² is always inadequate for normal speech.

The effects of tongue placement and other compensatory phenomena associated with clefting are emphasized because in most instances, the measurements obtained by simple manometric tools such as U-tube manometers and blowing devices are influenced more by these activities than the degree of incompetency present. Thus, an instrument which measures

nasal emission of air alone may reflect effort more than palatal competency.

In addition, many of these measurements are made during non-speech activity such as blowing or sucking, and individuals with incompetent closure can sometimes perform these activities satisfactorily utilizing lingual-palatal contacts.

The problems associated with simple devices do not negate their use providing the clinician realizes the possibility of artifacts, especially in the borderline incompetency range.

Recognition of these problems has led to the development of more elaborate, complicated and expensive instruments for objective evaluation of cleft palate speech. The basic components of the aerodynamic measuring systems are flowmeters which record volume rates of airflow and pressure transducers which record airway pressures within the vocal tract. Used individually, these instruments are subject to the same inaccuracies as the less expensive devices. For example, flowmeters have been used to estimate velopharyngeal competency under the assumption that nasal airflow is linearly related to palatal function. However, there is good evidence that this assumption is not true. The same problem of contamination by compensatory phenomena is present with these instruments when used alone.

When flowmeters are used in conjunction with pressure transducers, velopharyngeal function can be separated from the influence of compensatory adjustments by other vocal tract structures. Hydraulic equations have been used to measure such parameters as velopharyngeal orifice size, nasal airway resistance, oral port opening, and the timing of consonant production in order to identify the compensatory adjustments, most often maladjustments, which occur in response to incompetent closure.

The advantage of techniques which directly measure the size of the sphincter is obvious, since this is precisely the information that the surgeon should know. Comparison of preoperative and postoperative speech samples is not an effective method of evaluation, since poor articulation may remain even after successful surgery, thereby masking the surgical result.

The drawback to this approach is that the instruments are more complex than the average clinician desires, and a compromise between simple devices and sophisticated techniques is desirable. This means that a manometric instrument should be simple to use, inexpensive, and able to delineate palatal function from other articulatory influences. The solution is to use an instrument which records the difference between oral and nasal pressures during plosive consonant production, such as the /p/ sound. A zero pressure obtained with this differential pressure transducer technique means that the palatal function is so minimal that pressure in the nose equals pressure in the mouth, or there is no functional separation between the cavities. As the palatal mechanism improves in its ability to achieve closure, the pressure

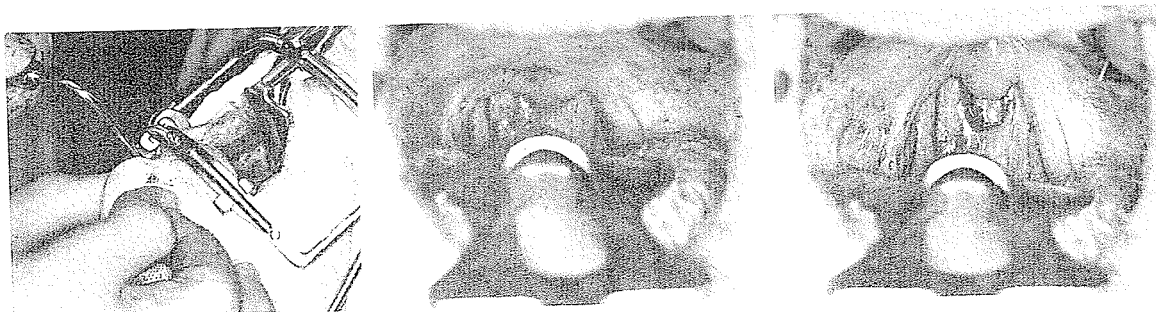
difference rises. Utilizing this instrument during production of plosive consonants eliminates the effects of tongue and mandibular position, since the oral cavity under these circumstances encloses a stagnant column of air. Similarly respiratory effort would have no effect since a difference in pressures, both influenced by effort, is involved. This allows the surgeon to evaluate palatal function directly, rather than recording some indirect parameter somewhat related to the individual's speech performance. Limiting assessment to the palatal sphincter is the only valid way the surgeon can judge his specific contribution to the speech habilitation process.

Postoperative suction test

There is an immediate postoperative test which is a reverse aerodynamic challenge of the velopharyngeal seal, used for many years by a multitude of surgeons to estimate the effectiveness of the palate surgery and predict the eventual, or potential, velopharyngeal closure. In 1972 David Sullivan of Spokane wrote about this palate suction test:

The suction test, which I learned from Mr. Moore and which I find very useful, may not be original with him. A metal suction tip is introduced well back in one nasal cavity, then the hole in the suction tip and both nares are occluded while watching the velopharyngeal opening from the oral side. In a positive test the soft palate, posterior pharyngeal wall, and the sidewalls of the nasopharynx are quickly and readily pulled together to form an air-tight seal. This test is carried out before starting the operation. Presumably if it were positive at that time, there would be no indication for the operation. In practice, the test is always negative. If, after surgery, the test is positive, the surgery is over.

It wasn't!



This is indeed an excellent guide and, although I have been using the suction test for years, I cannot say who first used it.

Fluoroscopy by Borel-Maisonny

In 1948, I had the unique opportunity to visit Victor Veau's Hôpital Saint-Michel and to talk with his speech pathologist, as reported in "Plastic Peregrinations," 1950.



Susanne Borel-Maisonny

No one is in a better position to judge Veau's palates than the devouée Madame Borel-Maisonny, his speech therapist for twenty-five years. Often as early as two weeks following surgical closure of the palate, Madame Borel evaluates the result. A 20 cc. syringe of liquid barium is injected into the naris, thus coating the nasal surface of the palate. With the patient's profile under fluoroscopy, the different positions of the palate during certain fundamental sounds are marked on tracing paper. It is possible for Madame Borel to predict the prognosis of each palate, prevent adenoidectomies when that excess tissue is needed, prescribe obturators when the palate is insufficient in length. She says she has been able to obtain normal speech results in 74% of Veau's palate cases. In some of these cases it was necessary to fit an obturator against the pharyngeal wall for the short but mobile palate to play against for normal speech. Then there were always the few short and scarred palates from which normal speech can never be formed.

It is interesting that 25 years later there was only a 1 percent improvement over Veau's palate results. In 1973 Hughlett L. Morris of the University of Iowa reviewed the literature between 1960 and 1971 to determine the percentage of patients with velopharyngeal competence, as judged by "speech results" following primary cleft palate surgery. He concluded:

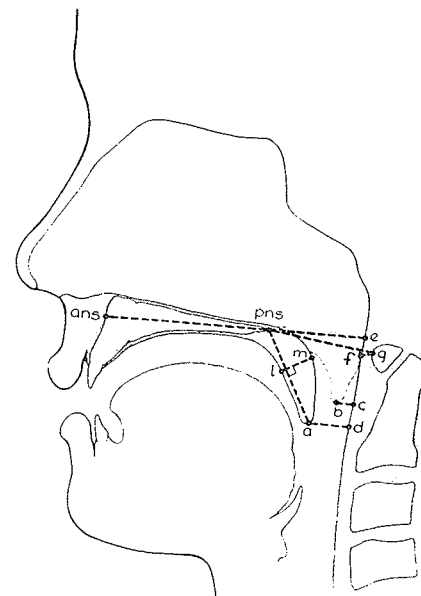
A success rate of 75% seems reasonable in estimating the velopharyngeal competence results from primary cleft palate surgery, although it is apparent that the success rate is influenced by many factors.

Yules

In 1968 in *Plastic and Reconstructive Surgery* Richard B. Yules, while still a resident, with William H. Northway, Jr., and Robert A. Chase of Stanford University School of Medicine, reported quantitative data accumulated from routine sound cinefluorography of 68 cleft palate patients, 24 velopharyngeal incompetent patients and 34 controls. A standard speech test was used, consisting of vowel and consonant sounds, single words (designed to test linkage of vowel and consonant sounds), connected speech,

spontaneous speech, blowing and swallowing. Lateral studies were performed by single-frame and sequential-frame analyses, utilizing a Kodak cine-analyzer projector. Measurements were determined directly from the image projected onto a paper screen and corrected for the magnification present in each frame, as indicated by the metal marker disk. Eight separate measurements were determined:

- (1) HPA: the hard palate to atlas distance of the posterior nasal spine (pns) to the mid-anterior atlas (pns-g)
- (2) HPP: the hard palate to posterior pharynx distance, or distance along a line drawn through the anterior (ans) and posterior nasal spine to the posterior pharyngeal wall (pns-e)
- (3) SPL: the soft palate length, or distance from the pns to the soft palate tip (pns-a)
- (4) EPL: the effective palate length, or the length of the soft palate in the plane of velopharyngeal closure (pns-f)
- (5) SPT: the soft palate thickness taken perpendicular to the SPL line at its thickest point (l-m)
- (6) RDUP: the resting distance from uvula or soft palate tip to the pharynx, taken on a line parallel to the HPP (a-d)
- (7) QDUP: the distance of the uvula from the pharynx when the soft palate was maximally stressed for velopharyngeal closure, i.e., while saying the word "quack" (b-c)
- (8) RDPA: the resting distance from the pharynx to the atlas, taken from the point of closure or expected closure on the posterior pharyngeal wall to the atlas (f-g)



No statistically significant differences in measurements were obtained by age or sex grouping. Certain other important differences were, however, noted:

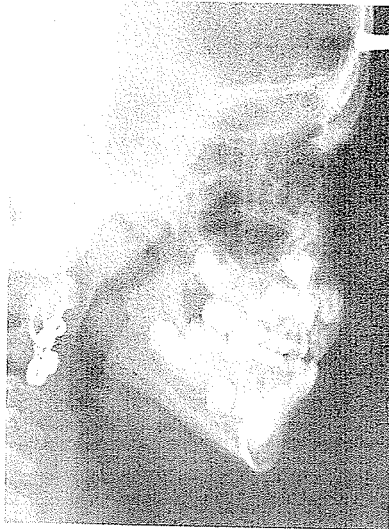Control soft palate length was shown to be longer than in cleft palate and velopharyngeal incompetent patients; hard palate to pharynx distance was increased in velopharyngeal incompetent patients, compared with controls and cleft palate patients. . . . Routine sound-synchronized ciné-radiography is in itself dramatic in a descriptive sense; it will become most useful when it is quantified to the extent that the surgeon may choose from a given set of operations and a speech therapist choose his therapy from quantitative data which will allow prognostication.

Berkowitz

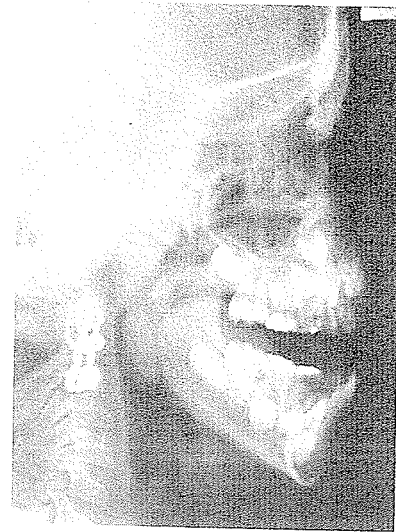For years Sam Berkowitz has been carrying out lateral cephalometric evaluation of velopharyngeal function in our cleft palate clinic. Here are some of his 1977 comments:

Cephalometric roentgenology has contributed static and dynamic data of interest to the speech physiologist. It has been utilized to study variations on the depth and configuration of the oral and pharyngeal cavities, and in the measurement of the adenoid and soft palate. Understanding the dynamics of growth and development of the nasopharyngeal spaces and their contiguous organs is essential for a proper evaluation of the speech mechanism. Many studies have emphasized the need to appreciate the structural variations that

Incompetent velopharyngeal closure

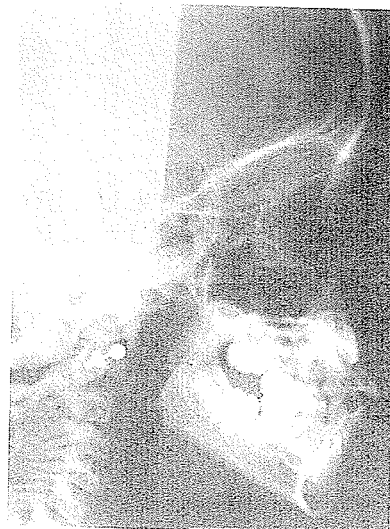
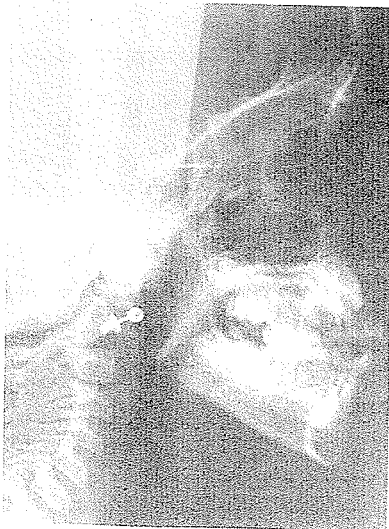
At rest—velum lying on dorsum of tongue



Vocalizing "Youuu. . ." velum elevates but fails to make contact with adenoid

Incompetency due to velar paralysis



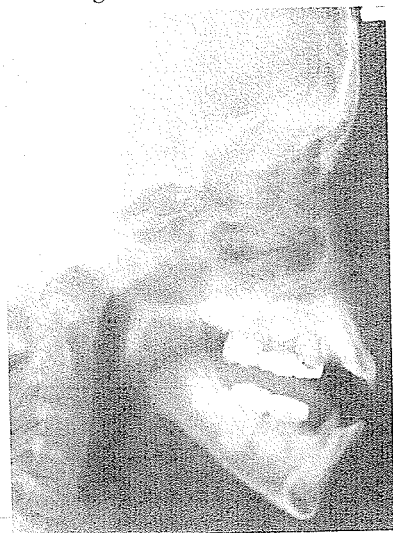Neuromuscular malfunction evidenced by failure of soft palate to elevate while phonating "Youuu. . ."

might exist in the intra-nasal and pharyngeal architecture of infants with various clefts of the lip and palate.

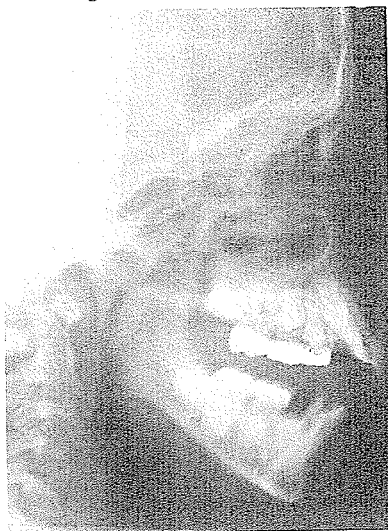The lateral cephalograph is an excellent diagnostic tool to assess the capabilities of the patient to perform proper velopharyngeal closure in the anteroposterior dimension. It has permitted the clinicians to appreciate the significance of the variations in the dimensions of the pharynx and pinpoints those factors which determine the success or failure in obtaining proper air flow control and which might be beyond the influence of the surgeon's skill. *It is impossible to assess velopharyngeal closure by preoral examination due to the abnormal posture of the head and the line of visual inspection.* It has been stated that cephalometric films can provide single point-in-time estimates of velopharyngeal function that agree rather well with cinefluorographic observations with sounds *s* and *u*. It appears possible to make meaningful generalizations concerning dynamic aspects of speech from cephalometric data.

Three head plates are taken: one at position rest, the second during sustained phonation of the vowel *u* ("Youuu. . ."), and the third while saying *s* ("sss. . ."). These films reveal information related to:

Vocalizing *u*



Vocalizing *s*

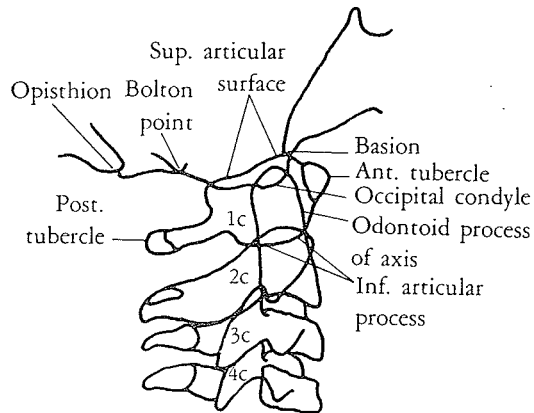


Stretch reflex: the ability of the soft palate to increase in length during function. Left. Incompetent closure when vocalizing "Youuu. . ." Right. Soft palate now makes contact when vocalizing "sss. . ." because of its increase in length. These patients are amenable to speech therapy and need not have palatal surgery unless all else fails.

1. length of velum at rest and in function
2. variations in the skeletal framework that determine the outlines of the nasopharynx
3. relationship of the adenoid tissue to the nasopharynx
4. the neuromuscular functional capabilities of the pharyngeal musculature.

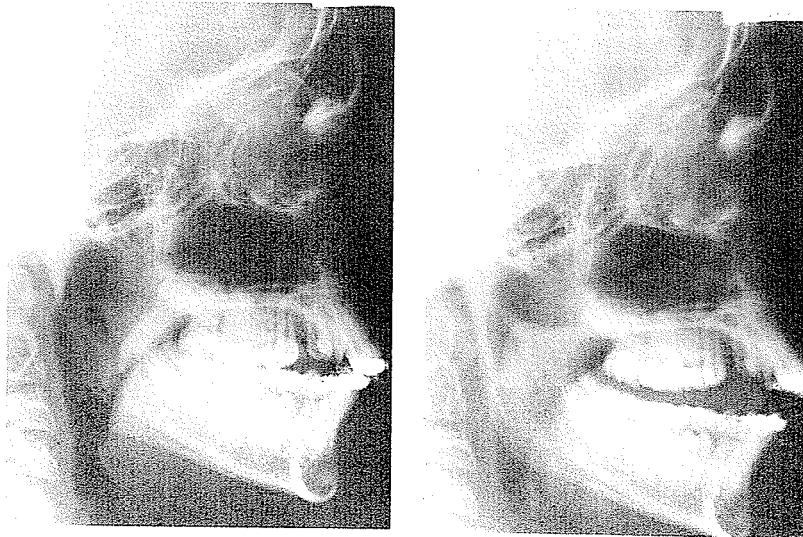
Nasopharyngeal Configuration

Velopharyngeal valving is dependent not only on the sensory-motor adequacy of the velum and synergistic musculature, but also upon the morphologic dimensions of the nasopharyngeal port. The size and shape of the nasopharynx is determined by the contiguous osseous anatomy of the maxilla, cranial base and vertebral column. Various anomalies of the cervical vertebrae, such as fusion of C₂ and C₃, occipitalization of the atlas, malfor-



Normal radiographic anatomy of the cervical vertebrae

mation of the anterior tubercle of the atlas, and malposition of the atlas, increase the pharyngeal depth and are often seen in patients with congenital palatopharyngeal incompetence (CPI).

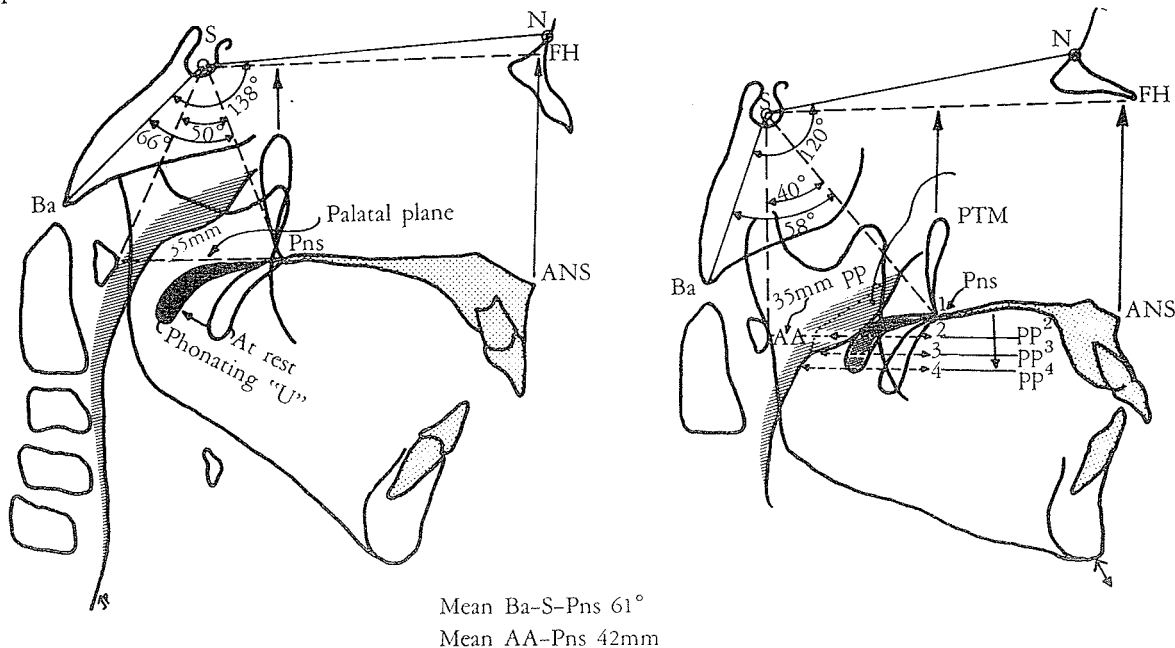


Malformation of the atlas associated with an increase in the AP pharyngeal dimension. Pharyngeal flap used to correct velopharyngeal incompetence. *Note:* Posterior pharyngeal wall being pulled forward during function.

Variability of the Anteroposterior Pharyngeal Dimension

Ricketts demonstrated that problems in the cranial base and skeletal structures, rather than in the palate alone, can be responsible for cleft palate

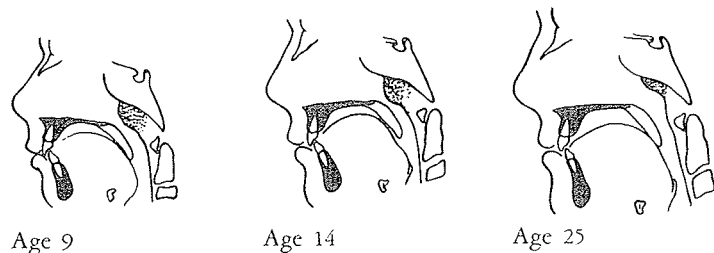
speech. Deep retropharyngeal dimensions are often coexistent with obtuse cranial bases which distally position the cervical spine relative to the maxilla. He demonstrated that there can be cleft palate speech if there is a deep retropharynx with or without adenoid tissue. Yet, in another case, without adenoid tissue but with a shallow retropharynx (due to an acute cranial base which brings the cervical spine closer to the maxilla, and/or due to an exceptionally large anteroposterior maxilla), there might be normal speech. The utility of the adenoid tissue in velopharyngeal closure is related to the overall dimensions of the nasopharynx. If the adenoid is exceptionally large and/or close to the posterior nasal spine of the maxilla, it may block off the posterior nasal choanae and cause nasal atresia with denasal speech.



As the face grows, the palatal plane (pp) descends away from the anterior cranial base (NS), affecting the pharyngeal depth. This dimension increases with growth. (Berkowitz, S.)

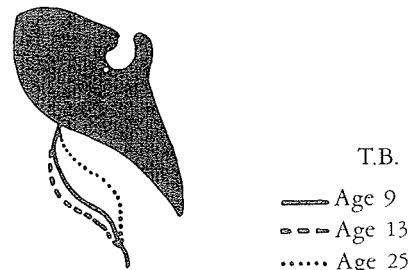
Subtelny has demonstrated that the AP pharyngeal dimension increases with growth and the soft palate has to span a greater distance in order to make contact. Hypernasality, therefore, can occur at a later date with or without adenoidectomy.

Atrophy of Adenoid Tissue



Subtelny

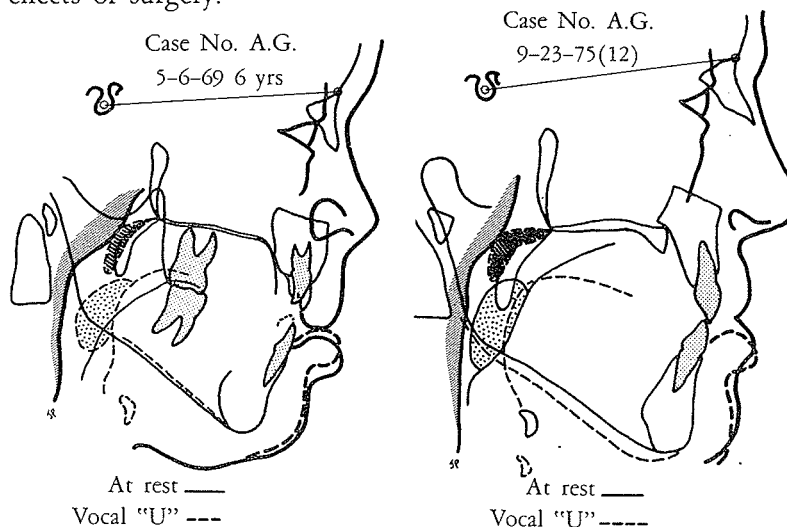
Atrophy of Adenoid Tissue



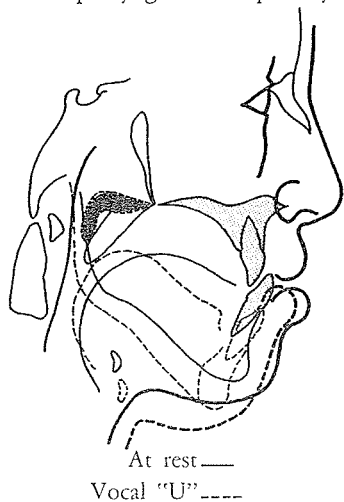
Subtelny

T.B.
— Age 9
- - - Age 13
..... Age 25

Not all cleft palates have inadequate velopharyngeal function. The pharyngeal dimensions are not related to the cleft type, but are influenced by the effects of surgery.



Mid-facial hypoplasia with velopharyngeal incompetency



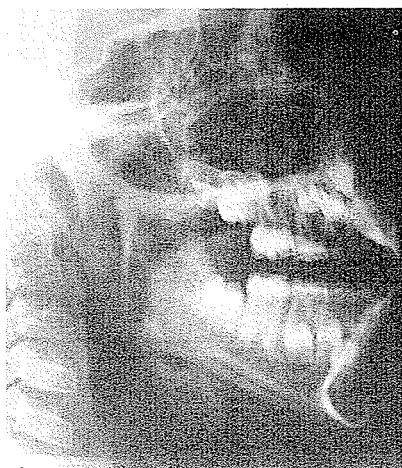Adequate velar closure in bilateral cleft lip and palate due to a very well-developed maxilla coupled with a very shallow pharyngeal space is shown. Although this dimension increased slightly in six years, velar closure remained competent.

Mid-facial hypoplasia was brought on by non-physiological surgery. Maxillary size was reduced in all three dimensions, resulting in an anterior dental crossbite, erroneously diagnosed as being due to an oversized mandible. Failure of the maxilla to develop in the anteroposterior dimension increased the depth of the pharyngeal space, causing velopharyngeal incompetence.

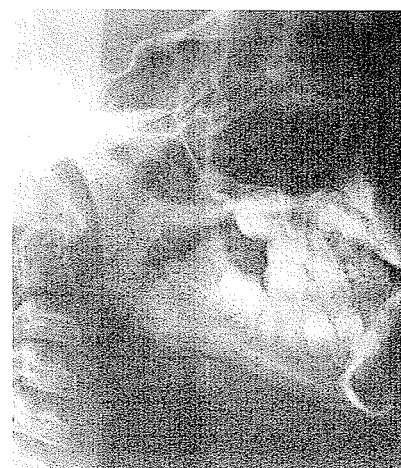The Pharyngeal Flap Procedure

Many excellent reports support the continued use of this procedure for the correction of hypernasality. It has been our experience that a wide superiorly based flap is the surgical procedure of choice, especially when the palate is scarred.

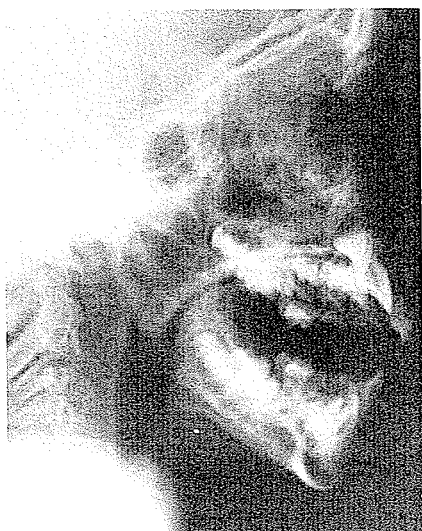Case A



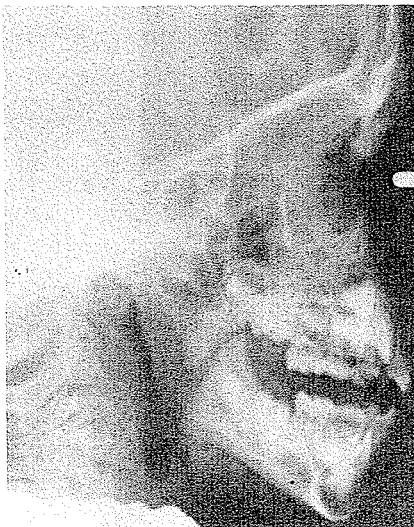Velopharyngeal incompetence seen when vocalizing "Yuuuu. . ."



After surgery; note pharyngeal wall being pulled forward



Incompetent closure on vocalizing "Yuuuu. . ."



After surgery; posterior pharyngeal wall being pulled forward during function

Videofluoroscopy

M. Leon Skolnick of the University of Pittsburgh has achieved a breakthrough with a multiview videofluoroscopic technique. He reminisced in 1977:

According to my medical school classmates, I chose radiology in order to pursue my favorite hobby, photography, so that I could continue to enjoy my love of highlights and shadows. I became involved in radiographic studies of speech shortly after I arrived at the Upstate Medical Center in Syracuse, New York, in November, 1967. The radiology department had been providing lateral cine studies of cleft palate patients but none of the radiologists were interested, so, as the newest member of the department, this task was given to me like a hot potato. I began to attend the weekly conferences of the cleft palate clinic and, as a result, a growing rapport developed. I am indebted to plastic surgeons David Stark and Alfred Falcone and speech pathologist Gerald McCall for their interest and encouragement.

Soon I began to realize the limitations of lateral cine studies. These studies were initially performed without barium and the soft tissue detail was often poor. Specifically, one could not always tell whether closure was occurring or whether a small gap was present. In addition, though the children were speaking, these were silent cines. We had no way of indicating what sounds the patients were producing as the films were taken. While searching for ways of recording sound and roentgen images simultaneously, I happened upon a beautiful and dust-covered 2" Sony video tape recorder, then a microphone, and lo and behold, I could record roentgen images and speech simultaneously on video tape! In addition, since I was able to play back the images immediately, I wheeled the video recorder into the cleft palate clinic to show the physicians the results of studies performed the same



Leon Skolnick

day. What a fantastic effect this had on everyone! Now I too could participate in the clinical evaluation of the patients and present my findings, the fluoroscopic study of the pharynx on video tape. Often lively discussions ensued because the clinicians observed one thing intraorally and I demonstrated something different videofluoroscopically. They began to realize the limitations of their physical examination and place more value on the fluoroscopic study.

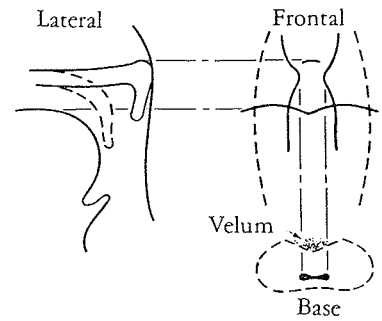
A major source of information that was not provided by the lateral film was information on movement of the lateral pharyngeal walls. The need for this information was stressed by the plastic surgeons. I settled on barium as the best contrast agent because of its acceptance by the patient and excellent coating. Initially, after examining sagittal specimens of cadaver head and neck, I realized that the view that would visualize the palate and pharyngeal walls at one time would be one looking down through the velopharyngeal portal. I first obtained an intact head and sectioned it in a transverse plane just above the hard palate to visualize the plane of the velopharyngeal portal more carefully, and then had to devise the optimal patient positioning for this view. Obviously, one needed a cooperative subject who would tolerate holding a variety of uncomfortable positions so that I could determine which would be most satisfactory—my wife, Irene! By the spring of 1969, the base view was born and soon perfected. One comment about my presentations at national meetings is in order. Except for my first paper presented at the Radiologic Society of North America in December, 1968, all my subsequent presentations were at cleft palate or plastic surgery meetings. Several papers submitted to national radiological meetings were rejected. In the radiological field, I was somewhat of a peculiar fellow.

In 1969 Skolnick used videovelopharyngography in patients with nasal speech with emphasis on *lateral* pharyngeal motion in velopharyngeal closure. In 1970 he used videofluoroscopic examination of the velopharyngeal portal during phonation in lateral and *base* projections. In 1972 he studied velopharyngeal competence and incompetence following pharyngeal flap surgery with videofluoroscopy in multiple projections. Finally, in 1973, with McCall and Barnes in the *Cleft Palate Journal*, he described the various patterns and configurations that the sphincteric mechanism exhibited in a group of 85 non-nasal and nasal subjects without pharyngeal flaps. These patients were studied with his multiview videofluoroscopy (lateral, base and frontal views) after the nasopharynx was coated with barium.

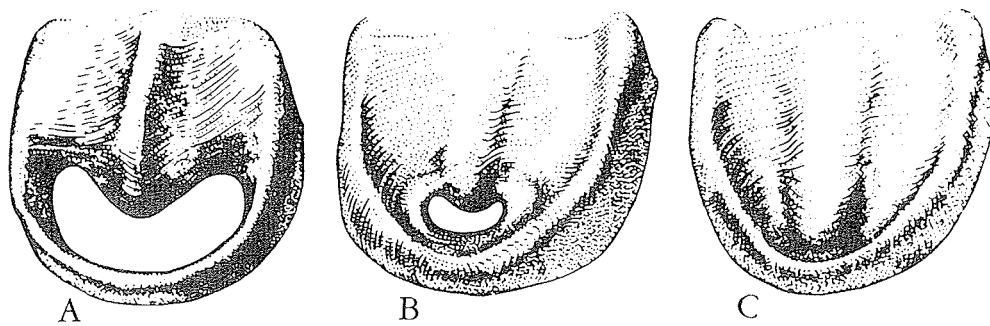
Skolnick presented a schematic view of the normal pharynx showing the sphincteric mechanism of velopharyngeal closure

from the lateral, frontal and base radiographic projections. The dotted lines represent the velum and pharyngeal walls at rest; the heavy solid lines show the same structures during velopharyngeal closure. Skolnick noted:

Observe on the lateral view that the velum elevates and elongates posteriorly during phonation. . . . It should be emphasized that the frontal view is useful because it best demonstrates the vertical extent of the pharyngeal portion of the velopharyngeal sphincter. However, the base view which permits visualization of the portal en face is required to appreciate the total sphincteric concept of velopharyngeal closure.



Skolnick also presented sketches of sphincteric closure of the velopharyngeal portal in a normal subject seen from base view, presenting the portal at rest (A), during partial closure showing a coronal pattern developing as the velum moves posteriorly and the pharyngeal walls contract centrally (B), and at full closure producing a coronally oriented slit (C).

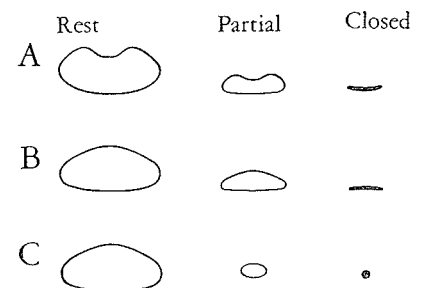


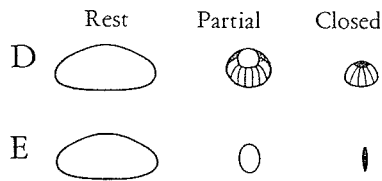
In both non-nasal and nasal subjects, Skolnick found multiple patterns of sphincteric closure. The multiple patterns result from variations in the relative contributions of the velar and pharyngeal movement components to the closure mechanism. His diagrammatic outline of the VP sphincter presents the velopharyngeal portal at rest (on the left), at partial closure (in the middle) and at full closure (on the right).

A portrays a normal subject showing convex projection of the uvula portion of the velum into the velopharyngeal portal at rest.

B presents a postoperative cleft palate showing absence of the uvular muscular bulge at rest, with a coronal pattern of closure similar to the normal.

C shows a postoperative cleft palate with circular closure pattern.





D shows a postoperative cleft palate with circular closure pattern and Passavant's ridge. (Ridge is represented by stippled and lined area in middle and right columns.)

E shows a postoperative cleft palate with sagittal closure pattern.

Skolnick's stinging logic emphasized:

The articulatory and resonance characteristics of a patient's speech are valid indicators only of (1) the presence or absence of velopharyngeal incompetence and (2) the consistency or inconsistency of the incompetence. The speech symptoms provide no information about the precise defects in a patient's velopharyngeal mechanism that is producing his incompetence. We believe it is vital to know these precise defect(s) in a given patient's velopharyngeal closure mechanism prior to undertaking procedures to correct the abnormalities producing the deviant speech, whether by surgery, prosthetic devices or speech therapy. Only by this means can the treatment be adequately tailored to the needs of an individual patient and the results then objectively assessed.

He concluded:

However, it is clear that multi-view video or cinefluorography offers an adequate approach for the examination of the sphincteric mechanism of velopharyngeal closure. It behooves us to begin taking the necessary steps required to incorporate this roentgen procedure into our clinical protocol if at all possible. Therefore, think sphincter!

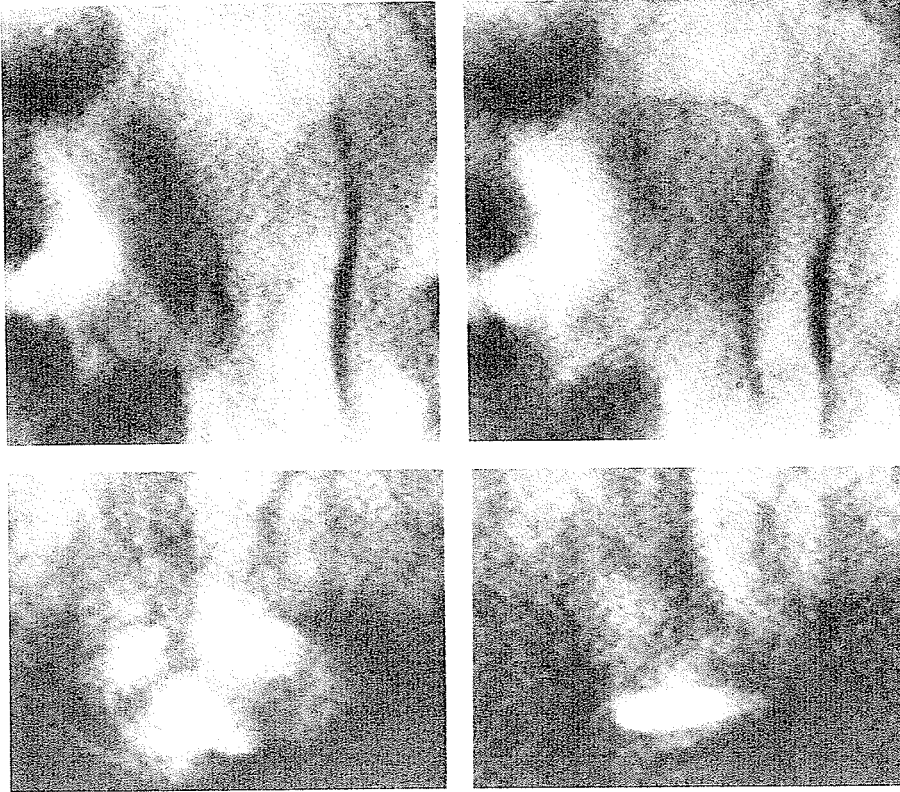
In 1975, with Shprintzen, McCall and Rakoff, Skolnick examined in multiple videofluoroscopic projections 30 postoperative cleft palate patients (2 to 12 years of age) with normal speech to assess velopharyngeal closure in three dimensions. They found:

1. All 30 subjects exhibited contact between the superior border of the velum and the adenoid mass in the nasopharynx. . . .
2. All 30 subjects showed good localized medial movement of the LPW at the appropriate plane of the hard palate.
3. 10 out of 30 subjects, 33%, had a Passavant's Ridge during speech. All 10 of these subjects utilized the ridge as a point of closure, as well as the adenoids.
4. The observed patterns of closure were consistent across varied consonant utterances.
5. The mechanism of velopharyngeal closure in this group of subjects is essentially the same as for normal adult speakers and differs only anatomically due to a lack of head growth in children.

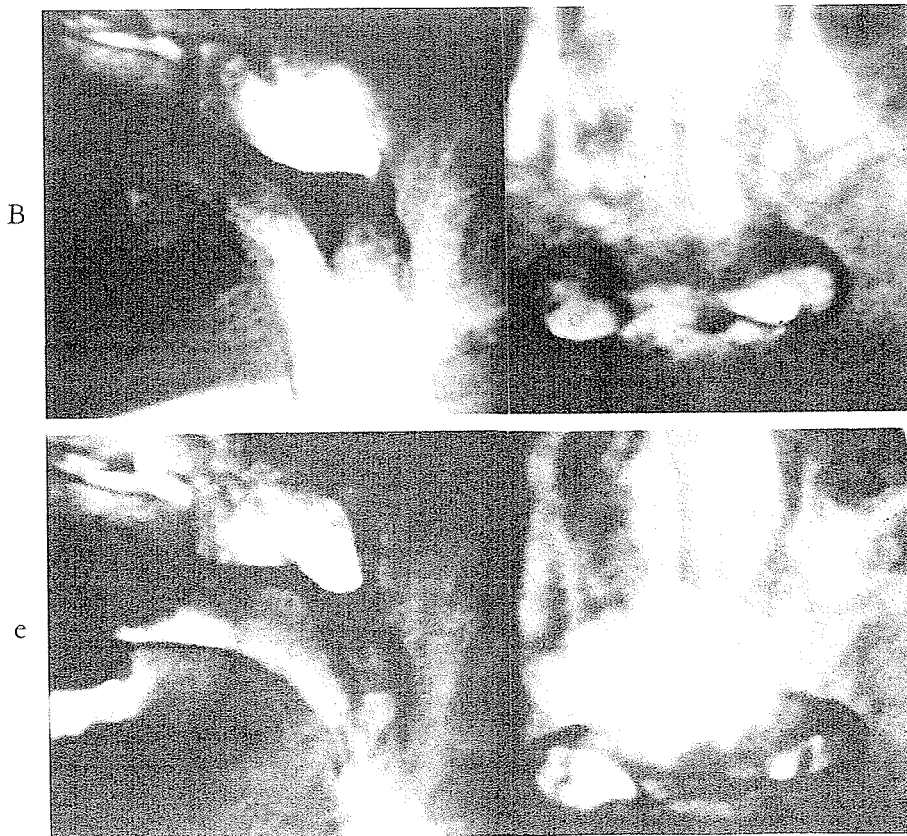
In 1977, upon request, Skolnick forwarded some photographic illustrations of his multiview fluoroscopic studies of cleft palate:

B

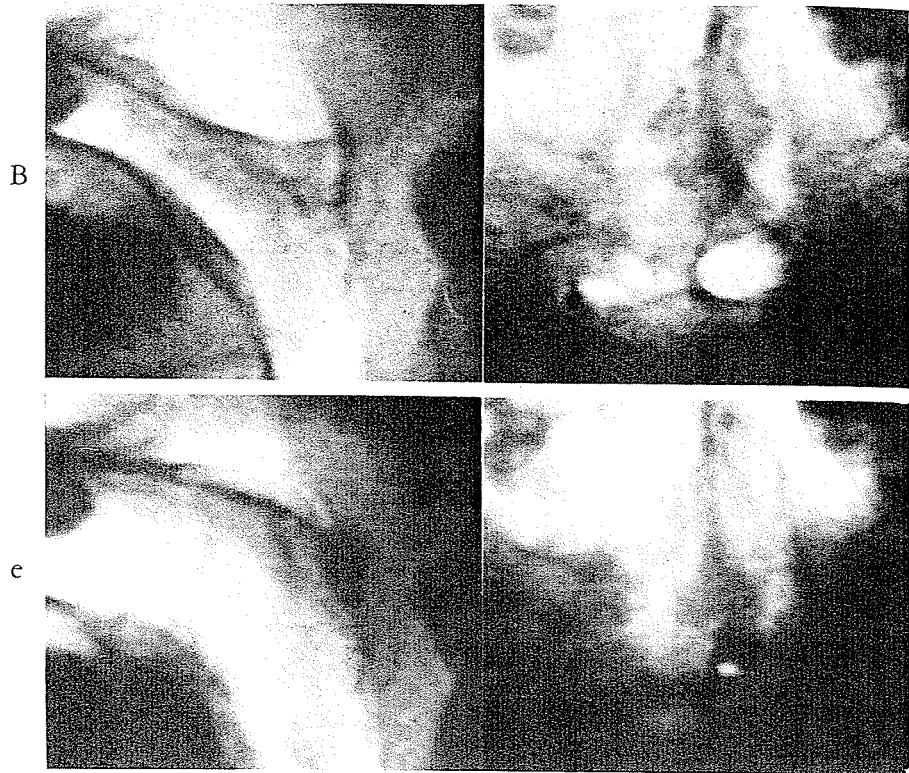
e



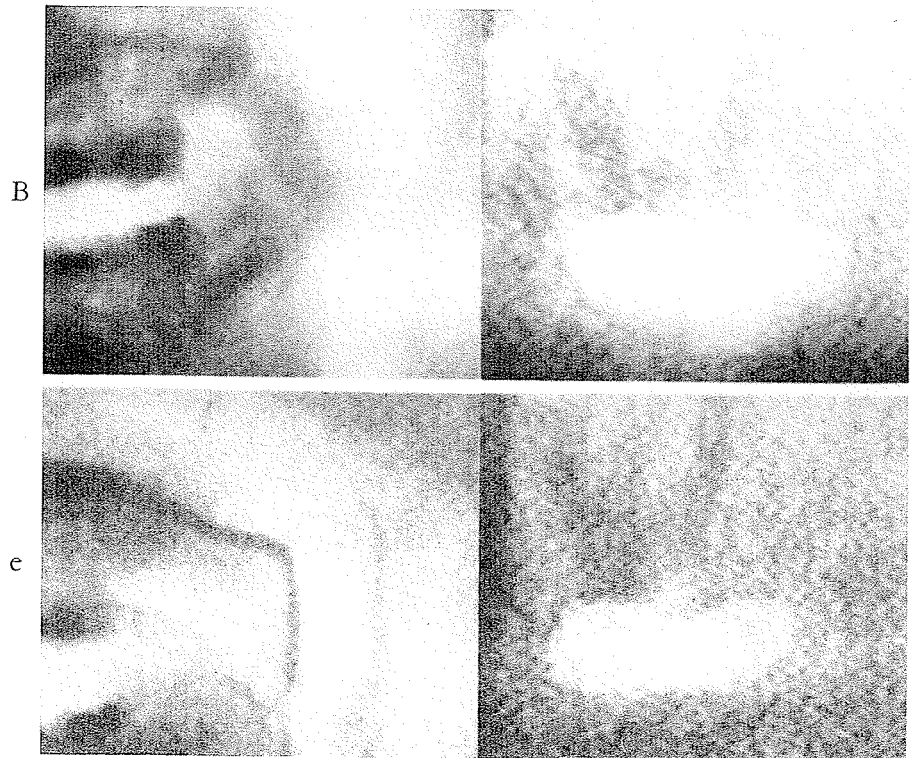
Lateral and base views of repaired cleft palate with coronal type of velopharyngeal insufficiency on base view.



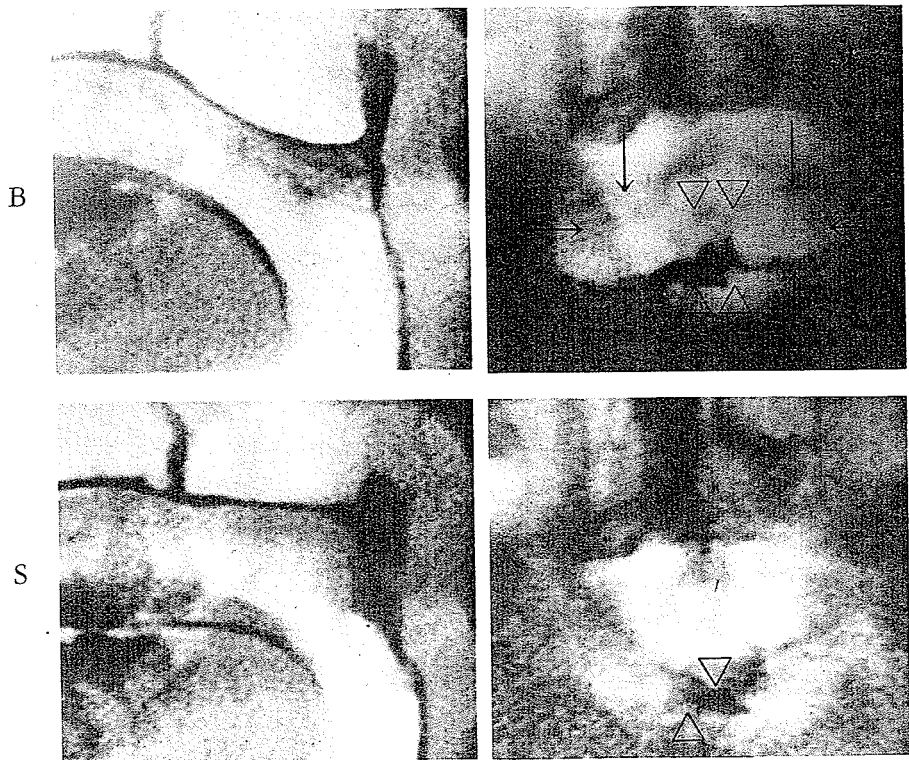
Patient with pharyngeal flap who demonstrates bilateral incompetence after surgery. Lateral and frontal views during quiet breathing (B) and phonation of *e* (e) are presented. Note on the base view that even with phonation, both lateral portals remain open.



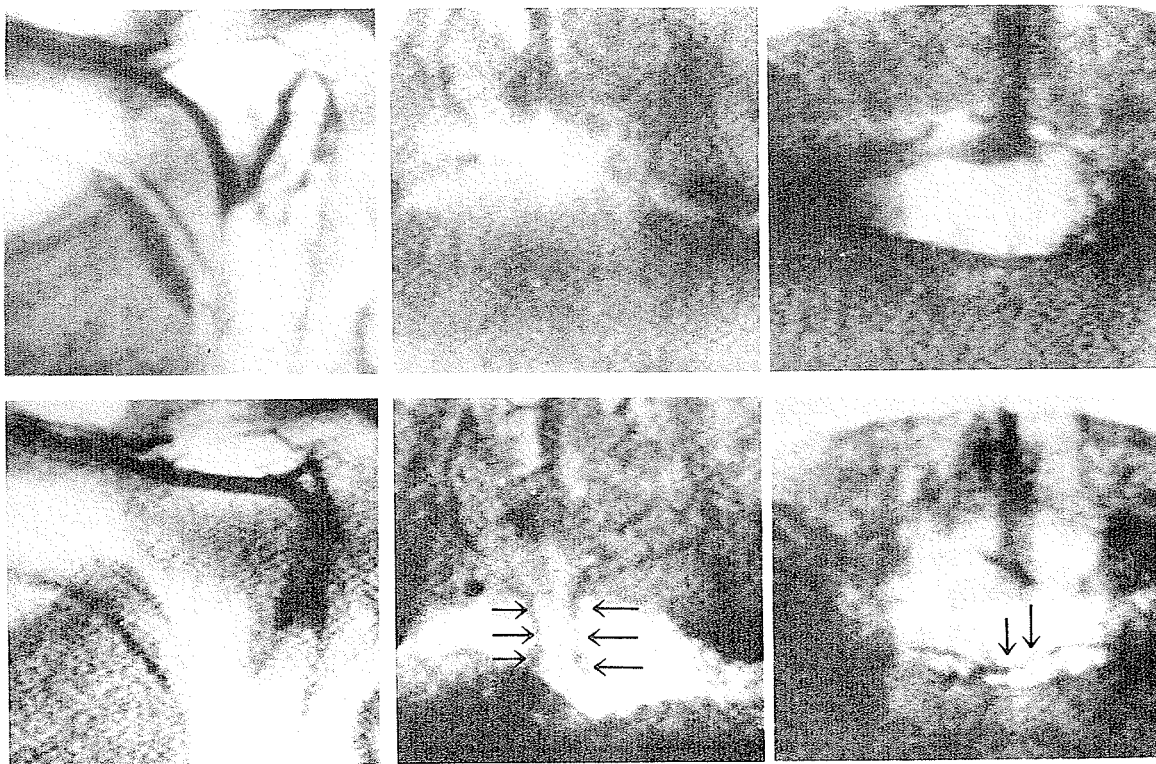
Lateral and base views of patient after pharyngeal flap with unilateral portal incompetence. B represents quiet breathing; e represents phonation of this sound. Note on the base view that the left portal completely closes and the right portal, though reduced in size, still has a small opening through which air escapes.



Lateral and frontal views during breathing (B) and phonation of *e* (e) of a repaired cleft palate in a patient with velopharyngeal incompetence. No pharyngeal flap is present. On base view during phonation, portal decreases in size, but a large coronal defect remains.




Lateral and frontal views of patient with a pharyngeal flap during breathing (B) and phonation (S) who demonstrates satisfactory closure of the portals on either side of the flap. The base view during breathing demonstrates a central narrow flap and bilateral open portals. During phonation the portals close against the edges of the flap. Arrows indicate the open portals during breathing. Arrowhead indicates position of flap during both breathing and phonation.



Lateral, frontal and basal views during breathing (top row) and during phonation (bottom row) of normal subject. During phonation velum elevates and touches posterior pharyngeal wall on lateral projection. On frontal projection localized medial movement of lateral pharyngeal walls is seen in nasopharynx (horizontal arrows). On base view the barium-margined oval seen during quiet breathing centrally contracts to close the velopharyngeal portal in a coronal closure pattern. Arrows indicate the region of the closed portal. Barium lateral to arrows represents barium squeezed above and below the level of the portal during closure.

ENDOSCOPY

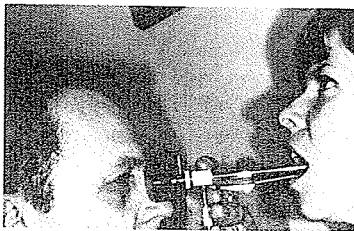
Of course, the best method of studying the function of the velopharyngeal sphincter during speech would be under direct vision. Although this has been possible in rare cases after removal of a portion of face and maxilla during extensive tumor ablation, such action is a bit radical for routine postoperative cleft palate evaluation. The next best view of the sphincter is offered by endoscopy.



Stanley Taub

Oral

According to Pigott, Madame Susanne Borel-Maisonny of Paris published findings of oral endoscopy in cleft palate in 1937. In 1966, in the *Cleft Palate Journal*, Stanley Taub of Brooklyn, New York, a self-taught ventriloquist with a natural interest in the mechanisms of speech, reported that in 1962, as a resident at Kings County Hospital, he had developed the oral panendoscope. This instrument is an integrally illuminated, tubular optical device with a lens system which increases the light transmission from the objective prism to the viewer and camera at the proximal end. A high-intensity incandescent lamp adjacent to the objective lens illuminates the target surfaces at proper levels of light, as required for direct observation, motion picture and still photography. An eyepiece is provided with a glare shield for clinical use and a threaded adapter for camera mounting. A nylon removable tongue depressor functioning as a heat shield is fitted to the instrument. The oral panendoscope is inserted into the oral cavity with the objective lens up and is manipulated for viewing the posterior pharynx and nasopharynx. The muscular activity of the palatopharyngeal sphincter mechanism is clearly observed while the patient recites various combinations of vowel-consonant-vowel sounds. The mouth may be closed with the instrument inside, providing visual observation during phonation. Excited by the visualization of the nasopharynx, Taub exclaimed:



My joy at viewing this area could be compared to looking at the dark side of the moon!

and concluded:

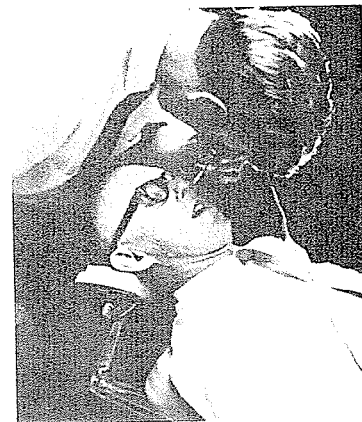The Taub oral panendoscope . . . creates the opportunity for improved diagnosis, treatment and research, by providing a tool and method for simultaneous visual observation and audio-visual recording of the operation of the speech mechanism during the production of speech sounds in normal and abnormal subjects.

Nasal

Ronald W. Pigott, a deft left-handed, imaginative and artistic Irishman who played hockey for Ireland (British Combined Services) and tennis for the University of Dublin, came to the University of Miami in 1967 as a Robert W. Johnson Fellow. He became interested in the direct visualization of the velopharyngeal sphincter. The versatility of fiberoptic instruments opened new possibilities when, finally, the American Cystoscope Company's Infant Urethroscope (overall diameter 3 mm.) was found suitable to pass through the infant's nostril. With University of Miami speech pathologist Jack F. Bensen as an educated subject, Pigott, in 1969 in *Plastic and Reconstructive Surgery*, presented his method of nasendoscopy utilizing 1% cocaine spray. The "patient" lay in a semi-recumbent position in a dental chair equipped with a headrest so that the surgeon could be positioned as in surgery. Speculum exposure allowed the scope to pass gently into position, and mucus was suctioned until



Ronald Pigott



the posterior border of the soft palate and the posterior pharyngeal wall can be seen 1-3 mm before the tip of the instrument contacts the posterior wall.

Bensen went through standard test phonetics on 25 normal subjects ranging from 11 to 45 years of age while Pigott observed the palate and pharyngeal walls and noted the following:

At rest

1. The enormous bulk of the musculus uvulae could be seen. The majority of subjects had a large ridge down the soft palate. . . .
2. The levator sling can be detected. . . .
3. The side of the ridges of the salpingopharyngeus varied enormously.
4. The eustachian orifice could be examined easily. Occasionally, movements inside it could be seen, with opening and closure of the tube. . . .

During Speech Movements

Extremely rapid movements were made. The levator sling could be seen to tighten into a bar, throwing the convexity of the musculus uvulae bulge

up and back to fit into the concavity of the posterior superior pharyngeal wall. In normal rapid speech, almost no lateral or posterior wall movements seemed to occur. Sometimes the levator ridge hardly seemed to contact the pharyngeal wall, but the contracting musculus uvulae flipped the passive free margin of the palate back into contact, where it stuck momentarily to the pharyngeal wall, before dropping away (as the levator relaxed). The lateral gutters (noted in 1880 by Falcson and confirmed from below by Taub) were occasionally seen . . . sometimes leaving a gap apparently 2-3 mm in diameter. . . . These lateral gutters were blocked by medial movement of the salpingopharyngeus in many subjects, though escape of air below the level detectable by ear has been found by Bjork and Nylen and by Warren.

As nasendoscopy allowed unobstructed observation of the nasal surface of the velopharyngeal valve without interruption of speech, Pigott, with Bensen and White in 1969, was able to report interesting findings and treatment suggestions in velopharyngeal incompetence. Asymmetrical velopharyngeal closure suggested a pharyngeal flap on the open side; a pharyngeal flap ineffective on one side called for a second flap on that side; midline gaps suggested pharyngeal flaps; the lack of a salpingopharyngeal fold and poor lateral gutter closure suggested a Hynes pharyngoplasty. One pharyngeal flap, appearing narrow to the surgeon but presenting normal speech to the pathologist under endoscopy, was shown to be broad above, leaving slit-like orifices which closed with mere palate flicking, proving that an adequate flap reduces the velopharyngeal opening to a size controllable by meager palate movements. Light palate contact against large obturator suggested gradual reduction in size of obturator or quicker improvement with a pharyngeal flap; pushbacks with island flaps showed mobility, normal speech and firm closure if the island had blended imperceptibly with the surrounding tissues, but examples of partially extruded islands indicated need for through-and-through sutures between the island and mucoperiosteal flaps during surgery. Inconsistent closure, but with mechanisms for consistent closure present, offered a good case for postponement of surgery. Pigott also noted the high percentage of almost completely atrophic musculus uvulae in these patients, coinciding with Broomhead's finding that the lesser palatine nerve serving this muscle is routinely cut in pushback operations

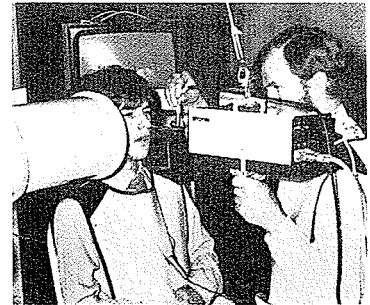
when the aponeurosis is freed from the edge of the hard palate. This emphasized the importance of trying to preserve these nerves during the dissection.

At Frenchay Hospital, Bristol, Ron Pigott continued to develop his nasendoscopy, properly renamed "nasal pharyngoscopy" by Huffstadt of Gröningen. He was joined by A. P. W. Makepeace of the Audio-Visual Aids Unit, University of Bristol, whom Pigott describes as

an audiovisual eccentric, a scientific magpie who knows more sciences and medicine than one would believe possible without a degree. He devised the split screen videotape recording.

In 1975, in the *British Journal of Plastic Surgery*, Pigott and Makepeace described their technique of recording nasal pharyngoscopy to aid memory and improve clinical care and research. Improvement in topical anesthesia was achieved by an intravenous cannula with a wisp of cotton wool held on to the tip with Micropore tape and saturated with 4% lignocaine. Most children over 8 years old were found to cooperate. The Storz-Hopkins nasopharyngoscope was introduced somewhat as previously described.


In recording sessions the endoscope coupling is fixed to the endoscope eyepiece before the procedure starts and the Lavalier microphone suspended by a cord round the patient's neck. . . . The television camera, suspended in a simple gimbal and coupled to the suspension shackle by a snap hook is advanced so that the magnetic coupling can find its automatic location on the eyepiece. . . . With a minimal movement of the head the examiner can watch the monitor while a videotape recording is made, in this case simultaneously with the lateral pharyngeal X-ray.



Pigott tests forced closure on *pah-pah-pah*, *tab-tab-tab*, *sab-sab-sab*, and then asks the patient to count up to 20 quickly. He notes:

Where closure is achieved on the isolated tests, it may be deduced that the potential of speech education exists. Failure of closure will be seen on rapid counting especially in the second 10 when muscle fatigue and loss of concentration often expose weakness. Total, central, bilateral or unilateral defects may be noted. Movement may be present in all walls, any or none, and the operative plan should take account of this.

In the 1975 *British Journal of Plastic Surgery*, B. C. Sommerlad, E. J. Hackett and J. Watson of the London Hospital and St. Andrew's Hospital, Essex, presented a simplified method of recording. They noted:



The endoscope about to be introduced is connected by the fibre-optic teaching aid to the special lens on the camera (on stand) and by a twin fibre-optic light cable to the light source (on the left of the picture). The videotape recorder with its small attached screen is beside the light source.

They concluded:

In view of Pigott's work, it would appear that a pharyngoplasty without prior pharyngoscopy is similar to an operation on the bladder without cystoscopy. Now that a simple method of recording . . . is available, we hope nasal pharyngoscopy will become a routine examination in patients with speech defects.


In 1977 Pigott acknowledged:

Recording is now facilitated using fibre-optic teaching attachment between television camera and endoscope as suggested by Sommerlad and Hackett. This has been a big step forward and means that any patient who can be endoscoped can be recorded. . . . Failure to endoscope patients over twelve years of age is negligible. Between eight and twelve, success rate is about nine out of ten, and between three and eight years, about three out of four. The youngest children who find cooperation for endoscopy most difficult do well with basal x-ray assessment. Yet not all patients have flexible enough necks to achieve correct position for basal studies and these are the older patients easier to scope. Mucus coated with barium creates serious artefacts occasionally which leads to the wrong diagnosis. Whenever possible, both endoscopy *and* x-ray should be used.

At the 1975 International Congress in Paris, I challenged Pigott to get me action photographic records of various methods with his nasopharyngoscope. At the 1977 International Cleft Palate Congress in Toronto, where he was giving a seminar on nasopharyngoscopy, he presented me with the coveted photographs which are displayed with captions in the margin. Pigott summarized his 10-year experience:

Some specific observations are:

Flaps don't always stay the size they are cut and their base migrates. Orifices don't always stay the size they are left. So, accurate planning is

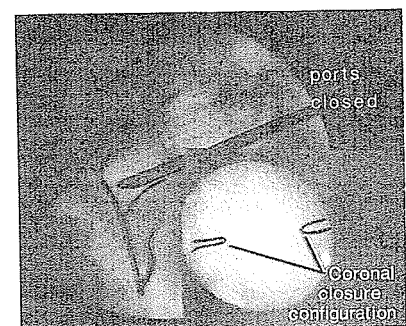
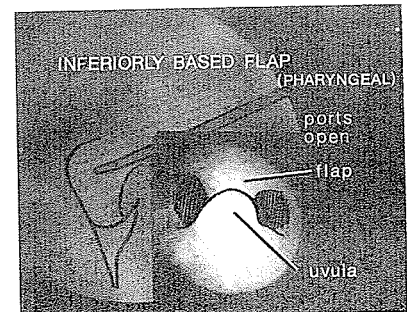
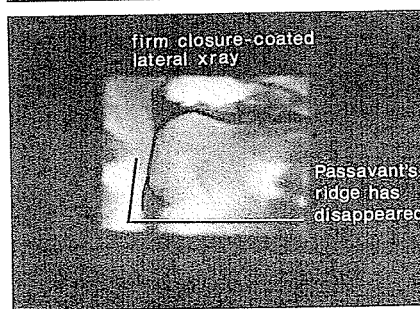
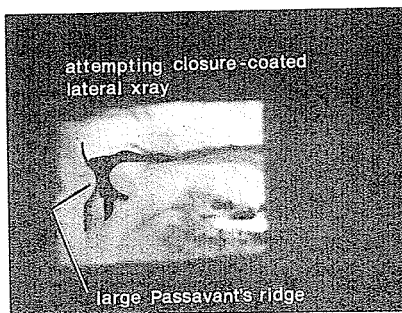
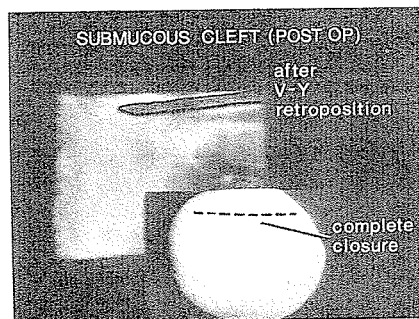
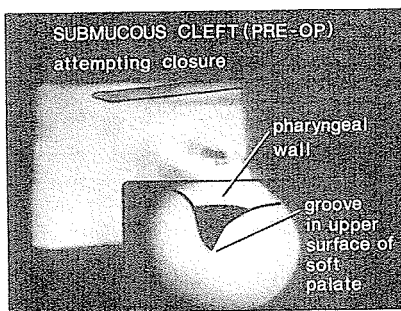




wishful thinking in many cases. Successful flap cases leave relaxed ports far smaller than the normal isthmus so nasal resonance is adversely affected. No successful pharyngeal wall implant case has yet been recorded by me for a defect greater than 0.5 cm.². By success, I mean that there is *no* nasal escape. I do not accept "improvement" as "success" because of the difficulty in grading, whereas it is relatively easy to say there is, or is not, nasal escape.

It is not true that audible nasal escape ceases below a port size of 20 mms.². Passavant's ridge is a stress phenomenon which disappears with adequate palatal lengthening. I suspect but cannot prove that the lateral wall movement of so-called normal speakers is also a stress phenomenon in compensation for minor degrees of pharyngeal disproportion.

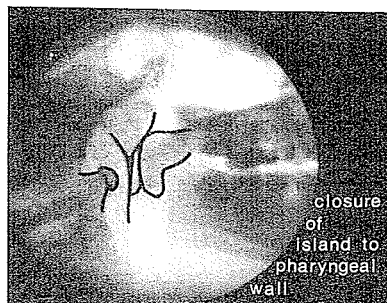
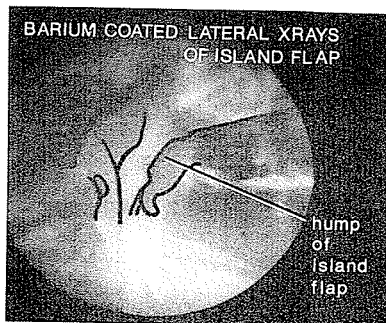
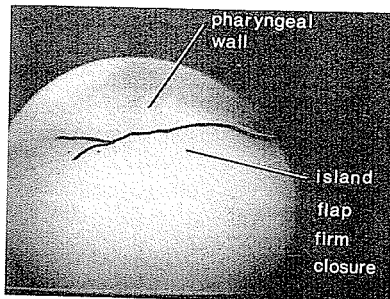
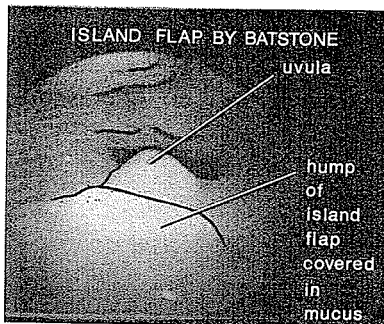
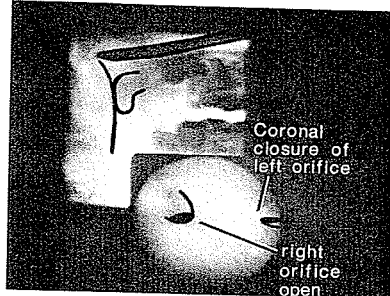
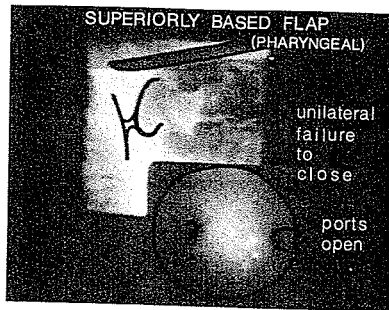
Pharyngeal disproportion exists at the same time as cleft palate. So highly competent surgeons doing excellent standard repairs will find to their chagrin that the palate, though mobile, is incompetent, just as isolated pharyngeal disproportion palates are incompetent.

Why not do primary pharyngoplasties? Well, they have their disadvantages. Reduced nasal resonance, catarrh. They don't always "work." They increase the operative time and anyway, most experienced surgeons achieve 80% +/- 10% palatal competence without. What we need is to recognize pharyngeal disproportion. So far as I know we still cannot be sure which is which.



What benefit have I had from ten years of fairly intensive experience in this field?

1. *Speech Assessment:* I see what I hear. The visual feedback finds me in a strong position to know what nasal escape sounds like. That is to say, if the



isthmus is firmly shut, what I'm hearing is NOT palatal incompetence and I can state that more objectively than the speech therapist and back the statement with a video tape. It is not infrequent for articulatory faults of cleft palate speakers, such as glottal stops and velar fricatives, to be thought synonymous with palatal incompetence. This is unfortunate because it leads to disappointment that a given pharyngoplasty does not "cure" articulatory fault habits. At best it merely paves the way. Surgeons, trainees, parents, patients (and even an occasional speech therapist) do not always understand this. So people continue to report "speech" and intelligibility improvements as the result of pharyngoplasty, not palatal competence—surely muddled thinking. Or, it may be a failure to realise that this is a simple valve which is open or shut; air does or doesn't go up the nose at the wrong time, and is or is not audible.

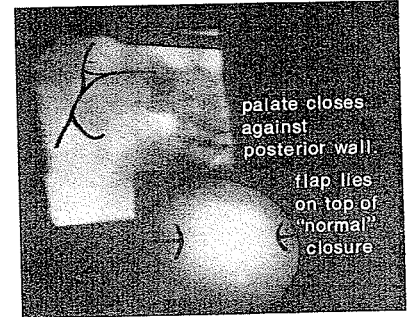
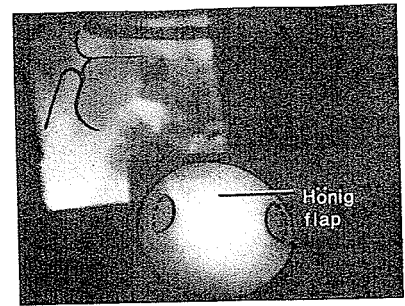
2. "Best Buy" Pharyngoplasty: In my experience the majority of defects are reasonably symmetrical. About five out of six have enough lateral wall movements for closure of the lateral ports against a good pharyngeal flap. About five out of six, not necessarily the same ones, have enough soft palate lift to close if the palate and pharyngeal wall are brought near enough to each other. About two-thirds have a closure defect of the central third of the relaxed orifice and of these, about a quarter have only a gully in the midline, equivalent to atrophy of the musculus uvulae (which is never well developed in the cleft palate patient). Of the remainder, about a sixth have a defect of two-thirds of the relaxed orifice and about a sixth have a total lack of lateral wall adduction. Of these it has occasionally been noted that midline contact is achieved, but lateral gutters remain patent. The ideal technique should therefore be most effective in ensuring midline closure. Lateral flap techniques such as Hynes, Orticochea and Moore are least effective in blocking the midline defect. Implants are not very reliable so far in the deeper failure to close, but may be effective for small depth defects.

I have no experience of the Dorrance or Cronin palate lengthening procedures. The so-called Veau-Wardill-Kilner procedure was shown by Calnan to be successful in lengthening the palate to only a minor degree. Many cases will already have had this done. I am very doubtful if repeating it gives further length. Millard's island flap, brilliant in concept, is oddly disappointing in practice. A thick plug of mucus persists on its upper surface causing chronic catarrh. It seems to make the palate too thick and reduces mobility, and it is possible that peripheral scar contracture is responsible. However, it too can be successful in correcting incompetence and can be invaluable where pharyngeal wall has already been used without success.

Pharyngeal flaps have the potential for success in about five out of six cases (in which lateral wall movement is adequate, excluding technical faults). Those attached to the trailing border (inferiorly based) or to levator


eminence (standard superiorly based) tend to reduce the amplitude of the elevation. They simply obturate the central area while the lateral walls adduct against them.

The combination lengthening operation with pharyngeal flap inserted into the nasal layer near the back of the hard palate and well forward of the levator sling does not seem to reduce the palate lift: in fact it sometimes increases it and the pharyngeal flap pedicle may then be seen to be redundant on endoscopic examination. Examples of this technique are the Hömig modification of the superiorly based flap and the Millard T flap, and if one did not have adequate facilities for pre-operative assessment, it is my present feeling that this operation more than repays the extra time of retroposing of the palate. The lateral wings of the Millard T allow essential lengthening up to the pterygoid plates.




G R A B B

William Grabb, trained by Dingman at the University of Michigan and following him as chief of the unit, is not only a fine surgeon but an exceptional organizer and a prolific writer. His training and experience in cleft surgery have rendered him both knowledgeable and discerning. His 1971 book, *Cleft Lip and Palate*, with Rosenstein and Bzoch, is the best and most complete work on the subject and has been the source of much material used or referred to in *Cleft Craft*. Grabb is completely sound, with his feet firmly planted on the ground—except, that is, when he is relaxing.



William Grabb

Dr. Grabb's bag is *Yankee Doodle*, his red, white and blue hot-air balloon with a unique swing seat which looks like a wheel-less wheelchair. He has served as president of the Balloon Federation of America and has been in the air more than 150 times, flying low enough above the trees to pick leaves, and flying well enough to capture third in the 1968 Indianapolis Speedway Balloon Race, third in the Columbus International Balloon Race in 1969, second in the 1970 U.S. National Championships and first at Columbus in 1970. He once flew badly enough to land in a patch of poison sumac. When asked if he wrote his books while in the air, he admitted:



No, once up, I spend most of my time figuring how to get back down!

In 1971 Grabb summarized the speech results reported in the literature during a 21-year period (1948-1968). The overall average speech of this group of 3,743 children who had operative closure of the palate cleft was normal in 71 percent of cases. Grabb also noted a definite trend of a higher rate of normal speech results in recent years, regardless of which operation was performed or who performed it.

In 1977 Grabb wrote about his University of Michigan cleft palate study designed to determine, in as objective a way as possible, which cleft palate operation or operations gave the best results. He outlined the research plan:

Beginning on January 1, 1971, some 90 children with cleft palate had the palatal cleft surgically closed by either: 1) staphylorrhaphy, 2) staphylorrhaphy and pharyngeal flap, 3) von Langenbeck palatorrhaphy, or 4) push-back palatorrhaphy with Cronin nasal mucosal flaps. The operation performed was determined in a random manner by drawing a slip of paper from an envelope. The operative technique has been carried out by a variety of staff and resident plastic surgeons following the explicit written directions and drawings in the Cleft Palate Study Syllabus.

The children with cleft palate in this study have had appropriate base line photographs, cephalograms, dental casts, and examinations recorded on the worksheet by the ear, nose, and throat physician and a plastic surgeon. These studies were repeated before each operation and will be repeated at ages 5, 10, and 15 years.

The 90 children in this study are divided into subgroups as to incomplete cleft palate, complete unilateral cleft palate, and complete bilateral cleft palate.

At the present time, the children reaching five years of age are being evaluated in regard to their speech, facial growth, and hearing. It is anticipated that at some time in the mid or late 1980's, preliminary results from this study will be reported. We do not have a computer system that will run off this data but rather it is stored in the form of dental casts, cephalograms, and worksheets in one central location. I hope the room does not catch fire.



David Dickson

DICKSON

David Ross Dickson, speech pathologist at the University of Miami School of Medicine and director at the Mailman Center for Child Development, has the ability to simplify speech nomenclature for the surgeon. He explained to us at one of our residents' conferences in 1978:

Vowels are formed by modifying the laryngeal sound in the pharynx and mouth. Low vowels may not reveal mild velopharyngeal insufficiency but high vowels will. Plosives such as *t* and *d* are created by stop and release with little pressure. Fricatives *s*, *z*, *sh*, *ch*, are high pressure sounds formed by back pressure forced through a restricted area causing friction and heavy impedance. When there is a constant leak, not enough pressure can be generated to produce fricatives successfully.

Dickson brings all aspects of investigation and intervention into reasonable perspective:

It seems amazing, after all these years of research, how hard it is to sort out what we know from what we do not, and what is relevant from what is not. Also, it is most interesting how much information in this area has been contributed by professionals outside the field of speech. To me, this demonstrates that cleft palate assessment and treatment is truly interdisciplinary and not just multidisciplinary, since our best information has come from professionals from a number of disciplines working together and sharing ideas and constructive criticism. It is also clear that each professional must be interdisciplinary in understanding of the problems we confront to be effective. Certainly Pigott is right that "even" speech pathologists can confuse speech attributes which are not related to velopharyngeal competence with those that are. One can be an exceptionally good speech pathologist and not understand cleft palate assessment, just as one can be an exceptionally good surgeon and not understand the problems of cleft repair.

A number of things have been brought out which I feel deserve emphasis. It should be too obvious to state at this time in our history that cleft palate is not a normal palate with a hole in it. There are physiological differences due at least in part to muscular deformities. As pointed out by Pigott, one of the most important (and most neglected) of these may be the lack of a functioning uvulus muscle. Also, there are extra-palatal morphological differences including the pharyngeal disproportion noted by Pigott and others. Work in our laboratory has demonstrated that at least in the mid-term fetus, pharyngeal and cranial base disproportions are significant in cleft palate.

The principal goals of assessment are first, to determine whether speech is adequate or inadequate; second, if speech is inadequate, whether the problem is related to velopharyngeal incompetence; and third, whether surgical intervention will be necessary. As to the first question ("Is speech adequate or inadequate?"), to date, our best instrument is a trained ear. A trained ear is one which is hooked on to an informed, experienced person capable of common sense and logical deduction. A trained ear is necessary, in part, to avoid confusion among hypernasality, hyponasality, and speech problems not causally related to current velopharyngeal dysfunction. The second

In our weekly
Miami CP clinic
D. Dickson and the
residents do routine
nasopharyngoscopies
for diagnosis and
the planning of
specific surgery.

right

yes!

Surgeons and
Speech Therapists
please note!

question had to do with whether an existing speech problem is related to velopharyngeal dysfunction. The assessment of velopharyngeal adequacy involves two factors: the movement patterns of the velum and pharynx, and the degree of velopharyngeal closure. The latter has been approached by Warren. Evaluation of velopharyngeal patterns of activity has been attempted by a wide variety of radiological procedures, by nasendoscopy, and by ultrasound. Use of ultrasound has not been fruitful. Nasendoscopy is difficult in young children and is often difficult to interpret due to the lost third dimension of vertical space. Radiological procedures, especially combined lateral and basal videofluoroscopy developed by Skolnick, though also difficult with very young children, seems to be the method of choice currently. However, even this procedure should be used selectively, not in grossly incompetent cases but rather in cases of marginal velopharyngeal adequacy. The bottom line in assessment is that you use the tools at your disposal efficiently. This means that if a patient walks in with a palate that is obviously extremely short and inactive and his speech is extremely hypernasal, it is not going to take a lot of fancy gadgetry to determine that he has an inadequate velopharyngeal mechanism. It's the borderline cases that necessitate more involved evaluative procedures.

The third question was "Will speech therapy normalize speech or is surgical intervention necessary?" If velopharyngeal closure can be produced without excessive effort on occasional speech attempts, the patient is a good candidate for speech therapy, since there is at least a reasonable probability that the velopharyngeal problem is not due to structural or neurological inadequacy. If the patient does not achieve velopharyngeal closure on any speech attempt, it is unlikely that speech therapy is going to result in his being able to do so. Also, if the patient can just barely make velopharyngeal closure with maximal or concentrated effort, he will probably not be able to achieve closure with connected speech. Imagine yourself trying to use a typewriter with weights attached to your fingers. Imagine that those weights are so heavy that with all the strength you can muster, you can just barely move your fingers from one key to another. Now try high-speed typing (without any errors, of course). Another way of putting it is that you can't expect a person who can lift a 500-pound weight to use it in his juggling act. Speech therapy may help the person who can't get his act together but it won't make up for a short or inactive mechanism.