

## 55. Maxillary Surgery

MODERN maxillary surgery has become an important part of secondary rehabilitation of the cleft lip and palate deformity, and it all began when a brilliant and curious Frenchman started hammering on cadaver skulls to see where they fractured.

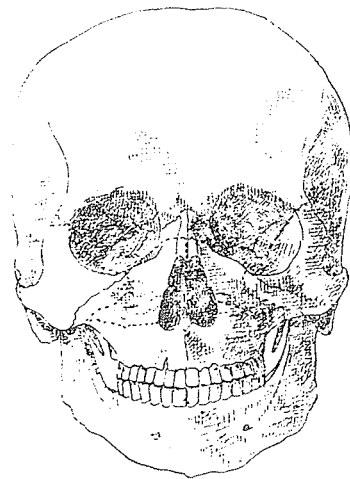
René Le Fort of the University of Lille, France, served for years as a military surgeon at Val de Grâce Hospital in Paris. In 1901 he published the results of his cadaver experiments, which followed the principles of the scientific method laid down 50 years before by Claude Bernard. His work involved positioning cadaver heads, striking them with a piano leg, and then, by dissection, discovering the extent and type of the maxillary fracture. Here are some of his notes, as translated by Tessier:

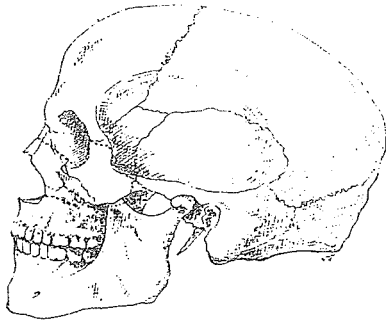
The upper jaw, despite its multiple connections to the base of the skull, enjoys a considerable independence from it. . . . A great number of weak points (or better said, *lineae minoris resistentiae*) cause the facial bones to break into fragments so that the stress is exhausted by the effect produced, preserving the integrity of the bony envelope of the brain.

His *first great weak line*, or Le Fort III fracture, passed through the nasal bones, cribriform plate, upper part of the frontal process of the maxilla, upper part of the lacrimal bone, medial walls of the orbit, into the intraorbital fissures, across the orbital floors into the sphenoid and even frontal bones, and down across the base of the pterygoid processes. His *second great weak line*, or Le Fort II fracture, crossed the lower part of the nasal bones, frontal processes of the maxilla, lacrimal bones at the nasolacrimal canals, infraorbital rims at the junction of the malar bone and the maxilla, through the infraorbital foramen, around the malar bone




René Le Fort





respecting it, across the upper nasal septum, into the pterygomaxillary fissures, and across the base of the pterygoid processes. The *third weak line*, or Le Fort I or Guérin's fracture (1866), started from the lower part of the pyriform aperture, crossed the canine fossa below the malar bones, rising posteriorly to cross the pterygomaxillary fissure, and cut the pterygoid process. He acknowledged:

This third line is the one involved in Guerin's fracture, one of the most frequent forms of upper jaw fracture.



*Martin Wassmund*

### USE OF LE FORT I IN TREATMENT

Martin Wassmund of the Rudolf Virchow Hospital, Berlin, was the first to create a Le Fort I fracture for treatment purposes. Wassmund, the son of a preacher and a fiery, temperamental surgeon with degrees in dentistry and medicine, would go into battle at the drop of a glove to defend his methods. During World War II he was a chief of the Military Hospital for Maxillo-Facial Surgery, and over the years he carried out a phenomenal amount of maxillary, mandibular and palatal surgery. His favorite adversary was Axhausen. As early as 1927, he was the first to perform an osteotomy and repositioning of the entire maxilla in a case of anterior open bite. His osteotomy was performed along the lines of a Le Fort I fracture, extending completely across the maxilla and including the pterygoid plates of the sphenoid.

In 1934 Axhausen used elastic traction postoperatively to pull the maxilla forward into the desired position. In 1942 Karl Schuchardt was the first to suggest sectioning of the maxilla in the pterygomaxillary groove, thereby leaving the pterygoid plates intact.

### FORWARD MOVEMENT OF THE MAXILLA THROUGH LE FORT I OSTEOTOMY


In 1952, Gillies and I wrote of Gillies' planned Le Fort I osteotomy:

When a mandible has been retroposed following osteotomy, the pouting lower lip can be nicely tucked in behind the upper. Yet the harelip-cleft palate deformity is merely a relative prognathism of the lower jaw because of a *true agensis* of the upper. For this reason protrusion of the maxilla by osteotomy would seem a more direct approach. Confidence in this technique has been developed through familiarity in dealing with floating fractured maxillae. . . .

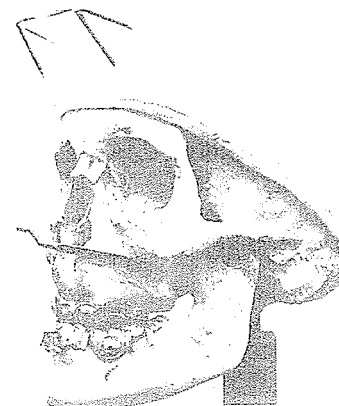It is now freely admitted that the stresses laid on the maxillary arch by the early surgery of palate and lip lead to gross maldevelopment and agensis of the maxilla and its teeth. We here follow the principle of "replacing normal into normal position," and in the maxilla, therefore, we very much favour the bold osteotomy of the tooth-bearing segment. The fragments can now be held in predesigned positions to give maximal function and appearance.

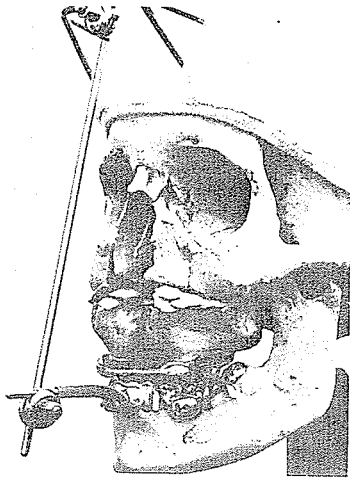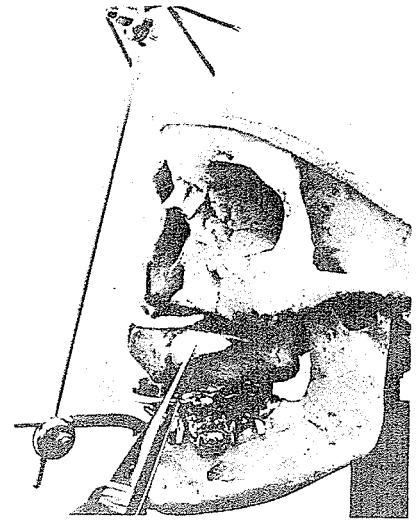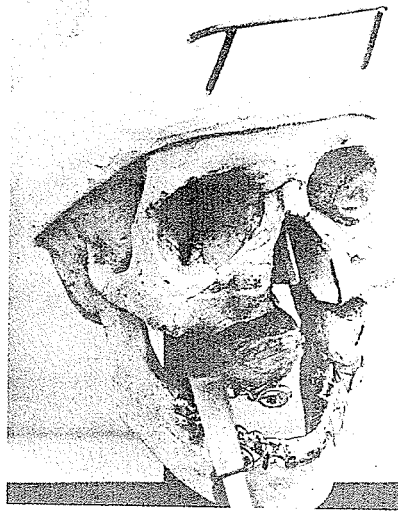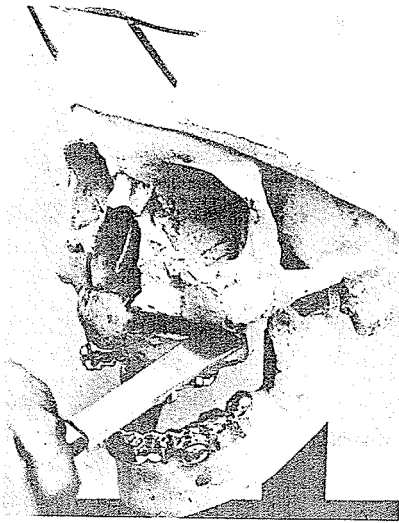The example case was Joyce, who had had nine operations for a bilateral cleft lip and palate, including three attempts at palate closure. The maxilla was contracted and the cleft still present, with the soft tissue remnants so tiny that even a Gillies-Fry procedure was not planned. An upper buccal inlay and nasal correction improved the lip and nose moderately, and the patient was able to speak more or less intelligibly with the aid of a huge obturator. Being a girl of great determination, Joyce was dissatisfied and eager to have maximum treatment. The plan was to correct the distorted maxilla and replace her obturator with a tube pedicle. The Rooksdown House chief of oral surgery, dynamic Norman Rowe, made dental models and the necessary splints and planned the fixation. Then, with his co-author H. C. Killey, Rowe made demonstration models which Gillies and I used in *The Principles and Art of Plastic Surgery* to show osteotomy and bone grafting of the deficient cleft palate maxilla. This was our description:

The upper buccal sulcus is incised, the mucoperiosteum reflected and nasal saw cuts are made in the maxilla on a line above the apices of the teeth. It is not always possible to avoid opening into the antrum, but when this occurs it does no harm. Remember that the principal blood supply of each maxilla following osteotomy is derived from the greater palatine artery, and preservation of this artery is essential. Therefore no attempt is made to divide the tuberosity with the saw. The final sectioning is achieved by inserting the chisel into the distal end of the saw cut, and after a few cautious taps the maxilla is levered downwards and outwards until the



Norman Rowe





*Wolfe notes  
That Gillies  
sectioned the  
pterygoid plates  
and so could  
not put bone  
grafts in the  
interpterygo-  
Maxillary space  
(IPM) as now  
preferred*

remaining bony attachment of the tuberosity is fractured in a greenstick manner. It may also be necessary to pry open the original hard palate cleft before the segment is free enough to go into satisfactory occlusion with the corresponding lower teeth. The gum may go blue but the circulation has been found quite adequate. The casual hospital onlooker is often impressed by the fact that the patient suddenly takes on a more normal contour. The two maxillae are now fixed by plates and bar in the position they might have taken had their development been normal.

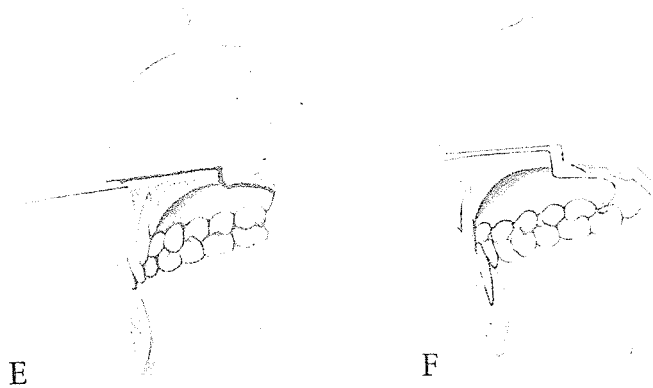
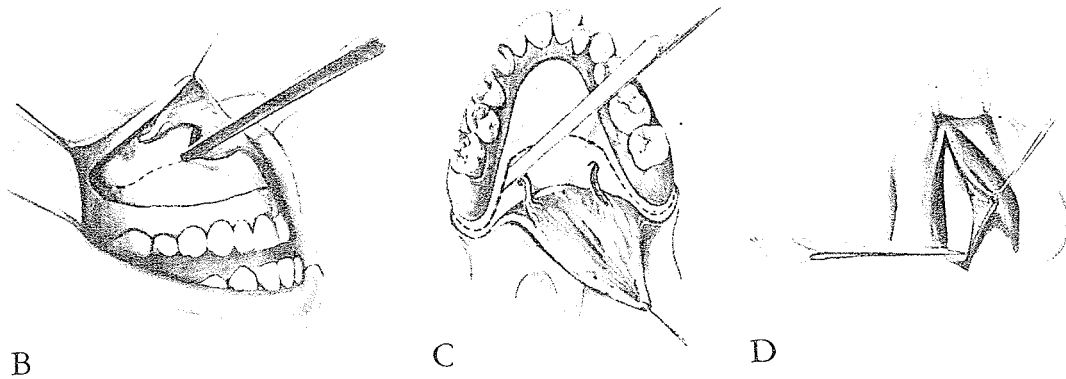
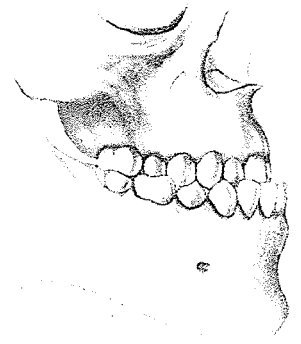
Care must be taken to relate the occlusion to the mandible and to the cranial base. Cancellous chips from the ilium are packed into the hinge, but a strong one tapped into the apex of the bone cut serves as the main wedge to keep the new position. Others are added to consolidate. . . .

Initially it was feared that the bone graft, being exposed to the nasal cavity or possibly the antrum, might become infected. Experience has shown that this is not the case, for to date no graft has failed to achieve bony union. The integrity of the graft is probably preserved by the excellent blood supply, which is derived from the adjacent bone and muco-periosteal covering—the mucosal closure should be meticulously performed.

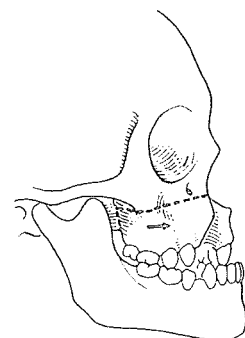
The sparks of Gillies' original work in osteotomies of old facial fractures and forward positioning of the maxilla in cleft cases, as well as his osteotomy design for correction of the oxycephaly of Crouzon's disease, kindled Tessier's interest in the new field of craniofacial surgery. Indeed, Tessier made many visits across the Channel to observe the work of Sir Harold Gillies.

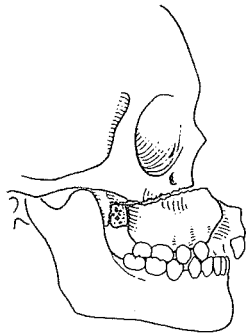
It is now well recognized that the forward movement of the maxilla is much more frequently indicated to correct the prognathic appearance in cleft patients than retropositioning of the mandible. Gillies spearheaded the early work in this shift in clefts, as already described.

John Converse has been interested in forward advancement of the maxilla. In 1952 in *Plastic and Reconstructive Surgery* J. M. Converse and H. Shapiro described advancement of the maldeveloped maxilla with malocclusion (A). Their line of osteotomies extended from the pyriform aperture to the maxillary tuberosity on each side (B), crossing the hard palate (C), through the septum at the level of the nasal floor (D). Advancement of the maxilla reestablished dental occlusion (E, F). The illustrations by Stilwell were explicit.

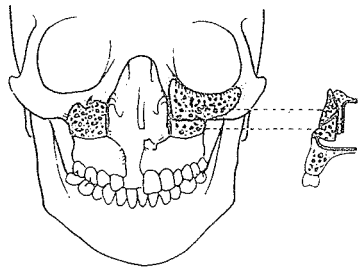


By 1971, Obwegeser and his co-workers had carried out the Le Fort I osteotomy in over 100 cases, and it had become routine. Here are the steps in his approach: (1) vestibular mucoperiosteal incision from one infrazygomatic crest to the other; (2) osteotomy of anterior wall of the maxilla and lateral wall of the nose, and separation of the nasal septum from the hard palate; (3) mucoperiosteum on the palate not elevated, transverse bone cut on the palate (Converse, 1952; Köle, 1965), and cutting the pterygoid plate avoided; (4) separation achieved with a heavy osteotome at the pterygomaxillary fissure; (5) tilting of maxilla forward with fingertip, fracturing the posterior part of the lateral wall of the nose and the posterior wall of the maxillary sinus; (6)





B



C

forward movement of maxilla facilitated by incision of soft tissue scarring.


Intermaxillary fixation with skeletal suspension, either circumzygomatic or percutaneous by wire to headcap or to pins in the frontal bone, is used, but direct wiring between osteotomy lines has been satisfactory in some cases.

In 1969 Obwegeser stressed the importance of placing bone blocks in the interpterygomaxillary space (IPM), wedged between the buttress of an intact pterygoid plate and the tuberosity to maintain the advanced position of the maxilla. In 1971 he readvocated insertion of this bone block, noting:


Failure to do so permits the scar tissue to contract and pull the maxilla backward.

He also recommended the insertion of bone where there is insufficient bony contact along the path of the anterior maxillary osteotomy. In spite of exposure these medullary bone grafts survive, as noted by Gillies and others. To correct any flatness in the areas of the infraorbital rims, subperiosteal bone onlays are inserted.


Here is a unilateral cleft case with retromaxillism and a humped nose that was corrected by Obwegeser, as shown in preceding diagrams (A, B and C) and partially presented in *Cleft Lip and Palate* with his technique of advancement in two sections. Models show preoperative occlusion and model operation for accurate planning (D).



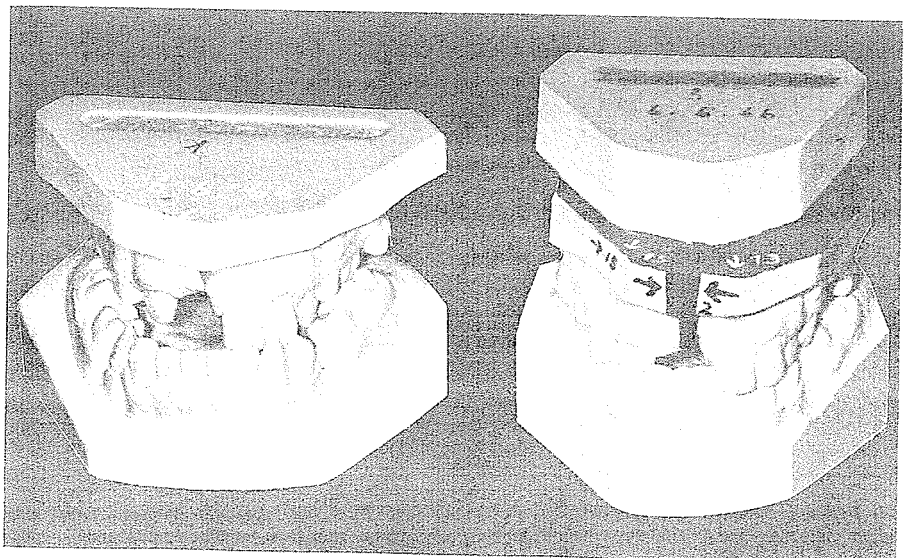
E



F



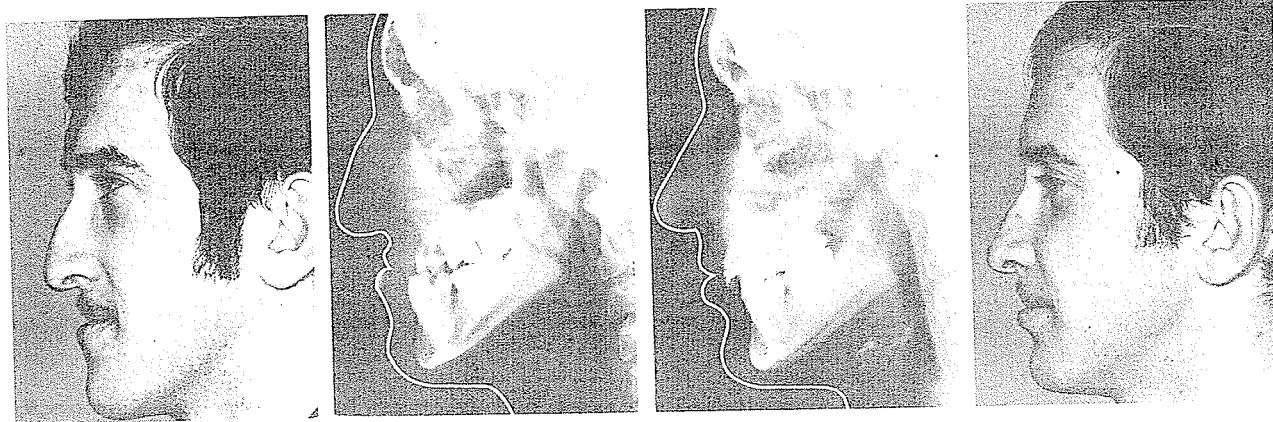
G



D

Occlusal views are shown of preoperative (E), postoperative (F) and final dental bridge work by patient's dentist (G).

Cephalometric x-ray films show preoperative condition and result four months postoperative with huge retromaxillary bone graft still visible. The before and after profiles show correction of the humped nose by forward movement of the maxilla only, without nasal surgery.



Tenacious Joseph E. Murray of the Peter Bent Brigham Hospital and Boston Children's Medical Center, the premier pioneer in kidney transplantation, has also been fascinated by craniofacial deformities. He fashions his plan of treatment according to the patient's desires and enjoys shifting and shaping bones. Once in the Brigham operating room while visiting as a Monks Lecturer, I watched Murray tailoring an iliac graft. He glanced up with a twinkle in his eyes.

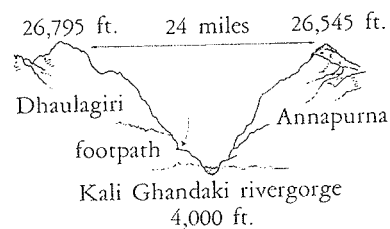
Imagine getting paid for doing something as much fun as this!

Murray is challenged by deformities of the skull and facial skeleton as much as by the bleak face of a bad mountain. Whether on a wedge ascent of a chimney in the Alps or on the treacherous Nepal footpaths leading to Tibet high over the Kali Ghandaki River running in the deepest gorge on earth, he faces each crisis with conditioning, caution and courage. He warns:

While wondering about the next hand, foot or rope hold there is danger; doubt is dangerous. Decisiveness in decision is followed by decisiveness in action and a secondary decision can be just as vital. . . . After a very difficult

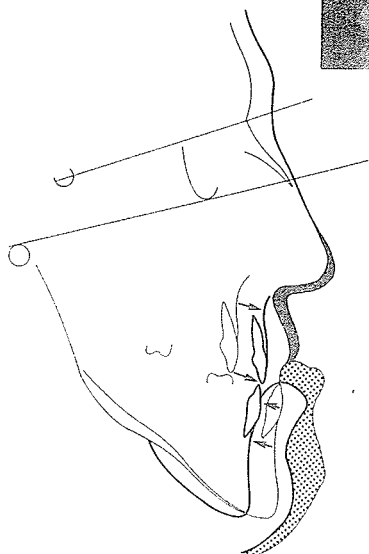



*Joseph Murray*



traverse half way up Mt. Darwin in the Sierras we were trapped in a cul-de-sac with no escape. Here admission of our fault and retracing the tough traverse to a better alternative route was chosen over chancing an improper, unplanned new route.

In 1977 Murray forwarded a secondary cleft case in which Robert Gross had closed the lip in the early 40's. The patient had been lost to follow-up for 20 years.



Profile change  
 Preop (10-2-72) —  
 Postop (10-22-74) - - -  
 Reduction of prognathism ※  
 Maxillary advancement ■

In November 1972, Murray, with Paul Tessier assisting during his first operative visit to Boston, carried out a mandibular setback (Obwegeser ramusotomy), maxillary advancement (Le Fort I) and onlay bone graft to the maxilla.



Murray reported:

bilateral paresthesia in mental areas, realignment of maxillary dentition and fixed prosthesis and excellent psychosocial rehabilitation. The patient married one of the nurses caring for him and now has a child and a successful real estate business.



Ian R. Munro of Toronto trained at Cambridge University and St. Thomas's Hospital, London, and took his postgraduate study at the University of Toronto, where, as a resident at the Hospital for Sick Children, his interest in craniofacial deformities was first stimulated. From 1971 to 1974 he peregrinated between Tessier and Obwegeser, and now returns regularly for further observation. He always has classical music playing in his operating room, with his best work created during Wagner. Here are two of his secondary cases corrected by Le Fort I osteotomies:



*Ian Munro*

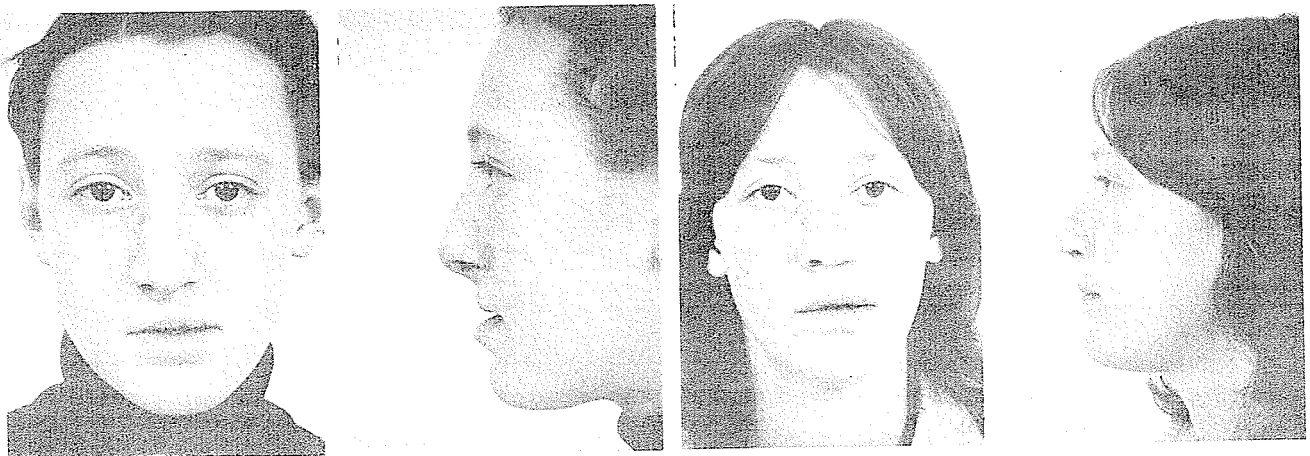*Case A:* Preoperative—15 years old. Unilateral cleft lip [LeMesurier] and palate with superior flap pharyngoplasty. Postoperative—1 year later: Le Fort I maxillary advancement in 2 segments and simultaneous lengthening of pharyngeal flap.

A



*Case B:* 1973: Preoperative—15 years old. Unilateral cleft lip [Blair-Brown] and palate. 1976: 3 years after Le Fort I maxillary advancement and 2 years after secondary operation of Neuner bipedicle visor flap of mucosa from lower to upper lip and rhinoplasty.

B



The blood supply to the maxilla during these advancements can become somewhat impaired. Gillies noted this situation, as has Obwegeser, who warned:

Often [gingival and palatal tissues] appear cyanotic during surgery, and, therefore, the suturing must be meticulous and the tissues handled with the utmost gentleness. The true fate of the palatal blood vessels is not known, but in a forward movement of up to 20 mm. it is improbable that they still function. However, in my experience, I have not seen necrosis of a bony segment.

Intermaxillary fixation is maintained for four to six weeks, and for two or three weeks after release of fixation forced opening exercises may be necessary. The first signs of a possible relapse will already be apparent during this period.

#### A WARNING

It has been noted that in patients in whom cleft palate surgery has included ligation of the greater palatine vessels, partial maxillary necrosis can occur when major maxillary advancement (2 cm.) is carried out subsequently. In 1979 Rainer Drommer of Gottingen, Germany, with Obwegeser studied 12 cleft palate patients being considered for Le Fort I osteotomies, using external carotid arteriography to show presence or absence of vessels. All but 1 of the 12 revealed the descending palatine artery and its branches to be intact. In the one exception a Le Fort III osteotomy was used. They concluded that in the absence of the greater palatine vessels, Le Fort II or III osteotomies, in preference to Le Fort I, may be indicated for a safer advancement since these more radical procedures at least preserve the needed anterior vestibular blood supply.



*Anthony Wolfe*

Multilingual Stephen Anthony Wolfe of the University of Miami, as the son of a military attaché (a legitimized spy), spent his childhood in Russia, France and Switzerland. As a Harvard medical student, during a visit to a state institution for the mentally retarded, he saw several patients with acrocephalosyndactyly (Apert's syndrome) with near normal intelligence. He

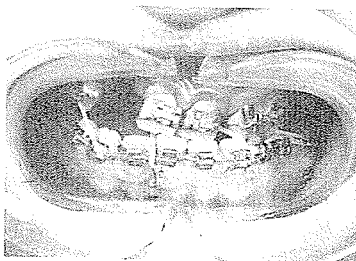
learned that one of these patients, with the usual grotesque and monstrous facial appearance, had had to take the institution entrance exam three times to get a low enough I.Q. test score to qualify for admittance and relegation to a hiding place. While a surgical resident at Boston's Peter Bent Brigham Hospital, Wolfe came upon Paul Tessier's first corrective craniofacial publication including Apert's disease, in the *Annales de Chirurgie Plastique*. In 1968 he saw Tessier give a presentation in Montreal. After completion of a plastic surgery residency at the University of Miami, Wolfe went to Europe to study for a year at the hard tissue centers of excellence, working primarily with Tessier in Paris, but also visiting Obwegeser in Zurich. Wolfe was impressed with the importance of Obwegeser's IPM bone grafts. He noted:

In the Le Fort I osteotomy, these IPM bone grafts are more crucial than in the Le Fort II or III osteotomies, since only in the IPM space and across the anterior maxillary osteotomy lines are bone grafts put to maintain position against subsequent soft tissue pressures. In the Le Fort I osteotomy, even if there is good intercuspsation of the teeth in their new position, intermaxillary fixation for six weeks is necessary. If there is not good intercuspsation, an overcorrection of 2-3 mm. should be done.

Wolfe outlines his Le Fort I osteotomy:

1. Nasal intubation, with tube sutured to septum.
2. Infiltration of alveolar mucosa with 1:400,000 epinephrine high near upper buccal sulcus to facilitate later closure.
3. Mucosal incision stops near the first molar and further dissection into pterygomaxillary space done by tunneling to permit later closure.
4. Mucosa dissected free from pyriform aperture and septum. In cleft cases, a more thorough dissection of the nasal floor in the cleft side is necessary.
5. Medial anterior maxillary cut well above pyriform aperture ("Le Fort 1½") and slightly up on beginnings of malar prominence to avoid tooth roots.
6. Pterygomaxillary disjunction done gently with butt of hand on a sharp, curved osteotome. The pterygoid venous plexus may bleed vigorously, but generally this can be controlled with packing. Re-operative surgery in this area can be particularly bloody.
7. The septum is cut submucosally with a guarded osteotome.

8. At this point, firm downward pressure on the maxillary alveolus will open up a gap in the maxilla through which the medial and posterior walls of the maxillary sinus can be cut under direct vision.
9. The Rowe forceps, or Tessier "de-Crouzonizing" grappels achieve a completely free maxilla which can be brought into the desired occlusion.
10. Bone grafts placed in the IPM space if there has been an advancement of more than 2 to 3 mm., and wired along the anterior maxillary cut. Fresh iliac cancellous bone is preferred to all other materials. In cleft cases there is often a differential movement of the two segments. Bone grafting of the nasal floor on the cleft side gives bony continuity to the palate, which can be continued anteriorly to close the alveolar arch.
11. Suspension and immobilization with circumzygomatic wires. If there is any mobility at the maxillary osteotomy line, further stability can be obtained with a wire passed percutaneously around a screw in the glabellar region (Kufner suspension).
12. Nasogastric tube passed at end of the case.
13. Intermaxillary fixation 6-7 weeks.



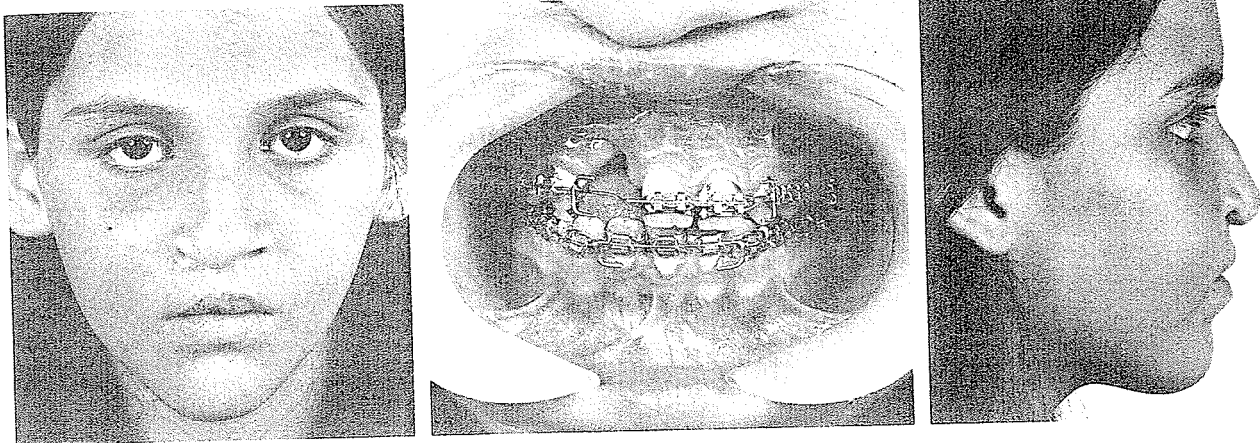
Here is a girl born with a unilateral cleft of the lip and palate, treated in infancy in South America, who developed a retro-maxillism which, in turn, was treated by another service with a Le Fort I osteotomy at the age of 11 years with apparent correction of occlusion. When seen at age 15 years, she revealed a moderately severe class III malocclusion requiring a 10 mm. advancement. This postoperative relapse is a common occurrence in cleft cases, but it was exaggerated by continued growth of the mandible while the osteotomized, bone-grafted maxilla remained stationary.

Tony Wolfe, with the assistance of orthodontist Sam Berkowitz, undertook maxillary correction. He noted:

Re-doing a Le Fort I osteotomy is not as easy as the original operation. When a bone graft has been placed in the pterygomaxillary space, the pterygoid venous plexus becomes adherent to the bone graft and considerable bleeding can occur during dissection of the soft tissues from the bone. This occurred in this case during the pterygomaxillary disjunction but fortunately was controlled with patience and by packing with Surgicel. This bleeding can be far more serious, and indeed deaths from sanguination at this stage in a Le Fort I osteotomy have occurred (D. Wood-Smith verbally reported one at the Duke Cleft Palate Symposium in 1973). Therefore, one

should wait until mandibular growth is complete before advancing the maxilla.

This timing of maxillary surgery pertains to other craniofacial procedures. Those advocating early maxillary advancements in the first half of the first decade of life for Crouzon's and Apert's syndromes to "spare these poor little children and their parents any psychological stress" will markedly increase risks when reoperation becomes necessary.

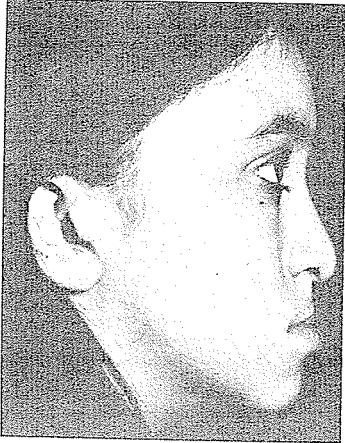

After osteotomy

Nine months after maxillary advancement and correction of malocclusion, I performed a cleft lip rhinoplasty including nasal reduction, alar cartilage lift and overlap, septal cartilage struts into columella and alar base advancements (Volume I). Three months later the alar rim was revised and upper lip scar excised with transposition of a narrow vertical flap from center of lip to lengthen the short left side. A shield-shaped Abbe flap was transposed into the defect.



*Orthodontists  
beware!*

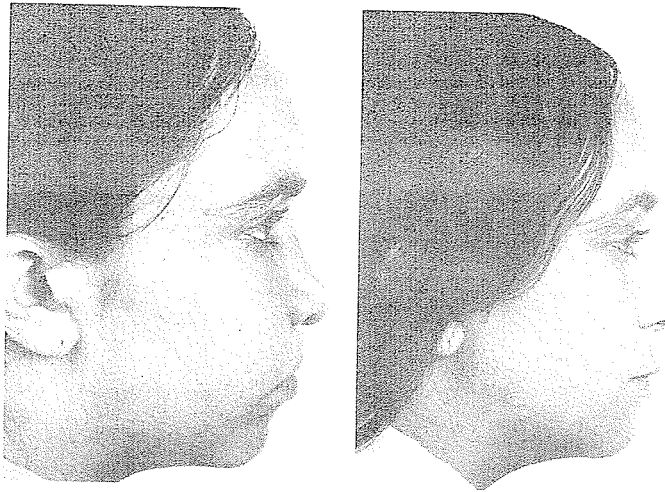

In cleft palate patients, once the Le Fort I has been performed, the two halves of the maxilla will be independently mobile. Transverse palatal expansion can be achieved and maintained by bone grafts in the cleft space.

Excellent occlusion by a skilled but overenthusiastic orthodontist can prevent the best treatment and force second-rate onlay grafting. S. A. Wolfe considers this a frequent and frustrating situation, one of the greatest crosses the maxillofacial surgeon is being forced to bear. He noted:

Orthodontists who do not work closely with a surgeon can fall into the trap of treating skeletal deformities with orthodontics. In essence, they burn the bridge for a monobloc advancement. This patient had maxillary hypoplasia and class III malocclusion, but underwent extraction of teeth and orthodontic therapy instead of a Le Fort I. Onlay bone grafting gave considerable improvement, but was clearly the procedure of second choice.

She later had some nasal correction and a midline, shield-shaped Abbe flap.



In 1977 Hans Freihofer of Zurich emphasized the wisdom of waiting to do bone surgery:

Based on the experience of 100 cases, I would strongly suggest that before performing orthodontic surgery, one should wait until growth is completed. This applies especially to Le Fort I osteotomies so important for many cleft patients. The comparison between non-cleft and cleft cases has shown that the results in young non-cleft patients are very bad whereas the results in cleft patients are even worse. Among patients being operated below the age of 16, there are 71% non-acceptable results, and among patients being

operated between 16 and 17 years, the percentage was 27%. In non-cleft patients the respective figures are 29% and 12%.

Of course, this is very bad news for cleft patients because, according to our philosophy, "first the bone and then the soft tissues." This means that secondary corrections can only be undertaken very late and often cannot be terminated at the age of 20.

## NASAL CHANGES WITH LE FORT I MAXILLARY ADVANCEMENT

In 1977 in the *Journal of Maxillofacial Surgery* Hans Peter M. Friehofer, Jr., of Zurich elaborated on the nasal effect of maxillary advancement first noted by Obwegeser:

Based on 25 cases with unilateral clefts of lip, alveolus and palate with retromaxillism (CLAP) and 25 cases with pure retromaxillism (RM) the effect on the nose of advancing the maxilla by a Le Fort I osteotomy is analyzed. It can be shown that on average the base of the nose which is at the same time the base of the upper lip, follows the base of the maxilla in a ratio of 4:7 while the nasal tip is advanced in a ratio of 2:7. This means that to achieve a specified advancement of the nasal base, the maxilla has to be brought forward about twice this amount. A planned advancement of the tip of the nose can, on average, only be obtained by an advancement of the maxilla by three times this amount. The tangent to the columella is tilted considerably forwards and upwards. The movement is a little more marked in CLAP than in RM. . . . Leaving the nasal spine intact and tilting the maxilla forwards and upwards have a favourable influence on the advancement of the nasal tip. . . . On the other hand, if the nasal profile is required to stay unchanged as far as possible, the nasal spine should be removed and the maxilla should rather be tilted downward.



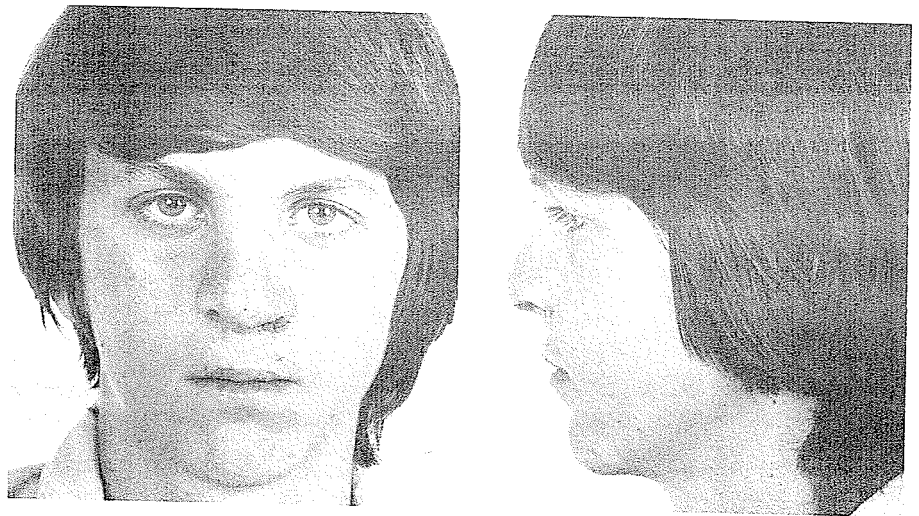Hans Friehofer

## FORWARD MOVEMENT OF THE MAXILLA WITH LE FORT I AND OPENING THE CLEFT

Forward advancement of the maxilla while simultaneously opening the cleft is most often used in unilateral complete clefts, combining the techniques of rotation and advancement of the maxillary segments. Obwegeser has been a pioneer in this maneuvering.

Here is an interesting segmental Le Fort I osteotomy by S. A. Wolfe, who refers to this type of Le Fort I as a "Le Fort  $\frac{1}{2}$  plus  $\frac{1}{2}$ ." The patient was born with a unilateral cleft lip and palate. A LeMesurier closure of the lip and a von Langenbeck palate procedure had been carried out in Alabama. I did some lip and nose revisions at age 6 years and a cleft lip rhinoplasty at 16. Subsequently, the patient's orthodontist wrote from Georgia stating that he was unable to obtain a satisfactory occlusion and that an oral surgeon had recommended a mandibular setback. Tony Wolfe was consulted and this is his report:

The patient's soft tissue result was reasonable and the profile acceptable but there was still moderate flatness of the midface. Analysis of the dental models showed class III malocclusion at the molar level of both of the maxillary segments, but with a left segment which was also in crossbite, and anteriorly had an open bite of 13 mm. Thus, the left maxillary segment was making very little contact with the mandible, and was almost useless to the patient for mastication. There is no way that moving the mandible back would correct this. It would only give a better occlusal relationship to the teeth of the right side and would do nothing for the flatness of the patient's midface.

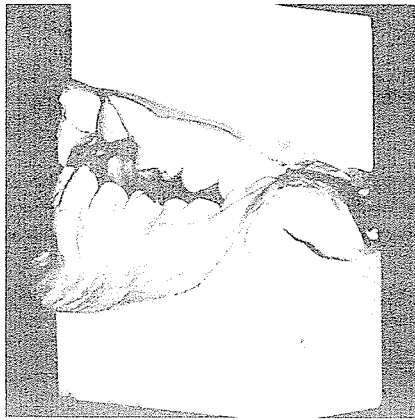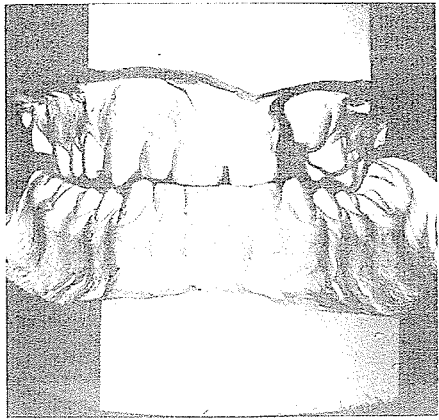


Before osteotomies

*Operation:* Anterior maxillae sectioned well above the level of the pyriform aperture. On the left, there was no pyriform aperture since the bony cleft extended into the nasal floor. A large oronasal fistula present on the left, running up through the cleft alveolus. Careful sectioning of bone connections between pterygoid plates and maxillary tuberosities. Nasal septum and vomer cut from palate (attached on right only). Fracture of medial and posterior walls of maxillae then produced by firm posterior pressure. Maxillary osteotomy line then opened up with distraction forceps, and remaining


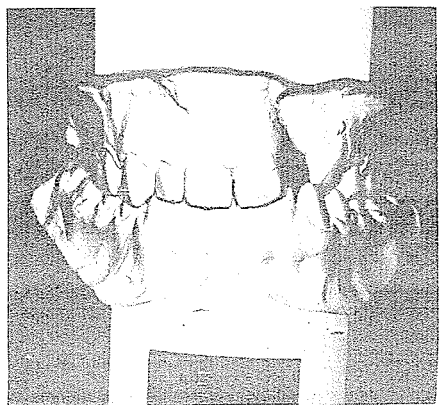


small bony connections, clearly visible through the now-opened maxillary sinus, sectioned with a small osteotome. Both greater palatine vessels clearly seen from above, through the sinus. Soft tissue stretching carried out with Rowe forceps and Tessier grappels until both maxillary segments could easily be moved beyond their intended positions with only slight traction from a tissue forceps. The right segment was moved 6 mm anteriorly and 2 mm laterally. The left segment was brought forward 8 mm, laterally 4 mm, and rotated inferiorly 13 mm. Circumzygomatic suspension attached to the circummandibular wires to avoid excessive traction on teeth, and intermaxillary fixation obtained. Nasal lining had been separated from the palate the entire length of the palatal cleft on the left, and this was closed. Cancellous iliac bone used to fill the palatal cleft, rebuild a nostril floor and pyriform aperture on the left, and close the alveolar cleft. Corticocancellous chunks placed in pterygomaxillary spaces. The oronasal fistula was easily closed.



Before

Intermaxillary fixation was maintained six weeks and dental models obtained to show the results clearly. Such a result could have been obtained only by very great difficulty and extensive postoperative orthodontics if the mandible had been set back and the cleft bone grafted, as suggested, and he still would have had a flat face.

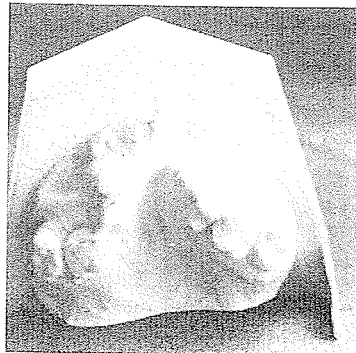



After

In the bilateral cleft, forward advancement of the maxilla, while opening the cleft, poses a danger because the blood supply to the premaxilla enters only through the vestibular mucosa. Obwegeser advised:

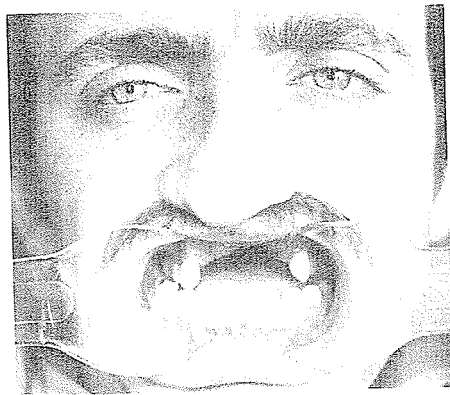
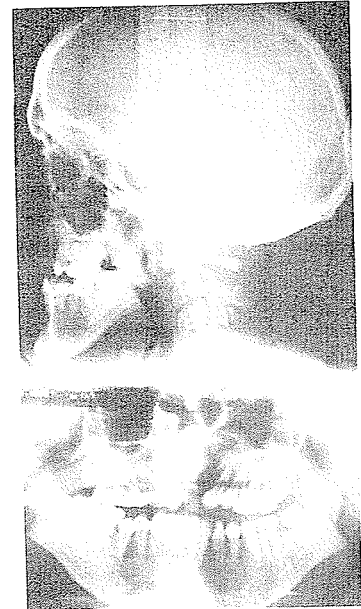
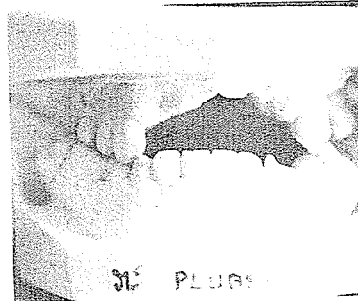
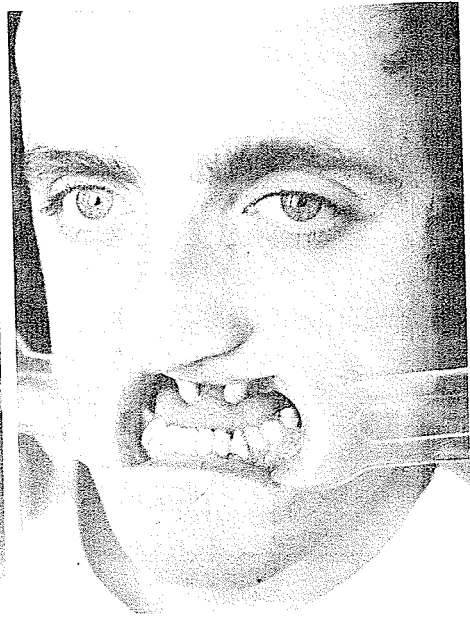
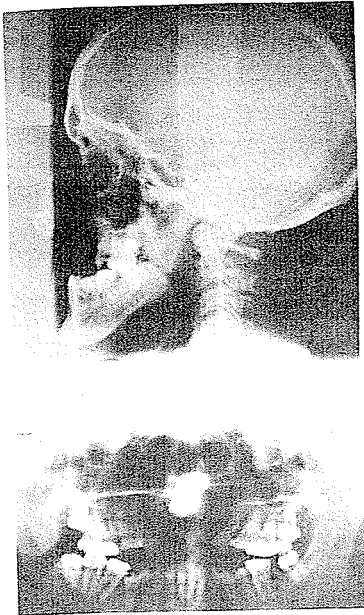
In the first operation the lateral alveolar segments only are advanced; in the second operation, when the re-opened cleft is being closed, I advance the premaxilla and do a simultaneous bone implantation.

Jacques Dautrey of Nancy has added a modification. For cleft lip and palate cases he no longer does a complete Le Fort I, having noted that the second superior molar almost always occupies the normal position. He therefore performs a unilateral segmental osteotomy which mobilizes the incisors, if present, and the canine, the two premolars and the first molar. The positioning of this limited segment is much easier and is satisfactorily immobilized with a simple arch bar (without the use of intermaxillary fixation) since the second molar of one side and the entire hemi-arch of the opposite side remain intact. Three months later he does the other side, if necessary.



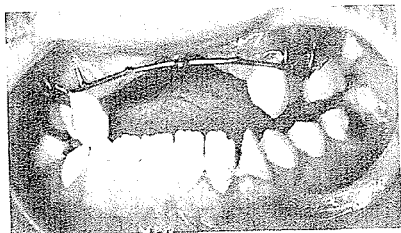


Here is a fantastic case. The premaxilla had been excised at the time of closure of what was probably an incomplete bilateral cleft. Dautrey achieved advancement of the maxilla and opening of the cleft using his modification. When the patient was first seen at the age of 20, the mandibular arch was normal and the two remaining maxillary segments were in severe crossbite, with dental contact only at the right second molar. Cephalometrically the mandible was in relatively normal position, but its prognathism can be explained by the fact that, with a maxilla contracted in the vertical plane, the mandible had to go beyond the normal closing angle before making contact with the lonely molar, reminiscent of the pseudopognathism of the edentulous elderly.

Dautrey moved the mandible back within striking distance by sagittal split with intermaxillary fixation. Then with extraction of a first molar, keeping the second molar and the maxillary arch on the other side as stable fixation points, he freed one two-tooth segment and rotated it into relation with the mandible. The movement was lateral and posterior and put the teeth into a usable maxillary arch. Fixation was achieved by a rigid arch bar from the shifted segment to the stable segment of the opposite side. In the second stage, the opposite maxillary segment was



shifted and fixed in similar fashion. The final result shows the patient without any soft tissue surgery but with a fixed anterior bridge in place.



## FORWARD MOVEMENT OF THE MIDDLE THIRD OF THE FACE BY LE FORT III OSTEOTOMY

Gillies was the first to accomplish this maneuver, having become interested during the wars in maxillary refracture. As we wrote in 1952, and published in 1957:

A plethora of these upper jaw fractures since 1916 enables our War Office report to state categorically in 1939: "Malunion has occurred, interfering with mastication and/or appearance. Treatment—an attempt should be made to obtain union in a more favourable position by osteotomy.

An important case for Gillies was Airman Forbes, who crashed coming in from an operational flight, crushing his face against the dashboard with a type of Le Fort III fracture, plus splitting the hard palate and sustaining a symphysis fracture of the mandible. Immediate disimpaction and fixation resulted in a remarkable recovery which was exciting to Gillies.

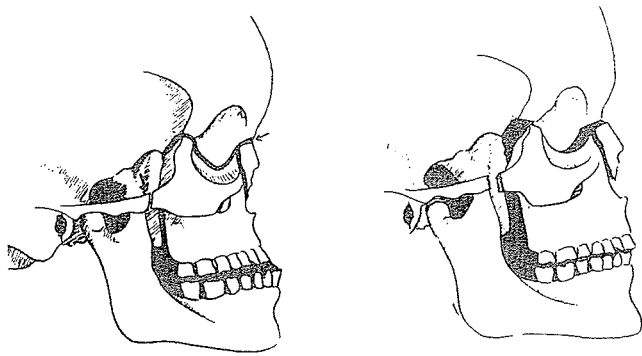
## LATE OSTEOTOMY

Another historic case concerned a Hurricane pilot who crashed, suffering severe fractures of the face with everything below the eyebrows pushed back. His spinal injury caused facial correction to be postponed one year. Then in 1941, with neurosurgeon Cone, Gillies made

chisel cuts through nasal arch to floor of orbit—out to fronto-nasal synchondrosis—over to zygomatic arch—down speno-maxillary suture (with osteotome)—lever behind last molar—entire maxilla rocked free. Forward retention maintained by 1-lb. weight and pulley attached to maxillary splint. . . . After a bone graft was implanted in the floor of the right orbit, the diplopia was reduced.

## FIRST OSTEOTOMY IN CONGENITAL CASE

In 1949 Sir Harold Gillies performed the first osteotomy of the facial bones along the lines of a Le Fort III fracture to advance the mid-face in a nurse with Crouzon's disease.



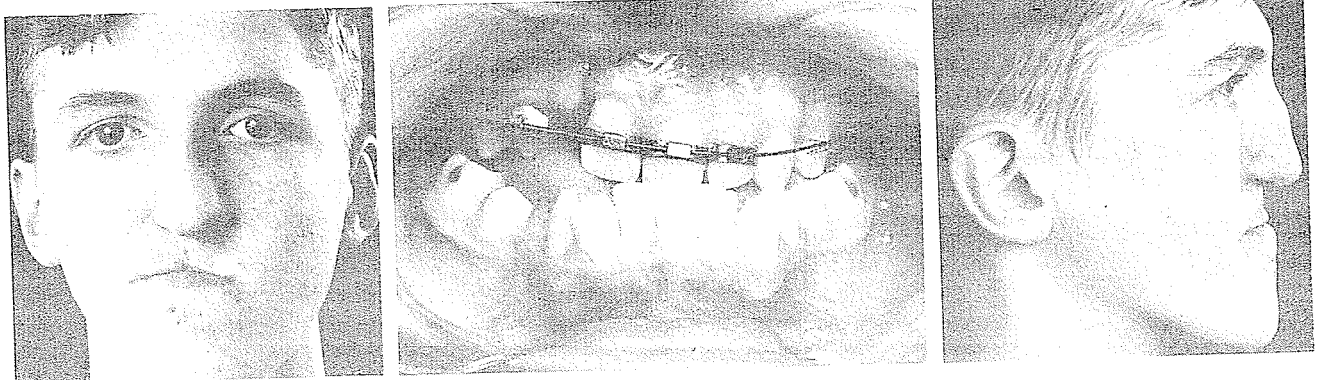
There was considerable postoperative loss of the maxillary advancement gained surgically in this case. In 1954, with Norman Rowe, Gillies acknowledged that bone grafts in the osteotomized spaces were necessary to maintain the advanced position of the maxilla.

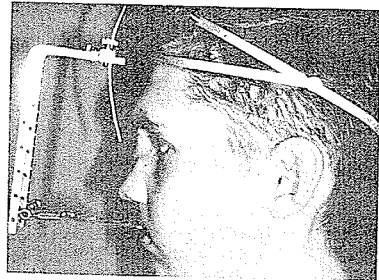
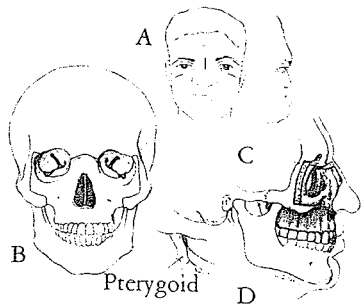
Although Gillies was first with a Le Fort III, Paul Tessier of Paris has developed principles which now allow movement of any part of the upper half of the facial skeleton into any position.

Reed Dingman of the University of Michigan stated in 1977:  
In the past, we have done mandibular setbacks when we should have been doing maxillary osteotomies with advancement.

He forwarded this interesting case of a 16-year-old boy who had his cleft lip closed at 1 week and his palate at 1 year in Detroit. He noted:

The nose had a large dorsal hump with a bulbous drooping tip and flattening on the side of the cleft. The upper lip was short and tight transversely with notching at the site of the lip repair. The middle one-third of the face was underdeveloped and recessed. There was relative mandibular prognathism and Class III malocclusion. The palate was very short but moved very well. The teeth were in fairly good condition and speech was satisfactory.



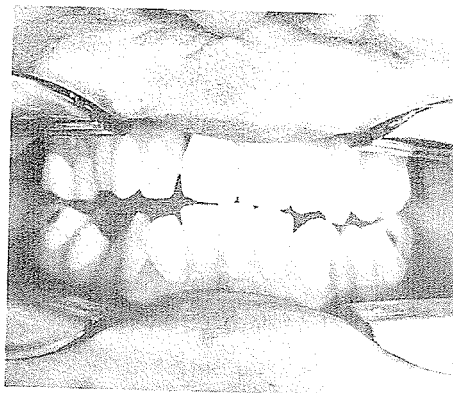



After consultation with orthodontist Ponitz,

On July 9, 1969, the patient had a tracheostomy followed by a Le Fort III-type maxillary osteotomy with mid-face advancement and bone grafts from the right iliac crest [Tessier]. Intermaxillary fixation was maintained by means of Erich appliances and rubber bands. Five days later a Georgiade halo appliance was added to apply forward traction on the maxilla. The patient was discharged on the 8th postoperative day.

After 4½ weeks, the halo apparatus was removed as well as the rubber bands. One week later the arch bars were removed. His occlusion was satisfactory. However, the patient's speech showed a great deal more nasality than before his operation. This was thought to be due to advancement of the palate leaving a larger velopharyngeal gap. Therefore, the patient had a superiorly-based pharyngeal flap and palatoplasty performed on November 18, 1969. Following this, his speech was again excellent.

In 1970 the patient had an Abbe flap and submucous resection for a deviated septal cartilage and later a corrective rhinoplasty.



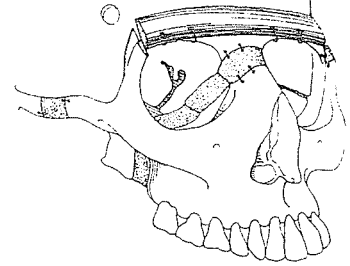
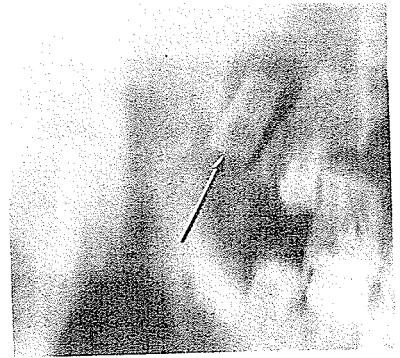
Wolfe suggests that in a case such as this, without exorbitism, it may be preferable to use a Le Fort II osteotomy, since a Le Fort III can result in enophthalmos.

In the Le Fort III osteotomy, Wolfe noted:

There are enough points of osteosynthesis that the maxilla is often so stable in its new position that IMF is not necessary. This has been done in two patients now with no appreciable relapse over a 2 year period, and Tessier has had a similar experience.

The major monobloc shift of a Le Fort III corrects many problems simultaneously—retromaxillism, exorbitism, nasopharyngeal atresia, with often a dramatic improvement in facial appearance.

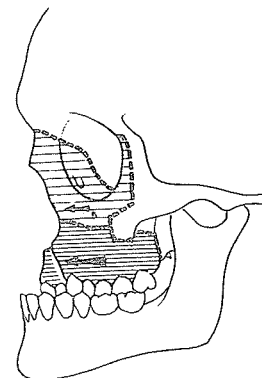
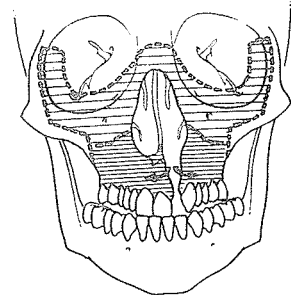
As taught by Obwegeser, it is important to keep the pterygoid plate intact to serve as a buttress against which a bone graft block can act to hold the advanced mid-face in the forward position. Here is a case by S. A. Wolfe in which a Le Fort III osteotomy had the advantage of a bone graft block placed exactly the same as in a Le Fort I. The tomograms show the bone graft in the space between the pterygoid plate and the maxillary tuberosity.



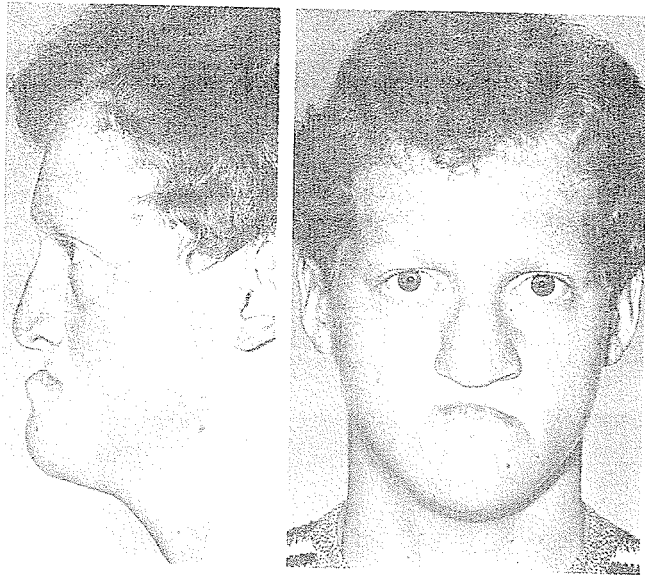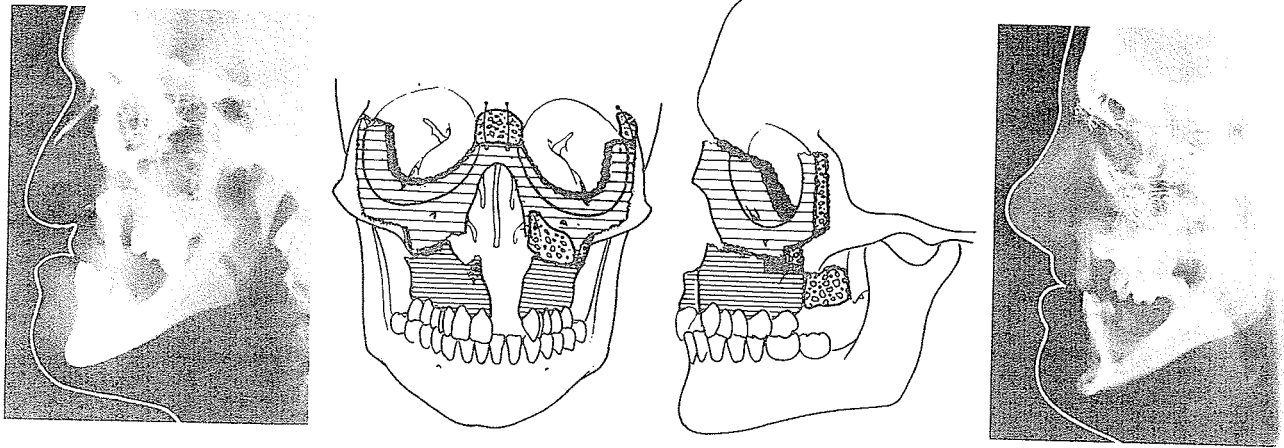
### SEPARATE FORWARD MOVEMENT OF THE MIDDLE THIRD OF THE FACE BY COMBINED LE FORT I AND LE FORT III OSTEOTOMIES

When there is a disparity in the retroposition of the upper half and the lower half of the middle third of the face, each half poses a separate problem. Primarily, the upper half has an aesthetic deficiency with pseudoexorbitism, while the lower has functional impairment of occlusal imbalance. This calls for Le Fort I and III osteotomies simultaneously. The gaps are filled with bone, and fixation is maintained with intermaxillary wiring plus inter-skeletal suspensions.

Here is a dish-face deformity in a bilateral cleft case corrected by Obwegeser by advancement of the middle third of the face in two layers after Le Fort III and Le Fort I osteotomies, anterior



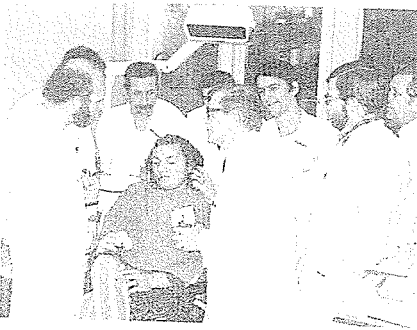positioning of the premaxilla with bone grafting and closure of remaining fistulae and elongation of the columella and complete rhinoplasty. Cephalometric x-ray films show patient before and after surgery, but before dental prosthodontic work.



Before



After



Professor Obwegeser in clinic

*you can bet everyone in this crowd has a dental degree or wishes he did!*

Professor Hugo Obwegeser is constantly involved in clinical teaching. In 1971 in *Cleft Lip and Palate* he set as the goal in hard tissue surgery of the maxilla in postoperative cleft lip and palate cases the old Gillies edict: *Replace into normal position what is normal and retain it there.* He noted that adhering to this principle required the following:

1. Correct the axes of inclination of the teeth with the alveolar process; create a normal arch, which may be done by surgery or by orthodontic treatment or by both methods.
2. Reposition the alveolar process so that its axis is properly aligned with the base of the jaw.



3. Establish acceptable intermaxillary and occlusal relationship; the new position should, of course, harmonize with the other parts of the facial skeleton.
4. Some cases require additional facial contour alterations. The main procedures are: onlays, recontouring a bone that is too prominent, or using a dental prosthesis.

Obwegeser's aids to preoperative planning are:

1. Photographs (front and profile views of the face and intraoral views—occlusal, palatal, and any special views needed).
2. Extraoral radiographs (cephalograms, standard views, orthopantomograms, and tomograms).
3. Intraoral radiographs (periapical and occlusal).
4. Dental examination: carious lesions, vitality, and periodontal tissues.
5. Study casts: one stone set to record the preoperative occlusion and the jaw relationship; two plaster of paris sets to be used for model operations.
6. Observe the functional movement of the mandible and the motility of the muscles of the facial expression; check the trigeminal nerve.
7. Record the patient's speech.
8. Evaluate the patient's total health.
9. Secure any additional indicated consultation of other specialists: e.g., speech therapist, orthodontist, prosthodontist, otolaryngologist, etc.

## MALPOSED TEETH

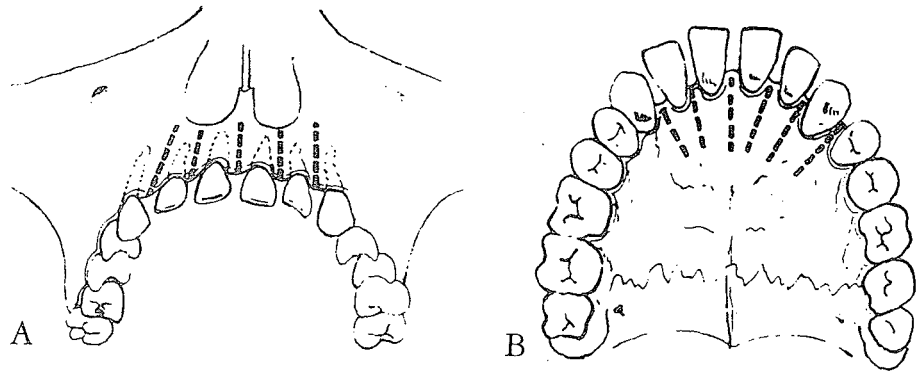
In the presence of a good jaw and an acceptable alveolar relationship, malposed teeth can be corrected with orthodontia. Orthodontic treatment should be limited to aligning the axis of the teeth with the axis of the alveolar process. Creating an overjet by orthodontia results in little improvement in the patient's outward appearance—the teeth and/or alveolar process inclining too far anteriorly while jeopardizing periodontal tissues—and renders subsequent surgical correction of the profile more difficult.

## SOPHISTICATED SEGMENTAL PROCEDURES

### *Corticotomy*

It often takes a long time to move adult malposed teeth by conventional orthodontic methods alone. Corticotomy combines

surgical and orthodontic treatment and, by decreasing bony resistance, shortens the time factor. In 1958 Heinrich Köle of Graz described this technique. A gingival margin incision allows reflection of the mucoperiosteum in the selected area. A thin bur is used to make vertical cuts through the cortical plate of the

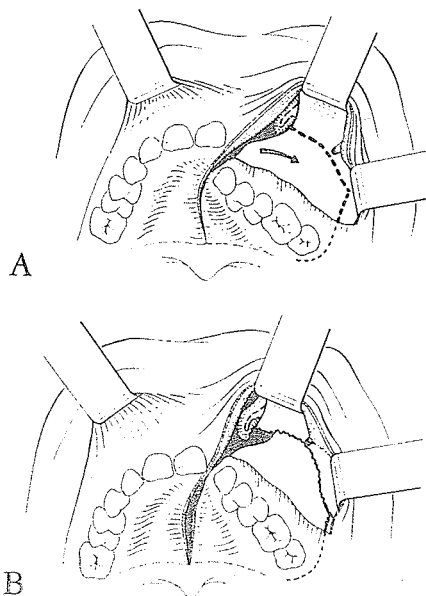


alveolar bone on the buccal or palatal side, depending on which direction the surgeon desires to move the teeth. The vertical cuts are placed on both sides of each tooth selected for movement and extended to a level just above the apices of the teeth. The mucoperiosteum is replaced, sutured and allowed to heal about 10 days before orthodontic movement is begun.

*Unilateral rotation of small alveolar segment*

A common deformity in clefts of the alveolus and hard palate is the upward and inward displacement of the alveolar process and its teeth on the cleft side. As noted by Gillies and Millard in 1957 in *The Principles and Art of Plastic Surgery*, this segment has to be tilted downward and rotated laterally. As pointed out by Norman Rowe in 1954, the axis for both movements is an imaginary line extended through the maxillary tuberosity. In Obwegeser's diagrams for *Cleft Lip and Palate*, the broken line marks the mucoperiosteal incision and the bone cut by bur as a horizontal osteotomy from the pterygomaxillary fissure anteriorly to the pyriform aperture at the level of the infraorbital foramen (A).

An osteotomy is also done on the lateral wall of the nose just below the level of the inferior concha. Bony connections, between the halves of the hard palate and mucosa of the nasal floor, are cut with a small osteotome. A heavy elevator is used to pry the segment into the desired position. This rotation creates two



fractures: The posterior wall of the sinus will fracture, and the pterygomaxillary fissure will greenstick fracture (B). The mobile fragment should be held in corrected position for six weeks by a preoperatively applied splint fixed to the other side of the upper arch. The upper arch and palate is shown before operation by Obwegeser (C). The upper arch and palate is seen after lateral rotation of a small segment and closure of reopened cleft using a vestibular flap as oral layer in the anterior palatal area and after definite bridgework constructed by patient's dentist (D).

Obwegeser noted:

The goal of all these procedures—the osteotomy, the repositioning of the displaced alveolar segment, cleft closure with bone grafting, and postoperative orthodontic treatment—is to create normal occlusion, and to create more favorable conditions for the construction of a denture or a fixed bridge. All of these, of course, improve the appearance of the face.

#### *Rotation of bilateral alveolar segments*

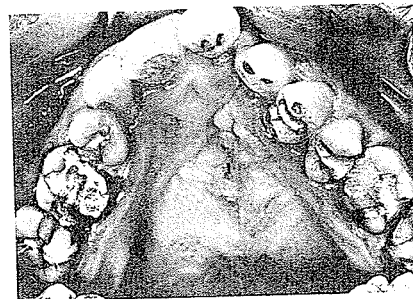
The management of a bilateral case is similar to that of a unilateral case. Both sides are rotated simultaneously with greenstick fractures in the tuberosity areas. In addition to intermaxillary fixation, interskeletal suspension, usually by circumzygomatic suspension wires, is required. If the premaxilla needs repositioning, this is done later with bone grafting, at the same time that the cleft is closed.

#### *Unilateral complete clefts*

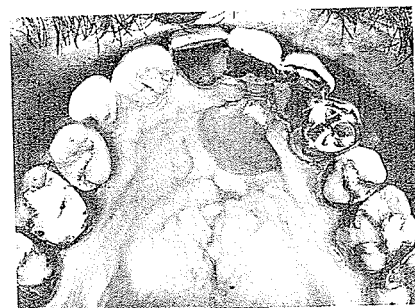The smaller segment is moved as already described. The incision for the larger segment is carried across the midline and extended into the cleft. The mucoperiosteum is reflected, the nasal spine removed and the vomer separated from the palate. The bone cutting and repositioning are similar to those on the other side. As soon as the fragments are mobile, the smaller segment is positioned laterally first. If the mucosa of the vomer prevents lateral rotation of the large segment, it is incised at its junction at the floor of the nose under direct vision. Fixation and intermaxillary immobilization are essential.

#### *Reducing broad maxillary arch*

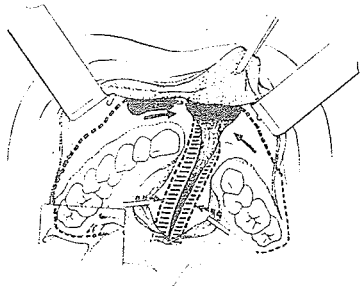
As noted by Hugo Obwegeser, an orthodontically overcorrected



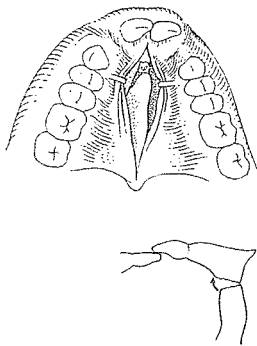
C



D



maxillary arch may be too broad, with the teeth flared. Also, in cases of retromaxillism, surgical bilateral rotation of the alveolar segments without forward repositioning may produce an arch that is too broad. To compress such an arch, tissues must be removed from the cleft area of the hard palate and the alveolar process. With limited reflection of palatal mucoperiosteum, the planned amount of bone and soft tissues along the margins of the palatal cleft is removed. The broken lines mark the bone cuts, which are carried out as in the outward rotation technique. The arrows indicate the direction the palatal segments are moved in order to compress the arch.



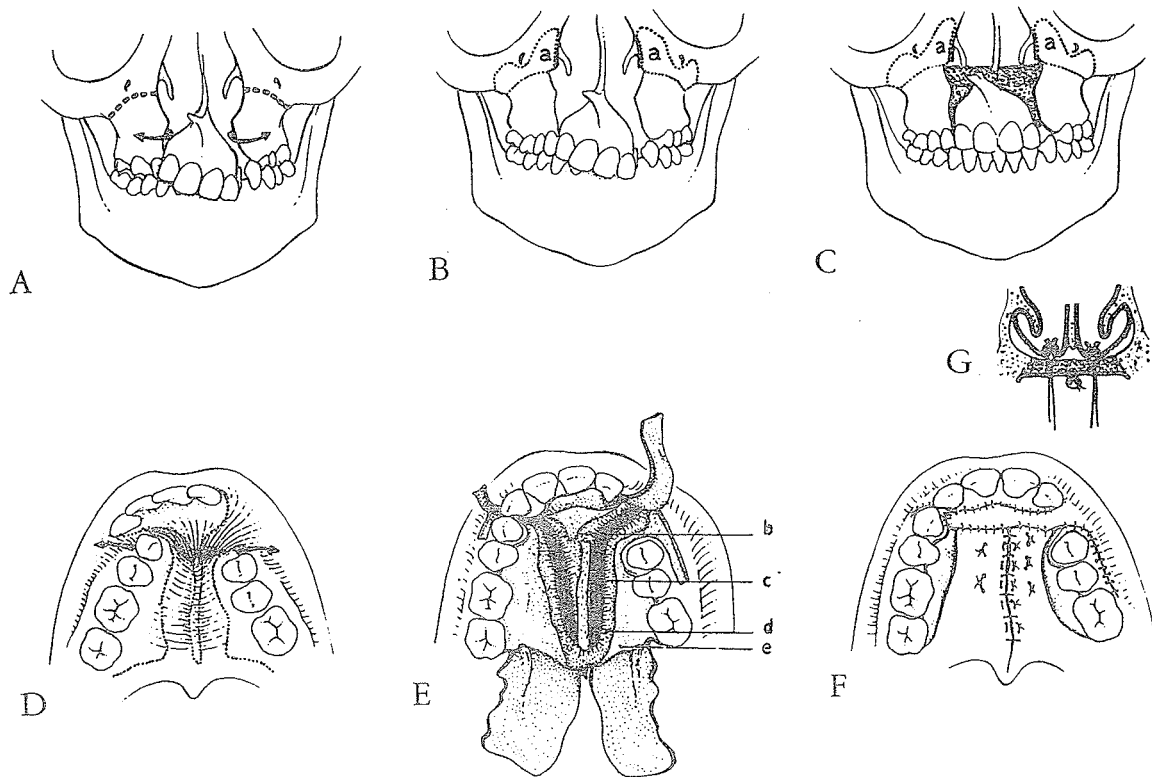
#### *Osteotomy for tilting premaxilla*

When the premaxilla is tilted palatally but lateral occlusion is satisfactory, the base of the premaxilla is fractured. Obwegeser varies the incision. With an open cleft, the bone cut is made through the cleft; with a closed cleft, it is made on the palatal side. After the soft tissues have healed, the orthodontic tilting is quite quick and easy with the soft tissues stretching. He noted:

If the teeth are to be used as bridge abutments, the premaxilla should have bony union with the lateral segments. . . . Therefore, it is usually wise to do both the osteotomy for the tilting and the bone implantation all in one stage.

#### *Severe maxillary deformities in bilateral clefts*

Obwegeser admitted that he, as well as Barsky, Kahn and Simon (1964) and Pfeifer (1966), followed this sequence in a three-stage procedure: (1) repositioning the lateral alveolar segments, (2) closing the reopened cleft and (3) carrying out the premaxillary osteotomy, repositioning and secondary osteoplasty. He hailed Perko's 1964 plan for premaxillary osteotomy and cleft closure with simultaneous bone grafting in one operation as the second stage, after repositioning of the lateral alveolar segments. His series of diagrams demonstrates this two-stage design.



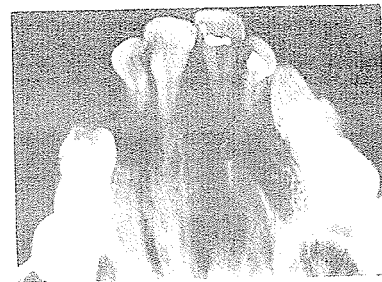He presented an impressive case in *Cleft Lip and Palate* treated in this manner.



Before operation



After rotation of both lateral alveolar segments

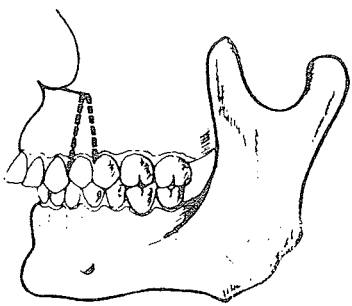


After repositioning premaxilla, simultaneous bone grafting and cleft closures

### *Various movements of the anterior segment of the maxilla*

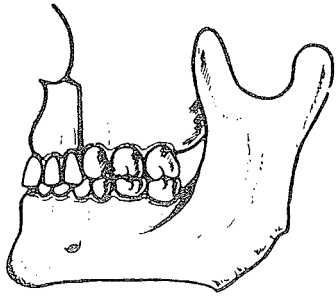
As noted by H. Obwegeser of Zurich:

Whether an anterior segment of the maxilla is to be moved forward or backward, the principles of planning and of operative techniques are similar. Also, the methods of bracing or stabilizing it are the same. One very seldom sees a true maxillary protrusion in patients with clefts. In such patients the planning and the principles for the correction of maxillary protrusion are



similar to the techniques used with noncleft patients. Since the reopened cleft provides better access to the operative site, it is simpler.

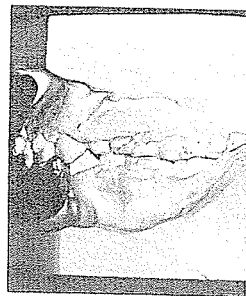
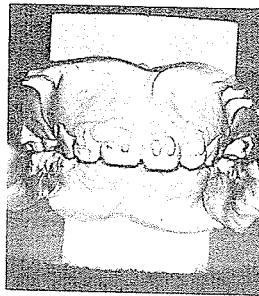
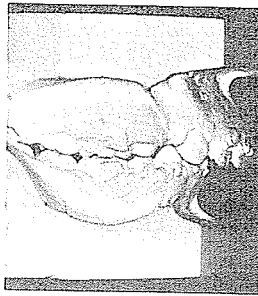
*Backward segmental movement*



In 1935 Wassmund of Berlin developed a technique of segmental osteotomy to correct open bite by retrusion of the maxillary median fragment, thus causing a deep bite.

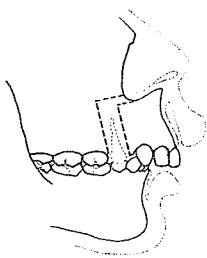
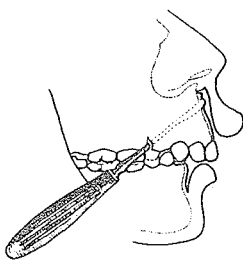
Here is a case of premaxillary protrusion, or "proalveolie." The patient had had the upper first bicuspid extracted, and even after years of orthodontic treatment she still had a premaxillary segment that was 8 mm. too far anteriorly and 6 mm. too far inferiorly.

Wassmund

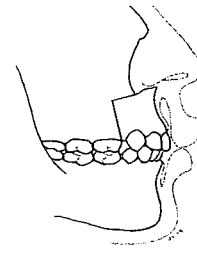


Wolfe described his one-stage surgery:


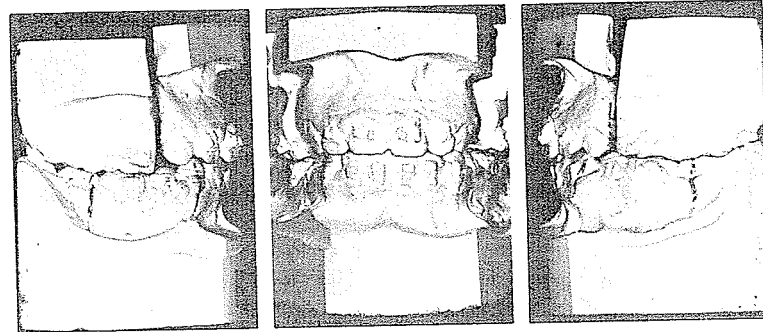
First, extraction of the remaining upper bicuspid. A transverse incision 1½ cm. in length made across the area of the nasal spine. Subperiosteal dissection carried up from the dental extraction sites across the premaxillary alveolar bone to the nasal spine incision bilaterally, enough to allow a small retractor to reflect the mucoperiosteum enough to permit the vertical osteotomy to be done with a small burr. The vertical osteotomies were carried up from the dental extraction sites, and the required 8 mm. of bone removed without damaging adjacent teeth. Transverse osteotomies were made just above the level of the pyriform aperture, but the nasal spine was left attached to the septum, which was then sectioned. A curved osteotome could then be introduced through the space beneath the nasal spine, and the palatal bone sectioned from above, with a finger held against the palate from below to be sure that the palatal mucoperiosteum was not damaged. The premaxillary segment was then free, and remaining segments of bone of



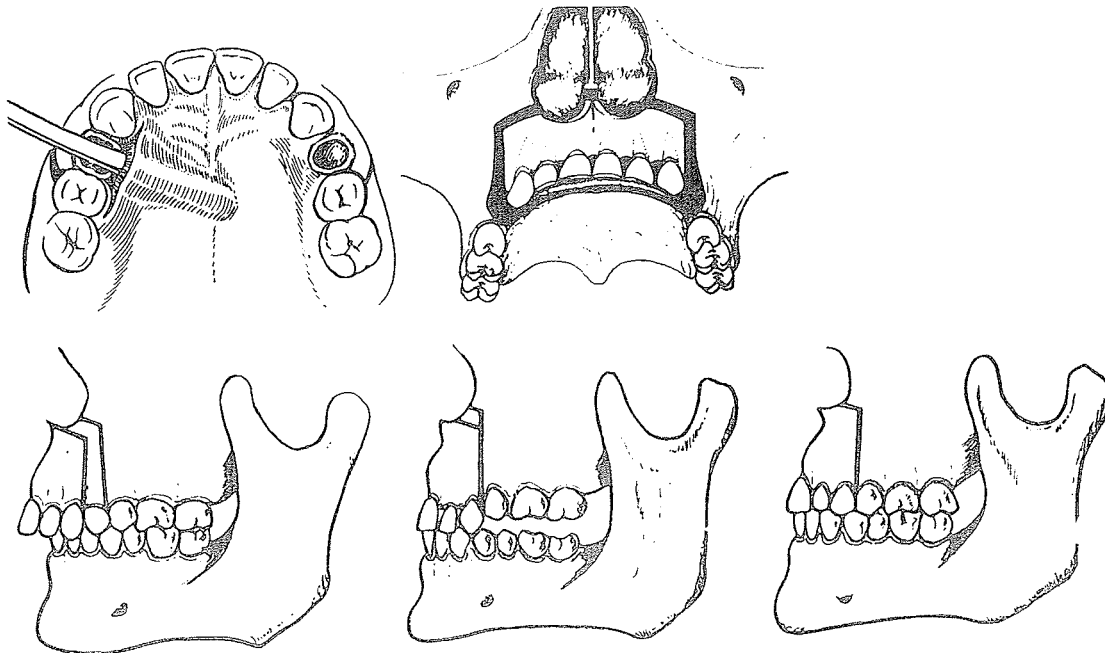
palate and alveolus could be removed under direct vision. The segment was moved into its predetermined position and was fixed to a prefabricated acrylic splint which was solidly attached to the stable posterior maxillary segments. Intermaxillary fixation was not required. A sliding genioplasty was performed at the same time.



*Comment:* This procedure preserves almost all of the mucoperiosteum on both sides, palatal and labial, of the premaxillary segment, and is thus much safer than the original Wassmund-Wunderer method.

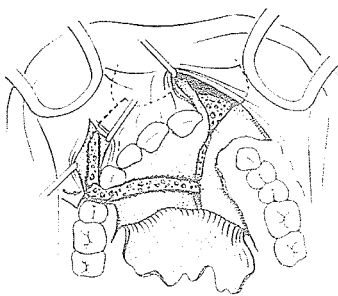
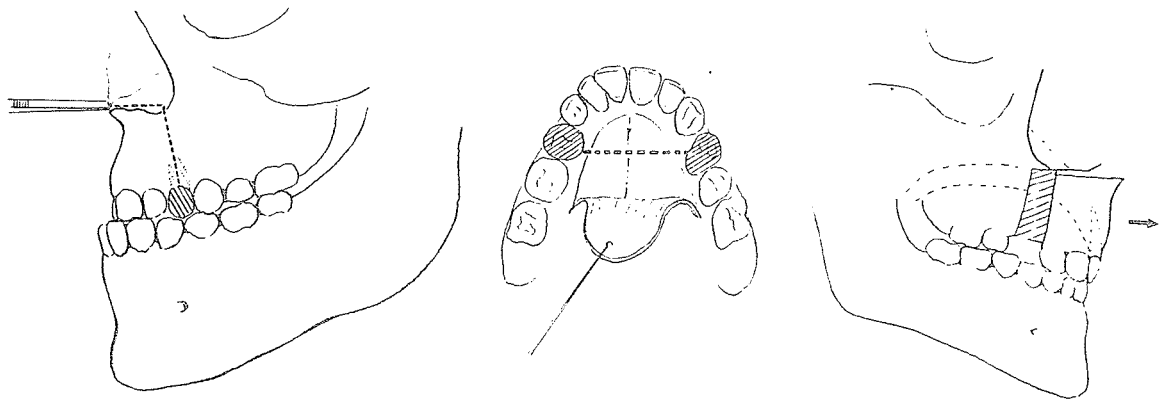


In 1959 Köle of Graz described the posterior and vertical repositioning, avoiding deep bite by splints. The maxillary median fragment was elevated; thus normal occlusion was obtained posteriorly. Elastics were later replaced by intermaxillary wires.



In 1964, in *Reconstructive Plastic Surgery*, John M. Converse, with Sidney L. Horowitz and Donald Wood-Smith of New York, described a simple surgical advancement of the anterior portion of the maxilla by

Bilateral extraction of premolar teeth with the line of osteotomy extending through the site of extraction to the pyriform aperture and a further osteotomy of the vomerine attachment to the floor of the nose. . . . Advancement of the anterior maxilla and maintenance of advancement by orthodontic fixation appliances and interposition of split rib bone grafts.

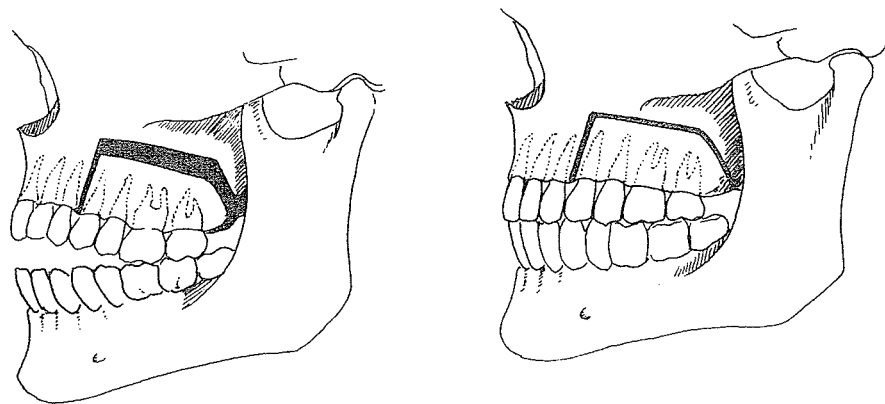


In 1971, in *Cleft Lip and Palate*, Obwegeser presented his technique for forward repositioning of the anterior part of a large alveolar segment in a case of unilateral cleft. As noted, this approach was much like that of Wassmund (1935) and Wunderer (1962). The moving maxillary segment received its blood supply through the narrow pedicle of vestibular mucoperiosteum. The defects were filled with bone, and the gingiva was moved to cover portions of the bone graft, as the arrow indicates.

#### *Moving posterior segment of maxilla*

In 1959 Schuchardt of Hamburg described a posterior maxillary osteotomy in which the posterior maxillary alveolar segment was freed and impacted into the maxillary sinus. This is a useful procedure in cases of anterior open bite in which the vertical facial height deserves reduction that can be achieved in one stage through a short buccal incision. The medial osteotomy must be done with accuracy, since the distance between the tooth root and the nasal cavity is only about 3 mm.

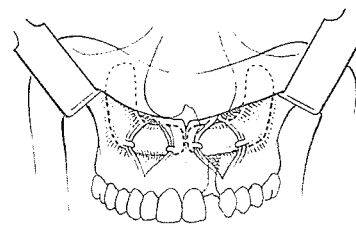




### CONTOUR CORRECTION OF THE UPPER HALF OF THE MIDDLE THIRD OF THE FACE

When there is a marked flatness of the middle third of the face, giving a "dish-face" effect, but dental occlusion is satisfactory, the preferred methods of correction are:

1. Mobilization and forward motion of the upper half of the middle third of the face, according to the method of Tessier.
2. Use of onlays of bone or cartilage inserted through an intraoral approach to the canine fossa and the paranasal areas. Even if surgical repositioning of the maxilla or mandible, or both, has achieved satisfactory occlusion, there may be residual flatness of the profile. Here onlays can be of great value.



### CORRECTION OF PROFILE WITH COVER DENTURE

If enough teeth remain, a special cover denture can give support to the lip. Often this will require buccal inlay procedures to facilitate application of the denture with especially overbuilt flanges to alter the profile in specific areas.

### MOVING BOTH MAXILLA AND MANDIBLE

Of course, all the methods described for moving the maxilla and the mandible can be used in simultaneous combinations in an

attempt to achieve satisfactory occlusion and ideal skeletal contour. There are certain specific rules that have been found useful by experience.

When movement of the alveolar processes of both the maxilla and the mandible is indicated, they should be handled at the same operation.

When the entire maxilla and the mandibular alveolar segment are to be moved, they can be advanced simultaneously or the maxilla advanced in the first stage and the lower alveolar segment later.

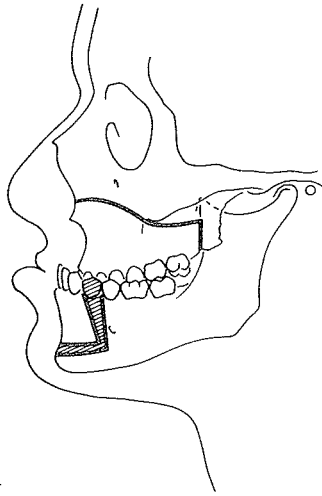
When a maxillary segment and the entire mandible must be moved, the operations can be executed simultaneously. An intact section of maxilla is useful for establishing a good occlusal position and stabilization of the movable mandible.

When the entire maxilla and mandible are to be moved, they can be moved separately or simultaneously.

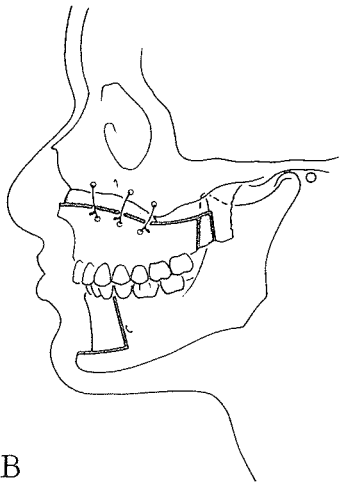
Obwegeser prefers to mobilize both maxilla and mandible and fix them in occlusion with intermaxillary wiring. Then with the teeth locked, the entire maxillary-mandibular unit can be moved en bloc. He did admit:

But it is not easy to decide where the bloc should be positioned in relation to the remainder of the facial skeleton. This is especially difficult because one can move this bloc in all directions.

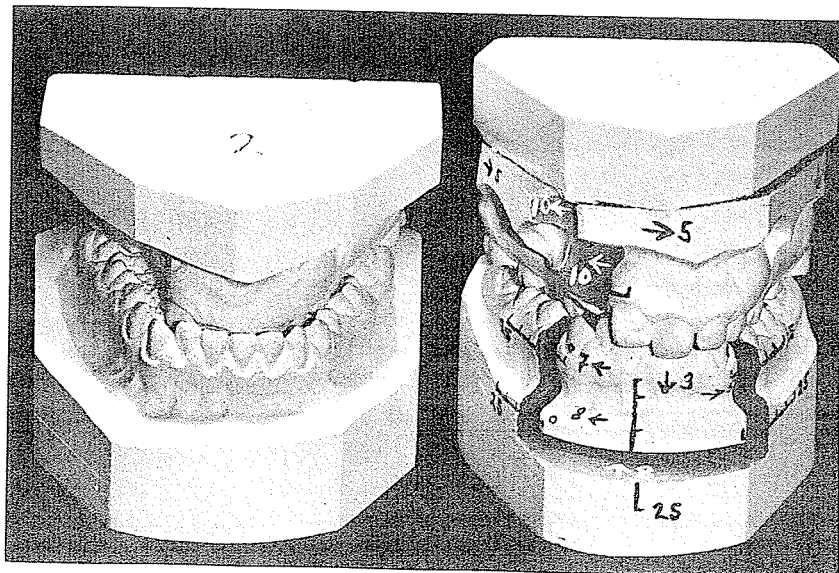
Obwegeser's upper and lower jaw juggling mastery is superbly demonstrated in four of his cases.

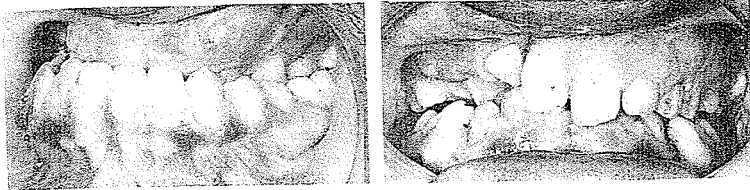


A



B

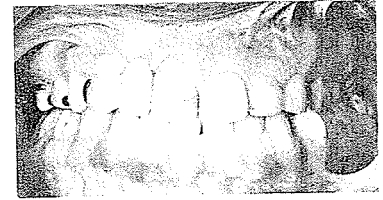



C

D

The first reveals retromaxillism and severe ectropion of the lower lip, corrected by advancement of the maxilla and repositioning of the anterior mandibular alveolar segment (A, B). Models show preoperative occlusal situation and details of planning. (C) shows preoperative circular non-occlusion, (D) occlusion after surgery, and (E) final occlusion with replacement of missing second upper right incisor. (F) shows collapsed



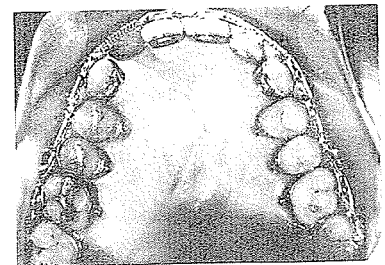
E



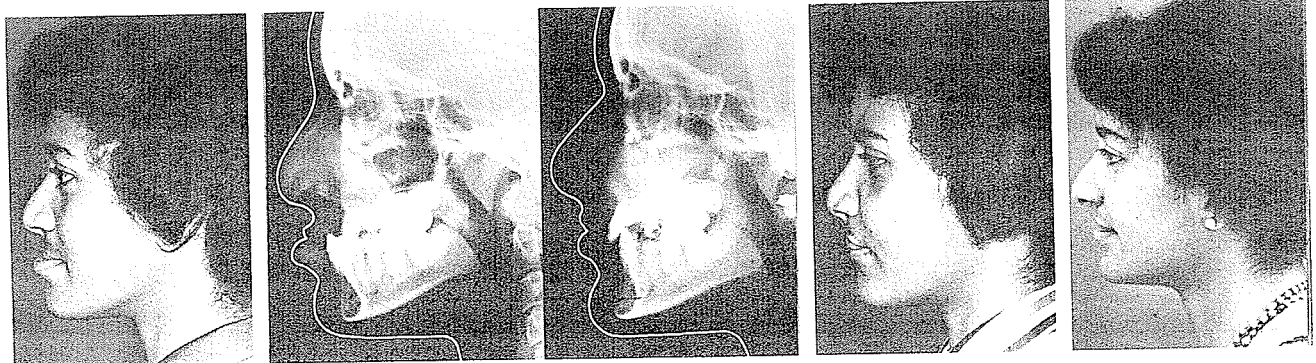
F

G

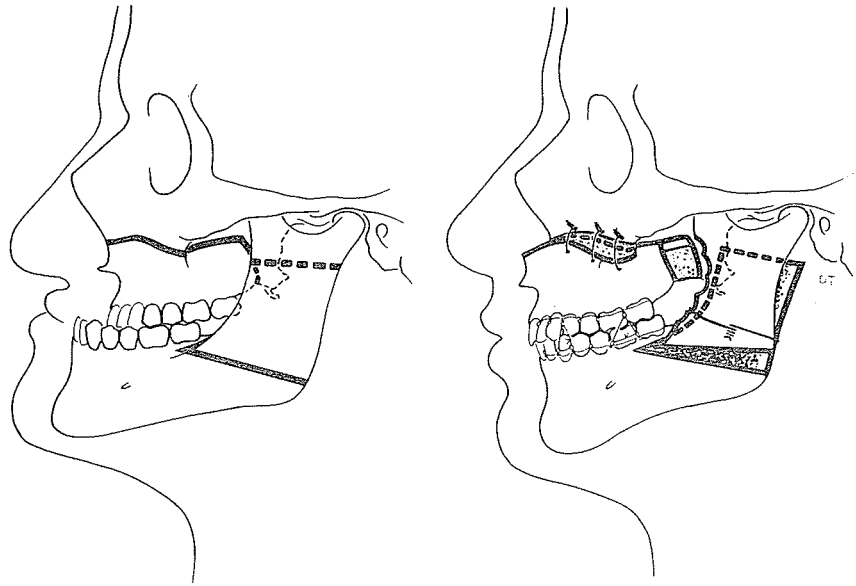
maxillary dental arch before surgery, (G) upper dental arch after advancement of maxilla in 2 sections with reopening of palate cleft, and (H) upper dental arch after orthodontic treatment by P. Stöckli, University Dental School, Zürich. Cephalometric X-rays show before and after bone surgery using homologous deep frozen bank bone. Profiles present before bone surgery, after bone surgery, and after columella elongation using Millard's forked flap.



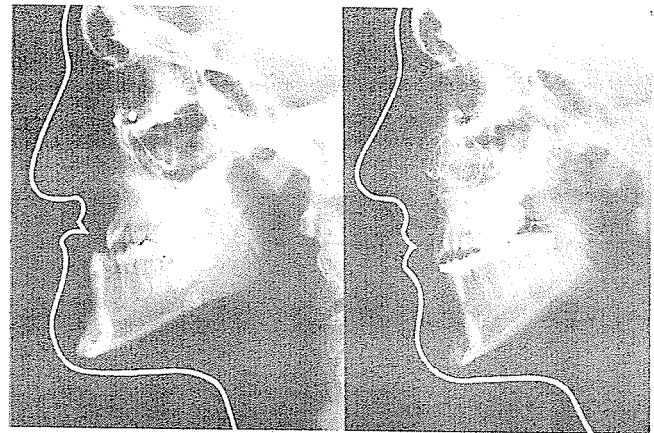
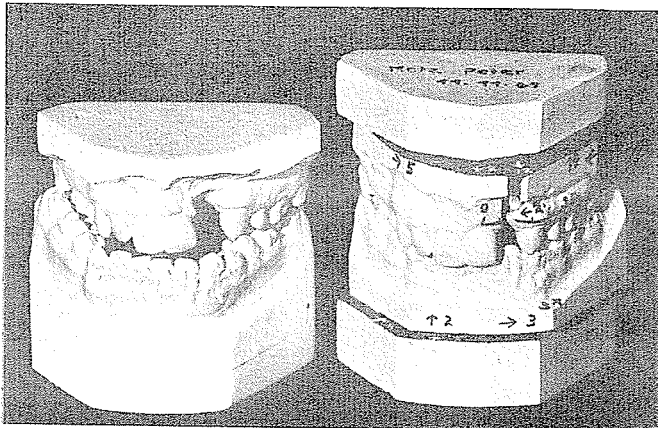
H




This unilateral cleft case with retromaxillism and mandibular prognathism was corrected by Obwegeser and partially published in *Deutsche Zahnärztliche Zeitschrift*, 1973. Surgery involved:



(1) Advancement of maxilla in 2 sections and simultaneous repositioning of the whole mandible using sagittal splitting procedure. (2) Re-operation of palate with bone grafting for closure of remaining cleft fistula. (3) Rhinoplasty for correction of nasal deformity and revision of lip. Models show plan of osteotomies and cephalometric X-rays show progress of surgery.

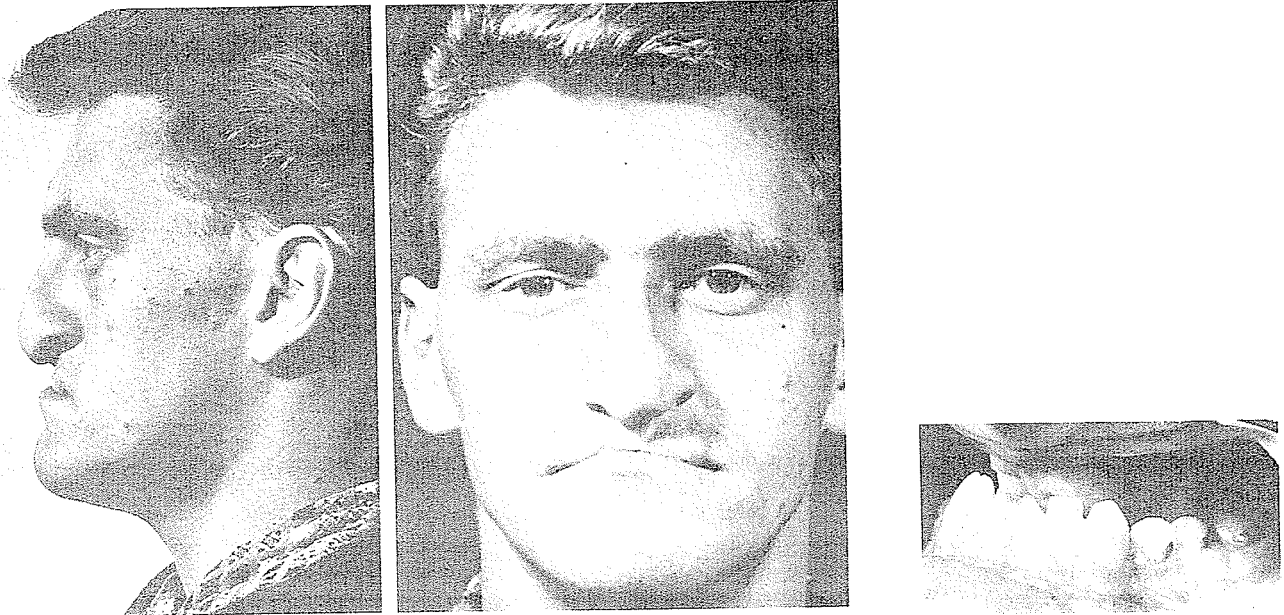


Before




After

This bilateral cleft case with mandibular prognathism and collapsed maxilla with severe nasal deformity was corrected by Obwegeser and presented in the *Transactions* of the Fourth International Congress of Plastic and Reconstructive Surgery, Rome, 1967. The following procedures were used:



(1) Lateral rotation of lateral maxillary segments with reopening of cleft according to Gillies. (2) Closure of reopened cleft with simultaneous bone grafting. (3) Repositioning of premaxilla. (4) Retropositioning of whole mandible using Obwegeser's sagittal splitting procedure. (5) Elongation of columella by Millard's forked flap and simultaneous reoperation of bilateral cleft lip correcting whistle defect without an Abbe flap.

Models (A) show preoperative occlusion and plan of corrective surgery. Also shown are the preoperative circular non-occlusal view (B), the perfect occlusion after repositioning of maxillary



A

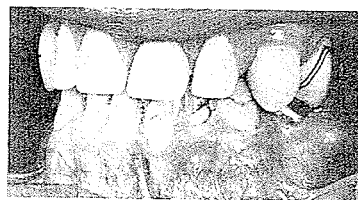
B



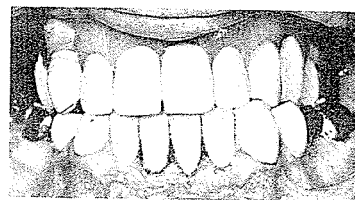
*This is an example where the length of the columella gained, surpassed the artistry of the result achieved.*



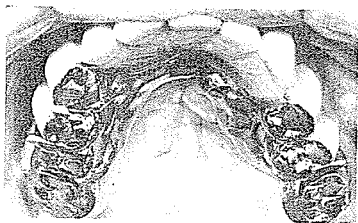segments and mandible (C), the occlusal view after final prosthodontic reconstruction by J. Wirz, University of Zürich (D), and the palate view (E).



C



D



E

This bilateral cleft case with mandibular prognathism, anterior open bite and retrusion of the premaxilla was treated by M. Perko and E. Steinhauser according to planning by Obwegeser.

(1) Mandibular ostectomy through oral route by Obwegeser method.  
 (2) Repositioning the premaxilla, closure of remaining palatal fistulae with simultaneous bone grafting and repositioning of anterior mandibular alveolar segment and (3) revision of bilateral lip scars. (4) Elongation of columella.

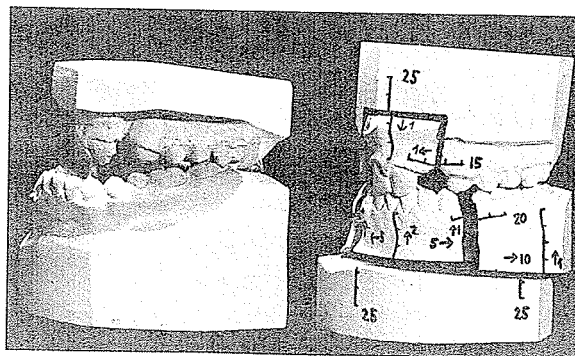
(A) Models show preoperative condition and model-operation for osteotomies presents plan.

(B) preoperative occlusion.

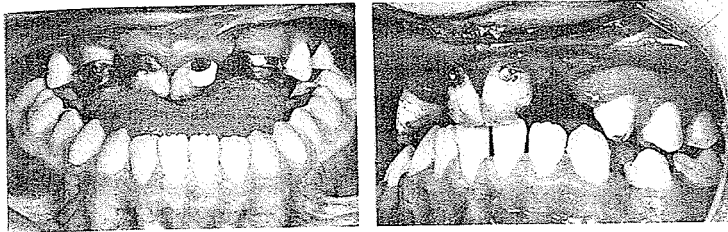
(C) postoperative occlusion.

(D) occlusal view after prosthodontic work by J. Wirz, University of Zürich.

(E) palate view.

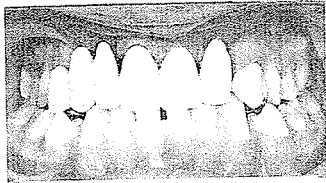


A

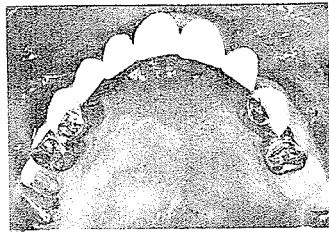


B

C

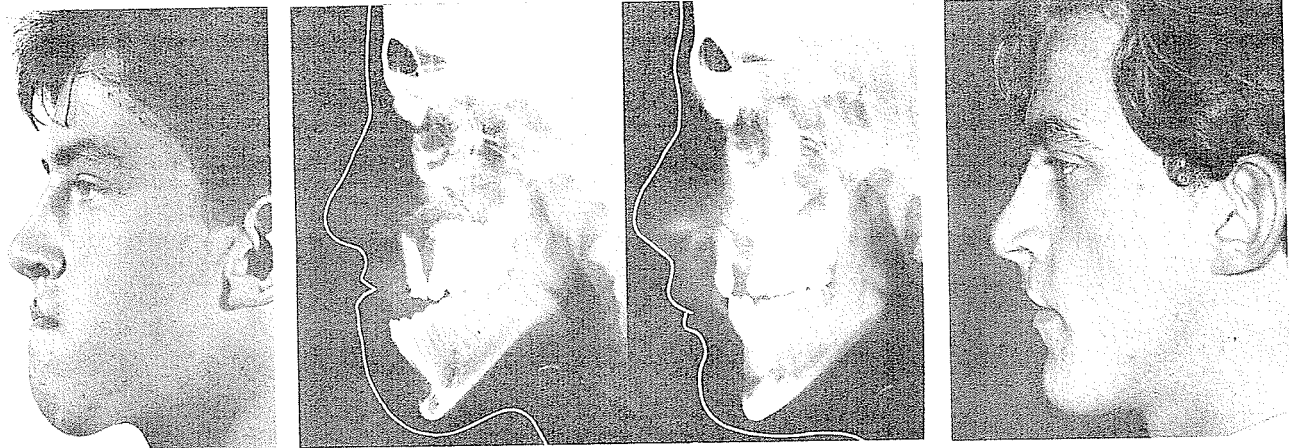

D



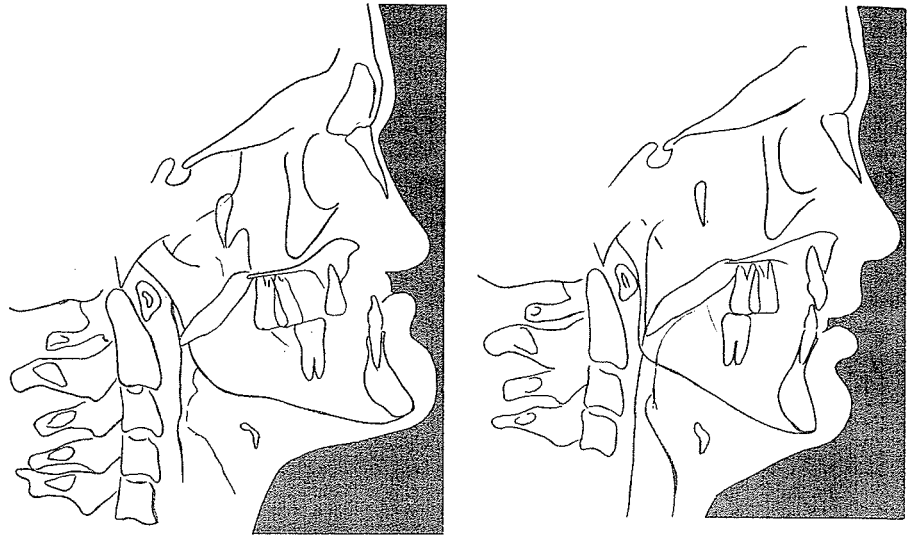
E

Preoperative and postoperative cephalometric views and patient's profiles show the result.



Converse's case of mandibular prognathism combined with maxillary retrusion is a 33-year-old female who had a cleft lip closed at birth and cleft palate closed at 18 months. This was his summary:

At 32 years of age, she underwent a Le Fort  $1\frac{1}{2}$  maxillary advancement of 10 mm. and six months subsequent to this, the correction of malocclusion was finalized by a vertical osteotomy, with an 8 mm. set-back. The combination of these two procedures was necessary in this patient because of the wide occlusal disparity. Included with the photographs are the cephalogram tracings.



### CHANCES OF RELAPSE

Occasionally patients with cleft palate who have had surgical correction of dysgnathia—maxillary and mandibular abnormalities—suffer partial relapse. If the cause of the dysgnathia deformity is still present at the time of the surgery, partial relapse is a possibility. Other factors include the higher tendency for relapse in the growing patient, insufficient bony union and failure to obtain complete mobility of the fragments at the time of repositioning. Obwegeser warned:

Palatally malposed lateral maxillary segments that had been treated by the combined surgical and orthodontic (expansion plate) method [W. Widmaier, 1960] showed a very pronounced tendency to relapse if, at surgery,



the segments had not been made *completely mobile*. In these cases only a tilting, not a true lateral movement, had been achieved. This is similar to the procedure of the forced expansion without osteotomy [H. Derichsweiler, 1955; E. Nordin and B. Johanson, 1955]. This non-surgical forced expansion affects the base of the maxilla very little [L. Rinderer, 1965] . . . . The tendency for relapse is much less if the surgeon places bone along the path of the bone cut. This precaution seems to ensure a better bony union. . . . Defects between the margins of a repositioned segment and its host site do not always become filled by bone automatically; soft tissues may fill in, and these contract, which may result in a dislocation. To obviate this the defects are closed with a bone transplant, which is pressed snugly into the defect. The iliac bone is my choice of donor sites for the bone grafts and the medullary paste. In some cases, however, rib grafts or bone from the chin prominence are used. Occasionally we have also used autologous or homologous frozen bone with good results.

Additionally, after the fixation is removed, a retention denture is inserted. This counteracts the scar contraction in the cleft area. Also, after a secondary osteoplasty for stabilization of the segments, a temporary denture should be provided until the definitive denture or bridge is inserted.

In some cases my co-workers and I have performed the procedures described above in patients aged 10 years and older. We have the impression that there is a higher tendency for relapse in the younger patients' cases than in those patients operated on after the age of 17 years. This seems attributable, in part, to scar formation in the soft tissues; the scar dislocates the segment and interferes with further growth. It seems that even the surgical intervention itself adversely affects growth. However, the number of cases operated upon in youth is too small, and we cannot yet judge definitely whether these operations can be done during the growing period with the same final results as when they are performed when growth is terminated.

In 1977 Hans P. M. Freihofer, Jr., summarized the experience of 100 cases in relation to timing osteotomies of the facial skeleton in adolescence.

1. Generally speaking, osteotomies in adolescence have to be refused before growth has ceased. Exceptions to this rule are very marked functional and psychological indications. In these special cases, however, the patient and his parents have to be told of the likelihood of changes in the post-operative result due to further growth. The necessity of a second later operation cannot be excluded.

2. It is difficult to give a precise age limit for operations because of the variation in time to growth completion. The cases presented, however, show that the 17th year of age is frequently too early. Boys are more at risk in this

respect than girls and cleft patients more than non-cleft patients. We would suggest a rule of thumb, namely, that girls should have reached the age of seventeen and boys the age of 18 at least before osteotomies are performed. As an exception again, we would like to cite those cases for which a series of cephalometric X-rays can be presented proving earlier termination of growth, with a very high degree of probability with respect to accuracy.

3. The main reason for clinically unacceptable results is further forward growth of the mandible. The combination of partial true relapse and further forward growth of the mandible influences the results disastrously. True relapse of the operation alone seems to play a secondary role.

4. The osteotomies have no influence on the growth of the mandible.

5. A negative influence of osteotomies on growth of the maxilla could not be proved. However, several indications are given that it does in fact exist.

6. Comparison with data in the literature proves that particularly in the treatment of Angle class III cases more unfavourable results are obtained in adolescents than in adults. There is thus a danger of true relapse and pseudo-relapse following a repositioning of the mandible, backward displacement of the lower anterior segment, advancement of the whole midface and advancement of the maxilla.

7. Repositioning of the maxillary anterior segment and advancement of the mandible as a whole are the only operations which can be performed without risk before growth is completed. In these groups, results are comparable to those obtained in adults.

8. The treatment of open bite is accompanied by special problems. Residual growth plays a part, but results are also unsatisfactory in adults if certain surgical techniques are applied.

Osteotomy of the premaxilla and its stabilization, on the one hand has to be seen in the context of the complete treatment plan of a cleft patient, and on the other hand has to be considered in the light of the experiences gained in the advancement of the maxilla. To achieve good results in the rotation of the small maxillary segment in cleft patients, operative technique and post-operative treatment have to occur under optimal conditions.

9. Most questions which had to be left totally or partially open, can be answered by specific studies. The most important and difficult problem to be solved is the question of negative influence of osteotomies on maxillary growth.

10. It is to be hoped that the number of osteotomies performed during adolescence will decrease markedly as a consequence of the results presented. Patient and surgeon would therefore be spared the disappointment of failure and further strain of reoperation. However, exceptional cases will always be found in which a special indication is present for surgery during growth. Surgeon and patient must then be aware of the problems involved.

## TEETH VITALITY AFTER SURGERY

In reconstructive dentistry, the vitality of the teeth is an important aspect. Obwegeser's experience is encouraging:

Pulpal injury is rare, even in cases in which the segment has been moved as much as 20 mm. Though the immediate postoperative vitality test is negative, after a time the response becomes positive. This means that within 6 to 9 months, the teeth in a repositioned segment will usually respond positively to the vitality test. The positive response appears earlier in maxillary teeth than in teeth in a mandibular segment.

## EFFECT OF MAXILLARY ADVANCEMENT ON SPEECH


One of the possible side-effects of forward advancement of the maxilla after osteotomy is velopharyngeal incompetence. Pulling the soft palate forward to its attachment to the hard palate may render the velum unable to participate with the pharyngeal wall in the sphincteric action during phonation. If there was minimal contact prior to osteotomy, the effect could be devastating to speech. The risk, however, does not seem to be large, as noted by those who are following maxillary surgery in cleft palate patients.

In 1977 Ralph Bralley and Z. G. Schoeny of the University of Virginia reported a 19-year-old patient with a surgically closed submucosal cleft palate who was evaluated following a Le Fort I osteotomy, to determine the effects of the surgery on his speech. Preoperative and postoperative tape recordings during administration of an articulation test, casual conversation and repetition of standard sentences, along with preoperative and postoperative spectrographic analysis of standard sentences, revealed that *maxillary advancement had no adverse effect on articulation ability or voice in this case*. The authors stated:

However, an unexpected and substantial reduction in the magnitude of the third formant in the postoperative recording was noted. The existence of hypernasality in speech has been shown to be associated with increased magnitude of the third formant (Hattori, Yamoto, and Fujimura, 1958). The observed reduction in magnitude of the third formant may have resulted from an increase in the oral cavity size giving added resonance to lower frequencies. The increase of resonance in the lower frequencies may exert a second-



*Mutaz Habel*



*Joseph McCarthy*



*Kenneth Salyer*

ary benefit to speech and, therefore, deserves consideration in the evaluation of the patient who is being considered for maxillary advancement.

Mutaz B. Habal of the University of South Florida, Tampa, trained by J. Murray in Boston, reported at the Florida Cleft Palate Association meeting in Miami, 1978, that Le Fort I osteotomies had been carried out on a series of 25 secondary cleft palate cases. He noted that all had normal speech preoperatively and none developed velopharyngeal incompetence after maxillary advancement.

In 1979 Joseph G. McCarthy, P. Coccaro, M. Schwartz, D. Wood-Smith and J. Converse noted in reference to velopharyngeal function following maxillary advancement:

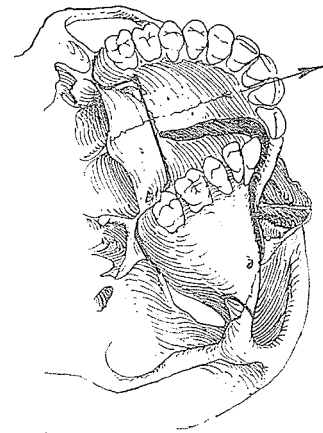
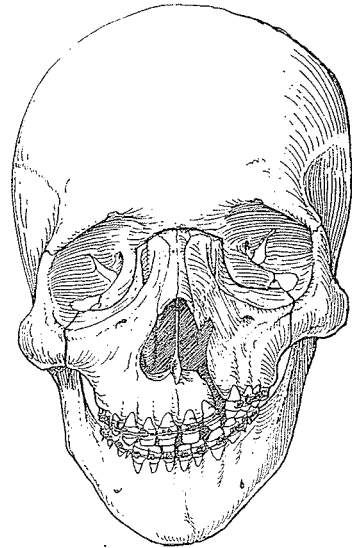
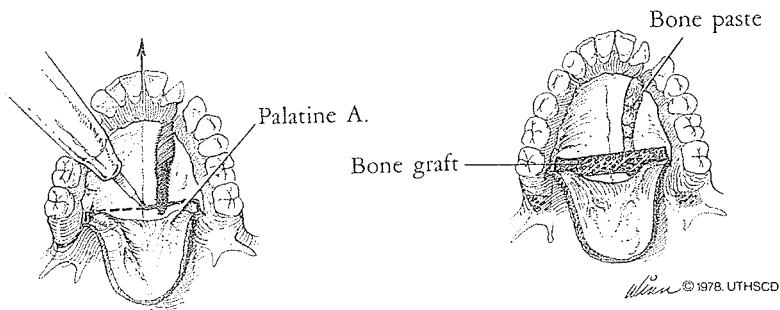
A prospective study of 40 patients, who underwent maxillary advancement, included preoperative and serial postoperative cephalometric analysis, aerodynamic evaluation of velopharyngeal orifice area and Templin-Darley articulation testing. The group was subdivided into those with (11) and those without (29) a cleft palate. Distinct anatomical differences in the velopharyngeal area between the cleft palate and craniofacial dysostosis group was detected. Consequently the cleft palate group is more at risk for the development of postoperative velopharyngeal incompetence. No patient developed hypernasality after maxillary advancement. On cephalometric analysis there was a definite postoperative change in the posture and position of the velum; nasopharyngeal volume was also increased. Hyponasality was eliminated in 4 patients with Crouzon's disorders.

Industrious Kenneth E. Salyer of the University of Texas Southwestern Medical School, Dallas, extensively involved in craniofacial surgery, expressed some thoughts in 1978 on maxillary advancement and velopharyngeal competence:

The Le Fort II maxillary advancement is an excellent procedure in cleft patients as it allows the advancement of the nasal spine and nose as well as augmentation of the hypoplastic maxilla and correction of the occlusal problems to be accomplished in one procedure. In both cleft and non-cleft

patients, it is important to assess the velopharyngeal mechanism as incompetency may result following facial advancement. Contrary to some of the literature on this subject, we have found that patients with adequate touch closure prior to surgery on occasion develop velopharyngeal insufficiency after facial advancement. Correction of this condition with a pharyngeal flap should be postponed until one year following advancement as the pull of the flap can contribute to relapse of the maxillary advancement if performed earlier after facial advancement.

To overcome or circumvent this possible untoward result, we have found it advantageous to utilize a one centimeter osteotomy across the palate just anterior to the edge of the bony palate, leaving the horizontal palatal bones intact in patients where we do not want to alter the existing velopharyngeal anatomy. In Le Fort II advancement, exposure is provided by a mucoperiosteal bilateral palatine flap. This type of surgical approach offers maintenance of the position of the hard palate. Another advantage lies in the



facilitation of advancing the maxilla, particularly in the cleft patient where palatal scarring hinders and makes it difficult to maintain the advanced position of the maxilla. Elimination of tethering of the maxilla is but another advantage to this type of surgical procedure. Due to possible interference with the blood supply of the maxilla, it is not possible to use this approach in a Le Fort I advancement in the cleft patient.

In patients undergoing maxillary advancement subsequent to the insertion of a pharyngeal flap, it is important to advance the pharyngeal flap for length as advocated and performed by Tessier and reported by Whitaker.

This subject is treated in more detail in Chapter 42.