

54. Mandibular Surgery

MANDIBULAR surgery, although not indicated as often as was initially thought, has an important place in the total correction of secondary cleft deformities. The original cleft with its varying degrees of discrepancy and distortion, which occur in addition to the secondary effects of trauma, scar contracture and their retarding influence on early bone growth, places the main surgical problem in the maxilla. Some faces, however, are destined by genes to grow prognathic mandibles. This factor, of course, compounds the problem but also necessitates mandibular corrective surgery. Should genetic destiny produce a retrognathia, although it may blend better with the hypoplastic maxilla of the cleft deformity, the end result is a deficient face which might conceivably deserve both maxillary and mandibular correction.

Not surprisingly, some of the great maxillofacial centers of the world that have contributed to the treatment of mandibular prognathism have been located in the Hapsburg belt. As pointed out by Grabb, Hodge, Dingman and Oneal in 1968 in *Plastic and Reconstructive Surgery*, Charles V was the first of the Hapsburgs to rule Spain. His portraits show a severe mandibular prognathism with Angle class III malocclusion. Historian Rhea Marsh Smith wrote that Charles' protruding lower jaw caused his mouth to hang open and gave him the appearance of an imbecile. It is reported that when Charles first came to Spain from Ghent, a Spanish peasant shouted to him:

Your Majesty, shut your mouth, the flies of this country are very insolent!

Genetic studies of the Hapsburg family have shown that their facial characteristics were transmitted as a single dominant trait.



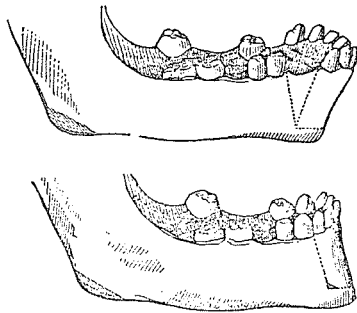
The genetic inheritance was practically assured by the family tradition of close intermarriage as a means of preserving the house of Hapsburg. Charles and his relatives suffered from realistic artists of their day, who painted what they saw without regard for flattering their subjects. Since members of royalty were painted frequently, it was possible to trace the effect of aging on their faces—beautiful and delicately featured children acquired the grossly distorted features of the Hapsburgs by the mid-teens, more pronounced with each passing year.

Mandibular prognathism is not always transmitted by a single dominant gene, as shown by Schulze and Weise, who found transmission by an irregularly dominant mode of inheritance with variable penetrance.

TIMING OF SURGERY

In 1971 R. O. Dingman and T. G. Dodenhoff of the University of Michigan stated:

Operations should be deferred until patients have attained practically full mandibular development. In females this occurs by 18 years of age and in males usually by the age of 20. Growth may be considered complete when identical cephalometric X-ray studies, taken at 6-month intervals, can be superimposed exactly. Growth after age 20 is uncommon. Earlier operation may be indicated in patients with severe deformities and a serious psychological reaction to their deformity. The best results from osteoplastic operations upon the mandible are noted in the young adult age group. Patients beyond the age of 40 may have slow or incomplete healing as a complication.



MANDIBULAR BODY OSTECTOMY

In 1848 Simon P. Hullihen of Wheeling, West Virginia, was faced with a 20-year-old patient who had an elongation of the mandible caused by a burn contracture of the lower lip and neck, present since the age of 5 years. Hullihen carried out a V-shaped osteotomy of the anterior body of the mandible bilaterally, which allowed the distal portion to be moved back into its proper position.

In 1896 Edward H. Angle advised bilateral resection of the mandible through the entire body for a patient with a progressive type of prognathism. This patient, however, came under the care of Vilray P. Blair of St. Louis, who resected a quadrilateral section from either side of the jaw, brought the teeth in occlusion, wired them in place, but had difficulty holding the jaw fragments in occlusion.

In 1907 Blair discussed his mandibular osteotomy:

This operation presents three distinct problems: 1. the cutting of the bone, which is the easiest of the three; 2. the placing of the jaw in its new position; and 3. holding it there.

Blair discounted the seriousness of injury to the nerve:

We need not concern ourselves with the consequences of cutting the inferior alveolar nerve and artery. Normal sensation eventually returns to the teeth after their section.

Blair wrote in 1915:

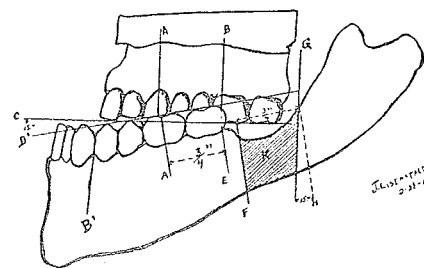
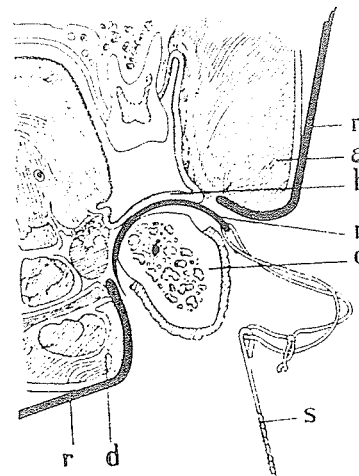
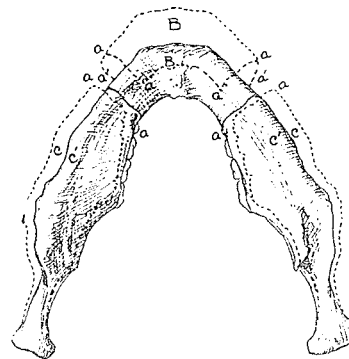
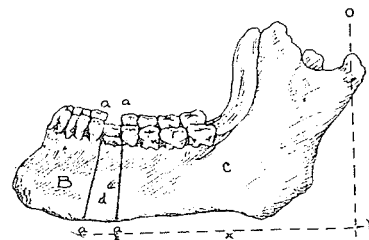
Before operating upon my first case of mandibular protrusion, I carefully considered the best site of attack. It would be a natural procedure for a simple forward position of the body of the mandible to make a cut in the ramus and push the jaw back to its proper relationship, but the fear of crowding the retroramal structures and thus possibly to interfere with free opening, decided me to remove a section from the body itself.

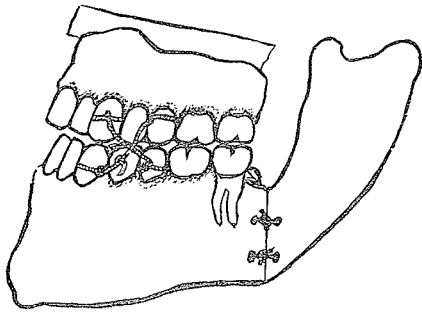
This operation was first done by Blair in 1907:

The result was obtained not only by taking out a section of bone on each side and setting back the mental piece, but the premolar teeth had to be crowned to bring them into occlusion.

To avoid opening into the mouth and the infection that invariably followed, Blair developed the subperiosteal osteotomy, passing a needle around the mandible carrying a wire saw which he used to divide the bone.

This approach was advocated later by C. Henschen and R. Schwarz in 1928-1929 and V. H. Kazanjian at Harvard in 1941. The refinements of the method were introduced in 1912 by W. Harscha and J. Eisenstaedt, independently of each other and both in *Surgery, Gynecology and Obstetrics*. They described short-

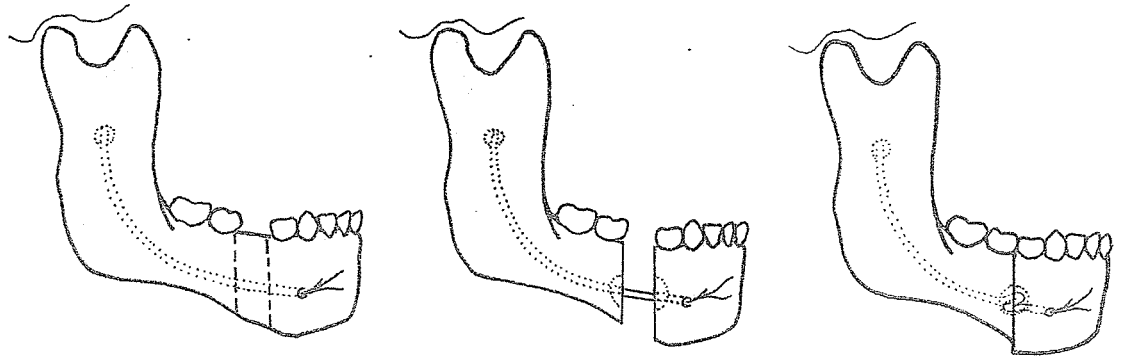




ening the horizontal ramus through a $2\frac{1}{2}$ inch incision beneath the border of the mandible. Subperiosteal saw resection of the determined amount of bone, without entering the mouth, was followed by wire sutures to the bone and immobilization with interdental wiring.


In 1941 Gordon New and John Erich of the Mayo Clinic, Rochester, Minnesota, reviewed the various methods of treating mandibular prognathism. They expressed preference for

bilateral resection of a segment of the mandible in the bicuspid or first molar regions. . .



and described division of the segment of the mandible with a motor-driven circular saw from below up, near the mandibular canal, and from above down near the canal with a Gigli saw. Then the bone was chipped out with a chisel, leaving a small amount around the nerve and vessels which was carefully picked off with a rongeur. They were more concerned about the nerve than infection from suturing the oral cavity, exclaiming:

Many surgeons consider severance of the mandibular nerve to be of little consequence, but those of our patients who had the mandibular nerve cut complained bitterly of subsequent numbness, and in some instances, normal sensation in the lower lip never was regained entirely.



Reed Dingman

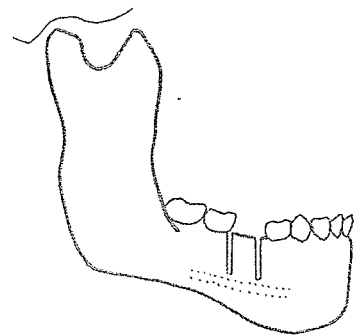
Reed O. Dingman of the University of Michigan, Ann Arbor, while an undergraduate at Wayne State University, served one summer as the boxing and wrestling coach at a boys' camp in northern Michigan. He soon made friends with one of the other counselors, Freddie. When this young entrepreneur discovered that Dingman, besides playing football, was a middleweight on the university boxing team, he conned him into taking on all comers at the Saturday night fights in the small lumber mill

towns. At \$50 an appearance plus side bets, Dingman fared well until matched against the promising local champion, a lumberjack. After six tough rounds, a loss by a close decision and a look in the mirror at his bruised face and fractured nose, he decided to bypass the prize ring and proceeded to get his dental and medical degrees.

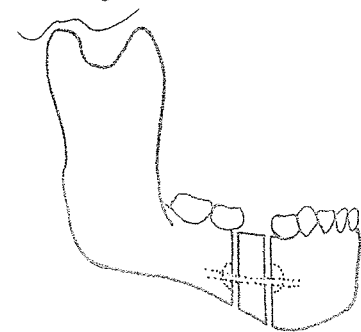
His firsthand knowledge of giving and receiving jaw trauma especially prepared him to pioneer the specialty of jaw surgery. In 1944 he described a two-stage procedure for correction of mandibular prognathism which removed bone of the horizontal ramus without interfering with the inferior alveolar nerve and its associated structures. In his first stage, under local anesthesia, through an incision along the crest of the alveolar ridge, the mucoperiosteum was elevated on the buccal and lingual surfaces. This maneuver allowed a resection on each side of the mandible with a bone drill, usually in the second molar region, the desired amount for removal being predetermined by the orthodontist. The saw cuts were not carried down to the nerve but extended on the outer surface of the mandible as a guide for the second stage. If necessary, a tooth in this area was extracted, but the bone was retained and the mucoperiosteum closed to seal off the oral side. Four to six weeks later, the second stage, usually under local anesthesia, was carried out through bilateral incisions parallel to and 1 cm. below the inferior border of the mandible in the area marked for resection. Subperiosteal resection of the bone block with drill and chisel, taking great care to stay clear of the mandibular nerve, was followed by removal of the medullary bone surrounding the nerve, including a hollowing out around the nerve to provide a safe resting place for excess nerve when the mandible was shortened. The bone fragments were approximated with 27-gauge stainless steel wire, and the orthodontic appliances, with the teeth held in occlusion, were secured by intermaxillary rubber band fixation. After several weeks, the bands were replaced by stainless steel wire.

In 1960 Dingman called attention to the possible use of his mandibular ostectomy in secondary cleft deformities:

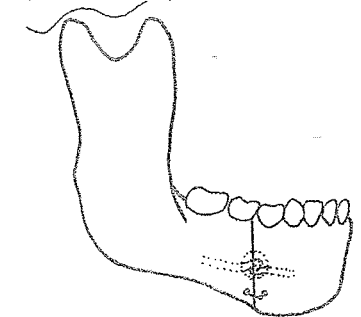
A patient with underdevelopment of the middle third of the face and a normal mandible may give the appearance of having a prognathic jaw. Ostectomy of the mandible may be helpful in such cases.



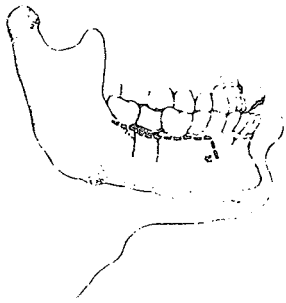
First Stage: Intra-oral



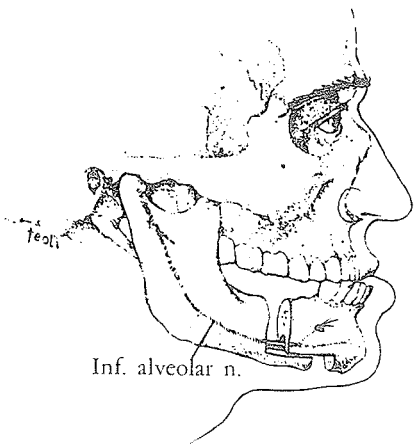
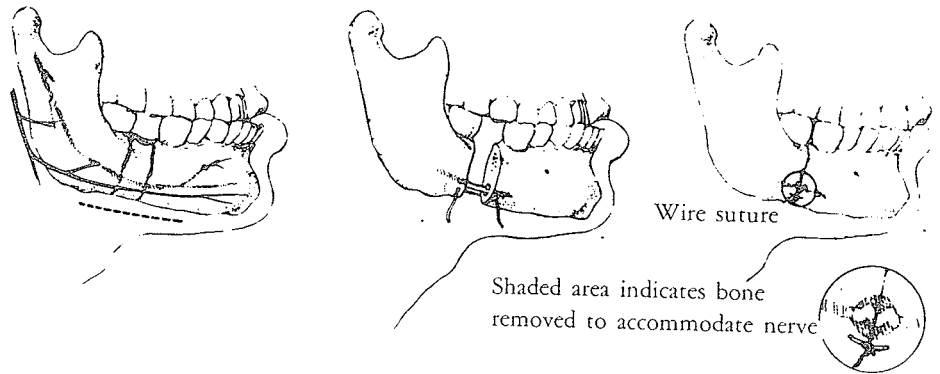
Second stage: Extra-oral
(4 weeks later)



Second stage
(Completed position)

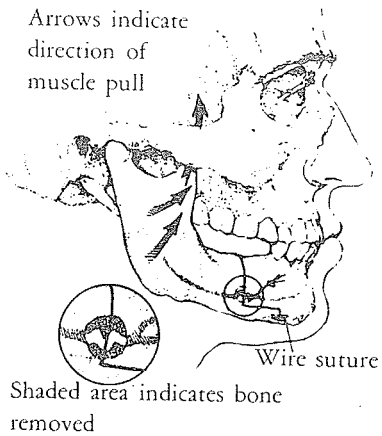


After 14 years' experience of 95 cases, Dingman had reduced the operation to *one* stage, carrying out the intraoral portion exactly as previously described and closing this wound. Then, at the same time, he entered through the skin and carried out the previously described second stage, following it with the same fixation. In *Plastic and Reconstructive Surgery* he presented his one-stage ostectomy procedure:



He also presented a favorable step ostectomy for the patient with an edentulous posterior mandible.

In 1971 Dingman and Dodenhoff noted the advantages and disadvantages of the ostectomy of the mandibular body:



Advantages: (1) accessibility of the operative field, (2) the section of bone can be removed without injury to the inferior alveolar neurovascular structures, (3) the operation does not interfere with the physiological action of the muscles of mastication, (4) the fragments can be positioned and secured accurately and firmly, (5) a dental splint can be used to hold the fragments in place after only a short period (4 to 6 weeks) of immobilization, (6) open bite is less likely, and (7) good cosmetic results are usual. Its disadvantages are: (1) removal of bone, (2) removal of functional teeth, (3) not as applicable in extreme cases of prognathism, (4) the obtuse mandibular angle is not corrected, (5) if more than one tooth is removed on each side, the disparity in arch size makes bony appositional surface less than optimal, (6) if a gap of more than 2 or 3 mm. exists, the possibility of nonunion is present, and (7) the depressor group of muscles may cause open bite. . . .

. . . We believe the advantages far outweigh the disadvantages. We have corrected a deformity as large as 27 mm., and we do not feel limited in severe cases.

POSTOPERATIVE CARE

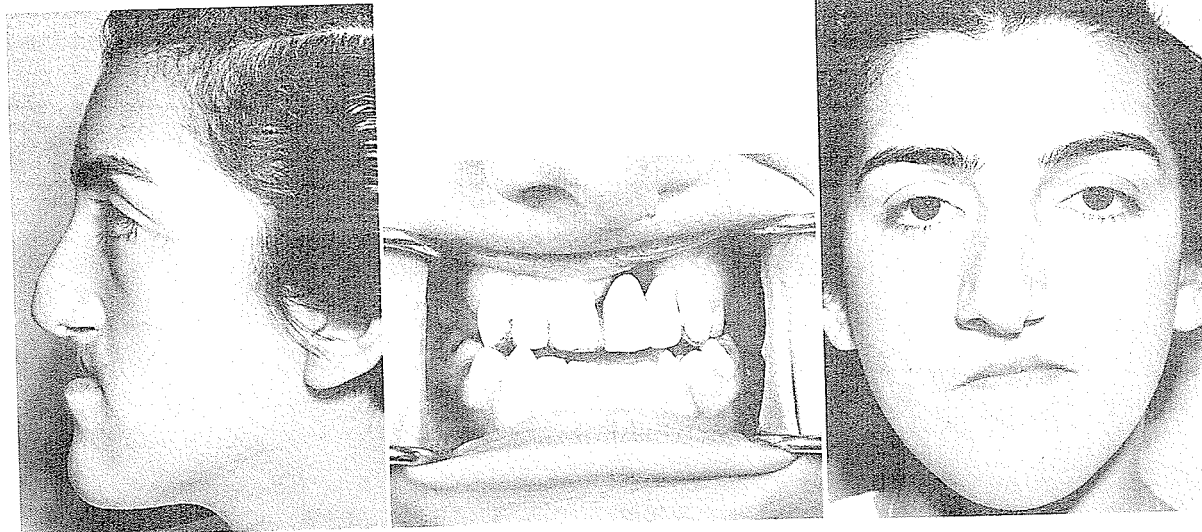
The ostectomy site is wired with a No. 24 stainless steel wire through drill holes in the bone. Intermaxillary fixation with

rubber bands initially will, by one week, have settled the lower jaw into optimal occlusal relationship. This allows replacement with stainless steel wire which will be maintained about six weeks.

Dingman's postoperative regimen is practical. The patient is placed on a high-protein, high-vitamin liquid diet and is usually discharged from the hospital on the second to fourth postoperative day. Oral hygiene is facilitated by the use of a small toothbrush or water pick and mouthwash irrigations every four hours.

Here are two of Dingman's cases, with Ponitz as the orthodontist.

1. South American teenage girl, who had unilateral lip and palate cleft closed in infancy in New York, revealed a tight lip, typical nasal deformity, scarred palate with contracted maxilla, and class III malocclusion when first seen by Dingman in 1955.




1955

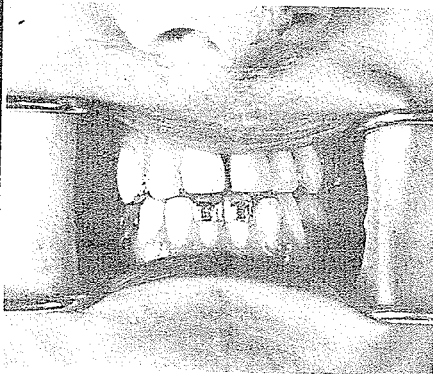
In 1957, lip revision, pharyngeal flap and rhinoplasty were performed, followed in 1959 by Dingman's one-stage bilateral mandibular ostectomy.

Intraoral: Flaps elevated from cuspid area of the mandible on both sides, first permanent molars removed, parallel bone cuts 7 mm. apart allowed removal of upper portion of bone and intraoral wounds closed. Extraoral: Skin incision $1\frac{1}{2}$ cm. parallel with and below the angle of inferior border of mandible allowed exposure for continued resection of inferior mandible 9 mm. wide, salvaging the inferior alveolar nerves. The fragments were fixed

with #25 stainless steel wire and the teeth brought into occlusion with rubber band traction. Six weeks later, unilateral rotation of the cleft nostril with alar lift improved nasal symmetry.



1959 After osteotomy but before alar lift


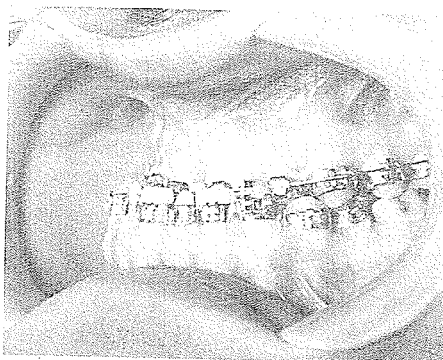


After alar lift

2. This 13-year-old boy had his unilateral cleft lip closed at 1 month and palate cleft closed in two stages at 18 and 24 months by oral surgeon Kemper at University Hospital, Ann Arbor. When seen by Dingman in 1960, he revealed velopharyngeal incompetence and class III malocclusion.



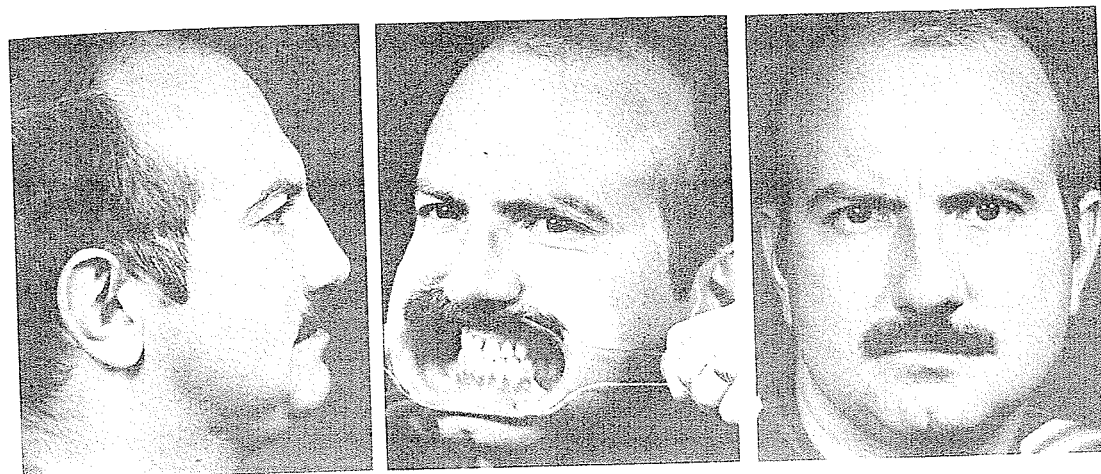
1960



1965



He had a setback palatoplasty and a pharyngeal flap and, at age 18 in 1965, a Dingman one-stage osteotomy resecting 1 cm. at the superior mandibular border and 1.5 cm. at the inferior border on the right, and 1 cm. superiorly and inferiorly on the left. The inferior alveolar nerve was preserved and the bone hollowed out to bed the excess nerve. Fixation was the same as in the previous case.



1977

In 1977 Dingman acknowledged that in the past mandibles had been moved back when in fact maxillae should have been moved forward. He noted, however:

I think there are still some cases that have reasonably good maxillary development, with a true prognathic mandible deserving osteotomy.

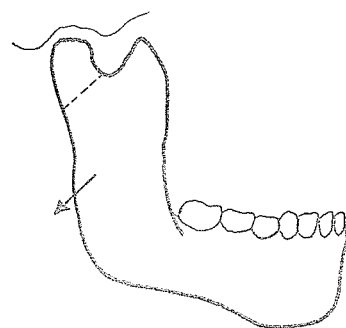
SUBCONDYLAR OSTEOTOMY


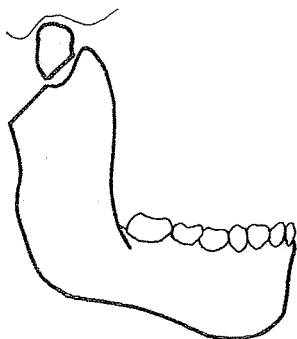
In 1897 Berger resected the mandibular condyles to treat prognathism. In 1898 M. Jaboulay and L. Berard reported their method of subcondylar osteotomy.

In 1921 Leon Dufourmentel of Paris, one of the early pioneers of plastic surgery, advocated condylectomy and mandibular repositioning for prognathism. During my 1948 peregrinations as a plastic surgery student, I had the pleasure of dining with the senior Dufourmentels in their luxurious apartment, and at one time they had five different wineglasses at my place. It was impossible to lift one without striking another, and my side of the table began to sound like noon chimes in Notre Dame.



Leon Dufourmentel





Francis Kostečka

Leon Dufourmentel was chief of l'Hôpital Saint-Louis and did his mandibular work there. Today his equally famous son, Claude, is chief of this same hospital. It is 400 years old, having been set up by King Louis XIV as a stopover first aid station for him and his court on their way back to Versailles in case of accidents during hunting trips.

Francis Kostečka of Czechoslovakia was another contributor to mandibular surgery. Born in South Bohemia, trained in general surgery and specializing in stomatological surgery, he traveled to most of the important oral surgical centers in the world, including Vienna, Berlin, Geneva, Paris and London, with three months in Chicago with Brophy, studying cleft surgery. He returned to Prague to head the stomatological clinic at Charles University, and in 1926 at the Eighth International Stomatological Congress in Philadelphia, he presented his surgical treatment of prognathism. In 1931 Kostečka simplified the subcondylar osteotomy by the use of the Gigli saw. This method became known as the Kostečka osteotomy and enjoyed some popularity.

Dingman's evaluation of this procedure is of interest:

A fascial interposition prevented union and resulted in a false joint. Destruction of the temporomandibular joints plus the abnormal pull of the pterygoid muscles makes this an undesirable procedure.

EARLY CONDYLECTOMY

In 1976 dentist Edmond A. Adler of West Perth, Australia, published a paper on "Early Condylectomy to Prevent Prognathism" in the *Journal of Oral Surgery*. It described how, through a standard endaural incision, stripping of the lower head of the lateral pterygoid muscle from its mandibular insertion and section of the condyloid process at the junction of the head with the neck were accomplished. Adler noted:

Bilateral condylectomy in young patients brings about cessation of anteroposterior growth of the mandible. If the condyles reform before body growth is complete, anteroposterior growth of the mandible recurs. Preliminary observations indicate that the procedure, used in ten young patients, reduces or prevents mandibular prognathism.

The *Journal* editor warned:

One must be careful in drawing a positive conclusion about the effectiveness of such a procedure from the current series of cases, since six of the ten patients were children with cleft palate and the correction involved adjusting a normal mandible to a retrusive maxilla, rather than the treatment of true prognathism.

In 1977 Harold K. McComb, also of West Perth, who cooperated in the surgery, added:

We have been halting mandibular growth in some of our cleft lip and palate patients if and when cephalometric studies show that their mandibles have already reached adult size, and that they are heading for an absolute, as well as a relative mandibular prognathism.

This has proved to be a very simple and effective way of forestalling gross malocclusion, and particularly for avoiding the traumatic effects of disfigurement during adolescence.

HORIZONTAL OSTEOTOMY OF THE ASCENDING RAMUS

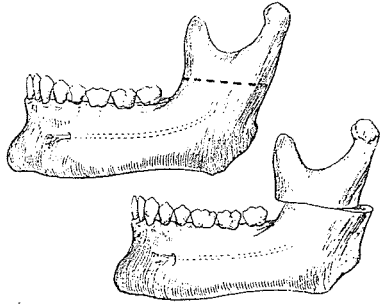
In 1907 Vilray P. Blair of St. Louis first described division of the ramus of the mandible and shifting of the body of the bone backward. Blair, as evidenced by the many surgical innovations noted throughout *Cleft Craft*, was one of the pioneering geniuses of plastic surgery. He enjoyed the fringe benefits of genius, paying little attention to material things as long as they served their purpose, carrying out everyday necessities with varying degrees of rapidity while thinking of more important things and not always concerned with technique per se. A few lines from a 1972 letter from Blair's talented artist, Gertrude Hance, which accompanied her portrait of him, are pertinent:

Dr. Blair was driving a very old, dilapidated Pierce Arrow, faded to what I called pink. We went to Jefferson Barracks several times a week and he was the world's worst driver.

In 1913 and 1915, Blair reported more on his horizontal osteotomy of the mandibular ramus, carried out percutaneously with a Gigli saw. A Blair needle was passed anteriorly from the



Vilray Blair

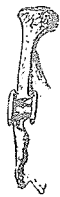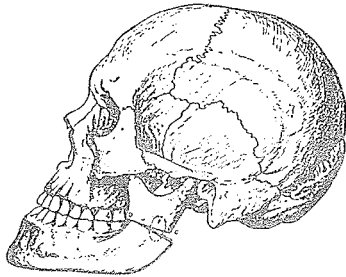
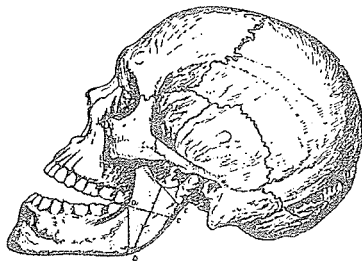


Sketch by Hodge

posteromedial border on the medial surface of the mandible and out through the soft tissues of the cheek anterior to the mandible. The Gigli wire saw was passed through and the ramus sectioned horizontally between the inferior alveolar foramen and the notch, allowing the body to be moved posteriorly.

As early as 1909, W. Wayne Babcock of Philadelphia noted:

An ingenious method has been suggested by Dr. V. P. Blair, who makes a vertical incision one half inch in length posterior to the ramus, through which a heavy needle is passed into the incision behind the ramus, and then brought out through the cheek. By means of the needle, a Gigli saw is pulled through the tissues. A small metal tube is slipped over the saw through the puncture in the cheek so as to prevent lacerations of the face, then by simply pulling the saw backward and forward the ramus is divided.



Babcock then presented his own operation, using

a skin incision over the posterior border of the ramus of the jaw from zygoma to a point under and anterior to the angle of the jaw. . . . The outer fibers of the masseter muscle were separated and the external surface of the middle of the ramus exposed. With a small chisel a transverse section was then made through the ramus. The operation was repeated on the other side, and the body of the jaw then forced back, and the teeth placed in the best possible occlusion. . . . Certain of the lower teeth were wired to the upper.

In the illustrations of his osteotomy, Babcock presented an ivory or metallic button to fix the fragments. He also defended his external skin incisions as opposed to Blair's "scarless" Gigli saw osteotomy:

The Gigli saw, as used by Blair . . . is very ingenious. . . . In my operation it was my desire to see the ramus. I wished to see how the fragments looked after the reduction, and I wished to use wedges also.

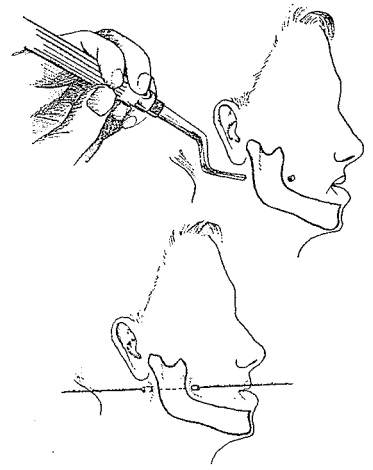
In Sweden, Allan Ragnell of Stockholm, in 1938, and K. E. Hogeman of Malmö, in 1951, performed horizontal sectioning by means of a saw introduced through a postauricular incision, temporarily severing the external auditory canal in order to obtain a more adequate approach to the ramus.

In 1950 J. Barrett Brown, with Minot Fryer and J. B. Templeton, noted:

There are, however, some late deformities in patients with cleft lips and palates that show such disproportion as to appear prognathic, and to have occlusions that are not adequate for mastication. When these patients are too old, or otherwise not suited for orthodontic expansion of the upper arch, then the lower jaw can be recessed to proper proportion with the upper, so that an external balance of appearance is obtained.

He advocated the horizontal osteotomy operation Blair described in 1907, with minor refinements.

In 1954 V. H. Kazanjian of the Massachusetts Eye and Ear Infirmary, Harvard University, recommended a beveled cut with the chisel, sectioning the ramus obliquely from below through an external approach. This method increased the surface of contact between the bony fragments and decreased the tendency for separation of the fragments brought about by the pull of the lateral pterygoid muscle. The lovely drawings of this method for Converse were done by the famous artist Daisy Stilwell.



Varaztad Kazanjian



Dingman evaluated the advantages and disadvantages of the horizontal osteotomy of the ramus:


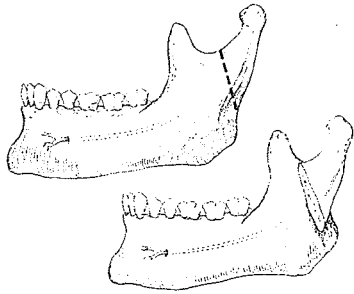
It is short and simple, no scar is involved, a good cosmetic result can be achieved, and there is no sacrifice of bone or teeth and no disturbance of the mandibular arch. The disadvantages, which may be serious, are: injuries to the facial nerve, to the internal maxillary artery with severe hemorrhage, to the parotid gland and to the mandibular nerve because of the blind approach. The failure rate is high due to lack of control of the proximal fragment. The strong pull of the lateral pterygoid and temporalis muscles may cause displacement or overriding and eventual nonunion or malunion. The thin cortical bone in this area contributes to poor healing. The strong muscles of mastication are positioned out of functional alignment, and with spasm, there is shortening and overriding of the fragments. With the molar teeth in occlusion, the resulting Class One lever forces the anterior teeth

into an open-bite position. These muscles are so powerful that the anterior teeth may be extruded from the maxilla or mandible regardless of the type of appliance or intermaxillary fixation used.

OBLIQUE SUBCONDYLAR OSTEOTOMY

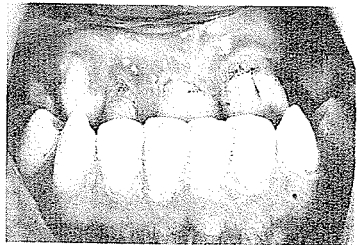
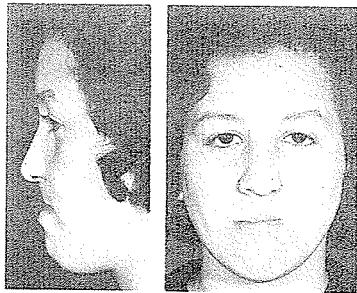In 1967 Edward C. Hinds and W. Girotti of Houston, Texas, advocated the oblique subcondylar osteotomy of the mandible through an external incision. They have had good results over a large series. Also in 1967, M. Robinson, simultaneously with Hinds, published a similar method of extraoral section of the ramus from a point behind the gonial angle to the sigmoid notch. The chief advantage of these procedures was simplicity, which has been responsible for much popularity of the principle.

Hinds and I have been friends since my residency days in Houston in 1951. He has continued his work in the Dental Branch of the Texas Medical Center, and his only true escape from jaws has been his snowmobile in northern Minnesota. I wrote him for an example of a cleft palate case in which he had used his oblique subcondylar osteotomy. He kindly forwarded this case, noting:

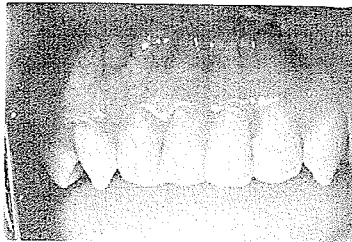
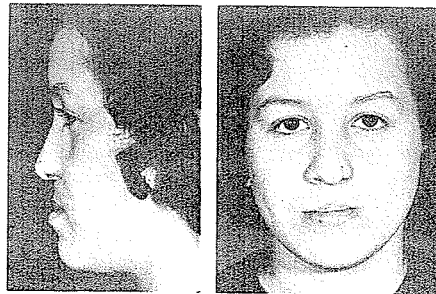

Edward Hinds

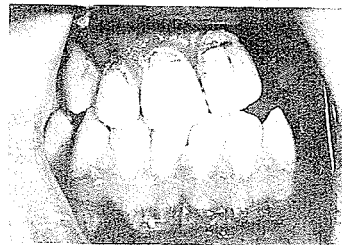
This young lady was a 15-year-old Latin American with a history of operated cleft lip and cleft palate. She was wearing a maxillary plumper to hold the upper lip out. A bilateral subcondylar osteotomy was performed on March 12, 1962. No direct wiring of the fragments was performed in accordance with my policy in management of prognathism by this procedure. In most



Preoperative



With labial plumper



Postoperative

other osteotomies I do use direct wiring. We felt that setting the mandible back would give her much more acceptable facial appearance and certainly better oral hygiene. At that time, as you know, we were not involved in maxillary surgery to any significant degree.


In 1961 in *Plastic and Reconstructive Surgery*, Nicholas G. Georgiade, with Galen W. Quinn, of Duke University evaluated the reported satisfactory results of Hinds and Robinson, with variations of vertical osteotomies through the ramus of the mandible, and then modified the procedure, commenting:

The use of a vertical osteotomy that extends from the coronoid notch down to the angle of the mandible, rather than a short osteotomy high on the condylar area, we feel, has many advantages and practically none of the disadvantages of the older procedures. . . . Splinting of the bony fragments after section of the muscles of mastication, we feel, aids considerably in their eventual rapid healing of the osteotomy sites. Treatment postoperatively by means of intermaxillary wiring and fixation is all that has been found to be necessary for satisfactory stabilization of the mandible.

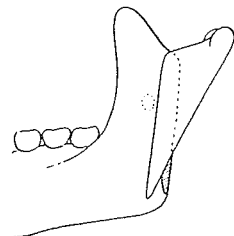
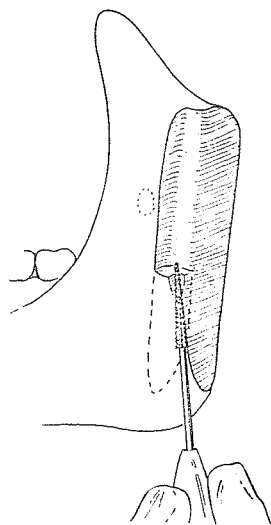
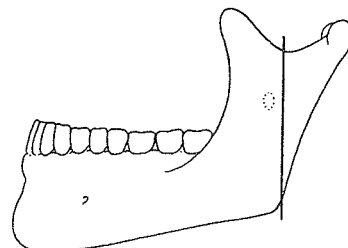
One of their representative cases was a patient with a severe maxillomandibular disproportion due to cleft palate and associated retardation of maxillary growth. The modified sliding angular ramus osteotomy improved the relationships. They noted the importance of preoperative cephalometric studies and preoperative equilibration. The advantages of their modifications are italicized. A *short* procedure in *one* stage under *direct* visualization through *small* submandibular incisions, with the line of sectioning from the coronoid notch to the angle of the mandible always proximal to the inferior alveolar nerve and vessels, avoided any damage to these structures.

J. B. Caldwell pointed out, however, that these techniques were not applicable in moderate or severe cases of prognathism because the temporalis insertion on the coronoid process prohibits retrodisplacement of the anterior fragment more than 10 to 12 mm. This difficulty may be partially overcome by transection of the coronoid process of the mandible.

Open bite, non-union or malunion, and the long period of immobilization required are disadvantages, according to Dingman.



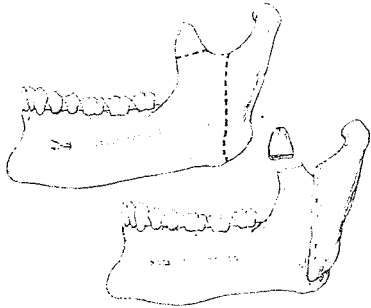
Galen Quinn



VERTICAL OSTEOTOMY OF THE ASCENDING RAMUS



Gordon Letterman



Jack Caldwell

Army oral surgeon Jack B. Caldwell served at Walter Reed General Hospital in Washington, D.C., prior to transfer to Letterman General Hospital, San Francisco. While in Washington he collaborated with Gordon S. Letterman, son of the Letterman of the Army Hospital, who had trained in plastic surgery under Blair. In 1954 Caldwell and Letterman introduced vertical osteotomy of the ascending ramus. Through a submandibular incision which allowed elevation of the masseter muscle with the periosteum, the entire lateral surfaces of the ramus from the sigmoid notch to the inferior border of the mandible were exposed. The outer cortex was perforated with a dental drill and the ramus sectioned vertically from the sigmoid notch to a point 1 cm. in front of the angle of the mandible, posterior to the mandibular foramen. The coronoid process was sectioned to release the pull of the temporalis muscle. The outer cortex of the anterior fragment was removed by osteotomy with a dental bur, and the anterior fragment was placed posteriorly, residing on the medial side of the posterior fragment. The teeth were then held in occlusion with intermaxillary fixation.

In 1977 Caldwell, now of Denver, recalled the patient and circumstance that prompted the development of this method:

A young staff sergeant had been reduced to the rank of corporal within 6 months. Investigation revealed he was extremely concerned about his appearance due to acceleration in the growth of his mandible, which caused such deterioration that he was found drunk on duty. After a period of observation of the patient and the arrival of a Broadbent cephalometer along with orthodontist E. P. Suchard, a protégé of Broadbent, we came up with the idea of a vertical section in the ramus to correct this growth deformity in this patient, who had a protrusion of slightly over two centimeters with a tendency to open bite anteriorly. I had been unable to figure out how to treat him with methods known to us at that time. Faced with this dilemma, we made cut-outs of tracings of the patient's profile and finally decided on the vertical section which has been universally adopted since then.

A MAXILLOFACIAL FOUNTAINHEAD

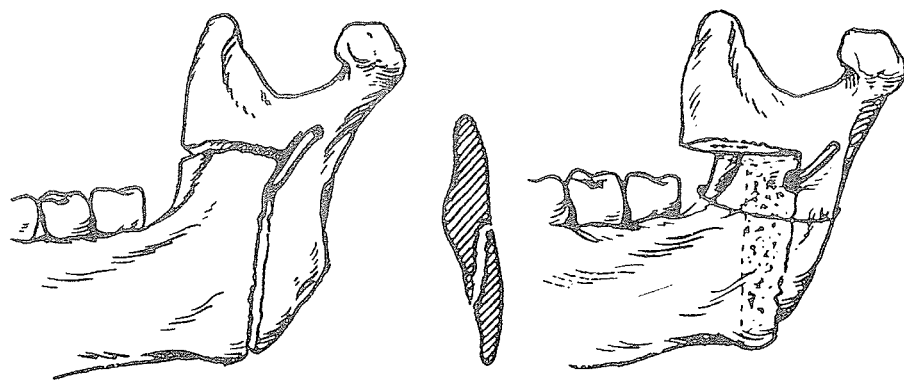
Out of the ruins of an old castle in the center of the Austrian town of Graz rises a tiled roof tower with a large clock. Here

families of friendly squirrels romp when not better occupied accepting nuts from visitors and cracking the shells with tooth and jaw efficiency that must inspire the entire little world of maxillofacial surgeons. Possibly coincidentally, Graz has had an impact on the reparative surgery of the jaw, having produced more than its share of ranking maxillofacial surgeons beginning with Trauner, then Obwegeser, Köle and the many others who traveled there to study.



In 1955 in *Oral Surgery, Oral Medicine and Oral Pathology*, Richard Trauner, with Obwegeser, described his L-shaped osteotomy of the ascending ramus:

To avoid any possible damage to the mandibular nerve, it is best to perform a vertical section in the frontal plane of the ramus, immediately posterior to the mandibular foramen which lies about 15 mm. in front of the posterior border. Vertically, it is situated between the upper and middle thirds of the ascending ramus; and in certain cases a little lower. . . . We prefer a rectangular osteotomy of the ramus, an inverted L with its angle facing anteriorly.



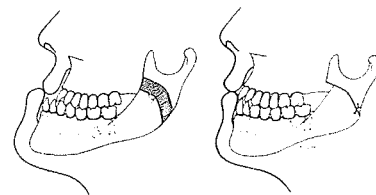
Heinrich Köle, at present of Linz and winner of the 1959 Martin Wassmund prize, while with Trauner in the Graz University Dental Clinic, noted the disadvantages of Trauner's L-method in 1965 in *Oral Surgery, Oral Medicine and Oral Pathology*:

1. The angle of the jaw remains too far forward.
2. The extraoral incision produces a scar which is especially visible in cases in which there is a deep impression of the retromandibular area.

Therefore, the esthetic results do not satisfy all demands. . . . I decided to try an ostectomy (that is, effective removal of the surplus bone) in the ascending ramus, thereby saving the angle of the jaw as far as possible.

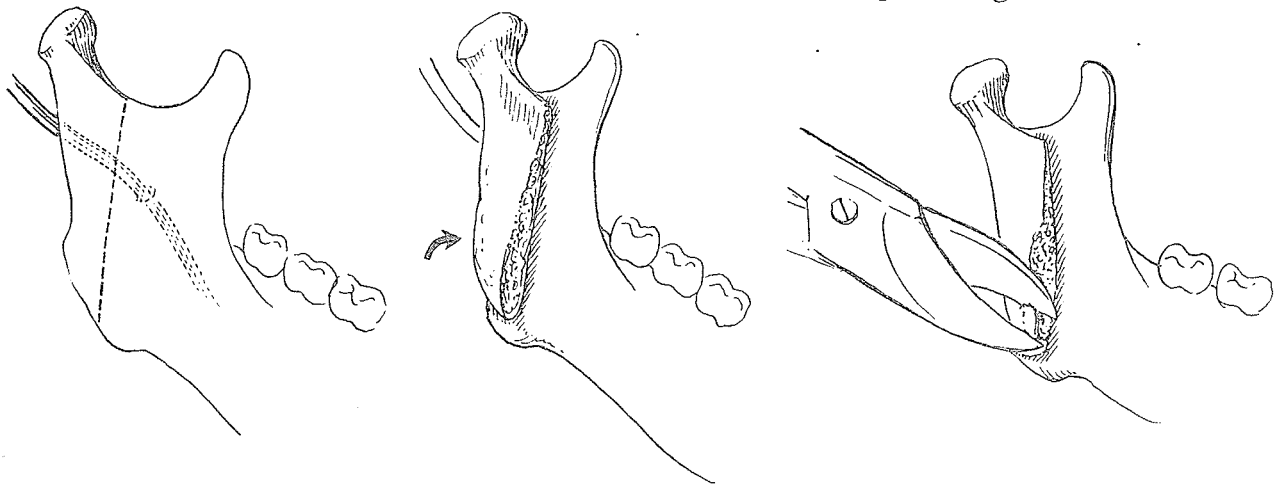


Heinrich Köle



To save the mandibular nerve and to improve the angle of the jaw, Kôle performed an arched osteotomy. This method was especially indicated, he felt, in cases of extreme protrusion in which there were broad and long ascending rami and an obtuse angle of the jaw.

In 1964, in his book *Reconstructive Plastic Surgery*, John Marquis Converse, with S. L. Horowitz and D. Wood-Smith, described a simplification of vertical osteotomy which has become quite popular. Through a submandibular incision avoiding the marginal branch of the facial nerve, the ramus of the mandible was sectioned with a Stryker reciprocating saw. The medial



pterygoid muscle was raised from the medial aspect of the posterior fragment, and the anterior fragment was moved posteriorly until the desired occlusal relationship existed. Excess bone in the posterior fragment was trimmed. In severe prognathism, a portion of the posterior border of the anterior fragment was resected to avoid impingement upon the mastoid bone or facial nerve. The teeth were held in fixation for six to eight weeks.

Dingman's evaluation is of interest:

Advocates of this procedure consider its major advantages to be: a safe approach, effectiveness in severe prognathism, no intraoral contamination, arch moved as a unit without sacrifice of teeth or bone, avoidance of injury to the inferior alveolar nerve, normal temporomandibular joint relationship assured, and achievement of a good cosmetic result. Some of the same disadvantages of transverse osteotomy apply to the vertical osteotomy—that is, facial nerve injury, hemorrhage, parotid fistula, and prolonged immobilization. The muscles of mastication are thrown out of balance, and non-union, malocclusion and open bite can occur.

SAGITTAL SPLITTING OF THE ASCENDING RAMUS

In 1954 Karl Schuchardt of Hamburg described a short step osteotomy of the ramus that was the precursor of the true sagittal osteotomy.

The champion of the true sagittal splitting of the ascending ramus is Hugo Obwegeser of Zurich. With both dental and medical degrees, he received his early training in maxillofacial surgery with Trauner in Graz, then came to Rooksdawn House to study under Gillies about 1952-1953, while I was writing the book with Sir Harold. He was a young, gentle, blond, blue-eyed Austrian, eager to learn the principles of plastic surgery and fascinated by them set out as "Ten Commandments." It was apparent even then that Obwegeser would become a leader in his chosen field, but there was no hint he would become the dogmatic advocate of mandatory acquisition of both dental and medical degrees for all maxillofacial surgeons. Ideally he is right, for *only* those who have obtained a dental degree have the trained capacity to appreciate the true ecstasy of achieving a perfect occlusion of the teeth. There have been, however, notable exceptions.

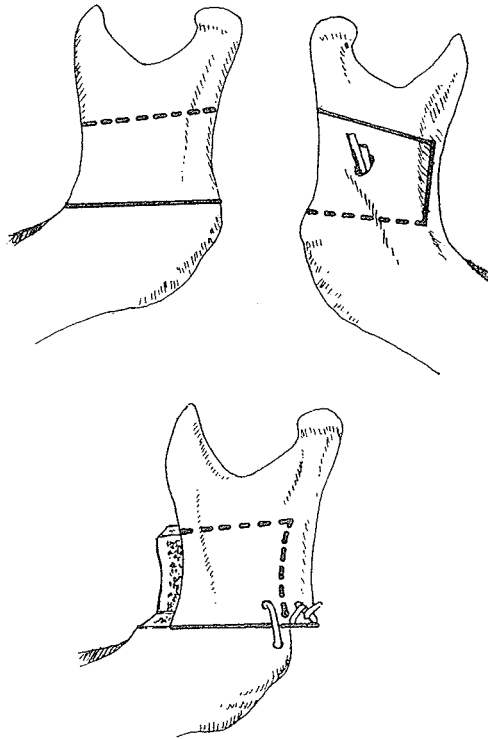
Less than five years after his time with Gillies, Obwegeser, with Trauner in a 1957 *Oral Surgery, Oral Medicine and Oral Pathology*, presented the first true sagittal splitting of the mandibular ramus. This is his original description of the procedure:

The incision is made in the mucosa and periosteum, extending along the external oblique line. The lower end of the incision should be directed farther away from the molars toward and into the moveable tissue so as to facilitate closure. Next, the periosteum of the outer surface of the ramus is elevated. A wide-blade periosteal elevator with a deep curvature is hooked behind the posterior border just above the angle of the jaw. With the soft tissue thus kept out of the way, the bone is incised with a Lindemann burr. The cut should be carried horizontally. It should penetrate the cortical bone only. Next, the periosteum, together with the soft tissues between the mandibular notch and the lingula, is elevated medially. The contents of the mandibular canal are protected by again hooking the aforementioned periosteal elevator below the neck of the condyle. Now the bone is cut just below the mandibular notch to a depth that will leave only the lateral cortex



Hugo Obwegeser

giant with
double degrees:
Kazanjian
Trauner
Dingman
Obwegeser
Schuchardt
without:
Gillies
Blair
Tessier
Conover
Murray
Munro



intact. This cut should be about 25 mm. above the first cut. For correction of mandibular prognathism, the bone cut will have to be inclined upward and backward, whereas for correction of a mandibular retrognathia it should take a downward and backward trend. . . . Then an osteotome about 20 mm. wide is inserted and, in order to avoid damaging the contents of the mandibular canal, it is forced backward along the outer cortical plate. . . . When the osteotome is twisted, the ramus splits in two. Thus, a steplike splitting results in the sagittal plane of the ramus, with large cancellous bone surfaces facing each other. . . . By this method, three types of correction may be made. First, by retrusion of the large anterior segment, mandibular prognathism may be corrected; second, the jaw may be set forward to correct mandibular retrognathia; and third, rotating of the anterior segment will correct an open bite. . . . The next step in the procedure is fixation of the mandible by intermaxillary wiring.

In 1964 Obwegeser, concerned about damage to the skin, nerves and vessels, and the parotid gland sometimes incident to the external approach, in addition to the problems of non-union, continued to promote his sagittal splitting technique utilizing the intraoral approach. Fixation was held for six weeks. Obwegeser contended logically that the large surface contact area provided greater bony union. The obtuse angle of the jaw can be corrected, thus improving a major part of the deformity.

Dal Pont

Giorgi Dal Pont of Belluno, Italy, made a contribution in mandibular osteotomy. His basic interest in philosophy and mechanical sciences has influenced his work in stomatology. It is his feeling that

in science, methods and theories often lead to blind alleys which prevent progress.

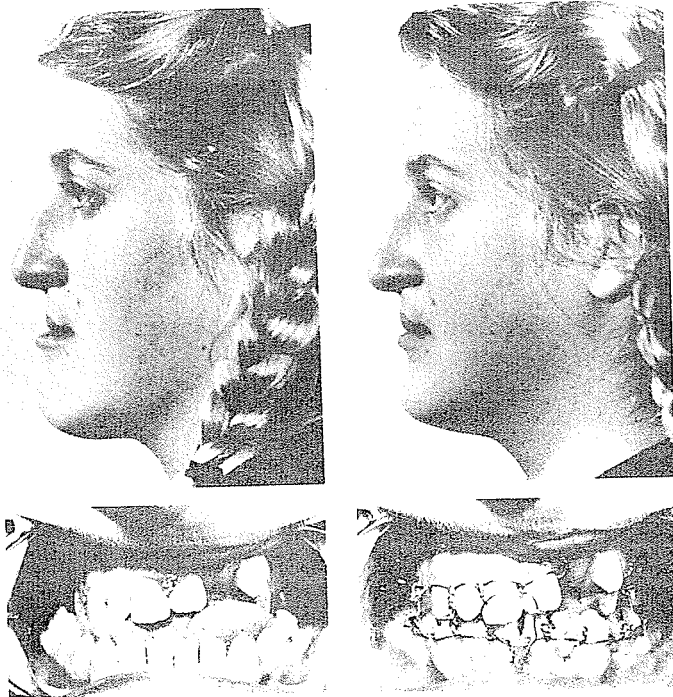He explains his own "breakthrough":

The technique of horizontal section of the ascending ramus, developed from Blair to Obwegeser, was bound to the concept of the horizontal section. Maybe because I was facing the problem the first time, it was not difficult for me to realize at once that the optimal solution was to abandon the external horizontal section and substitute a vertical section.

In 1959 Dal Pont suggested extension of the sagittal splitting osteotomy up to the third molar region. In 1961, in the *Journal of Oral Surgery, Anesthesia and Hospital Dental Service*, he presented a case of cleft lip and palate before and after his retromolar osteotomy and pointed out the advantages of this approach:

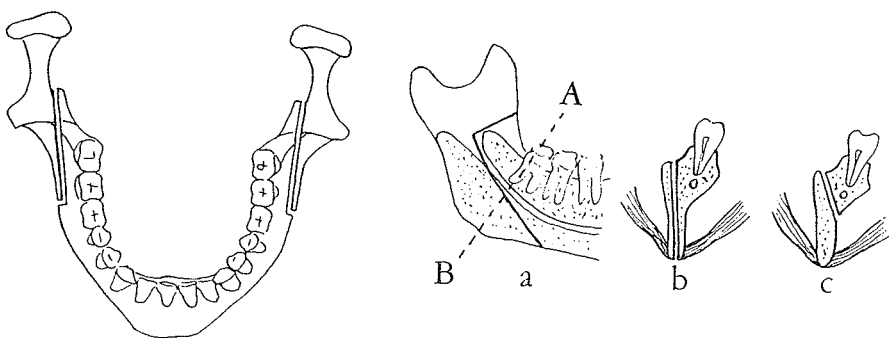


Giorgi Dal Pont



(1) a better and easier adaptation of the fragments; (2) broader contact surfaces; (3) greater possibility for correction of prognathism, micrognathia

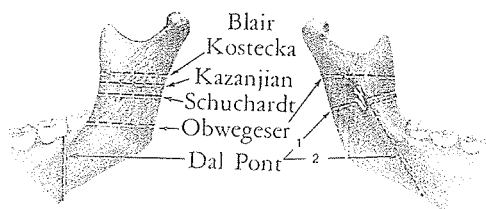
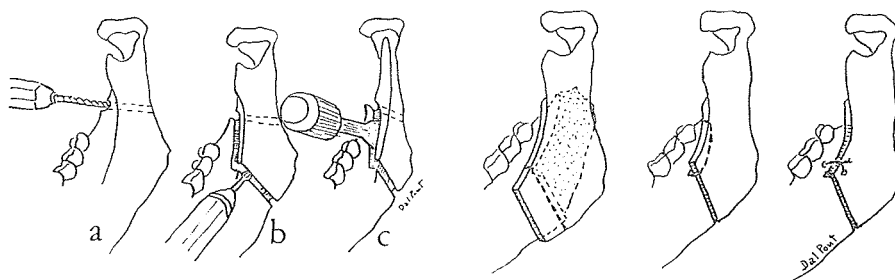
and open bite; and (4) avoidance as much as possible of muscular displacement.



He noted (in b) that the masseter muscle was left on the distal fragments, whereas the internal pterygoid muscle moves together with the displaced larger fragment. In the other possibility (c), both muscles remain on the distal fragments.

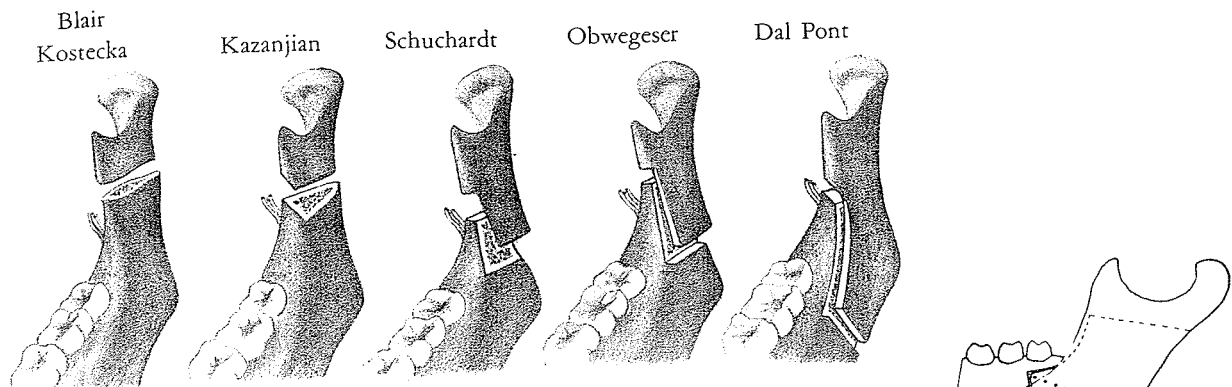
Dal Pont described a sound sagittal procedure for retromolar osteotomy

in which bone incision lies on a plane that starts near the edge of the linea obliqua and extends sagittally between the cortical plates from the retromolar region up to the mandibular angle. . . . To correct the prognathism, a piece of cortical bone is removed on the buccal aspect and in the anterior border of the ascending ramus, for proper adaptation of the fragments.

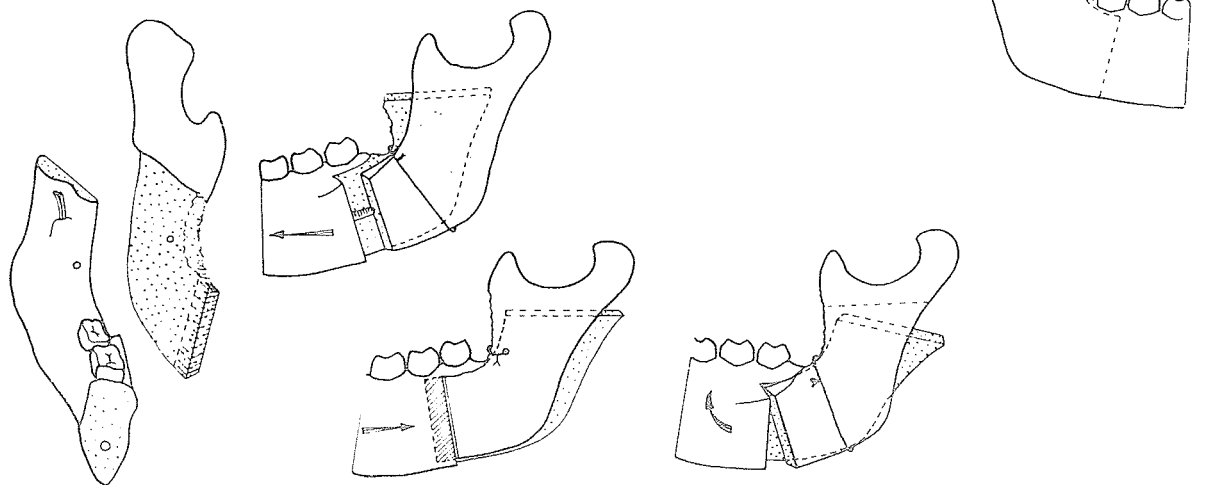


Tony Wolfe points out that this procedure increases the length of bony contact but warns that it also brings the third molar into the field. If the third molar is impacted, it can be difficult to remove without fracturing the proximal fragment and may well merit preliminary extraction.

In 1966 Dal Pont charted the evolution of ramus osteotomy with simplicity.



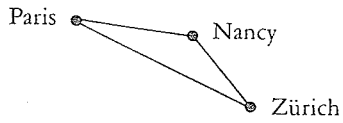
By 1971 Obwegeser had incorporated the Dal Pont extension in his procedure. It was well illustrated in his chapter in *Cleft Lip and Palate*, where he presented the versatility of the principle.



In 1974, at the Second Congress of the European Society of Maxillo-Facial Surgery in Zurich, Walter Pepersack and Hugo Obwegeser presented long-term analysis of their results in cases of sagittal splitting. They reported a 30 percent incidence of early anesthesia of the lower lip. This technique requires a skill beyond that of some surgeons. In 1972 Stanley J. Behrman of New York reviewed 600 patients receiving the sagittal splitting procedure by 64 oral surgeons and reported such complications as regression and relapse, hemorrhage, trauma to the mandibular nerve, edema, fragmentation of the ramus, necrosis or sequestration of bone, and infection. He warned that it required great technical skill, specialized instruments and assistants, and that because of the difficulty of exposure, it was not easy to teach. Because of the excellent bony apposition and remarkable freedom of movement

of the mandible afforded by sagittal splitting, however, he concluded that it was superior, and with experience, complications would decrease.

After completing his plastic surgery training at the University of Miami, S. Anthony Wolfe went to Europe for a year of postgraduate training in craniomaxillofacial surgery. No sooner was he overseas than he discovered the three centers of excellence in "hard tissue" surgery: Paris with Tessier, Zurich with Hugo Obwegeser, Hans Peter Freihofer, and Walter Pepersack, and Nancy with Jacques Dautrey. Nancy is a city situated right in the center of the prognathism belt stretching all the way to the Hapsburgs' Vienna and midway on the road between the other two cities.

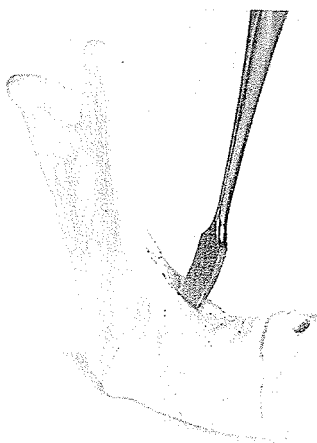


Jacques Dautrey

Dautrey

Jacques Dautrey started as an orthodontist and stomatological surgeon with Ginestet at Foch Hospital, Paris. He and Tessier are old friends; in fact, Tessier insists his assistants and visitors drive three hours to the dreary industrial town of Nancy to see Dautrey work in his operating room on ground level at Clinique Saint-André. He limits his surgery to procedures on the maxilla, mandible and temporomandibular joint and carries out each with perfection and finesse in an atmosphere of tranquility. His two large operating room windows overlook rolling fields dotted with cows grazing peacefully.

Dautrey has done more than 500 sagittal splitting procedures of the mandibular rami and has reduced the incidence of numbed lip postoperatively to virtually zero. Patients leave the hospital two to three days after the surgery. Here is Wolfe's outline of Dautrey's refinements:



1. Instrumentation: All retractors used in the mouth are matte, and have outward-curved edges to avoid injury to the lips. Note also his modified Smiley osteotomes which when twisted will not crush the nerve. Fibre-optic aspirator is important for lighting, and Kerr drill with irrigating attachment prevents bone burn.

2. Ballooning of mucosa with dilute vasoconstrictor solution, and separate periosteal incision at a slight distance from the mucosal incision allows for a two-layer closure.

3. After drill holes are made through the anterior cortex, and medial and lateral cortical cuts made with a Lindemann burr, the modified Smiley osteotomy is used to hug the lateral cortical plate.

4. Ramus split delicately without using heavy instruments which crush the nerve.

5. He keeps the condyle seated in the glenoid fossa (which must be done to prevent postoperative anterior open-bite) by several tricks:

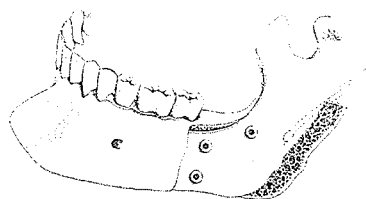
(a) Before the osteotomy, he scores a vertical line, beginning on the maxilla behind the last molar, and running down on the lateral surface of the mandible. These marks on the maxilla and condylar fragment of the mandible are made with the teeth in their initial occlusion and should line up at the end of the operation.

(b) Another method is to push the condylar fragment forcefully back against the posterior wall of the glenoid fossa, compressing the capsular cartilage, then allow it to come forward 2-3 mm. before trimming the excess bone from the distal portion of the condylar fragment. The two fragments would then fit exactly and are held together by a fine wire through the lateral cortices.

A final refinement developed in 1977 by Dautrey is the keeping of a small spur on the proximal fragment which fits into a pocket in the distal fragment, giving further stability by auto-contention.

In 1976, in *New Concepts in Maxillofacial Bone Surgery*, Bernd Spiessl of the University of Basel, Switzerland, described a touch of finesse he adds to the method by permanently fixing the two sagittally split fragments with three lag screws which can be inserted percutaneously through small stab wounds. The advantages claimed by Spiessl included a guaranteed position of the fragments, early mobilization and a shorter period of intermaxillary fixation.

In 1965 C. C. Knowles analyzed the remarkable change in facial contour after osteoplastic procedures on the mandible in cases of relative prognathism. It is his belief that preoperatively many of these patients have shortness and eversion of the upper lip and absence of the rolled outline of the vermilion border of the lower lip. Their appearance postoperatively gives the impression that the upper lip has been lengthened and has lost its eversion while the lower lip, previously undefined, now has a natural fullness. Knowles contends that this improvement is due

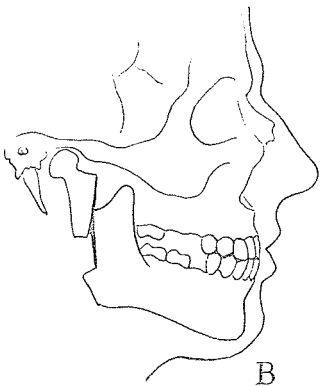
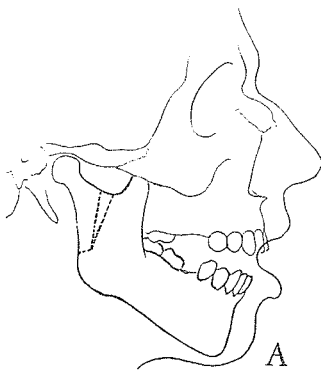


to an alteration of the muscles of facial expression, particularly the depressor anguli oris inserting into the mouth. The origin of the muscle from the lower border of the mandible tends to pull the mouth downward as the mandible is moved back. The backward movement of the risorius and platysma transmitted to the orbicularis may be responsible for the improvement in the lower lip roll.

MANDIBULAR RETROGNATHISM

According to Dingman in his section in *Cleft Lip and Palate*, edited by Grabb, Rosenstein and Bzoch:

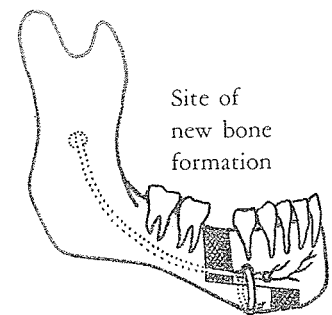
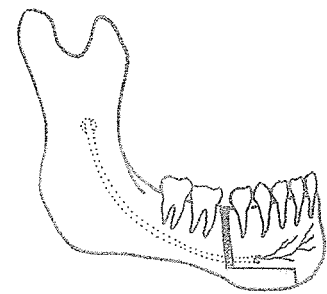
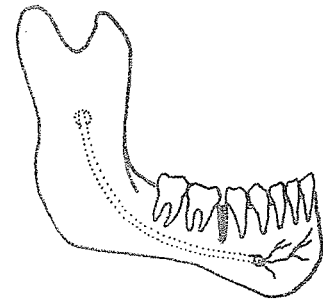
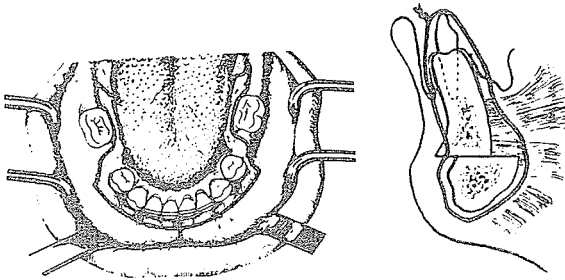
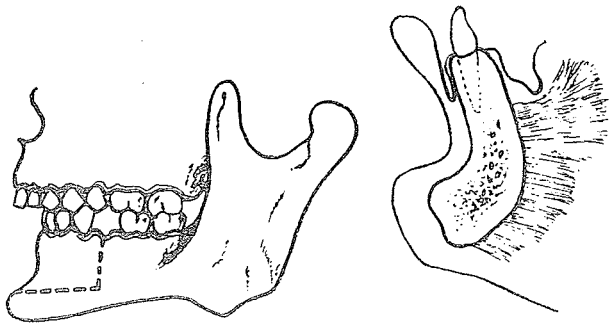
Eighty to 90 percent of children born with the Pierre Robin syndrome (glossoptosis and micrognathia) have clefts of the soft palate or soft and posterior hard palate [B. E. Bromberg, R. Pasternak, R. W. Walden, and L. R. Rubin, 1961; W. S. Kiskadden and S. R. Dietrich, 1953]. The growth potential of the micrognathic mandible is inconsistent; while normal growth is eventually seen in most of these patients [S. Pruzansky and J. B. Richmond, 1954; B. Douglas, 1956], a significant number of them will fail to reach full mandibular growth and have a retrodisplaced mandible with Angle Class II malocclusion. If occlusal abnormalities are minimal or orthodontically correctable, facial contour can be improved with onlay chin implants of autogenous bone or cartilage, irradiated cartilage, synthetic materials, or horizontal advancement osteotomy of the mandible below the apices of the teeth. For severer degrees of retrodisplacement, a step osteotomy through the molar region, with advancement of the anterior fragment and insertion of a bone graft, has been our choice of treatment. This operation can be carried out in the teens any time after mandibular growth has ceased.



According to Converse, oblique vertical section of the ramus was described by A. A. Limberg of Leningrad in 1925 in the treatment of micrognathia with open bite (A and B). Later, in 1928, Limberg proposed the addition of a costal bone graft for the micrognathia. In 1927 Wassmund described a vertical section with a forward angulation above the lingula, extending through the base of the coronoid process.

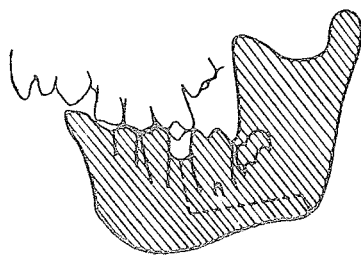
In 1936 and 1942 O. Hofer described a method of correcting anterior alveolar retrusion in the normal mandible by advancing the entire alveolar fragment. In 1959 H. Köle modified the

mucosal incision and presented cross-section diagrams of this osteotomy with the correction fixed with circumferential wiring, as shown.

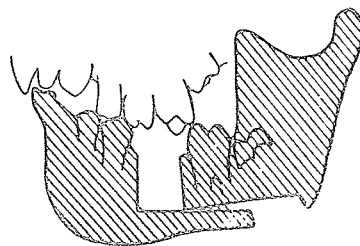


In 1948, in *Plastic and Reconstructive Surgery*, Reed Dingman presented his favorable step osteotomy for correction of mandibular retrusion in a two-stage procedure, with the first stage a single vertical cut above, at the point of lengthening. Two weeks later, through a skin incision 1 cm. below the inferior border of the mandible, a vertical cut well forward of the initial cut, and a horizontal cut below the inferior mandibular nerve joining the vertical cuts, produced a step osteotomy which allowed forward advancement of the mandible. Dingman noted that advancement of the mandible 1 cm. was possible without tearing the nerve. Bone wires and intermaxillary fixation were used.


In 1948 Pichler and Richard Trauner of Austria described a step-like osteotomy of the body to bring the mandible forward in microgenia.



A



B

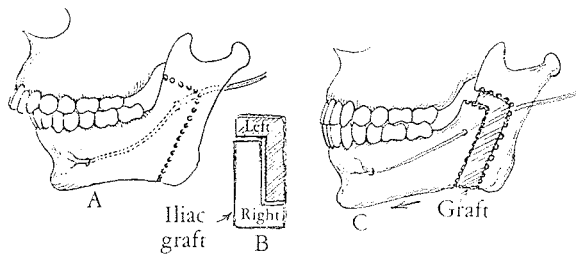


In 1957 Trauner, again with Obwegeser, readvocated his cartilage graft of 1955:

For mild forms of mandibular prognathism I prefer the retrocondylar cartilage implantation because it is a minor surgical intervention which does not require a postoperative intermaxillary wire fixation. . . . Between the anterior wall of the auditory meatus and the glenoid fossa lies a bone suture, the fissura petrotympanica. Just before and above it, the bone is perforated with a small drill. The piece of cartilage is tied to the bone with wires going through this hole. The cartilage is situated close to the anterior wall of the bony auditory meatus.

In 1957 Hugo Obwegeser called attention to the fact that his sagittal splitting osteotomy of the mandibular ramus was also applicable to the correction of retrognathia.

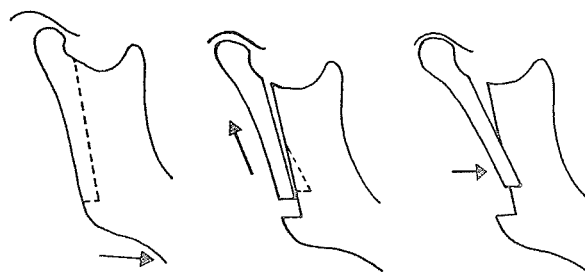
In 1958 Karl Schuchardt of Hamburg utilized this type of osteotomy and inserted an L-shaped bone graft for the elongation of the mandible in micrognathia.



Herbert Mehnert

In 1976 Herbert Mehnert of the University of Innsbruck, Austria, presented his variation of the vertical osteotomy of the mandibular rami for retrognathism. He explained:

(a) After forward movement of the mandible to an Angle class I occlusion, the ramus is vertically osteotomised. (b) The condyle-bearing segment can then be replaced in the glenoid fossa. (c) Creation of a step with a bur to wedge in the condylar segment, so that the mandible does not slide back into distocclusion.



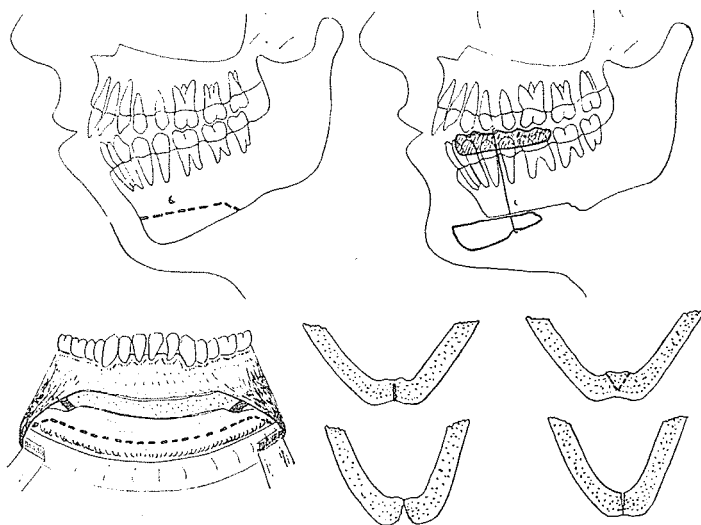
In 1977 Broadbent and Woolf of Utah reported 26 cases using the Obwegeser-Dal Pont sagittal split osteotomy for retrognathia. They noted that complications, especially relapse, weakness of the lower lip and numbness of the lower lip, were common enough to encourage them to look for another surgical approach with less morbidity, possibly the methods of Hinds, Trauner or Mehnert.

Obwegeser
Dal Pont
Dautray
and Wolfe
would not
agree

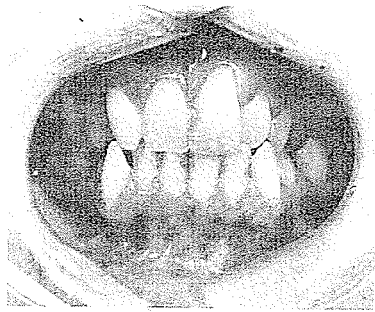
In our Rag Bag chapter in Gillies' and my *Principles and Art of Plastic Surgery*, a case of Treacher Collins syndrome presented a mandible of abnormal vertical length with a receding chin. An advancement osteotomy pivoted on a Gillies periosteal hinge was beneficial.

Method: An osteoplastic flap was cut from the lower margin of the mandible, leaving the periosteum along its upper border. This large block of bone could then be folded over to rest in front of the mandible to give the necessary prominence and contour.

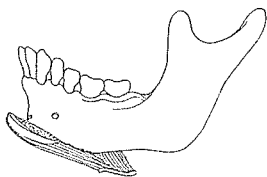
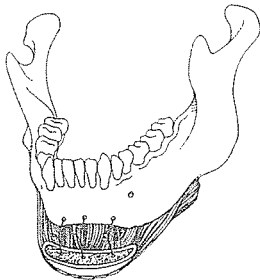
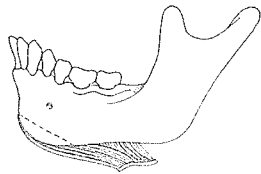
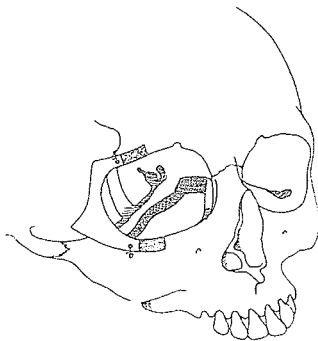
Along the same principle but as a free graft rather than a flap, Obwegeser, advanced a V-shaped segment of inferior mandible to increase the mentum projection. By minor osteotomy or osteotomy of the anterior angle, he regulated the shape of the advancing arch.



Finally, here is Tony Wolfe's modification of mandibular advancement for receding chin in a 35-year-old schoolteacher with a bilateral cleft lip and Crouzon's disease. Extensive ortho-



odontic treatment gave her "satisfactory" occlusion, but she was left with considerable facial disharmony.



As Wolfe noted:

It would have been vastly preferable *not* to have had the preliminary orthodontics, so that a Le Fort III osteotomy alone would have corrected all the problems at once. Now if a Le Fort III advancement were done to correct the exorbitism and maxillary hypoplasia, she would end up with a Class II malocclusion, and either reverse orthodontics postoperatively or a simultaneous Le Fort I would be needed to maintain her present occlusion. The patient declined these two possibilities, so an orbital expansion, onlay bonegrafting to the anterior maxilla, and *modified sliding advancement of the mandibular symphysis, retaining muscular attachments*, were performed. She also had an Abbé flap and a corrective rhinoplasty.

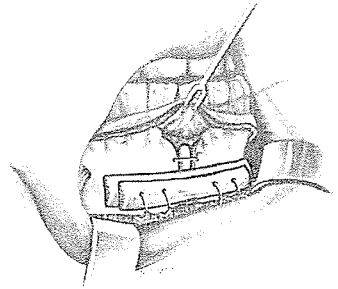

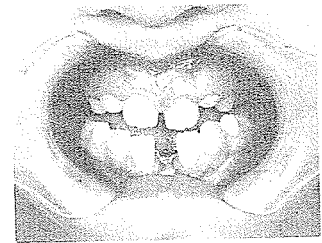
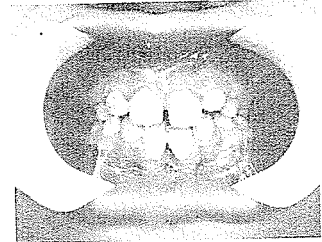
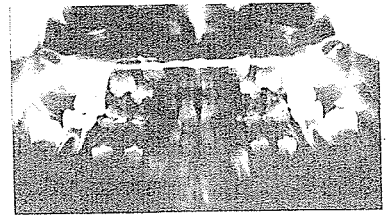
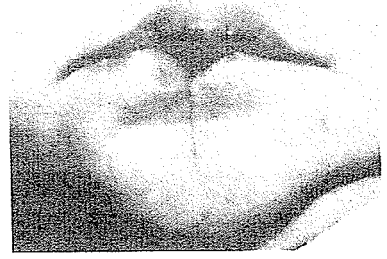


BIFID MANDIBLE

This patient was born with a cleft of the lower lip involving the vermilion, a submucous cleft of the orbicularis muscle, a frenulum of the tongue attached in the cleft alveolus and a bifid mandible. At 5 months of age the tongue was detached and the lip cleft closed with muscle approximation, leaving a skin dimple (Volume II, P. 814).

At 8 years of age the bifid mandible revealed an instability exaggerated by masseter muscle contractures which could separate the mandibular segments 0.5 cm. At surgery the mandibular symphysis was exposed through a lower labial sulcus incision leaving a proximal mucosal flap for closure. The mental nerves were visualized somewhat lateral to their usual location. S. A. Wolfe harvested a portion of the right 6th rib and stabilized the cleft in this manner:

The midline cleft of the mandible was dissected free of soft tissue attachments and several millimeters of sclerotic bone on either side were removed with a burr. An appropriate segment of rib was fashioned to fit in the diastasis and was fixed with two #40 wires. The remaining rib was split in two and overlaid the anterior mandible across the cleft and wired. One



Hemovac® was used for drainage and the wound closed in layers. Four circummandibular wires were passed and used to fix a previously fabricated Vitallium splint (Berkowitz).

An uneventful recovery was followed by removal of the splint and circummandibular wires after 8 weeks.

