

# VII. *Jaws*

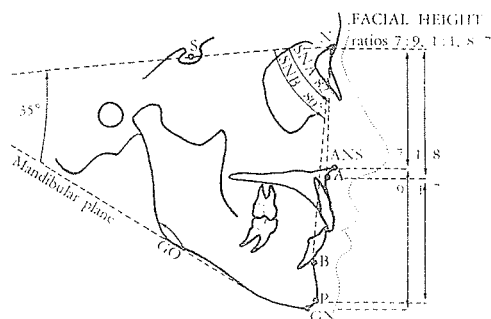
# Introduction to Part VII

When the cleft anomaly has occurred on the framework of a face which, without the cleft, would have been prognathic (Angle class III) or retrognathic (Angle class II), it tends to increase or decrease, respectively, the absolute occlusal discrepancy between the two jaws. Edward Angle of Pasadena was the modern father of orthodontics in the early 1900s.

Cephalometric analysis may aid in the defining of the deformity, but in the final analysis, the decision as to which structure is deformed and which should be operated upon—the maxilla or the mandible—will need to be made on a clinical basis, with an understanding of what would constitute the most pleasing es-



Edward Angle



thetic relationships for the particular patient's face. Cephalometric analysis takes the sella-nasion (SN) line as the fixed line against which to measure the most anterior point of the maxilla (point A) and the most anterior point of the mandible (point B). Dingman and Dodenhoff's cephalometric x-ray tracings demonstrate the differences between normal relationships, pseudoprognathism, and true prognathism.

In severe maxillofacial deformities, the cephalometric baselines themselves become affected and invalid, as in the patient with Crouzon's disease with a steeply tilted anterior base, or in the patient with hemifacial microsomia, who has a short cranial base on the affected side. The majority of adult postoperative cleft patients will have class III malocclusion due to maxillary hypoplasia, and generally the maxilla—the blighted structure—should be moved forward rather than the mandible backward, to obtain both proper dental occlusion and a satisfactory facial profile. When from cephalometric determinations the mandible is more

Angle

Class I = normal maxillary-mandibular molar relationship.

Class II = max. molar teeth too far in front of mand. molar teeth.

Class III = Mand. molar teeth too far in front of max. molar teeth.

protuberant than the maxilla is recessive, the mandible may be moved back.

Any major discrepancy in the sizes of maxillary and mandibular arches is usually caused by the maxillary deformity. As a rule, the maxilla should be expanded, but again, in some cases the deformity will be predominantly due to an overlarge mandibular arch which will need to be reduced by a body or symphyseal osteotomy.

#### *Correcting priorities*

In 1959 Heinrich Köle of Graz made this sound observation:

The choice between orthodontic and surgical treatment is based on the severity of the deformity and the age of the patient. Generally surgery is preferred when the malformations are very pronounced or when bone growth has ceased.

It is the opinion of Obwegeser, Tessier, Dautrey, Pruzansky, Aduss and others, as well as Wolfe and Berkowitz in our unit, that mandibular prognathism, as we define it by cephalometric analysis, is not more common in the cleft lip and palate group. Furthermore, our unit has not had gratifying results in treating mandibular pseudoprognathism (i.e., retromaxillism) with orthodontics when there was a *skeletal* discrepancy between the basal alveolar bone of the maxilla and mandible. Many of our patients, although they end up with "satisfactory" dental occlusion, have required onlay bone grafting to these maxillae, which still possess their recessed, hypoplastic appearance.

The surgeon must work closely with the orthodontist in defining the deformity and planning the proper procedure. The orthodontist, in turn, must know which cases should *not* be treated by orthodontics alone. Orthodontics treats the malalignment of teeth, but when the supporting skeletal structures—the alveolar ridges of the maxilla and mandible—are in poor relationship, surgery must be performed before a satisfactory dental and facial result can be obtained.

Surgical procedures most commonly used in cleft patients are:

1. Segmental procedures.
2. Procedures for mandibular recession.

3. Procedures for maxillary advancement.
4. Onlay bone grafting procedures for patients with orthodontically obtained class I occlusion but persistent maxillary hypoplasia.

A modern, premier hard tissue surgeon for correction of the postoperative cleft lip and palate, mandible and maxilla, is Hugo Obwegeser of Zurich. In the introduction to his 1971 chapter for *Cleft Lip and Palate*, he stated:

Various degrees of residual jaw deformities and displaced teeth are usual sequelae to primary closure of clefts of the lip and palate. They have been present in the past, they are still seen, and, I believe, some of them will still occur in the future. New surgical techniques notwithstanding, there is no panacea in cleft surgery. The cause of these anomalies is attributable to four factors: (1) genetic, (2) type of surgical procedure used, (3) skill of the surgeon, and (4) the orthodontic treatment. . . .

Most patients with malposed jaws have an altered, often severe facial disharmony. . . .

In cleft cases, some supplementary correction may be required on the soft tissues; however, this should follow the correction of the bony parts. As in any type of maxillofacial surgery, especially in the correction of secondary jaw deformities, one must adhere to the principle, "*first the bone, then the soft tissues.*"

Obwegeser generalized:

I believe that in a cleft case it is extremely difficult for one to postulate exactly what the interrelationships of the facial bones would have been had they not been changed by both the cleft deformity and the further disruptive forces of surgical intervention. For this reason, the surgeon's treatment planning is greatly influenced by imaginative and intuitive factors.

Create the best possible occlusal relationship; this is a basic guide. Most of these patients have an Angle Class III type of appearance. In the past, I operated primarily on the mandible, and the results were only marginally satisfactory. The operation on the mandible only, often created a pronounced retrodisplacement of the middle third and lower third of the face. Today in cleft cases I usually operate on the upper jaw only. I seldom operate on both the maxilla and mandible and very infrequently on the mandible exclusively. For profile considerations, when the maxilla is moved forward, I strive to create a Class II occlusion, thus slightly overcorrecting the occlusion.

add  
(5) Timing!

a 1948  
Pichler  
edict