

53. Palatal Obturators

LONG before surgery of the palate had been developed, obturators were in use. According to historical scholar Blair O. Rogers, as noted in *Cleft Lip and Palate*, 1971:

Interestingly, the earliest evidence of a simple, retentive dental prosthesis was found at El Gizeh, dating from the end of the Old Empire (circa 2500 B.C.). It was made of gold wire, linked together the lower left second and third molars, and had been woven around their gingival margins. Thus began man's early attempts to construct the intraoral prostheses that played such an important role in subsequent centuries in the evolution of cleft palate therapy and surgery. . . . Despite the supporters of Amatus Lusitanus as the inventor of the obturator [B. W. Weinburger], Paré was familiar with palatal obturators as early as 1537 to 1539, since he had observed their use many times ". . . in the battles fought beyond the Alps."

In 1560 Lusitanus, previously of Ancona, was probably the first to describe what is known today as a palatal obturator. A Greek nobleman presented a permanent luetic fistula of the palate to Lusitanus, who designed a prosthesis. These are his words, translated by Joshua Leibowitz of Hebrew University in Israel while at Yale:

Pay attention to the way . . . I invented the following extraordinary artifice which made possible a correct and distinct speech, as if he had never had any illness.

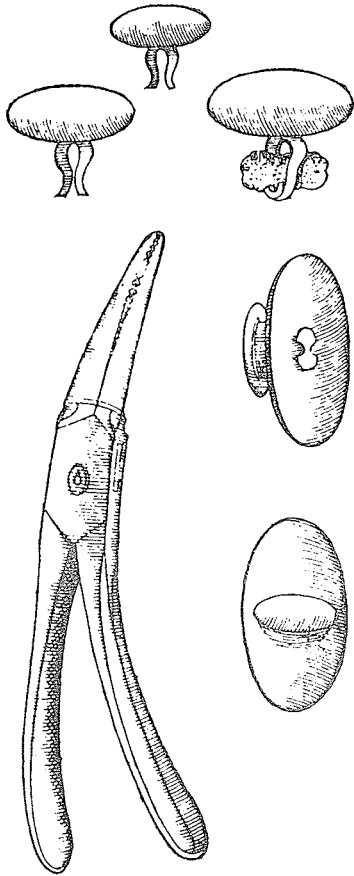
I ordered a goldsmith to prepare a golden-headed nail; the head of the nail was round and broad enough to close the total circumference of the foramen. Whereas the tip of the nail was narrow and round . . . and to this tip a small sponge was fitted. . . . This the patient had to introduce into the foramen where it expanded with moisture and so remained fixed in position.

This obturator was removed twice daily for cleaning. While it was in, the patient's speech was "elegant"; when it was out, totally deficient.

Jacques Houllier's mention of the use of wax or sponge to plug palate perforations suggests that such primitive obturators were already in use by the middle of the sixteenth century, when buccopharyngeal syphilitic ulcers and palatal perforations were prevalent and recognizable.

In 1561 Pierre Franco, a Huguenot surgeon of Paris, wrote:

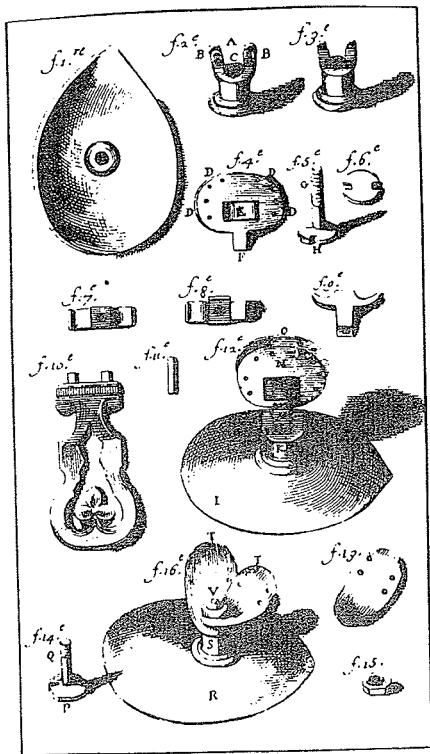
Those who have cleft palates are more difficult to cure: and they always speak through the nose. If the palate is only slightly cleft, and if it can be plugged with cotton, the patient will speak more clearly, or perhaps even as well as if there were no cleft; or better, a palate of silver or lead can be applied by some means and retained there.



In 1564 Ambroise Paré called his small obturators *couvercles* and only in 1575 changed the name to *obturateur*, which Rogers conjectured was probably the first time in medical history that the word *obturator* was used. Paré, referring only to traumatic and luetic palatal defects, explained his technique of

filling the cavities of the Palat with a plate of gold or silver, a little bigger than the cavity it self is. But it must be as thick as a French Crown, and made like unto a dish in figure; and on the upper side, which shall be towards the brain, will become more swollen, and puffed up; so that it will fill the concavity of the Palat, that the artificial Palat cannot fall down, but stand fast and firm, as if it stood of it self.

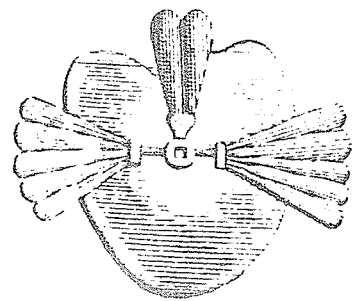
Since surgical correction of a hard palate defect offered difficulties for centuries and, as Rogers has noted, surgeons of the Middle Ages avoided surgery of the palate like the plague, the prosthetic aids of the Renaissance deserved praise and were used for about 200 years. The principle was improved in 1728 by Pierre Fauchard, the father of modern dentistry, when he inaugurated a fixation of the obturator to a dental prosthesis. He described five different obturators of a sophisticated design, some with movable wings operated by screws and each covered with soft sponges, which could fill in most palatal perforations, no matter how irregular their margins. These were illustrated in Plate 38 of Fauchard's *Le Chirurgien Dentiste, ou Traité des Dents*, 1746.



In 1757 Bourdet improved palatal obturators by fixing them, not to the palate itself or inside the nose, but, by means of lateral clasps, to the teeth. In 1820 Delabarre constructed a rubber prosthesis with bands and clasps that utilized the palatal muscles to move the velar section of the prosthesis. Mineral teeth were attached to the palate by means of springs. A movable part made of elastic gum was attached to restore the velum and uvula.

Mohamed Aramany of the University of Pittsburgh, studying the history of prosthetic management of cleft palate, reported that James Snell was believed to be the first to attempt the treatment of congenital clefts with obturators in 1828, about 300 years after Paré wrote his "Surgery," describing an obturator for luetic and traumatic clefts. Snell's attempt to restore the soft palate stopped short of occupying the pharyngeal space. In 1841 Stearn, who had a congenital cleft himself which had undergone a few unsuccessful operations, attempted to construct an appliance of his own and was the first to extend the speech aid into the pharyngeal area.

In 1845 Simon P. Hullihen of Wheeling, West Virginia, noted:



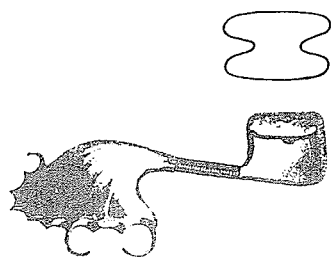
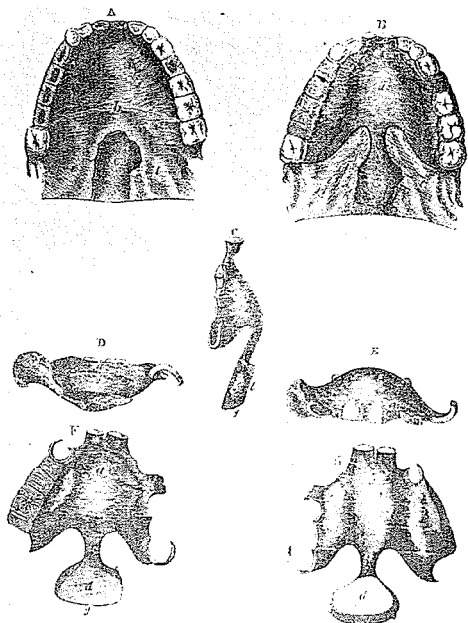
Where the osseous palate is likewise involved, more or less of an aperture will of course remain which must be closed either through the medium of granulations, or by a gold obturator or artificial palate before much benefit can be derived.

In 1860 McGrath introduced a fixed prosthesis and extended the velar section into the nasopharynx. Also in 1860 Norman Kingsley worked with Stearn to construct a speech appliance for a severe bilateral cleft and later improved Stearn's design by simplifying it. For this advance he received a gold medal at the American Dental Convention at Saratoga in 1863.

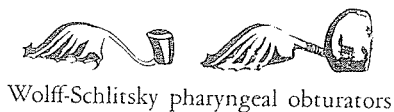
In 1867 Wilhelm Suersen, a German dentist, also improved Stearn's appliance, constructing a fixed prosthesis, and emphasized the importance of the muscle activity of the pharynx, particularly in securing contact of the pharyngeal section of the prosthesis with the pharyngeal musculature to occlude the nasopharynx temporarily. In 1880 N. Kingsley was the first to advocate speech therapy following the construction of an obturator.

In 1878 Passavant employed a collar-button obturator similar to that of Gariel, to maintain posterior displacement of the velum after a transverse incision.

In 1885 Wolff of Berlin advocated the use of Schlitsky's soft rubber pharyngeal obturator after successful cleft palate operations in all cases in which the velum was too short to reach the wall of the pharynx. In 1894 Wolff discarded this obturator for Hahn's hollow hard rubber pharyngeal obturator, which, except for the material, was constructed like the Schlitsky one.



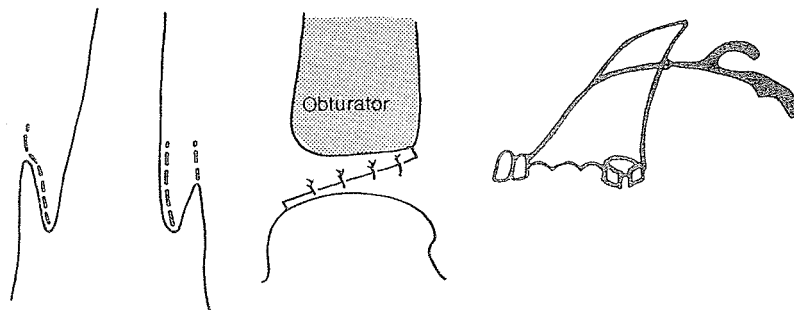
Schlitsky's obturator



Wolff-Schlitsky pharyngeal obturators

EARLY COMBINED USE OF PROSTHESIS AFTER SURGERY

In 1912 Pickerill of New Zealand combined a prosthesis with palatoplasty in a rather unusual and unphysiological way.



In 1921 C. S. Case developed the velar obturator, designed with careful attention to the palatopharyngeal muscles that contacted the prosthesis. Also in 1921 dental surgeon Kelsey Fry insinuated his appliance into the combined hole of the anterior hard palate and the defect between hard and soft palates created by Harold Gillies to achieve a pushback of the velum. This technique is described in Chapter 25.

COMBINED PROSTHESIS FOR TEETH, FACIAL CONTOUR AND PALATE OBTURATOR

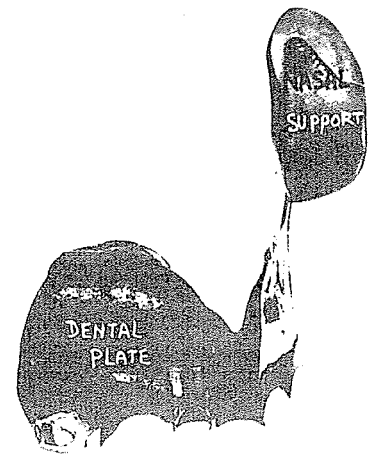
In 1932 in the *Lancet* H. D. Gillies, with T. P. Kilner, revealed his early deciphering of one of the major problems in secondary cleft surgery.

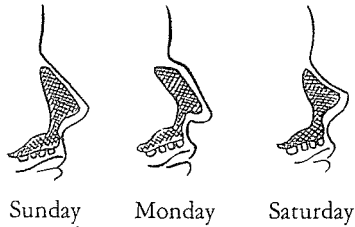
The commonest contour deformity seen in old hare-lip and cleft palate cases is produced by flatness of the lip and depression of the nose. It is obvious that the flat lip is caused by a lack of forward projection in the underlying maxilla, most marked when the premaxilla has been removed, but present in a lesser degree in a large proportion of lips, either bi- or uni-lateral.

The type of depressed nose encountered may be defined as one which as a whole, is situated nearer the vertical axis of the body than normal. . . . This nasal deformity has a more complicated origin than that of the lip. Factors observed include: (1) the backward displacement of the maxillae resulting from the scar tissue pull which follows successful closure of the palate cleft; (2) a definite under-development of the normal amount of bone in those parts of the maxillae which border on the pyriform opening; (3) the backward pressure of a tight lip; (4) a definite failure in the forward growth of the nasal septum. . . . The natural corollary to the backward displacement of the maxillae is that the upper teeth come to lie well inside those of the lower jaw, creating inefficient mastication and an ultra-prominent lower lip.

In 1932 Gillies and Kilner readvocated the buccal inlay and prosthetic principle first developed by Gillies and Fry in 1921 for the cleft palate patient but admirable too in the contracted faces and noses of the luetic deformity. In fact, intranasal prosthetic support attached to the upper plate could be introduced into the

Early awareness
of maxillary
deformity






luectic, skin-graft-lined nose

so that it is perfectly possible for a patient to pocket several different-shaped bridges and change his racial and facial characteristics by a simple sleight of hand.

A preoperatively prepared, simple metal cap splint was fixed to the existing teeth. It held a small adjustable tray in front to support the molding material used to build forward the contour and carry a Thiersch graft to line the pocket. Through an upper buccal sulcus incision, the soft tissues of the lip, nose and cheeks were freed from the underlying retroposed maxillae. Into this raw area a Thiersch graft was fitted, raw surface outward, taken from the hairless inner aspect of the upper arm and mounted on the molded stent over the tray which was fixed to the cap splint. Once the graft had taken and the lined pocket had been established, a permanent upper denture was fitted to replace missing teeth, hide misplaced ones, block the oronasal communication while leaving the nasal airway free, and push forward the lip and nasal base and occlude its teeth normally with those of the mandible.



As noted by Gillies and Kilner:

The whole character of the face is altered for the better. . . . The drawbacks are few. The patient is doomed to wear a denture (how many of us escape?): very occasionally a few drops of imbibed fluid leak through the nose; and occasionally an irritant rhinorrhea persists for a time.

There are times, even today, when this approach is used and on rare occasions is the method of choice.

COOPER

Herbert K. Cooper, an orthodontist of Lancaster, Pennsylvania, in the late 20's and early 30's began to see many cleft palate wrecks. General surgeons, after a full morning of colectomies and thyroidectomies, would turn over the cleft palates to the junior surgeon, and consequently many cases were botched, ending up with fistulae and scarring. Cooper felt that no further surgery was indicated in such disasters, and during his dental restoration he added a bulb to the prosthesis to help the palate. In the late 30's Dorrance became aware of Cooper's success with obturators and made an effort to combine forces.

Robert Ivy, a friend of both Cooper and Dorrance, recalled with glee an episode in a cleft palate clinic about 1938. The heavy, dogmatic, domineering, over 6 foot Dorrance finally irritated the quiet, unassuming, 5 foot 8 inch Cooper into throwing down the gauntlet. To a Dorrance boast about his pushback procedure, Cooper responded:

I can bring 100 cases that have been restored dentally which have good speech, George, if you'll bring a hundred palate cases which have had your "push-back operation" to the same meeting. We'll have a show-down!

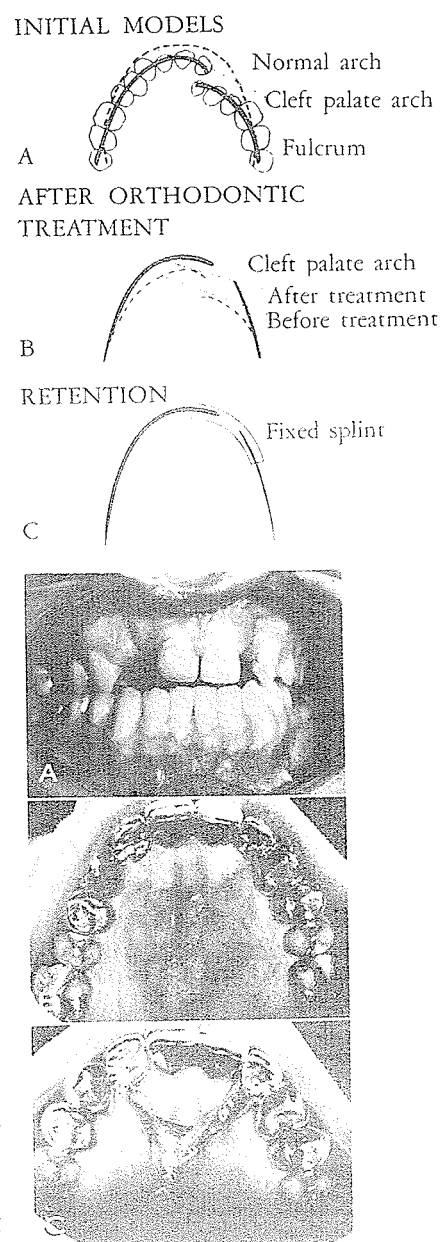
Ivy said Dorrance never took Cooper up on this challenge.

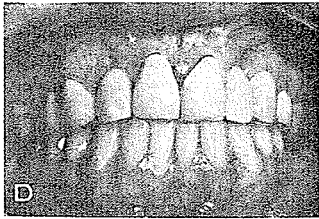
FIXED BRIDGE

Egil P. Harvold, now of the University of California, while at the University of Oslo in 1947 first began studying maxillary development in cleft lip and palate cases. He showed that the main factor in the development of the cleft palate malocclusion was an inward rotation of the maxillary segments around a fulcrum in the region of the maxillary tuberosity, rather than mere individual tooth movement. For correction of this, Harvold demonstrated in 1954 and 1963 that the dislocated segments could be relocated by orthodontic means and then the position of the individual teeth could be corrected by standard orthodontics. In 1951 and 1967 A. Böhn, in cooperation with Harvold, solved the prosthodontic problems by establishing that the postorthodontic results could be permanently retained by means of a relatively short splint across the cleft. Besides retention, the splint provided missing teeth and correction of malformed teeth in the cleft area. Following this regimen, T. Ramstad of the University of Oslo, in the 1973 *Cleft Palate Journal*, presented several impressive cases in which the postorthodontic arch form had been maintained while the dental abnormalities were corrected. He noted:

The fixed bridge is the prosthodontic treatment of choice.

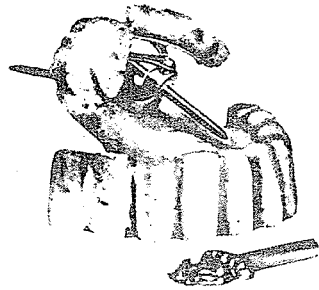Shown here is one of his bilateral clefts after orthodontic treatment, with an eight-unit retention bridge with removable fistula obturator in position and incisor relationship satisfactory. Treatment results with reference to the postprosthodontic adult






occlusion in 63 unilateral and 19 bilateral complete cleft cases were noted:

No buccal crossbite occurred in 63.5% of the unilateral- and in 78.9% of the bilateral cleft cases. Positive overjet and overbite occurred in almost 90% of the unilateral- and in all the bilateral cases.



MORE COMPLEX APPLIANCES

In 1965 A. C. Roberts presented complex obturators attributed to Fauchard and designed to open in the cleft to provide retention; movement of the wings is achieved by using the key.



Before palatal surgery had been developed, and later when less sophisticated and more traumatic surgery had so scarred the palate that function was impaired, and also in cases of severe congenital insufficiency of palatal tissue, the obturator has been of use. As surgery has improved, the obturator has gone on the shelf, but in some areas under certain conditions it may be of value.



Robert Millard

MODERN STAND ON PALATE PROSTHESIS

Robert T. Millard, director of speech and hearing services at the Lancaster Cleft Palate Clinic, acknowledged that the majority of clefts can be closed by operative procedures. In 1971, for *Cleft Lip and Palate*, he presented some interesting guidelines for cases in which a prosthesis was under consideration:

Indications for Prostheses in Unoperated Palates:

1. A wide cleft of the soft palate with insufficient local tissue available to accomplish a functional repair
2. A wide cleft of the hard palate which cannot be closed with a vomer flap or other local tissue
3. Neuromuscular deficit of the soft palate and pharynx
4. Cases with a justified medical contraindication to surgery, such as a blood dyscrasia, or when surgery is delayed
5. Expansion prosthesis for improvement of spatial relationships
6. Combined prosthesis and orthodontic appliance


Indications for Prosthesis in Operated Palates:

1. Incompetent velopharyngeal mechanism with a deep pharyngeal space behind the velum
2. Surgical failures—fistulas in the alveolus, hard, or soft palate.

Contraindications for a Prosthesis:

1. Feasibility of primary or secondary surgical repair based on definitive diagnostic methods
2. Severe mental retardation
3. Uncooperative patient and parents
4. Uncontrolled dental caries, partial or complete anodontia, dentinogenesis imperfecta, and amelogenesis imperfecta
5. Lack of a trained prosthodontist

I. Kenneth Adisman of New York University Dental Center, chosen to write the chapter on "Cleft Palate Prosthetics" for the 1971 *Cleft Lip and Palate*, was trained under Walter Wright and since 1971 has worked with John Converse at the New York University Medical Center to integrate dental treatment with reconstructive plastic surgery and speech therapy. According to Adisman, there are three general types of prosthesis:

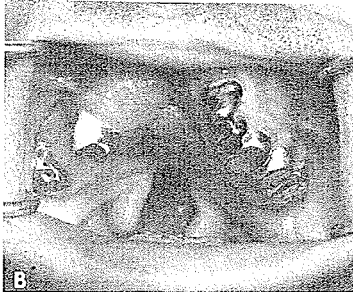
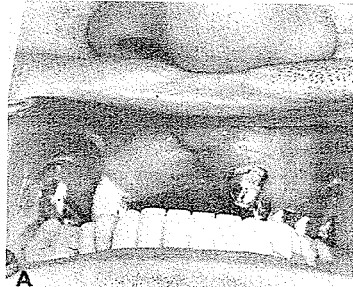
Kenneth Adisman

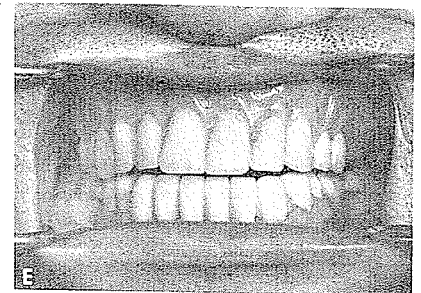

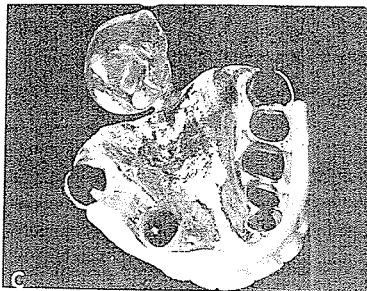
1. The fixed or immobile prosthesis which remains stationary, permitting the palatal and pharyngeal musculature to contract and function against its lateral and posterior surfaces. This is the accepted type for prosthetic therapy.
2. The hinge or moveable prosthesis popular in the nineteenth century which attempted to imitate the soft palate but was too complicated and difficult to make and maintain.
3. The meatus type extended into the nasal cavity instead of the pharynx with an airway provided by a perforation of the nasal extension. This type is indicated for unrepaired hard and soft palate clefts.

Adisman considers prosthetic intervention indicated for feeding aids and where surgical closure is not deemed advisable or practical because of poor health, extensive clefts, lack of local tissue, collapsed arches or failed surgery, or in conjunction with surgery. He forwarded examples of his cleft palate prosthesis. The modern standard prosthesis is composed of three parts:

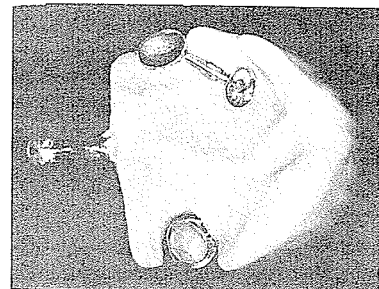
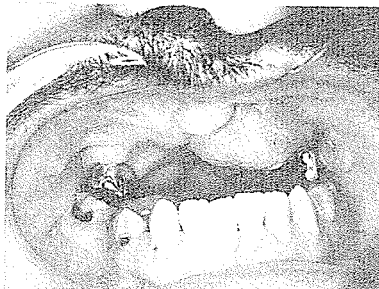
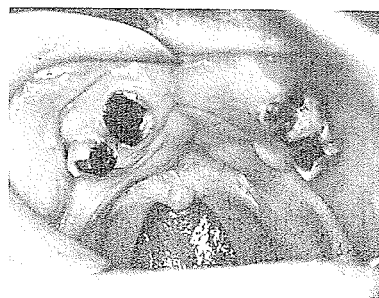
1. The maxillary section, a simple acrylic resin base covering the hard palate and retained on the teeth by flexible gold wire clasps.

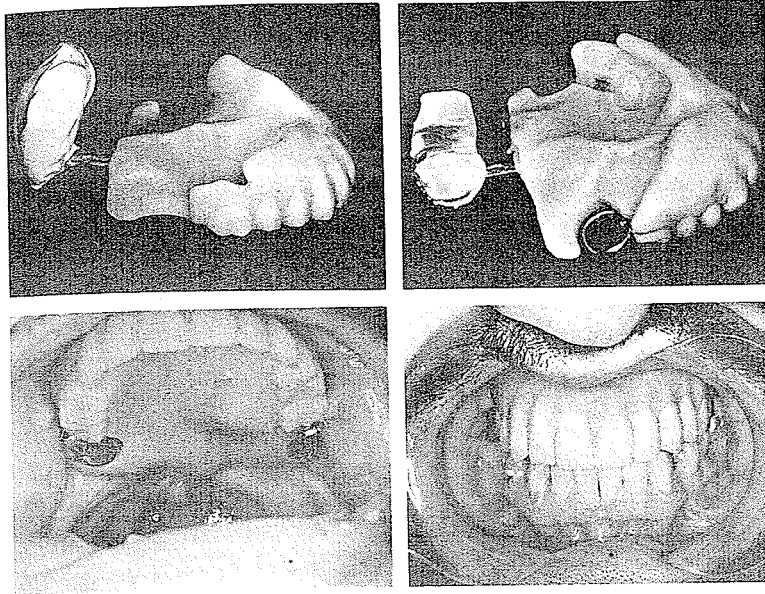


2. The palatal extension section, a cast metal bar that traverses the length of the soft palate and ends in a loop for retention of the nasopharyngeal section.
3. The nasopharyngeal section, which ends in a bulb of the required size, depending on the deformity. It is usually made of a clear methyl methacrylate resin so that irritation of the pharyngeal mucosa can be detected. It must be large enough to provide a velopharyngeal seal during phonation and swallowing, but not block the nasal passages for respiration. In unoperated cases, most pharyngeal bulbs are situated high in the nasopharynx, with the lower area of the bulb in line with the posterior nasal spine and palatal plane. In postoperative cases the bulb is generally placed lower in the nasopharynx because the velar tissue aids in partially closing the velopharyngeal port but not so low as to be dislodged by the tongue during swallowing.



With the same artistic streak that attracts him to the beaches for seashell collecting, Adisman constructs cleft palate prostheses as shown to improve both function and appearance, to help the patient "in taking a useful role in society."

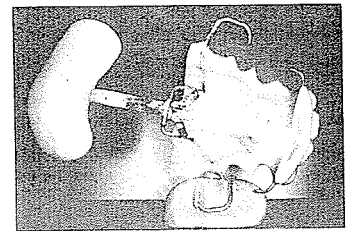




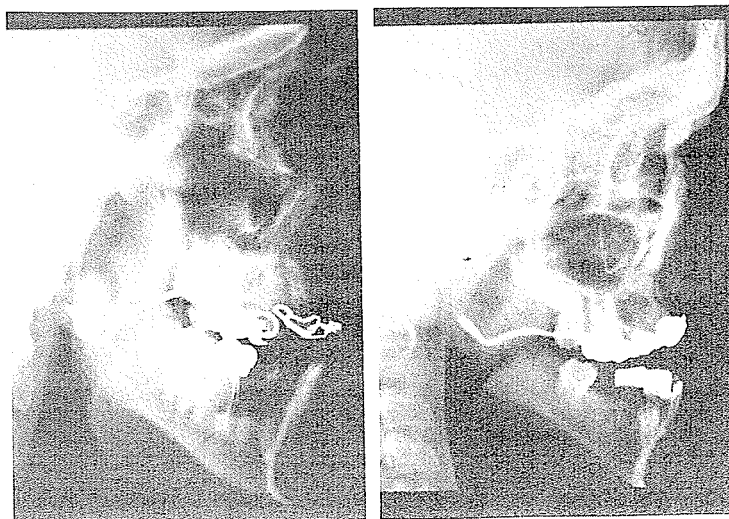
Prostheses can be constructed as appliances for palatal training, stimulation or lifting. S. Berkowitz of the University of Miami expressed his thoughts about a speech aid prosthesis:

Aram and Subtelny report that when the synergistic behavior of the velar and pharyngeal musculature is inadequate in creating sphincteric type of lumen closure (velopharyngeal closure), speech can be assisted by a prosthetic aid. The speech bulb (pharyngeal extension), usually constructed of acrylic resin, must conform to the dimension, shape and position of the velopharyngeal opening which exists during function. Therefore, the proper positioning of the pharyngeal section is critical to prosthetic success.

Prosthetic failures, that is, those which do not improve speech, result when pharyngeal sections are inappropriate in size, shape or placement.



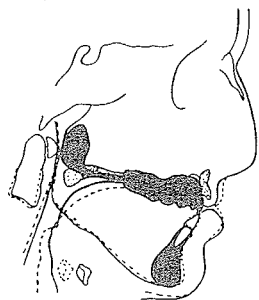
Speech aid appliance. The three parts: (1) speech bulb connected to (2) denture by (3) shank.



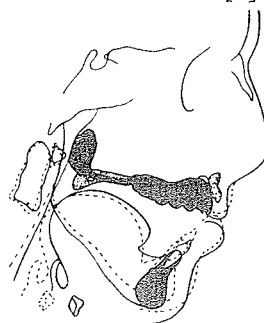
Competent speech aid appliance

They state that velopharyngeal closure is closely related to the palatal plane. From 4 to 8 years of age, it is slightly below the palatal plane; after 9 years of age, contact is slightly above the plane. Also, the anterior tubercle of the first cervical vertebra is a poor landmark for the placement of the pharyngeal section. The pharyngeal section must make contact with the posterior pharyngeal wall and be contacted by the muscles of the lateral aspects of the nasopharynx as well as the soft palate during function.

REST



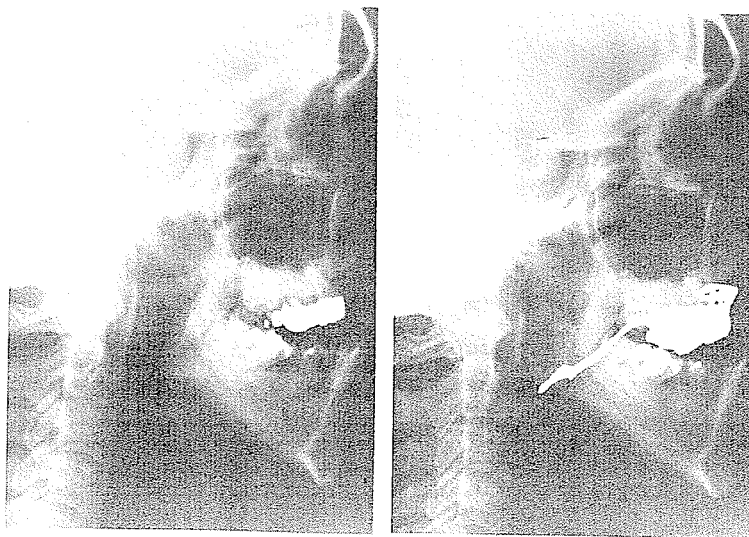
PHONATION OF [u]



Poor prosthesis ————
 Proper prosthesis ————
 Aram & Subtelny

Incompetent Speech Aid Appliance

This velum was heavily scarred and immobile. It failed to elevate on function. The maxilla was hypoplastic. The speech bulb was placed very low due to the nature of the velum and therefore failed to reduce nasal resonance. Although it made contact with the posterior pharyngeal wall and was of adequate width, it still did not function and do all it should have done to improve speech. Had it extended more superiorly into the pharynx it would have reduced nasal resonance.

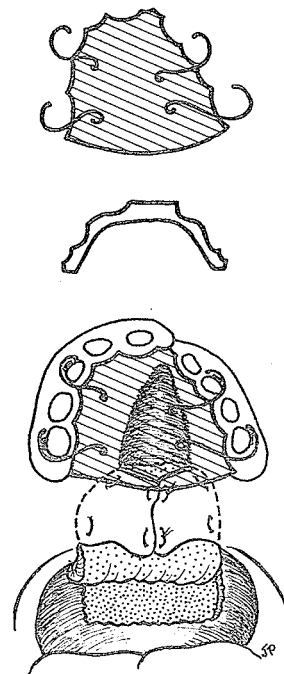


VARIATIONS IN COMBINED USE OF OBTURATOR AND PHARYNGEAL FLAP

In 1958 in the *American Journal of Surgery* Richard Webster, with Quigley, Coffey, Querze and Russell of Brookline, proposed the early use of an obturator to close the cleft of the hard palate in order to avoid surgery of this area until the age of 5 to 8 years, as earlier surgery was coming under scrutiny as a possible cause of maxillary growth retardation. At the same time, in order not to impede speech development, Webster closed the soft palate with the aid of one of his wide, superiorly based pharyngeal flaps.

In 1973 Tomohiro Shigematsu of Tokyo Dental College, after an extensive study, concluded:

The above results indicate that pharyngeal flap surgery and speech aid improve the hypernasality and dysarthria of cleft palate patients with nasopharyngeal incompetence. Speech aid is less effective than pharyngeal flap surgery for improving speech, but it seems to be useful to set a speech aid before pharyngeal flap surgery in order to improve postoperative speech results.



TEMPORARY OBTURATOR AS STOPGAP PENDING POSSIBLE LATER SURGERY

Robert W. Blakeley, a tall, lanky lad growing up in the Michigan outdoors, got to college via the high hurdles with a strong contention for the Olympic Games. After a year and a half of law school, he discovered the excitement of speech pathology and ended up with three degrees in this specialty. At the University of Oregon, he has pioneered systematic reduction of temporary speech prosthesis for cleft palate patients in whom surgery was unsuccessful. Here is a resumé of his comments in 1977:

It is important that we interrupt nasal emission early enough for each child in order that this nasal emission not interfere with development of the 16 air pressure consonants, or, that we stop the nasal air leak early enough so that errors already occurring do not become firmly habituated; early compensatory errors are usually relatively easily alterable by the patient and/or clinician if normal oral breath pressure is provided early enough, as I noted in 1972. Substantially habituated compensatory errors are difficult to "undo"



Robert Blakeley

even with formal speech habilitation procedures. The speech goal for children with repaired cleft palate should be prevention during pre-school years, not correction in grade school after habituation.

The temporary speech prosthesis can be constructed, placed and the child obturated within a period of two to seven days depending upon manageability of the child and cooperation of the parents. Obturation, of course, is the goal. Stop the nasal emission of air early enough and the child will develop normal articulation on his own or with minimal parent/professional assistance. In virtually all instances the obturator will provide normal voice quality (or slight temporary hyponasality) when it is placed in the child's mouth.

The Oregon Crippled Children's Program at the University of Oregon presently has 125 children who wear a temporary speech prosthesis in a program encompassing some 750 patients. Obturators have been provided for children as young as two years, eight months.

The obturator reduction program works something like this: Initially, an obturator, of necessity, is made large enough to eliminate hypernasality and nasal emission. This virtually always entails "overimpingement" upon the musculature of the V-P area at about the horizontal plane of the hard palate. The patient tends to "draw away" from the obturator initially, or may *habitually* relax the pharynx to produce some sounds because that has been his/her learned response. Thus one must "force" oral emission via the obturator, taking care not to impinge too firmly upon soft tissue overlying the atlas, in order to get control of the hypernasality and nasal emission. Thereafter, the recommendations are specific to consonant articulation alone. No other management of the voice is required save manipulation of the size of the obturator.

After the patient has worn an obturator four to eight months that patient is an habitual oral speaker (with the obturator in place) and is altering articulation by maturation alone, by parent assistance or by formal help from a speech pathologist. It is at this time that systematic reduction of the obturator can begin. This is carried out by the speech pathologist and dentist using a combination of speech testing (utilization of a nasal listening tube and the nasal "flutter" test), pressure indicator paste on the obturator during speech testing and oral inspection. The amount and place of reduction is thereby determined in gradual steps at each appointment (e.g., 1 to 3 mm on each side of the obturator and 1 mm from the anterior) and continues until the speech pathologist begins to detect subclinical signs of hypernasality and/or nasal emission. The reduction process is then discontinued, a model of the obturator portion is reproduced in dental stone as a permanent record, and the patient returns in approximately four months for the same approach to obturator reduction because his palatopharyngeal musculature has usually "made up" the difference by this time in an

apparent physiologic "maintenance-of-the-status-quo" for complete V-P closure. Obturator reduction continues in this fashion over six, nine and twelve month intervals until the limits of V-P compensation are approached.

Most of the patients at this point in their management have both normal voice and articulation. Thus any surgical procedure (usually a pharyngeal flap) becomes a substitute for the prosthesis in a child with normal speech. It is felt by the surgeon [V. V. Lindgren], dentist [R. M. Adams], and speech pathologist [R. W. Blakeley], as published in 1964, that the patient, because of a normal monitoring system for speech and maximally compensated V-P musculature, is a far better candidate for secondary V-P surgery for speech purposes than he would have been prior to use of the speech prosthesis.

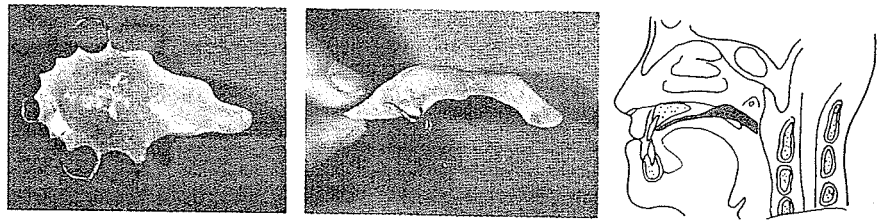
In one study by me in 1970 of 60 obturator patients, 19 percent of the obturators were reduced in size to the point of removal leaving those patients with normal voices. Thirty percent of the 60 were referred for surgical substitute with good results after it was felt that their obturators could not be additionally reduced in size. The remainder of the patients continued under the obturator reduction program.

One cannot account exactly for the amount of V-P compensation (muscle hypertrophy) in an obturator reduction program for any given patient. Some patients, no doubt, require no compensation of musculature but only need obturation and obturator reduction ("weaning") to "teach" the V-P musculature how to function optimally during speech. However, some generalizations can be made. Based upon the historical dental stone models of obturators reduced, the greatest compensation obviously occurs in the lateral pharyngeal walls and compensatory hypertrophy of V-P musculature does take place in a substantial number of patients. In the 60 patient study noted, the mean lateral reduction was 14.5 mm while the mean A-P reduction was 2.9 mm.


In 1975, in the *Transactions* of the Sixth International Congress of Plastic and Reconstructive Surgery, T. Hirose of Matsumoto, Japan, recalled that 10 years before, a case of purpura in a cleft palate had prevented early surgery. This precipitated the early fitting of an obturator to facilitate eating and speech until such time as surgical closure was indicated. Hirose's subsequent experience with the use of temporary obturators proved that they were most effective when they covered the cleft correctly and extended to the posterior pharyngeal wall. When the velar piece fitted snugly into the cleft and its tip almost touched the posterior pharyngeal wall, five out of eight patients obtained normal speech.



T. Hirose



When the velar piece, made of soft elastic silicone rubber, covered the cleft, the tip again almost touching the posterior pharyngeal wall, seven of nine patients obtained normal speech.



Hirose noted:

The proper age to begin wearing the obturator seemed to be two years, because at that time the dentition of first molars is almost finished and we can use them to hold the obturator with clasps. . . . The children soon liked to wear the obturators and they did not like to speak or eat without the obturators. . . . In nine cases of which the pushback operation was performed at a later date, all obtained normal speech by this method and all cases retained normal speech.

FOR FLOATING PREMAXILLA

A prosthesis can be used to fix a floating premaxilla. A fixed partial denture in the teenage child consists of acrylic or vinyl resin over cast gold copings on abutment teeth, and acrylic or vinyl resin pontics for the missing teeth. The result is fixation of the premaxilla to the lateral maxillary processes, a functional occlusion and normal cosmetic appearance.

OVERLAY DENTURE

Superimposed prostheses are indicated for patients with cleft palate who require occlusal and cosmetic improvement because of underdeveloped maxilla or overdeveloped mandible to correct the disharmony and malrelationship between the two, where for

some reason corrective surgery is contraindicated. Overlay dentures are indicated for

1. Patients who had premaxillary resection early in life resulting in maxillary contraction, leaving a foreshortened occlusal relationship in consequence of the lack of vertical, lateral and anteroposterior growth.
2. Patients with floating premaxillae in abnormal relationships so that maxillae are contracted.
3. Patients with lip collapse and tightness, in whom the superimposed prosthesis supports and plumps the lip for a more harmonious facial contour.
4. Postoperative cleft palate patients with few or minimal number of abutment teeth, exhibiting collapsed occlusal relationships due to inhibition of maxillary growth as compared to mandibular development.

As the prosthodontist comes to the aid of the surgeon, the surgeon can be of assistance to the prosthodontist. A scarred palate may be redivided to create a more favorable nasopharyngeal area for placement of this section of the prosthesis. Reconstruction of a labial sulcus or excision of fibrous bands and adhesions can facilitate the placement of a prosthesis. Resection of an obstructing, floating premaxilla may create a better environment for a prosthesis. And in the absence of teeth, creation of retention perforations in the mucosa may allow mucosal inserts to aid in retaining the prosthesis.

Robert Millard emphasized the importance of having the speech pathologist and the prosthodontist work together with the patient and the parents to achieve the optimal use of the prosthetic speech appliance.

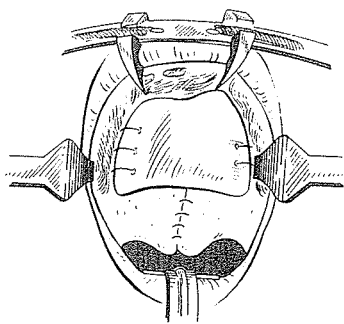
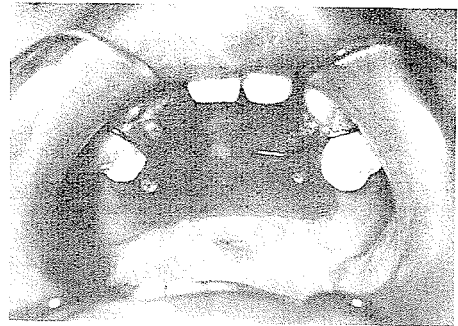
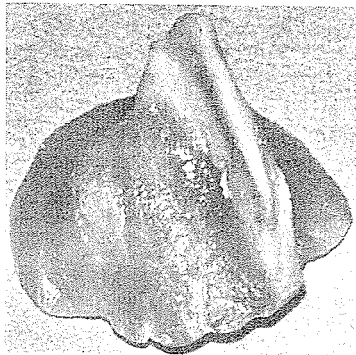
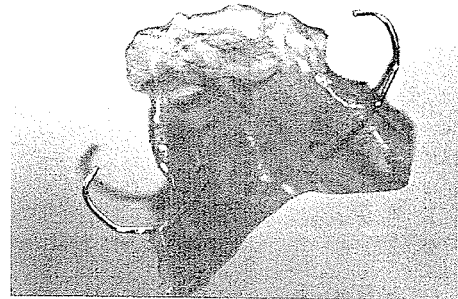
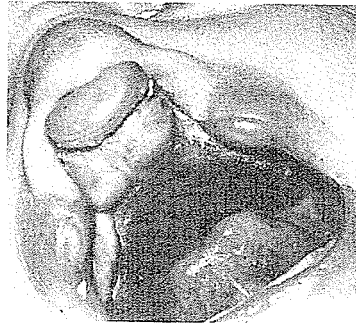
Prostheses can be of inestimable value in maintaining function while one is awaiting the optimum time, in respect to growth, for surgery. From the surgeon's point of view after that, the need for a prosthesis should be extremely rare, as it indicates either failure of surgery or unwillingness or inability to carry out adequate secondary surgery.



Libby Wilson-Mackby

Libby F. Wilson-Mackby of Rancho Los Amigos Hospital, California, emphasized the value of various prosthetics before and immediately after cleft palate surgery. In 1978 she noted:

Prosthetic devices can positively affect the outcome of surgical procedures. When placed in a neonate with a palatal defect, intra-oral appliances help to obturate the cleft. During feeding, the appliance provides a firm surface against which the infant's tongue will trap the nipple and facilitate delivery of fluids. It may also afford some protection to the delicate nasal mucosa which would otherwise be exposed to irritants from the oral cavity.



After lip closure, this or similar devices help retain position of the palatal shelves and promote more favorable maxillary-mandibular relationships. Maxillary arch form can be regulated by modifying the appliances as the child grows.

When palatal repair is performed the suture line can be protected from the infant's tongue by contouring a plastic container lid to the arch and securing this wafer in position with absorbable suture materials.