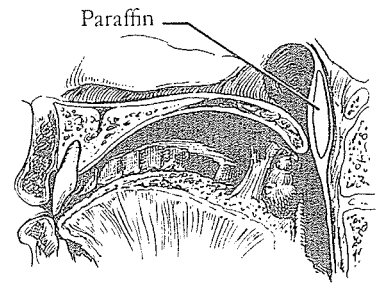


## 52. Implantation of Material into the Retropharyngeal Space

### PARAFFIN

IN 1900 Gersuny suggested the possibility of advancing the posterior pharyngeal wall to secure velopharyngeal closure by injecting soft paraffin into the retropharyngeal space. In 1904 Eckstein modified the method by substituting hard paraffin. The ill effects of paraffin injection into the retropharyngeal area with the possibility of migration and even mediastinitis were eventually pointed out by Lexer, Warnekros, Roese and von Gaza.



### AUTOGENOUS CARTILAGE

In 1912 Hollweg and Perthes first suggested insertion of autogenous cartilage into the posterior pharyngeal space by an external cervical approach. In 1928 Wardill, in his typically direct manner, suggested the transoral route for the introduction of autogenous cartilage. By 1947 Bentley had demonstrated poor long-term results with this approach.

### FAT AND FASCIA

In 1925 H. Halle used fascia for the retropharyngeal implant. In 1926 von Gaza introduced fat and fascia from the abdominal and gluteal region of adults and fascia lata in children, behind the posterior pharyngeal wall, to produce bulging. His fear of infection caused him to avoid the intraoral approach and to make the

insertion through the neck by way of the superior triangle. Dorrance recoiled from this approach, citing the skill required, the danger involved, and the free graft shrinkage inevitable as the child's pharyngeal canal increased in size. He concluded, in a characteristic, dogmatic offense, that the maneuver was not justified when there was such "a simple procedure as the 'push-back operation'" available.

## HOMOLOGOUS CARTILAGE

In 1950 Russian Lando used cadaver cartilage for his posterior pharyngeal implant.



Robert Hagerty

Robert Hagerty, a Bostonian entranced by the charm and warmth of old Charleston, works at Ashley House, lives in a nearby renovated slave quarters and has greenhouses within Confederate cannon range of Fort Sumter. He worked out a wick-in-trough watering method for his three greenhouses of geranium pots with the same concern for basic principles and careful technique that he studied cartilage and its use in pharyngoplasty. Following excellent studies on pharyngeal wall and palatal movement in normal and cleft palate patients, Hagerty pioneered augmentation pharyngoplasty in the United States. In 1960, in a continued serial in *Surgery, Gynecology and Obstetrics*, Hagerty, Calhoun, Lee and Cuttino studied human cartilage preserved in air, merthiolate and plasma. In 1961 Hagerty and Hill presented their cartilage pharyngoplasty, which placed the implant just above the atlas promontory (first cervical vertebra) at the level of greatest potential velar impact. This was accomplished through a 2 cm. transverse incision using homologous cartilage stored in air at 3° to 5°C. The implant was buried deeply under the muscle on the prevertebral fascia and the wound closed with chromic catgut sutures. In his straightforward manner, Hagerty, with Mylin and Hess, in 1969 reviewed 40 out of 64 cases of augmentation pharyngoplasty, concluding that this procedure

appears to have something to offer the patient with good palatal mobility but inadequate velopharyngeal closure. With the use of homologous cartilage as the augmenting material, one can expect gradual absorption—

with possible decrease in the anterior projection of the posterior pharyngeal wall by as much as two to three percent per year.

In spite of gradual cartilage absorption and tonsil involution, Hagerty feels that increased palatal mobility compensates adequately for the eventual loss of pharyngeal wall projection, with improved speech as a long-term result. In 1971 he told me that the difficulty of maintaining a cartilage bank has influenced him to use silicone for his more recent pharyngoplasties, and he admits an occasional extrusion of the implant. At 6 years of age, if speech and cinefluorography of the soft palate indicate a need for a secondary pharyngoplasty, it is performed through a transverse incision over the atlas promontory. A soft block of Silastic is shaped  $3\frac{1}{2} \times 1\frac{1}{2}$  and 1 cm. thick and inserted into a pocket created with curved scissors. The wound is closed with vertical mattress sutures.

While at Pawley's Island, South Carolina, in the summer of 1976, I called on Hagerty to get his latest stand on posterior pharyngeal wall implants. After the speech pathologist's evaluation and if the soft palate motion is good with no more than 1 cm. distance to the posterior pharyngeal wall, he will do an implant. The patient must be 5, 6 or 7 years old, no younger. A piece of fine silicone is fashioned at the operating table, and holes are made in it to aid in fixation by fibrous tissue invasion.

## SILICONE

Ralph Blocksma of Grand Rapids, Michigan, in 1963 suggested silicone implants for augmentation pharyngoplasty. In 1968 Blocksma and Braly did a world mail survey of plastic surgeons known to be interested in pharyngoplasty. Forty-seven surgeons out of 378 responding reported 372 retropharyngeal implants, including all types of medical silicones, ivalon, etheron, polyethylene, Teflon, autogenous and homologous cartilage, bone and dermafat. Out of 262 surgeons who perform surgery for velopharyngeal incompetence, 50 percent approved of the implant principle, 35 percent disapproved and 15 percent were undecided. Regardless of the material implanted, *speech* results in general were far *better* than tissue *tolerance* scores. Speech results were best

when the incompetence gap did not exceed 5 mm. on preoperative cinefluoroscopic examination.

In 1971 Blocksma concluded after a study of his 38 retropharyngeal silicone implants that, in general, medical silicones have shown a very high rejection rate with the possible exception of RVT Silastic S-5392 liquid, which vulcanizes into a gel in vivo after a catalyst is added prior to injection. However, like Dow Corning medical fluid MDX-44011, it is still banned from use by the Food and Drug Administration. Blocksma felt that experimentation with silicone fluids and Teflon paste held promise because of the simplicity of the injection but that it was too soon for evaluation with regard to speech improvement and tissue tolerance. Having become known for his interest in silicone work, he concluded, with his usual honesty:

The safest material at present for retropharyngeal implantation is homologous cartilage in young children in whom the palate is moveable and the deficit small.

Thus, for a time, Blocksma joined Hagerty in the use of cartilage but then, like Hagerty, switched to silicone. Yet by 1975 Blocksma was back with the paste:

In cases with minimal velopharyngeal incompetence (as shown by panendoscopic examination), we have injected PTFE paste [Ethicon] behind the posterior pharyngeal wall with a Lewy syringe, as an outpatient procedure. An average of two to 6 cc is implanted, depending on the preoperative panendoscopic findings.

#### TEFLON

Teflon injection of the paralyzed vocal cord has been studied since the early 60's. In 1962 G. E. Arnold and in 1963 R. B. Lewy reported dramatic restoration of vocal function by the injection of the paste into the paralyzed vocal cord. In 1964 Lewy injected Teflon into the posterior pharyngeal wall of one patient with neurogenic velopharyngeal incompetence and obtained improved speech. In 1966 Lewy reported an intracordal Teflon injection; the case went to postmortem for unrelated disease and revealed only fibrosing foreign body reaction to the Teflon.


Lewy, Cole and Wepman promoted posterior pharyngeal Teflon injection in 1965 for velopharyngeal incompetence. They used a 50% suspension of polytetrafluoroethylene in glycerine (Ethicon PTFE) with the consistency of toothpaste, which was injected through a 17-gauge needle on a special pressurized Lewy syringe. Ward and Wepman confined the injection of the Teflon paste to the submucosa and superior constrictor muscle, forming a ridge across the posterior pharynx using 4 to 30 ml. per injection with a maximal total amount of 98 ml. per ridge.

At the 1967 International Congress in Rome, Charles Bluestone, R. Musgrave and B. J. McWilliams of the University of Pittsburgh reported that since 1964, 27 patients between ages 5 and 82, who revealed hypernasal speech, good levator activity and near velopharyngeal closure (3 mm. gap), had been submitted to Teflon injection pharyngoplasty. Under general anesthesia with a Jennings mouth gag aided by a Love palate retractor, the patient received 10 to 20 ml. of Teflon paste via a Lewy syringe and No. 18 needle submucosally, just above the tubercle of the atlas on either side of the median raphe. The amount was determined by the specific patient need. Of the 27, 16 revealed absence of hypernasality, 11 had improvement, and 5 of these after a second injection were successful, with one failure. The conclusion:

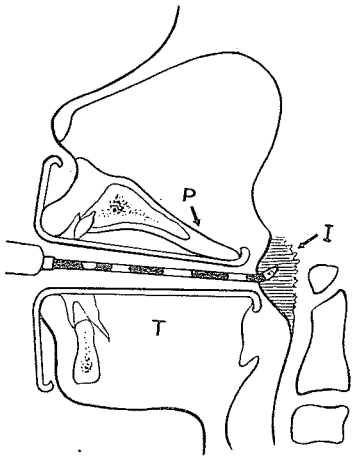
Teflon is an excellent implant material for the correction of velopharyngeal insufficiency in selected cases. It is doubtful whether this procedure is beneficial in patients with poor levator function or a large velopharyngeal gap.

In 1971 James Calnan of London, in an effort to avoid his usual autogenous costal cartilage operation and obtain an implant for treatment of nasal escape following removal of tonsils and adenoids, used Teflon implants cut to size in four patients. In every instance the material was extruded after months with a well-healed pharyngeal wound. He reported that solid plastic implants suffered the same fate.

Howard S. Sturim of Brown University, Providence, Rhode Island, who likes to sail his Pearson 36 along the East Coast, was attracted to plastic surgery by Robert McCormack and to cleft surgery by Ross Musgrave. In 1972 Sturim and C. T. Jacob, Jr.,



*Howard Sturim*



reported in *Plastic and Reconstructive Surgery* on 23 patients with velopharyngeal insufficiency treated by Teflon injection pharyngoplasty from 1968 to 1970. Patients selected were those with cineradiographs demonstrating a gap less than 1 cm. between the soft palate and posterior pharyngeal wall during attempted vowel closure, regardless of levator activity or intelligence level. Sturim and Jacob used a Lewy syringe with a No. 18 needle and had good results with 12 patients, improved results with 10, and no change with one. They also made an interesting suggestion:

[The procedure] can be used, also, as a supplemental treatment in patients in whom an unsuccessful pharyngeal flap has been performed.

At the Montefiore Hospital cleft palate center, a super team approach is used in Teflon pharyngoplasty for velopharyngeal insufficiencies no greater than 4 mm. in diameter. Preoperative diagnosis with multiview videofluoroscopy (lateral, frontal, base, and left and right oblique) and flexible fiberoptic nasopharyngoscopy defines the exact location and size of the velopharyngeal gap. On a part-day admission under local anesthesia (sedation and topical 3% cocaine) the patient, as young as 7 years, is placed in supine position. Otolaryngologist Charles Croft, at Pigott's personal suggestion, introduces a nasopharyngoscope and confirms the gap site marked by surgeon Avron Daniller with methylene blue. The needle is inserted submucosally in the chosen spot and Teflon injected (3 to 7 ml. with maximum 8 to 9 ml.), as seen through the nasopharyngoscope and recorded by speech pathologist Robert Shprintzen during the patient's phonation. An extra 1 ml. is added for good measure. For small central gaps in the velopharyngeal sphincter, the Teflon is injected in the posterior pharyngeal wall. In the presence of an active Passavant's pad or adenoid mass in position of valving, this procedure is not used. For a unilateral deficiency, unilateral injection is made, and for an insufficient pharyngeal flap, Teflon is injected into the actual flap.

Postinjectional complications have been minimal but include slight temperature rise, localized pharyngitis, sore throat (one week), stiff neck (one week) and localized edema. In 1977, 20 patients with follow-up of five months to two years, with nasopharyngoscopic examination every three months, were reported as

revealing no significant shift of Teflon from the injection site, only rare diffusion and no speech relapses (once hypernasality eliminated, normal speech maintained).

Daniller, originally of South Africa, was brought to Stanford University by Robert Chase. In 1977 he wrote from Montefiore Hospital, New York:

The technique of combining the injection of Teflon with simultaneous observation through the flexible Fiber-optic nasopharyngoscope for its precise placement has proven to be most rewarding. I have to issue a word of caution, however, in that the FDA has not fully released this drug, and it is still listed as investigational.


In 1977 Leonard Furlow, W. Williams, K. Bzoch and C. Eisenbach of the University of Florida, Gainesville, reported retropharyngeal injection of Teflon paste in 36 cases (28 with operated or short palates showing mobility and a gap no more than 8 mm., and 8 with nasal emission long after a pharyngeal flap). The success rate claimed was 74 percent in the operated or short palates and 63 percent in the failed pharyngeal flap group. Most cases were corrected by one injection, a few by two injections and none by three. Several patients not improved immediately after the injection improved later, but all who revealed immediate success maintained it. One bolus was extruded. Serial cine speech studies allowed measurement of the posterior pharyngeal wall advancement and the permanence of the Teflon pad with an injection projection of 6.2 mm. lasting as long as seven years.

#### VACILLATION BETWEEN CARTILAGE, TEFLON AND SILICONE

In 1971 the clever José C. Viñas with E. Jager of the University of Buenos Aires, Argentina, at the Melbourne International Congress reviewed his development of what he termed "pharyngeal push-forward," an analogy to Dorrance's "Palatal push-back." He first reported having used autogenous costal cartilage inserted through a transverse incision into the retropharyngeal space in 1954. The incomplete dehiscence and partial loss of the

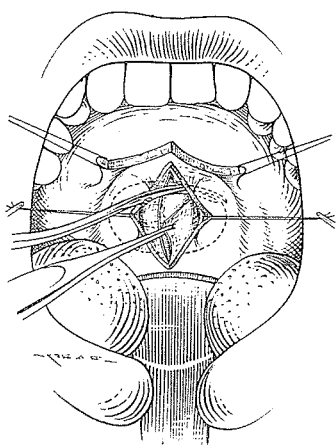


*Avron Daniller*



*José Viñas*

graft stimulated Viñas to try two vertical lateral incisions and experiment with fresh and boiled maternal and homologous cartilage, preserved homologous bone, derma-fat grafts and spongy and compact silicone. Although his life ended tragically in a train wreck long before his time, he published 13 papers on various aspects of this subject. All homologous grafts, he found, were eventually unsuccessful, the autogenous derma-fat ones were failures, spongy silicone shrank and the compact type extruded. The last four years he returned to his original choice, made 16 years before, of autogenous costal cartilage, having decided it was not the cartilage but the poor blood supply of the retropharyngeal space that was responsible for the difficulties. He described his final plan and began by splitting the velum for exposure:




A mid-line vertical 4 cm. incision is made in the posterior pharyngeal wall, using the tubercle of the atlas as reference.

Dissection proceeds laterally exposing the aponeurotic layer, which is excised over the graft bed required, and thus the muscle layer is exposed. The space is deepened towards both sides so as to reach the lateral angles of the pharynx. . . . The piece or pieces of cartilage necessary . . . are put in transversally, trying to cover the whole width of the pharynx.

He reported advancement up to 1½ cm. and for periods up to 15 years, and concluded:

Some years ago we left off using pharyngeal flaps. We believe they have been excessively used. Perhaps some day the last ten years will be remembered as "The Flapping Sixties"! In the great majority of cases they give no better results than those obtained with the technique or association of techniques referred to in this paper.

In 1973 Raymond O. Brauer of Houston, the home of two famous domes, the Astrodome and the Cronin Silastic breast implant, reported the use of a lesser dome in the form of a "pillow" in the retropharyngeal area in 26 patients. This implant, a Dow Corning Silastic bag slightly underfilled with Silastic gel and covered with Dacron wool, was made in two sizes—a large one (1.5 × 2 × 0.6 cm.) and a small one (1.5 × 1 × 0.6 cm.). Through a 1½ inch lateral longitudinal incision where one incision of a pharyngeal flap is usually made, he dissected the muscle from the prevertebral fascia, cutting fibers necessary to





create a pocket toward the base of the skull. Into this pocket one or two "pillows" were implanted transversely, and the incision was closed in two layers.

In 1977 Brauer reported that since 1968 he has used the "pillow" in 38 patients, with five requiring removal because of exposure. Of 28 followed, 11 developed normal speech and 2 almost normal speech, 1 achieved closure, 10 were greatly improved, 3 improved, and 1 did not improve. He now uses an easier midline longitudinal incision, administers preoperative penicillin and has the implant in four sizes (the largest  $25 \times 14 \times 7$  mm.). He stated:

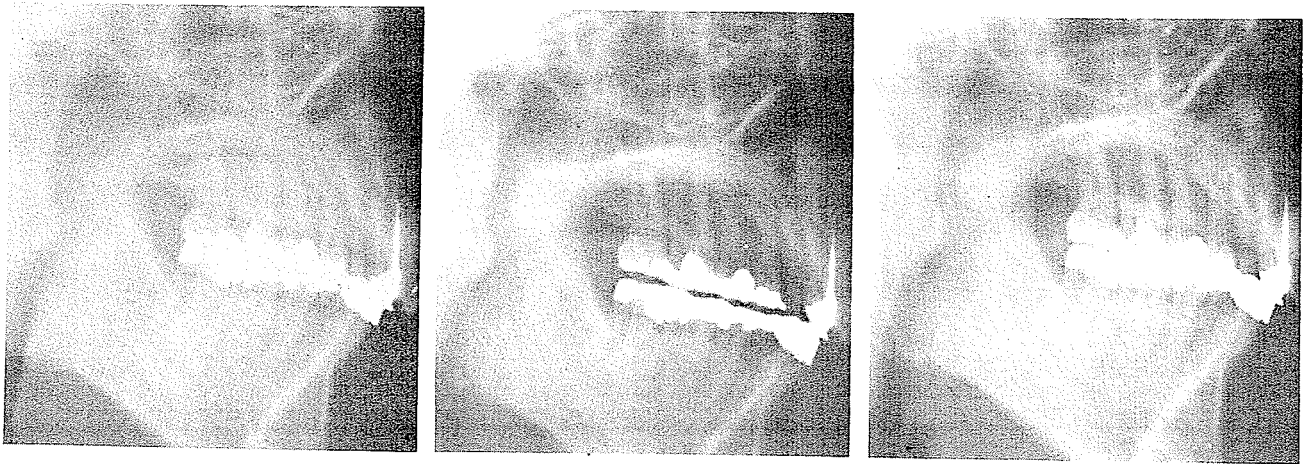This operation has its greatest place in the patient who has a little nasality and where the cine studies reveal excellent soft palate motion with a gap of probably no more than 5-6 millimeters. By moving the pharyngeal wall forward, this patient can achieve complete relief from his nasality. The operation has no place in the palate that is short and stiff or one that is paralyzed. I think there are too many surgeons doing pharyngeal flaps for a minimal defect or doing nothing when this procedure could give the needed boost.

In 1977 V. Michael Hogan, for Converse's second edition, discussed augmentation pharyngoplasty with a port size of less than 40 mm.<sup>2</sup> or with the anteroposterior deficiency less than 4 mm.:

While theoretically sound under these strict criteria, the technique itself has not been perfected in that there still remains an unacceptable degree of complications. The complications include extrusion of the implant, infection, and inferior migration with loss of the surgically restored competence. Injected fluid also has a tendency to migrate in the posterior pharyngeal area.

This general approach to correction of velopharyngeal incompetence has never greatly appealed to me. The most that can be accomplished is usually so little. Yet it can be argued that when so little is needed and a simple procedure can provide it, this is the route of choice. It is not that easy to determine the exactly effective position for the projecting mound. I have recently acquired a case in which the projection is certainly present but *far too low* to be effective, as demonstrated by Berkowitz with x-ray films showing palate at rest, vocalization of u to show ability of

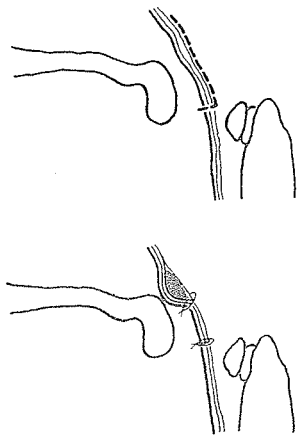
velum to elevate, and sustained vocalization of s to determine capability of the soft palate to stretch in anteroposterior length.



At rest

u

s



It is always a temptation to take the easy road to contour building by simple insertion of foreign body substance, and there is no doubt that we are getting closer to the ideal "inert" material. In the area of the posterior pharynx, however, solid implants have been notoriously unsuccessful, with a high rate of extrusion, and fluid injections are still undependable and likely to migrate. Homologous cartilage will usually absorb, and autogenous cartilage, the most reliable of the group, requires a separate operation and the extra scars. Certainly the insertion incision should not lie over the implant but be placed well below. A tacking suture through the mucosa, picking up prevertebral fascia below the implant to close the tunnel against migration, is indicated. Yet except in the "minimal" case, there are better ways.