

50. Tube Pedicles to the Palate

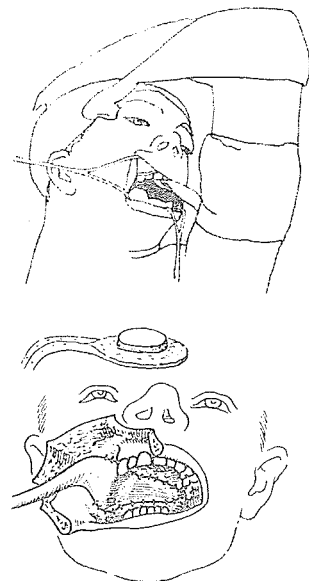
DURING the reconstruction of World War I facial injuries, multitudes of pedicle flaps were used, and as the techniques were perfected, the tube pedicle evolved. H. P. Pickerill of New Zealand, stationed at Sidcup with Gillies, claimed that he was the first to introduce a tube pedicle to the palate for traumatic loss. In 1928 he advocated tubed skin pedicles from the neck or abdominal region constructed so to close the traumatic defect with a partition covered on both surfaces with skin.

The next logical sequence of events was to be the use of the tube pedicle in congenital clefts, but this step met bitter opposition. Victor Veau of Paris severely criticized the use of these distant flaps for closure of congenital clefts, referring to such procedures as "surgical crimes" in his 1931 book. Ivy vehemently seconded this stand. Dorrance also was not enthusiastic about the foreign pedicle transfers, and Kilner would turn almost purple at the mention of putting a patient through a series of operations to get a pedicle into the palate. I recall vividly Gillies' invitation to Professor Kilner to come to Rooksdawn House to see all his tube pedicles on their way to palate clefts and how the little professor fussed and fumed over the entire situation.

Nonetheless, many surgeons have dared to transfer tube pedicles to cleft palate. In 1917 Hugo Ganzer of Berlin reported a method of closing a traumatic palatal defect by a pedicle flap from the inner hairless surface of the arm. He pointed out that he formed the pedicle of this flap into a cord before introducing it into the mouth. He also fashioned the end of the tube like a lined collar button to plug the palatal perforation, as described by Hoffman-Axthelm of Berlin in his 1975 book on Ganzer.



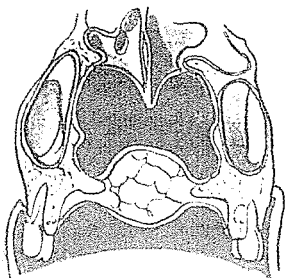
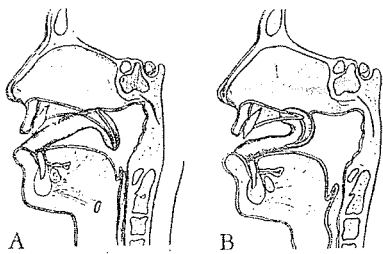
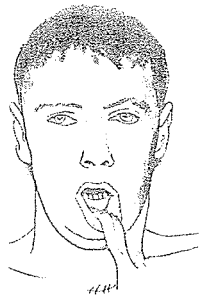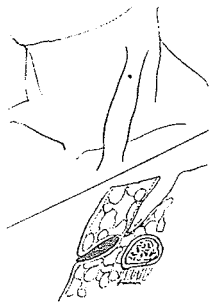
H. P. Pickerill



According to Dorrance, in 1920 W. T. Coughlin implanted a piece of costal cartilage with its perichondrium (40 by 6 mm.) into a tube pedicle of neck skin and platysma which was transferred into the traumatic palate defect successfully in five operations.



Balcombe Quick



QUICK

Balcombe Quick of Melbourne, Australia, according to Sir Benjamin Rank, was to the manor-born, probably receiving the Little Lord Fauntleroy treatment as a child, which left its touch of pomposity. Yet Quick was ingenious in dealing with residual surgical problems in World War I, conceiving the principle of exteriorizing bony cavities of the lower extremity and lining them with split-skin grafts. He was also the first to transport the tube pedicle to a cleft palate patient. In April 1928, he tubed the skin of the neck parallel to the sternocleidomastoid muscle (13.75 by 4.3 cm.). Approximately six weeks later, the upper end of the tube was severed and attached to a triradiate incision in the left inside mucosa of the lower lip. Three weeks later, in a delay procedure, a skin graft inlay was inserted obliquely across the lower end of the tube to create a lined, thinner extremity to join into the velar cleft. After further delays, the flap was detached, incised along its sides and inserted into the freshened edges of the posterior two-thirds of the cleft (A). Since there was difficulty with this attachment, Quick had to disconnect the pedicle and reverse its attachment (B), suturing only one side to the posterior two-thirds of the cleft.

Six months from the time of tube construction, the lip attachment was divided and the freed pedicle let into the posterior palate. Quick reported:

The graft was now in position and the cleft closed in its posterior two thirds. Closure of the anterior one third which had been planned as part of the last stage, had been rendered impossible by reversal of the position of the graft from A to B. It was thought, however, that a dental plate would deal satisfactorily with this deficiency in the hard palate.

The tube was "defatted," the pillars of the fauces were advanced medially toward the uvula and a denture with an obturator completed the construction.


PADGETT

Earl Calvin Padgett was trained by Blair, who considered him the greatest of his scholars. He was also a pioneer and an innovator, conceiving and developing the first dermatome and introducing pharyngeal flaps in the U.S.A., and one of the early surgeons to transport tube pedicles to the palate cleft. Evidently he was always something of a "madcap" scholar, wielding his scalpel with bold sweeping strokes which even today, during recall, cause Kathryn Stephenson to flinch slightly. Once, when a cleft palate had lost a dangerous amount of blood, he stopped operating long enough to roll up his sleeve and give his blood to the patient. It is said that he was fond of "spirits" and after a long day in surgery he would fill up, hop into his two-horse surrey, and race around Kansas City.

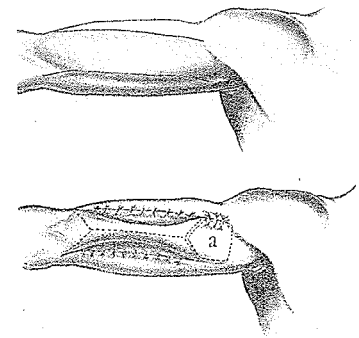
As early as 1930, and finally in his bold 1948 book, *Plastic and Reconstructive Surgery*, written with K. L. Stephenson, he advocated the use of distant skin tube pedicles for palate construction. He was never intimidated by the difficulty of the surgical problem or the criticism of such renowned colleagues as Veau and Dorrance who had expressed their abhorrence to tubes in the mouth. He recognized some of the problems of transporting tube pedicles and noted:

In the earliest cases, the mistake was made of tubing the part of the flap which was to be inserted into the mouth. Such a flap was too thick for the best ultimate result, and much more difficult to sew into the palate edges. A flat flap with a skin graft in the opposite surface was easier to sew in place the required width of raw overlap necessary. Up to the mouth the flap should be tubed, so that a flap long enough with a good blood supply is obtained.

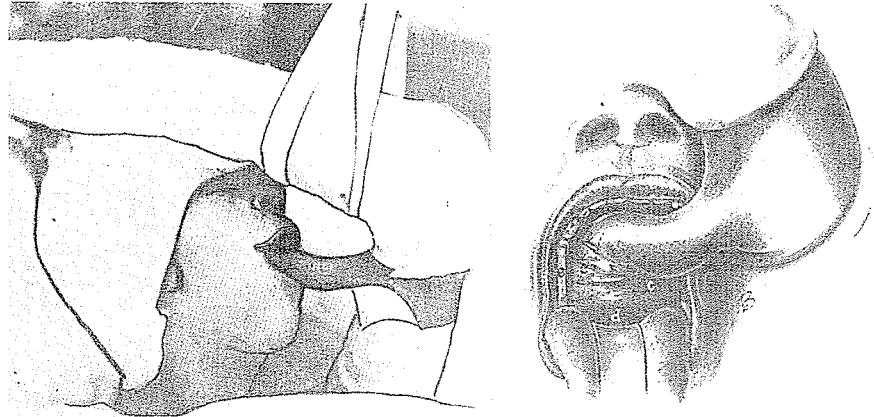
In detail, he described tubing the skin of the inside of the arm but lining the upper portion of the flap destined for the palate (a) and the total donor area with a thick-split graft. When the



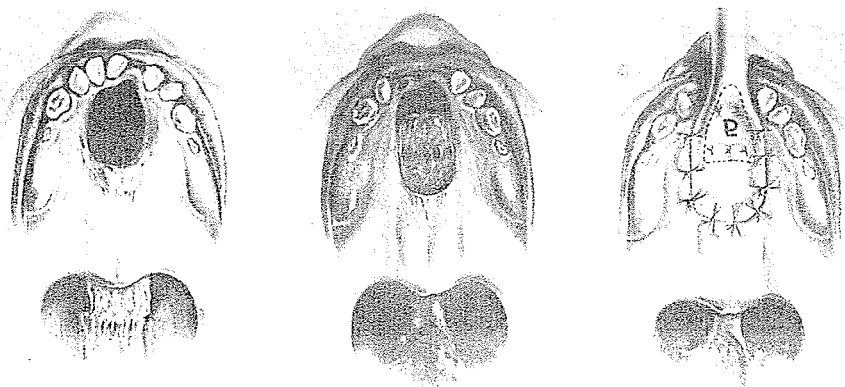
Earl Padgett



pedicle was ready for transfer, Padgett carried it directly into the mouth and attached it to the recipient site, which he prepared by turning shelf flaps up from the remnants of the defect and a pharyngeal flap forward to aid in the attachment posteriorly. In some cases, he attached the flap to a flap beneath the upper lip, which then facilitated the transfer of the opposite end into the palate defect. Once when his direct palate attachment from the arm failed, he attached it to the lip as a temporary touchdown.



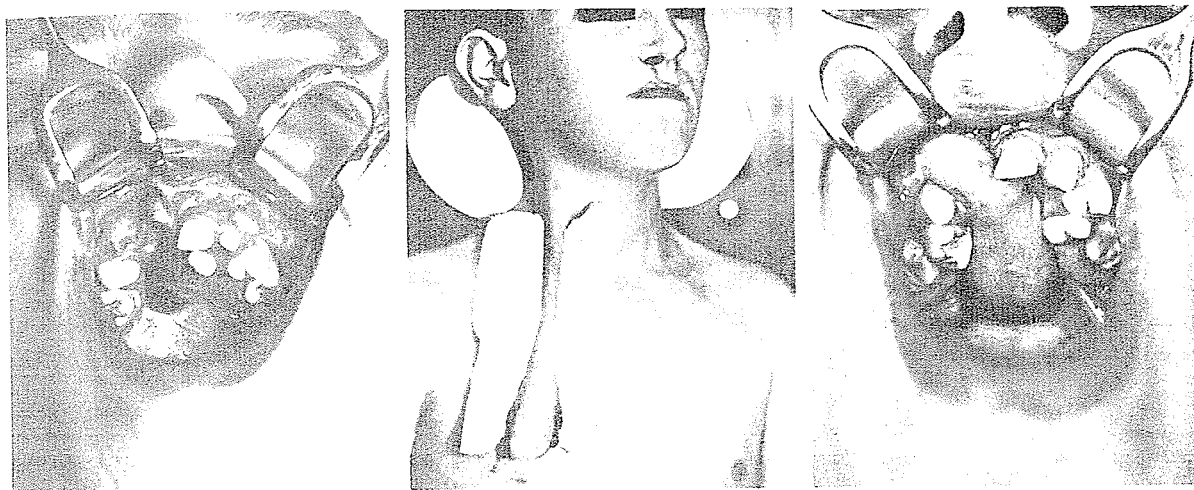
Padgett relished feats of combining various relatively rare procedures with a posterior pharyngeal flap to aid his posterior palate closure. After a local turnover flap of scar, he brought in an extraoral tube with a skin graft inlay to close and line the anterior palate hole.



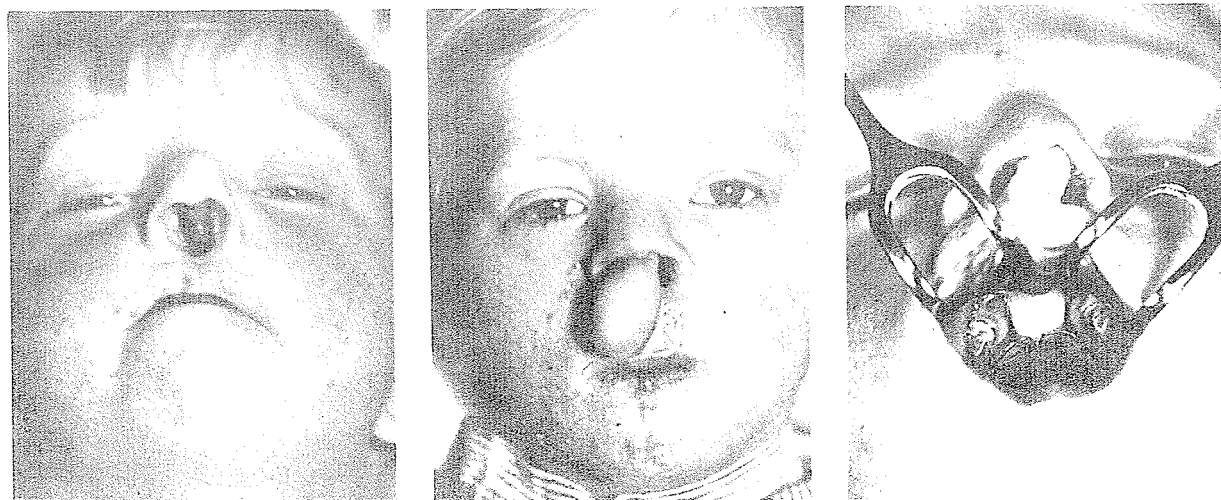
His general approach to this procedure was remarkably similar to what Gillies worked out independently many years later.

AXHAUSEN

In 1936, in his explicit little book *Technik und Ergebnisse der Gaumenplastik*, Georg Axhausen of Berlin used the tube pedicle to fill holes in fistulous, scarred secondary cleft palates. He called upon the cervicopectoral region and upper arm for donor areas and used the upper sulcus or columella site as attachment bases prior to introducing the tube into the palate defect.

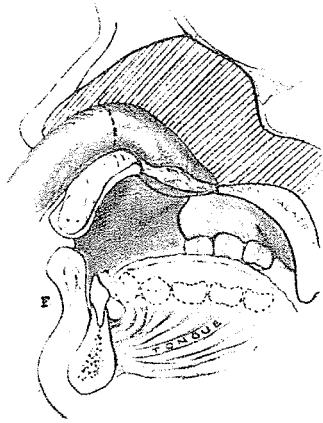


In one case, he used a tube pedicle to reconstruct the columella as well as close the large palate hole.



MACOMBER

In 1947 W. Brandon Macomber of Albany, New York, with William T. Berkeley, presented a group of U.S. Army traumatic



Brandon Macomber

defects of the face in which they used a tube pedicle from the neck for the reconstruction. They noted color, texture and thickness of the tissue, proximity to the defect, vascularity of the neck and ease of donor area closure along natural lines. One of the cases was a severe palatal defect in which the neck pedicle was introduced through the cheek defect in the nasolabial region.

Surgeons who transfer tube pedicles into the palate demonstrate a little more than the usual fortitude. Evidently Macomber's postwar pedicles to palate only tickled his courage, for in 1961 he received the Allwyn Cooper Award and in 1966 the Weatherby Big Game Trophy.

In 1967 in Nunga he shot a record elephant that served as lion bait. With his white hunter he followed the largest tracks and had just noticed that these tracks turned back on themselves when there was a tremendous roar and rush through the bush. A great maned lion, not in sight until only 10 feet away, was already fully outstretched in the air when both Macomber and the white hunter shot him in the chest. The momentum carried the beast on top of the white hunter, pinning him to the ground. Macomber had time to kneel and fire, but the lion whirled back on him and, in the mauling, crushed his left rib cage. As the white hunter retrieved his rifle, the lion attacked him again, clawing and biting, giving injured Macomber the shot he needed to drop the rogue. Both men ended up in an African hospital in Bulawayo, Southern Rhodesia, and eventually they returned to their chosen specialties.

K O S T R U B A L A

In 1950 Joseph Kostrubala of Chicago presented four traumatic losses of the palate in which he closed the defects with tube pedicles taken from the arm or abdomen, carried on the wrist. He introduced each tube through a portal other than the mouth, using the cheek, the side of the nose or the alveolar gap.

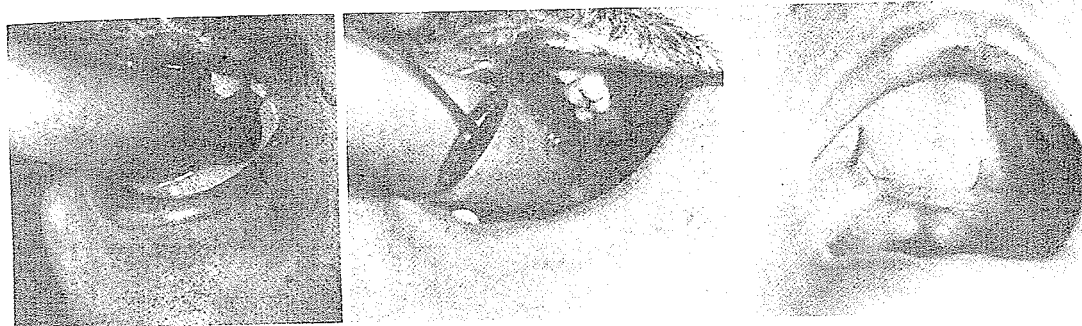


Jean Ginestet

G I N E S T E T

Jean Gustave Ginestet, a short, muscular man with an explosive speech and a quick step, started World War I as a stretcher-bearer and ended up a medical officer gas-poisoned at Verdun. He later earned both dental and medical degrees and during World War

He served as chief of maxillofacial surgery at the hospitals of Val de Grâce in Lyon and Foch in Paris, being given the rank of general in the Army Medical Corps. He was the first French surgeon to use tube pedicles, and one of his 520 papers was devoted to transplantation of arm tube pedicles to cleft palates. In his 1952 report he used the tip of the nose as a pedicle attachment on the way to the palate and left enough pedicle behind to construct the short columella. In 1967 L. Merville, a student of Ginestet, published a case of brachial tube pedicle used to close a large cleft of the palate in the manner of Ginestet.



GILLIES

There is no question that the personality of the surgeon influences his approach. Braithwaite noted in his comparison of McIndoe and Gillies:

Archie wanted to get on with the job and, I believe, used free skin-grafts because of the speed of accomplishment they afforded. Sir Harold used "tube pedicles," not only because of the skill with which he designed and used them, but also because of the arguments he could provoke amongst his acolytes. The twinkle in his eyes denied the possibility of malicious pleasure in the discomfiture of his victim. Archie always said that a person plastered with a pedicle on his face could smile behind it and betray no feelings. Sir Harold's retort was that a free-graft treatment of a face turned the recipient's face into a variegated piece of immobile linoleum.

The same criticism might be directed to tubes to the palate as their bulk and weight could in some instances cloak or choke speech.

It is interesting that it took Gillies, one of the originators of the tube pedicle, so long to come to putting tubes in the palate.

Once he got started, his enthusiasm was unbounded. He estimated that at two and a half pedicles per week he and his assistants had constructed enough tubes (like sausages laid end to end) to string the Royal Mile from Buckingham Palace down the Mall through the Admiralty Arch to Trafalgar Square and halfway up Nelson's monument. He admitted in 1953, published 1957:

It is my ambition that before my last pedicle is made, we will reach the top of this famous pinnacle with at least one pedicle left to go into the admiral's palate.

It is likely he made it, but as he said:

It is not a little embarrassing that Brophy suggested many years ago that I should put tube pedicles into palates. Indeed, in *Plastic Surgery of the Face*, 1920 (page 208), it is categorically stated that tube pedicles were inserted for traumatic losses of the palate and the method was considered normal. Pickerill, in 1928, was the first to report putting a tube into a traumatic palate defect, but it was Balcombe Quick who in 1929 first applied the principle to the congenital defect and with startling success. Today a timid murmur of approval may be heard—Bunnell, Pickerill, Schuchardt, Padgett, Kitlowski, Claoué, Ginestet and Lebourg. At Rooksdawn a combination of maxillary osteotomy and a tube pedicle replacement is now routine advice in many old cleft palate cases.

In 1953 Gillies proposed:

The palate may sometimes end up too short and too tight. Such a velum can be relaxed only by pushing it back and letting a pedicle into the defect Or go further and split the still tight soft palate, interposing the pedicle between the two halves; or even further and continue it all the way back to the pharynx, attaching it there.

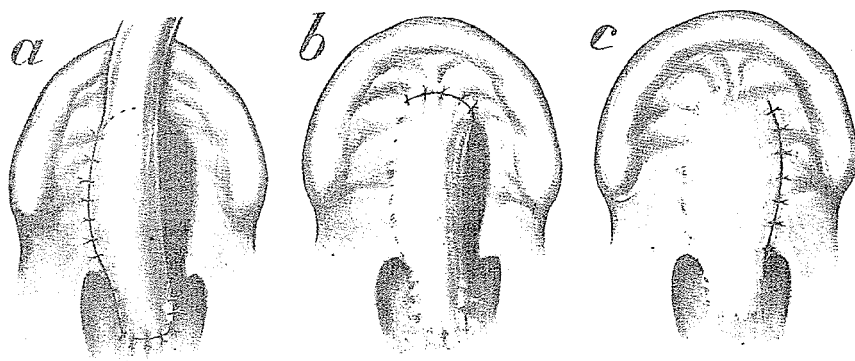
When this technique was suggested, Balcombe Quick's comment was:

Which does, in fact, out-Wardill Wardill.

Encouraged by this reaction, Gillies attacked the bogey of the intact muscular ring, admitting:

There are many surgeons who will throw up their hands in despair at the thought of introducing a non-muscular tube pedicle into a constricting muscular ring. . . . In any ordinary soft palate suture giving good speech

there must of necessity be a scar between the *two halves of the joined palate*. . . . Why should that scar not be broader, and if so, what better broad scar and what better median raphe have you than to interpolate a tube pedicle between the muscles? Attach it to the pharynx and you have a fixed raphe—a handrail from which these indifferent palate muscle halves can take purchase when closing their [now two] little sphincters.



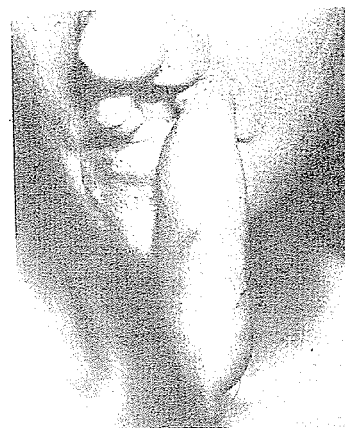In fact, Gillies developed a staged procedure which in 1967 Merville presented with excellent diagrams showing the end of the tube attached to a trapdoor posterior pharyngeal flap and one of its sides incised and sutured along a freshened side of the palate cleft (a). As soon as an adequate blood supply had been established, the pedicle was divided and set into the anterior defect (b). Later the opposite side of the tube was joined to the other side of the cleft with complete closure (c).

In *The Principles and Art of Plastic Surgery*, completed by Gillies and me in 1953, various possible interim attachments were noted, such as the lip, through a nasolabial incision as described by Schuchardt, or back of the masseter as advocated by Kitlowski.

As for the midline submental route to the palate, which would no doubt avoid accidental biting of the pedicle, we warned:

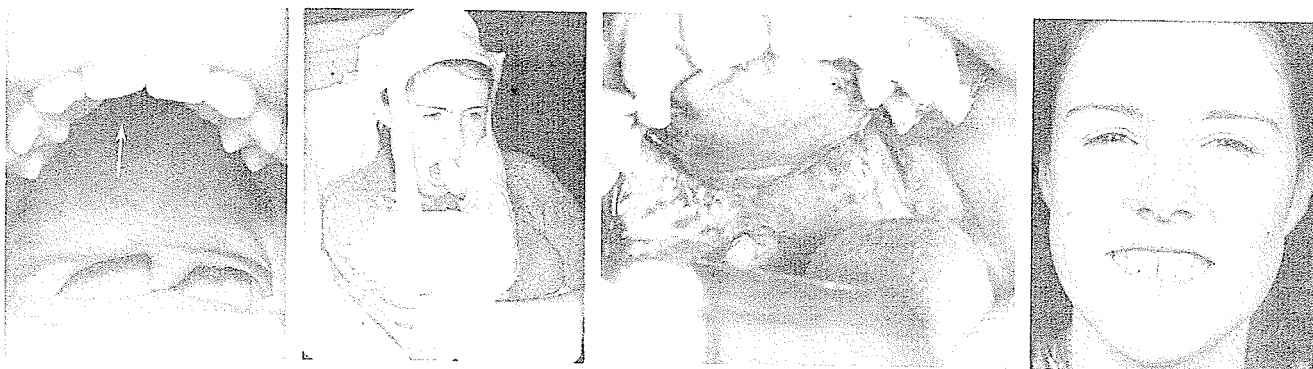
No, don't! This approach was not found practical because, although the method short-circuits the teeth, the unruly tongue pushes the pedicle off the palate.

One obvious group of tube pedicle candidates were all Gillies-Fry palate patients who had been condemned to wear a huge obturator requiring constant dental supervision, irritating the nose and lodging food. As Gillies and I wrote:

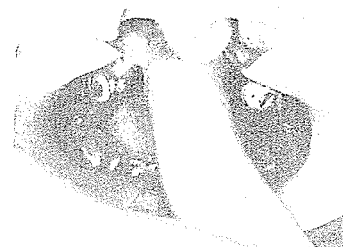
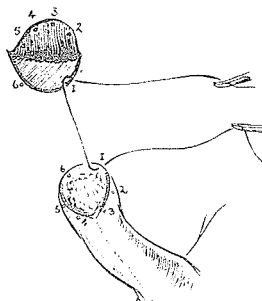
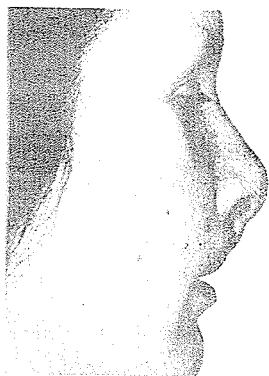
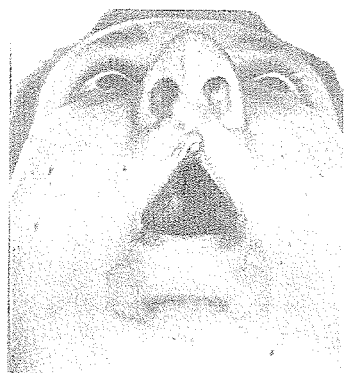


Graft in a tube and throw away the obturator so that the patient can be sick on a cross-Channel voyage and still enjoy a happy landing, eat and speak normally and kiss or be kissed without fear of being found out.


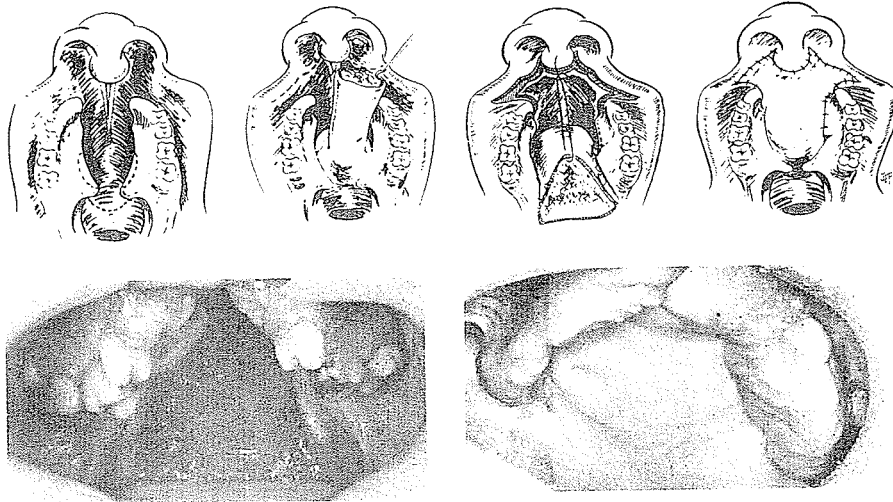
Here is an attractive young girl with lovely teeth who, because of an early Gillies-Fry palate operation, had been forced to wear an obturator. Persistent stomatitis necessitated removal of the obturator, so John Barron, then at Rookdown House with Gillies, undertook the task of filling her anterior palatal hole (arrow) with a tube pedicle, much to the relief of the patient.



This method worked well in secondary correction in adults. The pedicle was introduced through the mouth or through the nasolabial incision. Joyce was one patient so treated. She had had nine operations for a severe bilateral cleft lip and palate, but she still had a cleft and, in addition, a nasal deformity, a short, tight lip and a contracted maxilla. The lip was opened, the nose was released and a maxillary osteotomy spread the bony cleft wider. Then a pedicle tubed on her arm was passed through her mouth so that its end could be attached to a turnback pharyngeal flap. The posterior edges of the tube were incised and sutured to the freshened edges of the velum in an attempt to speed up blood supply to the pedicle.



Finally, the pedicle was divided from the arm and used to close the anterior palate cleft and assist in construction of the lip and columella base. This indeed achieved an excellent closure of a severe cleft.

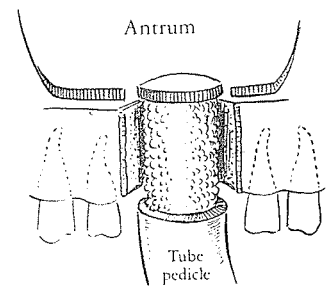


Joyce was chosen by Richard Dimbleby to give a radio interview on his "Down Your Way" program. We all crouched with Gillies about the radio, frightened at the thought of what noises might come forth. After she had overcome her preliminary nervousness she spoke very well.

Tube pedicle to plug fistula

A fistula can be plugged with a tube pedicle if there happens to be one in the vicinity. As Gillies and I wrote in our book:

The surplus end of the pedicle, lying there like a closed-off sausage, was freshened by taking off a cuff but leaving the skin dome on the top. A silk thread was drawn through the antral fistula via the nose and attached to the summit of the sausage; the pedicle was then pulled through to plug the fistula, raw surface to raw surface. This sealed off the antral cavity with the little dome of skin.



After a few trying but successful insertions of tube pedicles into secondary palates, Gillies began to consider the method for primary cases. Even in the best hands, only 80 percent of the primary palate operations resulted in normal or near normal speech. He challenged:



This leads to the supreme question. Can we, in that "other 20 percent," avoid alveolar distortion, attain good speech and have no call for an obturator? The answer lies in the introduction of new tissue, certainly, in the form of a tube pedicle, possibly—*at the primary intervention*. Or is this swinging the pendulum too far?

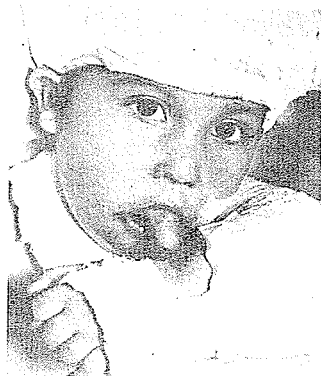A little too far!

Not all candidates, even willing ones, are suitable. This Rook-down patient is an example, as noted in our 1957 report:

A letter was received from a man with a cleft palate who explained he was not in favour of a Wardill, a von Langenbeck, a Gillies-Fry or even a Dorrance push-back—he wanted a tube pedicle! Naturally we were impressed, for this was indeed a new twist—usually the swallowing of a tube pedicle takes a lot of talking. An appointment was given, and the young accountant came in and convincingly repeated his desire. As his cleft palate was a suitable one for a pedicle, hospital admission was arranged, and while the iron was hot a lovely tube was made on his abdomen. Whereupon the patient went crazy and the next thing we knew he had admitted himself to the Park Prewett Mental Hospital next door. As he was a voluntary patient he soon became bored, signed out and caught the old red double-decker bus for the Basingstoke railway station. The last we heard of him was from one of our patients, who happened to be riding on the same bus. It seems our palate boy was passing from passenger to passenger inquiring if anyone knew how to get rid of a tube pedicle.

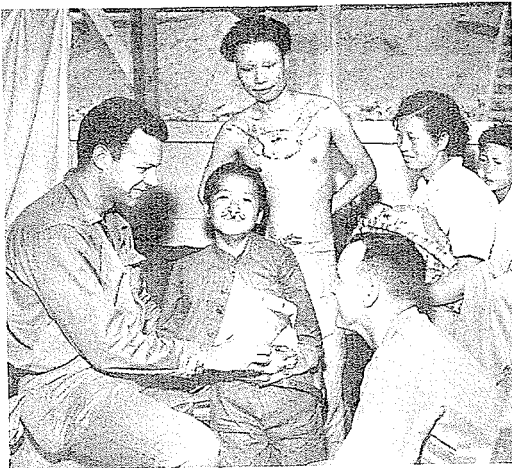
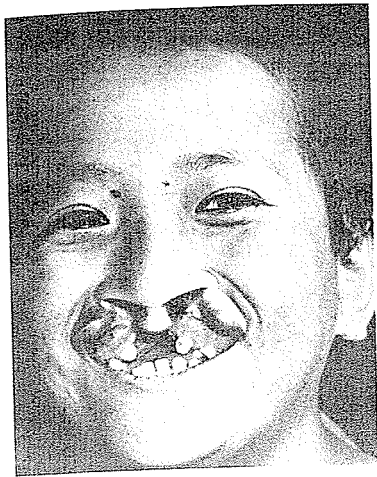
A primary case

Little Kay had a wide cleft in a short palate. A much debated and rehearsed plan to implant the tube pedicle and suture the little halves of the palate to it finally emerged. The fat pedicle not only had an indifferent blood supply but was too big for the mouth, so that suturing was unseen and probably incomplete. As we recorded in our book:




Kay was as sweet as pie, took fluids, never cried, and waved her doll at visitors. On the seventh postoperative day it was noticed that the pedicle had moved slightly out of her mouth. The pixy's little tongue had quietly pushed the pedicle off her palate. Is this a failure or a blessing in disguise, or will it merely serve as a challenge?

In 1954, while chief plastic surgeon to the First Marine Division in Korea, I was stimulated to take up Gillies' challenge by

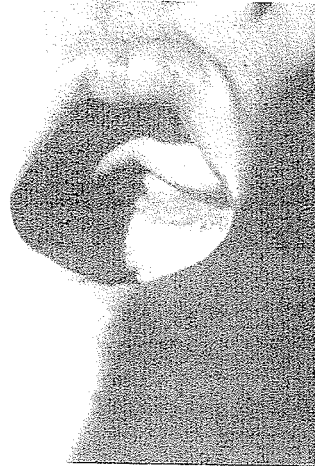
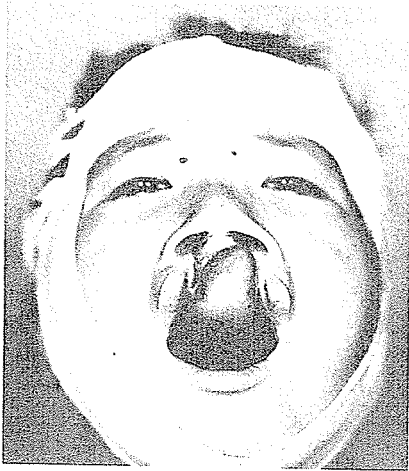

Kim Moo Uy, a 10-year-old Korean boy with a wide unoperated bilateral cleft of the lip and palate. Previous treatment by an oral surgeon had cost him his premaxilla. In addition, he revealed moderate maxillary underdevelopment. An abdominal tube pedicle was "pocketed" on the wrist and later attached to the prolabium. At this point there was a change of command and a new policy that abolished elective (?) surgery on the natives. The pedicle was detached from the wrist but left dangling at the time of discharge, as I had no intention of scrapping this pedicle, orders or not.



During the interval of his discharge Kim returned to his native village. Before his entrance into the American Hospital, he had had only a bilateral cleft lip, but now a great elephant trunk dangled from his nose. There was a noticeable slackening of native patients attending our outpatient clinic.

When a local Korean hospital became available, signs were placed for all our wandering patients. Kim found his way to Kum Chon where a pushback of the palate was followed by introduction of the tube pedicle into the anterior defect. Later the distal end was used to create an anterior alveolus-like ridge. The prolabium was shifted into the columella and an Abbe flap used



to construct the philtrum of his upper lip. Once his surgery had been completed, the patient flow started up again. On Christmas that year, for being a perfect and patient patient, Kim was presented a candy tree sent by Barbara Smith all the way from Tulsa, Oklahoma.

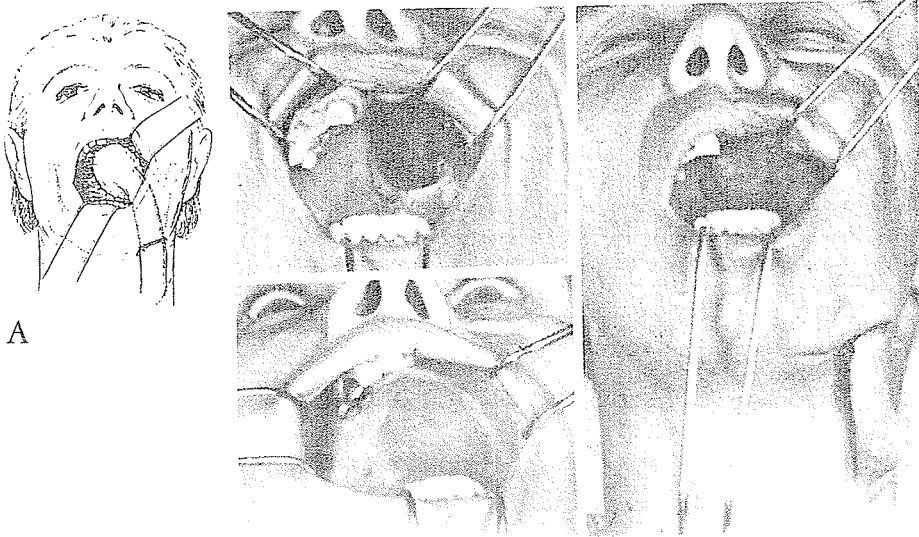
More tubes

At the First International Congress of Plastic Surgeons, held in Stockholm in 1955, there were numerous papers on introducing tube pedicles into clefts of the palate. Sir Harold Gillies and A. J. Evans of Basingstoke, England, displayed a grand group, and, with special permission from honorary committee member Mario Gonzales-Ulloa, I showed little Kim of Korea in an unscheduled presentation. There were two more official papers.

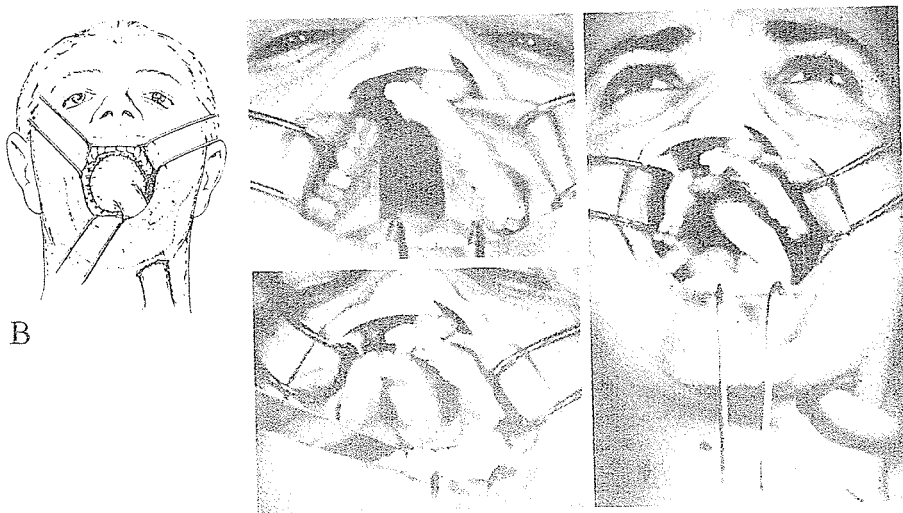
ČUPAR


Possibly as a by-product of Gillies' personal meeting with Marshal Tito and his close teaching experience with the Yugoslavian plastic surgeons, the tube pedicle had become popular in this

picturesque Dalmatian coast country. Ivo Čupar of the University of Zagreb, desirous of avoiding weeks of the uncomfortable arm-to-head attachment with the ridiculous open mouth position, advocated two possibilities. The cervicopectoral skin tube was his first choice as it could be made long enough for direct transfer into the mouth, while the acromiopectoral tube, also available, required its first attachment in the neck. Čupar recommended an incision below the lower border of the mandible. At this point the entrance could take one of two routes. If the defect of the palate included the alveolar ridge, the flap should be introduced on the buccal side of the mandible via the vestibule (A).



If the defect was in the middle of the palate with existing teeth, entrance should be made through the floor of the mouth on the lingual side of the mandible to the palate (B).





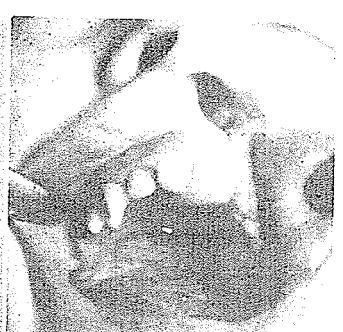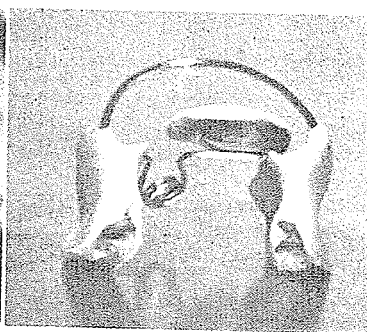

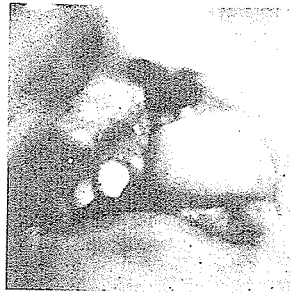
Erik Aschan

ASCHAN

At the same 1955 Stockholm Congress, P. E. Aschan of Helsinki, Finland, presented five cases in which he had used a tube pedicle from the arm first attached into the nasolabial fold of the cheek. In three of the cases, he split either the lip or the cheek to shorten the distance for his pedicle to reach the palate. He used the pedicle not only for the cleft in the soft and hard palate but also to assist in alveolar, lip and nasal construction. He warned:

The pedicle should preferably not be thicker than an ordinary little-finger or the work within the oral cavity becomes technically too difficult. . . .

For the compression and fixation of the unfolded oral end of the pedicle I have used a palate-plate.



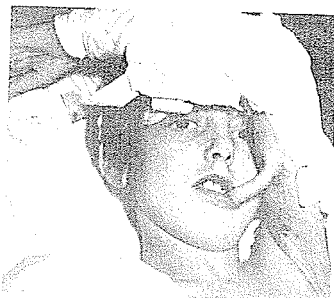Here are two case examples.



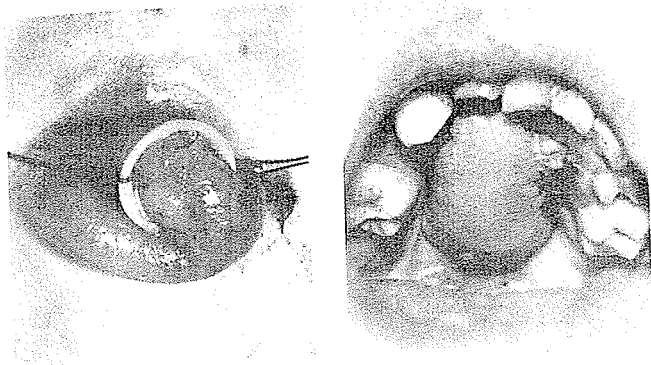
Campbell Reid

REID

Red-haired Douglas A. Campbell Reid of Sheffield, England, trained with Gillies at Rookdown House for a time when numerous pedicles were being transferred to the palate. In 1962 he presented five cases of large palate holes (over 2 cm.) which he closed with tube pedicles in three patients aged 7, 10 and 15 years. He used the inner hairless area of the upper arm for formation of the tube pedicle, which in its next stage was attached to the mucosal flap inside the lower lip near the commissure. At the time of final division of the pedicle from the arm and on its way to the palatal defect, Reid slyly slipped an acrylic sleeve like a napkin ring over the pedicle to protect it from the teeth's temptation to bite the "sausage." This was a safety ma-

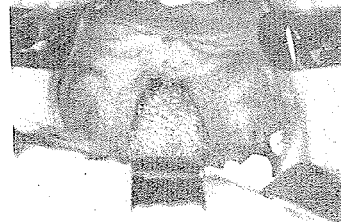
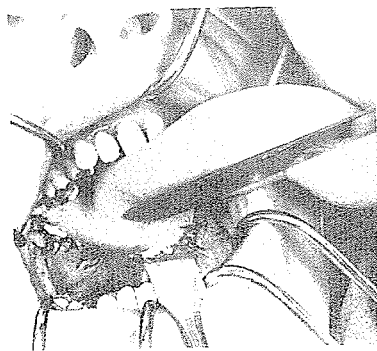
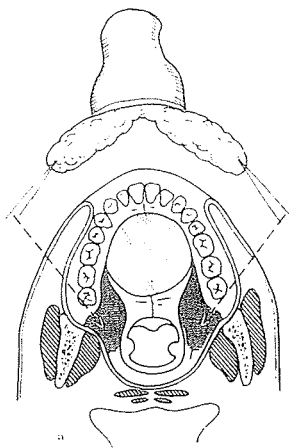
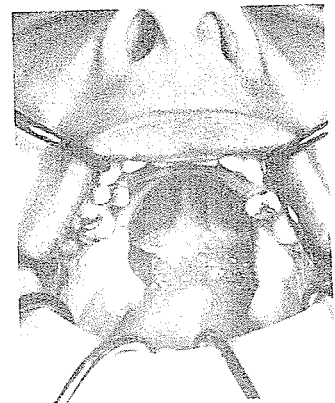


never to make the direct oral entrance for pedicles more palatable.



SCHUCHARDT

At his Second Hamburg Symposium in 1964, Karl Schuchardt presented his use of a tube pedicle to a wide cleft of the hard and soft palate in a 25-year-old patient who had had two unsuccessful procedures in childhood. He filled the parapharyngeal pouches with dovetailed adipose tissue of the end of the tube pedicle denuded of skin. The final result is shown with the soft palate at the height of phonation.



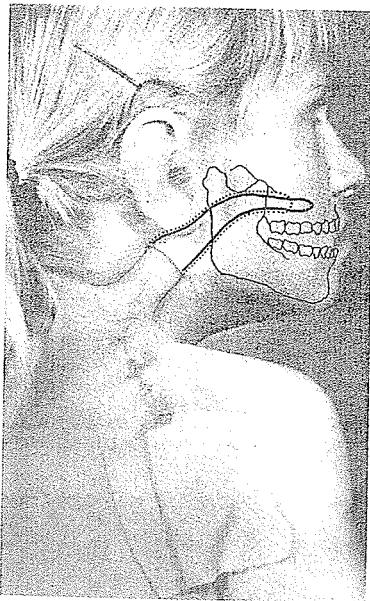
NEUNER

In 1971 Otto Neuner of the University of Berne Dental School described use of a cervicoacromial tube flap which he literally



threw over the shoulder and slid into an incision under the earlobe to pass through a tunnel medial and posterior to the ascending ramus of the mandible. Its distal end was attached to the palatal defect, and after three weeks the neck attachment was divided and spread to fill the remaining tissue deficiency. Neuner noted:

In the fourth operation, one can nicely form the palatal arch with the abundance of material present. As many cleft palate patients exhibit shortening of the velum, the velum can be lengthened posteriorly, thereby improving speech potential.



This posterior entrance calls for clever anatomical tunneling and avoids the disturbance of masticatory function or encroachment upon speech during the three weeks. It might be argued, however, that reduction in temporary discomfort does not warrant the back and neck scars or the close, blind skirting of the facial nerve.

ALMOST EXTINCT

With the modern approach to cleft palate, the need to bring in a tube pedicle monster should be almost nonexistent. It is, nevertheless, a procedure that is available in case of a rare palatal catastrophe.