

## 49. Distant Skin Flaps for Palatal Defects

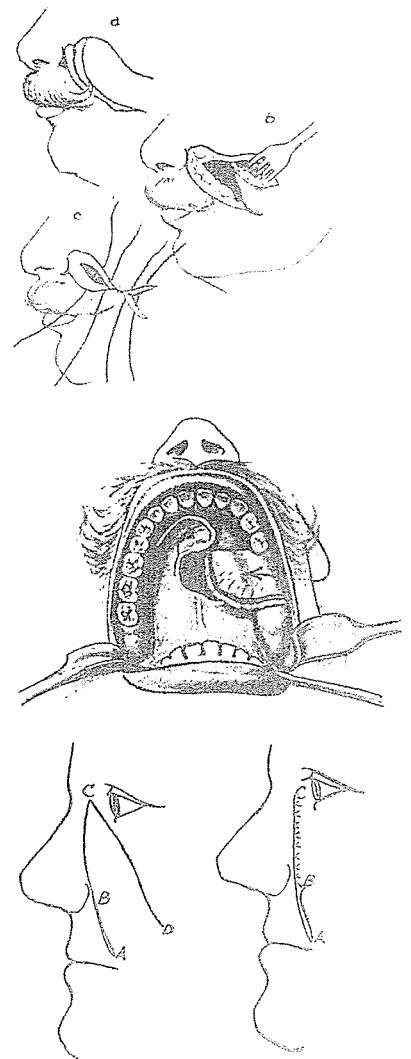
THERE have been far more distant pedicles transferred to the palate than one would ever imagine. When the primary surgery has been well executed or the cleft is standard, no such pedicle gymnastics are necessary, but severe clefts, poor surgery, failure in healing and multiple secondary procedures may use up the local tissue. As anywhere else in the body, if local tissue is not available, distant tissue must be brought in to fill the defect.

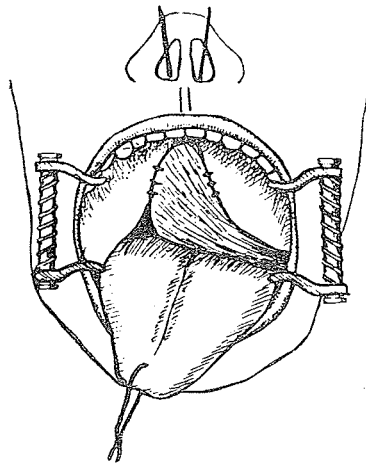
### CHEEK

In 1868 Thiersch used a full-thickness pedicle flap from the cheek to close a gunshot wound of the hard palate. The defect was satisfactorily closed, but hair grew on the palate at the site of the skin surface of the cheek flap. It is easy to imagine the patient's dismay as his small palatal mane whisked down his throat on inspiration and flew out his mouth on expiration.

In 1916 Rosenthal, finding the von Langenbeck method inadequate for large defects, designed a nasolabial cheek flap not unlike that of Thiersch with an inferior base for introduction into the palatal defect and aided by a local mucoperiosteal flap.

In 1918 J. F. S. Esser designed a nasolabial flap (ABCD), based inferiorly, incorporating the angular artery. The flap was introduced into the mouth through incision AB with the skin surface pointed toward the tongue. The borders of the palatal defect were denuded, and the flap was attached with bronze sutures. The bite was held open until the flap was well healed; then the pedicle was





divided and the cheek defect closed. In 1928 Esser was still using this nasolabial flap and described a case.

This patient had a hole  $1\frac{1}{2}$  cms. in diameter in the middle of the hard palate, surrounded by scar tissue. In this case a large massive flap, 10 cms. long and 3 cms. wide in its largest part, is cut, with pedicle in the cheek 2 cms. away from the corner of the mouth. A perforation of the cheek is made . . . and through this, the whole flap is passed, until the distant end reaches the hole in the palate, which it serves to close.

In 1918 Schlaepfer noted that Payr had attempted several times and failed to close palatal defects with a neck flap of skin and platysma muscle lined with a Thiersch graft. In 1918 he allowed the neck flap to granulate before it was transferred to the palate, fixed the flap into the cleft with sutures and succeeded in closing the defect.

In 1918, again, Kappis closed a palatal defect, 2 cm.<sup>2</sup> in size, with a neck flap lined with a Thiersch graft. The same year Kausch attached a chest flap to the tip of a finger of a soldier and covered the raw area of the flap with a Thiersch graft before transferring the flap to the palate. In 1920 Halle lined a nasolabial flap with a Thiersch graft prior to inserting it into a palate defect.

In 1930 Padgett was not intimidated by the size of the palatal hole. He used whatever tissue was available around the edges of the defect, brought in a pharyngeal flap from behind, then used upper buccal sulcus or cheek flaps to complete his two-layer closure.

In 1959 Karl Schuchardt of Hamburg used the Esser inferiorly based nasolabial skin flap to close a palatal fistula, drawing attention to the value of dividing the angular vessels near the inner canthus so they could be raised in the flap.

In 1966 Antony F. Wallace of Chelmsford, Essex, endorsed the Esser nasolabial skin flap for palatal defects and outlined the indications:

(a) The fistula is too large to close with local mucoperiosteal flaps, or these have been tried and have failed.

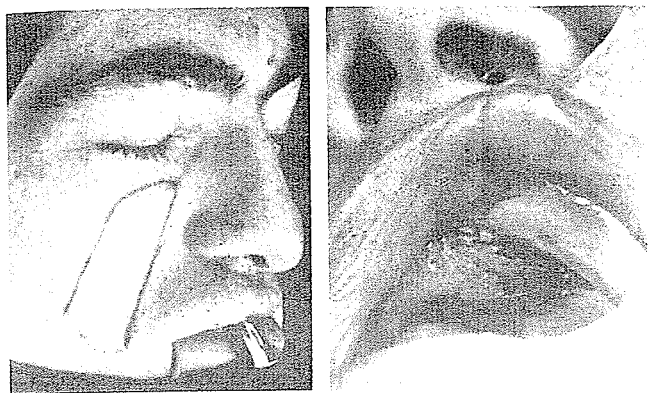(b) The patient is edentulous, or has a gap between the teeth through which the skin flap can be introduced.

(c) The upper alveolus has atrophied and the upper denture, in the absence of adequate suction, either will not stay up or slips about inside the mouth.

*Not justified  
to sneak out  
a tooth!*

(d) The beard area does not extend higher on the cheek than the level of the palate.

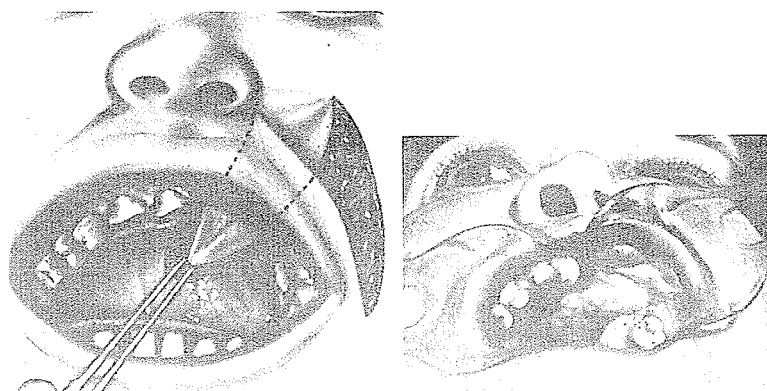
(e) The patient is prepared to accept a scar in the nasolabial line.



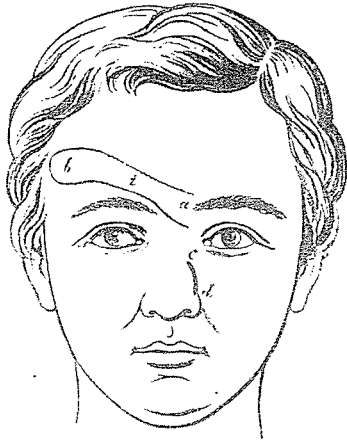
Wallace presented three cases that fit his criteria and suggested:

The nasolabial flap can reach well beyond the midline and should usually be taken from the larger side of the face when, as is often the case with old clefts, it is asymmetrical. Provided that the cheek is perforated by blunt dissection no facial nerve damage need occur. The parotid duct can always be avoided. Ectropion is not a problem and the facial scar is unobtrusive.

In 1969 Nicholas Georgiade, with R. A. Mladick and F. L. Thorne, of Duke University, endorsed tunneling the nasolabial skin flap for defects of the palate. They also emphasized the value of a superior base for this flap, noting that the flap can be wider than the inferiorly based Esser flap without fear of ectropion. If the flap is hair-bearing in the male, epilation is possible later. The flap was taken from the nasolabial fold closest to the defect and was made slightly larger than the defect. Mucosal or mucoperiosteal flaps were turned in around the fistula for nasal lining and, if this was not possible, a skin graft was used to line the flap. The



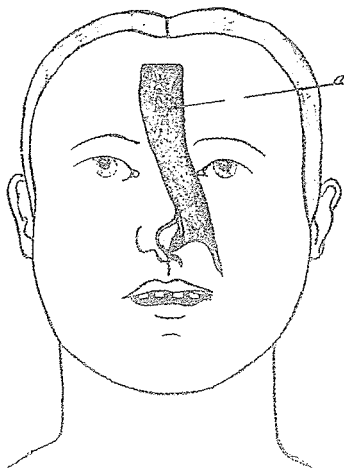
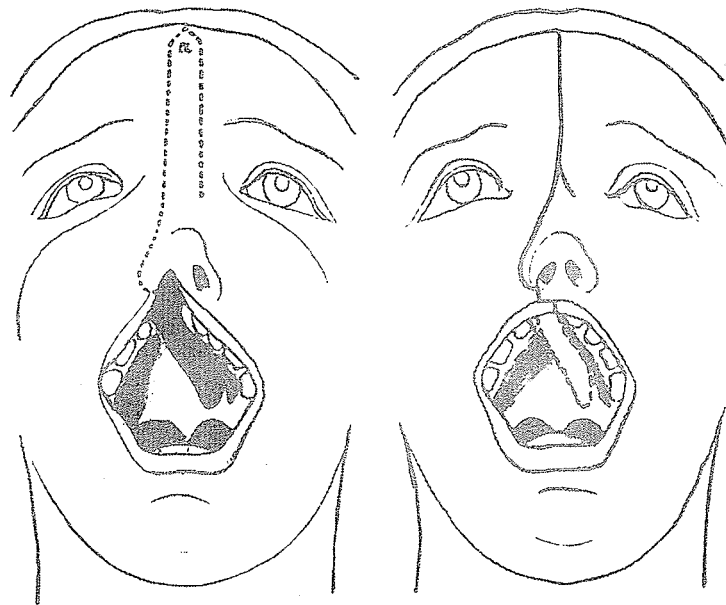
operation can be completed in one stage by denuding the portion of the base that fills the tunnel, but Georgiade prefers to divide the pedicle in a second stage. An excellent example of their approach was presented in *Plastic and Reconstructive Surgery*.



## FOREHEAD FLAPS

In 1880 Nussbaum outlined an operation similar to that of Blasius in which he used an oblique frontal forehead flap based on the medial brow, measuring 9 to 12 cm. or whatever the palate cleft required. He passed this pedicle through an incision at the lateral side of the nose to be sutured into the palatal cleft with its raw surface up. Once the flap had adhered to its palatal attachment, it was divided and returned to the forehead.

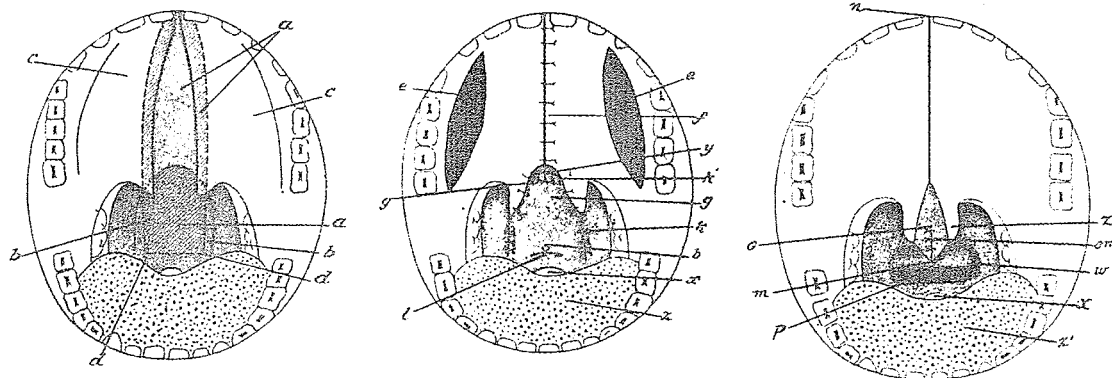
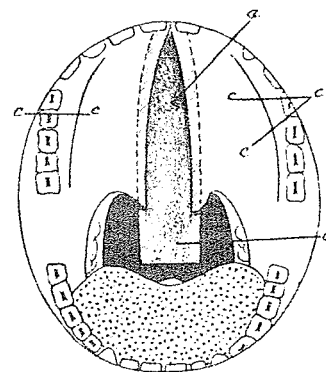
In 1889 Rotter used a midline forehead flap which he lined with a Thiersch graft eight days prior to transferring the lined



flap into a cleft in the palate. After another eight days, he divided the pedicle at the incisor teeth and replaced the remaining pedicle on the forehead.

In 1892 the German Bardenheuer described a rather complicated four-flap method of closing palatal clefts. First he turned a vertical forehead flap based on the lip, extending up between the inner canthus and the root of the nose, and fed it into the palate cleft through one nostril all the way back to the posterior

pharynx. The tail end of the forehead flap was received by an inferiorly based pharyngeal flap. The cleft edges of the palate were freshened and, with the aid of lateral von Langenbeck relaxing incisions, sutured together to overlap the forehead flap. Later the pharyngeal flap was detached and folded on itself to form a shelf-like projection on the posterior pharynx. The tail of the forehead flap was folded together to create a uvula.



This approach, although rather radical, seems remarkable for its time.

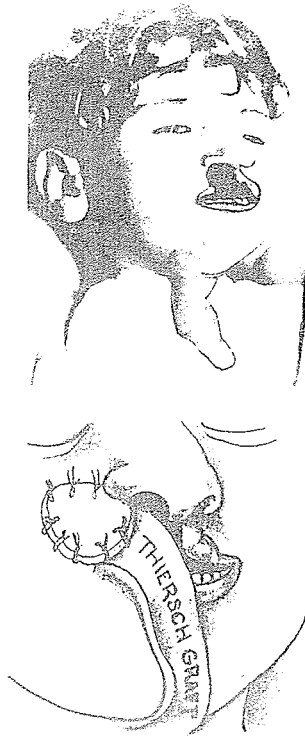
## NECK FLAPS

In 1911 Vilray Blair described a 2-inch-wide vertical neck flap incorporating skin, superficial fascia and platysma muscle which could reach the cleft in the palate with its base below the cheek. He introduced his flap into the mouth through an incision at the buccoalveolar cul-de-sac, and the defect in the neck was closed by undermining and suturing. The patient's bite was kept open while the flap was in continuity with the neck. After 10 days the pedicle was divided. Blair reported one case treated in this manner in which the velum functioned as satisfactorily as if the von Langenbeck procedure had been used.

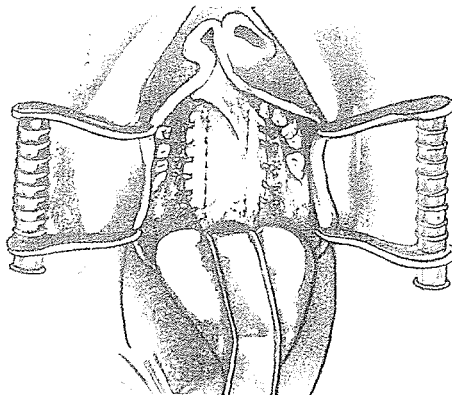
## NECK AND CHEST

In 1922 A. Luxenburger, preferring a flat plug to fill the palate cleft, bypassed the tube pedicle and used two flaps. One was taken from the skin of the neck behind the sternocleidomastoid and

over the trapezius, with its base upward and its apex at the clavicle, measuring 12 cm. wide. The second came from the chest below the clavicle, with its base upward and its apex at the anterior fold of the axilla, measuring 12 × 5 cm. The chest flap was turned under the neck flap as a double pancake and kept flat between cardboard splints. It was eventually attached to the cheek and later introduced into the palate cleft. One entire side was attached first, and the neck pedicle was finally divided to let the double flap be fastened along the opposite side of the cleft. Luxemburger suggested that bone from the pelvis or scapula might be implanted between his two flaps prior to moving the total component into the palate. Evidently he never carried out his threat.



In 1930 Padgett, trained by Blair, also used the chest-neck region as a donor area for a pedicle flap he lined with a Thiersch split-skin graft. Its first attachment on the way to the palate was on the mucosal side of the lateral lip element in an unoperated cleft lip. Next came detachment from the neck and insertion into the palatal cleft prepared for its reception by the turning of cleft edge flaps and a pharyngeal flap.



#### ARM FLAPS

In 1901 A. F. von Eiselsberg raised a long pedicle flap from the left forearm with its base at the elbow, which after seven weeks, when the edges had rolled into a tube, was denuded along its sides and introduced into the palate cleft. The arm was held up in position by a plaster bandage and the pedicle divided in 10 days, but the speech in this case was reported not improved.

*was coagulated  
tube  
pedicle?*

In 1917 Rosenthal described the use of a pedicle flap from the flexor surface of the upper arm for large palatal clefts. He folded the pedicle on its base as the first stage and later introduced it through the entrance of the anterior nares after the nose was freed and rolled upward.

## LITTLE FINGER

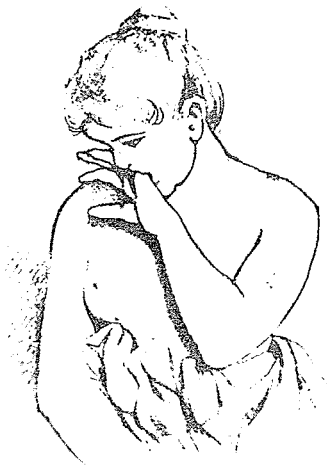Anton Freiherr von Eiselsberg, an Austrian who trained under Billroth and in 1908 became president of the German Surgical Society, in addition to using an arm flap for the palate, dared in one case to fill a palate cleft with a little finger. In 1901, in a patient with secondary bilateral cleft of the lip and palate deformities including a depressed nose and hard palate defect, he planned a procedure to correct both problems. A ventral skin incision was made the full length of the fifth finger to the metacarpophalangeal articulation, and the skin was dissected and turned back on either side, exposing the ventral surface. The flexor tendons were cut subcutaneously at the base of the finger. Then the little finger was inserted into the mouth and, guided by a suture through the skin of the nose, was used to push up the depressed nasal tip. The denuded surface of the finger was sutured as well as possible to the freshened borders of the premaxilla and septum nasi and the hand fixed with a plaster cast. At 13 days the blood supply to the finger was gradually compressed with a tourniquet, until, after 20 days, the finger was detached from the hand. A secondary procedure was necessary to straighten the flexed finger so that it could be used to fill the palatal cleft.

Quite apart from the nasal and palatal improvement, this approach has near classical overtones. The patient's position of finger into nose has artistic qualities rivaling Venus de Milo, if only with a little finger instead of an entire arm at stake. It is even possible that this is the origin of the saying "keeping your finger on the problem." I remember how infatuated Sir Harold Gillies was with the finger-to-palate procedure because of its application of the plastic principle of *replacing missing tissue with similar tissue in kind*, certainly bone for bone, if only skin for



Anton von Eiselsberg





mucosa. He was not, however, fascinated enough to threaten to sacrifice a little finger. Today this approach is more of historical interest than practical value, I hope.