

## 48. Palatoplasty with Other Tissues Within the Mouth and Nose

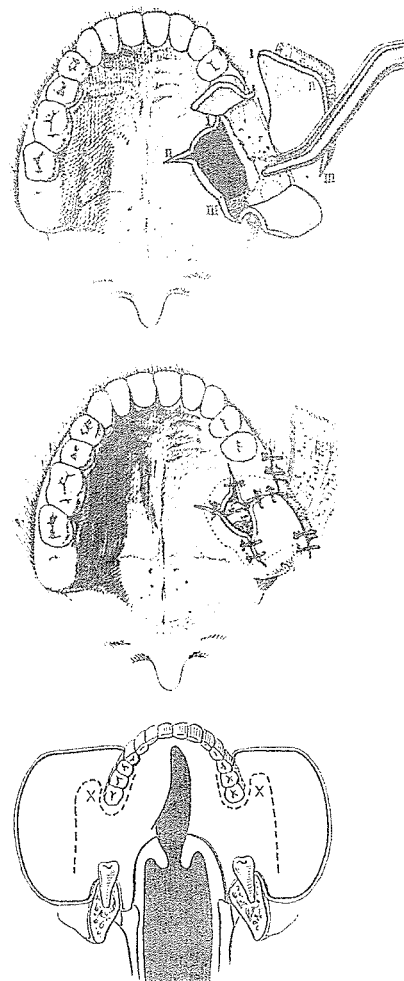
THE posterior pharyngeal wall has been the most popular donor area, with the posterior pillars of the fauces second. Even the tongue has been found useful in rare occasions. Mucous membrane flaps from the cheeks and lips have also been employed.

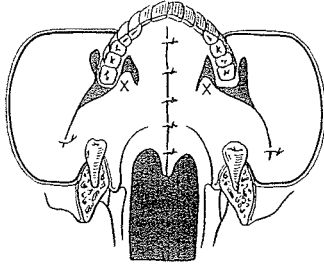
### CHEEK FLAPS

In 1829 Dieffenbach restored a velum destroyed by scrofula with a flap from the cheek. In 1862 von Langenbeck used the mucosa of the cheek as a flap to assist in partial closure of a large palatal defect. In 1869 Delorme closed a defect in the anterior hard palate by a pedicle flap of mucous membrane from the cheek and lip. In 1917 Rosenthal described the use of a quadrilateral cheek mucosal flap turned under alveolar and palatal mucosal flaps for nasal lining to a large posterior defect. He trimmed the alveolar ridge to facilitate introduction of the flaps, as shown here.

### *Blair*

In 1911 Vilray Blair of St. Louis utilized the cheek in various ways to assist in cleft palate closure. He used quadrilateral cheek flaps based medially to advance inward during cleft closure. He also designed cheek flaps (X) to transpose around the maxillary tuberosities to fill secondarily the palatal relaxing incisions necessary to close a central defect.



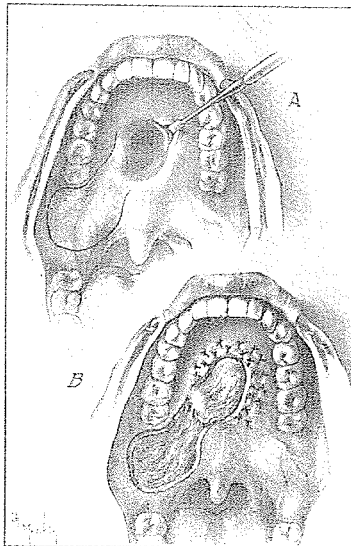
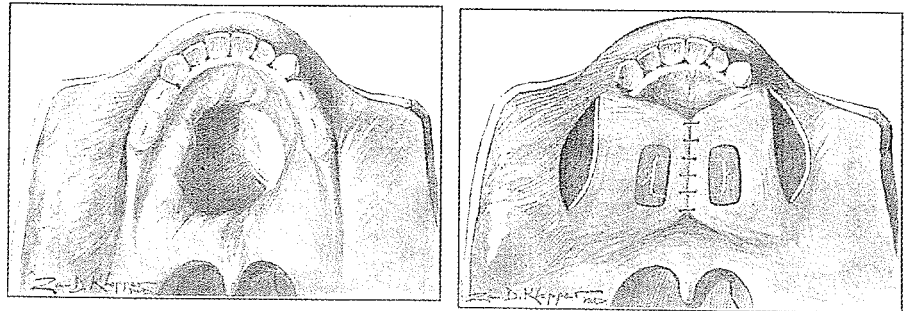


Blair's experience in primary and secondary palate surgery was most extensive, and his clear mind always allowed him to evaluate the problem logically. Usually, what he said in the early 1900's is still pertinent today. Take, for instance, this statement:

I believe the following are causes for failure in cleft palate operations: too early operation; insufficient freeing of the tissue; inaccurate approximation with sutures; destruction of blood supply by cutting the lateral arteries and, most common of all, infection.

### *Brophy*

In 1915 Truman Brophy of Chicago, in his book *Oral Surgery*, described the use of relaxing incisions in the buccal mucosa to obtain two bipedicle flaps for medial advancement to close a large hard palate fistula.



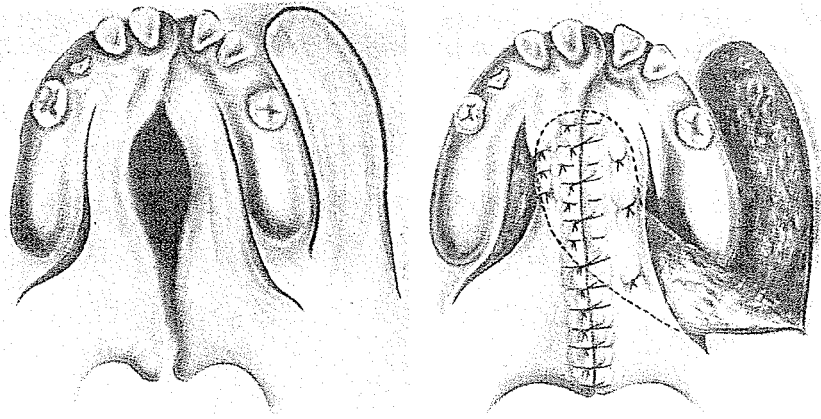
In 1923 Brophy endorsed Sir Arbuthnot Lane's use of cheek and soft palate mucosa as a long flap to be turned over, tucked into the split edge around the hard palate fistula and fixed with quilted mattress stitches. Brophy reported:

I have made these operations on many patients, nearly always with good results.


The hole was closed, of course, but imagine the scar contraction and distortion with reduction in function of the soft palate.

### *Padgett*

In the truly large secondary defects of the palate in which a part of or an entire mucoperiosteal flap had been lost, Earl Padgett of Kansas City called upon any local area available for a two-layer closure. His cheek flaps were more daring than those of Blair,



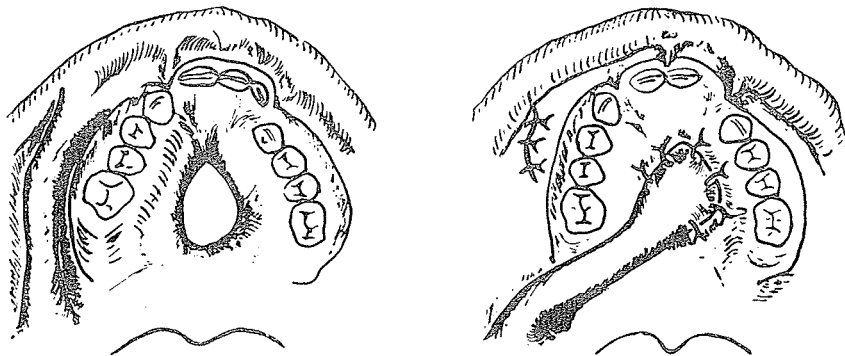
who had taught him the principles of this radical secondary work. His 1948 book with K. L. Stephenson presented some exciting local flaps. He used a lateral cheek flap based posteriorly, which he tucked under one of the von Langenbeck mucoperiosteal flaps for nasal lining during closure of the total defect. His adherence to such principles as double-layer closure particularly in the scarred palate explained his success and sometimes even justified his radical actions.



In unilateral deficiency or losses of mucoperiosteal flaps, he ingeniously used only one von Langenbeck flap from the uninvolved side and then called upon a posterior pharyngeal flap and a cheek flap. The cheek flap was based anteriorly or it was based posterolaterally, depending on the defect.

#### *Schmid*

In 1960 E. Schmid of Stuttgart advocated a cheek mucosal tube pedicle to be used to close fistulae of the hard palate.




*O'Connor*

Gerald O'Connor of San Francisco recalled in 1973:

Among the hundreds of operative procedures Gillies did while I was with him, I remember a palate case that we saw in which he said:

“Jerry, this is the rare case that surgery cannot help and should have a prosthesis.”

It was a very wide post alveolar cleft of the hard and soft palate with very little soft tissue to work with and a small, extremely angulating cleft of the bony palate. Being very inexperienced, I agreed, as to me, his word was law. Little did he or I think then that in 1931 I would conceive a method of repair using his own baby “the tube pedicle” intraorally to correct the defect.



In 1972 O'Connor and McGregor presented the method of using one or two intraoral tube pedicles of cheek mucosa (2 × 6 inches) for large secondary palatal defects. The center of the flap was left attached during the first stage of the tubing. They called attention to the fact that their original case dated back to 1931, and then presented a more modern example in which a large

secondary defect involved hard and soft palate. First the anterior palatal defect was closed with mucoperiosteal flaps. Then a left cheek mucosal tube pedicle was constructed, attached to the palate defect and later used to close the hole, resulting in intelligible speech.

In 1964 F. Burian of Prague described a mucosal flap taken from the upper labial sulcus which could be used as a second-layer closure of the alveolar cleft. This same flap, as noted by Egyedi,

may also cover a fistula behind the intermaxillary bone in bilateral clefts.

In 1976 Egyedi designed a plan for fistulae not totally unlike that of Ganzer in 1917, which described "a broad bipediced flap from the lip" to close gunshot holes "in the anterior part of the alveolar process."

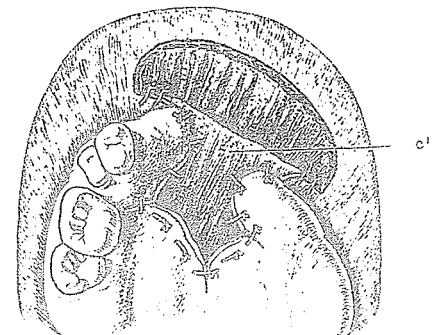
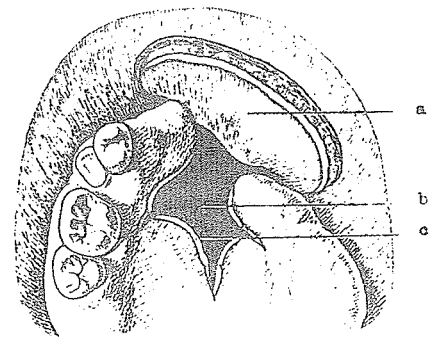
Egyedi's bucket-handle mucosal flap taken from the upper labial sulcus as thick as possible, including submucosal tissue and periosteum, was advocated for closure of difficult fistulae around the premaxilla. Egyedi reported five of these flaps with necrosis of only one and total closure of three of the fistulae.

#### *Cheek flaps for nasal lining*

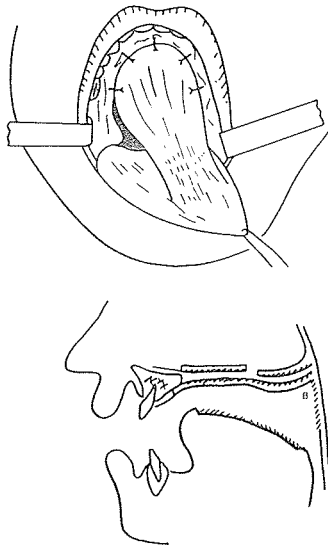
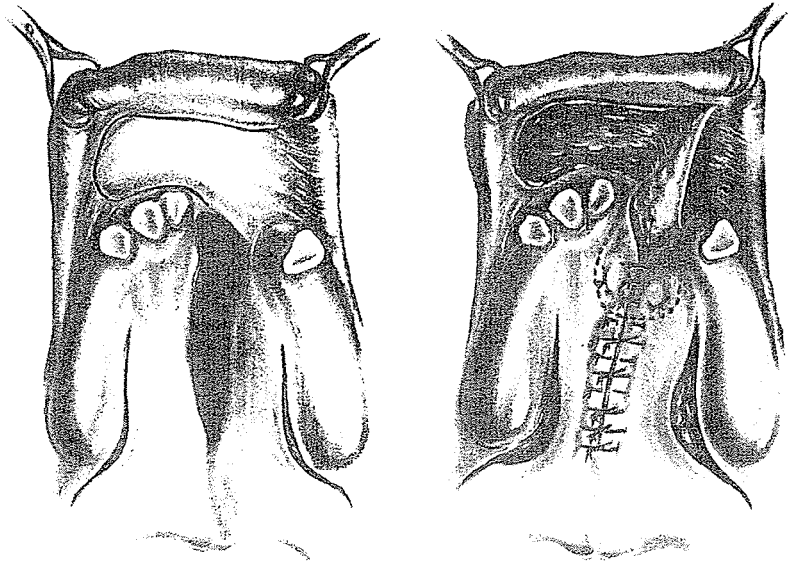
M. M. Mukherji in 1969 and A. C. Ganguli in 1971, both of Calcutta, described cheek mucosal flaps for use on the nasal and oral side of defects between the soft and hard palates after pushback. In 1975 E. Kaplan of Stanford also advocated the mucosal cheek flap for nasal lining during palate pushback.

#### LIP FLAP

In 1836 Regnoli closed an oronasal communication with a mucosal pedicle flap from the upper lip based on the cutaneous septum of the nose. In 1839 Diday reported Sanson's use of a reverse pedicle flap from the lip to close a hole in the anterior portion of the palate as a secondary cleft operation. In 1917 Rosenthal described a large mucosal flap from the upper labial sulcus (a) to be turned over into a huge anterior defect (b) and tucked under the peripheral edges (c).



Padgett in the late 1930's, as presented in his 1948 book, used an anterior sulcus mucosal flap for nasal lining of the anterior fistula in conjunction with a von Langenbeck procedure.



#### TONGUE FLAP

In 1975 in *Annales de Chirurgie Plastique* H. Cadenat, M. Fabie, R. Combelles, M. Clouet and A. Bernes of Toulouse described a primary tongue flap for the severe horseshoe-shaped palatal defect. In the first stage a distally based dorsal tongue flap was sutured into the anterior palatal defect. Twelve days later this flap was extended to the tip of the tongue and divided. A superiorly based pharyngeal flap was turned forward and attached to the velum, leaving a raw undersurface which received the extended tongue flap for oral cover.

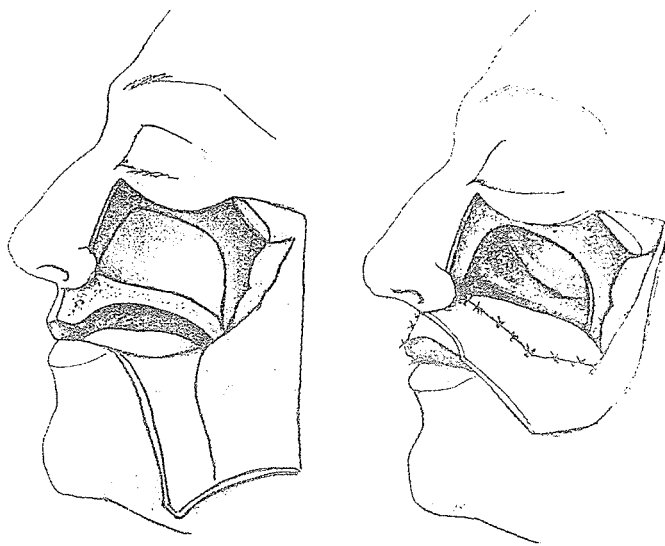
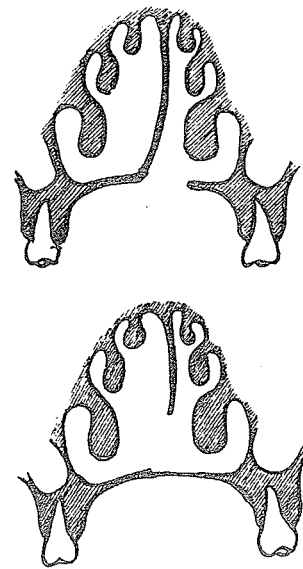
#### NOSE

##### *Septal flaps*

In 1851 Gay used the nasal septum in a case of unilateral cleft lip and palate after the lip had been previously closed. In 1872 Lannelongue performed a uranoplasty in a wide cleft, utilizing a portion of the vomerine mucoperiosteum which was continuous with the border of the defect. In 1890 Sabatier moved the nasal

septum to the horizontal plane of the palatal vault. His procedure consisted in sectioning the septum from its attachment to the base of the skull by chisel and breaking it at its junction with the palatal plate. Once in a horizontal position, the septum was held with sutures to the denuded free border of the palatal defect. In 1897 Wildt reported a case by Bardenheuer in which a full-thickness septal flap was turned to close a palate defect following unilateral resection of the maxilla. In 1901 von Eiselsberg used the vomer and its mucoperiosteum to close a unilateral cleft in the palate.

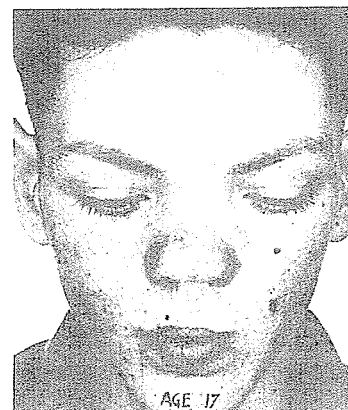In 1903 Foederl, after having experimented on the cadaver, reported success with a full-thickness septal flap turned into a unilateral defect of the palate following carcinoma excision.



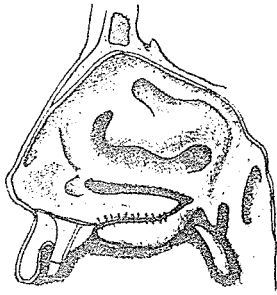
In the late 1930's Sir Harold Gillies hinged a whole-thickness flap of the septum in a primary cleft palate closure when the child was still in the growing age. The primary object of filling the palatal gap was successful, with the development of perfect speech. Yet the nose remained juvenile and flat, causing us to write in our 1957 book:

This was one of the occasions when the secondary defect created in search of a cure was almost as disastrous as the original condition.

In fact, correction of this nasal deformity required a hinged hip graft, an ox cartilage implant, a nasal inlay graft, a small tube

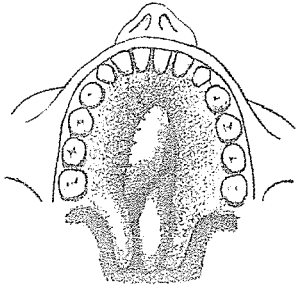
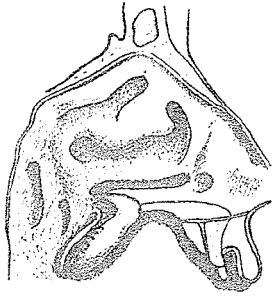


pedicle, a Wolfe graft and finally a forehead flap rhinoplasty with a dermatome graft to the brow defect!



### *Turbinate flaps*

In 1895 Kraske used the inferior turbinate bone to close a cleft palate in which lack of tissue made the classic operation of his time impossible. Resecting the inferior turbinate from before backward and keeping the posterior pedicle but cracking its bone to allow maneuverability, he attached the flap along one side of the cleft. Two weeks later the pedicle was divided, so that the turbinate could be moved to fill the entire defect. Kraske pointed out that both inferior turbinate bones could be used in cases in which the cleft in the hard palate was extensive. He also advised removing the turbinate bone so as to have only mucoperiosteum for cases with cleft velum.



In 1910 Gault used the mucoperiosteum from the inferior turbinate as a flap to close an anterior defect in the hard palate.