

*VI. Fistulae and
Failures and Their
Management*

47. *Secondary Fistulae*

TOTAL healing by first intention is the goal of the palate surgeon, but invariably there are occasional failures. Yules' 1970 review of the world literature revealed the following failure figures: 16 in 101 (R. McClelland and T. Patterson, 1963); 15 in 158 (A. Jolleys and J. Savage, 1963); 36 in 123 (J. Smith, W. Huffman, D. Lierle and K. Moll, 1963); 16 in 89 (R. Trauner and F. Doubeck, 1955); 2 in 12 (B. Williams and F. Woolhouse, 1962); 26 in 190 (L. Bernstein, 1967) 2 in 20 (D. Robinson, M. Byrne and W. McClelland, 1955); 4 in 79 (J. Owsley and H. Blackfield, 1965).

The occurrence of secondary fistulae in the palate anywhere along the site of the original cleft represents failure of surgical closure. The tract soon becomes epithelialized, with a resultant avascular scarring around the hole. The most common causes of fistulae are: inadequate approximation of the opposing raw surfaces, which may result from failure to evert one or both edges of the wound; necrosis of the end of a flap used in closure; tension; infection; careless suturing; and traumatic disruption of the healing wound. Through the years, the most effective closure of a fistula has been in two layers, without tension, in the absence of infection, using flaps with adequate blood supply fixed with mattress sutures and protected during the healing phase.

A fistula draws attention first because the hole allows embarrassing escape into the nose of fluid, food and, if large enough, air during speech. Yet the size of the hole, like the proverbial visible peak of the iceberg, does not tell all. Holdsworth, in his final 1970 edition, pointed an accusing finger at fistulae:

Scar which aggregates with repeated operation makes it [palate] short, and deforms the arch. Even when a small perforation heals itself, contraction of scar about the hole renders the palate short.

He also warned about a positive throat swab:

To operate in the presence of staphylococci, or β hemolytic streptococci belonging to Lancefield's group A, is inexcusable, nor can a week on penicillin or any other drug be trusted to clear the organisms. . . . With a postoperative upper respiratory tract infection, there is mechanical irritation and edema of the wound edges, which may impair healing.

There have been numerous reports of fistulae resulting from partial failure in cleft closure. In 1941 Oldfield reported a 10 percent occurrence. In 1960 Ross Musgrave and John Bremner of Pittsburgh reviewed 780 cleft palate operations over a 10-year period (1950-1959) and noted defects in primary healing resulting in fistulae in 5 percent. They reported:

The second stage operation for bilateral clefts gave the most difficulty with repair, the incidence of a healing defect being 20 percent. Defective healing was less common in unilateral clefts (7.7 percent) than in bilateral (12.5 percent). The fewest complications were encountered in the incomplete cleft palate group (4.6 percent).

Closure of a fistula often can be extremely difficult for the very same reasons that caused its occurrence in the first place. To compound the complexity, further inadequacy of local tissue and subsequent postoperative scarring can be added.

NON-SURGICAL TREATMENT

In 1967 Obermeyer advocated a cauterization technique using tincture of cantharides to help heal palatal fistulae in the immediate postoperative period. He reported 60 percent success out of 139 cases during an eight-year period, with 33 percent showing improvement and 7 percent being refractory. Certainly this treatment will intensify the scarring whether it closes the hole or not.

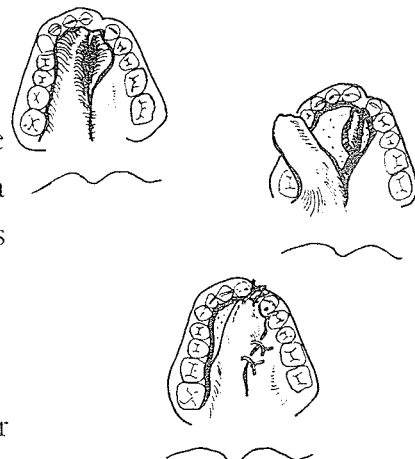
In 1977 Milton D. Berkman and M. L. Lewin of Montefiore Hospital in New York reported seven patients 2 to 24 years of age with oronasal fistulae treated with a vinyl palatal appliance

inserted within a two-week postsurgical period and worn continuously until closure of the fistula. They reported:

Treatment results in six of seven patients demonstrated complete closure within a two to three month period with no recurrence. In one patient, the fistula narrowed significantly.

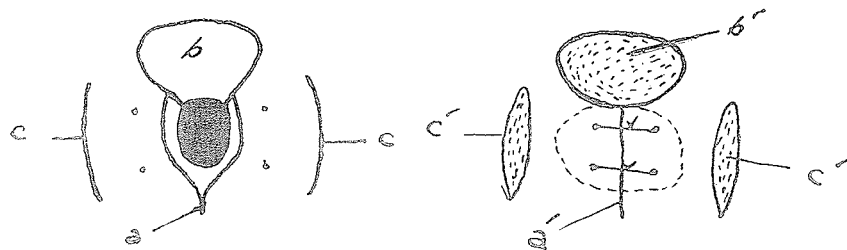
SURGERY

The mucosal or mucoperiosteal hinge flap swinging from one edge of the fistula, covered by a second mucoperiosteal flap, is a most popular approach toward closure. This type of closure was described by Krimer in 1827.



von Langenbeck

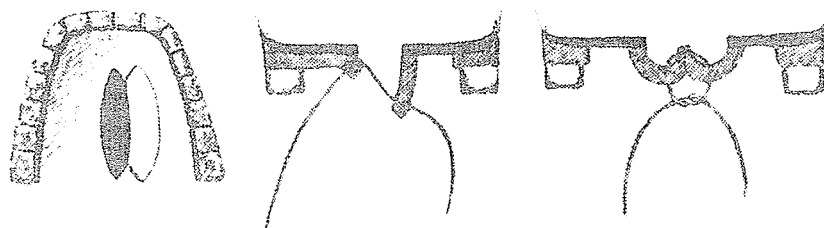
In 1864 von Langenbeck described a sophisticated two-layer closure of a fistula with a turnover hinge flap for the nasal side and von Langenbeck lateral incisions for bilateral strap flap closure of the oral side.



Fitzgerald

Naghten Fitzgerald designed several one-layered hinge flap closures. In 1875 he wrote:

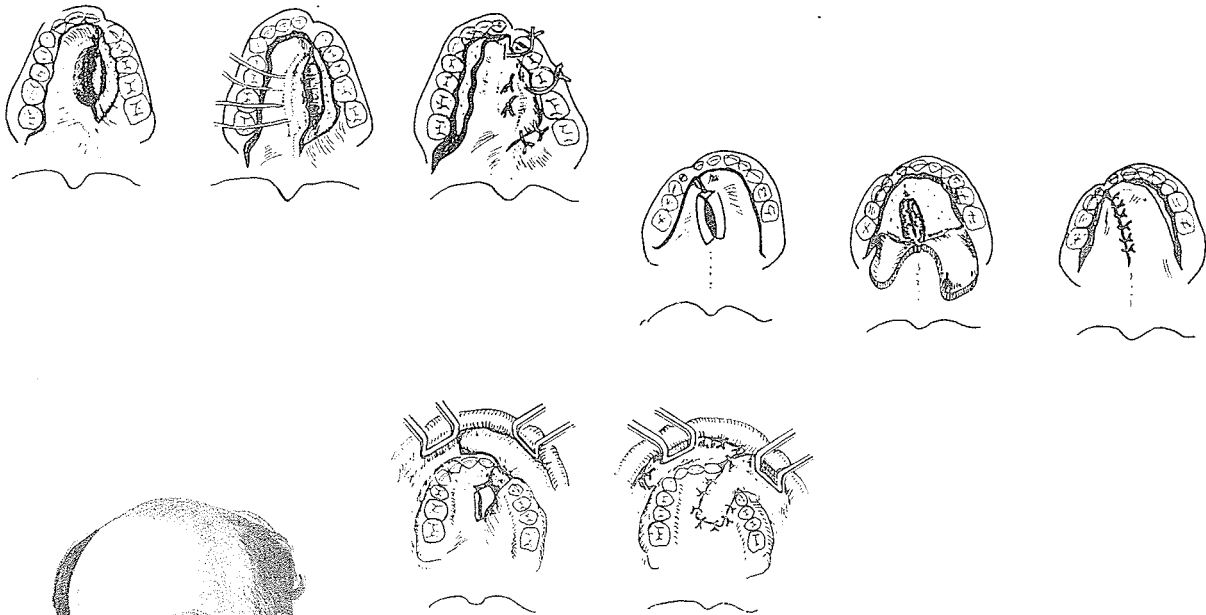
According to the size of the chink, I take a corresponding piece of mucous membrane and tissue down to the bone; from one side this is dissected from without inwards and made to hinge at the margin of the opening. . . .



Should the opening be very large, I take the wing or shutter from each side and stitch them in the center. . . . The great secret is to have the wings larger than the opening, so that there may be no tension to interrupt the circulation.

Wassmund

In a 1973 book by Schuchardt, Steinhardt and Schwenzer, a chapter by Luhr, Höltje and Hammer presented various two-layer methods by Wassmund, described in 1939. One was a modification of Krimer's method. Another used sliding mucoperiosteal flaps, while another used a labial sulcus flap. All had nasal lining turned from the edges of the fistulae.



Peter Egyedi

a fistula should be worth at least an egg or two!

Other labial sulcus flaps

Of course, the Burian upper labial sulcus flap can be used to close anterior alveolar fistulae. Then Peter Egyedi of the University of Utrecht, the Netherlands, described a method for closing fistulae in the difficult area around the premaxilla. Many years before, while working in Liberia, West Africa, he had learned the value of cleft surgery. He recalled:

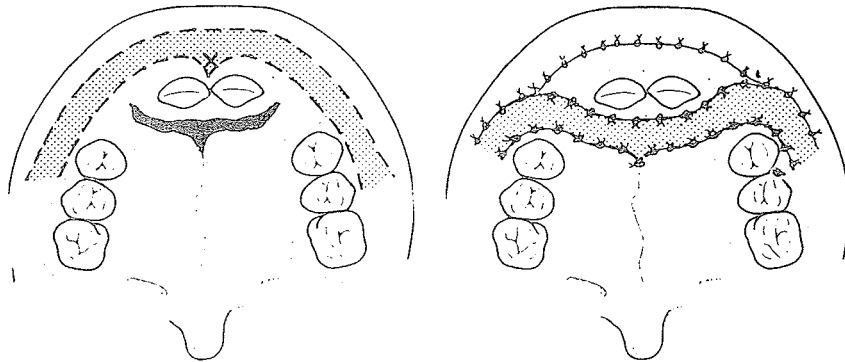
Once in Africa the husband of a lady with a cleft told me, after I had closed the lip, that her value had increased at least three chickens and one goat, because of her better appearance.

Thus in 1976, in the *Journal of Maxillofacial Surgery*, he noted:

It is always necessary to use vestibular flaps in the alveolar region. . . . Two flaps, one from each side, may be necessary for this purpose, but necrosis of

the tip of such flaps made us try the bucket-handle flap.

Even this bipediced flap can become necrotic. . . . The flap is raised including as much submucous tissue and periosteum as possible. . . . The flap is swung over the intermaxillary bone and sutured into position after excision of the margins of the defect. . . . No attempt at obtaining a nasal layer behind the intermaxillary bone was made. . . . In the case where the cleft behind the intermaxillary bone has the shape of a Y, the dorsal extension of the cleft cannot be closed unless it is very short. The bucket-handle flap could be extended as depicted.



Egyedi admitted:

An obvious disadvantage of the flap is the lowering in vestibular height in the region of the intermaxillary bone and the presence of the two pedicles on top of the alveolus. Therefore one should include a secondary correction of the vestibulum in the treatment planning.

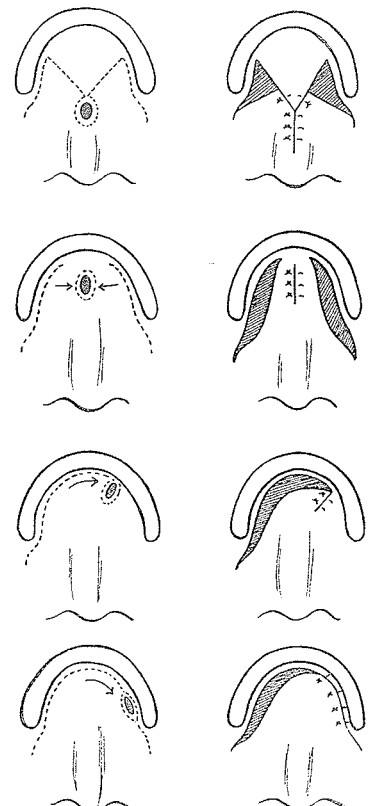
He reported that the bucket-handle flap had been used in five cases with four flaps surviving and one becoming necrotic in its medial one-third.

Holdsworth

Surgeons have continued to use these general principles, occasionally installing some modification. William Holdsworth was one of my early palate teachers and was working on the first edition of his book, *Cleft Lip and Palate*, published in 1951 when I was at Rooksdown House. He was an expert with the hook in his huge hands and could evert inaccessible edges with great skill for suturing. His advice for closing fistulae involved two-layer closure:

It is important that the nasal mucosa be closed as a separate layer, and that in both layers the closure be free from tension.

a Dutch neatness

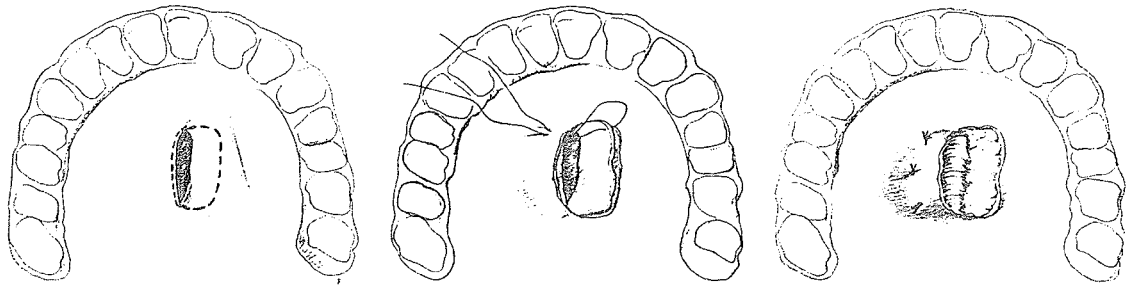


These simple, concise diagrams are typical of his book and represent the standard approach to fistulae in various positions.

Reid

In the 1962 *British Journal of Plastic Surgery*, astute Campbell Reid of United Sheffield Hospitals gave Hynes credit for a 1955 personal communication introducing the hinge flap for closure of slit-like fistulae and smaller holes. He noted:

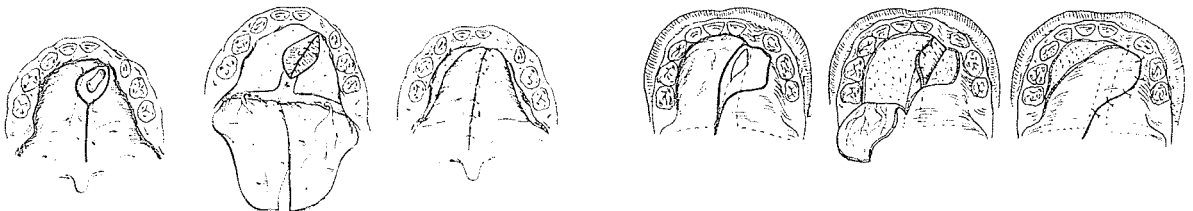
The principle of this procedure is to raise a mucoperiosteal flap immediately adjacent to the fistula based along one edge and to turn this as a hinge over the hole so that its buccal surface will lie uppermost in the fistula. . . . A slot is then prepared into which the free edge of the overturned flap may be fitted. This is achieved by a minimum number of three mattress sutures. . . .

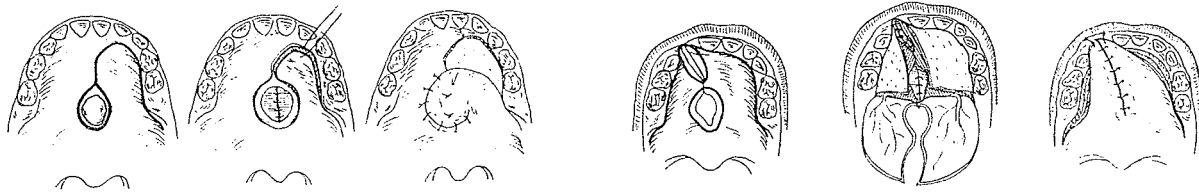


The hinge flap method of closure has been used with success in a number of small fistulae of the hard palate, *i.e.*, those less than 2 cm. in diameter. Sometimes a recurrent fistula has appeared, though smaller than the original. This is most likely at either end and results from a technical fault. The procedure may, however, be repeated after an interval when the small hole may be readily closed, using a flap from the other side. The distressing symptom of fluid regurgitating down the nose is effectively controlled.

Gabka

Joachim Gabka of Berlin in his 1964 book outlined two-layer fistula closure with inturning of the edges for the nasal side. He presented diagrams of V-Y mucoperiosteal flaps for closure of an anterior hole. A sliding mucoperiosteal flap was advocated for an





anterior slit. A rotation flap was shown for a posterior hard palate fistula. A V-Y was again shown to close both an anterior slit and a posterior round hole in the hard palate simultaneously.

Randall

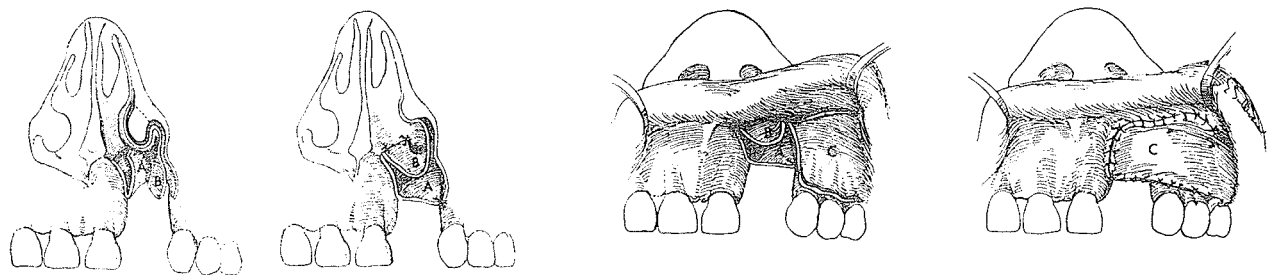
Randall, for Goldwyn's *The Unfavorable Result in Plastic Surgery*, commented:

Fistulas in the hard palate are much more difficult to close than they seem.

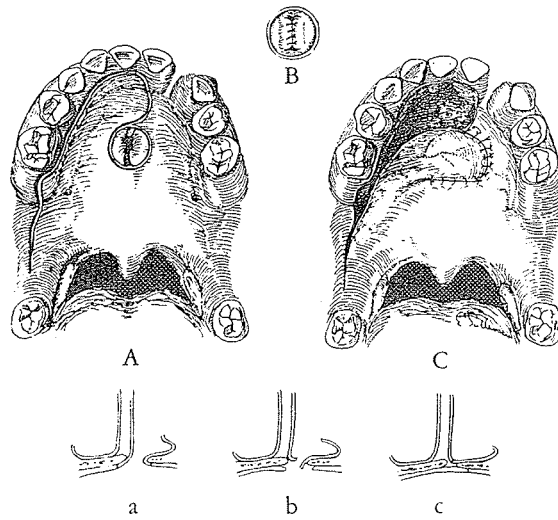
He showed diagrams of a modified von Langenbeck approach for a two-layer closure of a mid-hard palate fistula and a unilateral rotation flap, aided by a labial mucosal flap for a more anterior fistula.

Oneal

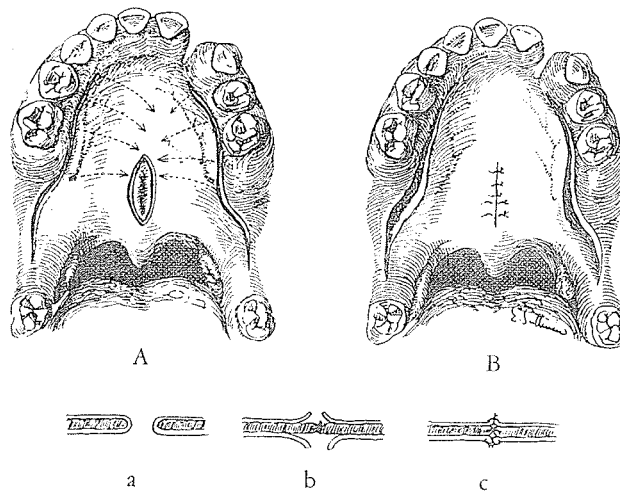
Robert Oneal of Ann Arbor, in *Cleft Lip and Palate*, edited by Grabb, Rosenstein, and Bzoch, presented a method of handling the various fistulae appearing in the three standard positions. An anterior vestibular-alveolar fistula was closed with a vomer flap (A), lateral nasal flap (B), and oral-gingival mucoperiosteal flap (C).



A hard palate fistula was closed with lateral edge turnover flaps for nasal closure covered by rotation of a flap of mobilized mucoperiosteum.

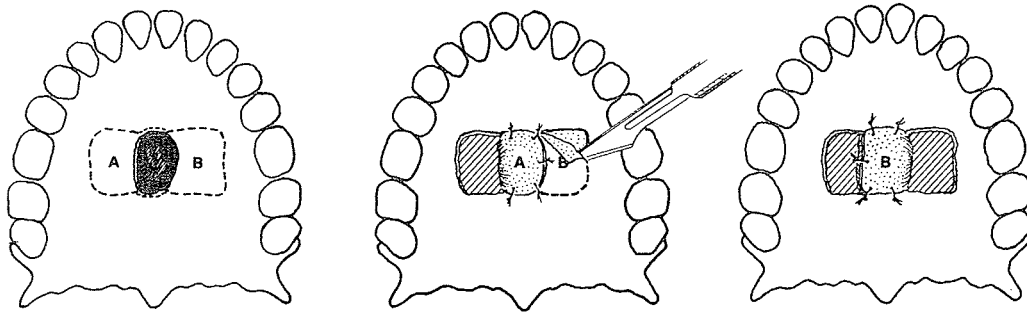


A soft palate fistula was closed by lateral relaxing incisions and complete mobilization of hard palate mucoperiosteum plus in-turning of fistula edges for nasal closure and three-layer suturing.



Rintala

Aarne Rintala of Finnish Red Cross Hospital, Helsinki, in 1971 described a new method using two hinge flaps at the edges of the fistula. One hinge flap (A), barely the size of the fistula, was elevated, freed from the bony edge with care not to perforate, and turned over to form the nasal layer. A similar flap (B), somewhat larger than flap A, was drawn on the contralateral side of the fistula but, before elevation, was denuded of epithelium by scalpel or abrader. Flap A was sutured to the opposite edge and then overlapped by flap B, which was also sutured. The operative area



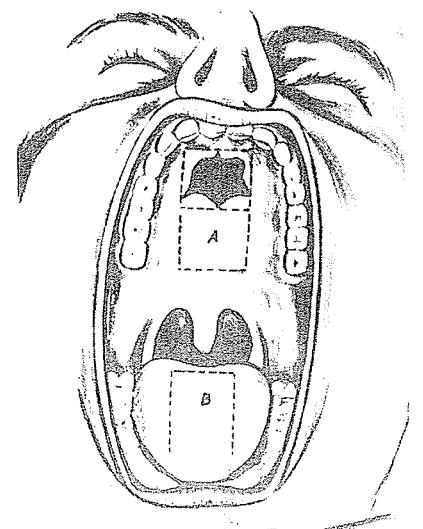
was dried and covered with Squibb Orahesive Bandage, an elastic membrane that adheres to mucosa, and the patient was kept on a liquid diet for a fortnight. Rintala reported 30 successful fistula closures, the largest being 2 cm. in diameter. The only complication of this two-layer closure had been hemorrhage from the exposed raw area, which epithelialized in three to five weeks, and which would, of course, have produced some cicatricial constriction. This was counteracted by a prosthesis in patients of growing age.

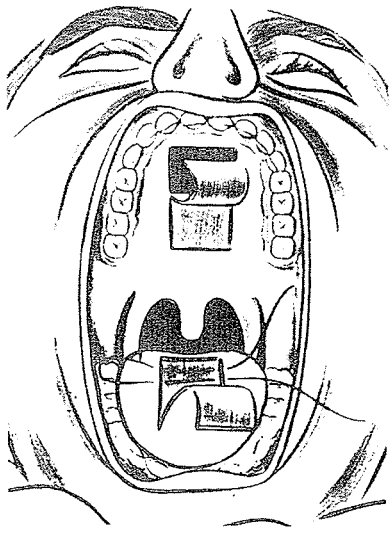
Tongue flaps

In 1901 von Eiselsberg mentioned that Gersuny had discussed with him the possibilities of transplanted pedicle flaps from the tongue to close defects of the palate. The two cases in which von Eiselsberg attempted tongue flaps ended in failure. In 1904 Ranzi and Sultan of Billroth's and von Eiselsberg's clinic reported that the seven cases of cleft palate in which a tongue flap had been used terminated in failure and that this method should only be resorted to when no other was available. Undoubtedly, the problem was a lack of immobilization of the tongue during healing.

Guerrero-Santos

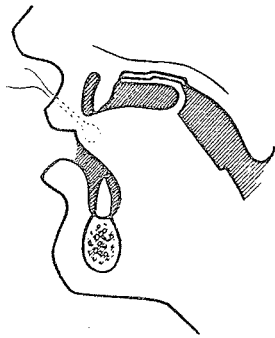
José Guerrero-Santos of Guadalajara, Mexico, appreciates the tongue as a donor area. In 1966 in *Plastic and Reconstructive Surgery*, he and J. T. Altamirano advocated a wide, distally based dorsal tongue flap for closure of hard palate fistulae. The scar was excised around the edges of the palate hole; then one or more turnover palate flaps were used for nasal closure, prior to covering the defect with a lingual flap. The tongue was held to the upper



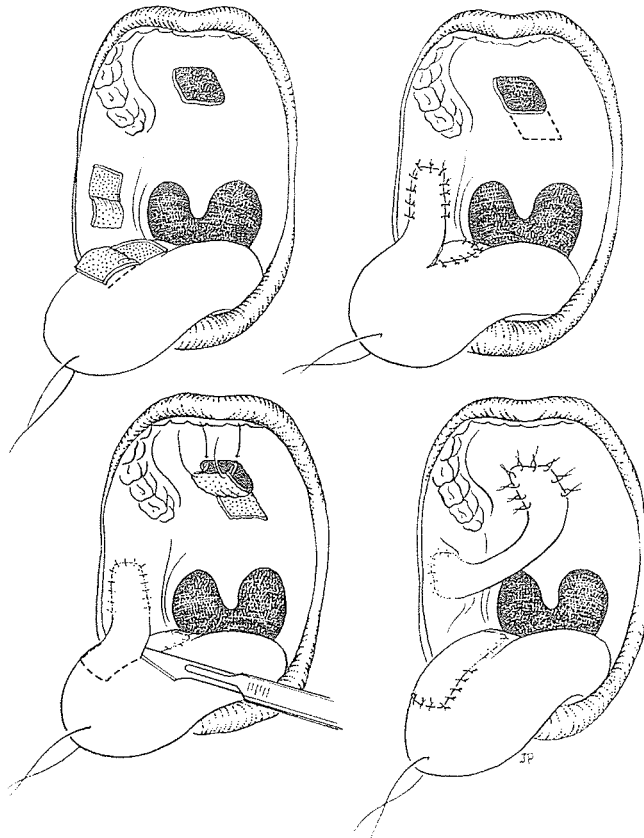


lip and dental arch with a wire suture. In this first presentation, they reported 10 patients with hard palate fistulae caused by noma, bullet wound, tumor and incomplete cleft palate closure.

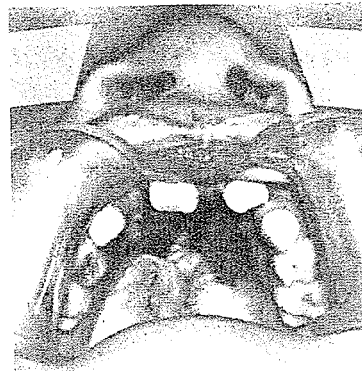
By 1967 at the Congress in Rome, Guerrero-Santos, with Garay, Torres and Altamirano, had increased the experience to 28 cases of palate fistulae treated by the same tongue flap method. Evidently, movement of the tongue had proved to be a problem because they described tongue immobilization with triple fixation. First, the tongue flap was attached over the fistula. Then a small distal tongue flap was sutured to a labial flap. Finally, a Kirschner wire was passed through one angle of the mandible, transfixing the tongue, and out the other mandibular angle.



In 1973 in the *Cleft Palate Journal* Guerrero-Santos, with Fernandez, offered an alternative two-stage method to avoid tongue movements dislodging the final palate attachment. A unilateral dorsal tongue flap, based distally, was waltzed to the inside of the cheek on the same side. Once this join had obtained a blood supply, the tongue attachment was divided and the flap was swung up to close the fistula in the palate.

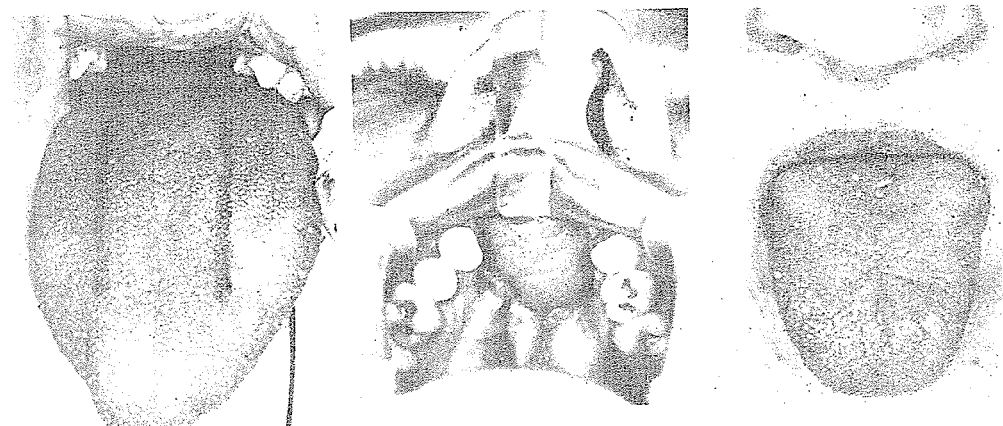


In 1970 in the *Annals of Otolaryngology, Rhinology and Laryngology* Raymond Massengill, K. Pickrell and R. Mladick of Duke University endorsed the anteriorly based dorsal tongue flap of Guerrero-Santos for a two-stage closure of anterior fistulae and reported four cases, one of which was illustrated as shown. They concluded:



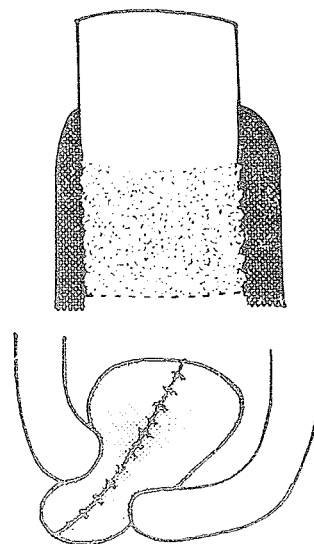
Previously, these large anterior palatal defects have been closed by a prosthetic method or complicated multi-staged surgical procedures with poor results. This technique . . . can accomplish closure in two stages within three weeks of time . . . and the esthetic results have been excellent.

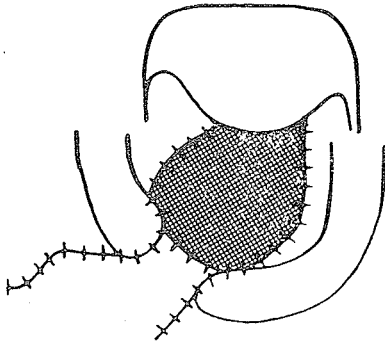
The results of the Templin-Darley Diagnostic Test of Articulation showed the lingual flap procedure to have no adverse effects on articulation. . . . No statistical differences were found between the patients and the control subjects in respect to the vertical lingual movements, and no statistical differences were noted between the two groups in lingual diadochokinetic abilities.



In 1972 Hector Marino wrote of a trick he had found valuable in fixing a tongue flap into the scarred, avascular area of a palate fistula. He advocated passing a strong nylon suture through the tongue flap and then through the fistula and out the nostril, to ensure flap apposition to the palatal defect.

In 1972 Ian Jackson, and in 1973 Jackson with Hannelore Sieber of Glasgow, Scotland, in the *British Journal of Plastic Surgery*, confirmed the value of the Mexican tongue flap for closure of anterior palatal fistulae in children. They described inturning of the edges of the fistula for nasal closure and suturing the tongue flap to the sides of the defect, allowing the unused portion to tube itself. The design of this flap was outlined:

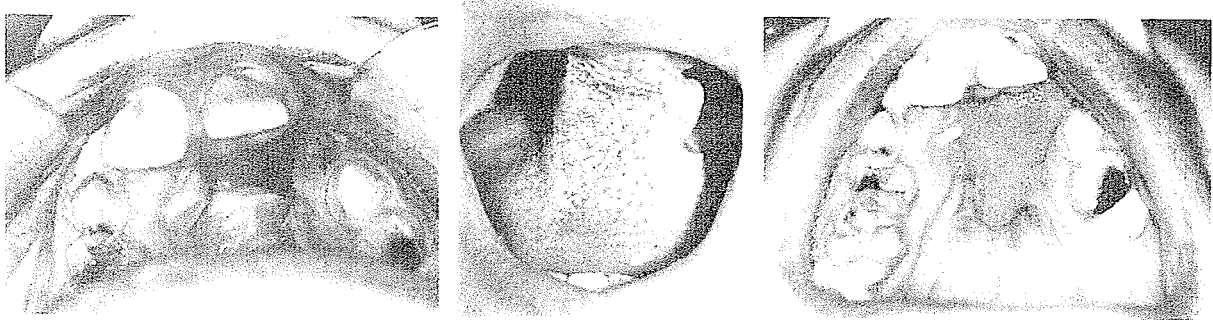




It is 5 or 6 cm. long and its width may be two-thirds of the dorsal aspect of the tongue.

They did not feel that further postoperative fixation, other than the attachment of the flap, was necessary.

In his 1975 Flemish book A. J. C. Huffstadt presented these photographs of an anterior hard palate fistula, which he closed with the aid of a distally based dorsal tongue flap similar to what Guerrero-Santos and Ian Jackson had used.



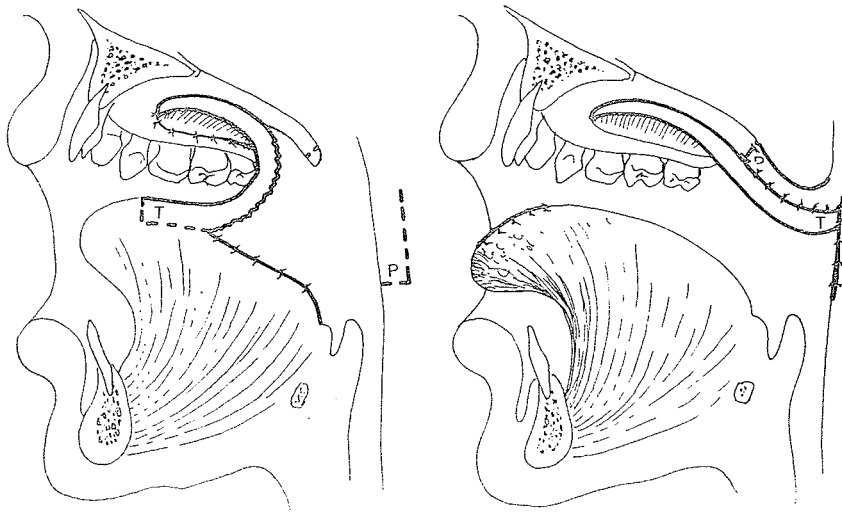
Basket cases

In 1976 a University of Virginia team of five (Golden, Mentzer, Fox, Futrell and Edgerton) attributed their success with 31 tongue flaps to the support and protection of an aluminum suspension basket wired to the teeth for 21 days until the pedicle was divided.

Contrary to Jackson (1972), we believe that gentle but exacting support of these flaps is the single most important determinant of survival.

It is likely that the blood supply of the flap and the recipient area and the method of apposition of the two with sutures is of first priority.

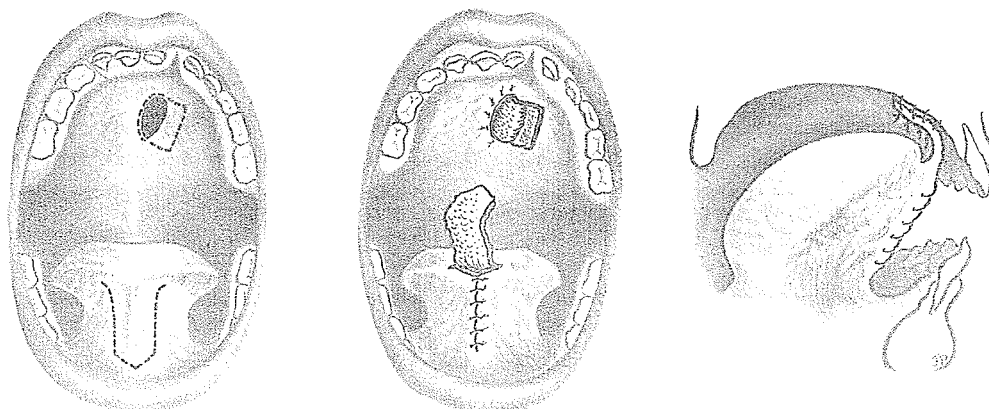
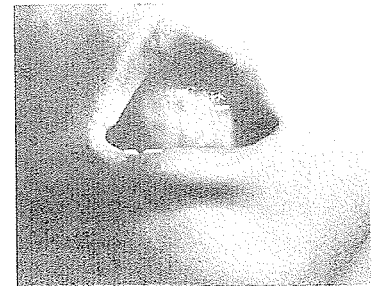
In 1978, in *Cirugia Plástica Argentina*, Miguel Correa-Iturraspe and Hector Luis Panigatti of Buenos Aires proposed a posteriorly based dorsal tongue flap to fill a large, scarred, central palatal defect. Flaps turned in from the sides provided the nasal lining and the tongue flap produced cover. In the second stage, when the base of the tongue flap was divided, it was attached posteriorly by overlapping it with a superiorly based pharyngeal flap.

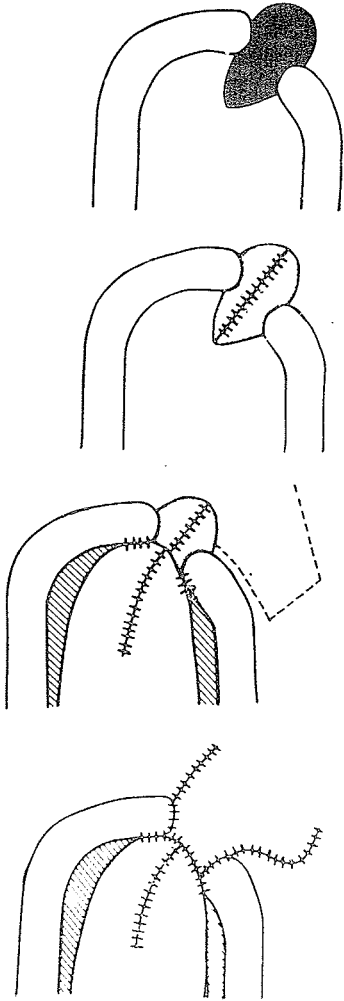


A variation

In the early 1960's, when the island flap was being used for nasal lining in pushback procedures as a primary operation at 18 months, unless great care was exerted in the anterior nasal closure of complete clefts, an anterior hard palate fistula would form. Use of the anterior mucoperiosteum for the island meant that there was less immediate tissue available in the vicinity of the fistula. Although more difficult, it was usually possible to maneuver mucoperiosteum for adequate closure. In one such case, local tissue failed and a tongue flap was used successfully.

Previous tongue flaps had been designed with the donor area on the dorsum where the taste buds and sensation are pronounced. It seemed more kind and economical to take the flap from the anterior ventral aspect with the base placed just beneath the tip. It turned up in an action not unlike that of an old bullfrog flicking flies with its tongue. The edges of the fistula were turned in, and the ventral tongue flap was flipped up into the anterior defect quite easily, requiring no extra fixation. The donor area closed without difficulty. This flap is suited only for anterior fistulae.






Bone-grafting the fistula

In 1972 Ian Jackson of Canniesburn Hospital, Glasgow, went a step farther in fistula treatment by advocating stiffening the closure with bone grafts. His method involved opening the lip for revision, turning flaps from the vomer and the lateral walls of the fistula to close off the nasal side and using both Veau mucoperiosteal flaps and an anterior buccal mucosal flap for oral closure. As he noted in 1976:

Prior to complete closure bone chips from the iliac crest are inserted to fill the area between the palatal shelves and alveolar margin of the defect; the nasal floor is thus elevated. Bone is also inserted under the alar base, along the front of the hypoplastic maxilla and into the lateral wall of the pyriform fossa. To achieve a good occlusal relationship, patients, when necessary, underwent either presurgical orthodontic treatment or a simultaneous Le Fort I osteotomy.

It was found that many of these cases demonstrated improvement of their velopharyngeal incompetence. Forty-four such cases were submitted to speech assessment and the results reported by Mary S. Jackson, Ian T. Jackson and F. B. Christie in 1976. All patients, they noted, had immediate speech improvement, the majority moving up one category in the assessment scale. This was their summary:

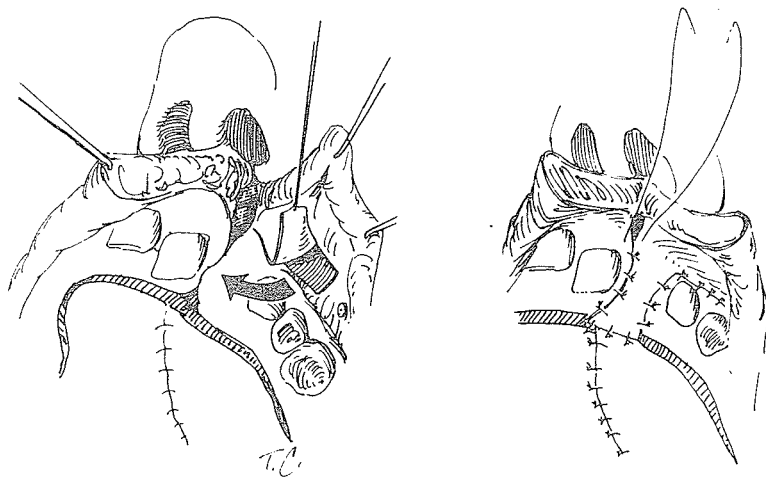


Shaded areas = bone grafts

Even the small anterior buccal fistulas had an underlying large bony defect. Once this defect was filled with a bone graft the tone of the voice was immediately improved whether the fistula was large or small. Creating a complete bony structure appears to alter resonance and thereby reduce nasal tones. A pre-alveolar fistula cannot be adequately sealed by an obturator; air is expelled into the nose whenever the lip loses contact with the prosthesis and speech improvement can be heard when the lip is pressed back against

it. It follows therefore that in secondary cleft palate repairs in patients with speech defects and an anterior fistula, it is not sufficient to restore velopharyngeal competence and fit an obturator; the fistula must be solidly closed.

In 1977 at the Toronto Congress, James A. Lehman, Jr., of Akron, Ohio, reported closure of anterior palate fistula with the use of a Burian type gingival labial flap. As he said:




We have found that this flap in combination with bone grafting has produced a very reliable technique for closure of large anterior fistulae. This has been used successfully in over thirty cases to date.

Caution about simple fistulae!

In 1975, at the New Orleans meeting of the American Cleft Palate Association, David G. Bowers of Vanderbilt University, who trained with Gerald O'Connor, called attention to the changing status of postoperative palatal fistulae. This is his abstract:

The character of palate fistula occurring after cleft palate repair is changing. Pushback palatoplasties leave more fistulae, and the location of the fistulae is usually in the most anterior portion of the cleft at the alveolar ridge rather than at the junction of the soft and hard palate as in past decades. Maxillary orthopedics to expand collapsed arches, often open more widely any previously unrecognized or asymptomatic fistulae, so their repair becomes necessary.

An analysis of repairs of 35 patients with a 48% failure rate and 46 operations with a 60% failure rate suggests the need for a drastic change in thought concerning the simplicity of closure of palate fistulae. Discussions



David Bowers

with experienced, established and well-recognized plastic surgeons also reveal a high rate of failure of fistula closure and an awareness of the change in the most common location of the fistula. . . . Recommendations include two stage cleft palate repairs to prevent fistulae and delay of palate flap procedure prior to closure of the fistulae.

Other flaps

The island flap has been found useful by some for closure of fistulae. When the hole is enormous, flaps have been and can be brought from a distance. Later chapters will be devoted to these procedures.

Conclusion

It is important to note that each fistula deserves a specific plan. Although most of the standard designs have been presented, the choice of the correct approach for each case calls for experience, care and patience.