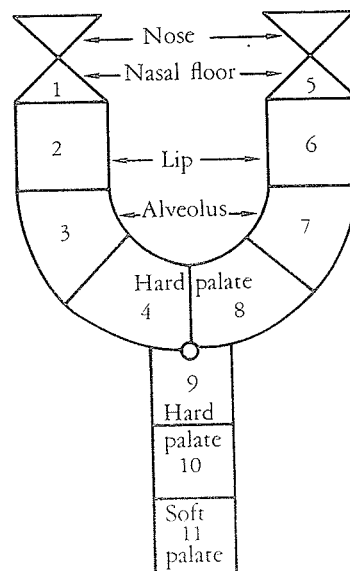


46. Personal Palatal Evolution

KEY TO CODE ON CASES

B.D.	birth date
F.H.	family history
F.T.	first trimester
O.C.A.	other congenital anomalies
Op	operation
Ad	adhesion
Adv	advancement
Rot	rotation
R-A	rotation-advancement
H.P.	hard palate
S.P.	soft palate
B.G.	bone graft
b-c	back-cut
wr	white roll flap
c	flap c
col	columella

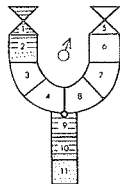


A cleft is indicated by stippling, a submucous cleft or submucous distortion by horizontal lines.

In the never ending search for improvement, it is imperative, as a logical guide to progress, to learn as much or more from our failures as our successes!

THIS chapter traces the evolution of my personal quest for a surgical solution to the cleft palate problem as exemplified by a sample of pertinent cases, many of which are the palatal follow-up of cleft lip cases presented in Volumes I and II. My actions were first influenced by training and later by experience. Observations of von Langenbeck procedures at Harvard and Vanderbilt in the mid-1940's revealed closure without lengthening and about a 70 percent good speech result. Kilner, Peet and Wardill in England in the late 1940's impressed me with the V-Y lengthening, and even without nasal lining release more than 75 percent obtained good speech but with some arch collapse. Brown, Byars and McDowell in St. Louis in the early 1950's demonstrated the Dorrance incision and radical nasal lining release during the pushback leaving large raw areas, but they obtained similar speech results and some arch collapse. My first cases combined V-Y lengthening with nasal lining release and left a raw area.

Vol. I P. 344
 B.D. 7-31-57
 F.H. No clefts
 E.T. Uneventful
 O.C.A. None

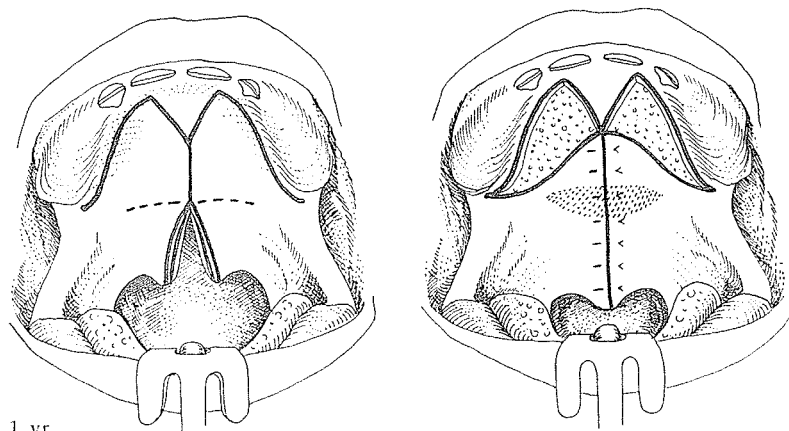
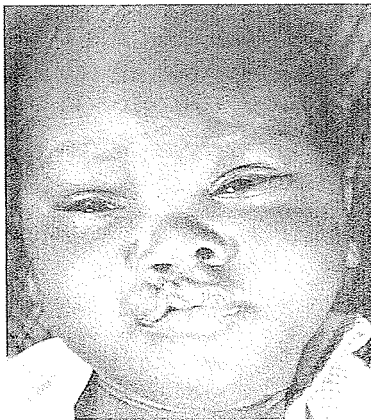

PRIMARY SURGERY

V - Y PUSHBACK

CASE 1 was born with a unilateral incomplete cleft of the lip and the palate but with an intact alveolus. In 1957 rotation-advancement of the lip cleft was successful.

In 1958, at age 1 year, a Kilner-Wardill type of three-flap V-Y pushback procedure was carried out leaving a portion of the nasal lining raw (stippling).



1 yr.

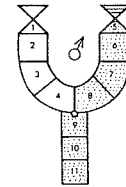

In 1960 Berkowitz first noticed a crossbite developing, on which he commented in 1963:

Unilateral crossbite of the right buccal segment due to medial collapse of the alveolus. Suggest expansion.

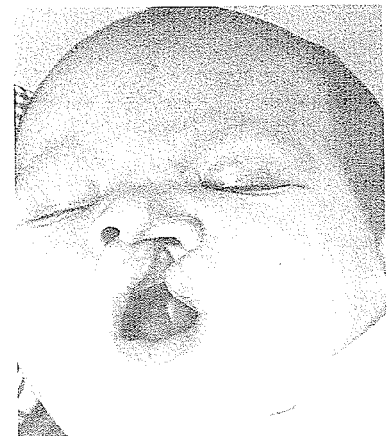
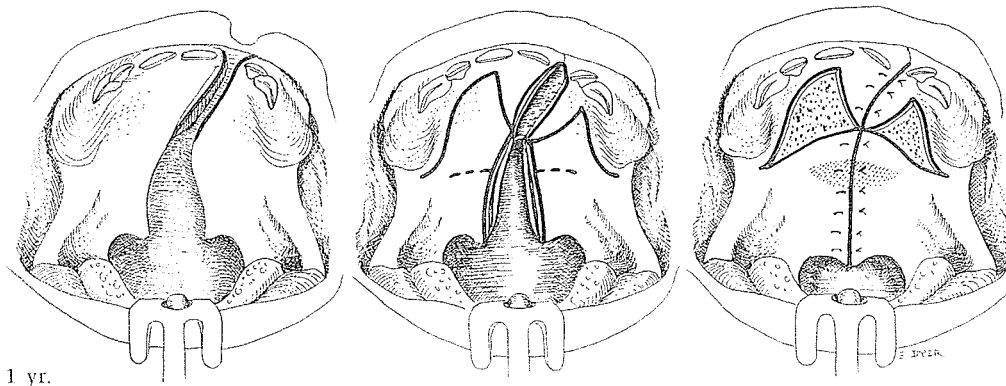
When seen in the cleft palate clinic in 1967, the patient was found to have normal speech and hearing, and a full-banded appliance was in place on both upper and lower arches. When last seen in 1977, the patient was a corporal in the army, with good occlusion and normal speech and hearing.

CASE 2 was born with an incomplete cleft of the lip, severe nasal distortion and a complete cleft of the hard and soft palate.

On 4-15-59 the lip was closed by means of the rotation-advancement method. On 3-23-60, at about 12 months of age, a vomer flap was used to close the anterior hard palate and a four-flap Wardill V-Y procedure achieved some pushback, leaving a raw nasal area at the junction of the soft and hard palate. A small fistula formed.




Vol. I P. 375
 B.D. 3-23-59
 F.H. No clefts
 F.T. Uneventful
 O.C.A. None



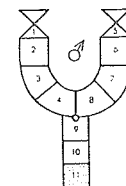
In 1966 the maxillary teeth were behind the mandibular teeth. In 1967 collapse of the cleft segment with crossbite necessitated placement of an upper, fixed lingual arch wire for maxillary expansion. On 6-18-68, following maxillary expansion, at the age of 9 years rib bone grafts were used as struts and chips to fit between the alveolar segments, overlay the arch and underlay the alar bases. In 1970 a palatal space retainer was adequate. Speech was normal. On 7-1-76, at age 17 years, a cleft lip rhinoplasty was carried out.

Bottom line: Concerned about the limited lengthening, the nasal lining raw area, the inevitable contracture and possible fistulae, I conceived the island flap method of pushback in 1960.



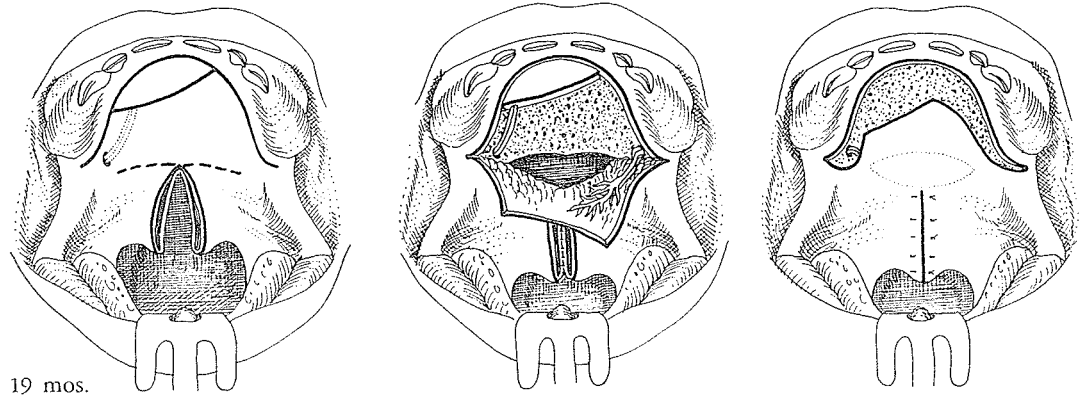
EARLY PUSHBACK WITH ISLAND FLAP

UNILATERAL CLEFTS. CASE 3 was born with a cleft of the soft palate which was treated at 19 months of age with a horseshoe shaped pushback using a unilateral island flap taken from the anterior mucoperiosteum and



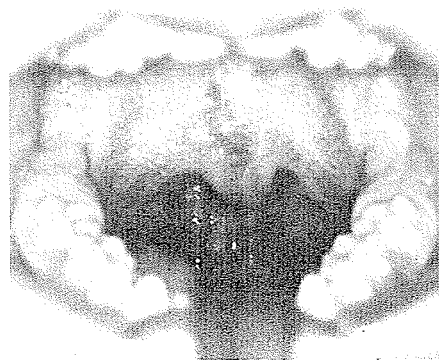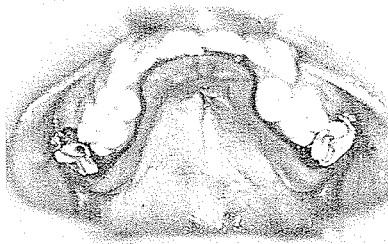
B.D. 9-24-61
 F.H. No clefts
 F.T. Uneventful
 O.C.A. None

crossing the midline 1 cm. Thomas Cronin of Houston observed the surgery and admitted with a slight wince that there might be a place in palate surgery for the island flap.

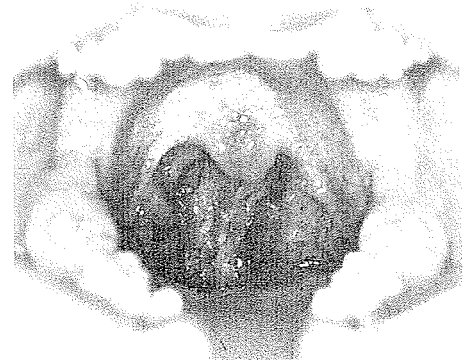


19 mos.

Healing was uneventful, and at his first cleft palate clinic evaluation the patient presented normal speech but a slight hearing loss, otitis media, enlarged tonsils and adenoids and allergies. Conservative treatment including anti-allergic therapy was instituted, and in 1967 Pigott pronounced the patient a perfect speaker, a judgment endorsed in cleft palate clinic in 1969, 1970, 1972, 1975 and 1976. Orthodontic expansion by R. Litowitz was started in 1971 for a mild "hourglass" deformity with crossbite of the upper left second bicuspid amenable to orthodontia. When last seen in 1976 the patient had a long, mobile palate with normal speech. At that time photographs were taken of his palate at rest and elevated into a competent sphincter while phonating "Aaahh."

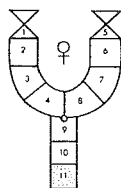


At rest

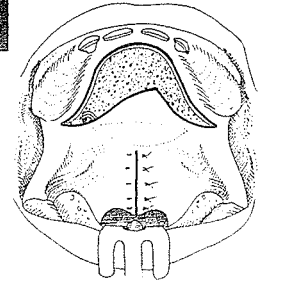
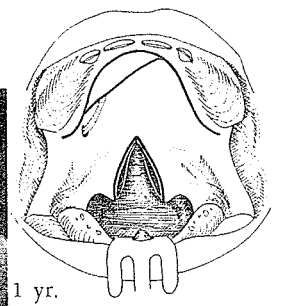
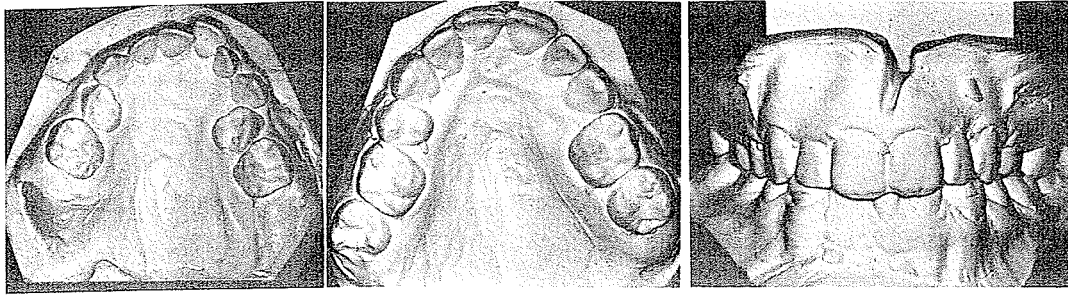


Phonating "Aaahh"

B.D. 4-9-62
 E.H. Maternal cousin
 had CL&P
 F.T. Uneventful
 O.C.A. None



CASE 4 was born with a cleft of the soft palate which was treated at 1 year of age with a horseshoe shaped pushback, a right island flap being used to fill the nasal defect after release of the soft from the hard palate. At age 12 years the patient began orthodontic treatment for crossbite and at age 16 years was reported by Berkowitz to have excellent palatal arch development and good occlusion.

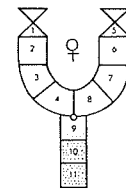


Regular examinations by various speech pathologists in cleft palate clinic revealed normal speech in 1973, 1974 and 1976, despite cephaloradiographs showing the velum failing to elevate sufficiently to contact the posterior pharyngeal wall when vocalizing u.

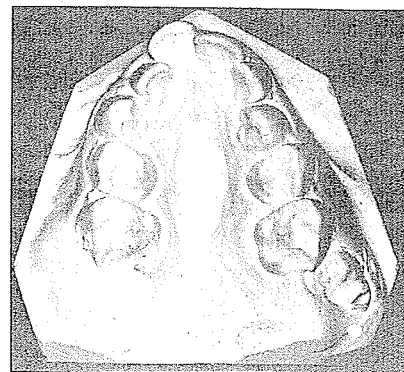
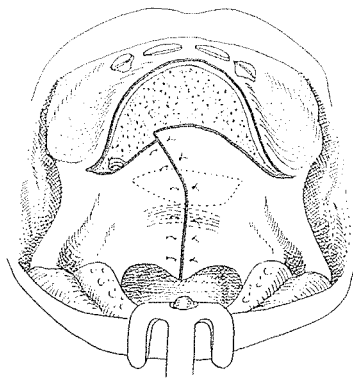
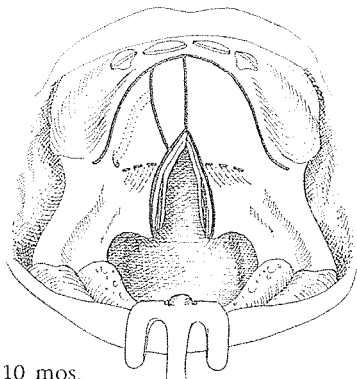
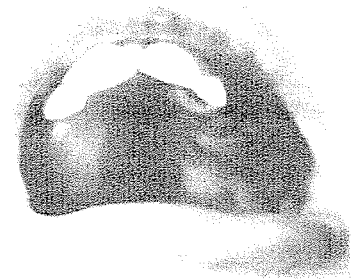
CASE 5 was born with a cleft of the soft palate extending into the hard palate. At 10 months of age a V-Y pushback was performed; a 1.5 cm. wide right island flap was used to fill the nasal lining defect after release of the soft palate from the hard palate edge. The levator muscles were detached from the edge of the hard palate, dissected into two bundles, repositioned and sutured together into an intact loop. The surgery took 43 minutes.

From the age of 3½ years the patient has had normal speech, but Berkowitz noted a narrowing of her upper dental arch.

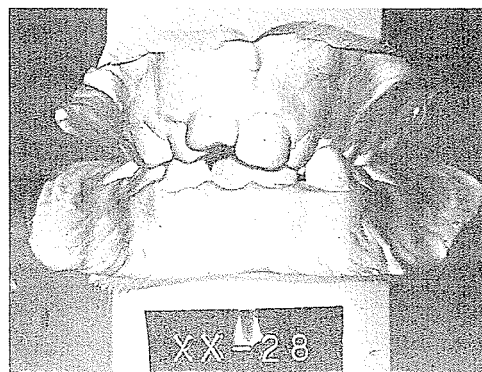
At age 6 years (1975), this record of the contracted arch was taken by Berkowitz; subsequently, a palate expander was used to spread the arch.



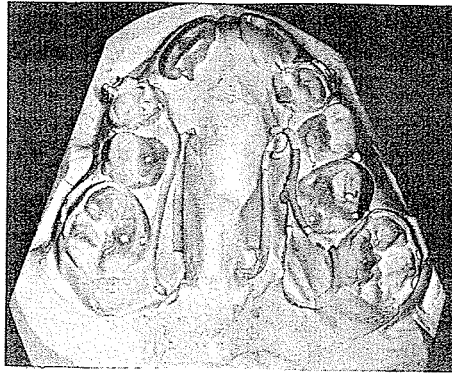
B.D. 2-6-69
F.H. Adopted
O.C.A. None



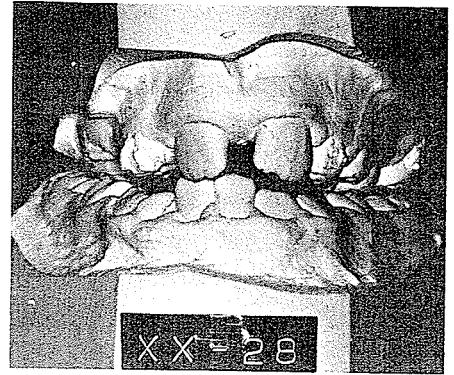
Arch deformation, 1975



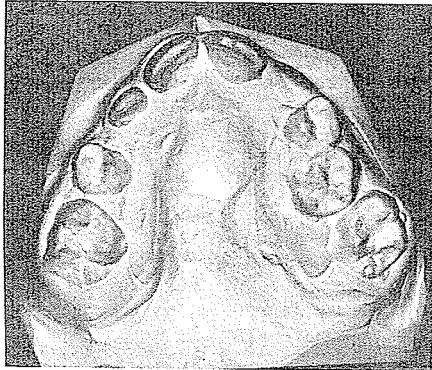
Buccal crossbite



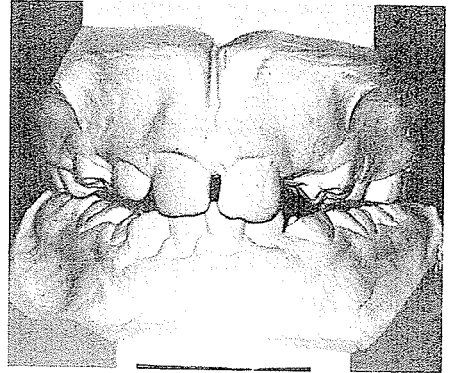
1-78 Palate expander in place



Separation of maxillary incisors mirroring expansion

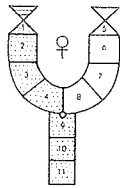


6-78 Transverse palate scar evident

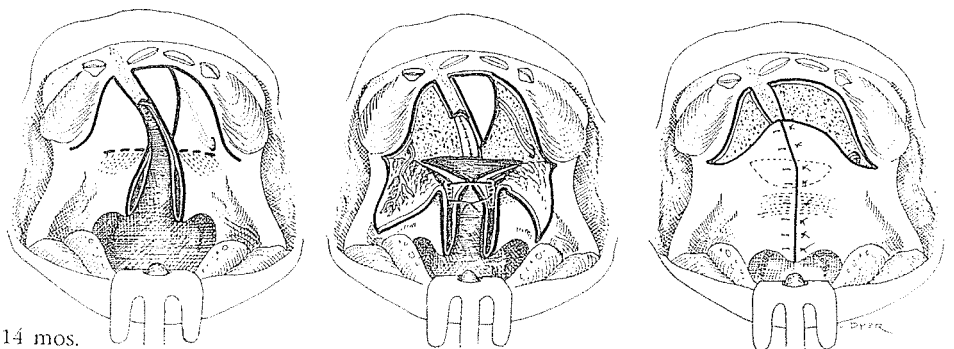
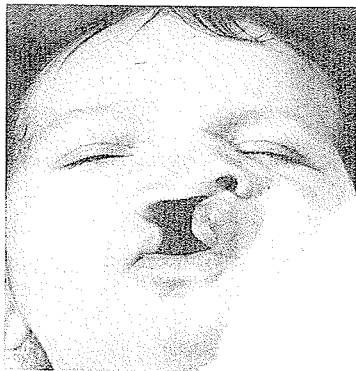

Buccal crossbite corrected

Vol. 1 P. 507
 B.D. 12-12-69
 F.H. Maternal cousin had CL&P
 F.T. Uneventful
 O.C.A. None



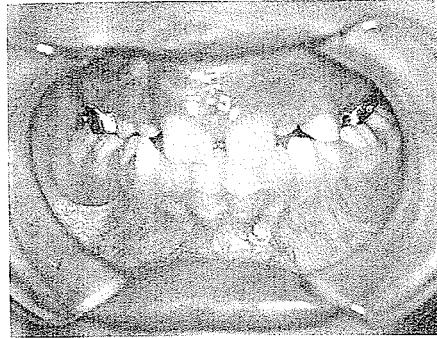
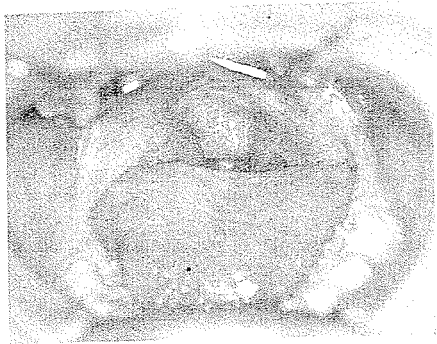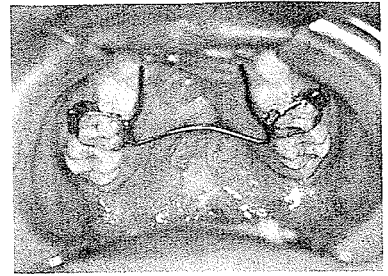
CASE 6 was born with a severe complete unilateral cleft of the lip and palate which was treated at 3 weeks by a lip adhesion with no undermining of the lateral lip segment from the maxilla. At 3 months of age the anterior cleft was closed with mucoperiosteal flaps from the cleft edge for nasal closure and excess mucosa from the lip adhesion for oral closure. At the same time, the lip was approximated with the rotation-advancement method. In 1971, at 14 months of age, a V-Y pushback was accomplished with a 1.5 cm. left island flap inserted into the release of the nasal lining.



14 mos.

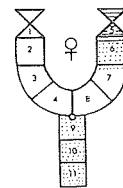
Levator muscle attachments were freed from the hard palate edge, dissected into bundles and sutured into an intact muscle loop.

In 1973 the patient revealed mild right buccal and anterior crossbite, which was treated successfully with expansion orthodontia. In 1977, at age 7 years, speech was normal except for a lisp. Correct occlusion is being maintained by a retainer. Nasal correction at 16 years is planned.

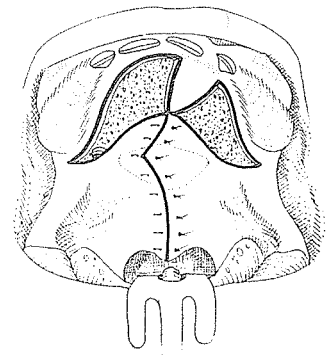
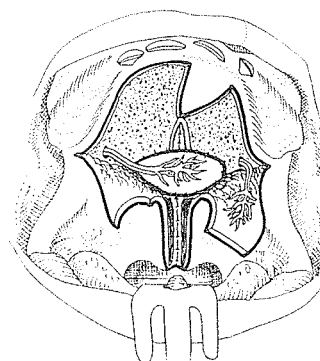
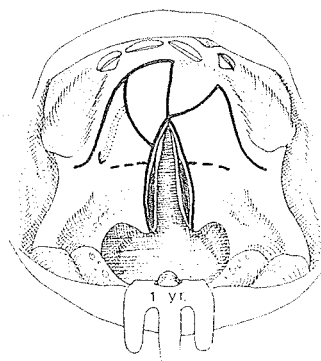
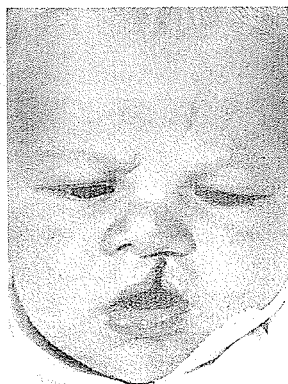

Bottom line: Here, an early pushback with island flap achieved normal speech with only moderate maxillary crossbite, corrected early with orthodontia. But maxillary deformity is usually greater than in this case.

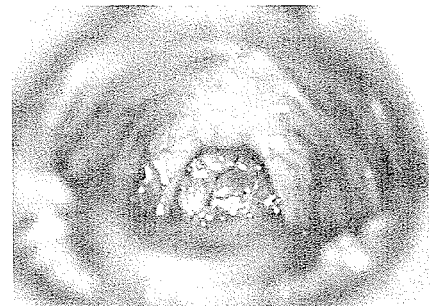
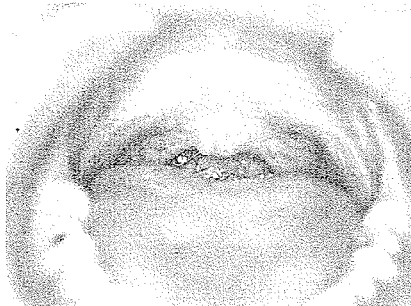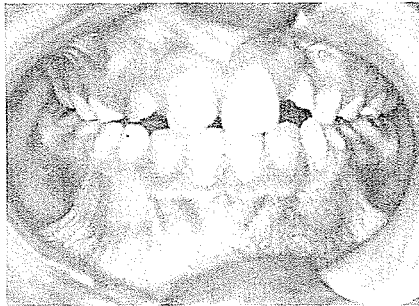
CASE 7 was born with an incomplete cleft of the lip, notch of the alveolus and cleft of the soft and the distal third of the hard palate. At 2 months of age rotation-advancement achieved lip closure. At 1 year a V-Y pushback of the palate used a right mucoperiosteal island flap, 1.25 cm. wide, to fill the nasal defect. The hamulus was fractured bilaterally, and closure of the palate was achieved in three layers with excellent healing.



Vol. I P. 374
 B.D. 8-12-68
 E.H. Father's grand-
 mother had
 CL&P
 F.T. Uneventful
 O.C.A. None



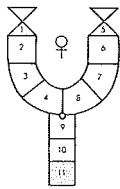
When last seen at age 10 years, after Berkowitz removed the maxillary expander, the patient revealed a good arch and good occlusion with a long, mobile palate producing normal speech.



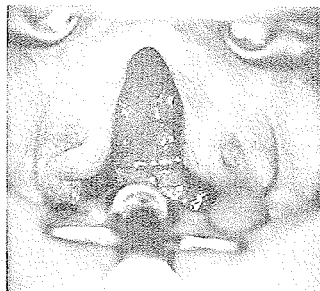At rest

"Aaahh"

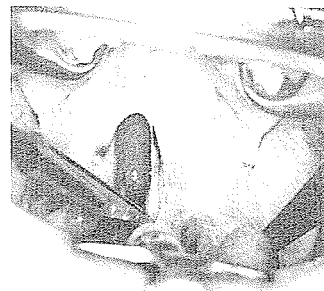B.D. 12-29-69
 F.H. No clefts
 E.T. Uneventful
 O.C.A. None



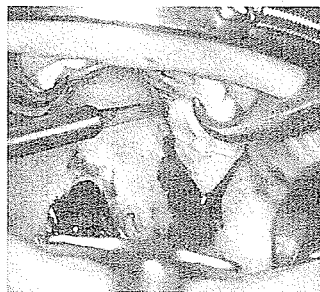CASE 8 was born with a short, cleft soft palate. At age 2 years she had a V-Y palate pushback preserving an anterior V-wedge of mucoperiosteum. After release of the soft from the hard palate, a 1.5 cm. wide left island flap was inserted into the nasal lining defect. The levator muscles were freed from the hard palate, dissected into bundles and sutured into a retroposed, intact muscle loop.



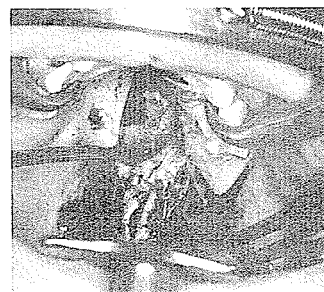
Short, cleft soft palate




Splitting edges



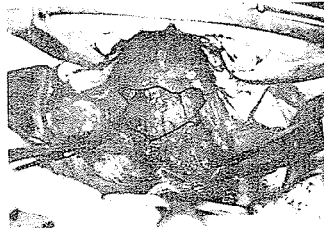
Horseshoe incision



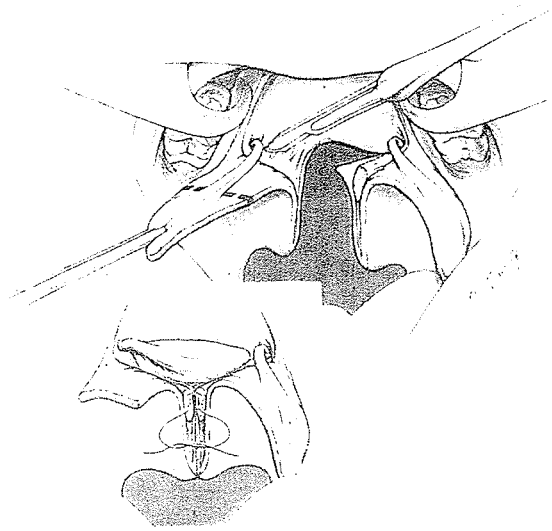
Left mucoperiosteal flap being elevated




Dividing nasal lining



Amount of pushback evident in nasal defect



Dissecting the levator muscle attachments from the hard palate and suturing them into an intact loop



Island bundles being dissected



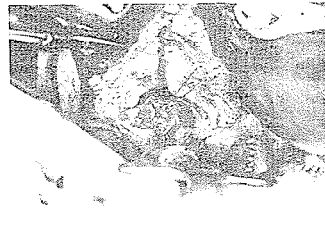Cutting the island free



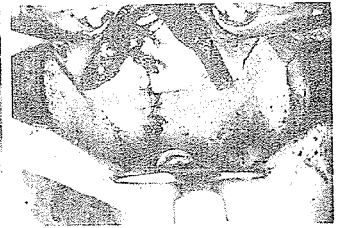Island being sutured



Nasal lining defect now closed

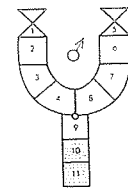


Levator muscle bundles being sutured

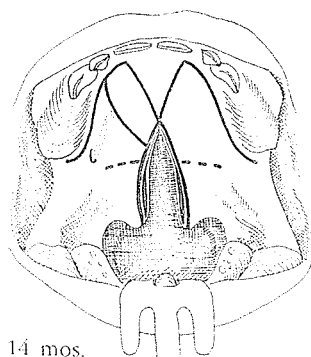


Asymmetrical V-Y closure of mucoperiosteal flaps

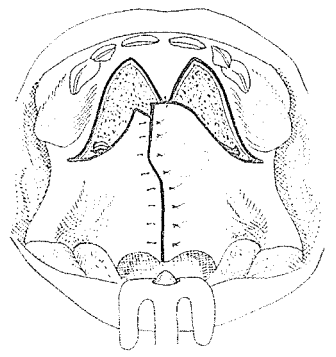
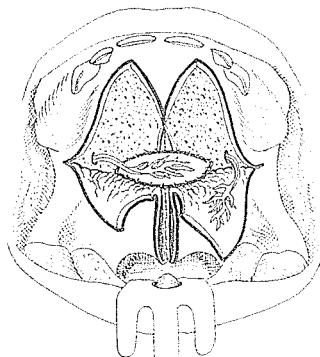
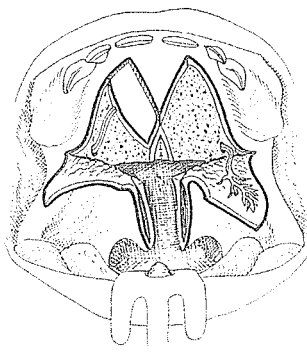
CASE 9, showing a moderate cleft of all of the soft and a portion of the hard palate with thin soft tissue elements, was treated with a pushback using a unilateral island flap at 14 months of age, with no fracture of the hamulus. Peter Randall assisted.

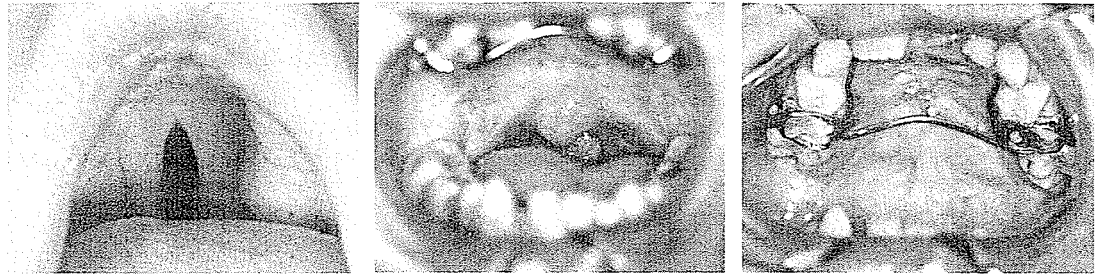

B.D. 10-4-70
 F.H. No clefts
 F.T. Uneventful
 O.C.A. None



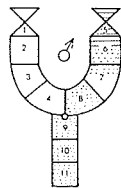
14 mos.



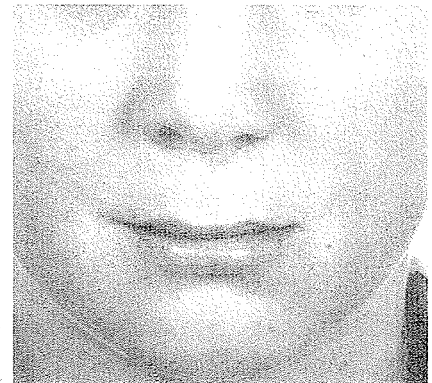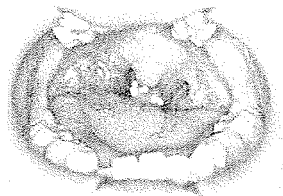

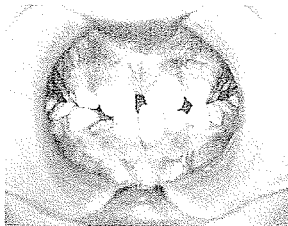
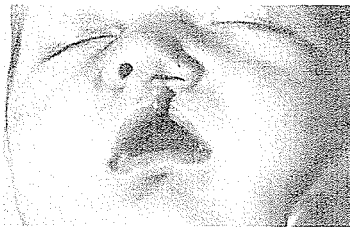

At age 6 years basal and lateral view videofluoroscopic evaluations were conducted during isolated and connected speech. The lateral view indicated light contact, but the basal view was somewhat obscure, suggesting no contact in connected speech. Because the patient's speech was "incredibly" good, intensive speech therapy was instituted. At age 7 years speech seemed near normal and occlusion of the teeth was good, but an expansion wire was still in place.

B.D. 6-11-70
 F.H. No clefts
 F.T. Uneventful
 O.C.A. None



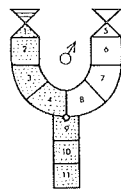
CASE 10 was born with an incomplete unilateral cleft of the lip, an alveolar notch and a cleft of the soft and part of the hard palate. At age 3 months the lip was closed with the rotation-advancement method. At 11 months a V-Y pushback was done using a right mucoperiosteal island flap to fill the nasal lining defect. At 8 years of age the child has normal speech but requires maxillary expansion to improve occlusion.



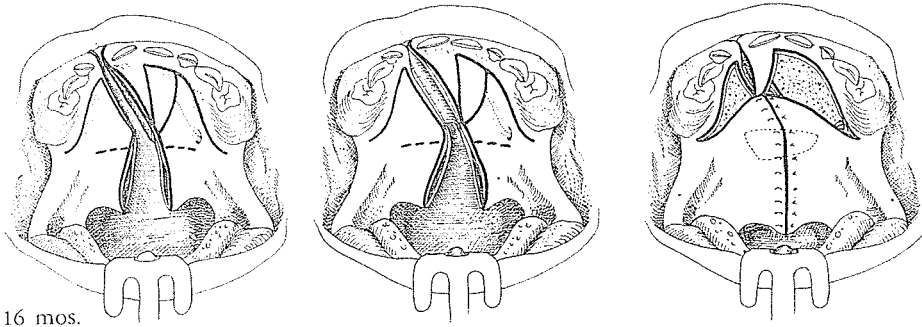
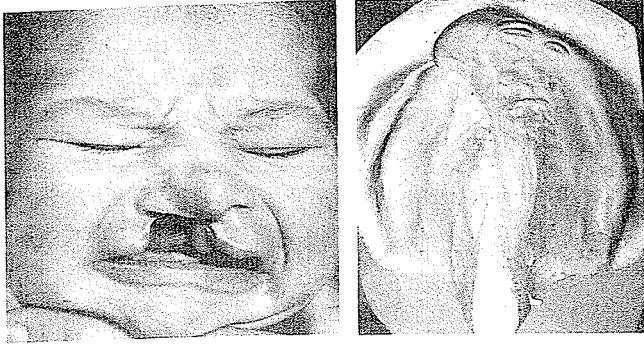
At rest

"Aaahh"

Vol. I P. 509
 B.D. 4-16-71
 F.H. No clefts
 F.T. Uneventful
 O.C.A. None

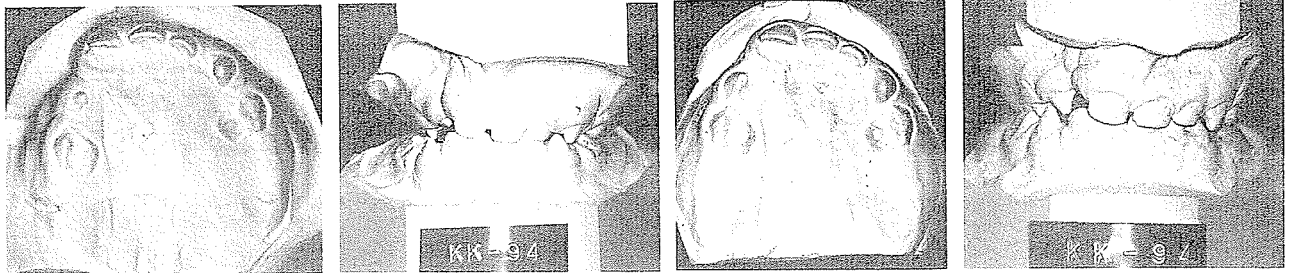


CASE 11 was born with a complete unilateral cleft of the lip and palate. A lip adhesion was performed at 3 weeks of age to mold the maxillae and was followed with a rotation-advancement lip closure at 5 months. On 2-18-72, at age 10 months, the palatal arch molding and growth were good. On 9-1-72, at 16 months, the hard palate cleft was closed with a turnover vomer flap and the soft palate lengthened by a V-Y pushback using a right island flap to fill the nasal lining defect.



16 mos.

On 2-7-73, the palatal scar had brought the lesser segment medially into buccal crossbite. Palatal form had stabilized by 9-6-73.



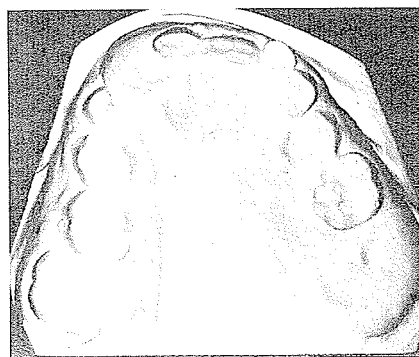
2-7-73

9-6-73

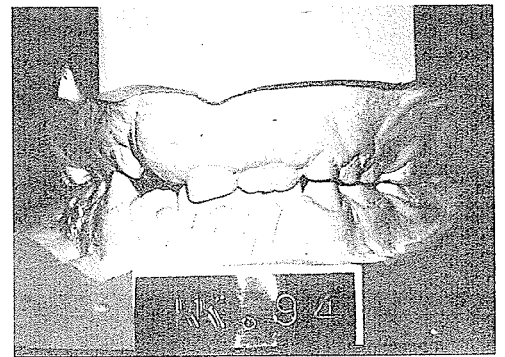
At age 4 years and again at 7 years speech reported normal



Age 7 years

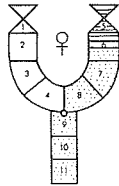


6-24-78 After orthodontia; excellent palatal development

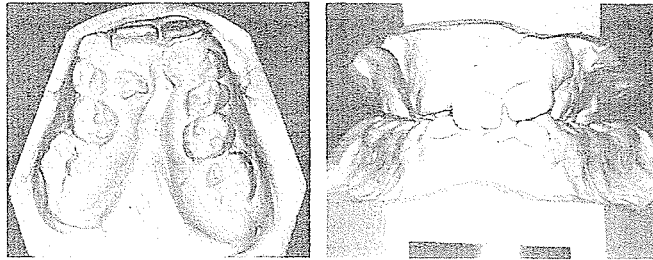
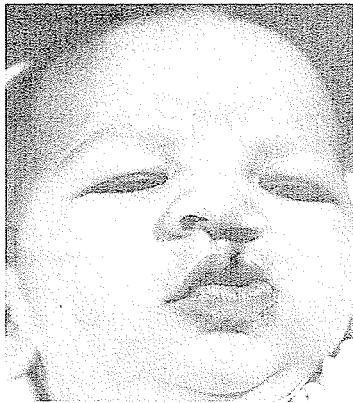

Bottom line: The "early island" gave good speech in 80 percent of the patients, with minor orthodontic correction required in 70 percent. The maxillary distortion in some cases was so great that it not only troubled the orthodontist but may require a Le Fort I advancement in a rare case. This possibility is seen in a couple of the following four cases.

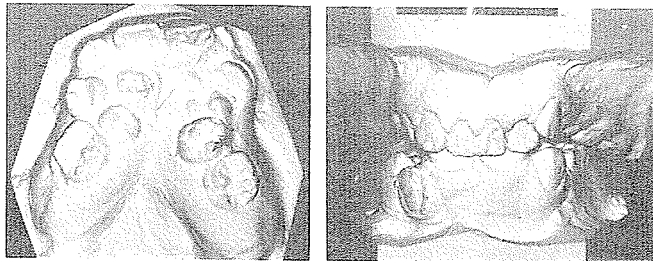
Vol. I P. 351
 B.D. 10-7-63
 F.H. No clefts
 F.T. Uneventful
 O.C.A. None



CASE 12 was born with an incomplete cleft of the lip but a wide cleft of the palate. At 2½ months rotation-advancement closed the lip and at 7½ months was followed by closure of the hard palate cleft with a vomer flap. At 18 months a V-Y pushback was performed with a right island flap inserted into the nasal lining defect. Normal speech was noted at 3 years, and speech is still normal at 13 years. Development of the maxilla was not so normal: This is one of the cases recorded by Berkowitz which caused me to stop the early island flaps!



(Age 9) 9-27-72 Good anterior tooth relationship, even with buccal crossbite



(Age 13) 3-13-76 Palatal distortion and anterior crossbite

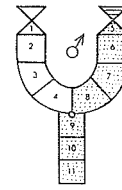


Berkowitz noted:

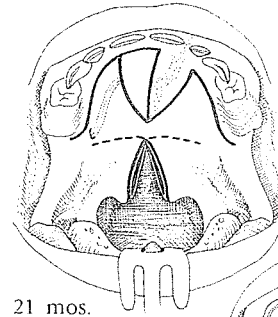
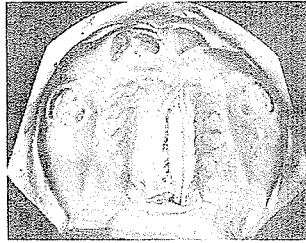
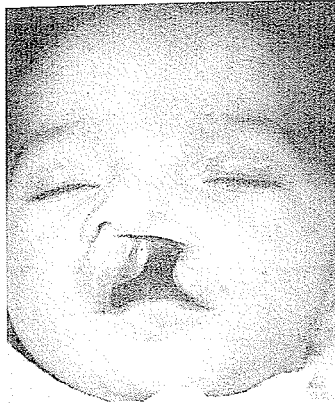The too-early island flap resulted in maxillary growth inhibition in all three dimensions. Both lateral segments were drawn medially, obliterating the palatal vault space. Anterior-posterior growth disturbance resulted in arch length deficiency with crowding of teeth and anterior cross-bite.

Orthodontia has begun to expand and advance the upper arch. Maxillary osteotomy may be required eventually if orthodontia cannot correct the deformity.

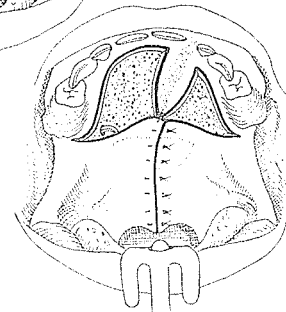
CASE 13 had a severe cleft of the lip, alveolus and palate with a deficiency of the maxilla and distortion of the nose. At 3 months of age rotation-advancement closure of the lip was carried out. The anterior palate cleft was closed at 18 months with a vomer flap. The patient had excellent arch form and palatal segmental relationship before the island flap, as seen in Berkowitz' model.



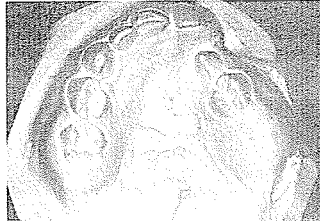
Vol. I P. 502
 B.D. 3-9-65
 F.H. Paternal cousin with lip cleft
 F.T. Uneventful
 O.C.A. None



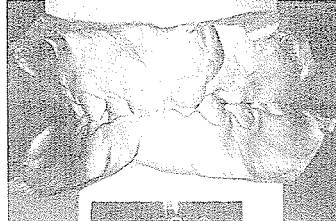
21 mos.




At 21 months a V-Y pushback of the palate was achieved, leaving the V over the anterior closure untouched and taking a unilateral island flap for nasal lining. Nine months after palate surgery, models show the transverse palatal scar causing medial pull of the lesser segment and carrying the buccal teeth into crossbite.



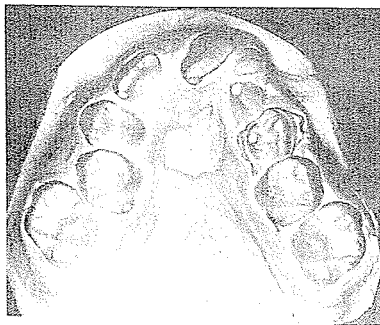
8-67 Crossbite after island



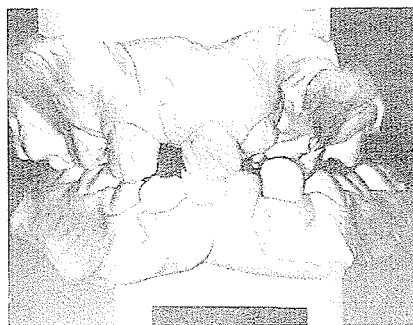
2-68 Orthodontic correction

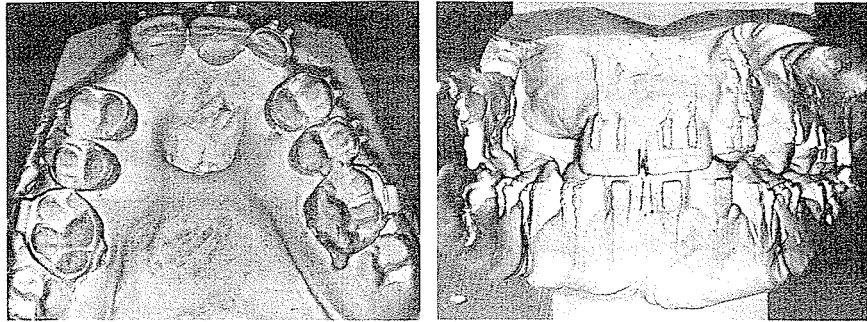


Palatal expansion widened the arch, correcting the crossbite. On 11-10-70 an iliac bone graft was placed across the cleft. Removal of orthodontic retention permitted medial relapse of the lateral palatal segments, resulting in palatal narrowing and severe buccal crossbite (11-73).

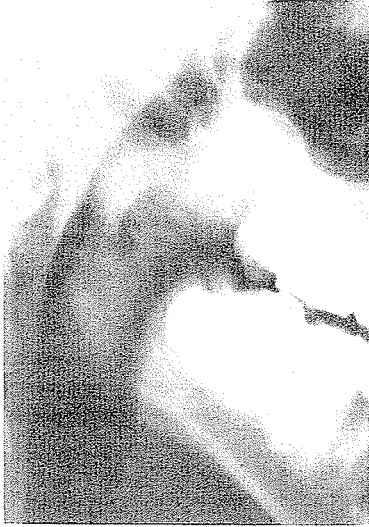

11-73



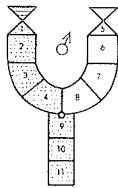


7-78

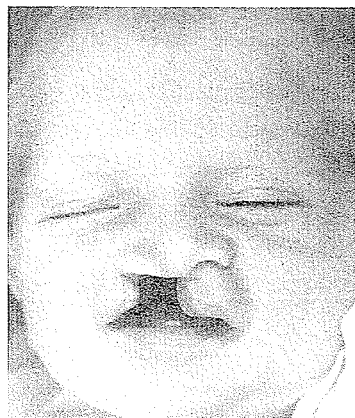


After orthodontic advancement and expansion, occlusion was achieved in spite of the palatal scar, but fixed retention will be necessary to maintain arch form integrity (7-78). At age 10 years the patient had normal speech. Cephaloradiographs made in 1978 by Berkowitz show the velum contacting the pharyngeal wall with vocalization of u.

Vol. I P. 503
 B.D. 5-4-66
 F.H. Paternal
 great-grandmother
 had twins—one
 with CL&P
 F.T. Bleeding
 O.C.A. None

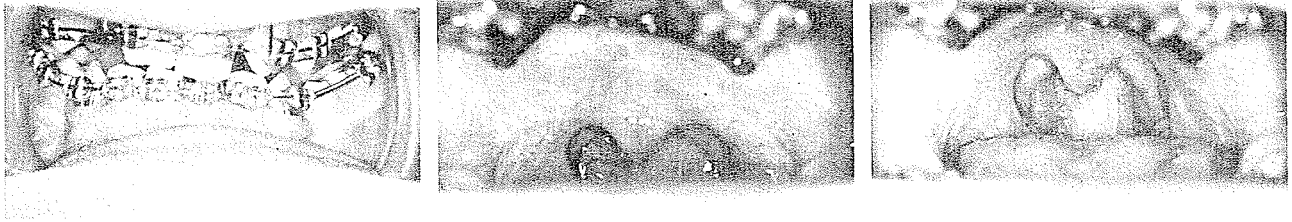

CASE 14 was born with a severe right complete cleft of the lip and palate with maxillary deficiency. At 4 months of age the anterior palate cleft was closed with a Burian flap and the lip with rotation-advancement. At 15 months maxillary expansion was started with a pinned screw plate, and at 20 months of age rib bone grafts were inserted across and into the cleft. At 2½ years, a V-Y palatal pushback was done using a left island flap to fill the nasal lining defect after release of the soft palate from the hard palate edge.



At age 12 years the patient has a long, mobile palate with good speech.

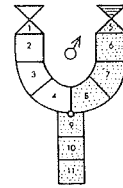
The original deficiency of the maxilla, the bone graft at 20 months and the denudement of the hard palate by the island flap at 2½ years seem to have influenced maxillary development with resulting arch contracture and crossbite. Treatment by expansion springs has brought improvement in occlusion, but it is possible that the patient will require maxillary onlay grafts at 15 to 16 years.



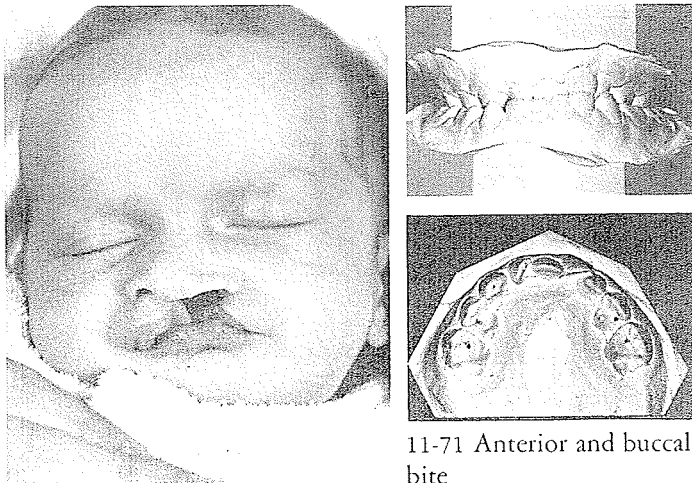
At rest

"Aaahh"

CASE 15 was born with a complete unilateral cleft of the lip and palate with a severe nasal deformity. At 2½ months the *anterior palate* was closed with cleft edge mucoperiosteal flaps, covered on the nasal side by a mucosal flap of the *inferior turbinate* based inferiorly after removal of bone. At 3½ months the lip was closed by the rotation-advancement method, but without *nasal tip correction*. At 11 months the alveolar and anterior hard palate cleft was filled with a *rib bone graft* and covered with a Burian labial flap. At 18 months a *V-Y pushback* of the palate was performed using a unilateral right *island flap*.



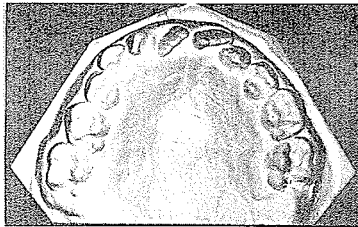
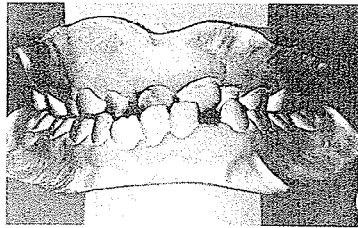
Vol. I P. 504
 B.D. 10-14-66
 F.H. No clefts
 F.T. Uneventful
 O.C.A. None



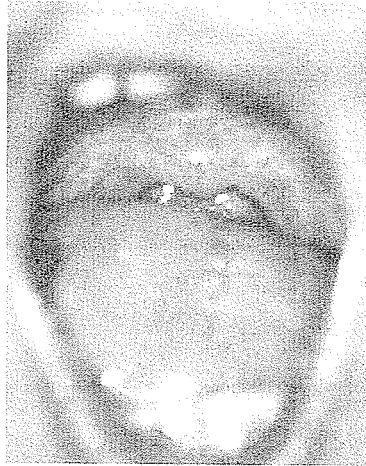
11-71 Anterior and buccal cross-bite

When the patient was seen in cleft palate clinic in 1971 at age 5 years, the speech pathologist reported that speech was essentially normal. The orthodontist noted collapse of the maxillary segments and an anterior crossbite deserving orthodontic treatment.

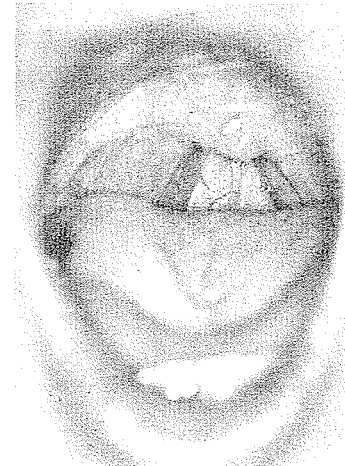
Orthodontic expansion of the maxilla was started, with improvement in occlusion. This treatment will continue, and at age 16 years a corrective rhinoplasty will improve the boy's appearance.



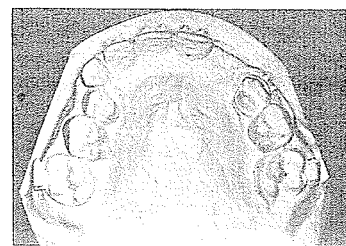
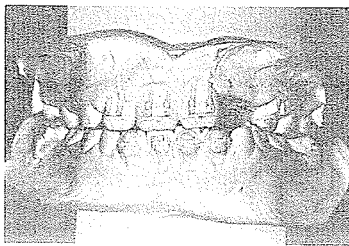
5-76 After buccal expansion and occlusal correction



At rest



"Aaahh"

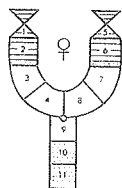


After advancement, maxillary incisors are in proper overbite-overjet relationships. Note excellent arch form and good vault space.

Although a convenient, early anterior cleft closure and normal speech were obtained and intentions were the best, using the turbinate in the anterior closure possibly started maxillary collapse. Then the early bone graft may have retarded growth. Subsequent early denudation of the maxilla with mucoperiosteal flaps and an island further affected the maxilla so that its growth was abnormal. It is remarkable that orthodontia seems to be expanding the arch with correction of the occlusion.

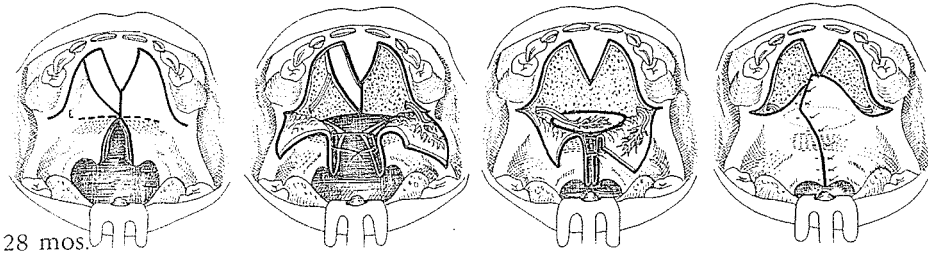
Bottom line: The temptation of convenience of anterior cleft closure and early pushback with an island for good early speech must be resisted until maxillary growth has progressed to 5 years.

Vol. II P. 199
 B.D. 1-26-68
 F.H. No clefts
 F.T. Infection
 O.C.A. None



BILATERAL CLEFTS—INCOMPLETE. CASE 16 was born with an incomplete bilateral cleft of the lip and a cleft of the soft palate. At 4½ months of age a bilateral rotation-advancement closure of the lip, without columella lengthening, was done. At 28 months a V-Y pushback of the

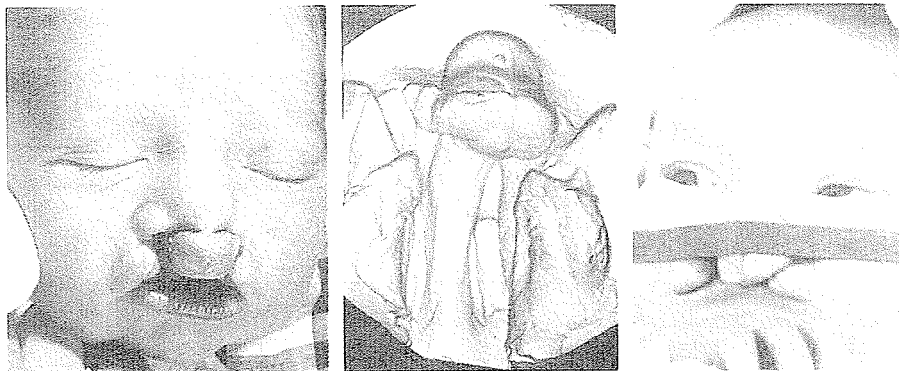
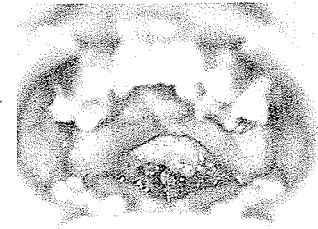
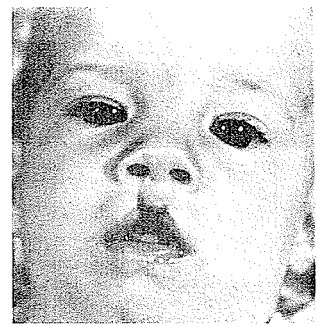
palate, leaving a V anteriorly, was achieved using a 1.25 cm. wide right island flap to fill the nasal defect. The levator muscles were freed from the edge of the hard palate, dissected into bundles and sutured into an intact loop.



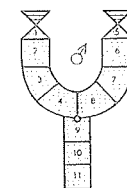
28 mos.

When the patient was seen in cleft palate clinic in 1972, at the age of 4 years, her speech was normal but a severe buccal crossbite of the molars was noted and orthodontic therapy advised. When seen in 1978 at the age of 10 years, she still had normal speech, but as no orthodontia had been used the crossbite was still present. The patient is now receiving dental correction.

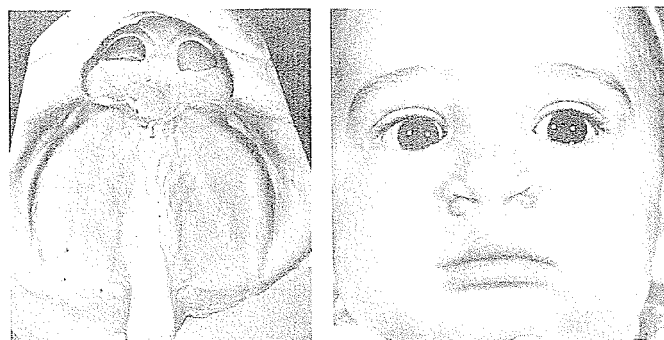
BILATERAL CLEFTS—COMPLETE. CASE 17 was born with complete bilateral clefts of the lip and palate, a projecting premaxilla and almost no columella. Rubber band traction was started at 7 days, and at 3 months of age the lateral lip mucosa and muscles were joined in the midline behind the prolabium and a forked flap was banked in whisker position.



11-19-69 Before rubber band 11-26-69 During rubber band traction



Vol. II P. 409
 B.D. 11-12-69
 F.H. Mother has same deformity
 F.T. Uneventful
 O.C.A. None

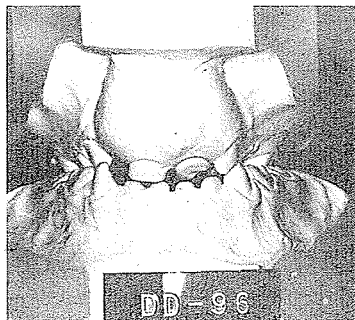
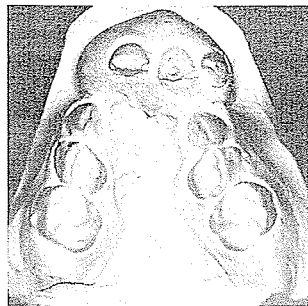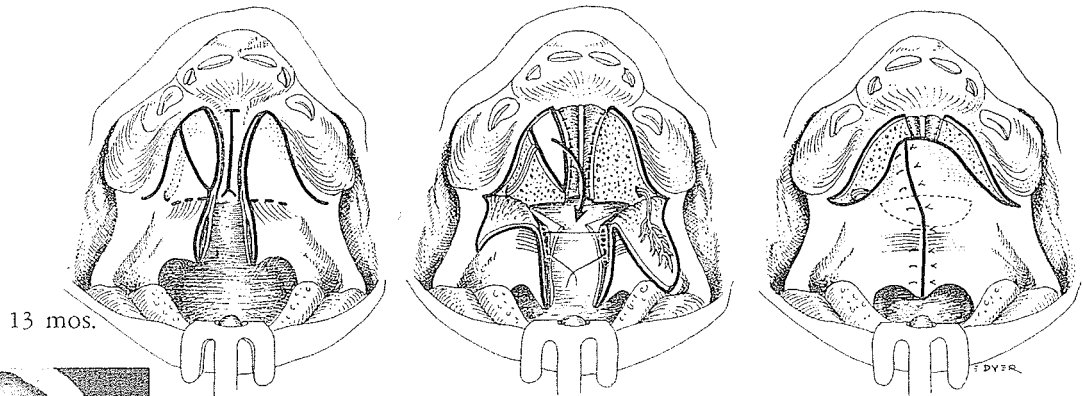


8-7-70 After closure of lip and fork banking

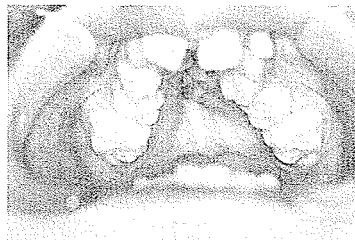
Berkowitz described the condition of the maxillae after lip closure:

Excellent approximation of the premaxillary and lateral palatal processes with marked reduction in the cleft space.

Two and a half months later, on 4-23-70, the banked fork was advanced into the columella. 12-10-70, at age 13 months, a V-Y pushback was achieved using a right mucoperiosteal island flap to fill a 1 cm. nasal lining defect. Vomer flaps were turned laterally for nasal closure. The levator muscles were dissected free and sutured into an intact muscle loop. A postoperative suction test was positive.



2-13-74



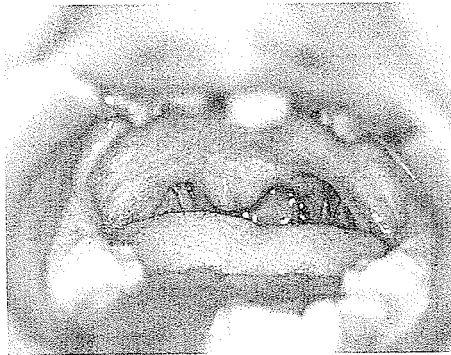
In 1974 otological examination revealed fluid in the right ear and retraction of the left superior tympanic membrane. Bilateral myringotomy was followed by insertion of P.E. tubes. Cleft palate clinic evaluation of speech and hearing found no abnormalities in 1976 and again in 1978, but the orthodontist's report was not so happy. Berkowitz reported on the 1974 models:

After island flap and palatal cleft closure at 13 months, the resulting palatal scar tissue caused distortion with bilateral crossbite. Where the premaxilla was in extreme overjet at the newborn period, at the age of five years, the incisor teeth were in tip-to-tip relationship due to diminished anterior-posterior maxillary growth.

Maxillary expansion was advised.

Bottom line: In complete bilateral clefts, as in complete unilateral clefts, extensive elevation of mucoperiosteal flaps before 5 years of age is contraindicated because of scar retardation of maxillary growth. In these double clefts it is possible that there will never be enough expendable mucoperiosteum for an island flap. Once the premaxilla and maxillae have been positioned normally and stabilized through the growth period (Latham-Georgiade approach), an island flap is sometimes available. At the

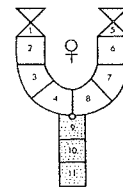
moment, despite the good speech with the primary island flap, I do not use it in bilateral clefts until the teenage years.



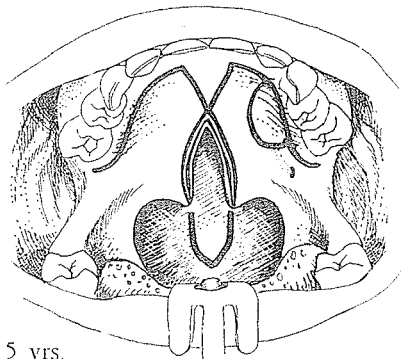
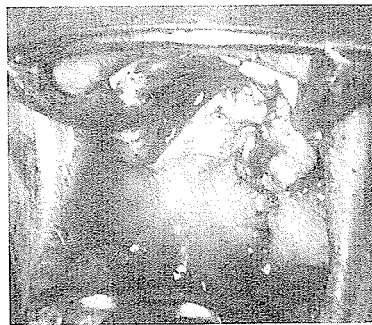

LATER PRIMARY ISLAND FLAPS (AFTER AGE 5 YEARS)

In certain cases the diagnosis or opportunity for operation may be delayed.

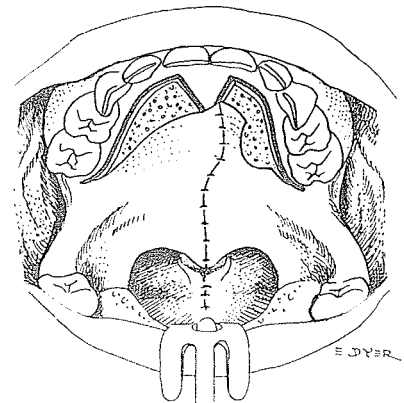
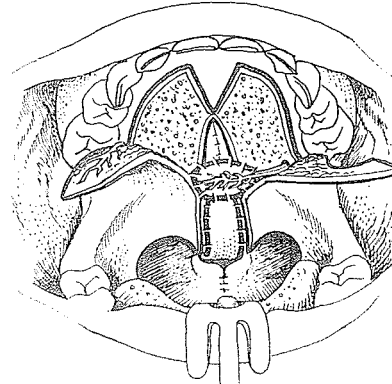
CASE 18 was born with a wide cleft of the soft and half of the hard palate. On 1-18-61, at about the age of 5 years, a V-Y pushback was achieved, taking a small atypical island flap for transverse lengthening of the nasal lining. A superiorly based pharyngeal flap was used primarily to close the nasal side of the soft palate cleft.



B.D. 3-29-56
 F.H. No clefts
 F.T. Uneventful
 O.C.A. None



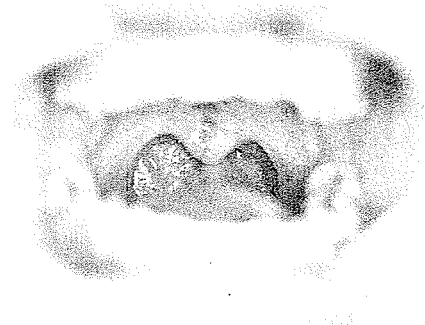
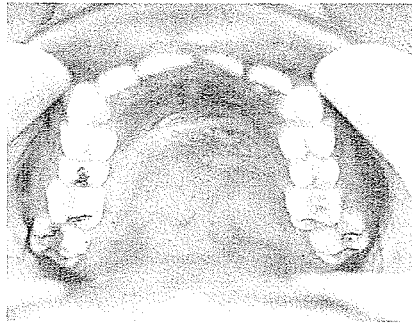5 yrs.



E. DYER

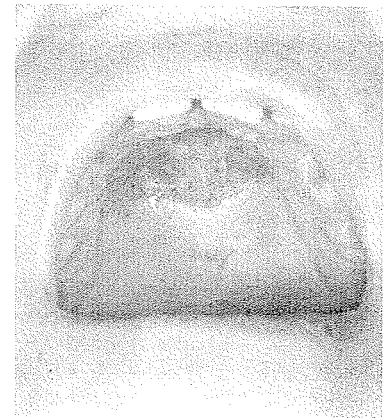
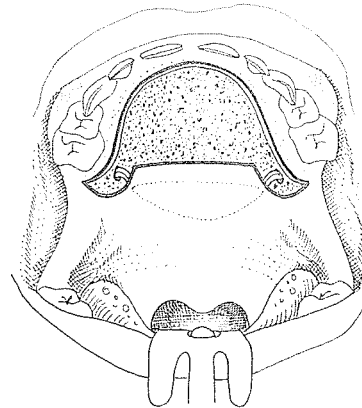
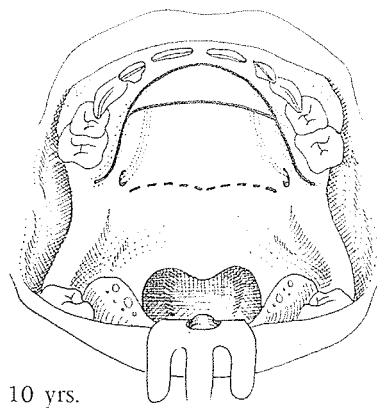


In 1967 cleft palate clinic evaluation reported class I bimaxillary protrusion with a lingual crossbite of the upper left first molar. Speech was normal. Last evaluation in 1977 found teeth in good occlusion and speech normal.

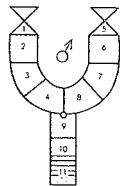


B.D. 11-26-62
 F.H. No clefts
 F.T. Uneventful
 O.C.A. None

CASE 19 was born with an apparently normal palate. Following T & A the patient developed nasal escape in speech; cephalometric studies by Berkowitz revealed an incompetent velopharyngeal sphincter at age 10 years. Mobility seemed good, so on 5-9-73 a pushback of the palate was performed with a bipedicle island flap inserted into the nasal lining defect. Healing was uneventful, with the donor area of the island epithelialized in three weeks. Speech pathologist Bensen reported a long, mobile palate with normal speech in 1974, and again in 1976.



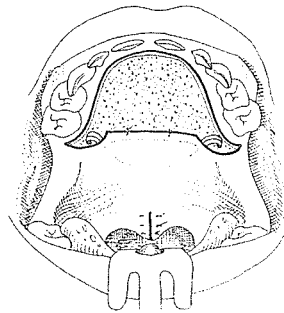
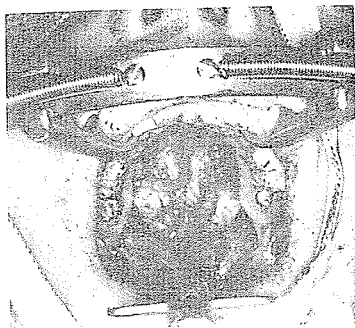
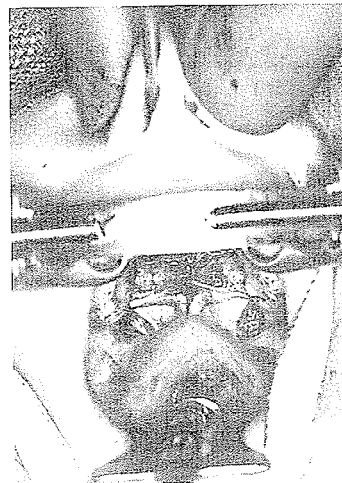
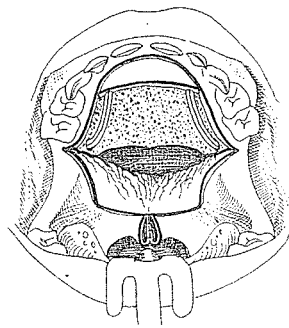
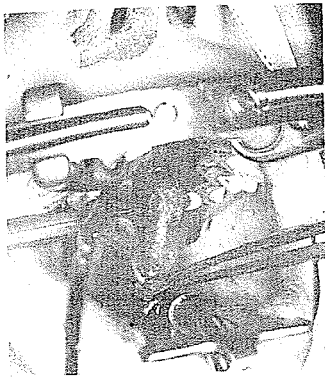
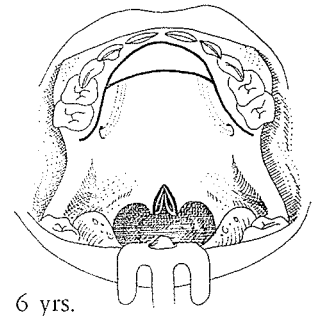
B.D. 2-4-67
 F.H. No clefts
 F.T. Uneventful
 O.C.A. None



CASE 20 was born with a submucous cleft palate with a V defect in the hard palate, cleft in the muscle with mucosa intact and a bifid uvula. Following T & A at 5 years the patient began to have nasal escape. Cephalometric studies by Berkowitz revealed a 1 cm. gap between the velum and pharynx on vocalization of u.

On 10-11-73, at the age of 6 years, a horseshoe-shaped incision was used to dissect the mucoperiosteum. Bilateral neurovascular bundles were freed

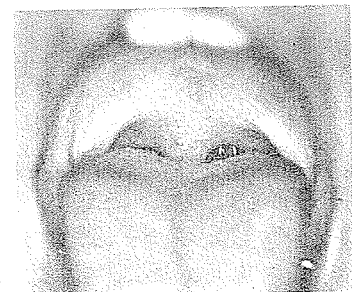
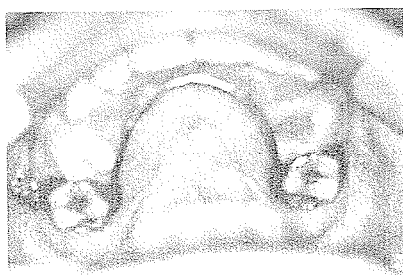by sharp dissection, and a 1.5 cm. island flap cut free from the anterior portion was inserted into the nasal lining defect after division of the mucosa along the edge of the hard palate. The levator muscle attachments were moved back by the release but not dissected as discrete bundles. The hamulus was not fractured. A suction test was positive.



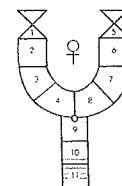
Island in nasal defect

Positive suction test

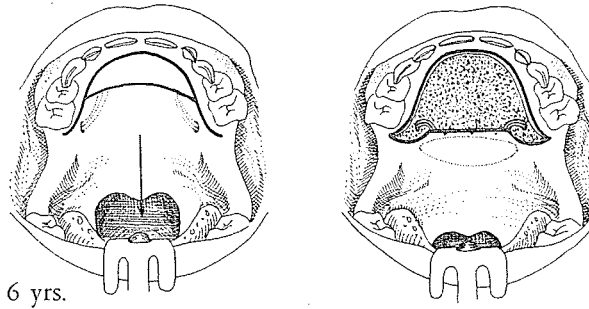
Cleft palate clinic evaluations in 1975 and 1977 found normal speech and hearing. The maxillary arch was narrowed and the vault space diminished. Buccal crossbite existed at both maxillary molars. In 1978 expansion wires to correct a maxillary hourglass deformity were in position. The palate was mobile and producing normal speech.



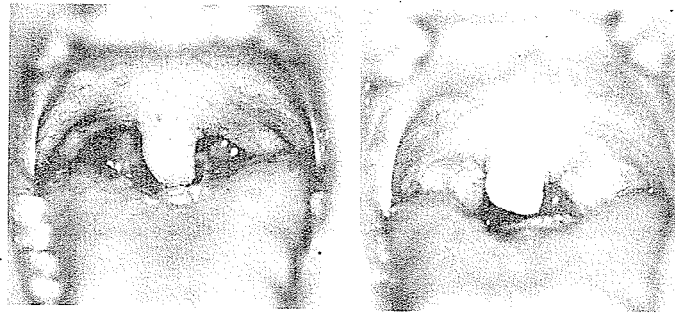
CASE 21 was born with a submucous cleft palate with a hard palate defect, cleft in the muscle, bifid uvula, short velum and nasal escape in speech. On 1-21-71, at age 6 years, a pushback was accomplished using an anterior bipedicle island flap transposed into the nasal lining release.



B.D. 4-2-65
 F.H. No clefts
 F.T. Uneventful
 O.C.A. None

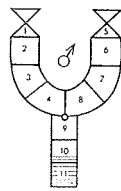


6 yrs.

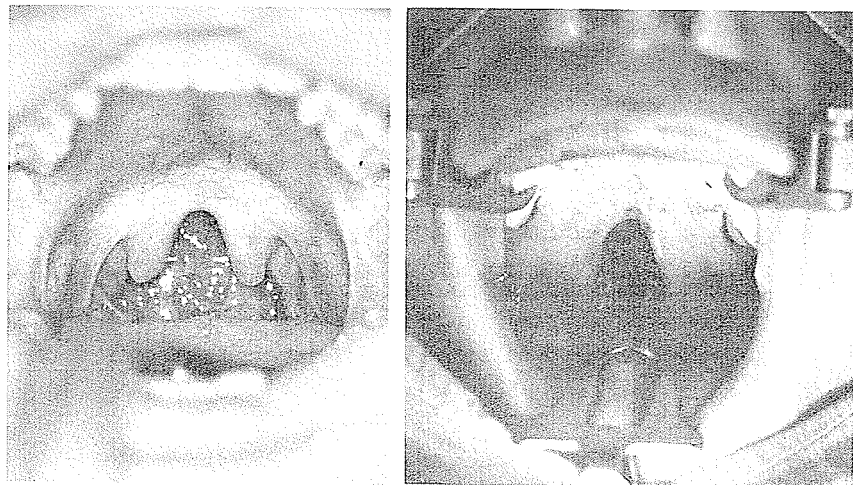


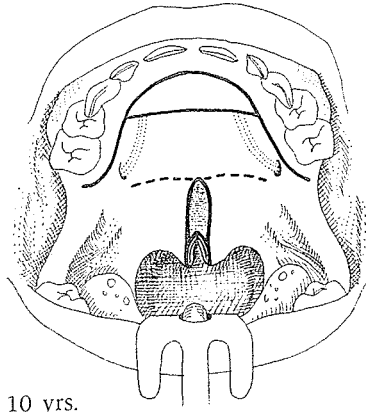
In 1975 orthodontic braces were used for maxillary expansion. In 1976 evaluation in cleft palate clinic found good occlusion with no crossbite and a long, mobile palate with normal speech. Photos taken in 1977 show the musculus uvulae contracting into an "inchworm."

B.D. 6-16-66
 F.H. No clefts
 E.T. Uneventful
 O.C.A. None

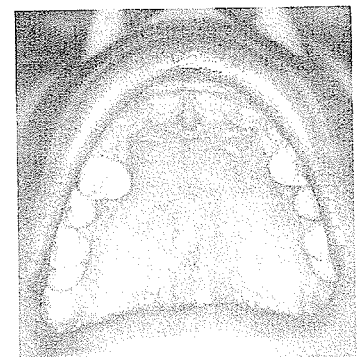
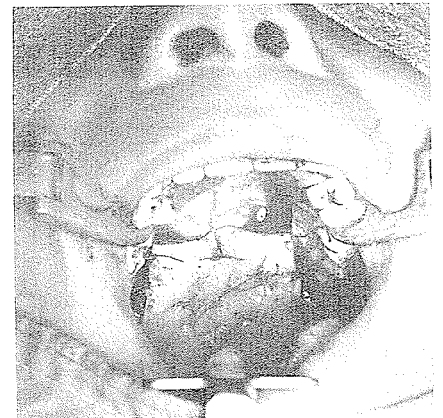
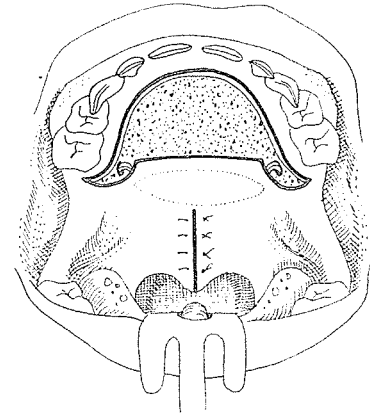
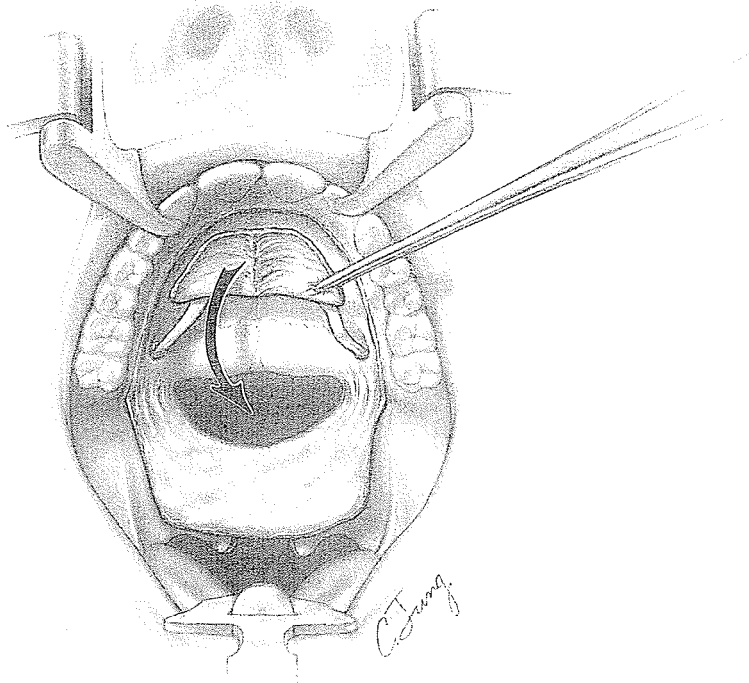

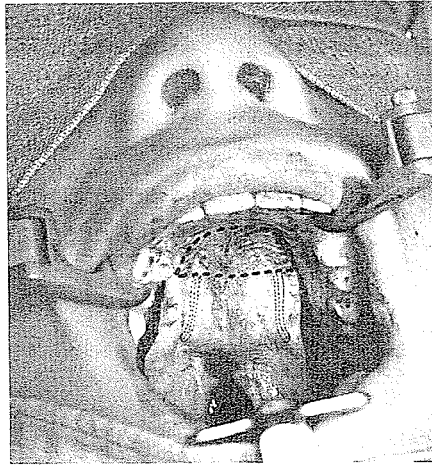


CASE 22 was born with a submucous cleft palate which caused difficulty in speech. At age 10 years, the speech pathologist in cleft palate clinic noted excellent movement of the palate and lateral pharyngeal walls, a short palate, nasal escape and good articulation. On 10-20-76, at age 10 years, a portion of the translucent area of the velum was excised and the edges of the bifid uvula were pared prior to a three-layer closure of the soft palate. A horse-shoe-shaped incision well away from the teeth allowed elevation of a mucoperiosteal flap. The anterior portion, taken as a bipedicle island flap, was used to fill the nasal lining defect after release of the soft palate from its attachments to the hard palate.





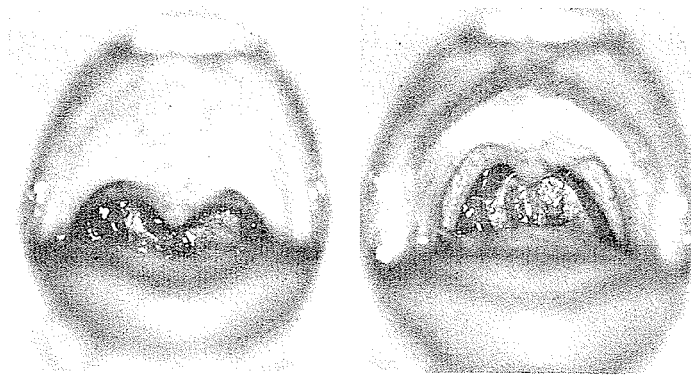
10 yrs.



Healed donor area

Two years after surgery the palate seemed slightly short; there was good speech with individual words and slight nasal escape in conversation. Cephalometric studies by Berkowitz revealed good velopharyngeal closure, but Dickson's nasendoscopy found a slit-like aperture during velopharyngeal closure for speech in the area of the right lateral port and a probable similar condition on the left. The posterior palate translucency indicated a thinness in this submucous cleft.

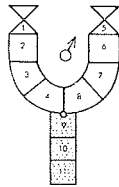
Assessment: Mild hypernasality; moderately good lateral wall and velar activity; short palate. This does not appear to be a problem which will be alleviated by speech therapy alone. The parents refuse further surgery (pharyngeal flap), but, as the hypernasality is of a mild degree and probably does not present too much difficulty, it can be postponed for now.



At rest

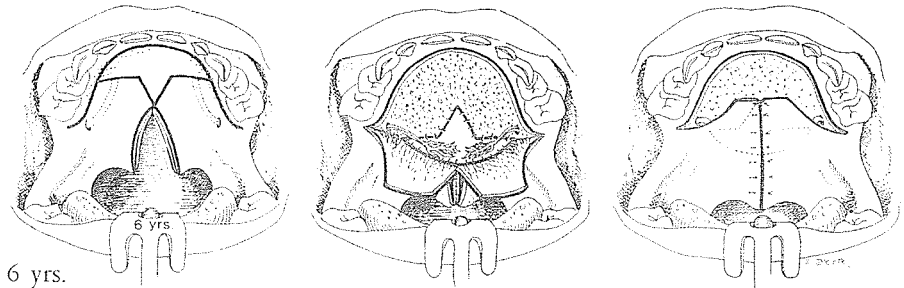
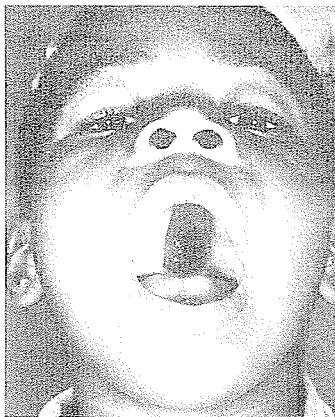"Aaahh"

B.D. 1960
 F.H. No clefts
 F.T. Uneventful
 O.C.A. None



CASE 23 was born in Haiti with a cleft of the entire soft palate and two-thirds of the hard palate. The cleft was over 1 cm. wide at the greatest point and remained untreated until, at the age of 6 years, the patient was first seen presenting typical nasal cleft palate speech.

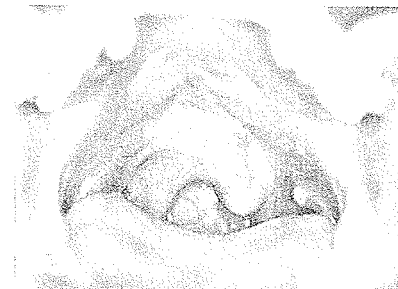
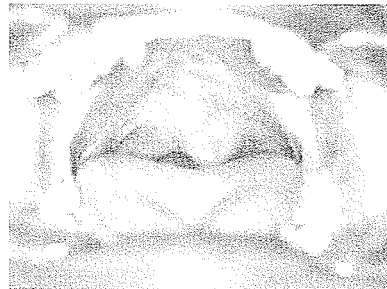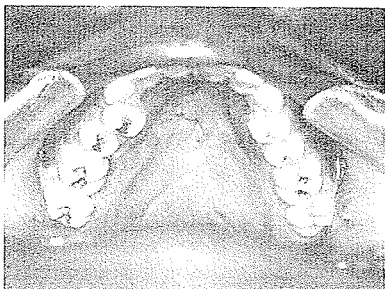
On 9-21-66 a V-Y pushback of the palate was carried out using a *special* designed bipedicle island flap for nasal lining.



6 yrs.

In 1967 Pigott studied this palate with his early method of endoscopy eight months postoperatively and reported only minor nasal emission. Speech therapy was advised.

In 1971, 1973 and 1974 the patient was evaluated in cleft palate clinic by all disciplines and reported to have normal speech, normal hearing and normal occlusion. He was last seen in 1978 with an excellent result.



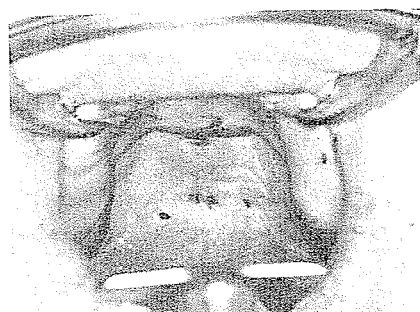At rest

"Aaahh"


CASE 24 had always had difficulty with speech. At the age of 30 years, evaluation in the cleft palate clinic reported:

Gross nasal emission is present on all consonants. . . . He uses the substitution of a glottal stop for many phonemes. He is now expressing a concern [about] the low degree of intelligibility. There is suspicion of congenital palatal insufficiency.

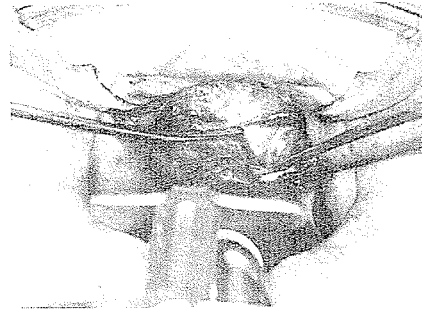
Cephalometric studies by Berkowitz revealed an A-P gap of at least 1 cm. On 5-30-73 a V-Y pushback was performed, the nasal lining defect being filled with a 1.25 cm. wide right island flap. The details of the surgical steps were recorded photographically.



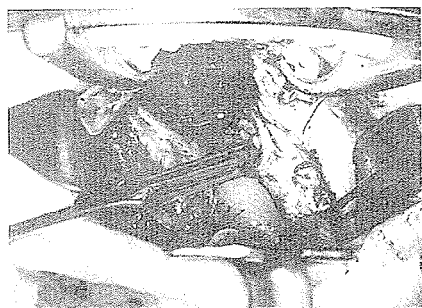Anterior island donor area marked




Horseshoe-shaped incision being made



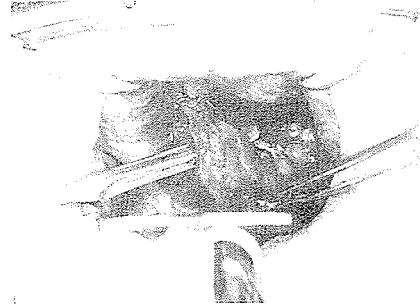Mucoperiosteal flap dissected off bone



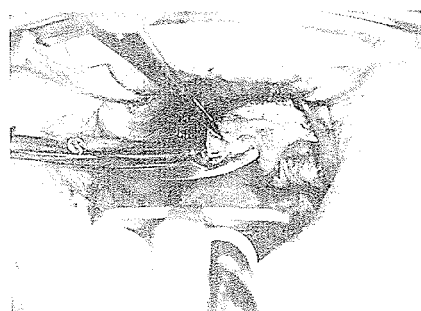
Freeing left neurovascular bundle for pushback



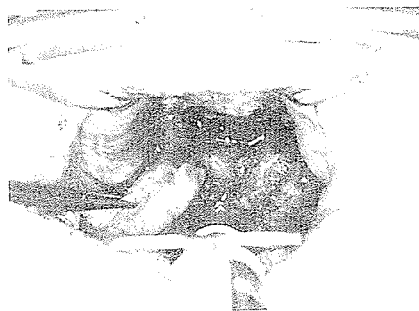Releasing nasal lining from hard palate (No. 11 BP blade)




Freeing island neurovascular bundle (No. 15 BP blade)



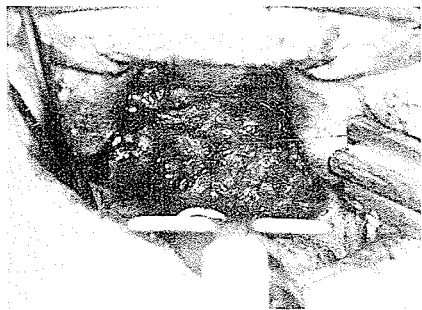
Cutting the mucoperiosteal island free



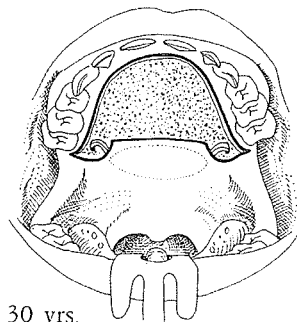
Island poised to go into nasal defect



Key sutures in the distal ends of island for placement in defect

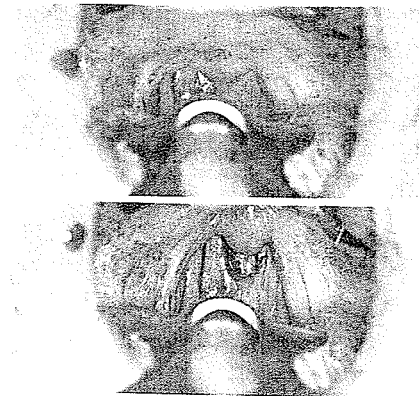


Island sutured into nasal defect



30 yrs.

Pushback with island flap completed



Postoperatively: At rest (above) and positive suction test (below)

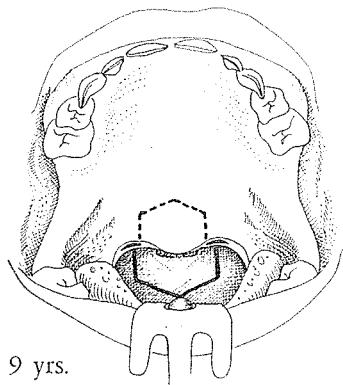
Even when a potentially normal palate is constructed at age 30 years, speech therapy is indicated to eradicate bad habits.

Bottom line: The later primary island flap achieved good speech results in a high percentage of cases but with much less arch and dental distortion. The fortunate delay in surgery in these cases was due in great part to the late diagnosis of submucous cleft palate.

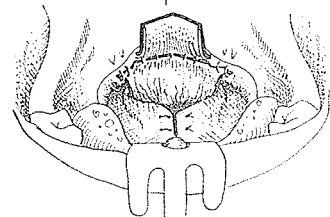
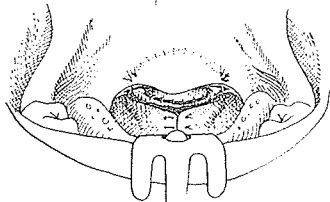
PRIMARY PHARYNGEAL FLAP

There are certain cases with palatal paralysis, large cleft defect, huge velopharyngeal gap or unavailable island flap in which a primary posterior pharyngeal flap may be of benefit.

B.D. 2-4-62
F.H. No clefts
F.T. Uneventful
O.C.A. None



9 yrs.

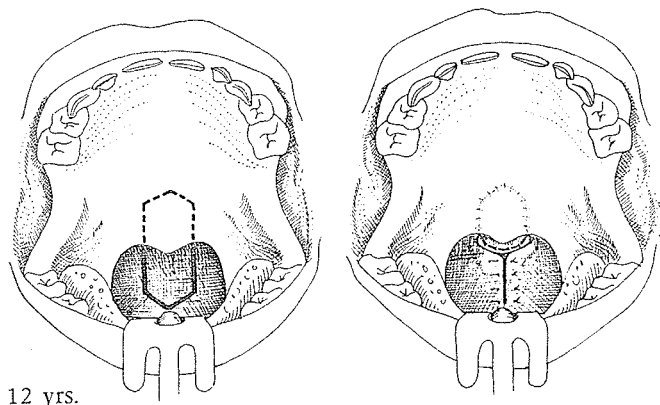


CASE 25 revealed speech difficulty to the parents at 2 years of age. At cleft palate clinic the diagnosis of paralysis of the velum was treated by a speech aid ineffectively. On 6-4-69, at age 7 years, a 1 cm. superiorly based pharyngeal flap was attached to the upper surface of the velum and the raw flap partially covered with a turnback mucosal flap from the uvula.

On 9-13-70 our speech pathologist noted some improvement but recorded nasal escape on all fricatives and on some plosives in conversation. On 4-20-71, at age 9 years, a second, wider (2 cm.) superiorly based pharyngeal flap was attached along the free border of the velum and again partially covered with a turnback mucosal flap from the uvula. This maneuver was carried out just beneath the previous pharyngeal flap and without disturbing it. On 11-26-73 the patient stated that her speech had improved so much that speech therapist Bensen saw her only once a year.

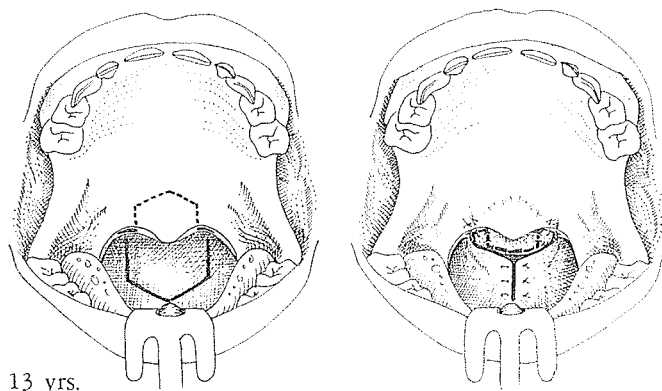
Bottom line: A paralyzed velum usually requires a *wide* pharyngeal flap.

CASE 26 had a congenitally short palate with good levator action but incompetent velopharyngeal closure. The patient was treated at age 12 years with a 1.5 cm. wide superiorly based pharyngeal flap attached to the nasal side of the velum. One year postoperatively, speech was normal except for a slight articulation problem of w/r substitution.



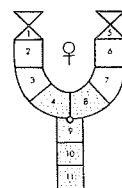
12 yrs.

CASE 27 was born with a normal-looking palate but a large nasopharynx and velopharyngeal incompetence. The problem was first treated with speech therapy, which only frustrated the patient. At age 13 years a 2 cm. wide pharyngeal flap was inserted into a fishtail incision along the posterior border of the velum and on the upper surface of the uvula; a mucosal turnback flap was used to cover the raw undersurface of the pharyngeal flap. In 1969 cleft palate clinic, the speech pathologist reported normal word production without nasal escape and with good prognosis for speech therapy. A parental report in 1978 stated that the patient can speak as well as he wishes, has a job and is getting married.

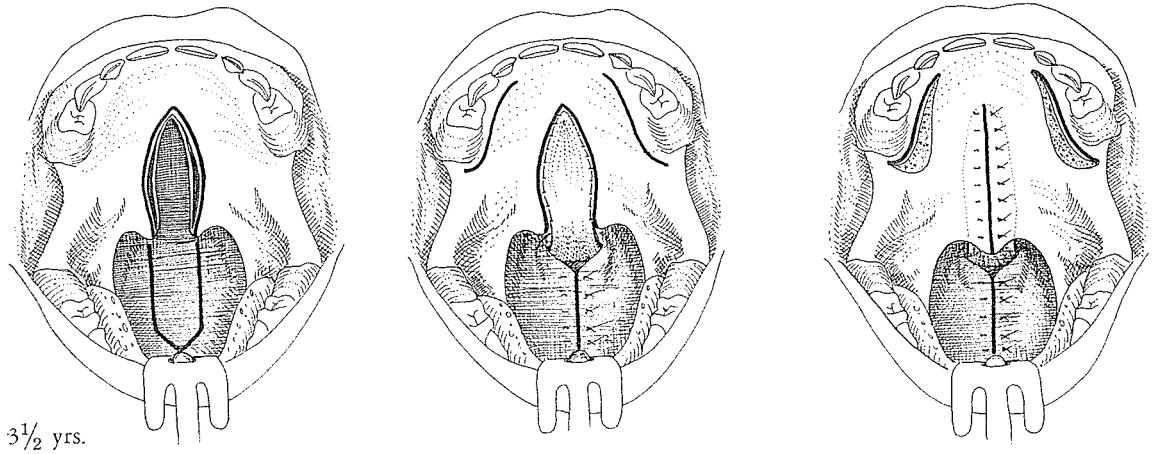


13 yrs.

CASE 28 was born with a wide cleft of the hard and soft palate. On 3-9-61, at the age of 3½ years, a *primary* superiorly based pharyngeal flap was used for nasal lining of this large defect. Von Langenbeck incisions allowed release of the mucoperiosteal flaps for oral closure.



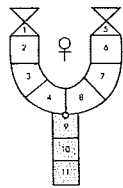
B.D. 9-22-57
 F.H. No clefts
 F.T. Uneventful
 O.C.A. None



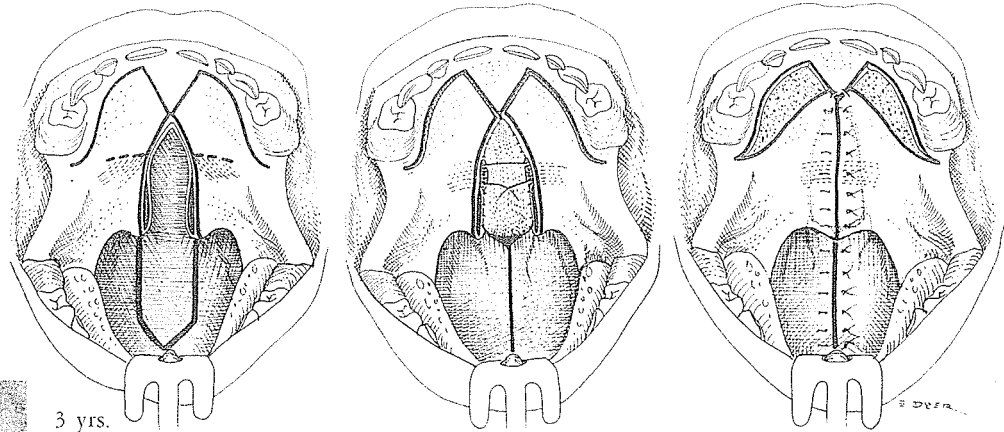
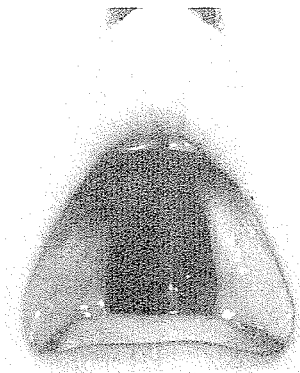
3 1/2 yrs.

Two months after surgery the pharyngeal flap seemed to tether the velum and restrict motion. Division of the flap was contemplated but postponed. In 1963 evaluation of speech in cleft palate clinic revealed a large number of minor sound substitutions, notably f for s and w for l. It was thought that maturation would improve speech without therapy, and, in fact, speech was within normal limits in 1973.

B.D. 5-30-71
 F.H. No clefts
 F.T. Uneventful
 O.C.A. None

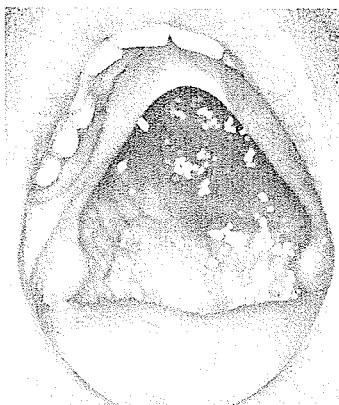


CASE 29 was born with a wide, horseshoe-shaped cleft of the soft and hard palate and a deficiency of tissue. On 4-3-74, at 3 years of age, a primary 1.25 cm. wide superiorly based pharyngeal flap was turned into the entire nasal defect. A V-Y mucoperiosteal flap pushback was carried out. The levator muscle attachments were freed from the edge of the hard palate and sutured into an intact loop, and the oral side was closed with mattress sutures.

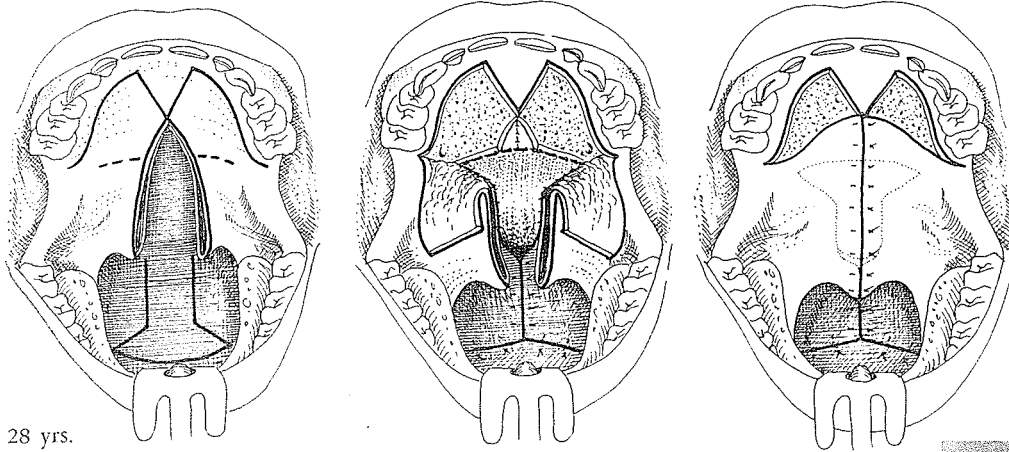


3 yrs.

Examination of the patient in 1978 revealed a mobile palate with good speech having a slight hypernasal quality but no difficulty with s's.

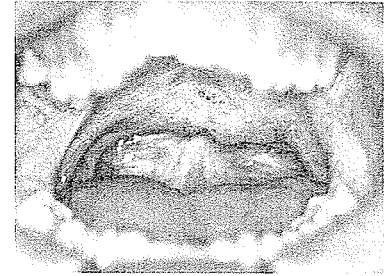

CASE 30 was born with a wide cleft of all the soft and part of the hard palate. This person received no treatment until, at 28 years of age, he joined the police force. An island flap pushback was planned, but during surgery no discrete bundles were found so the nasal defect was filled with a T-shaped superiorly based pharyngeal flap.

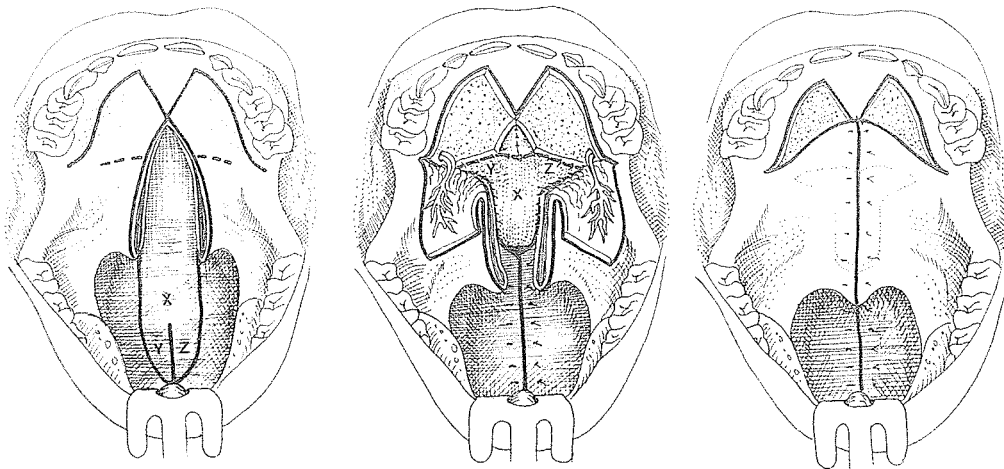


28 yrs.

Ten years later the patient's speech is nearly normal, with minimal nasality causing him no difficulty in his work. He has advanced to the rank of police lieutenant.



CASE 31 had a rather wide cleft of the soft palate, which was short. Treatment included a variation of the T pharyngeal flap. At age 2½ years closure of the cleft and lengthening of the palate was achieved without dissecting mucoperiosteal flaps and endangering maxillary growth. A superiorly based pharyngeal flap was split at its distal end. As the flap was sutured into the nasal side of the cleft, the split ends fitted into the lateral releasing incisions in the nasal mucosa along the posterior edge of the hard palate.

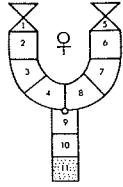


Bottom line: The pharyngeal flap may be *the flap of last resort*, but in severely deficient cases like these it is *a flap of great import*.

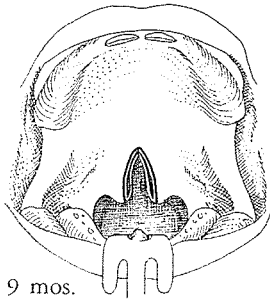
CONSERVATIVE PRIMARY APPROACH

In view of the effect on maxillary growth and development and dental occlusion caused by early denudation of bone, elevation of mucoperiosteal flaps was reduced to a minimum until the age of 4 to 5 years.

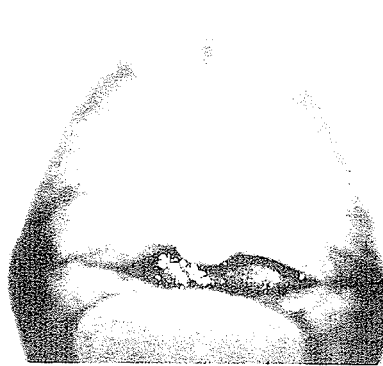
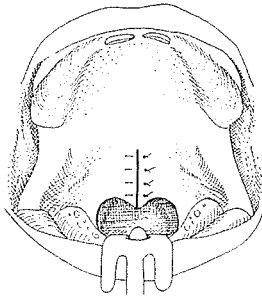
B.D. 10-14-69
 F.H. No clefts
 F.T. Uneventful
 O.C.A. None



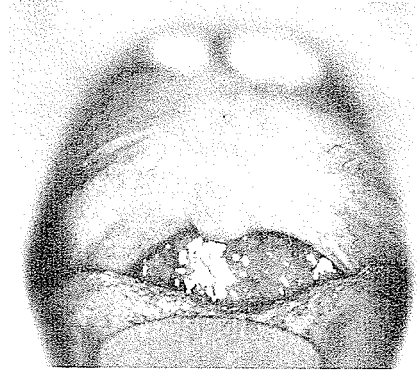
CASE 32 was born with a cleft of the soft palate, which was also short. At 9 months of age simple splitting of the cleft edges allowed closure of the velum in three layers. When seen in cleft palate clinic at age 7 years, the patient revealed a short, mobile palate. The speech pathologist noted excellent mobility, normal resonance balance and articulation, absence of hypernasality and mild hoarseness. Speech therapy was advised. Nine months later the patient had a T & A. At cleft palate clinic 10 months postoperatively her speech was borderline normal, indicating that she will probably succeed with speech therapy.



9 mos.

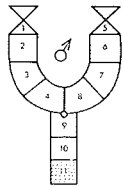


At rest

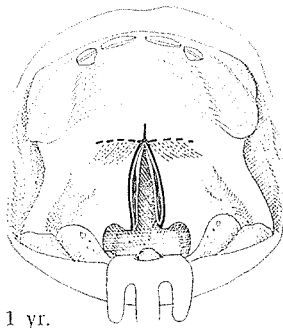


"Aaahh"

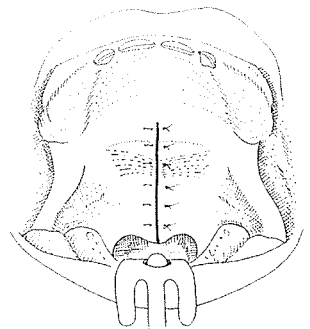
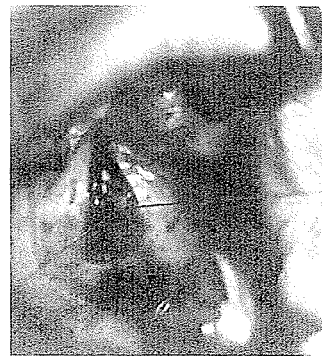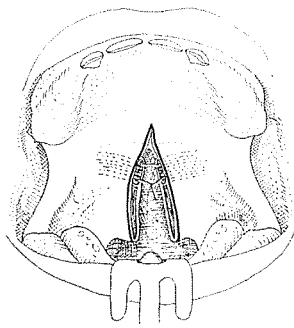
B.D. 3-16-77
 F.H. No clefts
 F.T. Uneventful
 O.C.A. None



CASE 33 was born with a soft palate cleft which was closed at 1 year of age by a procedure simply splitting the cleft edges and closing in three layers. This included freeing the levator attachments from the edges of the hard palate and, after dissecting them into discrete bundles, suturing them into a repositioned (1 cm.) intact loop.

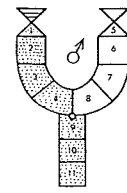


1 yr.

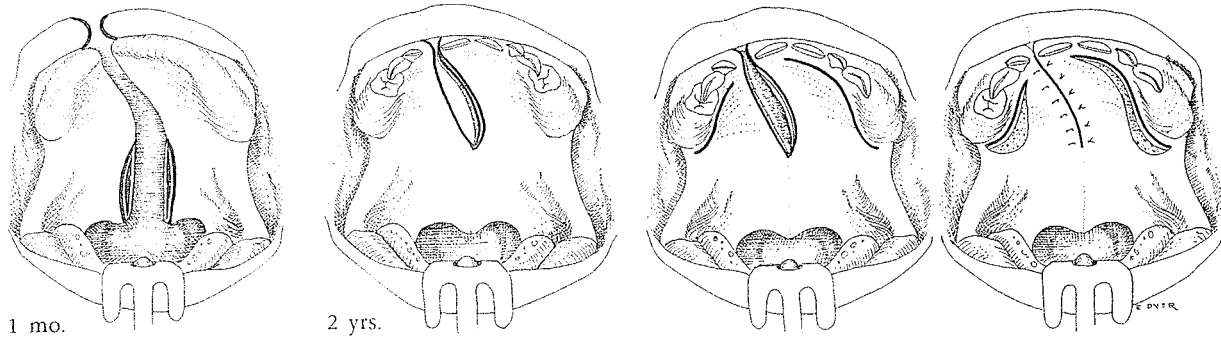


Bottom line: This approach handles the muscles in a more sophisticated manner than was used in the previous case and should give minimal distortion with a good chance of normal speech.

CASE 34 was a complete unilateral cleft of the lip, alveolus and palate treated at 1 month of age with P.E. tubes, soft palate closure and a lip adhesion. Six months later rotation-advancement of the lip was completed. At age 2 years a vomer flap and von Langenbeck incisions allowed closure of the hard palate. Evaluation at 4 years revealed that speech was progressing well.

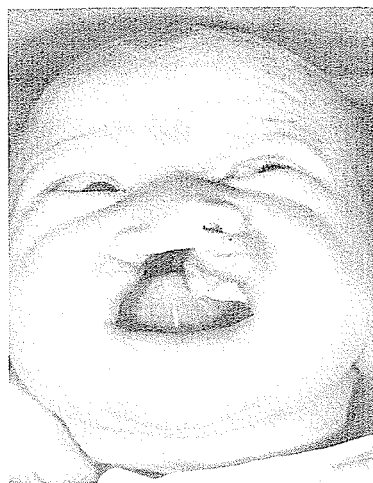


B.D. 12-29-73
 F.H. No clefts
 F.T. Uneventful
 O.C.A. None

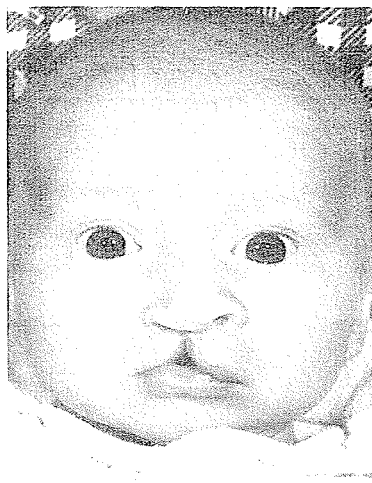

1 mo.

2 yrs.



6 days

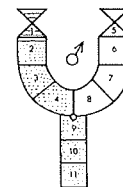


3 months

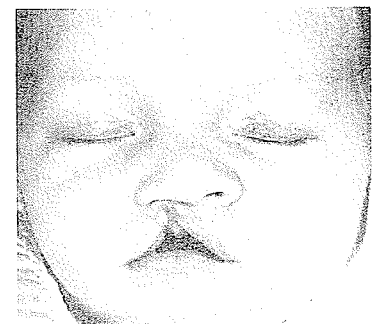

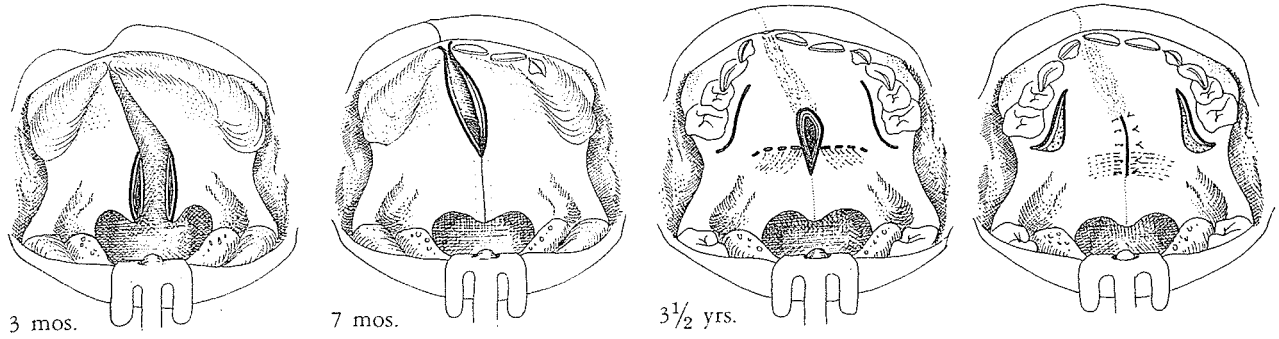
4 years

CASE 35 was born with an incomplete unilateral cleft of the lip, an abutting cleft of the alveolus and a cleft of the hard and soft palate. At age 3 months P.E. tubes were inserted, the soft palate edges were split and approximated and the lip was closed by rotation-advancement. At 7 months a vomer flap closed the anterior hard palate. At 3½ years von Langenbeck incisions and freeing of mucoperiosteal flaps allowed division of the levator muscle attachments to the hard palate edge so the muscles could be dissected free, retroposed about a centimeter and sutured into an intact muscle loop. The cleft in the soft and hard palate was then closed in three layers.

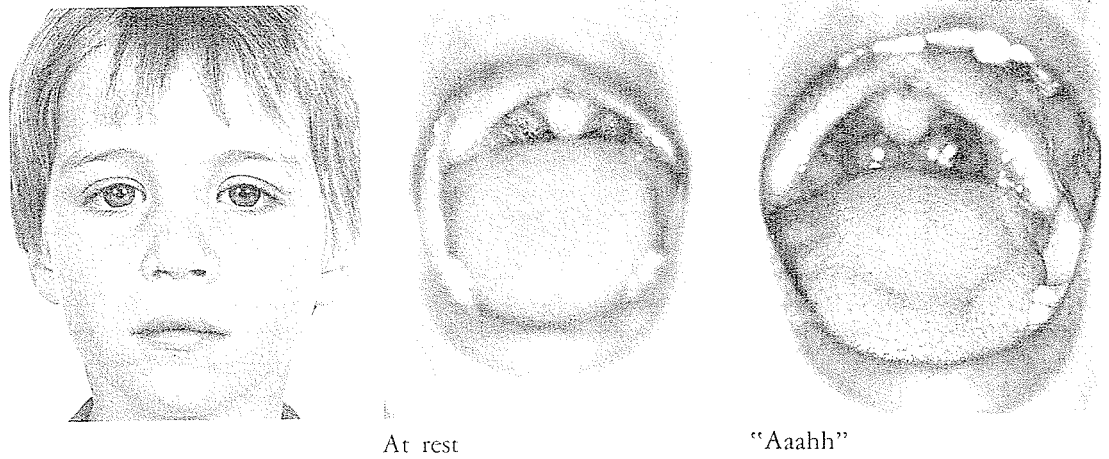


B.D. 1-22-73
 F.H. Lip microform
 in father; mother's
 cousin, cleft of palate
 F.T. Sore throat
 O.C.A. None





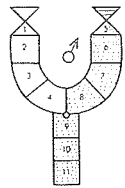
The patient returned from Alaska for a checkup in 1978 at age 5 years to reveal good appearance, good speech and good occlusion.



At rest

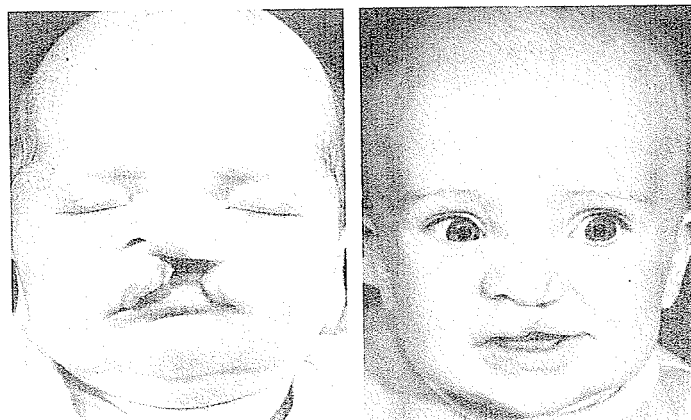"Aaahh"

B.D. 10-9-74
 F.H. No clefts
 F.T. Bleeding
 O.C.A. None

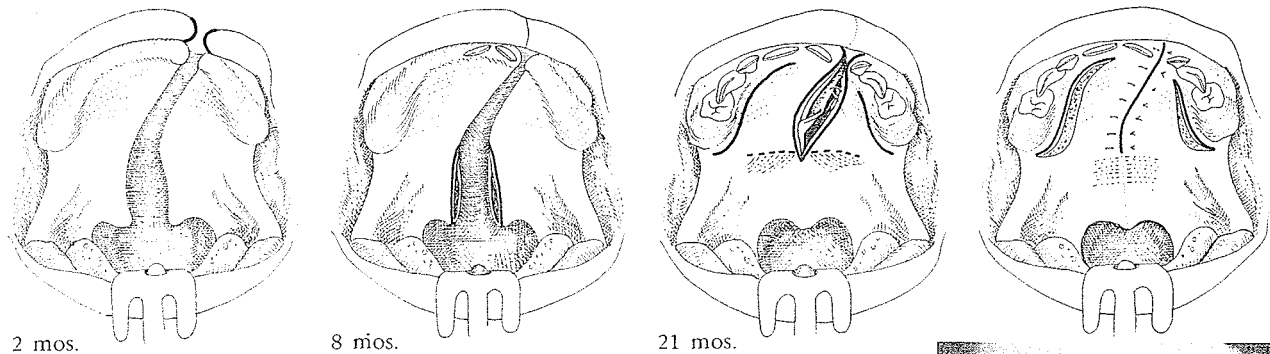


CASE 36 was born with a severe complete cleft of the lip and palate, a deficient lateral lip element and extreme nasal distortion.

On 12-11-74, at 2 months of age, a lip adhesion was accomplished using an I flap to release the lateral alar base and the short vestibular lining. P.E. tubes were inserted after myringotomy, but the soft palate cleft was too wide for closure. The adhesion was effective for six months, until 6-4-75, when rotation-advancement of the lip was achieved along with soft palate closure.



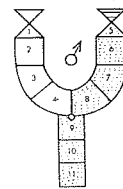
On 7-14-76, at about 21 months, a vomer flap was turned for hard palate nasal lining. Von Langenbeck mucoperiosteal flaps were dissected and the aponeurosis and levator muscle attachments divided from the hard palate edge, allowing the soft palate a slight posterior lengthening when the muscles were sutured.



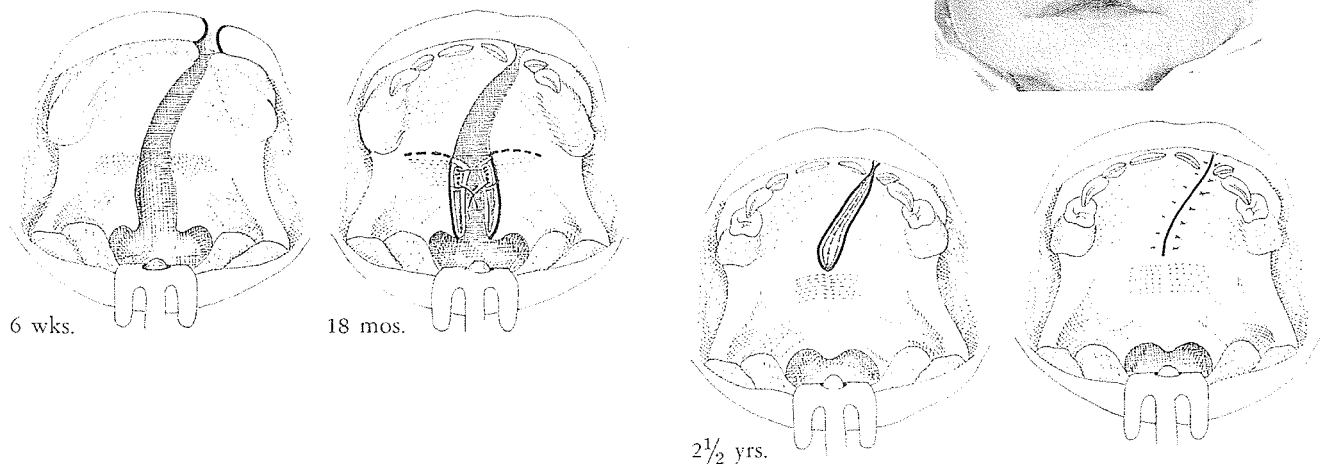
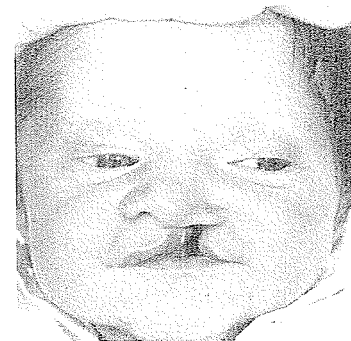When the patient was seen in 1978 at the age of 4 years both lip and palate seemed to be functioning well. It was noted that the child would return from Colorado at age 5 years, at which time minor nasal correction would be important for school. If speech is not found adequate at this time because of palatal shortness, an island flap pushback will be considered.

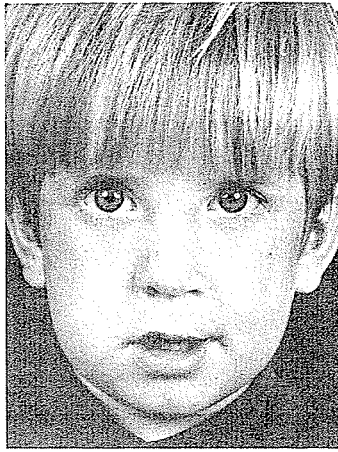


CASE 37 was born with a complete unilateral cleft of the lip and palate. At 6 weeks myringotomy with insertion of P.E. tubes and a lip adhesion procedure were done, but the cleft in the palate was too wide for closure. Rotation-advancement closure of the lip was performed at 9 months and followed with soft palate closure at 18 months. The cleft edges were split and the levator muscles dissected, divided from the anterior attachments to the posterior edge of the bone and sutured into an intact loop, achieving a 1 cm. retropositioning. At 2½ years the cleft in the hard palate had narrowed enough so that nasal mucosa and oral mucoperiosteum could be dissected and closed in two layers without elevation of large flaps.

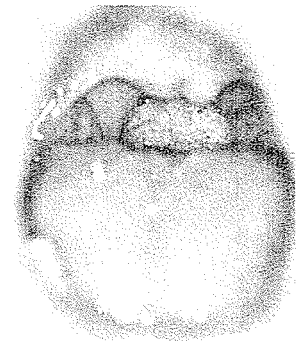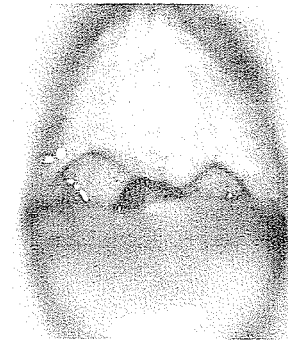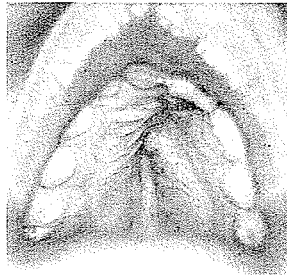


B.D. 7-27-73
 F.H. No clefts
 E.T. Uneventful
 O.C.A. None





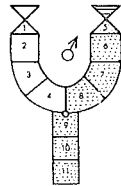
At age 5 years the child needed orthodontia to spread the maxillary arch. Speech was good despite a cephalometric study showing a slight velopharyngeal gap. He may need an island flap later.



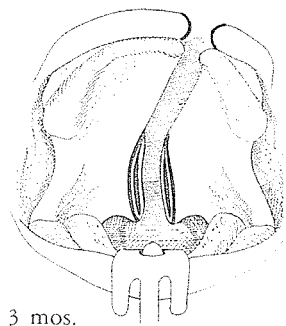
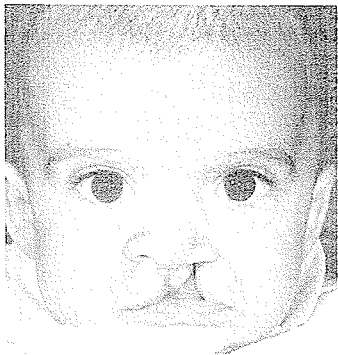At rest

"Aaahh"

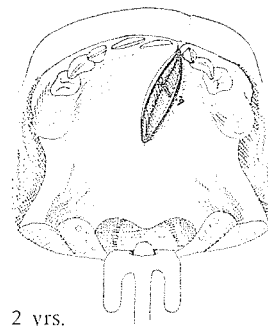
B.D. 2-19-74
 F.H. No clefts
 F.T. Uneventful
 O.C.A. None




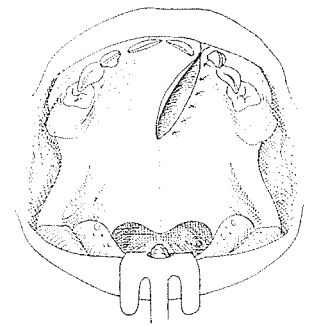
CASE 38 was an Ecuadorian patient born with a complete cleft of the lip and palate. At 3 months P.E. tubes were inserted, the soft palate was closed and a lip adhesion was done. At 6 months the definitive lip closure was achieved by means of the rotation-advancement method. At 2 years of age the hard palate was closed with a vomer flap turned over and tucked under the opposite mucoperiosteal edge of the cleft.



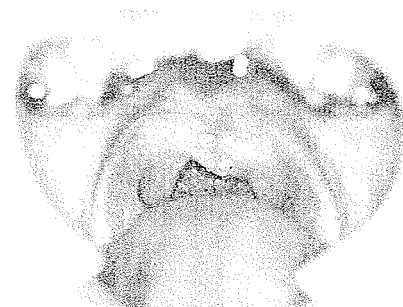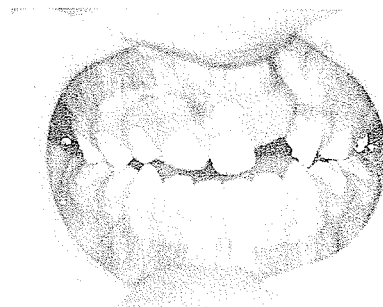
3 mos.



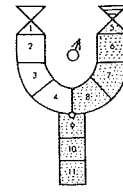
2 yrs.



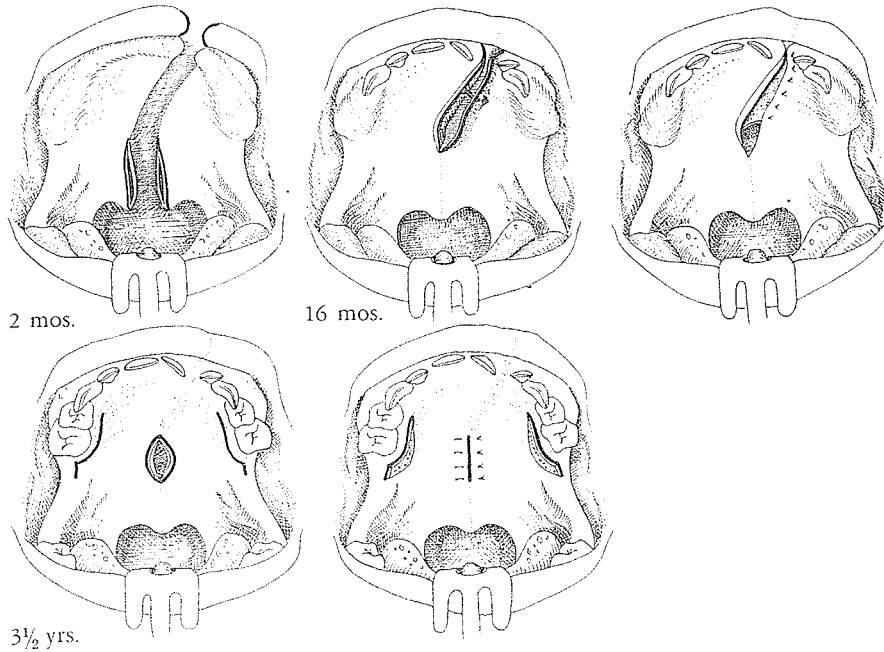
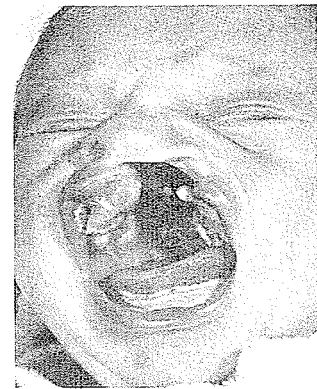Cleft palate clinic evaluation in 1978 at the age of 4 years found excellent velar and lateral wall motion, good resonance balance and an anterior lisp with every indication of normal speech to come.



CASE 39 was born with a complete unilateral cleft of the lip and palate. At 2 months P.E. tubes were inserted, the posterior soft palate was closed and the lip was approximated with an adhesion. At 6½ months definitive lip closure was achieved with the rotation-advancement method. At 16 months the hard palate was closed with a vomer flap and the remaining soft palate approximated, leaving a fistula at the junction. At 3½ years modified von Langenbeck incisions around the maxillary tuberosities allowed dissection of mucoperiosteal flaps and closure of the remaining opening.



B.D. 12-18-72
 F.H. No clefts
 F.T. Pneumonia
 O.C.A. None

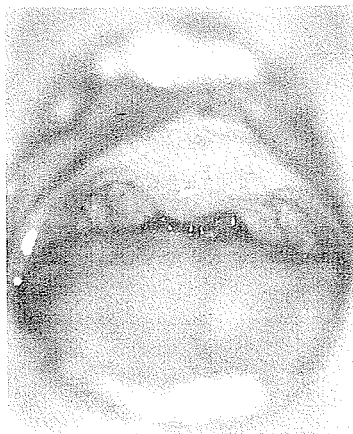


2 mos.

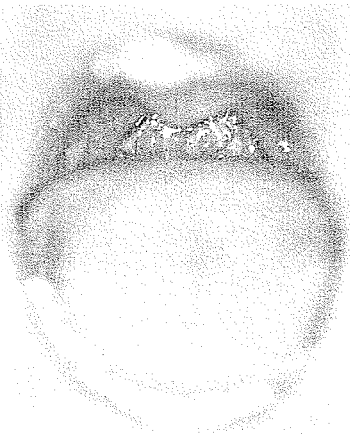16 mos.

3½ yrs.

Evaluation in 1977 cleft palate clinic at age 4½ years revealed a short palate functioning well, with closure against the adenoid pad and good progress in speech therapy. The patient's occlusion was excellent except for a "slight crossbite of upper left deciduous cuspid" with no need for orthodontia. In 1978, again in cleft palate clinic, no changes were noted in dental condition and speech was reported normal.

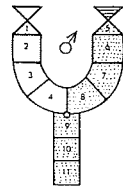


At rest

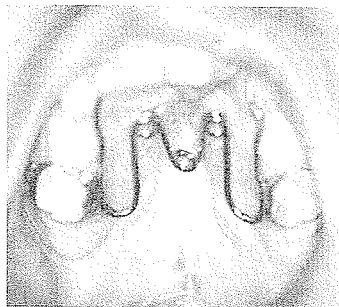
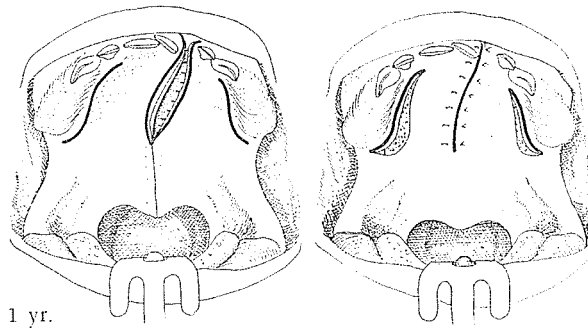
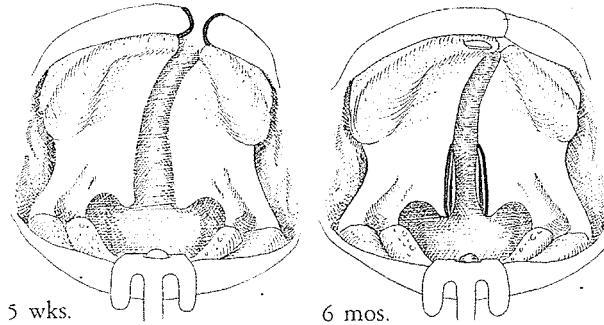
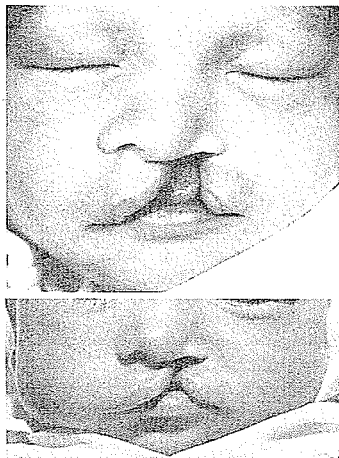


"Aaahh"

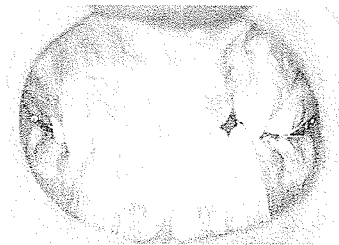
Vol. I P. 513
 B.D. 8-22-71
 F.H. No clefts
 F.T. Uneventful
 O.C.A. None



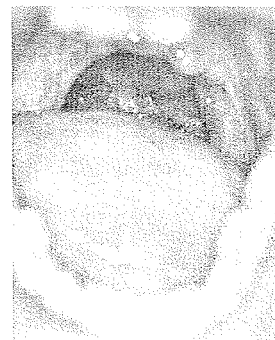CASE 40 was born with a left complete unilateral cleft of the lip and palate. At 5 weeks a lip adhesion was performed, mobilizing only the medial element. At age 6 months the soft palate edges were split and sutured, and the lip was closed with rotation-advancement. At age 1 year a vomer flap was turned over for nasal closure of the hard palate cleft. Von Langenbeck incisions allowed total oral closure of mucoperiosteal flaps.



At age 5 years, cleft palate clinic evaluation revealed excellent maxillary development with upper left deciduous cuspids in crossbite but posing no problem. When the patient was last seen in 1978 at age 7 years, a maxillary expander was in position with good arch form. The palate was short but moving well, with intermittent nasal escape. The patient is able to close the sphincter now, but when the adenoids shrink at about 11 years he may need a pushback with an island flap.



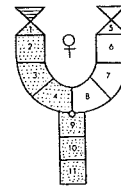
At rest



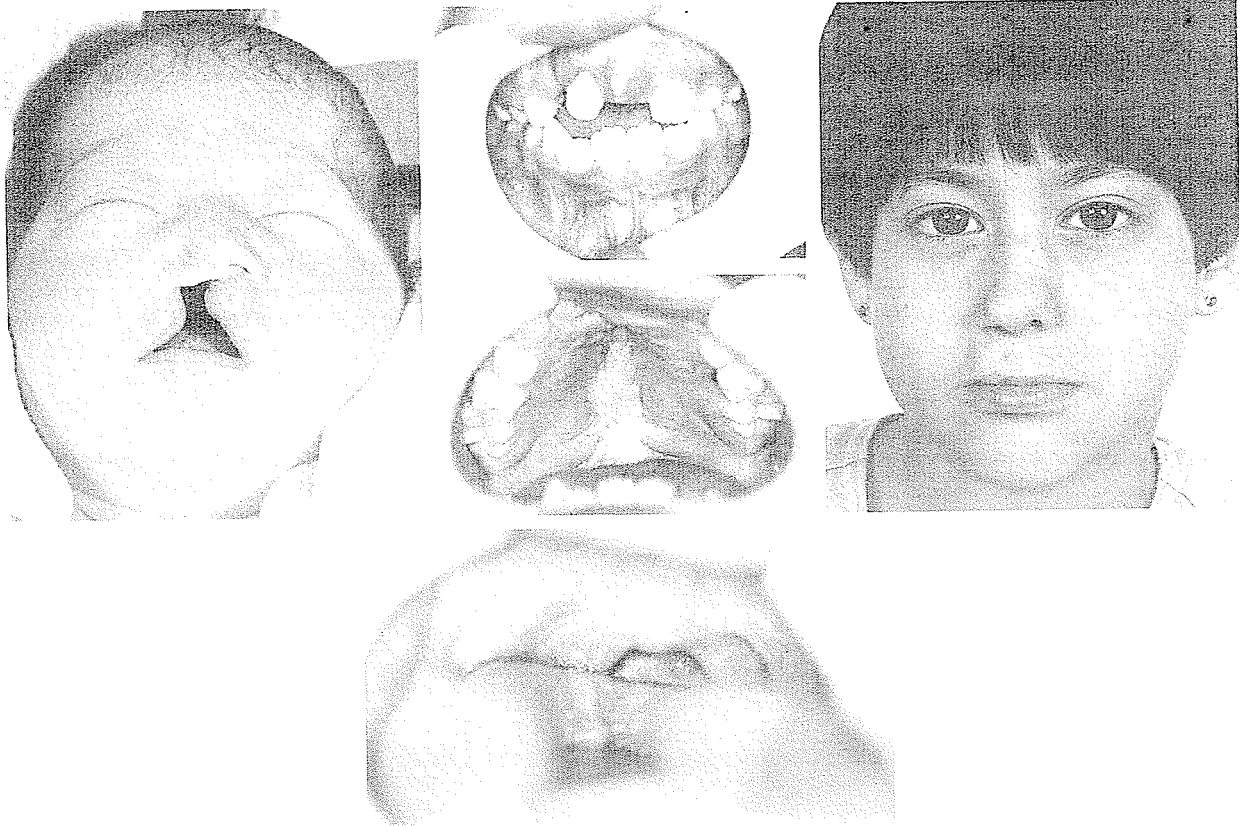"Aaahh"



CASE 41 was born with a severe unilateral complete cleft of the lip and palate. At 2 weeks of age a lip adhesion molded the maxilla and at 4½ months the lip was closed by the rotation-advancement method. At 1 year of age the soft palate was closed in three layers. At 17 months the hard palate cleft was closed with a turnover vomer flap tucked under the opposite cleft edge. On 2-23-77 basal and lateral view videofluoroscopic evaluations were made during isolated speech sounds and connected speech. Both lateral and basal views indicated very good velopharyngeal motion and somewhat dis-coordinated velopharyngeal closure. Intensive speech therapy for a period of one year was advised. In 1978, at age 6½ years, clinic evaluation repeated this recommendation. The orthodontist reported excellent buccal occlusion but found the anterior teeth developing in anterior crossbite or tip-to-tip relationship, meriting close observation and eventual orthodontia.

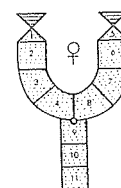


Vol. I P. 516
 B.D. 8-20-71
 F.H. No clefts
 F.T. Uneventful
 O.C.A. None

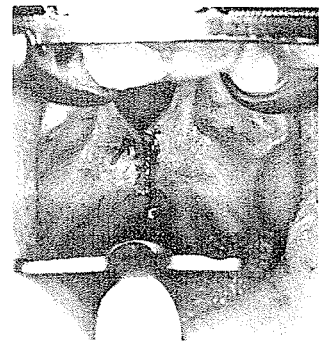

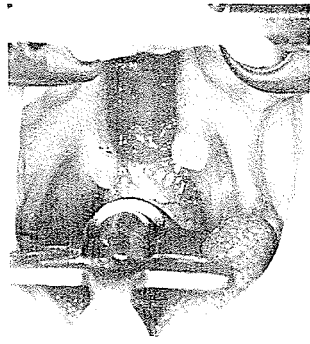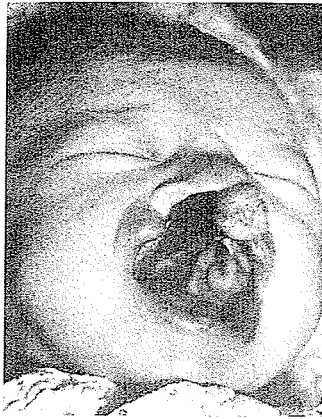


Bottom line: This regimen of early lip adhesion, soft palate closure at 1 year and hard palate closure at 17 months with no mucoperiosteal flap elevation and no palate lengthening has resulted in minimal, easily correctable orthodontic problems and borderline speech, often with enough velopharyngeal contact to make normal speech possible with the aid of intensive speech therapy.

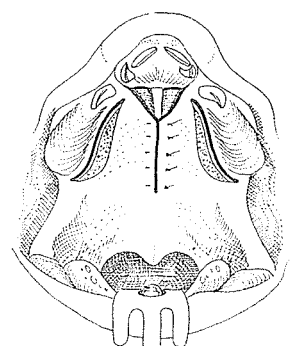
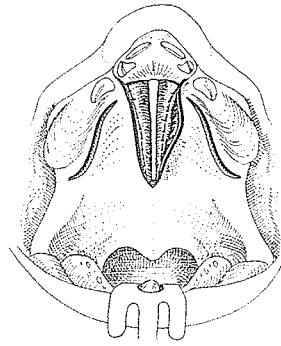
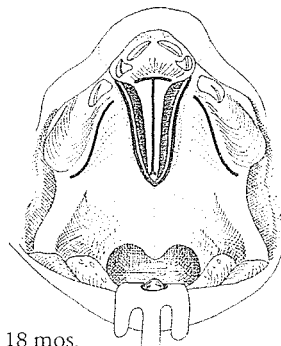
CASE 42 was born with a severe complete bilateral cleft of the lip and palate and a projecting premaxilla. At 7 months of age the soft palate was



Vol. II P. 379
 B.D. 1-31-72
 F.H. No clefts
 F.T. Uneventful
 O.C.A. None



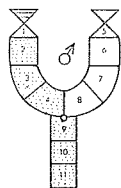
closed by splitting the cleft edges and suturing in three layers. At the same time the bilateral cleft lip was closed with union of the muscles across the cleft and banking of the forked flap. At 18 months of age bilateral vomer flaps were turned over for nasal closure and bilateral von Langenbeck incisions facilitated the dissection of bipedicle mucoperiosteal flaps, which made closure on the oral side possible.



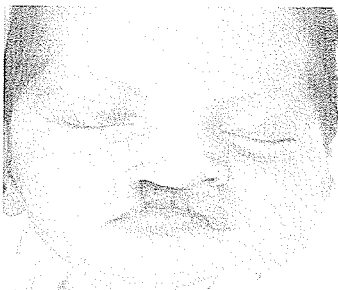
18 mos.

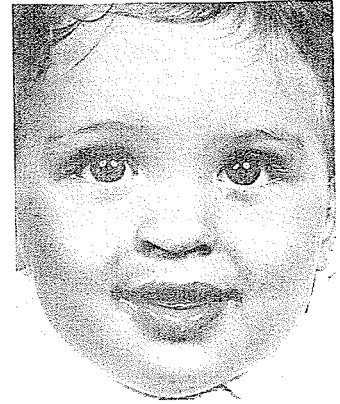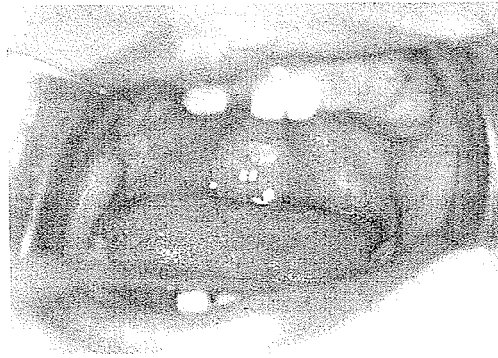
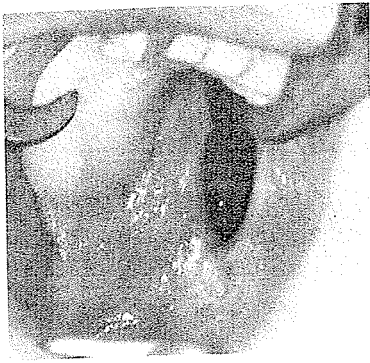
At 5½ years the banked forked flaps were used to lengthen the columella and free the nasal tip. The father reports from Europe that at age 6 years the child is doing well in school and that "her speech is perfect." She is now starting orthodontic treatment.

B.D. 6-16-77
 F.H. No clefts
 F.T. Flu, at 3 months
 O.C.A. None



CASE 43 was born with a complete unilateral cleft of the lip and palate. At 7 weeks a lip adhesion was achieved, but the palate proved too deficient for closure. At 8 months the edges of the soft palate cleft were split and sutured and the lip was closed by the rotation-advancement method. The maxillary arch, molded by the lip adhesion and definitive closure, facilitated hard palate closure employing a vomer flap and unilateral von Langenbeck incision at 16 months. Excellent arch form is present at 18 months.






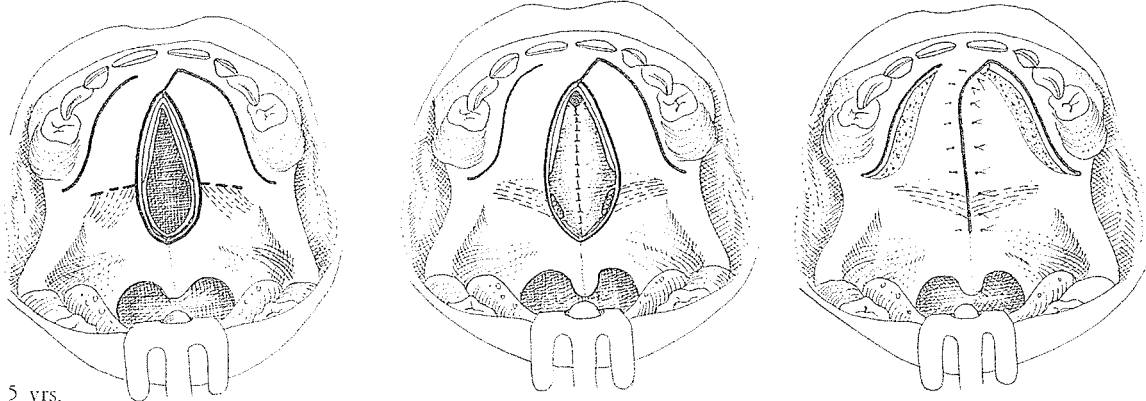
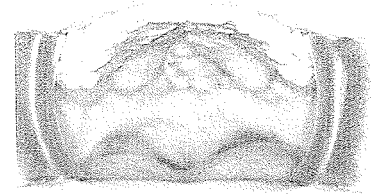
Bottom line: This conservative approach achieves early coordination of soft palate and velum, as well as hard palate closure before 18 months without wide mucoperiosteal dissections.

In the following case there was such a wide cleft that a conservative velar adhesion had been used primarily and the residual gap threatened to require the aid of a pharyngeal flap.

CASE 44, first operated on in central Florida, had had a wide cleft of the soft and hard palate partially closed with a velar adhesion at age 2 years. At age 5 years the residual defect was still huge. Freeing of the nasal mucosa from the bony edge of the cleft allowed closure of this layer except for a 0.5 cm. hole at the anterior end. The levator muscles were dissected from the



posterior bony edge, repositioned and sutured into an intact muscle loop. Then a variation was used to achieve oral closure without tension, especially at the anterior end. A von Langenbeck incision on the right and a V-Y type of flap on the left facilitated shifting of a mucoperiosteal flap over the anterior hole with sound closure, bypassing the need for a pharyngeal flap.



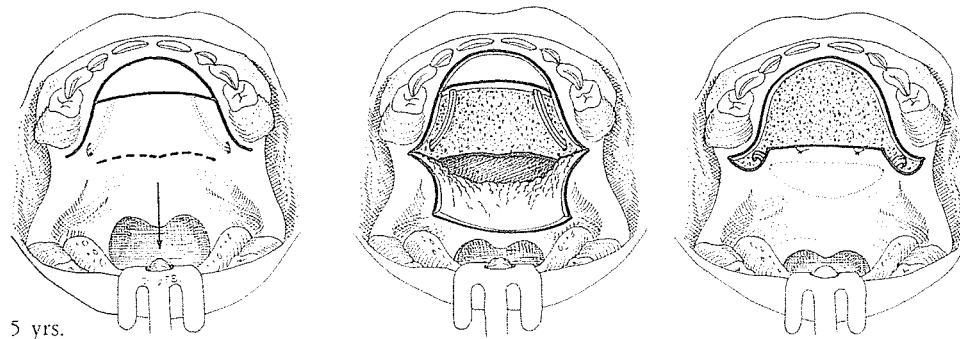
5 yrs.

SECONDARY SURGERY

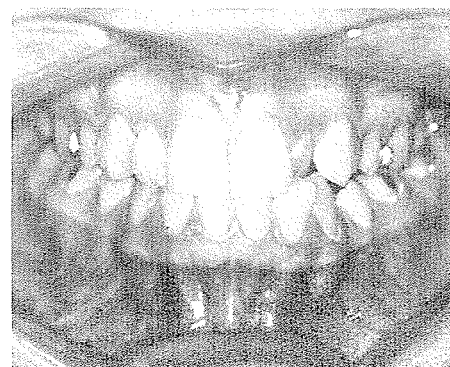
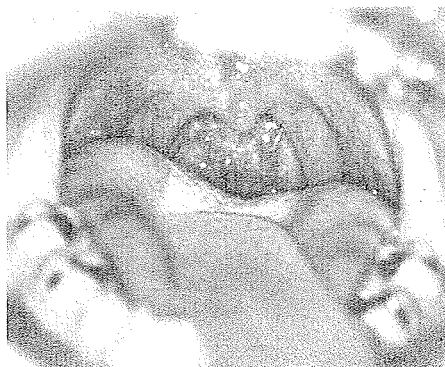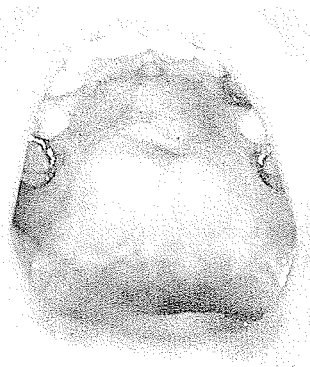SECONDARY ISLAND FLAP PUSHBACK

It was estimated in the conservative approach that the arch collapse and malocclusion would be greatly reduced and easily amended with orthodontia, but that only 70 percent of patients would get normal speech. Thirty percent (or more) would require an island flap pushback at 5 years or older. This regimen thus seemed acceptable.

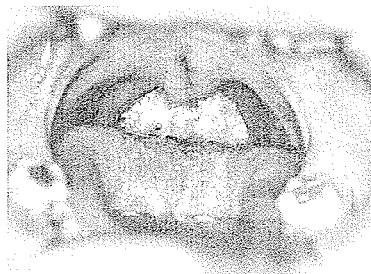
CASE 45 was born with a cleft palate, closed in Boston at 14 months of age. At age 5 years the patient revealed nasal escape during speech.



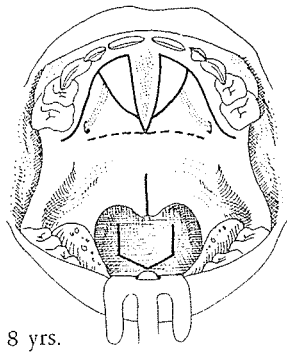
On 8-14-62, at 5 years, an anterior bipedicle island flap was used in a pushback of the palate for a 1.5 cm. lengthening. The palate was well healed two months postoperatively. Final evaluation in 1976 at 19 years revealed an active, mobile palate producing normal speech and good occlusion.



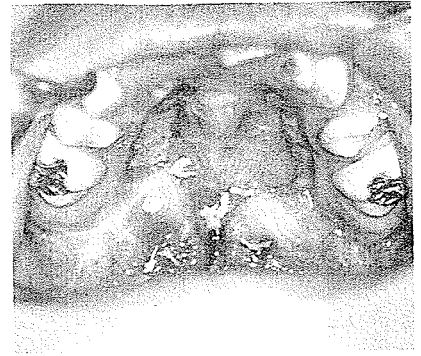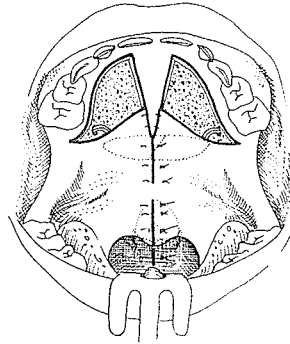
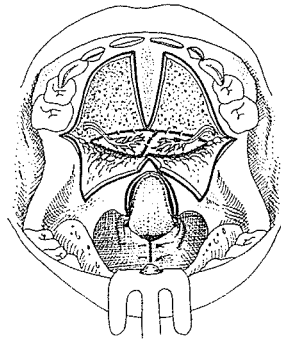
Two months postoperatively 1976



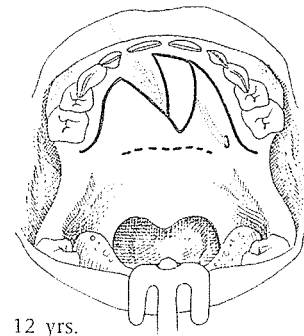
CASE 46 was an Ecuadorian girl with a failed cleft palate closure, who revealed nasal escape when seen at age 8 years. An island flap was taken from the anterior portion of each side of the mucoperiosteum, sutured to the other and inserted into the nasal lining defect after a pushback of 1.7 cm. A 1.25 cm. wide superiorly based pharyngeal flap was let into the bifid uvula. A suction test was positive.



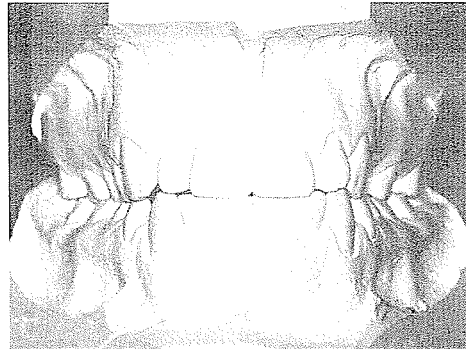
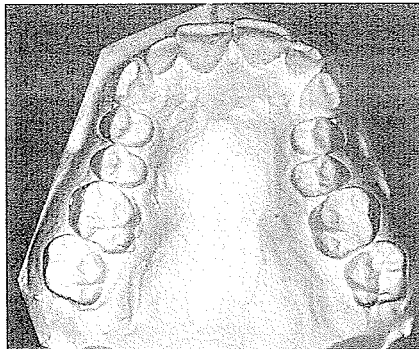
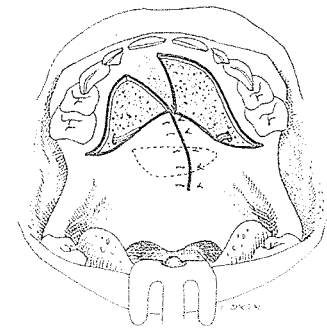
8 yrs.



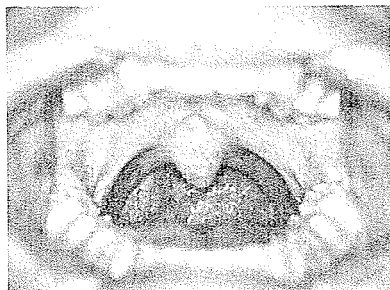
CASE 47 was born with a complete unilateral cleft of the lip and palate, treated in infancy in Tennessee. The palate was short, allowing nasal escape in speech. In 1968, at age 12 years, a secondary V-Y pushback was performed using 2 cm. wide left island flap to fill the nasal lining defect after release of the soft palate from the hard palate edge. Within two months after the pushback surgery the patient was speaking normally. In 1977, at age 21 years, the transverse palatal scar had caused some palatal migration of the bicuspid. Cephaloradiographs by Berkowitz soon after the island flap pushback surgery and nine years later show good elevation and contact with the posterior pharyngeal wall, consistent with the action that can be seen directly during speech.



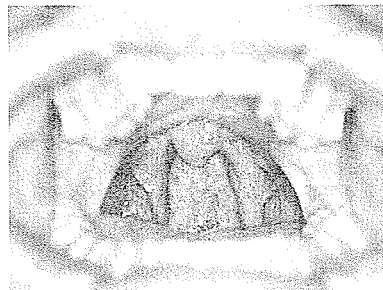
12 yrs.



1977



At rest



"Aaahh"

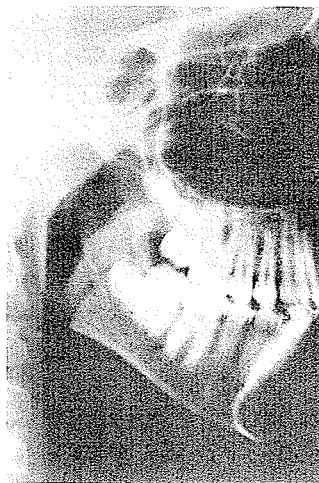

At rest



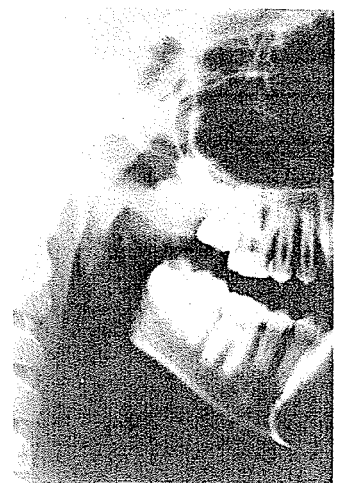1968

"Aaahh"



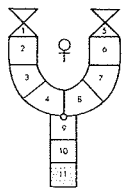
At rest

1977



"Aaahh"

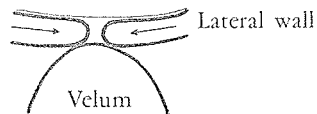
B.D. 12-17-71
 F.H. No clefts
 F.T. Uneventful
 O.C.A. None



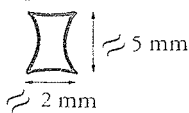
CASE 48 was born with a cleft of the soft palate which was closed at 4 months of age following splitting of the cleft edges and suturing in three layers. Cleft palate clinic evaluation in 1977 found good velopharyngeal activity with speech attempts characterized by mild to moderate hypernasality. In April 1978, nasopharyngoscopy by Pullen and the Dicksons found



Superior view



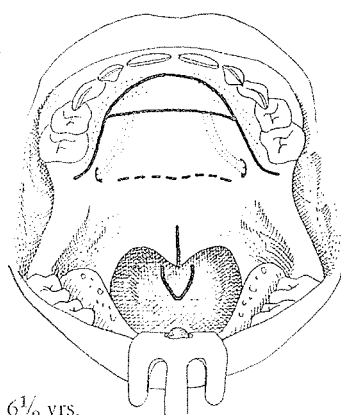
Aperture



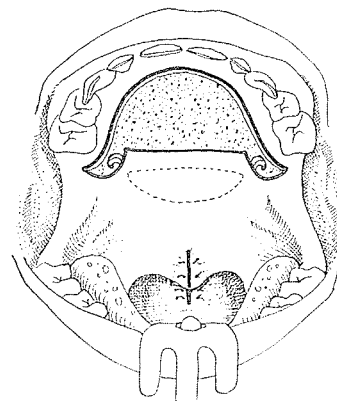
good velar and lateral wall motion with a rectangular velopharyngeal gap approximately 5 mm. in anteroposterior direction and 2 mm. in lateral direction. The lateral walls were observed to nearly meet with effort on the production of /slks/. Total closure was not achieved during any speech samples elicited.

Assesment: Velopharyngeal activity is inadequate for balanced resonance, presenting a persistent 5 × 2 mm. aperture during the production of fricative-vowel-consonant-fricative speech samples which prognosticates poorly for sustained and adequate closure during connected speech.

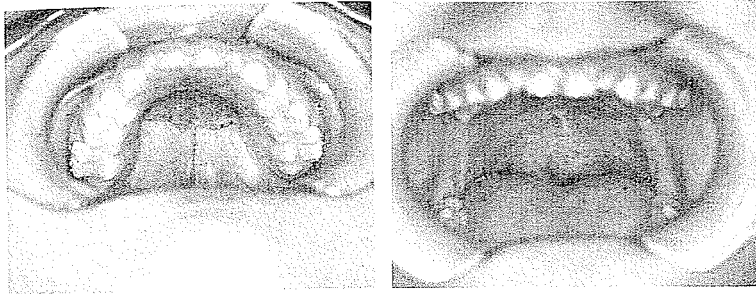On 5-19-78, at age 6½ years, a palatal pushback was done with an anterior 1.5 cm. bipedicle island flap inserted into the nasal lining defect. A small (Stellmach) superiorly based pharyngeal flap was inserted into the nasal side of the uvula for an adhesion. Postoperative suction test was positive.



6½ yrs.

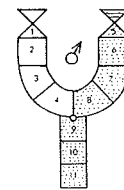


Bottom line: Early simple closure was not quite enough, so a pushback with an island enabled the velum to function in closure. A small pharyngeal flap adhesion offered a "hand-up" to the velum, reducing the *lift excursion* for better efficiency at little cost.

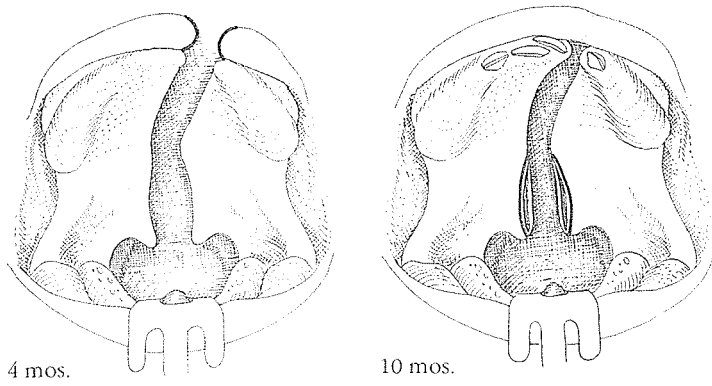


6-2-78

CASE 49 was born with a left complete cleft of the lip and palate treated at 1 month with a lip adhesion. At age 4 months rotation-advancement closed the lip, using 1 flap for nasal closure over turnback mucoperiosteal flaps from the alveolar cleft edges for nasal floor reconstruction. At 10 months the edges of the soft palate were split and sutured, and at 2 years a vomer flap closed the hard palate defect.

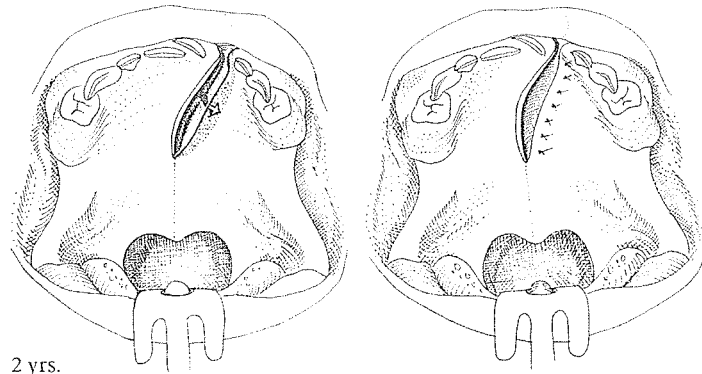


Vol. I P. 515
 B.D. 12-30-71
 F.H. Paternal grandfather, CL&P; paternal cousin, CL&P
 F.T. Uneventful
 O.C.A. None

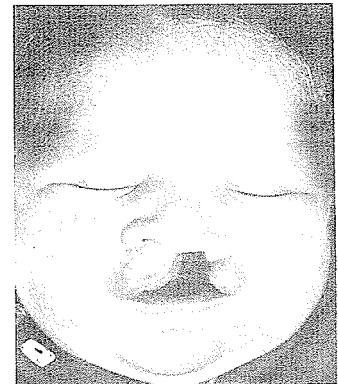


4 mos.


10 mos.



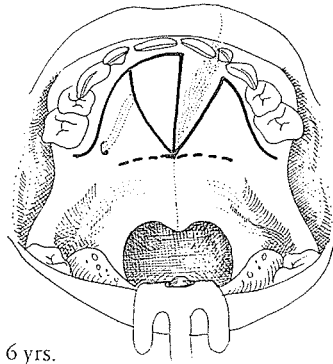
2 yrs.



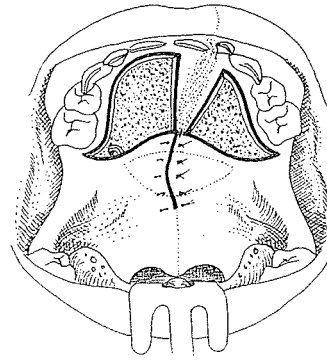
At age 5 years evaluation revealed a short, mobile velum and active lateral walls but hypernasal speech. The upper left cuspid was going into crossbite. In 1977, at age 6 years, a V-Y pushback leaving an anterior V over the previous cleft area and placing a right island flap into the nasal defect achieved a 1.5 cm. lengthening.



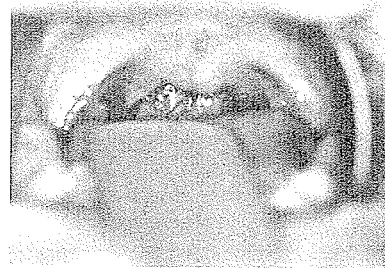
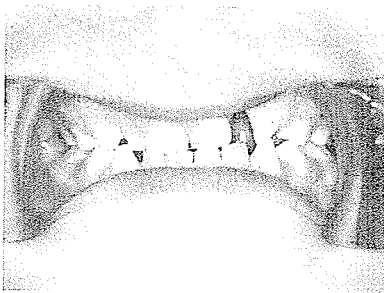
7 years



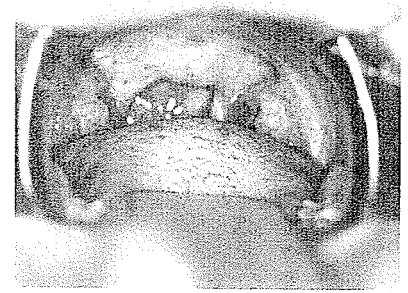
6 yrs.



In 1978 the patient had a slight upper left cuspid crossbite, to be treated by Berkowitz. Both isolated and connected speech were normal.

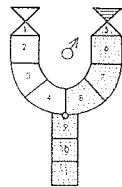


At rest

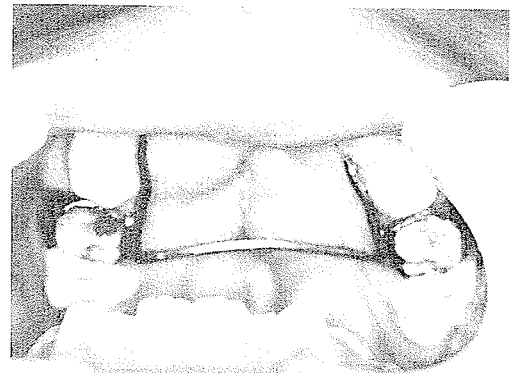
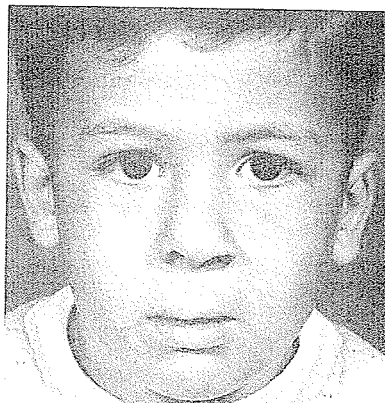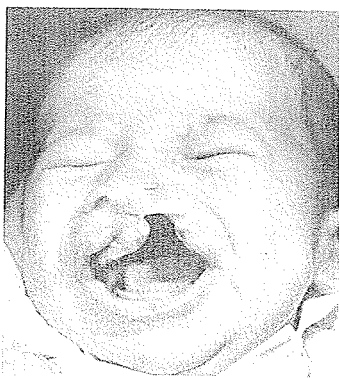


"Aaahh"

Vol. I P. 512
 B.D. 7-13-71
 F.H. No clefts
 E.T. Uneventful
 O.C.A. None

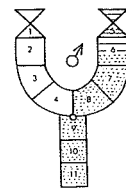


CASE 50 was born with a complete unilateral cleft of the lip and palate. A lip adhesion at age 1 month separated and was resutured five days later. At 6 months rotation-advancement closed the lip. At 16 months the soft palate was closed, and at 2 years a vomer flap was turned for hard palate closure. At age 4 years, because of nasal escape in speech, a V-Y pushback was performed, an island flap being inserted into the nasal lining defect. After one year of speech therapy the patient's speech was good enough to discontinue therapy. Orthodontia was in progress at age 7 years to give moderate maxillary arch expansion.

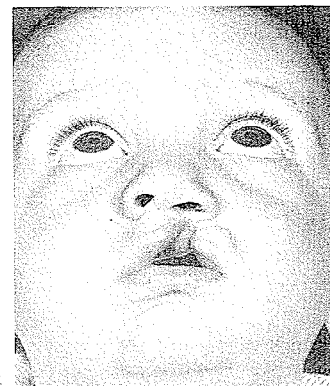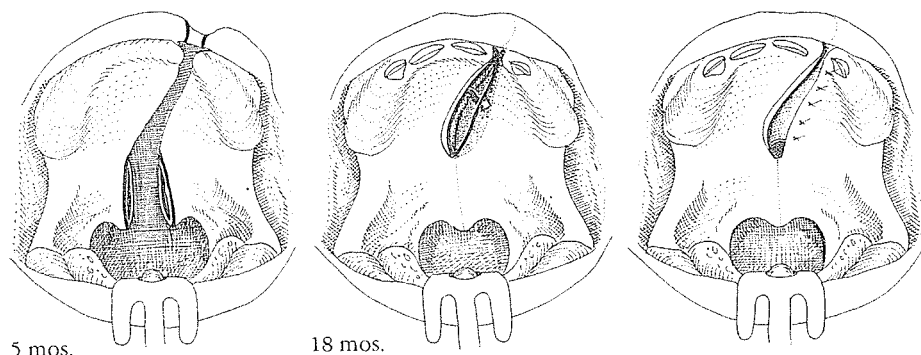


CASE 51 was born with an oblique unilateral incomplete cleft of the lip and complete cleft of the alveolus, hard palate and soft palate. On 5-8-73, at 5 months of age, lip closure by rotation-advancement and soft palate closure by splitting and suturing the edges were accomplished.

On 5-8-74 at nearly 18 months, a vomer flap was turned over and tucked under the opposite mucoperiosteal edge of the cleft to close the hard palate in one layer. A small fistula remained at the junction of the hard and soft palates.



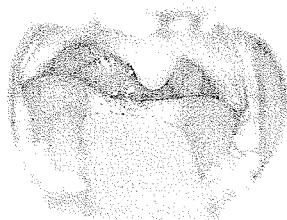
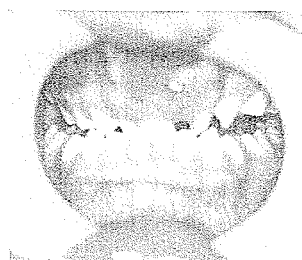
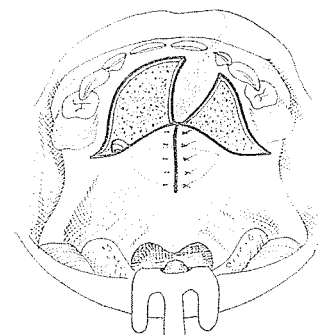
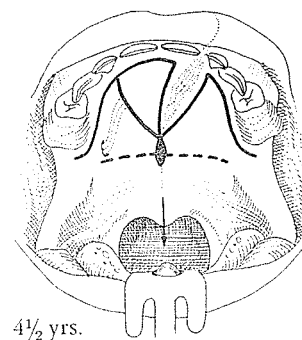
Vol. II P. 800
 B.D. 12-14-72
 F.H. No clefts
 F.T. Uneventful
 O.C.A. None



In 1975 the patient revealed good occlusion except for a crossbite of the left cuspid. Speech was unintelligible. In 1976 cephalometric evaluation by Berkowitz revealed velopharyngeal closure and good motion but a small soft palate and a thin, contracting adenoidal mass. The speech pathologist recorded nasal escape.

On 6-14-77, at about 4½ years, mucoperiosteal flaps were elevated on each side of the cleft and an island flap was developed on the right. The neurovascular bundle was freed on the left and the nasal lining divided, as were the levator muscle attachments from the posterior edge of the hard palate, allowing the soft palate to move posteriorly 1.5 cm. The island flap filled this defect, and the mucoperiosteal flaps were advanced posteriorly in V-Y manner to close the fistula and cover the island flap. The suction test was positive at the end of the operation.

When seen in 1978 the patient had perfectly normal speech without nasal emission, and only the left deciduous cuspid needed to be brought into normal labial position.

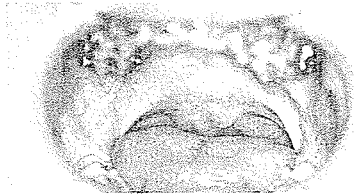

At rest

"Aaahh"

Bottom line: The reduction in scar contracture of the maxilla and the amount of required orthodontia seems to justify a delay in normal speech development in some cases. At 5 years an island flap can lengthen the palate and obtain normal speech with maxillary impunity.

A T E R T I A R Y P P F S T E P



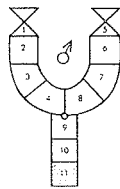
At rest



"Aaahh"

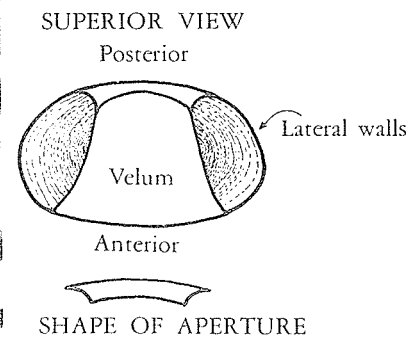
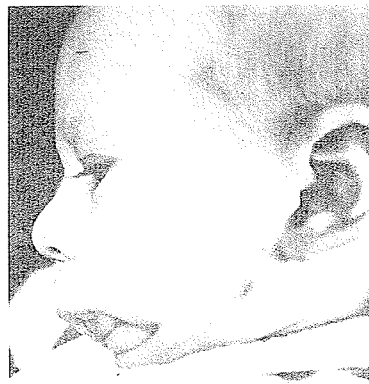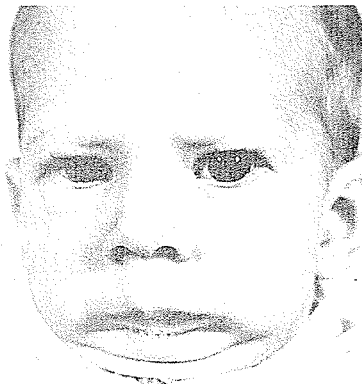CASE 52 was born with a cleft of the palate which was evidently treated at 8 months and again at 18 months by surgery elsewhere. When seen at age 6 years the child had a short palate and marked nasal emission during speech. In 1969, at age 6, a V-Y pushback was performed with a 1.5 cm. right island flap inserted into the nasal lining defect after release from the hard palate. Improvement in speech was noted, but nasal emission continued. At 8 years of age, therefore, a small anterior residual fistula was closed in two layers and a 1.4 cm. wide superiorly based pharyngeal flap inserted on the superior aspect of the soft palate and into a split along the posterior edge of the velum. In 1977 cleft palate clinic at the age of 14 years, the speech pathologist reported, "Speech is normal."

B.D. 5-8-68
 F.H. No clefts
 F.T. Uneventful
 O.C.A. Pierre Robin syndrome



CASE 53 was born with Pierre Robin syndrome, including a cleft of the soft palate. Glossoptosis with respiratory distress was treated effectively with a Kirschner wire through both mandible angles and the tongue. At 14 months of age a V-Y pushback was achieved, inserting a right island flap into the nasal lining defect.

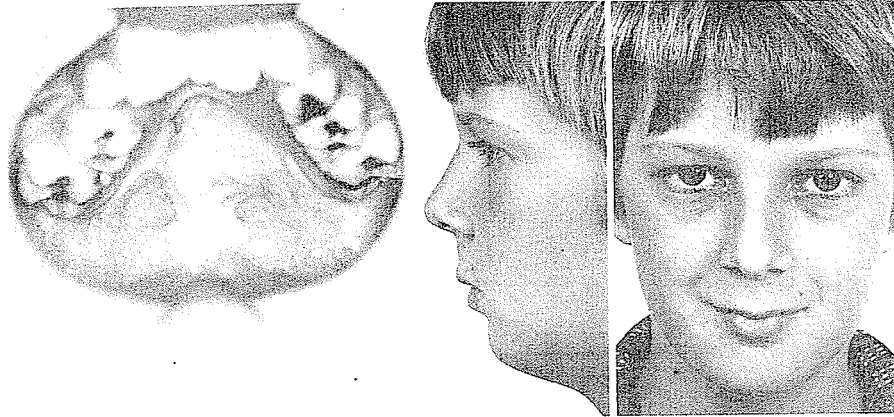
In April 1978, at age 10 years, nasopharyngoscopy by Pullen and the Dicksons revealed lateral wall motion to be minimal and velar motion good, with occasional touch contact. Connected speech samples showed near but not complete closure, with an opening narrow in the anteroposterior direction and broad in lateral dimension, as shown in the diagram, producing hypernasality in both isolated and connected speech samples.



On 6-28-78 a 2 cm. wide superiorly based pharyngeal flap was inserted on the superior surface and into fishmouth incisions of the lateral posterior

edges of the velum. Velar mucosal turnback flaps were used to cover the raw underbelly of the pharyngeal flap. Speech improved postoperatively.

Note the normal development of the mandible and minimal need for orthodontia of the maxillary teeth.



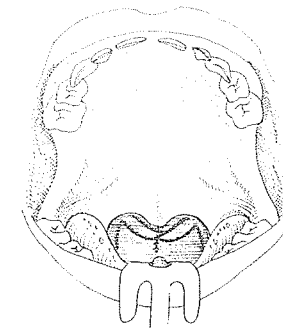
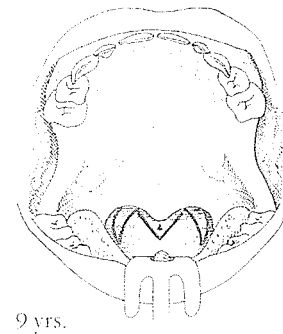
CASE 54 had a submucous cleft palate which developed speech difficulty after a T & A. At 5 years of age a bipedicle island flap pushback achieved a 1.25 cm. lengthening but with negative suction test results. Cephalometric evaluation revealed a 0.75 inch gap in velopharyngeal closure and hypernasal speech.

At age 7 years a 1.5 cm. wide pharyngeal flap based superiorly was attached to the velum with reduction in nasal escape except in connected speech.

At 9 years lateral recess flaps were transposed transversely across the posterior pharyngeal wall (Hynes). At the same time a V-Y upward advancement of the pharyngeal flap base was done (Hirshowitz). The suction test was positive, and near normal speech followed.

In 1979, David and Wilma Dickson gave a possible explanation for the prolonged difficulty of this case:

Our best guess is a supranuclear lesion somewhere within the extrapyramidal system, perhaps in the corticobulbar pathways, perhaps involving the cerebellar system. Our reasons for this are: (1) no observable peripheral pathology; (2) no paresis or other signs of pyramidal tract involvement; (3) normal function when operating "cortically"; and (4) reduced or absent velopharyngeal function during rapid or spontaneous speech and whenever his attention is distracted. In a sense this behavior is exactly the opposite of that found in dyspraxia or apraxia. Other possible explanations include a very subtle lower motor neuron pathology or involvement of the proprioceptive feedback system. The patient is being referred to pediatric neurology for further testing of both motor and sensory integrity.




By the way Some cases need help from both ends, so never give up.

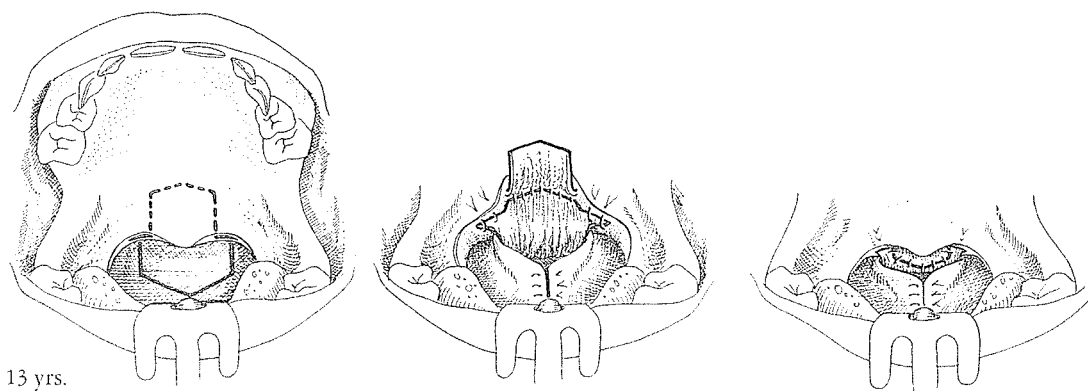
SECONDARY PPF

Some secondary cases with only a pharyngeal flap are presented.

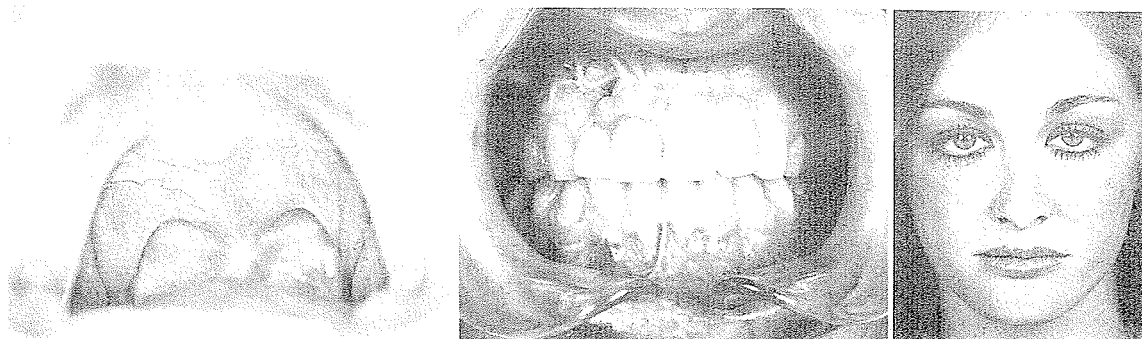
Vol. I P. 723



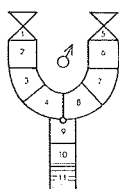
CASE 55 was born with a complete unilateral cleft of the lip and palate, receiving primary surgery in Virginia. Secondary deformities included a constricted nostril, a lip without landmarks, a retropositioned maxilla and a short palate with nasal escape during speech. At age 13 years the mobile but short and scarred palate was benefited by a 1.5 cm. wide superiorly based pharyngeal flap which was let into the nasal side and posterior edges of the velum. The raw underbelly of the flap was covered by a mucosal turnback flap from the upper surface of the velum and uvula. Subsequently iliac bone grafts to the maxilla, orthodontia, a midline Abbe flap and cleft lip rhinoplasty achieved a pleasing result. At age 17 years the patient had good occlusion, good speech and a good appearance.



13 yrs.



B.D. 9-21-68
 F.H. No clefts
 E.T. Uneventful
 O.C.A. None



CASE 56 was a 9-year-old boy who had received speech therapy since kindergarten. He revealed a submucous cleft palate with a bifid uvula, a midline cleft in the muscles and hypernasal voice quality during connected and isolated speech. On 1-4-78 Pullen and the Dicksons, using a Machida nasendoscope, visualized the velopharyngeal aperture, noting good velar and lateral wall motion during speech. Yet closure was incomplete at the midline for all samples of speech tested, particularly for high vowels and fricatives. There was a marked curvilinear depression at the velar midline, precisely where the uvular bulge is expected to produce closure. This was their assessment:

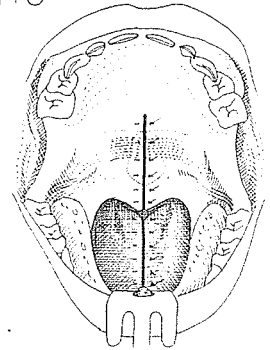
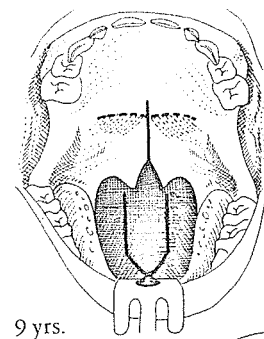
The midline velar depression results in incomplete velopharyngeal closure at midline; air escape is observable through this "hole" during isolated and connected speech samples, but not during swallowing. Since velar and lateral pharyngeal wall motion were clearly adequate except for midline closure, it is recommended that surgery be concentrated on this specific area—a narrow pharyngeal flap should suffice.

On 1-23-78 the edges of the bifid uvula were pared and the soft palate was divided in the midline. Levator muscle fibers were freed from the hard palate edge, dissected into bundles and sutured into an intact loop. A 1.3 cm. wide superiorly based pharyngeal flap was let into the longitudinal muscle defect on the nasal side to bolster the area of weakness. The pharyngeal wall donor area was closed with 3-0 Vicryl mattress sutures.

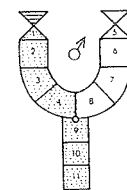
Five months later, evaluation in cleft palate clinic by the Dicksons revealed competent closure with good speech in isolated words, including s, but speech therapy is required to complete the correction in connected speech.

Bottom line: This is the kind of coordination of diagnostic and surgical teams that will eventually solve most palatal problems.

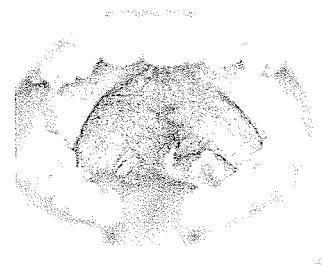
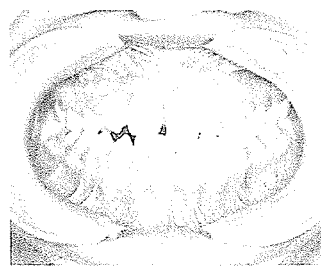
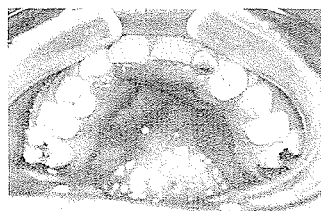
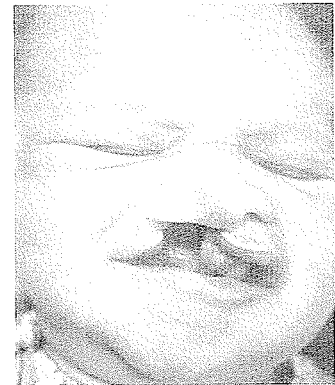
CASE 57 was born with a severe unilateral complete cleft of the lip and palate and mucous pits of the lower lip. At 3 months rotation-advancement closed the lip, and at 8 months alveolar mucoperiosteum was elevated so that split rib grafts could be inserted into and across the cleft. At 10 months the soft palate was closed, reducing the hard palate cleft so that at 2 years it could be closed with a vomer flap. The mucous pits in the lower lip were excised at this time. Speech was reasonable until the patient had a T & A which resulted in nasal escape during conversation. At 7 years a wide superiorly based pharyngeal flap was attached to the upper surface of the velum and along the posterior edge, facilitating normal speech. Orthodontic correction by Silver was being maintained with a retainer at age 15 years. A corrective rhinoplasty at age 16 years completed reconstruction.



Amen!

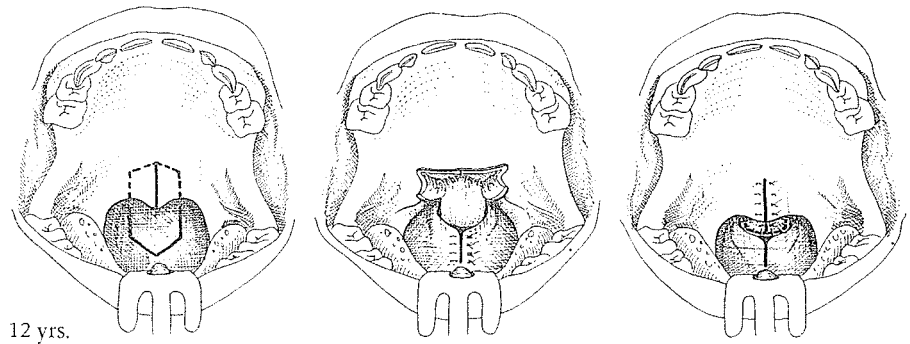


Vol. I P. 497
 B.D. 7-26-63
 F.H. No clefts
 F.T. Uneventful
 O.C.A. Mucous pits



CASE 58 was born with isolated cleft palate, treated elsewhere with a Wardill pushback at age 2 years and another pushback with a pharyngeal flap at 8 years. When first seen in our cleft palate clinic at age 12 years, this girl still had incompetent velopharyngeal closure with nasal escape.

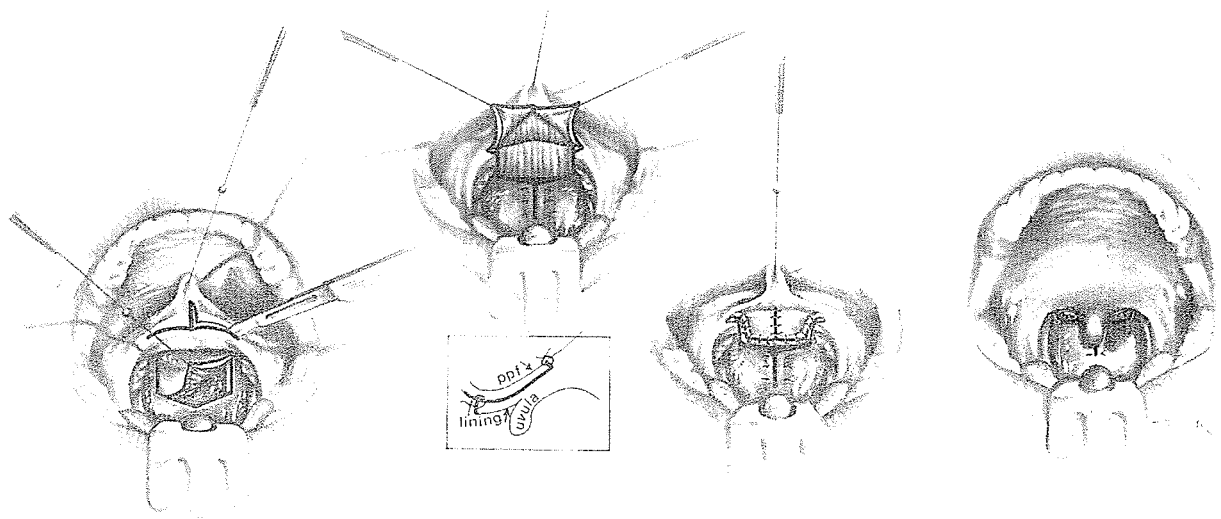
On 4-15-70 there was no evidence of the first pharyngeal flap. A second, 2 × 3 cm. superiorly based pharyngeal flap was attached nasally to a split in the soft palate.



Speech pathologists' 1974 evaluation at age 16 years reported essentially normal speech.

Bottom line: The velar-pharyngeal synechia may not be physiological but it often works.

Here is a modification in technique for attaching a wide superiorly based pharyngeal flap to the superior surface of the velum and laterally along the posterior pillars. It does not require splitting the entire velum, and there is a cosmetic advantage as the pharyngeal flap is hidden by the intact uvula.



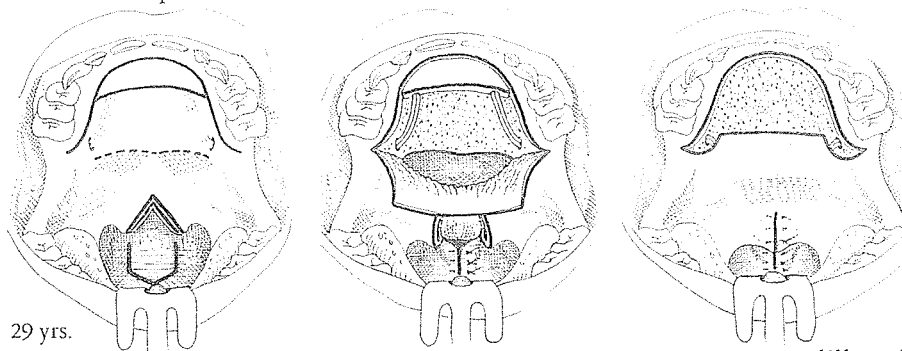
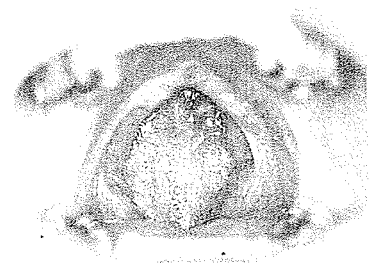
BOTH ISLAND AND PHARYNGEAL FLAP

Finally, when the tissues are deficient or the velopharyngeal gap is large, the island flap pushback and a complementary posterior

pharyngeal flap can be used simultaneously to lengthen the palate (belt) and reduce the velopharyngeal gap (suspenders). An additional advantage of the pharyngeal flap synechia is its "hitching post" function, which keeps the velum up and close to the posterior pharyngeal wall at all times and thus reduces the length of excursion and the amount of velar lift required by the levator muscle for more efficient sphincter control.

CASE 59 had an incomplete cleft of the soft palate treated in infancy. After adenoidectomy at age 5 years, the patient began to have difficulty with speech and was treated with a pharyngeal flap. The attachment, however, became disrupted and left a large central defect in the velum which was responsible for nasal emission. Contraction of the levator muscles presented limited lift of the velum because of their attachments to the hard palate edge.

At age 29 years the mucoperiosteum was elevated from the hard palate through a horseshoe-shaped incision. Both neurovascular bundles were dissected free to create an anterior bipedicle island flap 2 cm. wide. The soft palate was divided from the edge of the hard palate with a pushback of 2.1 cm., and the island was sutured into this defect. The levator muscles were dissected into bundles and sutured to each other to form an intact loop. A 1.4 cm. superiorly based pharyngeal flap was inserted into the nasal side of the split velum and uvula. Healing was uneventful.

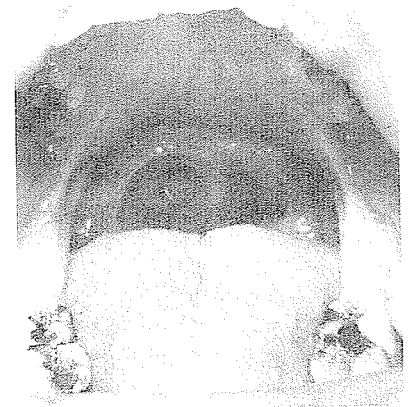


29 yrs.

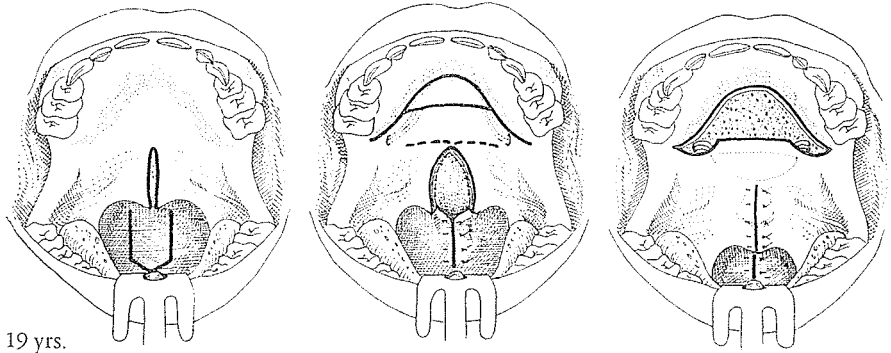
Sixteen months postoperatively, referring surgeon Gary Russolillo of Hartford, Connecticut, wrote:

Your patient has progressed marvelously and during an evaluation at the University of Connecticut Medical Center Speech Therapy Department was informed that she had such excellent speech that further therapy would be of no benefit to her. She indeed has a marked change in speech, noted both in personal contact and over the phone. Prior to surgery it was difficult to understand her on the phone and in person.

CASE 60 was born with a soft palate cleft, treated elsewhere at age 12 years with a pushback using a horseshoe-shaped incision. At age 19 years the patient revealed a short, mobile palate with a large velopharyngeal gap. The speech pathologist in cleft palate clinic reported a short palate with extreme

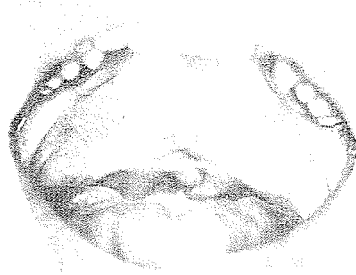

hypernasality but excellent articulation. On 1-16-78 a horseshoe-shaped incision at the line of the old scar allowed elevation of a mucoperiosteal flap. Bilateral dissection of neurovascular bundles produced a bipedicle flap of anterior mucoperiosteum which was turned over to fill the nasal lining defect after release of the soft palate from the hard palate edge. The old scar of the soft palate was opened, and a 1.4 cm. wide superiorly based pharyngeal flap was inserted on the nasal side.

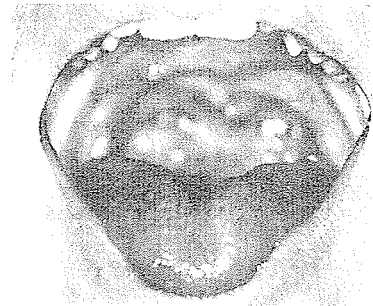


19 yrs.

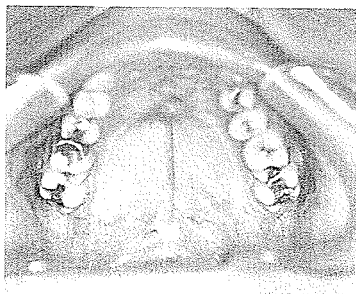
Six months after surgery there was a long, mobile palate which already made for much improvement in speech and good production of s's. Speech therapy is in progress.



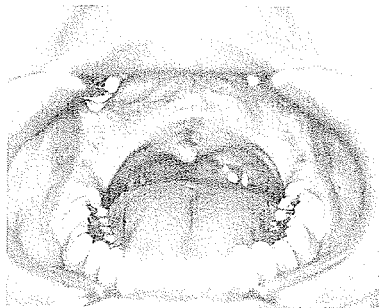
At rest



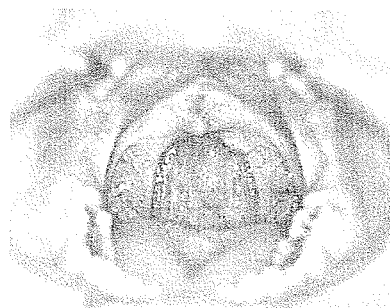
"Aaahh"



Healed donor defect



At rest



"Aaahh"

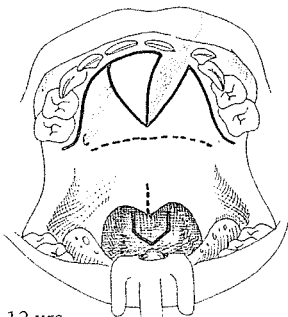
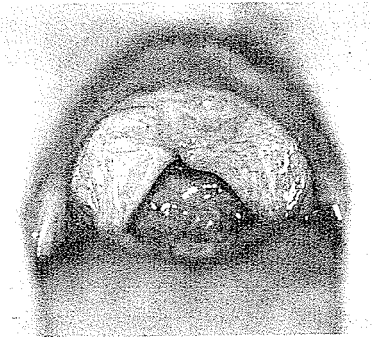
CASE 61 had an isolated cleft of the palate which was closed elsewhere with the von Langenbeck method. The result at 17 years of age was a mobile but short velum with marked nasal escape.

On 2-7-78, by means of a Dorrance incision, an anterior bipedicle island flap was used to fill the release in nasal lining. A small superiorly based pharyngeal flap was attached to the split in the uvula. The suction test was positive.

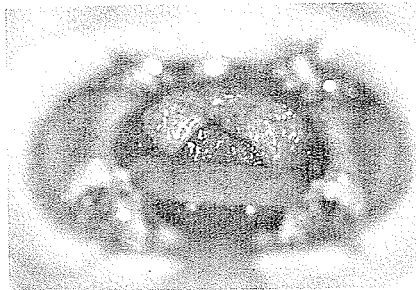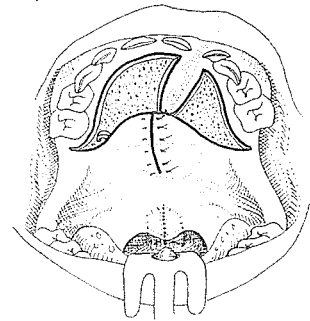
On 6-16-78 the palate appeared long and mobile. Nasal escape in speech was still present but diminishing. The patient is to have speech therapy.

CASE 62 was born with a complete unilateral cleft of the lip and palate. The lip was closed at 6 months and the palate at 18 months in Boston. At age 10 years this boy revealed buccal crossbite which was under orthodontic expansion. His palate was mobile but short and scarred, producing hoarse, hypernasal speech.

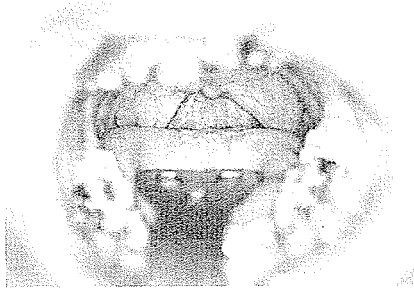
On 3-24-78 at age 12 years a 1 × 2 cm. superiorly based pharyngeal flap was sutured into a split on the superior surface of the distal velum and uvula as an adhesion. Bilateral mucoperiosteal flaps were elevated on either side of the previous cleft and the neurovascular pedicles dissected. A 1.25 cm. island flap was cut free on the right and turned over into the nasal lining defect after release of the soft from the hard palate. The remaining mucoperiosteal flaps were advanced posteriorly in V-Y fashion and sutured over the island flap. Uneventful healing was followed by speech therapy and normal speech.



12 yrs.



At rest



"Aaahh"

Bottom line: When the palate is mobile and short, with an anteroposterior gap of no more than 1 cm., a pushback with an island flap is considered more physiological. If the gap is greater than 1 cm., then a pharyngeal flap can be used in conjunction with the island flap. If the gap is extremely large, a wide pharyngeal flap may be necessary. Remember that too much reduction in nasal air flow causes destructive changes of the nasal mucosa, reduction in lung function and hyponasal speech.

Of course, there are other ways of achieving good results. This chapter is but a study of the successes and failures of one surgeon over 21 years.

and by now he should have come of age!