

## 42. *Complications and Failure of a Pharyngeal Flap and Its Secondary Surgery*

IMMEDIATE postoperative complications are more common after posterior pharyngeal flap surgery than with the usual palatal cleft closure. Pharyngeal flaps can, of course, be used to relieve tension in the closure and so to reduce certain complications. Yet the invasion of the normal posterior pharyngeal wall and its musculature and the *abnormal* attachment of a flap, partially raw on its undersurface and spanning an open space to a needy but unsuspecting velum, are not without a price.

There have been fatalities. In 1886 Schoenborn reported 20 pharyngeal flaps with one death due to pneumonia. In 1929 W. Kindler reported four cases of pharyngeal flaps with one death due to mediastinitis. Rosenthal, Axhausen and others warned that pharyngoplasty should not be performed in the first 10 years of life. Numerous accounts of intraoperative and postoperative complications from pharyngoplasties in infants exist. Schröder in 1959, Skoog in 1965, Owsley in 1965, and others told of the necessity of tracheostomies. However, in 1968 W. Bethmann and H. J. Hochstein of the Rosenthal Clinic of Thallwitz, Leipzig, reported on 529 pharyngoplasties in an eight-year period in children of the average age of 7 years without a tracheostomy or death. They noted:

During work in the pharyngeal region, considerable changes of the heart rhythm sometimes occurred (sinus tachycardia, bradycardia, bigemina). . . . Sufficient premedication and depth of narcosis are of decisive importance.

Mortality is very low today because of improved anesthesia and postoperative recovery room care, but deaths can happen. Sudden hemorrhage and airway obstruction are the most likely causes. In 1970 Yules confirmed this when he stated that, excluding potential anesthesia risk, complications were most often related to severe bleeding—with or without associated airway obstruction—with mortality usually associated with pharyngeal flap surgery.

*Hemorrhage* is more common after use of pharyngeal flaps, and bleeding in this area is not only awkward to get at but dangerous to the airway. Prior to surgery, the nasopharyngeal aperture has been generous, and the sudden partial to near-complete *obstruction of this air passage* can cause anxiety, panic, straining and gasping, which in turn may start bleeding. The prime reason for suturing the flap's donor area, in my opinion, is its early hemostatic effect. In 1966 Bengt Nylén and Åke Wahlin of Stockholm reported on airway complications of 103 pharyngeal flaps. They summarized:

There were 14 instances of postoperative complications (14% of the total group) and all were in connection with bleeding, which has also been important in other series. In 11 of the 14 cases the bleeding was checked by conservative measures or blood transfusions and did not cause concern, while in four tracheostomy had to be performed (with one death). We believe that the hemodynamic stress at extubation and laryngeal suction is due to reflex activation of sympathetic vasoconstrictor activity and venous blood congestion in the head and neck, in connection with coughing and straining and are the main causes of postoperative bleeding from a dry operative field. Extubation should therefore be planned with great care.

Yules and Chase, in the 1971 book *Cleft Lip and Palate*, list 18 groups using pharyngeal flaps with a complication ratio of about 10 percent. The compiled data of Nylén and Wahlin; Owsley, Lawson and Miller; Skoog; Edgerton; Smith, Huffman, Lierle and Moll; Walden and Rubin; Dunn; Moran; Williams and Woolhouse; Conway; Conway and Goulian; Stark and DeHaan; Gray and Jones; Champion; Longacre and DeStephano; Cox and Silverstein; Buchholz, Chase, Jobe and Smith; and Bernstein reveal a total of 1,149 pharyngeal flaps. In conjunction with them, there were recorded 3 hematomas, 19 respiratory difficulties, 15 tracheostomies, 37 flap detachments, 7 ear infections, 10 denasalities, 36 severe hemorrhages, 10 transfusions required.

With these findings in mind, Yules and Chase warned that for the first two days after surgery the patient must be watched very carefully for hemorrhage and respiratory obstruction. They noted that obstruction of the Eustachian tubes with mild otitis media was not uncommon and breakdown of the flap attachment was usually associated with bacterial infection. Even a fatality is a possibility which in the past exceeded 1 percent but has been reduced to about 0.3 percent. Single fatal cases of meningitis and mediastinitis have been reported.

In 1978, at the American Cleft Palate Association meeting, Bernard Borowiecki, Charles Pollak and Charles Croft of Montefiore Hospital, New York, commented:

A common finding in post-pharyngeal flap patients (children) is obstructive respiratory difficulty during sleep. . . . Some patients may continue to experience obstructive respiratory difficulty during sleep leading to development of obstructive apnea-hypersomnia syndrome and even death.

In 1973 Graham, Hamilton, Randall, Winchester and Stool noted that airway complications following the construction of posterior pharyngeal flaps were most frequent in children with micrognathia or other severe congenital anomalies. In the Pierre Robin syndrome, caution should be exercised before deciding to combine a pharyngeal flap and a palatal closure in one operation. An armored nasal tube may be useful postoperatively to ensure an adequate airway. These authors also advised that if tonsils are excessively large, particularly in small children, tonsillectomy be done at the time of the pharyngeal flap operation.

A *painful* "sore throat" and stiff neck are common complaints of the patients and have made this operation unpopular with me. Closure of the generous donor area under tension with large retention sutures or otherwise is seldom permanently successful and is responsible for the pain. Fára insists that muscle sutures will achieve permanent closure, but I have not had 100 percent success. When the *wound separates*, it leaves a wide, *messy* granulating area which will eventually heal by contracture and epithelialization.

A certain number of flaps become *detached*. In this event immediate reattachment or delayed re-flapping is called for. Reports of detachment of the flap are scattered through the

literature, but many more cases, of course, are unreported. In 1960 Ross Musgrave and John Bremner of the University of Pittsburgh reviewed 780 cleft palate operations performed over a 10-year period, 1950–1959. They stated:

It is noteworthy that most of the 22 pharyngeal flaps that have been performed were secondary procedures for palates shortened by scar contraction of failed primary healing. Only one of the pharyngeal flap operations had any complications, this being detachment of the flap.

Pigott of Bristol tells of his pharyngeal mishap:

Once while teaching the houseman how to raise a pharyngeal flap and in getting the base really high using double-curved scissors out of sight above the soft palate, I amputated the flap completely! The patient, an intelligent young man, was a total success as the isthmus contracted down to a very small port which could open and close with perfection. Astley Cooper used to do this routinely, but I never dared do it again.

Finally, there are the *insidious complications* in the healing of the flap which render it ineffective. These include immobilization of the soft palate by incorrect positioning of the flap's base for optimal velar action and simple flap contracture, dragging the velum down, frequently asymmetrically, to close only one port. There is also the rolling of a flap into a string tube with loss of its important obturator effect.

Pharyngeal flap reduction of velar mobility, for better or worse, is a fact. Joanne Subtelny, N. Oya, D. Subtelny, J. Curtin and R. McCormack in 1970 made a preoperative and postoperative analysis of velar and pharyngeal flap mobility. They asserted:

Despite the effectiveness of pharyngeal flap surgery, the results of this study indicate the technique generally does reduce velar mobility as reported by Skoog. Mobility of this flap is, however, significantly related to the extent of velar movement observed before surgery.

They also noted a reduction in the antero-posterior aspect of the pharynx. As shorter pharyngeal dimensions have been identified with less nasality, the relative importance of the pharyngeal environment and its influence upon postoperative speech status is emphasized.

Karl S. Musgrave, in his 1971 master of science thesis at Eastman Dental Center and Graduate School of the University of Rochester, New York, reported his extensive cephalometric radiographic evaluation of pharyngeal flap surgery. Sixty postoperative pharyngeal flap cases were separated into successful and unsuccessful groups by nasality ratings. The comparative preoperative cephalometric data, which turned out to be 89 percent predictive of postoperative results, revealed that the non-nasal speakers had (1) greater elevational velar mobility resulting in a smaller palatopharyngeal opening, (2) a shorter nasopharyngeal depth and (3) a smaller nasopharyngeal area. These preoperative features, in addition to a younger age at the time of operation, suggested an important requisite in pharyngeal flap surgery's attaining a high-positioned pharyngeal flap base attachment with good elevational mobility, thus enhancing the pharyngeal flap mechanism for production of adequate velopharyngeal closure during speech.

In 1969 Richard Yules and Robert Chase reviewed the literature on pharyngeal flaps and concluded:

Although pharyngeal flap surgery has justified its popularity, the failure rates even as noted indicate refinements yet to be made in flap surgery. . . . Before the pharyngeal flap procedure can stand up on its own as a procedure of choice within a given cline of cine, speech, and respiratory study measurements, pre- and postoperative reliable measurements must be available. The present literature is remarkable for the relative absence of any such measures.

#### PHARYNGEAL FLAP SECONDARY SURGERY

It is important to keep in mind that, despite what might be expected from the vast number of pharyngeal flaps being used today, this flap is not omnipotent or a cure-all. Skoog wrote:

A pharyngeal flap will not fully substitute for soft palate tissue in cases in which there is poor muscular function or a substantial deficiency of tissue. . . . It can be used to reconstruct a palatal membrane which will reduce nasal escape . . . but will not reproduce normal speech.

Barrett Brown of St. Louis was not an enthusiastic admirer of the posterior pharyngeal flap, but since he and his group were treating as many clefts as anyone else at that time, perhaps more, he did have occasion to use it sometimes. Frank McDowell informed me:

On rare occasions, Brown (and the rest of us) did a pharyngeal flap (secondarily) . . . usually by the method described by Padgett. Probably we did not do wide enough ones, or did something else wrong. Too often they seemed to coil up into a string or rope, which then acted as a tether to restrict movements of the velum.

Josh Jurkiewicz, one of Brown's residents, recalled:

Furthermore, he had little use for pharyngeal flap procedures and probably severed as many as any man alive. He saw a lot of failures after pharyngeal flap procedures, which at that time were simple attenuated tubed flaps, and he merely took these down, all the while castigating the procedure and occasionally Earl Padgett.

Pharyngeal flaps often are called upon to correct the residual velopharyngeal incompetence following other surgical procedures. Although these flaps, with their obturation, tethering and pharyngeal narrowing, do assist and are usually responsible for improvement in speech, there are many pharyngeal flaps which fail to solve the incompetence. The gap may be too wide, the scarring of the velum too extensive, the pharyngeal flap too narrow or its base not set at the optimal position.

In 1972 and 1973 Leon Skolnick and Gerald McCall, using videofluoroscopy in multiple projections (lateral, frontal and basal), studied velopharyngeal competence and incompetence following pharyngeal flap surgery. They found

the incompetent velopharyngeal mechanisms to be attributable to abnormalities of (1) flap width relative to the extent of medial movement of the pharyngeal walls, (2) flap position in relation to the pharyngeal walls on the horizontal plane and (3) flap level vertically in the nasopharynx as related to the region of maximum medial pharyngeal wall movement. These abnormalities have been noted to result in incompetence of one or both portals lateral to the pharyngeal flap.

Such findings, especially in the presence of continued velopharyngeal incompetence and poor speech, require secondary pharyngeal flap surgery.

## OWSLEY

John Q. Owsley, Jr., of the University of California, San Francisco, being born into a Navy family, naturally took to the sport of ocean racing, leaning his 6 foot 5 inch frame against all weather and winds. He also became the troubleshooter for failing pharyngeal flaps, investigating the causes of failure and prescribing the possible cure. In 1965, with Blackfield, he had emphasized the importance of maintaining an upward posterior vector of motion of the soft palate when attaching a pharyngeal flap. He noted the low pharyngeal flap which, when attached at the posterior margin of the soft palate, produces traction in an inferior or straight posterior direction and may actually restrict normal palatal elevation.

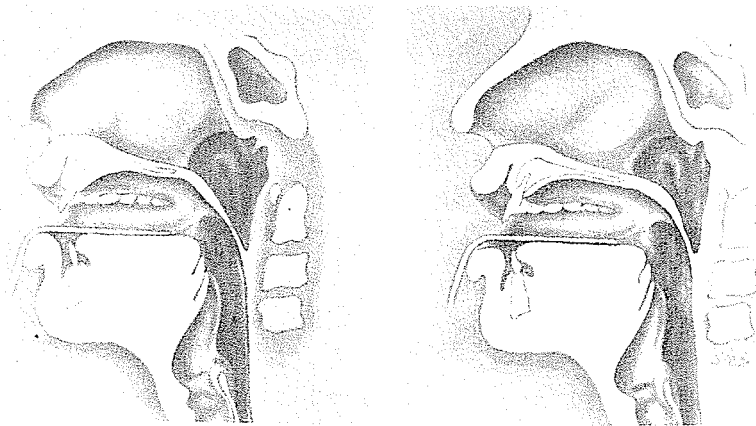


John Owsley

In 1972, with Brevator Creech and Herbert Dedo, Owsley said:

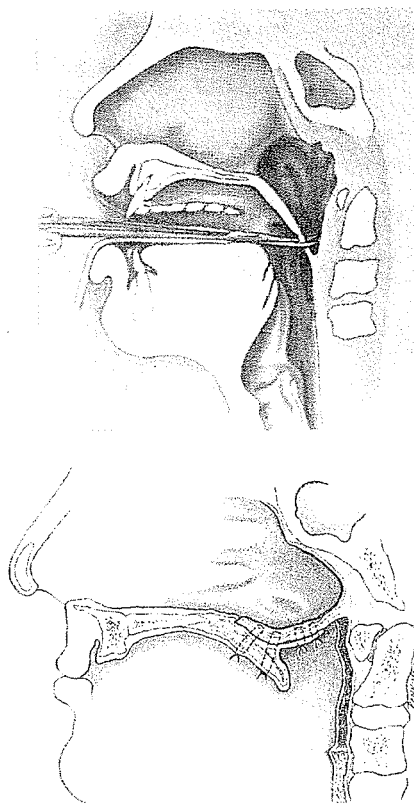
A significant number of patients with residual velopharyngeal incompetence after a pharyngeal flap operation have been found in our experience to have just this type of restrictive flap. Clinical and cinefluorographic examination of these patients suggest that the central pharyngeal flap acts as a static obturator. . . . If there is good palate mobility and pharyngeal muscle movement, many low attached pharyngeal flaps will provide non-nasal speech. However, if palate elevation is restricted and pharyngeal muscle activity is ineffective or easily fatigued, then hypernasal speech persists.

In the 1972 *Cleft Palate Journal* they presented drawings demonstrating restrained action in the presence of a restrictive pharyngeal flap: (A) at rest and (B) phonating "ah." Their recommendation was logical:



A

B



It therefore seems reasonable to suggest that poor speech due to a restrictive pharyngeal flap may be improved by division of the flap and reattachment of a new, high, anteriorly attached flap.

They divide the previous flap from the pharynx and suture the small defect in the pharynx. The soft palate is split, facilitating a view of the posterior pharyngeal wall, which appears unscarred in spite of its being the previous donor site. A new flap is cut with its superior base above the tubercle of the atlas. The recipient site is developed on the anterior nasal aspect of the soft palate by reflecting posteriorly based flaps of palate mucosa. After the pharyngeal flap is sutured into the recipient site, the mucosal flaps are used to line the raw undersurface of the pharyngeal flap and reduce inferior migration of the base of the flap again. No attempt is made to close the posterior pharyngeal donor area. The postoperative result in five patients was encouraging.

By 1976 Owsley, with Lucie Lawson and George Chierici, had had increased experience with the "re-do" pharyngeal flap:

Twelve patients with persistent hypernasal speech after a previous pharyngeal flap operation had a second pharyngeal flap operation performed by the high-attachment technique. Six of them achieved complete or near complete correction of hypernasality in connected speech. Four showed speech improvement of a lesser degree. Two patients had no significant improvement.

#### W E B E R



*Jaroy Weber*

In 1970 in the *British Journal of Plastic Surgery* Jaroy Weber, Jr., R. Jobe and R. Chase of Stanford University reported five patients with hypernasal speech resulting from low-lying, restrictive pharyngeal flaps. It is fortunate that Weber, with a trained ear and involved in American folk music playing the guitar, mandolin and banjo, should gravitate to palate surgery. These authors noted:

Superiorly based flaps . . . placed high in the posterior pharyngeal wall have augmented velopharyngeal function and have not appeared significantly to restrict palatal motion, either inferiorly or superiorly (Buchholz *et al.*, 1967). Cinés of our patients after pharyngeal flaps have been indistinguishable from those of patients who have had pharyngeal flaps performed at the University



of California by the method described by Blackfield (Blackfield *et al.*, 1963). . . . Flaps placed low on the posterior pharyngeal wall, . . . have been felt to tether the palate in an inferior direction.

They acknowledge that migration in the postoperative period, a result of scar contracture between the flap and its bed on the pharyngeal wall, can affect the location and pull of the flap.

In defense of the Stanford method, they stated:

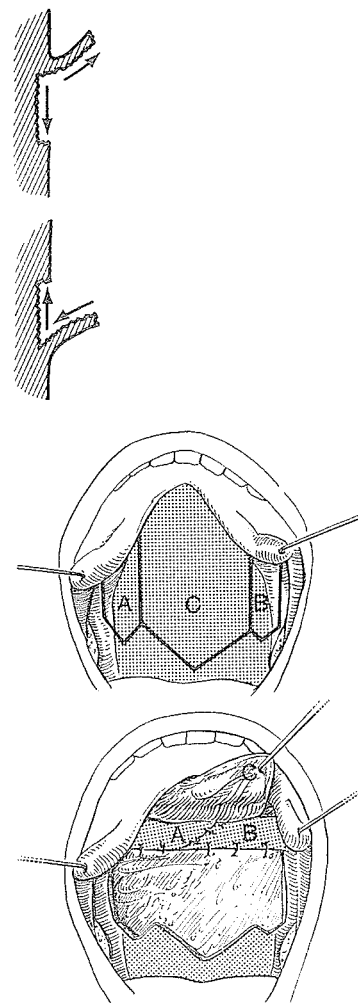
The importance of the site of the attachment of the pharyngeal flap to the palate has not been sufficiently emphasised. It is felt that the flap should be sutured at, or anterior to, the central insertion of the levators. This provides a surface for the raw nasal side of the palate over the levator insertion and thereby inhibits scar formation between the levators and the hard palate. . . . The increased superior motion of the palate due to the levators may also inhibit inferior migration of the flap origin on the post-pharyngeal wall.

Two of the five patients with restrictive pharyngeal flaps were improved by division of the flap and construction of a superiorly based flap in conjunction with the palate pushback.

#### DIRECTION OF CONTRACTURE

It is true that any raw area on the undersurface of a superiorly based flap will tend to pull the velum upward while its donor area is pulling downward. The opposite is true of an inferiorly based flap as the flap's raw area pulls downward while the donor area pulls upward. These counteracting actions probably explain why postoperatively it is often difficult to determine whether the flap was based above or below.

Tord Skoog of Uppsala learned respect for the downward drag of the donor area of a superiorly based flap and designed a three-fingered pharyngeal flap. He folded the two lateral narrow flaps under the main flap to line the junction of the flap with the raw area on the pharynx in a gesture to interrupt the potential contracture web. It is possible that a longer transposed flap from one side alone could well block contracture. At least, this principle is a prophylactic step against a possible complication.



## AUGMENTATION BY FLAPS

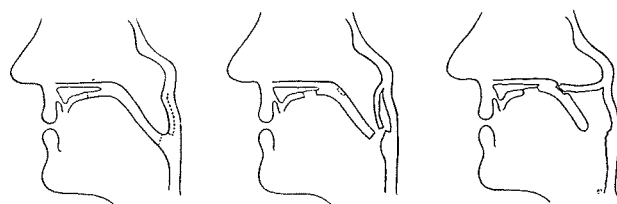
Bard Cosman and Arlene Falk of Columbia-Presbyterian Medical Center stated in 1975:

Nasality persists in a small but significant number of patients who have had a pharyngeal flap. In addition, nasality may recur long after doing an initially successful procedure.

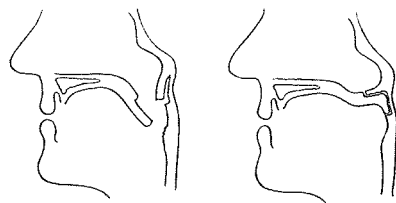
The causes of such primary and secondary failures are probably faults in the relative size and/or positions of these nasopharyngeal obturators.

They noted three methods of repositioning the pharyngeal flap:

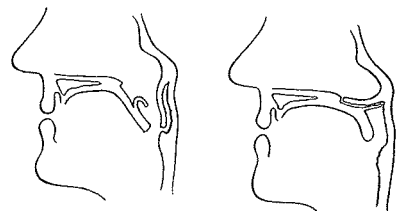
1. Weber's repositioning divides the tethering inferior base and attaches a new, superiorly based pharyngeal flap at a much higher level on the nasal surface of the velum. The new flap is raw on its undersurface.



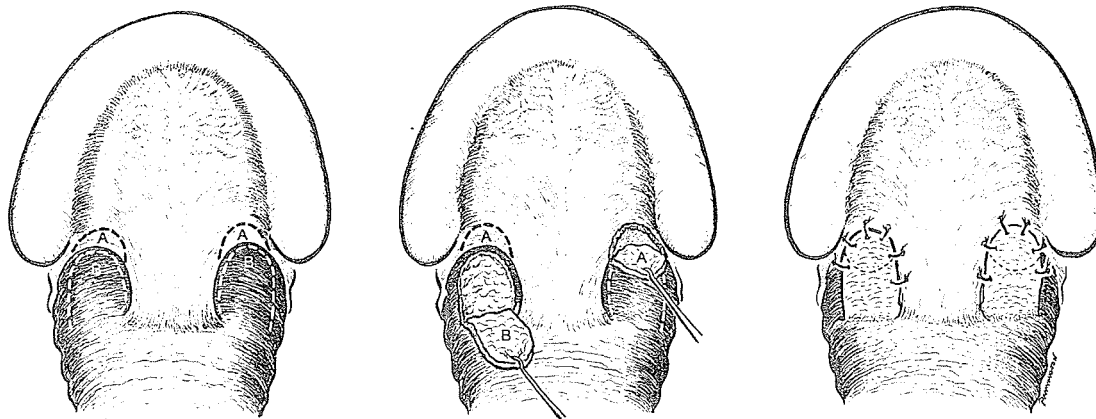
2. In McEvvitt's repositioning, the inferiorly based flap is converted to a superiorly based one.



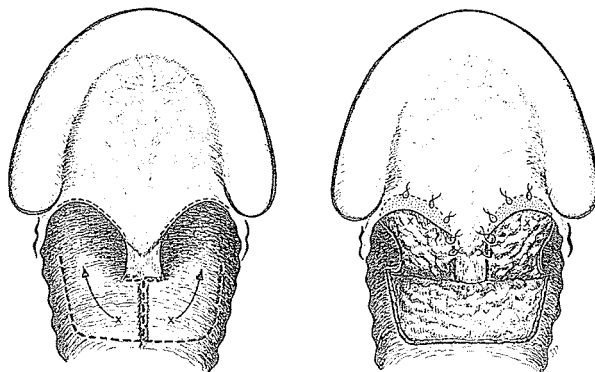
3. Owsley's repositioning divides the old, inferiorly placed base and attaches a new superiorly based flap high on the palate using a hinged-back lining from the nasal surface of the palate.



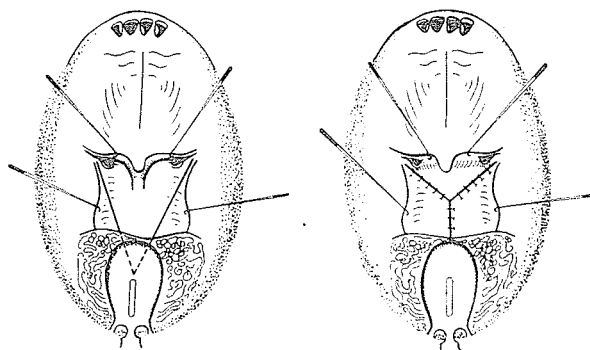
Cosman described his augmentation of a failing posterior pharyngeal flap. First he turns two inferiorly based pharyngeal flaps back from the lateral posterior wall on either side of the present pharyngeal flap. Then he turns two matching mucosal flaps from the lateral oral side of the velum with their bases on the posterior edge of the palate. These four flaps are overlapped on each side to augment the inadequate center attachment and to reduce the lateral apertures.



In the 1976 *Cleft Palate Journal* Bernard Hirshowitz and Dahlia Bar-David of Haifa, Israel, endorsed Cosman's principle of pharyngeal flap augmentation. They reported success in three cleft palates that had experienced failure with pharyngeal flaps. A secondary pharyngeal flap of maximal width and adequate length was based superiorly at the level of the previous flap. It was divided down the seam scar of the previous donor area, and each end of the double flap was tucked into a pocket split along each side of the posterior edge of the soft palate.



In 1977, again in the *Cleft Palate Journal*, the same Israeli team suggested another approach. They repositioned the base of superiorly based pharyngeal flaps, which had migrated inferiorly and which were associated with persistent hypernasality, with a V-Y upward advancement of the base. Relief of the downward tethering effect in four cases was followed by gratifying correction of hypernasality.



#### ADDITIONAL TEFLON

In 1972 H. S. Sturim and C. T. Jacob, Jr., of Brown University, advocated the supplemental injection of Teflon behind the posterior pharyngeal wall in patients in whom a pharyngeal flap had been unsuccessful.

#### PHARYNGEAL FLAP'S SECONDARY EFFECT ON THE MAXILLA

It is conceivable that the tethering of a pharyngeal flap attached to the velum could have some retracting effect on maxillary development. Certainly, a broad, unlined pharyngeal flap, used in an early primary cleft closure, with the subsequent contraction, has the best chance of transmitting backward pull on the growing maxilla. There is, however, little consistent confirmation of this influence in the literature to date.

In 1976 Robert Pearl and Ernest Kaplan of Stanford University Medical Center reviewed clinical and cephalometric records of 25 patients who had had a superiorly based pharyngeal flap

with a palate pushback. Linear and angular cephalometric measurements of these children revealed no later growth retardation of the face. There was an inherent tendency of the secondary palate cleft, classic submucous clefts and occult submucous clefts to demonstrate preoperatively a narrow SNA and SNB—but the difference between these two angles (ANB) was normal.

In 1977 R. Bruce Ross of the Hospital for Sick Children, Toronto, reported on 62 patients who had pharyngeal flaps attached to the soft palate. Serial cephalometric radiographs, from the time of operation for an average of 6.7 years (minimum, 3 years) from a mean age of 8.2 to a mean age of 14.9 years, were matched with twice the number of controls of the same sex, cleft type and age. He noted:

Several of the many growth measurements showed significant differences between sample and control groups. The conclusion, however, was inescapable that pharyngeal flap surgery performed at these ages does not interfere with maxillary growth.

In 1977 Roberta Pineda and J. Daniel Subtelny of Rochester, New York, studied the effects of primary pharyngeal flap surgery performed on 24 cleft palate individuals prior to the prepubertal growth period. Two control groups were used for comparison—28 non-cleft individuals and 18 cleft palates without a pharyngeal flap. Comparable longitudinal cephalometric records indicated

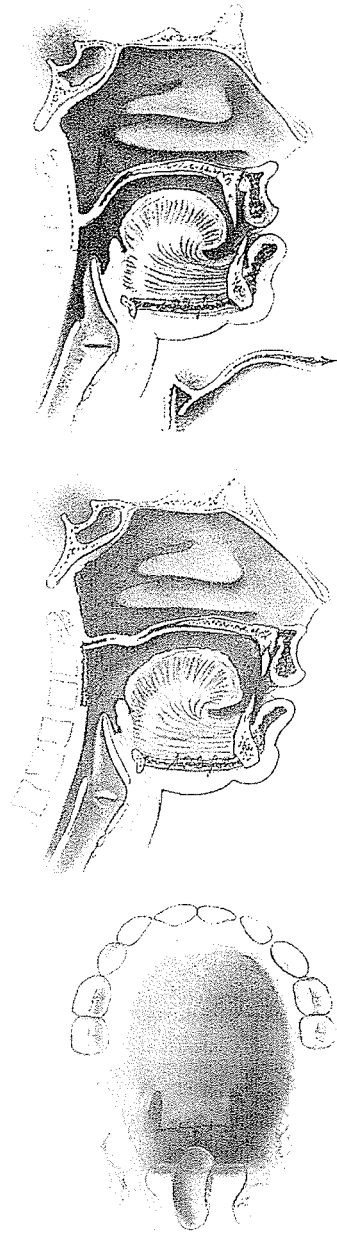
that pharyngeal flap surgery has an effect on maxillary growth. When compared with the normal sample, both cleft samples, with and without pharyngeal flaps showed some reduction in forward maxillary growth. However, the pharyngeal flap group showed significantly greater reduction in maxillary forward growth.

Gaston Maillard of Lausanne, Switzerland, trained by Tessier, Dufourmentel and a Maytag Fellow in Miami, has observed again and again the impossibility of moving the maxilla forward after osteotomy against the firm fixation of a pharyngeal flap. Only after division or lengthening of the flap can the maxilla be advanced, and, on this basis, he feels certain that early pharyngeal flaps have a retracting effect on maxillary growth.



*Bruce Ross*

## MAXILLARY ADVANCEMENT AND THE PHARYNGEAL FLAP



Paul Tessier of Paris, as an invited professor at the University of Pennsylvania, carried out two maxillary advancements in which posterior pharyngeal flap attachments had to be lengthened to allow the maxilla to come forward. Randall, at the time of surgery, suggested a method of lengthening the pharyngeal flap without dividing it but did not check with Tessier (there is some language barrier) to see whether he had used this procedure before. The method designed was utilized and then soon reported without mentioning the fact that Tessier was the surgeon. The publication, by resident Robert Ruberg, Peter Randall and Linton Whitaker, appeared in the March 1976 issue of *Plastic and Reconstructive Surgery*, presenting a logical lengthening of a previously existing posterior pharyngeal flap in order to preserve its attachment when maxillary advancement is necessary. Lateral relaxing incisions were made on either side of the base of the previous flap. The inferior portion of this strip was divided and the flap dissected upward, maintaining a superior base. The inferior portion was employed to line the underbelly of the upper portion as the flap was lengthened to allow maxillary advancement.

This publication infuriated Tessier, who had used the procedure before. In the September 1976 issue of *Plastic and Reconstructive Surgery*, Whitaker wrote an apology:

We neglected to mention that Dr. Paul Tessier was the operating surgeon on the two cases described in the article—though the idea of lengthening the flap was, insofar as we know, first conceived by Dr. Randall. We have done this procedure since on other patients.

Tessier was not appeased.

## MAXILLARY ADVANCEMENT MAY REQUIRE PHARYNGEAL FLAP

At the Craniofacial Symposium at the University of California, Los Angeles, in 1977, S. A. Wolfe inquired of those who are advancing maxillae how many advancements were causing velopharyngeal incompetence. He reported:

Dr. Paul Tessier stated that in his series of about 150 LeFort III advancements, he recalled 5 or 6 who developed VPI which persisted and required pharyngeal flaps—and they were all Aperts, who generally have a submucous cleft.

Henry Kawamoto of UCLA said that in his own relatively small series of about 20 LeFort I advancements, 4 developed VPI requiring PPF.

These were all CL/CP patients who were borderline pre-op—and the surgery nudged them over into gross VPI.

Reed Dingman of the University of Michigan noted in a case appearing in this volume that LeFort III maxillary osteotomy produced velopharyngeal incompetence in a cleft lip and palate case with borderline speech. He used a pharyngeal flap to correct the problem.

Ian Jackson of Glasgow noted in 1977:

We are often presented with a young child with nasal escape who will require a later maxillary osteotomy. In a small portion of cases this osteotomy will cause a recurrence of his velopharyngeal incompetence. In these, if the escape is mild or moderate and the child can cope, the situation is left untreated until after the osteotomy. If escape is severe . . . then a pharyngoplasty is performed.

In 1977 Mary Anne Witzel and Ian R. Munro of the University of Toronto described a 16-year-old postoperative cleft lip and palate patient who, after his maxilla was advanced 10 mm. and rotated down 4 mm., revealed hypernasality. Six months later, a palatopharyngoplasty restored his speech. Later that same year, Witzel and Munro reported further study of the effect of maxillary advancement after osteotomy on articulation and velopharyngeal function in 61 osteotomies (LeFort I, LeFort III and others). When articulation was directly tied to malocclusion, they noted, there was improvement in articulation after osteotomy with correction of occlusion. Of 18 cleft lip and palate cases, hypernasality occurred in five following LeFort I. It was found that patients who revealed a borderline mechanism preoperatively generally developed hypernasality. Those who were borderline preoperatively and remained so after maxillary advancement had a Passavant's ridge which evidently adapted by increasing its excursion.