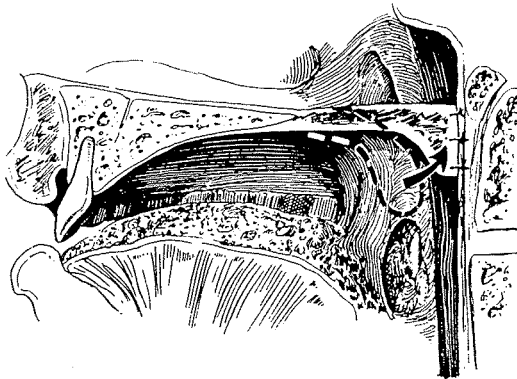


36. Velopharyngeal Synechiae with Various Pharyngeal Flaps

FIRST AN ADHESION

IN 1865 the remarkable Gustav Passavant described his adhesion method to reduce the velopharyngeal aperture. Ideal position for the adhesion was noted, and it was strategically placed on the free border of the velum and the posterior pharyngeal wall. Equivalent areas, 8 lines long and 5 lines in depth, were denuded of epithelium. The velum was then attached to the pharynx with sutures, with what Passavant described as better results.



INFERIORLY BASED PHARYNGEAL FLAPS

From Stellmach's scholarly research and translations of the original German, presented in *Plastic and Reconstructive Surgery*, 1972, revealing information has been provided on the earliest pharyngeal flaps.

A line
is $\frac{1}{2}$ of
an inch

In 1979 Chinese Surgeon Song Ruyao advocated a "raise-up" adhesion similar to Passavant using an inverted T incision in the posterior pharyngeal wall to create triangular flaps for suturing to the nasal sides of the cleft velum during palate closure.



Karl Schoenborn

Schoenborn

Karl Wilhelm Ernst Joachim Schoenborn was a student under von Langenbeck at the University of Berlin and later was appointed professor and chief of surgery at the University of Königsberg. In 1876 he described a flap as it is used today. He wrote with modesty, giving credit to those before him but demonstrating his own remarkable clairvoyance:

I believe it is a known fact among most surgeons that healing of the congenital cleft palate can be achieved, with a high degree of certainty, by the uranoplasty introduced by von Langenbeck and by a staphylorrhaphy. However, after even the most successful operation the speech of these patients leaves much to be desired; there is severe nasality. . . .

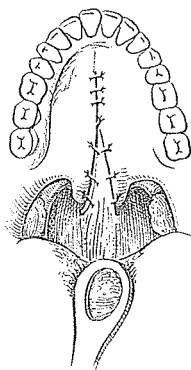
Passavant pointed out that the patient retains a nasal tone, despite the good healing achieved, because the newly formed soft palate is too short to accomplish velopharyngeal closure. . . .

Please allow me to bring a new surgical method to your critical attention. . . . This consists of incorporating a flap, taken from the posterior pharyngeal wall, between the two halves of the soft palate.

Here it comes!

About 4 years ago, as I was discussing with my friend and colleague Trendelenburg the possibility of closing an abnormally wide cleft palate . . . he advanced the idea that it might be possible to join a flap from the posterior pharyngeal wall to the soft palate. If I remember correctly, he also made some important attempts on human bodies and animals; however, the operations appeared to be very difficult and, as far as I know, there were no further attempts. . . .

I performed this operation on a female patient on July 2, 1874. This patient, Emma Kollecker, aged 17, had a congenital (unoperated) cleft of the hard and soft palate. . . .



An honesty

After induction of general anesthesia . . . I made rim incisions along the cleft borders. With a long scalpel . . . I outlined a flap about two cm long and 4 to 5 cm wide, with its long axis vertically and its base *caudally*, from the posterior wall of the pharynx. . . .

The incision was carried through the mucosa and underlying muscles. . . . (Particular attention must be paid to keeping the scalpel within the loose areolar tissue beneath the muscle, so that no part of the flap is thinner than the other.) Next, I detached the mucoperiosteal layer of the hard palate enough so that it and the soft palate were sufficiently mobile. Then I trimmed the edges of the flap so that it was in a triangular form, with the tip at the upper end. This was sutured then between the dissected two halves of the velum. . . . The cleft in the hard palate was closed with 3 additional sutures.

Schoenborn admitted partial separation of the flap on the left side and opening in the hard palate, which was corrected with a von Langenbeck operation.

Schoenborn continued:

The result of the operation, as far as improvement of speech was concerned, was very important. Immediately after healing had taken place, the patient's speech was absolutely clear and easily understandable to everyone. The nasality had not disappeared completely, but it diminished week to week as the patient learned, by speaking, to close both side openings through the activity of the pharyngeal muscles. These muscles being on the sides of the pharyngeal flap facilitate closing the communication between the nasal and oral cavity.

The patient had no difficulties in swallowing, nor in breathing through her nose. . . . Until this patient, I had not seen such a remarkable improvement in speech immediately after healing took place.

Ten years later, in 1886, Schoenborn reported progress with his flap:

I have now done the staphyloplasty on 20 patients. Of these, one died of septic pneumonia; in 3 other cases, the transplanted flaps became necrotic. Healing was achieved in 16 cases; in two of them it was limited to one side of the flap, but after a second operation the other side also healed. In the remaining 14 cases, healing was uneventful.

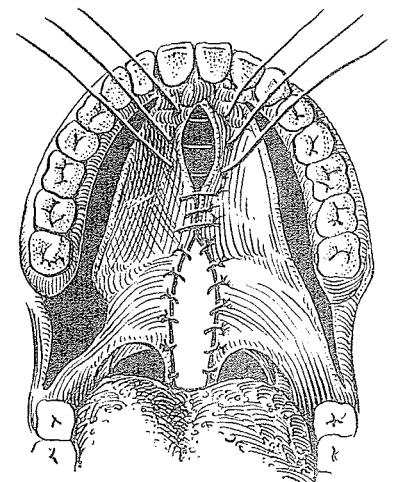
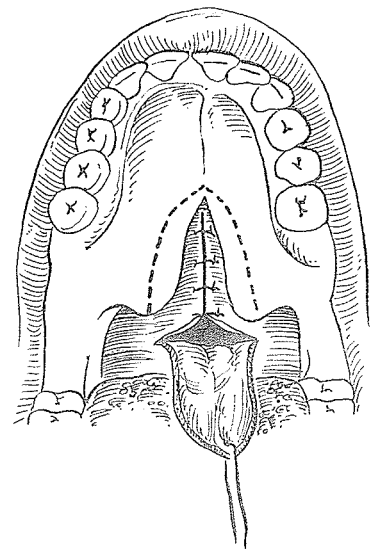
Rosenthal

In 1924 Wolfgang Rosenthal of Berlin revived Schoenborn's pharyngeal flap based inferiorly, combining it with a modified von Langenbeck palate closure for all cases involving the hard and soft palate. This combined procedure was done in one sitting and thus is the first use of the pharyngeal flap primarily in the cleft closure. Like Halle and Ernst, Rosenthal carried out lateral relaxing incisions close to the alveolar ridge and back along the pterygomandibular ligament to within 1 cm. of the last mandibular molar tooth. Rosenthal claimed:

You get perfect or almost perfect speech results if you combine a Langenbeck operation with a pharyngoplasty during the same procedure.

At the First International Congress held in Stockholm in 1955, Rosenthal reminisced:

When I performed a velopharyngoplasty for the first time, my reasons were less mechanical ones. At this time (1915-1916), I was occupied with an investigation of the muscular neurotization. A student of medicine with a completely mutilated velum was sent to me from Leipzig. The young man



spoke indistinctly and, therefore, had been dissuaded from his studies. His velum was totally paralyzed but the posterior pharyngeal wall seemed to be innervated. I took a muscular-mucous flap from the pharynx in order to obtain a muscular neurotization of the immobile velum parts. The success obtained was an astonishing one. The student, today, is an experienced physician at Zwickau-Saxony. He speaks normally.



Wolfgang Rosenthal

Encouraged by this, I applied that method not only in cases of velum shortening but also in two cases of velum paralysis remaining after diphtheria. Time of operation: not before the age of 12 years. . . . Closure of the pharyngeal defect by catgut sutures is necessary.

Wolfgang Rosenthal was as famous a musician and singer as he was a surgeon. He sang under many well-known conductors, such as Furtwängler, Vihirch, and Bruno Walter. His friend Trauner described him as

serene, open-hearted, full of wit and a true artist.

R. Meyer of Lausanne, recalling his charm, wrote:

He was known as the best ladies' speaker at congresses. However, once in a speech, he declared that man is more beautiful than woman and that this fact is well illustrated by the German language since we say: mmmm! aaaa! nnnn! = mann . . . and on the other hand: wwww! eeee! iiiii! b = weib.

In Bratislava in 1965 I rode in a car partway with Rosenthal and a group of East German plastic surgeons on their way back to their sector and remember him clearly: handsome, with chiseled features, white hair and a gracious smile. To add to his distinctions, he once operated on a lip cleft in a lion cub.

Rosenthal had to turn a charming old castle in the village of Thallwitz into a maxillofacial surgery hospital, and here it is said he operated on 30,000 primary clefts coming from Germany and Czechoslovakia. It is sad that this noble surgeon was never allowed to have his own proper clinic only because he was supposed to have had a Jewish great-grandfather. The irony is even greater because his great-grandmother confessed on her deathbed that her first son, Wolfgang's grandfather, was actually the son of a young count Schoenborn whom she had known while on duty in a castle in Poland. Fate played a second Schoenborn's trick on him, for his pharyngoplasty eventually was called the Schoenborn-Rosenthal flap, but alas, for an entirely different Schoenborn.



In 1951 Dunn noted that patients with a pharyngeal flap required less speech therapy than those with other repairs.

In 1972 Poul Fogh-Andersen of Copenhagen wrote of his inferiorly based pharyngeal flap attached to the mid-posterior oral surface of the velum:

As you possibly know, I was the first to "introduce" the pharyngeal flap operation in Scandinavia (1953). . . . In England, it seemed to be nearly unknown, even in Basingstoke, at the time I worked with the problem—as will appear from the enclosed copy of Gillies' letter from 1952.

Gillies' letter read:

I have not really enough experience of the pharyngeal flap operation to state that the speech results are worthy of the effort. I think they should be.

Dingman

In 1963, at the Third International Congress in Washington, D.C., Reed O. Dingman, W. C. Grabb and H. H. Bloomer of the University of Michigan reported dissections of 25 sagittally cut human heads, demonstrating:

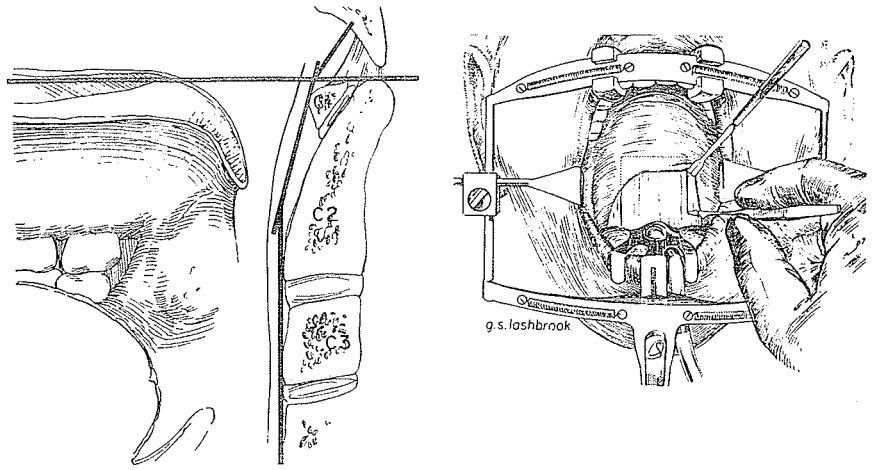
The circular fibers of the superior constrictor muscle can be identified beneath the mucosa of the posterior pharynx . . . [and extend] cephalad to the level of the junction of the first cervical vertebra and the basilar portion of the occipital bone. . . .

The posterior surface of the superior constrictor muscle is intimately related to a thin discrete buccopharyngeal fascia. The plane dorsal to this buccopharyngeal fascia is the retropharyngeal space which contains loose areolar tissue and separates the structures of the pharynx anteriorly from the prevertebral muscles and fascia immediately posteriorly. This loose areolar plane permits ready elevation of a pharyngeal flap. . . .

The internal carotid artery, with the cervical sympathetic nerves on its medial aspect, was identified in the dissections. In the adult cadavers, the distance from the lateral incisions of the pharyngeal flap to the internal carotid artery was measured to be between 1 and 1.5 cm.

In these sagittally cut sections, a definite concavity of the posterior pharynx above the level of the second cervical vertebra was readily apparent. This concavity begins at the upper edge of the second cervical vertebra and deepens gradually over the first cervical vertebra to reach its deepest point at the lower aspect of the basilar portion of the occipital bone.

← Important

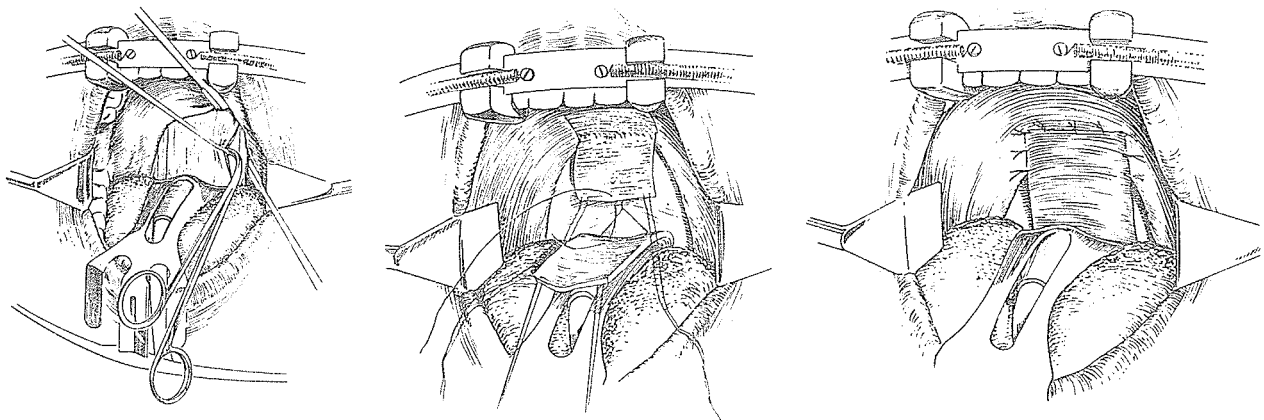


They described their operative technique for an inferiorly based pharyngeal flap:

The lateral incisions are placed so as to include almost the entire width of the posterior pharynx in the flap. The depth of the incisions is to the shiny white tendon of the longus capitus muscle. The flap is undermined with right angle scissors. . . . The flap may include a portion of adenoid tissue. . . .

After undermining the lateral pharynx with right angle scissors, the posterior pharyngeal donor site is closed with figure-of-eight No. 3-0 chromic catgut sutures. . . .

The distal end of the pharyngeal flap is held on the oral surface of the soft palate under minimal tension in order to outline the size of the soft palate flap. This flap of mucosa and submucosa based on the posterior edge of the palate is raised by sharp dissection. The two flaps are then sutured back to back.



They reported that, out of 50 posterior pharyngeal flap patients over one year after surgery, 21 had satisfactory speech records

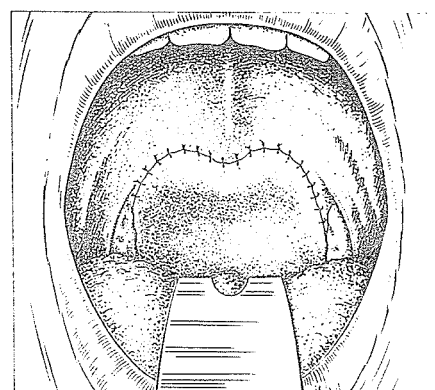
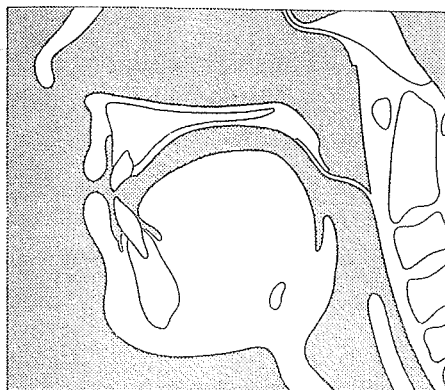
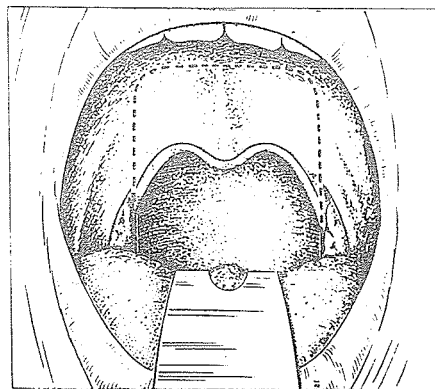
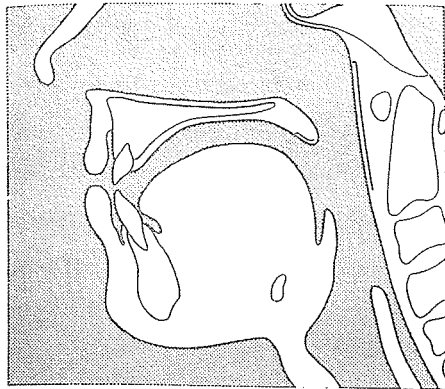
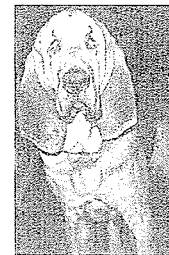which revealed improvement in articulation with few exceptions and invariably lessened hypernasality. Only seven were in the acceptable range, but all had shifted from moderately severe hypernasality to very mild hypernasality.

Huffstadt

A. J. C. Huffstadt of the Netherlands, besides doing a bit of bloodhound breeding and keeping three-fourths of an acre of pink peonies, mauve dahlias and apple trees, devotes the majority of his time to surgery. In 1970, in the *British Journal of Plastic Surgery*, Huffstadt, with J. M. H. Borghouts and A. J. Moolenaar of the University Hospital of Gröningen, expressed preference for the simplicity and freedom from fistulae of the Rosenthal type of pharyngeal flap. Their flap was based centrally and as high as possible, including the whole width of the dorsal nasopharyngeal wall. When sutured into the prepared cleft on the soft palate, the flap lies almost horizontally. As the donor area healed and contracted, they noted, the base of the flap was raised even higher.



A. Huffstadt



Chronic atrophic rhinitis or ozena, characterized by atrophic nasal and pharyngeal mucosa, formation of crusts and a repulsive smell, has an unknown etiology and a rare spontaneous cure. In 1976 A. J. C. Huffstadt and P. E. Hoeksema of Gröningen advocated reduction of nasal airflow with a pharyngeal flap. They reported:

The first 10 patients were treated with the wide flap we use for rhinolalia. All of them had some difficulty in nasal breathing. Next, the original Rosenthal (1924) method with a narrow flap and closure of the donor area was performed but it was obvious that this was very much less effective than the wide flap.

A flap of about three-quarters width of the dorsal pharyngeal wall is now used as a compromise between an effective reduction of the nasal airway and reasonable breathing.

LATERAL ADHESIONS FOR A LARGE PHARYNX



Harold Kirkham

Harold L. D. Kirkham was a plastic surgeon particularly interested in ears and palates. Born in England, he worked his way as a youth to America on a freighter, studied medicine at the University of Texas and returned to England for plastic surgery training with Gillies. A U.S. Navy veteran of both world wars, Kirkham was chief plastic surgeon at San Diego Naval Hospital and later at the U.S. Naval Hospital in Houston. He received the Legion of Merit and retired a captain. He was exceptionally talented beyond his surgery, excelling as a painter (he exhibited his prize-winning work, "Three Monks," in New York City), and as a violinist for the Houston Symphony. He never took a trip without his golf clubs and seldom returned without a trophy. Once he surreptitiously arranged for golfer Sam Snead, then an enlisted man with a back ailment, to remain a couple of extra weeks in the San Diego Naval Hospital so he could improve his golf game during afternoon sessions at a local golf course. This tall, lean Britisher, who turned into a drawling, tall-tale-telling Texan, could attract and hold a crowd all evening with his fascinating yarns. His favorite palate tale involved a family who came to consult him about the daughter's cleft palate. During the

*Kirkham later
complained that
after Snead's
special instruction
his game was
worse than ever!*

consultation he asked the mother whether there was any history of this deformity on her side of the family, and she denied any clefts. Then he asked:

What about your husband's family?

The mother said that she did not think so, but that he was out in the waiting room. Kirkham called the father in, noticing a typical cleft lip scar, and inquired:

Is there anything like your daughter's deformity on your side of the family?

The father answered in severe nasal speech:

No, there ain't nothin' like that in my family.

Kirkham then looked in the father's mouth and finding an extensive cleft of the entire palate, asked:

What about that hole in the roof of your mouth?

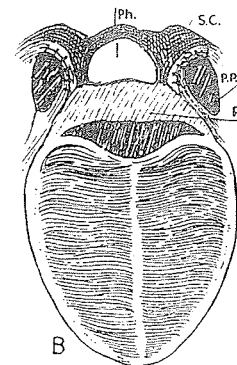
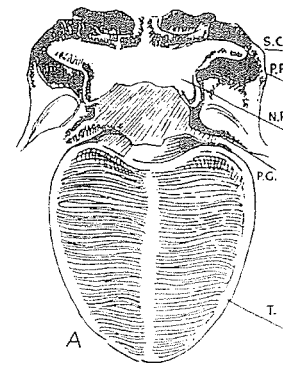
The father replied, again nasally:

Oh that ain't nothin', it's been there all my life!

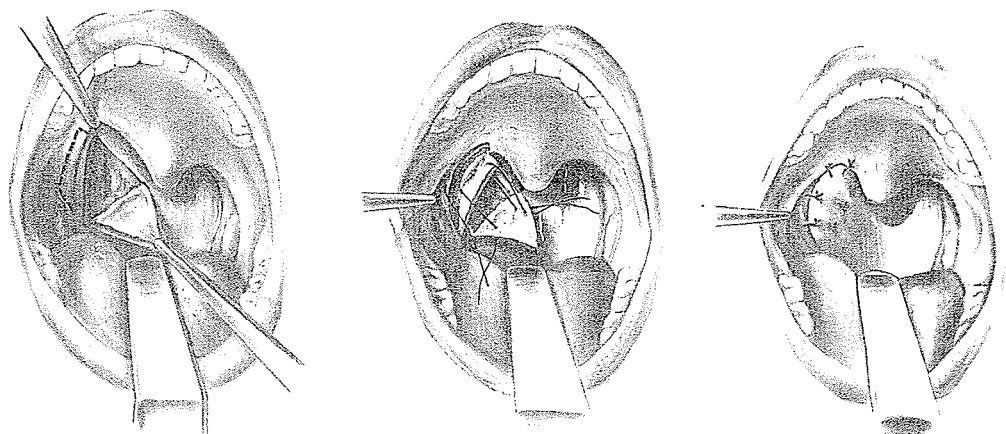
In 1927 Kirkham revived the velopharyngeal adhesion principle. His comparison of measurements of normal and cleft palate specimens of the same age at the Hunterian Museum of the Royal College of London indicated that velopharyngeal insufficiency was due more to the widened pharynx than to the shortened velum. He attempted to shorten the superior constrictor muscle by denuding lateral portions of it and suturing these raw areas to corresponding denuded sides of the palatopharyngeus muscles. Although the application of the principle in a 6-year-old boy was a failure, the importance of the wide pharynx was brought to the attention of palate surgeons.

LATERAL FLAPS

In 1932 Réthi designed an operation for "rhinolalia aperta" to correct the effect of an over-large velopharyngeal space. He turned a mucosal flap from the lateral posterior pharyngeal wall based medially and obliquely. To face this flap, he lifted, in leaf-of-book



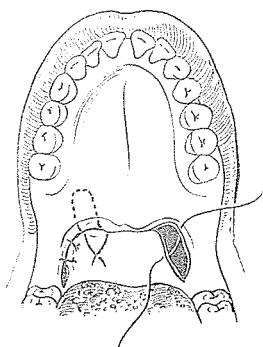
fashion, a mucosal flap from the posterior pillar of the fauces, based inward. These two flaps were coapted with sutures. Réthi advised repeating this operation on the opposite side when one procedure did not overcome velopharyngeal insufficiency. He reported two successful cases. This rather intriguing modification has never enjoyed popularity but possibly has more merit than realized.



The Kirkham-Réthi principle was revived by Richard Trauner of Graz in the mid-50's, as noted by his teacher Rosenthal, who wrote in the 1957 *Stockholm Transactions*:

He performs an orificial closure of the velum, leaving the patient only a median aperture for breathing.

Rosenthal presented his modification of Trauner's modification of Kirkham-Réthi lateral attachments.



PHARYNGEAL FLAPS WITH BASE SUPERIOR

It is not generally realized that, although Schoenborn started with an inferiorly based flap, he eventually changed to a superiorly based flap and gave sound, logical reasons for this switch. He also noted the possibility of dividing the flap attachment years later. In 1886 he wrote:

With time, the method of operation becomes simple. . . . A rather wide flap of the posterior pharyngeal wall is developed. Now, I regularly place its base cranially, high up around the pharyngeal tonsil. (Formerly, I made the bases

of these flaps caudally, but this is not ideal because the mucosa from the region of the adenoids is not suitable for suturing, being extremely fragile.) This flap is detached with the help of a long hooked forceps, and with Cooper's scissors. It is sutured to the raw edges of the two halves of the soft palate. . . .

After 6 to 8 weeks, the wound in the wall of the pharynx is healed and uranoplasty can be undertaken. However, it is better to wait about 6 months, during which time the width of the cleft in the hard palate diminishes. . . .

I am convinced that the operation should aim at later dividing the connection between the velum and pharynx again, if the patient maintains acceptable speech for some years.

In 1892 Bardenheuer suggested using a pharyngeal pedicle with its base superior.

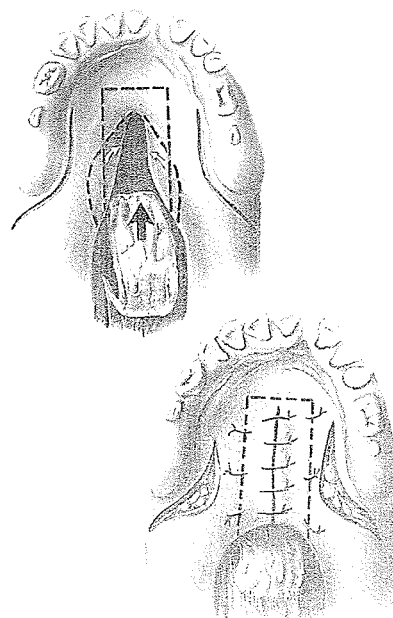
Padgett

Earl Calvin Padgett of the University of Kansas School of Medicine, Kansas City, Missouri, was born into a family of bankers in a small town in Kansas. Against family tradition, he decided to go into medicine and was refused financial assistance. After graduation from Washington University School of Medicine in St. Louis, he was honored by an offer of a position with Harvey Cushing at Harvard. Unable to afford the required stipend, he remained in St. Louis to train with Vilray Blair, under whose tutelage he thrived. Later he popularized the pharyngeal flap in the United States, reporting results in 1930, 1936 and 1947. He was particularly interested in its use in cleft palate cases in which previous surgery had been unsuccessful. With Kathryn Stephenson in a 1948 book, Padgett stated:

When the base is downward, one can get very little length to the flap. Therefore, we have used the flap with the base upward near the adenoid tissue and somewhat wider and longer than shown by Rosenthal.

In reference to maintaining the palatopharyngeal synechia, Padgett explained:

Ordinarily, the pedicle is left attached for a variable period of time and then cut. But in 3 instances, after the pedicle has been severed, the patients requested reattachments as speech seemed better with the pedicle attached. . . . Although it may not be physiologically the ideal procedure, it





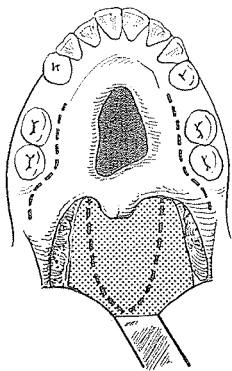
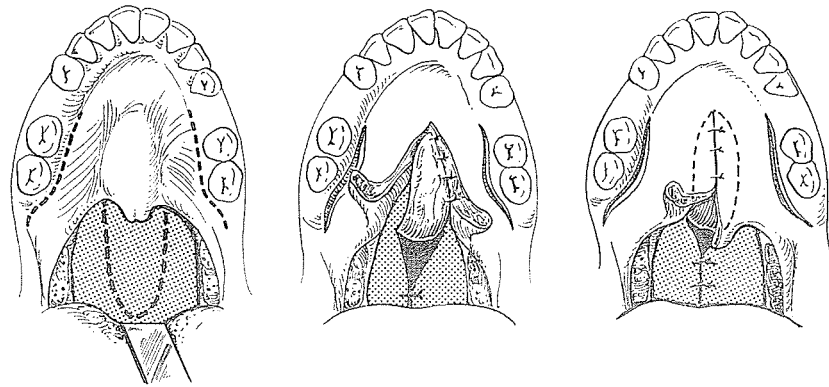
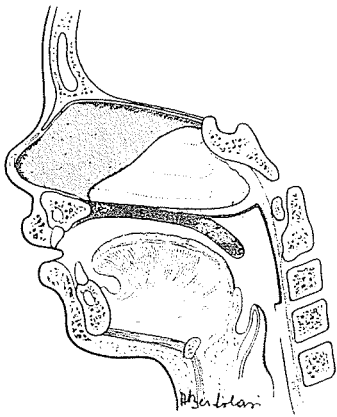
Gustavo Sanvenero-Rosselli

will allow one to close a very large defect of the soft palate with surprisingly good functional result.

Sanvenero-Rosselli

As early as 1935, Gustavo Sanvenero-Rosselli of Milan, Italy, suggested that a superiorly based pharyngeal flap be used with a Veau palate closure. This type of pharyngeal flap has become popular over the years, and 30 years after his original proposal, Sanvenero-Rosselli, at the Second Hamburg Symposium, reiterated his confidence in the superiorly based flap:

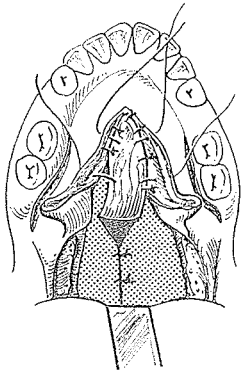
The backward and upper attraction of the velum that we obtain with the superiorly based flap is more similar to the attitude the latter assumes in normal speech conditions: the extreme portion of the soft palate remains free and mobile, the narrowing of the undue space between palate and pharynx occurs at the right level, and at the same time, also, the upper nasal resonating cavity becomes narrower.



As he said in Hamburg in 1964:

A diligent utilization of the remaining tissue, integrated with a pharyngeal flap of maximal size, offers a possibility of repair.

He diagramed his use of a superiorly based flap to close a large anterior palate fistula.



During a visit with Sanvenero-Rosselli in Milan in 1948, I was impressed with his sophistication in the handling of flaps in the operating room. Like Gillies, he was a flap man, which predilection probably explained his infatuation for pharyngeal flaps. He had great vivacity even in his later years, and when the announcement came that the Fourth International Congress of Plastic Surgery was to be held in Rome, he sprang to his feet and

screamed at the top of his voice to the entire assembly, "Vive la Deuchia!" As David Matthews wrote of him in 1974:

Sanvenero will be remembered for the warmth of his personality, his courtesy, his impeccable good manners, his immaculate dress, his charm and his enthusiasm. It can truly be said that he was surgically an aristocrat to his fingertips.

Moran

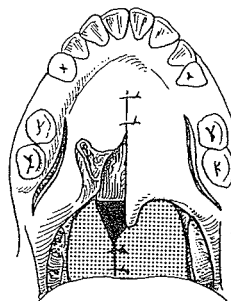
The dapper, fiery Pete Moran, surgeon to the Washington Redskins football team, in 1948 presented cleft cases using a superiorly based pharyngeal flap, which in 1951 he reported had been found beneficial also in the congenitally short palate and the paralyzed palate.

About this time a plastic surgical meeting was being held in Washington, D.C., and Pete Moran invited a group of his friends to make rounds with him to see his favorite cases. Without Moran's knowledge, his friends got together and decided to pull his leg. To add to the pomp and ceremony, Moran, a devout Catholic, had arranged that the hospital's Mother Superior be in attendance. Rounds started and Moran showed one of his remarkable temporal decompressions for exophthalmos. The surgeons accepted the case quietly with, "We have all seen these before, Pete. What else do you have?" Moran took the group by the animal lab and showed them a dog with a skin tube pedicle attached to the canine's heart in an attempt to increase the vascularity of the myocardium. The surgeons' nonchalance was expressed with: "We've seen this before." Moran's face began to show a tinge of purple but he led the way to the next patient with a partially paralyzed palate who spoke remarkably well with the aid of a superiorly-based pharyngeal flap. He received the same: "But we all have seen this before many times, Pete." Whereupon Moran reached over and pinched the right reverend backside of the Mother Superior with "Ever seen anything like this before?"


He was requested officially to leave the hospital and, as had happened before, he ordered a fleet of ambulances and evacuated his patients to another hospital until all ruffled feathers had been settled.

In 1951 Fred Dunn of New York wrote:

From my experience, the pharyngeal flap operation described by Dr. Moran is the most important surgical contribution thus far presented in aiding speech in those cleft patients who have had their palates closed and still do not speak well.



Pete Moran



Richard Webster

Maverick Richard C. Webster of Brookline, Massachusetts, had an important impact on American cleft palate surgery and on pharyngeal flaps. In the middle 50's he was active in getting plastic surgeons involved in the American Association of Cleft Palate Rehabilitation, then primarily orthodontists, otolaryngologists, prosthodontists and speech pathologists. The group became known as the American Cleft Palate Association, started the *Cleft Palate Journal* and elected Webster their president for 1962–1963. Excerpts from his reminiscences in 1976 are pertinent:

I am almost certain that it was in 1951 that I first was impressed by the pharyngeal flap procedure. Pete Moran presented material on this operation in the amphitheater at the Massachusetts General Hospital. He had 4 or 5 tape recorders and tapes demonstrating speech of patients before and after pharyngeal flap operations. Picture the scene: he has just finished telling how good the operation is and now he will show the speech results. He turns the first machine on, there is a puff of smoke and a smell of fused wires, his face gets redder than usual, he apologizes, and punches the "on" button of the second machine. Again, a crackling noise, some purple flashes, some smoke and plenty of ozone. His face gets redder; his temporal vessels begin to pulse. We hear some pungent Moranisms and he pushes the "on" button of No. 3. More of the same. The audience is mumbling, embarrassed, and some are beginning to laugh. I'm racing down the steps, trying to keep him from getting at the last machine, because I know that the amphitheater has DC current and that his tape players must be for AC current only. Just before his hand hits button No. 4, I grab his wrist and physically interpose myself between Moran and the last machine. His temporal vessels are pounding so severely that he is about to have a stroke. I explain the archaic wiring of the "old" Massachusetts General Hospital, that I have a converter, and that I will be happy to go get it. By the time I get back with it unfortunately there is no audience left. However, Dr. Moran and I listened to every tape and I heard speech results that, although not perfect, were definitely better than my push-back procedures were giving me. Pete was kind enough to spend the time explaining his operation in detail. He, like the others before him, made narrow flaps and tried to close the pharyngeal donor area.

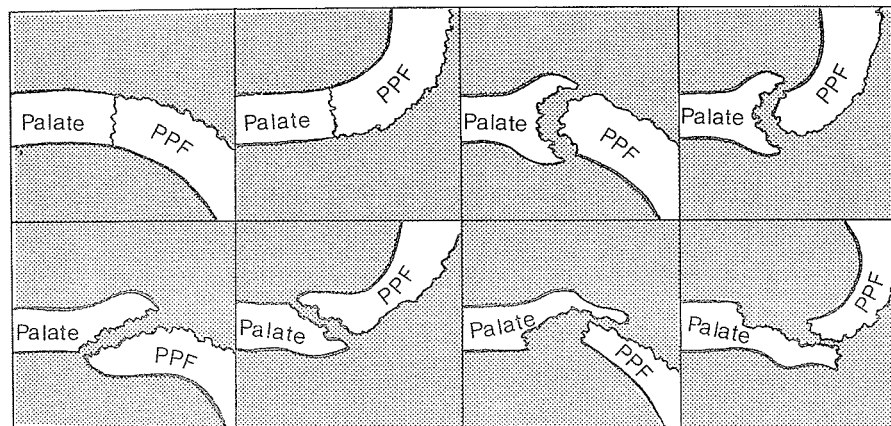
Having done adenoid surgery and pharyngeal tumor work, I reasoned that wide flaps made from salpingo-pharyngeal fold to salpingo-pharyngeal fold would give even more effective velopharyngeal closure and that no attempt should be made to close the donor area, at least in most cases. My first procedure went well surgically, but the child had a cardiac arrest and

expired when coming out of anesthesia. Obviously, plenty of fear was involved in doing the second and the third procedures. However, the results were so impressive that we continued and gradually extended the procedure to other applications.

A wider flap

In 1956 in *Plastic and Reconstructive Surgery* Webster, with R. J. Coffey, J. A. Russell and L. F. Quigley of Brookline, Massachusetts, advocated the widest pharyngeal flaps yet dared and showed little concern for the closure of the secondary defect in the pharynx.

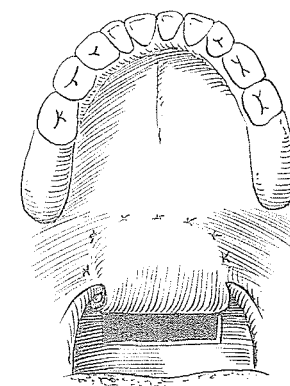
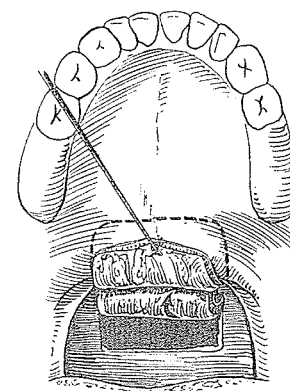
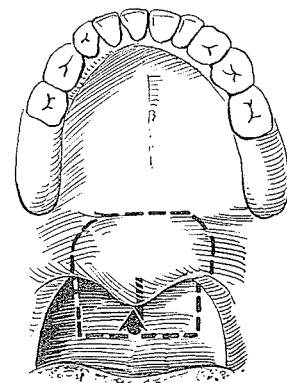
Webster classified various pharyngeal flaps as to their base position, inferior or superior, and their method of attachment to the palate, edge to edge, split border, denuded edge and turnover flap.



Quite apart from wide pharyngeal flaps with no concern for donor area closure, Webster reminded me of his early advocacy of primary pharyngeal flaps for

closure of non-cleft defects, supplementation in palatal paralyses, early primary cleft closure (before Dick Stark, I believe), and in combination with speech and orthodontic appliances, allowing deferral of hard palate cleft closure until later in life.

More than once Webster has proved to be ahead of his time, and some of his pioneering, which formerly met antagonism, has now gained approval. Here is one example in which his vision led him in a direction I feel personally was unfortunate for palate surgery:



It was obvious that much cleft palate care in American was going to be provided through government, and certainly, here in Massachusetts, government dictation was a fact of life. Although I have never found anything more interesting or challenging than the care of the cleft lip and palate patient, knowing my own character or code, I knew that I could not function as a free man with government running the show. That is why I stopped being active in the palate field and became engaged in the surgery and medicine of appearance.

This reminds me of another free spirit, Wardill of Newcastle, who left his homeland and palate surgery because of the threat of governmental intervention. There are many examples of this withdrawal throughout medicine. Eventually, of course, it will take its toll by discouraging people who lead the way from going into medicine in the first place, to the ultimate detriment of the quality and progress of this great field.

Webster indeed started a trend toward wider pharyngeal flaps for more effective closure of the incompetent velopharyngeal aperture. As with most fads, the pendulum swings too far. Some thought it was impossible to make a pharyngeal flap too wide. However, in 1964 Stuteville and Bzoch found hyponasality in 15 out of 40 patients with wide superiorly based secondary flaps. This caused Weisman to state:

It would seem reasonable to vary the width of the flap in proportion to the shortage of tissue, favoring a narrow flap when possible. For young children our flaps were 8 to 13 mm wide, 15 to 22 mm in length.

In 1977 Ken Bzoch of the University of Florida re-emphasized the danger of the broad flap:

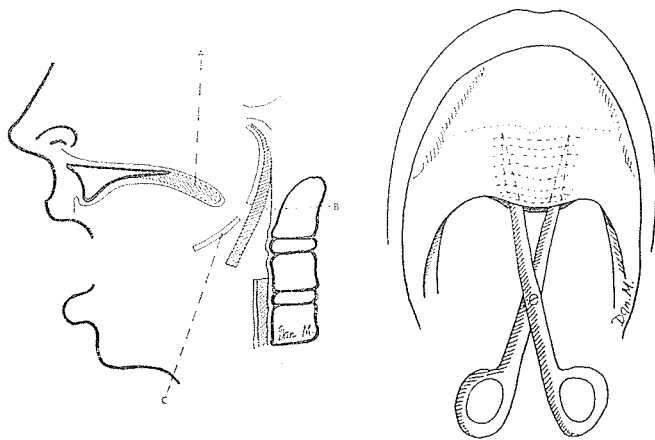
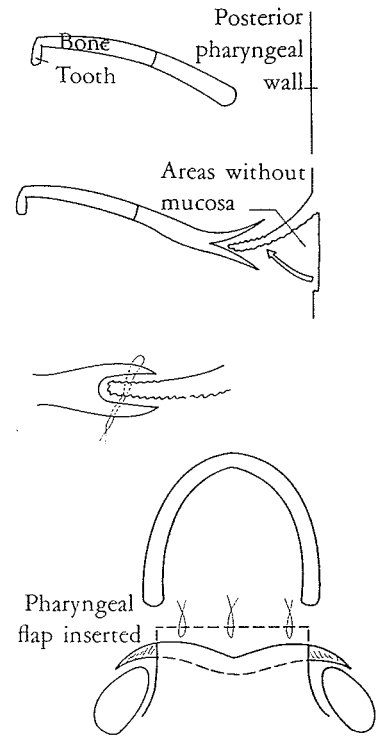
I am concerned about one of the regular sequelae of broad, obturating pharyngeal flaps used either as primary or secondary surgical methods. Sequelae regularly include mouth breathing. This has an adverse effect upon the muscle tone of the facial muscles and on the direction of growth of the jaws. The "adenoid facies" which results may present a greater handicap to orthodontic and facial appearance correction than any other post-surgical sequelae from palatal closure techniques. Recent observations of the Chase Type Push Back with incorporated pharyngeal flap appear much less frequently to lead to mouth breathing sequelae.

Fishtail attachment

In 1977 Dennis Walker of Johannesburg began using a variation in the attachment of the pharyngeal flap to the velum, slightly reminiscent of one of Webster's designs. He described his modification:

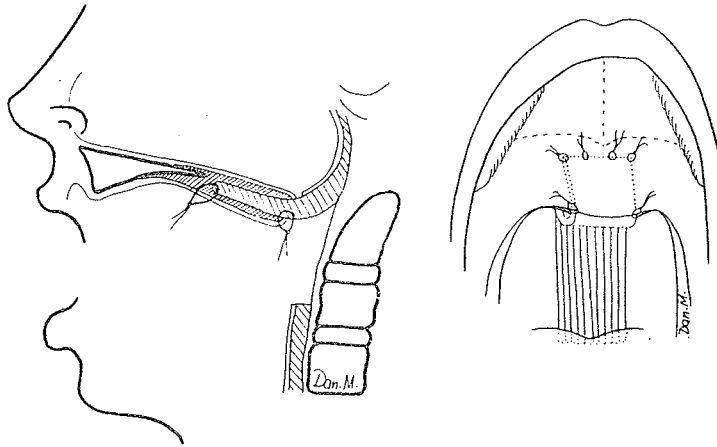
An additional manoeuvre I have started to use removes a strip of mucosa from the pharyngeal surface of the flap and inserts the double raw edge thus produced, into a slit, somewhat like a fishtail, opening right across the free back edge of the soft palate, following a curve from the tonsillar fossa and across the uvula to the other side. The raw part of the flap is then inserted and sutured as shown. The edges can be reinforced with one or two simple sutures. This procedure helps to give a bigger area of union.

In 1978 in the *British Journal of Plastic Surgery* Dan Mahler and Yoram Levy of Ben Gurion University Medical School of Negev Beer-Sheva, Israel, presented a similar method for attachment of a superiorly based pharyngeal flap. It had been used successfully without dehiscence in eight patients 4 to 7 years of age. A standard flap is elevated, held by two long sutures at its distal corners and infiltrated with saline while the distal mucosa is



de-epithelialized with delicate curved sharp scissors, leaving enough dermis to protect the vascularity. With the same scissors the posterior edge of the soft palate is split, developing a pocket between the oral and nasal layers. Into this pocket the denuded pharyngeal flap is guided and fixed with four long 4-0 silk sutures

tied on the oral side. The distal end of the flap should be close to the posterior edge of the hard palate. The edges of the distal velum are sutured to the mucosa of the sides of the pharyngeal flap.




Middle third nasal turnback flap

In 1963 at the Third International Congress in Washington, D.C., Harry M. Blackfield, with J. Q. Owsley, E. R. Miller and L. I. Lawson of San Francisco, presented their modification of the superiorly based pharyngeal flap. After study of normal velopharyngeal action as well as function in palates with pharyngeal flaps attached, using cinefluorography with a synchronous sound track, they altered their flap design. They split the soft palate for exposure and sutured a wide, superiorly based flap into the middle third of the nasal aspect of the soft palate after this area had been denuded by reflecting mucosal flaps backward off the soft palate. The turnback flaps were used to cover the raw undersurface of the pharyngeal flap. They concluded:

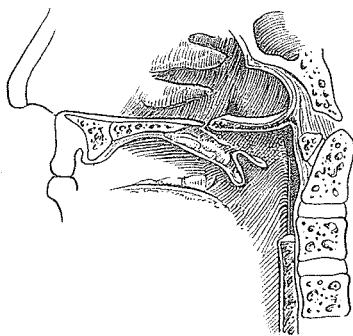
It is hoped that higher attachment of the pharyngeal flap with its undersurface lined with mucosal flaps from the palate will reduce the shrinkage of the flaps and will provide a more normal velopharyngeal closure, by aiding the palatal excursion in a more physiologic way.

Velar split exposure


Wallace H. J. Chang of the University of Massachusetts, Worcester, was described by his former chief Willie White as, the only Oriental I know with a Southern accent.



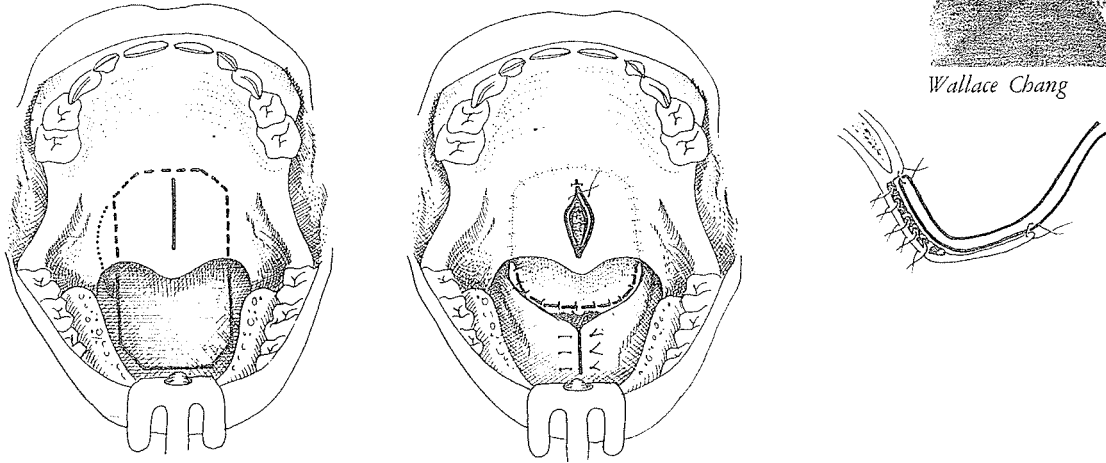
Harry Blackfield



In 1978 Chang suggested the use of a partial midline split of the velum for exposure. An incision through the oral mucosa and muscle, extending from the posterior edge of the hard palate to a point 2–3 mm. proximal to the base of the uvula, enables dissection of a distally-based nasal mucosal flap from the superior surface of the velum to create a recipient attachment site for a superiorly-based pharyngeal flap and to supply cover for the raw undersurface. Chang cites these advantages:



Wallace Chang



This technique allows (1) increased facility in dissection and (2) precision in the design of the flap for lateral port control. The procedure obviates an extra suture line in the lining flap, as is necessary in the standard *complete* palatal split technique.

The longest flap

Johanson is a virile Viking not particularly known for his surgical timidity. In 1958 he savored a triumph when he ventured all the way down the pharynx to the larynx for a pharyngeal flap which, based above, could reach forward to the alveolar cleft.

At the Second Hamburg Symposium he elaborated:

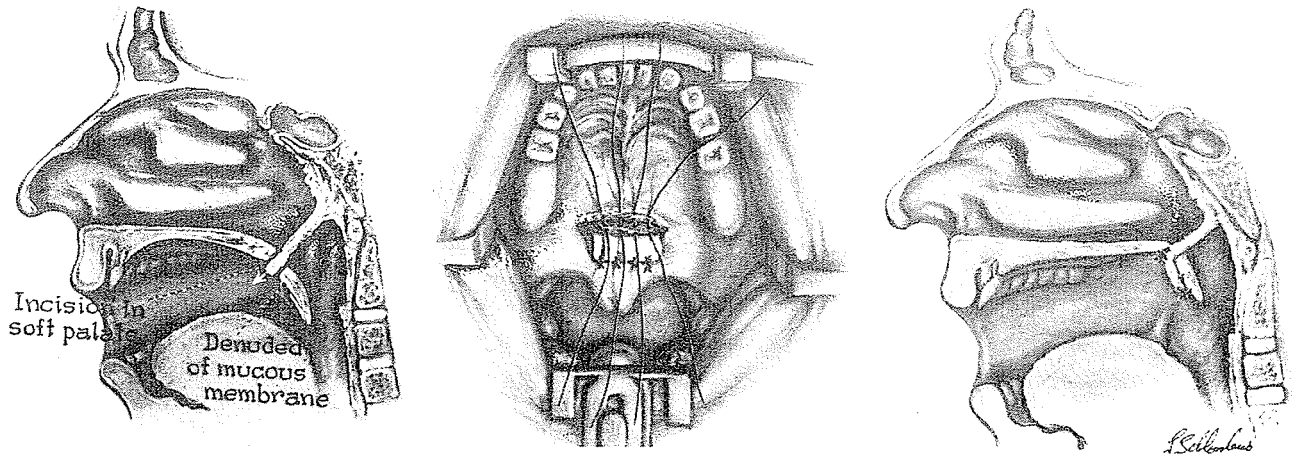
The use of posterior pharyngeal wall supplies us with very suitable tissue, bringing into the palate not only mucous membrane but also muscle tissue. . . . For that reason we raise a flap which is so long that it can reach the terminal end of the palate, just posteriorly to the incisors. We do this by pharyngotomy, and we free the larynx and go in through a lateral incision and raise the flap about 3 to 4 cm. From this approach, we close the pharyngeal wall carefully with stitches, put a stitch in the top and bring it

out through the mouth, and then perform the rest of the operation by the oral approach. You get in this way a very beautiful and well-supplied flap which is long enough to cover every defect in the palate. . . . There is enough material in the mucoperiosteal tissue to bring down to cover the oral defect. If not, then you can let the flap go up . . . and over the margin to the nasal side. . . . We always try to cover the defect in the hard palate with a bone graft so we need a lot of tissue. . . . I believe you should suture the soft palate in front over the raw base of the flap to avoid scarring of the base.

Superior suspensory flap

Milton Edgerton, in *Plastic and Reconstructive Surgery* in 1965, advocated the suspensory pharyngeal flap as an adjunct in correction of velopharyngeal incompetence. He justified this type of flap attachment with:

It has often been noted that elevation of a prosthetic speech bulb to a higher level in the nasopharynx will usually improve voice quality. Similarly, the use of a *superior* pedicle with a pharyngeal flap seems to aid speech in some patients more than an inferior pedicle.



Speech analyst W. Hardy pointed out that mobility and elevation of the soft palate normally play a major role in the formation of the diphthongs (speech sounds that change from one vowel to another on the same syllable). Thus Edgerton reasoned that in secondary cleft palates with speech problems involving a conspicuous merging of diphthongs (*cow, about, vacation*), the need exists for more elevation of the soft palate.

The suspensory pharyngeal flap is based high superiorly, includes muscle and is 3 cm. wide. It is brought through a horizontal slit on the dome of the soft palate and attached by bending its tip back 90 degrees and suturing it to a superficially denuded area on the oral surface of the soft palate.

Edgerton suggests that the muscle in the flap may lift the palate but admits:

This lifting is not consistently present and usually is seen only as a 2- to 3-mm. dimpling of the palate on swallowing.

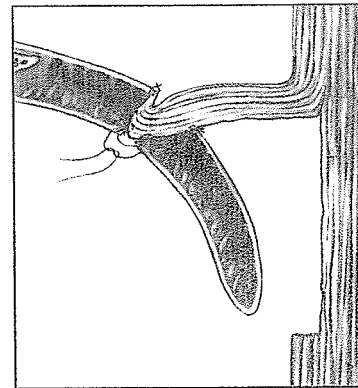
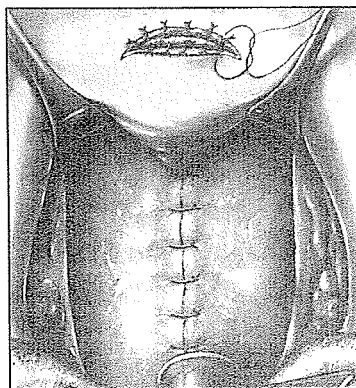
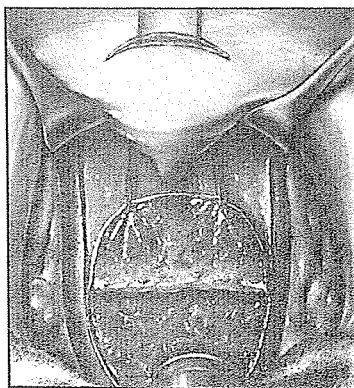
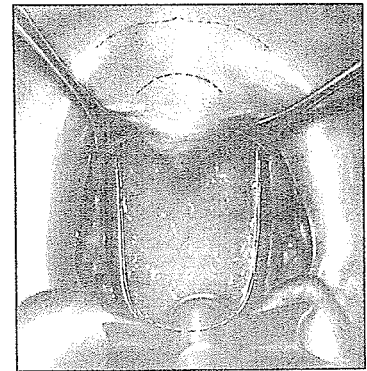
He concluded:

At the present time this operation is suggested as of possible value in patients with long, immobile or paralyzed palates who are having difficulty with production of diphthongs in speech.

Anteriorly superiorly based flaps

In 1974 in the *Cleft Palate Journal* R. Massengill and N. Georgiade of Duke University proposed an anteriorly superiorly based pharyngeal flap. The design of the flap has its base at a superior level, wider than the tip and containing mucosa, fascia and muscle. A transverse curved incision 3 to 4 cm. in length is made through the soft palate, 1 cm. posterior to the hard palate. The tip of a pharyngeal flap is folded as a knuckle and drawn to the incision for attachment to the soft palate.


unlikely, as there is no innervation and muscle fibers lie in wrong direction



This procedure was carried out on 18 patients varying in age from 4 to 39 years. The results were compared with 17 standard superiorly based pharyngeal flaps and 5 inferiorly based flaps.

The authors reported:

Cinefluorographic analysis dealing with velum movement showed that the anteriorly-superiorly based group as a whole had more movement than the control group. When the oral and nasal sound pressure recordings were compared for the two groups the anteriorly-superiorly based group as previously discussed had consistently better type readings.

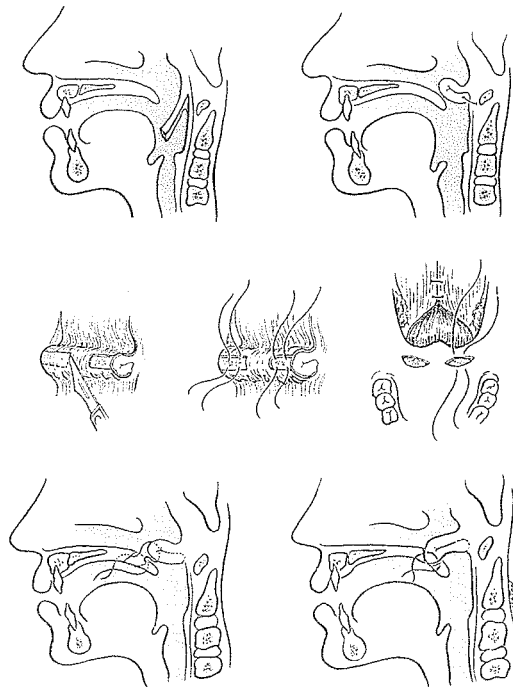


Nobuhiko Isshiki

Lining the superior flap

Nobuhiko Isshiki and Masanori Morimoto of Kyoto University School of Medicine, Japan, in 1975 modified the method of lining the superiorly based flap and the method of forming its superior suspensory attachment. They folded the pharyngeal flap to minimize the postoperative scar contracture and shrinkage during the healing phase. A superiorly based flap was elevated from the posterior pharyngeal wall and folded on itself with the mucosa outside. The flap-velum connection was made through raw surfaces produced by denuding both lateral areas of the ridge fold of the flap.

The flap-velum attachment is a little complicated. The lateral portions on each side of the ridged fold of the flap were denuded to present raw areas. Two corresponding penetrating incisions on the sides of the soft palate were made. Then, with mattress sutures passing from the velum to the pharyngeal fold and back,



the knuckle of the flap was pulled into the nasal side of the soft palate until tethered by healing.

Isshiki, who received the Gould Award for laryngeal research and the Cultural Prize of the Kyoto *Shimbun* newspaper for clinical cleft lip and palate work, evidently accepts few boundaries. Admitting no special personal abilities in ESP and only a purely scientific approach to its understanding, he stated:


I do not find it surprising that there may be phenomena such as these which are inexplicable by our present understanding of the physical universe.

Lateral pharyngeal port

As Dorrance noted, Schmidt determined by experiments that speech could remain normal while there was a rubber tube with a lumen of 6 mm. between the velum and the pharyngeal wall, but when a tube of a larger lumen was inserted, speech became nasal. He concluded that the superior constrictor muscle of the pharynx was capable of overcoming a certain amount of insufficiency which, if increased beyond 6 mm., could not be controlled by this muscle.

Michael Hogan of the New York University Medical Center, first in 1971 and then in more detail in the *Cleft Palate Journal* in 1973, presented his *lateral port control* (L.P.C.) pharyngeal flap. Under the premises that velopharyngeal incompetence or inadequacy is the primary cause of cleft palate speech and that the velopharyngeal sphincter becomes incompetent when, after maximum contraction during connected speech, the residual nasopharyngeal orifice or port remains too large for normal speech production, Hogan turned to the literature for a gauge on the size limit of the port.

D. W. Warren, in 1964 and 1966, analyzing aerodynamic pressure-flow patterns of consonant production in normal speech, concluded that oropharyngeal air pressure began to diminish rapidly when the velopharyngeal port exceeded 10 mm.² and that nasal escape of air was clearly evident at 20 mm.² N. Isshiki, I. Honjow and M. Morimoto, in 1968, utilizing acoustical as well as aerodynamic techniques, found a port size of 5 mm. in diameter to be the approximate threshold for occurrence of hypernasality. L. Bjork, in 1961, utilizing basal radiographic tech-



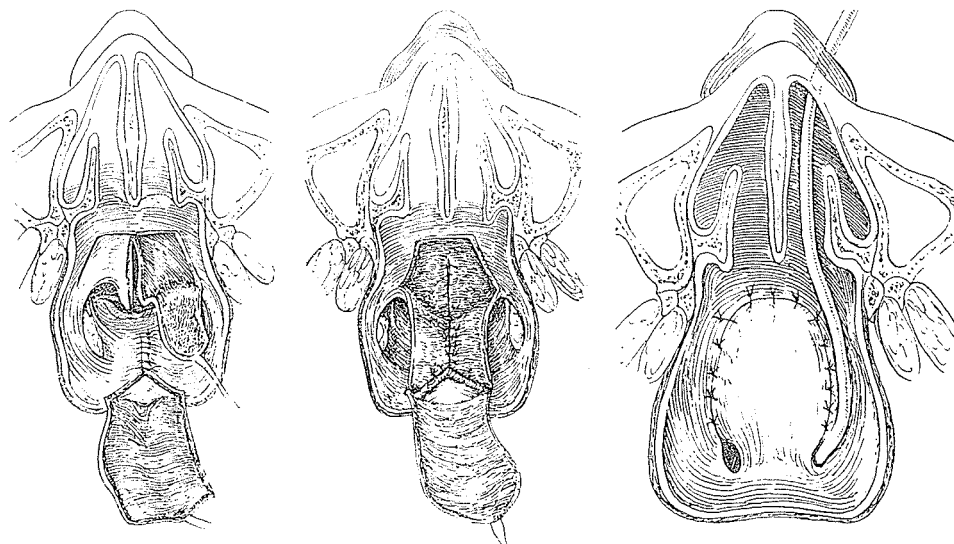
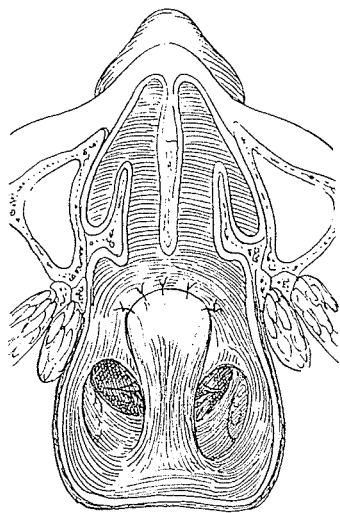
Michael Hogan

niques, estimated that incompetence occurs with a port size of 20 mm.² in area. Hogan concluded:

Thus if the velopharyngeal port is greater than 20 mm² in area during connected speech, hypernasality and nasal escape will tend to be present. The 20 mm² area thus appears to represent the threshold of velopharyngeal incompetence.

Hogan's goal was to design an operation to construct the velopharyngeal port size during connected speech below 20 mm.² in area. Success in this endeavor would give a competent sphincter, eliminating direct defect in cleft palate speech of hypernasality and nasal escape, and permit the patient and the speech therapist to eliminate the indirect speech maladjustment—pharyngeal fricatives, glottal stops, poor tongue positioning and nasal grimacing.

Hogan decided to change the standard superiorly based lined pharyngeal flap which was being used in conjunction with Veau-Wardill-Kilner palate pushback. This flap was giving the New York University surgeons 60 percent excellent results, 20 percent improvement and 20 percent no improvement. He explained that in the standard flap, if unlined or too narrow, the lateral ports became too large on account of shrinkage, as shown.



In his design of the lateral port control operation,

The lateral margins of the [wide] pharyngeal flap are sutured to the superior portion of the soft palate, laterally to the lateral pharyngeal wall almost

completely to the base of the pharyngeal flap. Port size is controlled by a measured catheter with an external diameter of 4 mm and thus positive control is exerted over the size of the port for the first time.

This series of drawings from Hogan's 1973 L.P.C. paper shows a wide, superiorly based pharyngeal flap being lined by nasal mucosal flaps from the soft palate, as the lateral ports are reduced around a 4 mm. catheter. It produced, he reported, a total port size of about 25 mm.² in area (12.5 mm.² + 12.5 mm.²), counting on mesial movement of the lateral pharyngeal walls to obliterate the residual space. He claimed restoration of competence to the velopharyngeal mechanism in 97 percent of 93 patients with a mean age of 16 years. Aerodynamic measurements of the 91 successfully treated patients showed an average velopharyngeal patency during speech of 5.8 mm.² As would be expected, hyponasality was noted, but surprisingly, Hogan remarked:

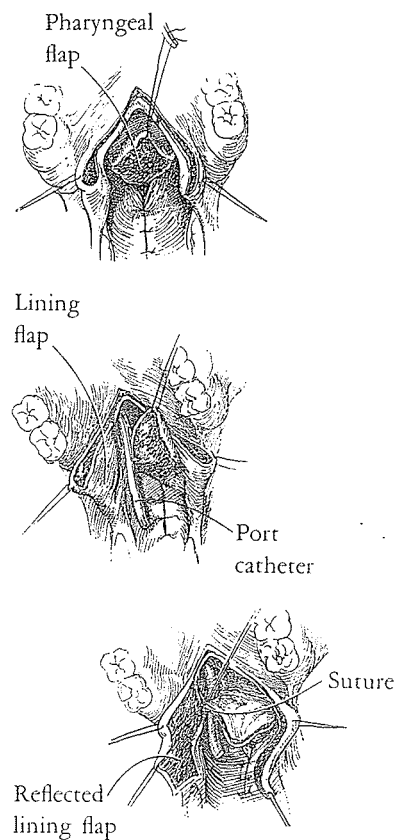
Persistent hyponasality (lasting more than 6 months) was found in 3 cases. Hyponasality lasting longer than a year called for surgical correction. A catheter passed intranasally presented the pressure area of its tip intraorally to define the obliterated lateral port. Incision through this area allows the catheter to pass into the oropharynx and the catheter is left for 5 to 7 days, to allow epithelialization to insure permanent patency.

By 1976, Hogan reported:

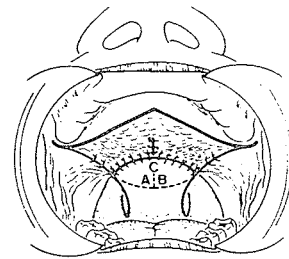
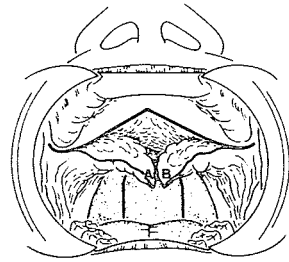
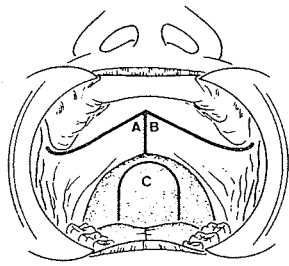
The complications of the lateral port control procedure may include persistent hyponasality, absence of nasal respiration, snoring and excess mucus production. . . . When absent nasal respiration with concomitant mouth breathing persists for a period greater than 1 year in the growing child, consideration is given to reopening the ports. . . . One should be cautious in reestablishing the patency of the port in the growing child, as very often, with growth, patency will be established over a period of several years as the naso- and oropharynx expand in size. The only indication for operating sooner is when the patient and parent find the existing situation intolerable.

However, in the adult, when hyponasality persists for a year . . . the lateral ports should be established by the catheter technique.

Reed Dingman's comment in the 1975 *Year Book* is interesting:



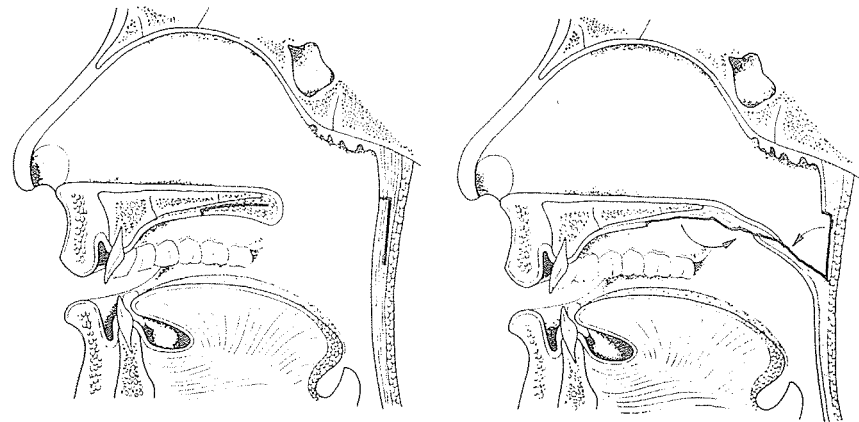
A 97% success rate of establishment of velopharyngeal sphincter competency by lateral port control in patients with a mean age of 16 years is highly significant.



Perko

Creating an obturator of scar with a controlled port

For the severely scarred, shrunken, shortened, non-mobile soft palate, Herfert in 1955 recommended turning a fold-back flap from the middle of the soft palate for an attachment to a pharyngeal flap. According to Perko, this left the lateral ports too large. In the 1973 *Journal of Maxillofacial Surgery*, Milivoj Perko of Zurich extended the fold-back principle across the entire width of the palate as two flaps A and B turned from the oral side of both the hard and soft palate. A wide, inferiorly based pharyngeal flap C was lifted to overlap part of flaps A and B to create a bridge of scarred tissue with remaining raw areas. It was a means of producing a non-dynamic obturator to fill partially the velopharyngeal aperture. Perko noted that this enabled him to fulfill Trauner's 1973 challenge that the lateral ports should be 3 mm.



Design of flap width by logic

In 1967 H. L. Morris and D. C. Spriestersbach of the University of Iowa reported on the pharyngeal flap as a speech mechanism. Speakers with successful pharyngeal flaps, they said, revealed either mesial movement of the lateral pharyngeal walls or superoposterior movement of the palatal flap structure, with the mesial movement of the lateral pharyngeal walls the better predictor of pharyngeal flap success.

Thus it is logical to cut the pharyngeal flap the width necessary to fit between and touch the medial excursion of the lateral pharyngeal walls. This is the plan designed by Donnell F. Johns and Kenneth E. Salyer of the University of Texas Southwestern Medical School, Dallas. Under topical anesthesia, the medial excursion of the lateral pharyngeal walls is marked with methylene blue on the posterior pharyngeal wall. Then, under general anesthesia, incisions along these marks fashion a flap of exact dimension based superiorly above the tubercle of the atlas to fill the sphincter gap.

Evaluation of flap attachment

In 1977 Michael Lewin, A. Daniller, C. Croft, and R. J. Shprintzen of Montefiore Hospital, the Bronx, compared three methods of insertion of superiorly based pharyngeal flaps of similar width:

The methods of insertion were: (1) midline splitting of the velum with levator retroposition and insertion of the PF into the midline split, (2) horizontal splitting of the velum along its posterior edge with insertion of the PF "sandwich" style; (3) Dorrance pushback combined with PF. Over 100 patients were examined at least 6 months postoperatively with multi-view videofluoroscopy and nasopharyngoscopy. . . . The sandwich method resulted in maximum obturation, the Dorrance with the least. The midline split method resulted in moderately wide PF.

TIMING THE PHARYNGEAL FLAP

At the Association meeting in Chicago in 1977, the Lancaster group of Harding, Mazaheri and Krogman, using the standard lip (3 months) and palate (18 months) closure, reported a 20 percent velopharyngeal incompetence rate. A retrospective study to see whether the failure cases could be predicted revealed that prior to three years, there were no significant morphological differences among the various cleft groups. In the cleft-palate-only group the velum was longer two years postoperatively, but between three and six years, measurable differences in length of the velum were consistent with velopharyngeal incompetence. Since speech improves as a function of maturation between ages 3 and 6, Harding and his colleagues advocated a superiorly based pharyn-

geal flap at a mean age of 6.5 years (definite V.I. at 3 to 4 years), with over 90 percent of all patients achieving acceptable speech.

Randall rose to take issue with this timing, referring to Ralph Hamilton's law: *Do a pharyngeal flap the year after you should have done it.* He advocated a pharyngeal flap at age 2 to 5 years, favoring early operation if incompetence is severe, and later surgery if it is borderline.

A HITCHING POST OF LAST RESORT

Attachment of the palate to the pharynx is not natural or nature would have prearranged for this mechanism long before surgeons found their way to the palate. Yet time and experience have shown that the pharyngeal flap does work to advantage in many cases. The combination of reducing the size of the nasopharyngeal vault, obturating some of the velopharyngeal space with the actual flap and either dragging the palate back or holding it in its "pushback" position contributes toward its success. Beware of obstructing the nasal airflow as can happen with very wide pharyngeal flaps. Not only does this unphysiological condition cause destructive changes in the nasal mucosa and decrease lung function, but it can be responsible for hyponasality in speech, which may be more objectionable than mild hypernasality.