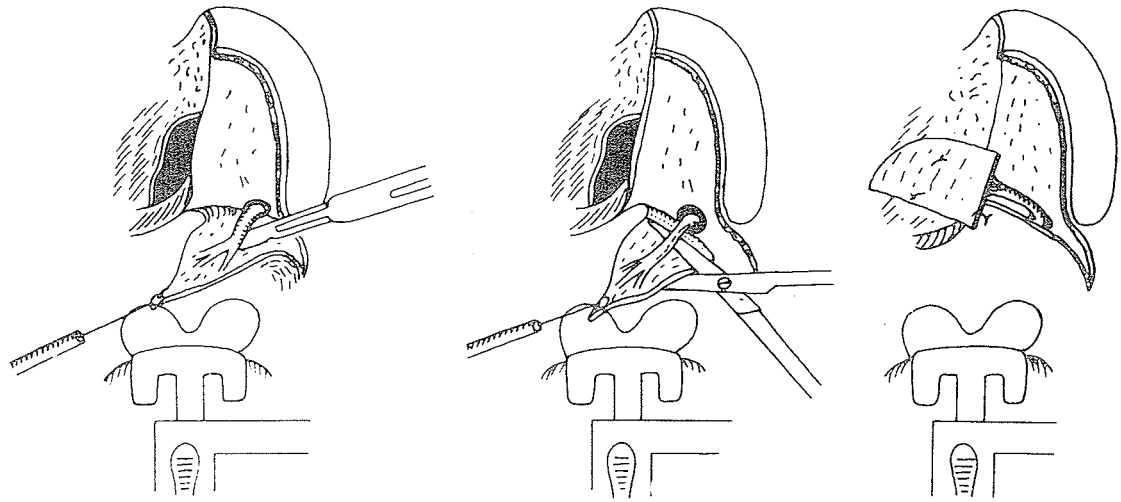


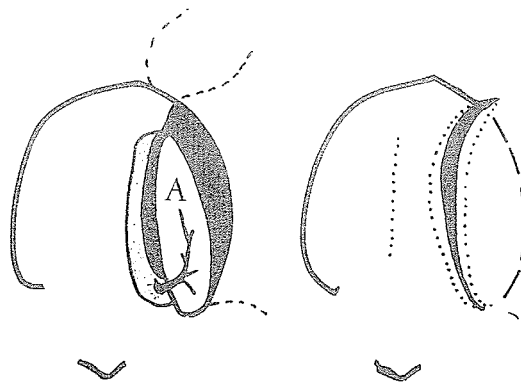
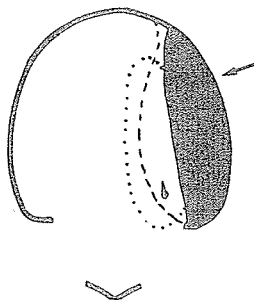
34. Use of the Palatal Island Flap for Ablative and Other Defects

THE principle of the island flap makes available large areas of mucoperiosteum supplied by a neurovascular bundle which can reach the distance of its pedicle a 360-degree area around the particular posterior palatine foramen. The donor area is backed by bone and, after full growth of the maxilla, will heal quickly without deformity. Thus the island flap is an epithelium-covered, independent, durable, maneuverable unit with many possible uses. In 1963 I predicted that this flap would be useful in soft palate defects following tumor ablation and trauma and in 1966 reported two cases briefly. One was a patient in whom a posterior pharyngeal and tonsillar resection for cancer treated with a skin graft had produced a pocket in the tonsil area that consistently trapped food. After excision of the graft, an island flap was fitted to fill out the pocket without further difficulties. In another case of subtotal soft palate excision, a wide pharyngeal flap based superiorly was covered with a large island flap to achieve partial soft palate reconstruction and improved velopharyngeal closure.

In 1969 Maisels reported a case of partial maxillectomy for squamous cell carcinoma arising on the alveolus which resulted in a bony defect in the nostril floor. At the time of ablation, a mucoperiosteal island flap carried on the contralateral greater palatine vessels was used to repair the defect.

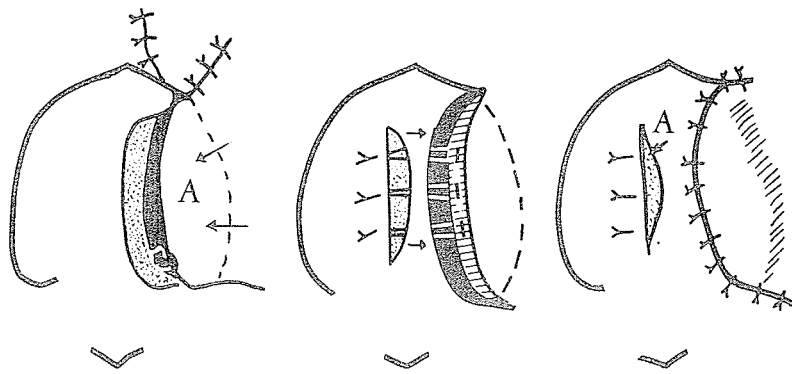


In 1974 in the *British Journal of Oral Surgery* D. Henderson of Glasgow, Scotland, noted that oroantral fistulae following maxillary excision of relatively benign lesions can result in major defects requiring a permanent prosthesis or extensive reconstructive surgery. He designed a two-stage repair utilizing a palatal island flap, noting that at the second stage, reexamination of the operative area to exclude recurrence was possible. He advised against this procedure for cases of malignancy or palatal salivary tumors known to invade bone or bony canals.



Following resection of the lesion, Henderson developed island flap A and, when possible, removed the anterolateral wall of the greater palatine foramen for extra freedom. He inverted the island with the epithelium facing the antrum and advanced buccal mucosa by incisions (broken lines) to cover as much of the island as possible. No attempt was made to advance these flaps to the midline to close the medial fistula. Six months later, the second

stage involved two-layer advancement of both edges with closure of the nasal layer by direct suture. Closure of the oral layer by a longitudinal relaxing incision in the mucoperiosteum parallel to the medial edge of the fistula created a bipedicle bridge flap for advancement to the buccal flap. Other small buccal flaps were suggested, if necessary, for the anterior end of the hole.



Another case was reported of a 12-year-old female requiring a partial maxillectomy for an odontogenic fibromyxoma in 1969. Reconstruction by the two-stage island flap method followed with a partial denture which was still serving well after five years.

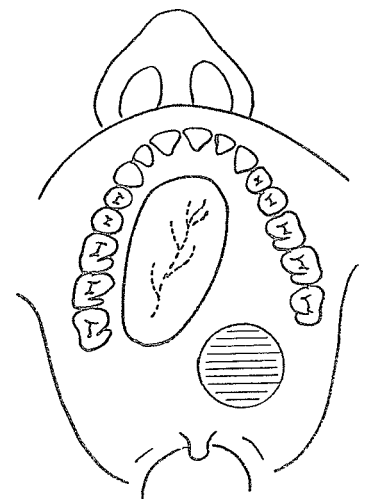
In 1974, in the *British Journal of Oral Surgery*, Philip Worthington of North Wales Hospital noted:

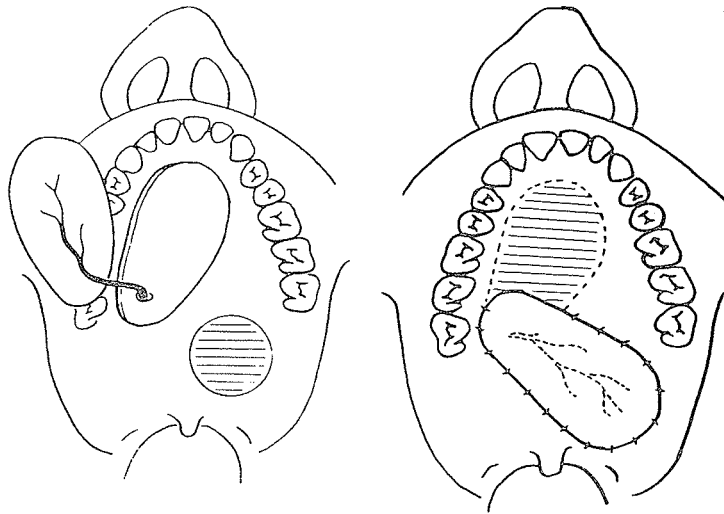
Some 55 percent of intraoral salivary tumours occur in the palate and of these some 55 percent are pleomorphic adenomata, 25-30 percent are muco-epidermoid tumours, 15-25 percent are cylindromata and 5 percent are carcinoma.

It is difficult to assess the limits of the pleomorphic adenomas, and they have a tendency to recur. On this basis it was suggested that a wide resection with fenestration of the palate may be necessary. Repair of the defect in six cases by Worthington involved an unlined oval island flap, based on the neurovascular bundle of the opposite side and transposed over the full-thickness palate fistula. He noted:

This application of the island flap may serve to remind us of its great versatility.

He then admitted, rightly:

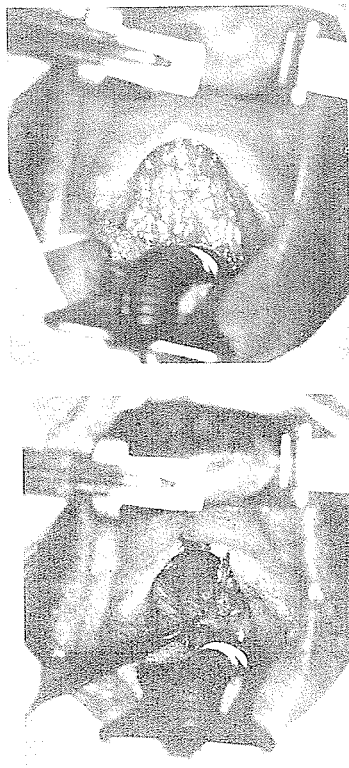




Criticisms of the use of an unlined flap are likely to be directed along the following lines: first, the raw upper surface may be the site of undesirable crusting with an unpleasant odor. Secondly, the flap is likely to contract, causing velopharyngeal incompetence. Thirdly, the flap may fibrose and render the palate relatively immobile, interfering with normal function.

OTHER PERSONAL CASES

Here are four other interesting cases of mine, published in the *British Journal of Plastic Surgery*, in which the island flap has been useful.

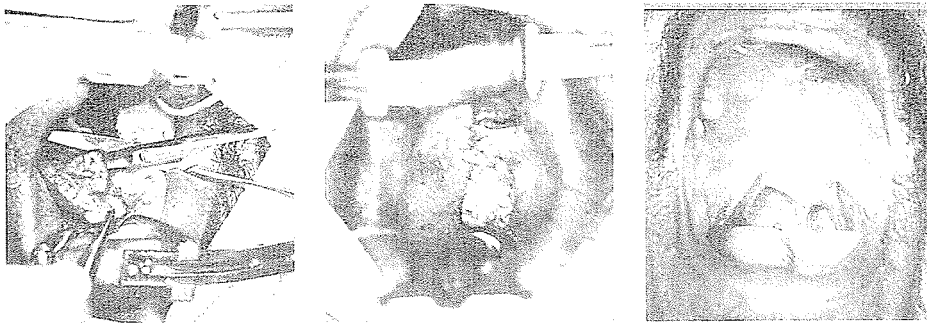
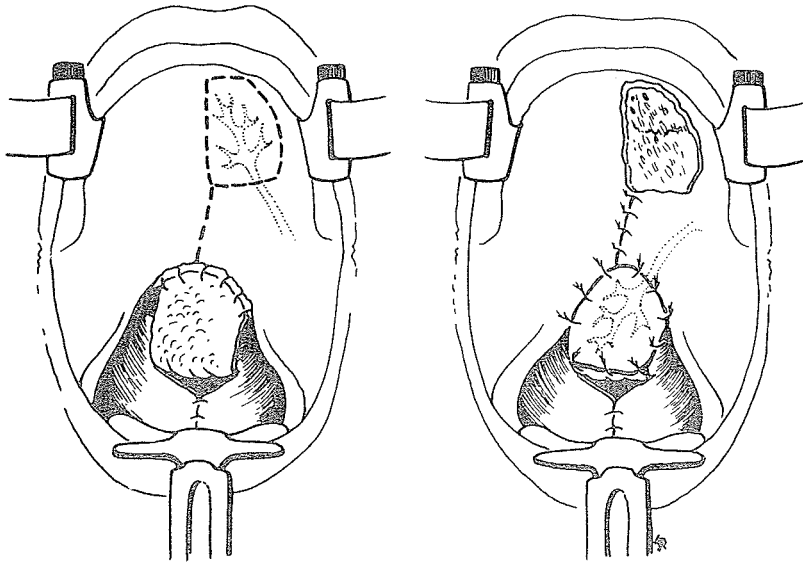


Squamous cell carcinoma

A 46-year-old black male, with a lesion of his soft palate and no evidence of local node involvement, had biopsy which revealed well-differentiated squamous cell carcinoma. Local excision involved resection of the entire soft palate to its junction with the hard palate, including the tonsillar pillars on both sides. After healing, the patient experienced difficulty in taking liquids and soft foods, and his speech was unintelligible.

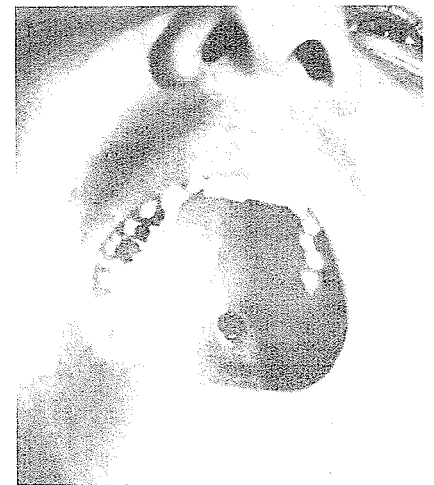
Six months later the reconstructive plan was designed, and resident H. A. Seider turned forward a wide, superiorly based pharyngeal flap and sutured it to the posterior edge of the palate. A mucoperiosteal island flap based on the left neurovascular bundle was lifted off the left hard palate and passed through a mucosal incision, connecting the donor area to the recipient site

to overlap the underbelly of the pharyngeal flap. The reconstruction healed uneventfully, and six weeks later the patient was having no difficulty with liquids or soft food and his speech was near normal and improving.

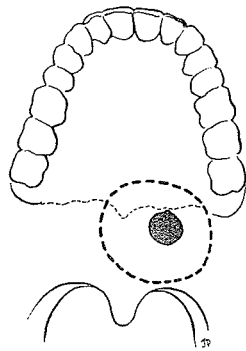


Acinic cell carcinoma

Nasse in 1901 was the first to describe acinic cell tumors, and Buxton in 1953 pointed out that these tumors can run a clinically malignant course with recurrence and metastasis. A rare acinic cell carcinoma of the soft palate in a 35-year-old white male (1) was reported which required radical resection of almost the entire left soft palate (Deutsch) (2). Healing produced a fistula, contractures and velopharyngeal incompetence with a speech-crippling effect not unlike that of an unoperated cleft palate (3). As the patient was a prominent criminal lawyer, his speech defect seriously impaired his performance in court and his livelihood. Reconstruction was mandatory.

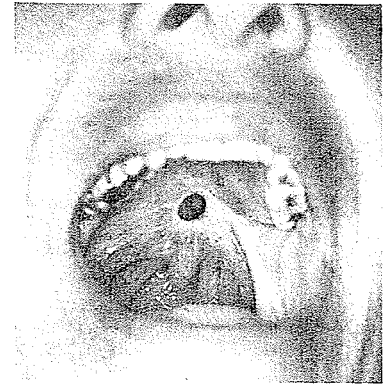


(1)



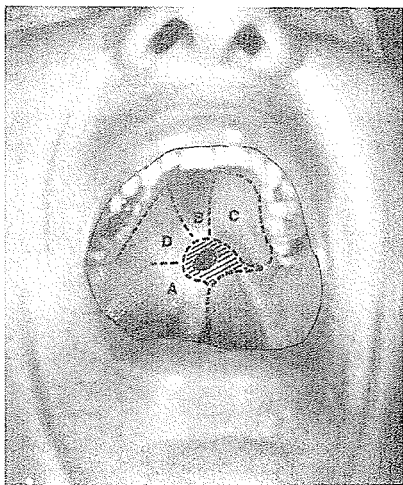
(2)

→ healed →

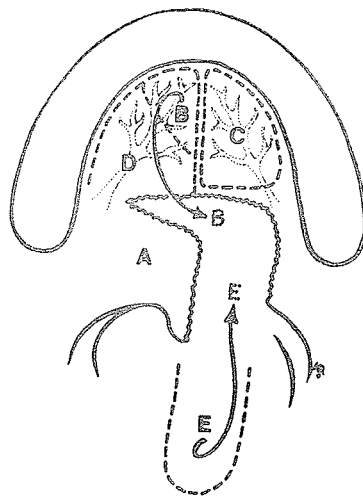


(3)

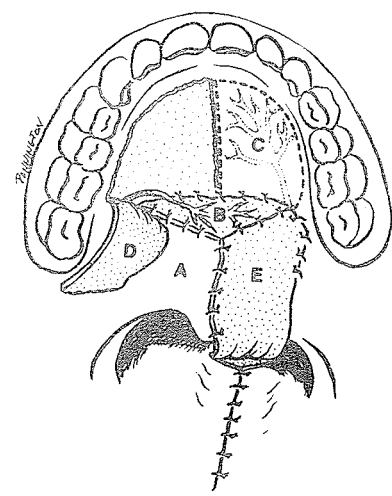
Ten months after ablation, scar excisions and release of contracture repositioned normal tissues (4 and 5). A right mucoperiosteal flap (B) was used to fill the nasal lining defect along the posterior edge of the hard palate. A superiorly based pharyngeal flap (E) was attached to the island flap and to the posterior edge of the palate defect to complete the reconstruction on the nasal side (6). Then a large mucoperiosteal island flap from the left side (C) was swung around for oral cover of the raw underbelly of the pharyngeal flap (7).



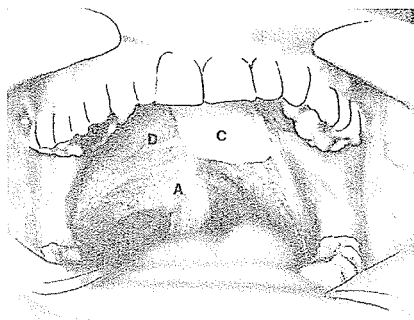
(4)



(5)



(6)



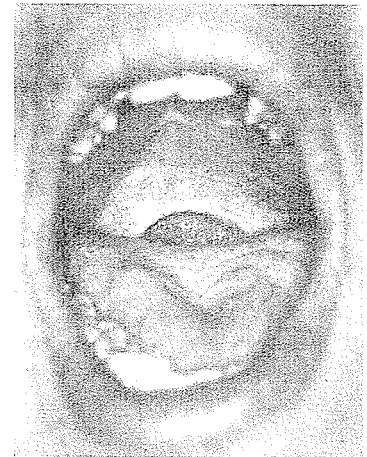
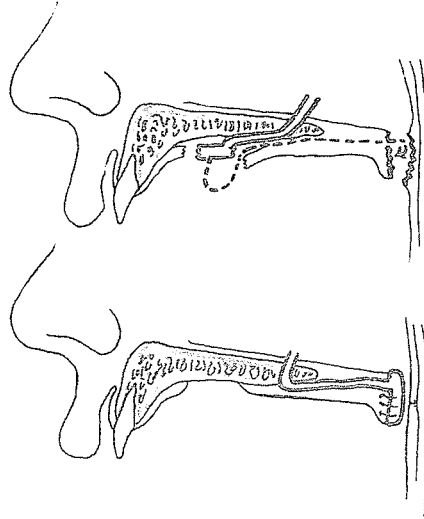
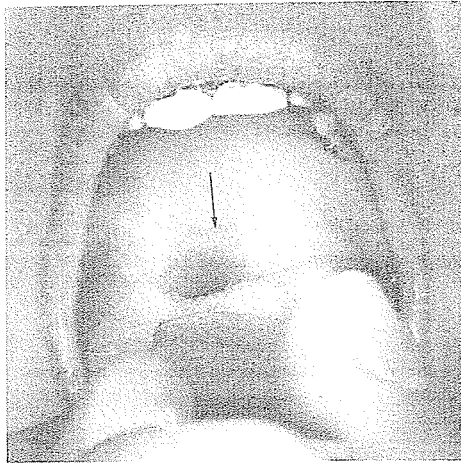
(7)

Speech improvement was almost instantaneous (one week). By one month, because of his effort and study to adjust to the defect prior to reconstruction, the patient felt that his speech was better than before the ablation. It is three years since reconstruction, and all is well.

Stenosis following T & A

A 13-year-old boy, six years after a tonsillectomy and adenoidectomy, presented a complete stenosis of the nasopharynx. One attempt at surgical correction had been unsuccessful.

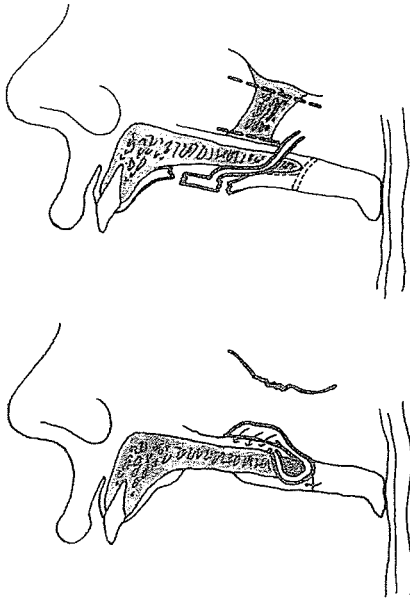
On examination, the entire posterior edge of the soft palate was seen to be plastered with scar to the pharynx, showing a dimpling (arrow) but complete obliteration of the nasal airway. The patient had great difficulty when eating and breathing at the same time.



During surgery, the adhesion between velum and pharynx was divided, leaving large raw areas on the upper surface of the posterior soft palate and on the posterior pharyngeal wall. A flap of lateral pharyngeal mucosa was transposed to close the pharyngeal defect. Then the soft palate was split down the midline, and a left mucoperiosteal island flap was dissected free and passed through to cover the raw superior surface of the posterior soft palate. The velum was resutured, and healing was uneventful. With the nasopharyngeal aperture completely lined, it has remained patent four years with normal speech. The patient can breathe through his nose with mouth closed and eat and breathe simultaneously without difficulty.

Choanal atresia

At the University of the West Indies, Kingston, a 14-year-old Jamaican girl with a choanal atresia was treated by Kenneth McNeill, who cut the palatal mucosa with a through-and-



through incision just back of the posterior edge of the hard palate. This gave exposure so that he could remove the bony obstruction with a chisel and mallet to open the airway from the nose to the pharynx.

The raw tunnel thus created, since it was without lining, was destined soon to close off. A slender right mucoperiosteal island flap was dissected free on its neurovascular bundle. Following ostectomy of the posterior wall of the greater palatine foramen, the island flap was slid along the bottom of the tunnel and sutured in place. This supplied an epithelial strip to maintain a patent nasal airway until complete epithelialization of the tunnel could be achieved similar in principle to the skin strip used by Denis Browne to create a urethra. Recently the patient was examined and revealed patency of the nasal airway with normal breathing eight years after the reconstruction.