

31. *Mending the Misplaced Muscles*

THE importance of muscles in the palate and pharynx was suspected early, but treatment was misdirected. Fear that the pull of the muscles was responsible for the disruption of the postoperative palate caused fiendish operations to be designed to divide normal musculature to relax wound closure.

DIVISION OF MUSCLES

In 1843 Pancoast modified cleft palate closure by advocating division of palatal muscles and the tendons of these muscles through the Dieffenbach type of incision.

A true interest in muscles in cleft palate was not shown until 1844, when Sir William Fergusson outlined an operation founded on anatomical and physiological data. In fact, he took too much interest in dividing these muscles. These were his words:

With a knife whose blade is somewhat like the point of a lancet, the cutting edge being about a quarter of an inch in extent, and flat surface being bent semicircularly, I make an incision about half an inch long, on each side of the posterior nares, a little above and parallel with the palatine flap, and across a line straight downwards from the lower opening of the Eustachian tube, by which I divide the levator palati muscle on both sides, just above its attachment to the palate . . . then, with a pair of long pointed curved scissors, I divide the posterior pillars of the fauces, immediately behind the tonsils, and, if it seems necessary, cut across the anterior pillars, too; the wound in each part being about a quarter of an inch in extent. Lastly, the



Sir William Fergusson

stitches are introduced by means of a curved needle, set in a handle; and, the threads being tied so as to keep the cut edges of the fissure accurately in contact, the operation is completed.

Fergusson admitted:

I have taken no notice of the action of the circumflexus, or *tensor palati*. I am inclined to think that its action is very limited. . . . I, therefore, without further preamble, propose, as an important accessory to the operation of staphylorhaphy, that the surgeon should . . . so conduct his incisions as to destroy all motory power in the soft palate for the time being and thus permit that repose of the stretched velum which is so essential to a happy result; in other words, I advise the division of the *levator palati*, the *palato-pharyngeus*, and the *palato-glossus* muscles.

wow!

Fergusson, repairing hernias in the inguinal region and producing them in the palate, could be dubbed the bad knight of the palate or Sir William the Ripper. He had his favorite thin flat scalpel embellished with a handsome ivory handle, which is on display at the Museum of the Royal College of Surgeons, London. Not only did Fergusson divide muscles, but he inspired others to do the same and more.

In 1846 Liston emphasized the necessity of dividing the tensor palatini muscle. He noted that Fergusson had advised division of the levator palatini and palatopharyngeus muscles with a set of crooked knives. He reasoned:

The union is apt to fail under any circumstances, and I think that this was found to take place in the hands of the above named professor, even after the division of the muscles as he has recommended. . . . If the fleshy belly of the *circumflexus (tensor) palati* could safely be reached and cut, this would . . . put the parts in a still more favourable condition to come together.

Cutting only the tensor muscle possibly was not too damaging, except for its effect on the function of the Eustachian tube. Yet during this muscle-cutting era from 1850 to 1900, a multitude of surgeons devoted much skill and energy to dividing such muscle structures as the tensor palatini, levator palatini, palatopharyngeus, palatoglossus and the anterior and posterior pillars of the fauces. The black list during this 50-year period included other renowned names: Sedillot, Skey, Browne, Pollock, Garretson, Avery, Agnew, Warren, Trélat, Schuh, Collis, Ehrmann, Collender, Michael, Whitehead, Verneuil and Casselberry.

Jonathan Mason Warren of Boston, condemning lateral incisions, advised relief of tension by division of the levator palatini and palatopharyngeus muscles. His speech results were probably dismal, but relief of tension must have been achieved, for in 1867 he reported 88 cleft palate successes in closure out of 100 cases.

DISSENTERS

In 1854 Syme deserved a commendation. Against the popular muscle-cutting stream, he had the audacity and the astuteness to question Sir William Fergusson's myotomy as unnecessary in staphylorrhaphy. In 1865 Annandale condemned extensive myotomy as done by Fergusson, preferring the von Längenbeck procedure in a single operation. He reported that in one of his cases the mucoperiosteum, which obliterated the gap in the cleft palate, had undergone ossification. In 1870 Tait strongly criticized extensive myotomy but advised that the velum be freed from its connections with the anterior and posterior pillars whenever they interfered with its function.

Sir James Berry was born with a cleft palate; needless to say, his speech was far from good. He was therefore undoubtedly acutely aware of the patients' problems, and this sensitivity led him in the natural direction of the least trauma. In 1905 Berry stated his preference for relaxing incisions over myotomies, and in his much-quoted 1912 book, *Harelip and Cleft Palate*, with Legg, Sir James continued to serve as the good knight, championing the stand against muscle-cutting procedures.



Sir James Berry

BILLROTH III

Meanwhile, back in the operating room, other less offensive methods of relieving tension were being instituted. More attention was being paid to obtaining good functional results. In 1889 Billroth condemned extensive lateral incisions extending into the velum because he felt these were bound to injure the palatal muscles. He advised section of the hamular process by fracturing it above its connection with the pterygoid plate with a chisel introduced through the posterior extremity of the lateral incision. This is a maneuver that temporarily releases the tensor palati



Theodor Billroth

action against the cleft suture line. In 1925 Dorrance advocated fracture of the hamulus to aid in the palatal lengthening:

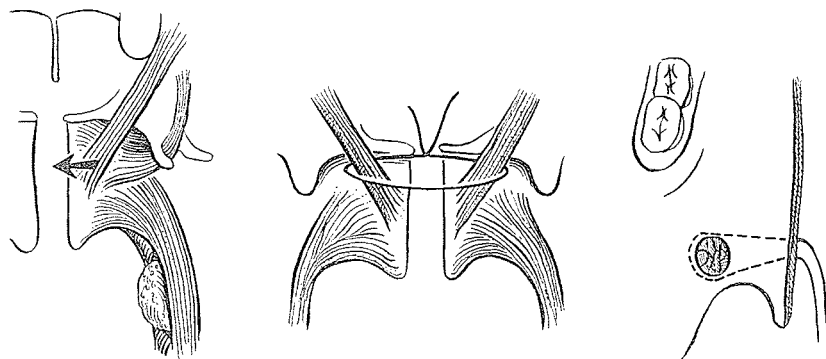
On reaching the tuberosity of the maxillary bone, it will be found that there is still some structure which prevents the palate from falling backwards. This structure is the tendon of the *tensor palati* muscle. If the hamular process around which this muscle turns at a right angle is broken off, the divided portions will be drawn downward by the *pterygopharyngeus* muscle. . . . After this hamular process has been fractured you dislocate the tendon of the *tensor palati* muscle, thus changing its direction so that instead of forming two sides of a right angle triangle it will form the hypotenuse . . . and will allow the lengthening of this muscle and transpose it from a *tensor* into a *levator* muscle. This can be demonstrated on any cadaver.

In 1964 R. Ruding of Amsterdam advocated slipping the tensor tendon over the hamulus:

The next step is to lift the tensor tendon from the hamular groove and to detach all insertions of the tendon and the palatine aponeurosis. (Later, after repair, the tensors will have a levator function.) Because the tensor is fibrotic and its tendon difficult to elevate from the hamular groove, it sometimes happens that the hamulus breaks off and disappears. If easily found, it may be removed, otherwise, one may let it go.

JOINING THE LEVATORS

In 1912 Ombrédanne of Paris cut the posterior pillars of the fauces near the uvula and sectioned the aponeurotic expansion of the tensor palati muscle by a blunt-pointed bistoury. Through the same incision behind the maxillary tuberosity, he passed a suture on a Reverdin needle around the levator muscles and sutured them together. Many palates and a world war later, Ombrédanne still preferred this approach for cleft palate.



Franz Ernst, pioneer of dentistry, was a forester's son who rose not only to professional fame but also to a high cultural plane. He played violin in the Academic Orchestra and was honored by Paul Hindemith, who dedicated his Concerto for Greater Orchestra to him, and Goetz, who dedicated the comedy *Hokuspokus* to him. During World War I, he worked in Berlin's Military Dental Institute under Willigen and later under Axhausen. He was the inventor of the Ernst plate made of plastic-celluloid. In 1924 he finished his work on the surgical techniques of handling a cleft palate by plastic surgery.



Franz Ernst

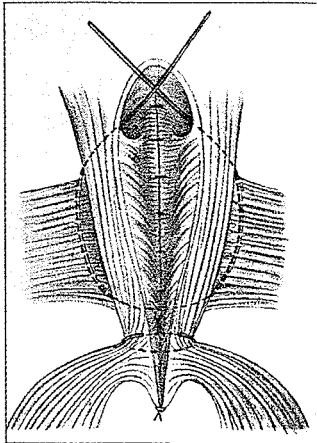
Ernst is best known to palate surgeons for his development of the "space of Ernst." This is a surgically dissected pocket created by cutting the oral mucosa, the very thin palatoglossus muscle, usually fracturing the hamulus and entering between the pharyngeal constrictor and internal pterygoid muscles—that is, between the masticatory muscles laterally and the pharyngeal muscles medially. He recognized that the musculature of the palate and pharynx had to be reassembled into a position where it could function physiologically. Many surgeons have used the space of Ernst for dissection of the lateral musculature prior to closure of the cleft. Kilner and Peet taught me this maneuver using a blunt dissection down the medial aspect of the medial pterygoid plate to the base of the skull for complete freeing of the structures prior to medial shifting and suturing. Braithwaite based his surgical approach on this dissection.

At the 1964 Hamburg Symposium, A. Immenkamp of Münster/Westfalen, Germany, emphasized the importance of Ernst's pioneer work:

For nearly 30 years I have done cleft palate repairs after the Langenbeck-Ernst-method. I was fortunate to see Ernst perform his method in Berlin. Wide dissection in the space of Ernst and backwards lateral to the constrictor freed the component "muscle block" of the velopharynx, and it assumed a relatively normal position. When doing push-back procedures of the velum we also use lateral pharyngeal space dissection. We have found that with congenital short palates this method suits the retroposing procedures admirably.

In 1977 Otto Kriens of Bremen repeated his concern about dissections and packing in the space of Ernst:

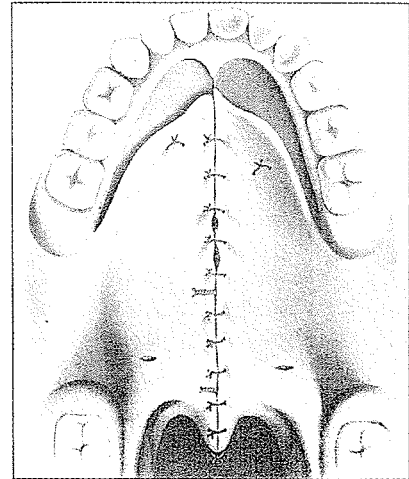
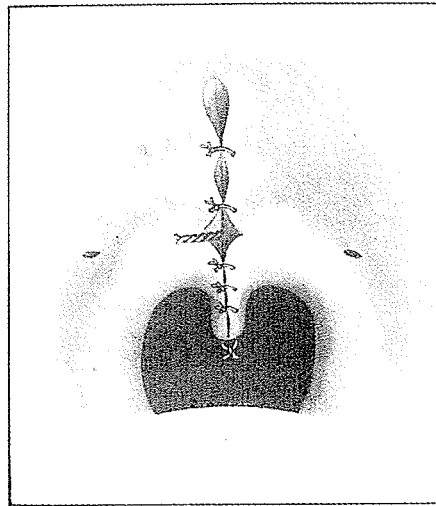
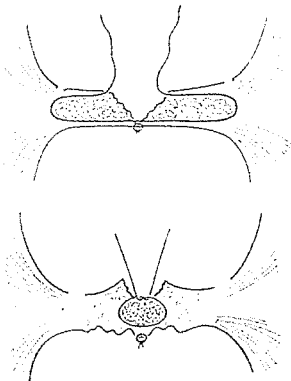
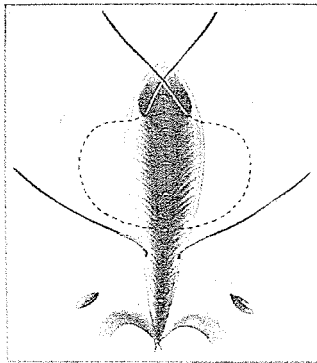
The space of Ernst is a surgically created pocket, which served the purpose to push the velar muscles medially and to accept a pack, which was left there for 8 to 12 days (or sometimes longer!). Preparing the space of Ernst means to operate outside of the pharyngeal or velo-pharyngeal area. According to Broomhead's study, the vascular and nerve supply of the velopharynx enters the pertaining muscle from the outside. Thus entering the space of Ernst means: possible damage to this supply and also: leaving the pathology within the velum proper.



VEAU

One of the major contributions to palate surgery by Victor Veau of Paris, besides his nasal mucosal closure, was his metallic suture of the muscles. In 1927, in the *Proceedings of the Royal Society of Medicine*, he emphasized the importance of a permanent encircling suture of the musculature on either side of the cleft.

Veau made no attempt to correct the direction of muscle fibers or to detach them from the edge of the hard palate. He used the wire muscle suture for simple closure of incomplete clefts or in a V-Y lengthening procedure in complete clefts.

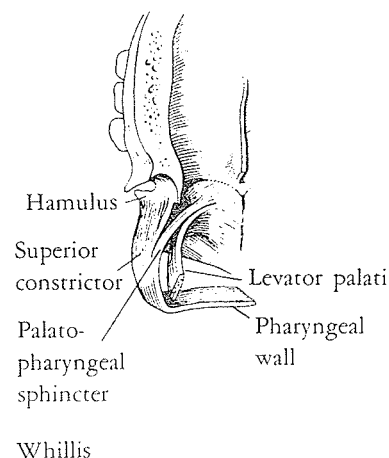


The most honest evaluations of a man's worth must come from his peers. George Dorrance, another palate giant, a contemporary of Veau and one not known for accolades to competitors, once said,

Veau's contribution to cleft palate surgery is outstanding and admirable. The intramuscular suture introduced by him for cleft palate is unquestionably the suture *par excellence*. This aluminum-bronze wire is the most practicable form of suture for holding the split anterior segment of the "palatopharyngeal-sphincter" in its proper relation. We also agree with Veau that the nasal mucoperiosteum is easily stripped off the nasal surface of the hard palate. However, as yet, we are unable to suture satisfactorily this tissue in its entirety.

WHILLIS

In 1930 J. Whillis of Guy's Hospital, London, made dissections to establish the muscular identity of Passavant's ridge. He found fibers of the superior constrictor muscle inserted into the palatal aponeurosis, constituting a lamella which he felt was responsible for Passavant's ridge and which he called the palatopharyngeal sphincter. In 1958 Calnan did his best to explode the "myth" that Passavant's ridge participated in the mechanism of speech, for indeed, his observations of the contractions of this muscular ridge showed it often to be below the level at which the soft palate occluded the nasopharynx. Yet, as pointed out by Braithwaite, it is possible that Whillis' lamella may serve speech by narrowing the lateral pharyngeal recesses and be a factor in palate occlusion of the nasopharynx when the levator sling contracts.



OLDFIELD

The muscular elements of the soft palate, apart from the uvulus muscle and the sphincter of Whillis, consist of four slings. These slings, as noted by Oldfield in 1941, are bilateral muscles gaining their sling-like function through their insertion in the soft palate, the levator and tensor palati with superior origins and the palatoglossus and palatopharyngeus with inferior origins.

BROWNE

Denis Browne, a transplanted Australian and an orthopedic and pediatric surgeon working at the Hospital for Sick Children,

Great Ormond Street, London, always had a salty grain of truth in his criticisms to add sting to the wounds caused by his comments. To know Browne was to know his barbs. He said in 1935:

Brophy's operation appeared to me to be a gross mutilation of the whole dental arch for a purpose that could be easily attained in a harmless way. . . . Lane's operation remains a complete puzzle to me. I have never heard of a good functional result from it, and I do not see how one could be attained. . . . Gillies's operation was not nearly ambitious enough. I wanted better results than speech with the aid of a plate needing extremely skilled dental assistance to fit. . . . Wardill's pharyngoplasty, by which he substitutes for the loose and actively rising posterior half of the sphincter a tight mass of scar tissue which drags the sides of the nasopharynx together, appeared to me to go against orthopaedic principles. Apart from my reluctance to destroy the only normal part of the mechanism I was trying to get to work, I had learnt to distrust the permanence of these draggings together and fixations by fibrous tissue.

He has
Something
here, too!

By 1932 Browne had decided that the nasopharyngeal passage is closed by the action of two overlapping slings of muscle, the superior constrictor aided by the palatopharyngeus posteriorly, and the levator palati with the tensor palati anteriorly. Resenting a less than 100 percent union of his cleft palates, Browne sought a twofold goal: (1) to remove all tension from the suture line and (2) to leave the joined sphincter in the completely shut position. As he said:

No one would suture a ruptured quadriceps or tendo achillis without leaving the limb so that the joined muscle lay in position of contraction during healing, . . . [so] treat the nasopharynx as one would the mouth of a sack that one wanted to keep shut, and tie a string round it.

In 1935 he described his orthopedic procedure for cleft palate. First he removed the tonsils and cut the posterior palatine arteries. Three months later, and after 18 months of age, he made two breathtaking lateral gashes from the canine tooth in front, backward just inside the teeth, then along the pterygomandibular raphe, cutting the anterior pillars of the fauces off the tongue. No wonder he ridiculed plastic surgeons' horror at large raw areas in the palate region. Blunt dissection through these canyon-like incisions moved the palate elements medially.

ugh!
wow!

CIRCUMPHARYNGEAL STITCH

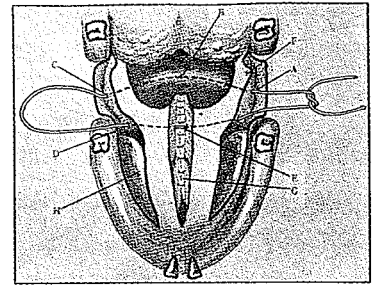
Then Browne got out his $1\frac{1}{16}$ -of-a-circle needle carrying a double suture of 40-day No. 1 chromic catgut mounted on a pistol-grip needle holder. When aided by his "needle-catcher" forceps, he was able, after much practice, to pass this cord around the back of the throat behind the superior constrictor, exactly in line with Passavant's pad. With a second bite, he completed the buried circle through the two halves of the palate. After the cleft edges had been sutured, the ring stitch was tied snugly and served to splint the cleft union as well as gather the velopharyngeal sphincter with a semi-closed and somewhat rigid ring. In 1948 at Great Ormond Street Children's Hospital, I saw him complete his palate operation in 20 minutes.

Browne reconfirmed his satisfaction with this method in 1955 at the International Congress in Stockholm. He reported spontaneous remarks on improvement in speech by parents and friends of almost every patient. Evidently few, if any, palates dared to separate once he had instigated this purse string. But then, few, if any, separate without a purse string.

In spite of his barbs and because of his work in all aspects of pediatric surgery, Browne was eventually knighted Sir Denis.

BRAITHWAITE

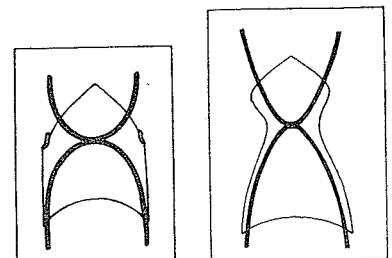
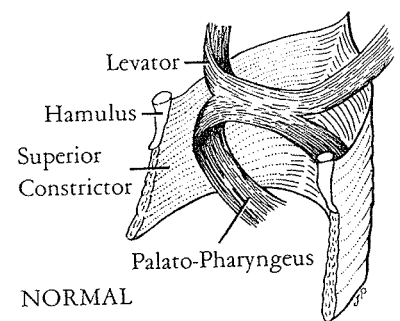
Fenton Braithwaite, a student of muscle physiology, even in his free time concerns himself with muscle coordination, being a director of Newcastle United, a professional football club with a high tradition in England. As Wardill's worthy successor in Newcastle upon Tyne, he continued to improve muscle efficiency in palate surgery. In Gibson's 1964 *Modern Trends in Plastic Surgery*, Braithwaite described and illustrated the speech mechanism of two muscle slings—the *levator*, descending on each side from its origin on the petrous bone passing downward and forward, and the *palatopharyngeus*, passing forward and upward. The levator arch elevates the soft palate in a backward and upward direction while the palatopharyngeus approximates the palatal arches and narrows the pharynx. These two loops with their common insertion in the palate counter each other, and the

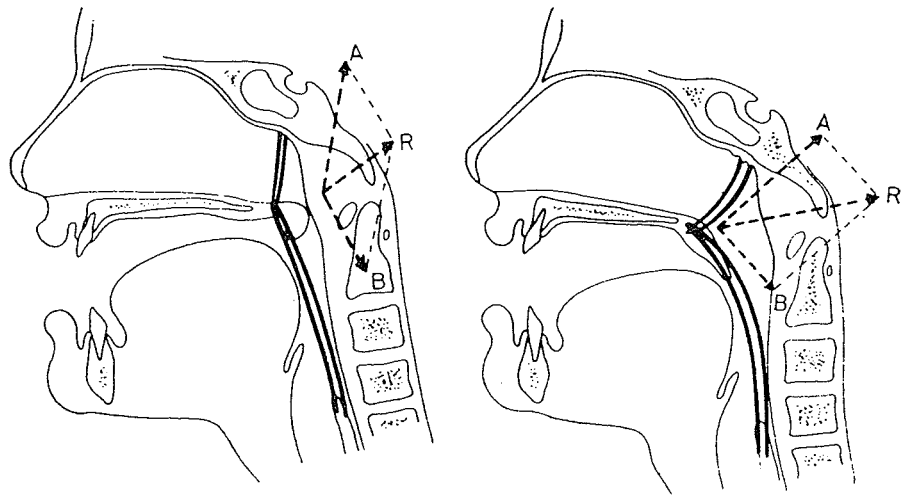


Placing that stitch is no simple maneuver!



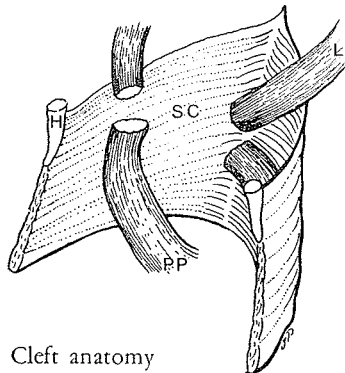
Fenton Braithwaite



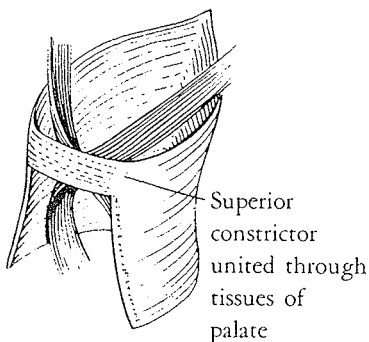


pull converts the U loops to Vs and the entire mechanism to an X. When looking through the patient's mouth, one can imagine this muscle action like the opening and closing of a pair of scissors. In profile the effect on the soft palate is shown during contraction of the levator and palatopharyngeus muscle.

Before the patient was 6 months old, Braithwaite united the lip and achieved a one-layer Veau-type closure of the nasal floor and anterior hard palate. Between 1 and 2 years he used a Ganzer-type V-Y operation, but his dissection had a special design. First he elevated his palatal flaps, isolated the posterior vessels and freed the mucosa from the nasal floor. The aponeurosis of the soft palate was divided from the edge of the hard palate, leaving the nasal mucosa intact. The hamulus was fractured and the fibers of the superior constrictor, along with the hamulus, were pushed medially and dissected radically from the medial pterygoid plate. This dissection was carried deep into the space of Ernst and backward around the lateral pharynx, moving the constrictors medially with the soft palate. The edges of the cleft were dissected so that the levator attachments could be divided and freed into robust bundles which were sutured together to close the levator sling. In 1968 Braithwaite reemphasized this maneuver as



Cleft anatomy



Superior constrictor united through tissues of palate

of great importance in the production of a palate with maximum mobility. This step consists in the careful dissection of the fan-shaped levator palati following its separation from the posterior edge of the hard palate so that it becomes a compact bundle before it is sutured (with widely placed mattress sutures) to its opposite number.

The lateral spaces were packed with gauze soaked in Whitehead's varnish and left for 10 days to support the sutured palate during the healing phase. Upon removal of the packs, Braithwaite claimed, the space was occluded in 48 hours as the adjacent tissues of the neck moved medially.

It was Braithwaite's theory that, once the superior constrictor's hamular and lateral attachments were freed, the soft palate aponeurosis from the hard palate was released and the levator sling was joined across the cleft, the pull of the sutured levator would maintain palatal length in spite of an intact nasal mucosa.

Spontaneous development of normal speech was usual following modern operations in infancy. Speech therapy was required if speech had not developed properly by 4 or 5 years of age. Braithwaite reported in 1964 that 19 percent of cases required a short interval of speech therapy and 10 percent a longer interval. Seventy-one percent were normal without therapy. Assessment of 290 children over the age of 4 years with operated clefts revealed 58 percent normal, 24 percent with articulation defects (8 percent of these being minimal s distortion) and 9 percent with nasopharyngeal incompetence, incoordination or anterior fistulae. There was another 9 percent not reported.

Cognizant of Braithwaite's priority in construction of the levator sling in cleft palate and his reputation as a silver-tongued after-dinner speaker with an elephantine memory, I challenged him to retrace his early experience. Here are some of his reflections:

When the war came, the leading lights of English Plastic Surgery sprayed themselves and their units to country sites at safer distances from London's centre. I remained at Barts under the "blitz" and, after the war, was transferred to East Grinstead with McIndoe. During the clinics and outpatients I noticed that everyone discussed speech in relation to "Push-Back" of the cleft or short palate. I recalled seeing in various types of injury that the levator palati muscles and the palato-pharyngeus acted as a pair of scissors. This is obvious if the palate or tonsils are touched by a probe; the tonsils are forced inwards, helped by a simultaneous contraction of the upper portion of the superior constrictor. It is also seen, on dissection of a cleft, that some fibres of the levator palati are attached to the posterior edge of the hard palate. If the scissor-like action of the palatal and pharyngeal muscles is to be restored, this complex must be freed of abnormal attachments and

again
what's so
sacred
about
mucosa?

given normal attachments by surgical suture. This was first discussed by me at East Grinstead in a surgical meeting. It was not met with enthusiasm, being overwhelmed by the popular mixture of "Push-Back" and Passavant.

At Newcastle upon Tyne, to which I was appointed in January 1949, I had the opportunity to try this concept. Dissection of the upper fibres of the superior constrictor muscle from its attachments to the pterygoid lamina allowed a further "pull in" of the superior constrictor. At the same time a blunt dissector could be inserted lateral to the upper pharyngeal muscular group and the latter freed from fascial attachments. The palato-pharyngeus and levator-palatal muscles can be dissected within the soft palate. The fibres of this group are augmented by the fibres which have been dissected from the hard palate and appear as an obvious muscle which just invites suture. These results were presented as routine "follow-up" patients for Dr. Muriel Morley's assessment and criticism. Her opinions of the success of this approach were reported in her well known textbook.

Dr. Betty McWilliams from Pittsburgh visited my unit, to confirm or dispute the results that had been publicized by Dr. Morley on the latter's visit to the U.S.A.

McWilliams recalled her visit with Braithwaite and Morley in Newcastle on Tyne:

A four-year-old with a repaired palatal cleft was finding it difficult to talk to the visiting American, who, his mother had unwisely told him, had come all the way across the ocean on a big airplane just to see him. Needless to say, he was scared speechless. Mr. Braithwaite suggested that an eight-year-old brother be invited to join his little brother in the hope that things would be a bit less tense. The eight-year-old was quite self-possessed and readily entered into conversation. His speech was extremely British and altogether delightful.

Falling easily into the surgeon's trap, I asked Mr. Braithwaite if we could get permission from the boy's mother to tape-record the speech of the older child as an example of not only normal but superior speech in a British male child. Mr. Braithwaite calmly replied, "I repaired *his* palate when he was a year old." That was a real test of excellence that is usually not possible except in controlled experiments. I did not *know* the boy's history, and he did not reveal it in his speech pattern. The goal for him had been attained.

Braithwaite concluded:

Delay in publishing these results was due to my feeling that many people published their results too early and with too few examples. Matthew Arnold, the poet, implied in his opinion "the lawless eclectic of a spurious


impressionism" did but ill favour to the uninformed who followed. I did not feel disposed to contravene the couplet:

"Be not the first by whom the new are tried,
Nor yet the last to lay the old aside."

Dr. Morley in 1961 examined 360 children who had been operated on by me according to this technique. The results are recorded in the sixth edition of her book *Cleft Palate and Speech*. I gained comfort from the fact that I appeared to be doing no more harm to my patients than anyone else did to theirs and that I had waited for 360 patients to attain an age of five to ten years before I published the results. This method was discussed as you know at Schuchardt's Second Hamburg International Symposium in 1964 and presented in Gibson's 1964 *Modern Trends in Plastic Surgery, I*.

RUDING

In 1964 in *Plastic and Reconstructive Surgery*, Roelof Ruding of Amsterdam, the Netherlands, a general surgeon interested in clefts, presented an excellent study of palate musculature with logical suggestions for surgical correction. He noted that the path of the levator muscle lies within the arc of the inferior curve of the posterior rim of the medial pterygoid plate, and upon contraction of this muscle, it moved away from the plate in a posterior direction "much as a slack line leaves the ground when it is drawn tight." He warned:



Roelof Ruding

Any operation where intensive dissection is done in the region of the posterior rim of the medial pterygoid plate runs the risk not only of injuring the pharyngeal orifice of the auditory tube but also leads to scarring and fibrosis within the levator muscle. Whereas the tensors can be eliminated, the levators cannot be eliminated with the retention of normal speech.

His description of the levator muscle in relation to the palate was concise:

The fibers of the levator pass in three directions. The anterior fiber bundles bend forward in a sagittal sense and insert in the palatine aponeurosis. The posterior bundles bend vertically, coursing downwards, and end in the uvula. The greater and bulkier part of the levator fibers continues between the anterior and posterior fibers to meet in the midline with fibers from the

opposite side. A levator loop is thus created. Starting with the diameter of about 1 cm. this muscle then broadens into a flat muscular sheet measuring approximately 2 to 2.5 cm.

Ruding discussed the two notorious muscle loops:

The combined action of both the levator palati and the superior pharyngeal constrictor on both sides produces the nasopharyngeal sphincter. The lateral fibers of both muscles, coursing to their separate attachments, cross each other. The palatal pharyngeal sphincter of Whillis is comprised of portions of both the levator palati loop and the superior pharyngeal constrictor loop. The posterior portion of the palatopharyngeal sphincter belongs to the constrictor; its anterior part to the palatal muscles. According to Whillis [1930], its anterior insertion is on the palatine aponeurosis, and according to Holdsworth [1951] some bundles unite with bundles of the other side. In both cases we can consider that a sphincter has been formed. Baggerman agrees with Whillis.

Ruding also discussed the palatopharyngeus muscle running in the posterior pillar and the palatoglossus in the anterior pillar, summarizing:

Together with the tongue, these palatopharyngeal and palatoglossal muscle loops form the oropharyngeal sphincter.

He did not give justice to the uvular muscle, stating:

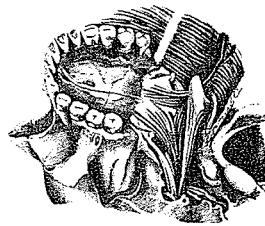
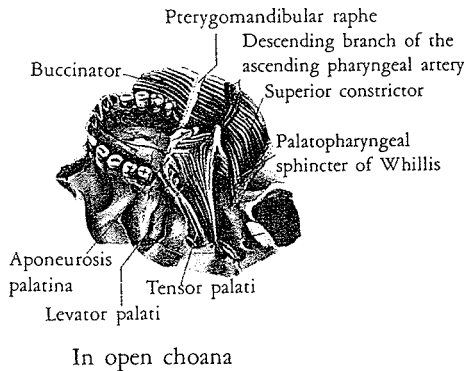
The uvular muscle is not very important and in the surgery of cleft palate is totally unimportant.

(David Dickson, as previously described in "Anatomy," considers this muscle important with its longitudinal contraction, like the humping of an inchworm, forming the "velar knee.")

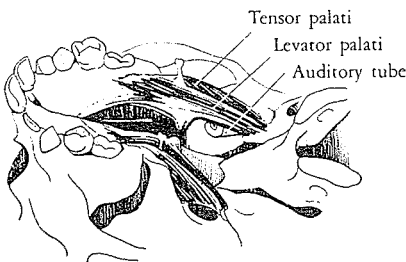
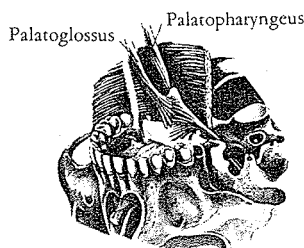
The exciting part of Ruding's presentation was his logical correction of the misplaced anatomy by surgery. He noted:

In the case of cleft palate, all the muscles and tendons which are normally found do indeed exist, and their origin is the same. It is their insertion which is abnormal. . . . This is particularly true of the insertion of the levator which is the most important muscle. This more anteriorly and medially situated portion of the muscle is called *muscle de la fente* (fissural muscle) by Veau.

Ruding mentioned that E. Baggerman in Amsterdam had dissected a fissure in which these bundles were macroscopically



Closed choana



well visualized. Just like the lateral portion of the insertion, this medial part was very firmly attached to the mucosa; giving the impression of a scar. Ruding conjectured:

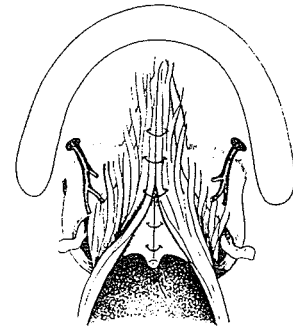
The ideal operation should imitate as completely as possible embryologic development: as the cleft is closed *in utero* in an anteroposterior direction, the palatal musculature also moves posteriorly to finally establish itself in a plane which is posterior to the plane through the hamular processes. The fibers of the musculature, as they follow the closure of the cleft, will change their directions from a nearly anteroposterior one to a nearly laterolateral one, so that when final closure of the cleft is complete *in utero*, all fibers destined to become bundles of muscle will have joined with their partners of the opposite side directly or through the palatine aponeurosis in midline conjunction with each other. Surgically, this can be obtained by carefully detaching every muscle and tendon fiber from their insertions to the bone and then by suturing in the median plane as many as possible of these detached insertions. The more successful this suturing technique, the more muscle fibers will take part in the construction of a true levator loop. . . . The important part is that the muscles, no longer fixed anteriorly and laterally, may now become effective forces modeling function and growth to obtain a more normal closing mechanism.

Ruding also advised ostectomy of the posterior rim of the foramen to let the greater palatine artery move backward and the lifting of the tensor tendon from the hamular groove and detachment of all insertions of the tendon and the palatine aponeurosis without great concern for the hamulus if it should be fractured in the process. He did emphasize dissecting the muscles and aponeurosis from the nasal mucosa and mentioned small lateral cuts for a minor release or larger cuts at different positions for a Z-plasty and even a wide, transverse release to be covered on the nasal side by a free skin graft, as he described in 1955. He concluded, however:

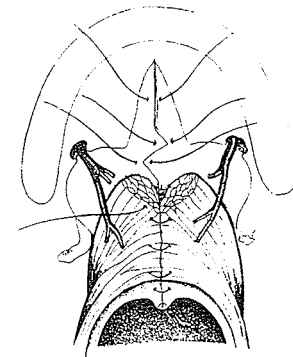
For most clefts of the palate these lengthening procedures are not necessary.

K R I E N S

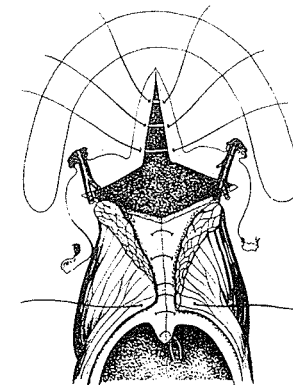
In 1967 Otto Kriens of Hamburg had the opportunity to dissect a stillborn bilateral cleft baby in Karfik's unit in Prague, and found that Veau's "cleft-muscle" was the common anterior



No



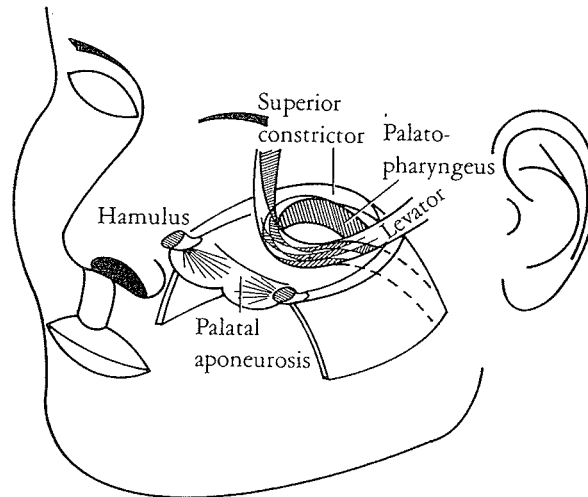
Yes



Maybe

portion of the levator and palatopharyngeal muscles. The superior constrictor pharyngeus muscle was the only intact muscle sling in the cleft palate. Further study by Kriens of the anatomy and applied physiology of palatal musculature threw some new light on their use in speech and Eustachian tube function. Kriens found:

In the normal soft palate there is the palatal aponeurosis and posterior to this the muscular velum. Muscle fibers of isotonic action intermingle in a predominantly transverse course through the palate.



The three muscular slings of the normal velo-salpingo-pharyngeal apparatus act isotonicly. Their contracture leads to the occlusion of the velo-pharyngeal opening. During the same action, the levator palati elevates the medial edge of the tubal cartilage. This opening movement of the Eustachian tube is furthermore afforded by the downward pull of the lateral edge of the tube by the tensor muscle and indirectly by the levator muscle which elevates the contracting salpingo-pharyngeal muscle.

Cleft Palate

Functional synergism of the velo-salpingo-pharyngeal muscles is impaired in the cleft palate with the exception of the superior pharyngeal constrictor. The other muscles of the cleft palate have ipsilateral origins and insertions. The levator palati extends in a bow across from origin to insertion on the same side of the head and thus contracts *laterally*, forward and upward instead of *backward* and upward. This causes the palatal halves to be pulled to the sides more than posteriorly!

A similar dysfunction is present in the lateral epipharyngeal wall around the levator palati muscle. Since the muscle does not join its mate to move dorso-cranially it deviates instead *craniolaterally* so that the medial edge of the Eustachian tube is not elevated.

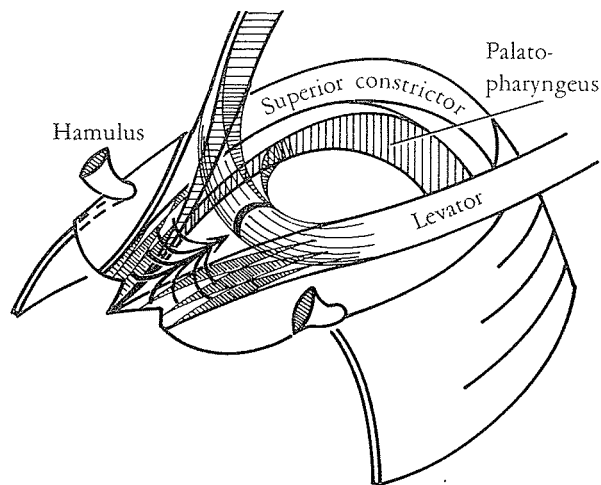
In cleft palate the levator space is retained during contraction of the muscles as long as the cleft-muscle is adherent to its attachments. The detachment from its insertion at the oral mucoperiosteum and from the cleft posterior nasal spine and the formation of a muscle sling through the soft palate are prerequisites for an improvement of an effective interplay of the palatal muscles around the levator space.

A Warning

Any intervention near the epipharyngeal portion of the Eustachian tube seems to offer a possible hazard. The fracture of the hamulus may easily lead to a disruption of the musculo-tendinous apparatus near the tube. Worst of all—as far as the subsequent damage is concerned—seems packing of the space of Ernst: immediate disturbance of the equilibrium of the muscle interrelations around the levator space and later scarring.

The attachments of Veau's cleft-muscle, especially its position in relation to oral mucoperiosteum and to the posterior nasal spine, retain the lateral position of the velar stumps and *have to be freed*.

Intervention other than elevating the nasal mucoperiosteum and dissecting the fibers attached to the bone should be avoided. If an immediate elongation of the nasal layer is necessary, a retro-displacement after Stark or Cronin or with Millard's island flap should be resorted to instead of severing the muscle attachments at the nasal lining. The latter intervention involves a great risk of a breakdown of the nasal lining with subsequent scars and fistula.



According to Kriens, after the cleft-muscle on each side has been shifted dorsomedially and the levator sling formed, closure of the cleft palate is easy. As Blair and later Widmaier did, he closed his lateral incisions with flaps of buccal mucosa.

MR. DEANE COMES TO MIAMI



Malcolm Deane

Soon after the arrival in Miami of astute Malcolm Deane, a registrar in Bristol on a Maytag Fellowship, we were introduced to the adjunct of direct dissection of the fanned-out levator muscle into two discrete muscle bundles as previously described by Braithwaite. In 1970 a modification of the Braithwaite approach was published with less radical lateral dissections but utilization of his muscle dissections

just before dividing the mucosa along the edge of the hard palate—to maintain a fixed point and thus facilitate this part of the surgery. The nasal mucosa is then cut along the posterior edge of the hard palate, allowing the entire soft palate to shift backward. Once freed from their anterior tethering, and developed into two bulky muscle bundles, the levator muscle stumps could be closed into an intact sling by direct suturing. The island flap is then inserted to insure and maintain the retropositioning.

It seemed that if direct levator suturing were used as an adjunct, in addition to the island flap for nasal mucosal lengthening, total palatal function should be facilitated even further.

HOOPES

In 1969 John Hoopes, A. L. Dellon, J. Fabrikant and A. Soliman, using cineradiographic evaluation of the vocal tract with synchronous sound recordings as described by Hoopes and Fabrikant in 1968, found a significant difference between patients with submucous or visible cleft palates and the controls, and also between submucous cleft palate and visible cleft palate groups with reference to one another. They found:

The more anteriorly the levator veli palatini is inserted into the soft palate, the greater is the degree of velopharyngeal incompetence and the greater is the degree of hypernasality (a higher numerical speech rating).

DELLON

Evidently A. Lee Dellon was a precocious student at Johns Hopkins University School of Medicine. In 1977 he recalled:

Following the first cine studies with Dr. Hoopes, it became clear that for velopharyngeal incompetence, with a cine-documented anterior displacement of the levator, the ideal repair would correct this anomalous location. I was still in medical school and went to the anatomy lab at night, when the students had gone, and took the sagittally sectioned heads, on which the velopharynx was usually untouched, and worked out the procedure. Dr. Hoopes was then at Barnes. I brought Dr. Edgerton to the lab one afternoon with his camera, and he was very supportive of our efforts. To have the least ambiguous clinical trial, I thought we should try this on non-cleft patients with congenital VI, whose only problem was a cine-identified anterior insertion for the levator. We reported our small series (4) in the *Surgical Forum* first; it later appeared in *P and R S*. The procedure grew out of a clinical problem, evaluated by clinical research, taken to the lab and then back to the patient.

In 1977 John Hoopes referred to his cineradiographic studies with Lee Dellon as having satisfied him that the position of the levator sling is the important determinant with regard to speech results after palatoplasty. He noted:

On the basis of the investigations performed by Dr. Dellon and myself, Milt Edgerton advocated specific dissection and retro-displacement of the levator muscles. This procedure is theoretically correct anatomically and physiologically; however, the speech results in the limited number of isolated levator dissections and retro-displacements performed in our institution have not been acceptable. I tend to suspect that the poor results are attributable to the excessive scarring associated with extensive dissection within the soft palate.

EDGERTON

Always quite quick to recognize a good thing and to adopt it like "a duck on a June bug," Edgerton was attracted to the levator muscle repositioning of Braithwaite, Ruding and Kriens. In 1971 with Dellon, Edgerton advocated exposure of the levator muscles through a midline oral mucosal incision in incomplete clefts and congenital palatal insufficiency and through the pared cleft edges in incomplete clefts. They then described dissecting the oral mucosa as flaps off the underlying muscles and continued:

Starting in the midline, the levator insertion (plus a small segment of aponeurosis) is separated from the bony palate and turned posteriorly, taking care not to disrupt the nasal mucous membrane, lying deeply above the soft palate. The dissection is then carried laterally and posteriorly to the point where the cord-like portion of the levator muscle may be seen originating from the lateral pharyngeal wall.

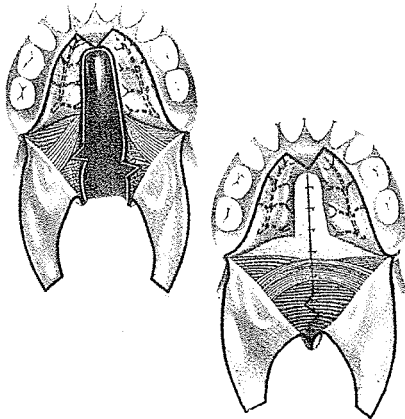
When this dissection has been completed and the levator is freed from connections to the bony palate, there will be a natural tendency of the levator insertion to retract posteriorly toward the uvula. . . . The two levator muscles are dissected free, as if they comprised the "meat" of a sandwich (with mucous membranes forming the "slices of bread" that are left intact on both the nasal and oral surfaces).

At this point in the operation a satisfying relaxation of the entire soft palate may be seen.

This has been an interesting description, but nothing really new has been added to Braithwaite's, Ruding's and Kriens' work. Edgerton's twist follows:

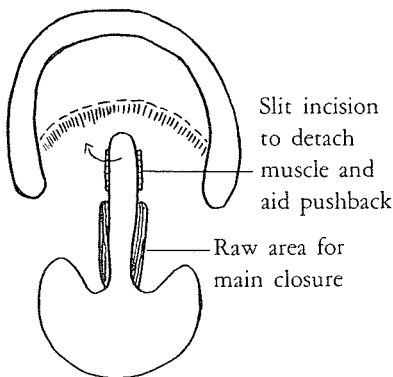
To help maintain a more posterior position of the levator insertion, we have elected to roll the insertion over on itself 180° before suturing it to the uvulus muscle near the base of the uvula. The oral mucous membrane layer of the soft palate is now closed, if no additional pushback of the soft palate is required.

unphysiological ?



PERKO

In 1974 Milivoj Perko of Zurich, in an attempt to reduce surgery's effect on maxillary growth, left the periosteum and the neurovascular bundles on the hard palate. He dissected the oral mucosa as rather hazardous flaps for exposure of palate musculature and detached the levator muscles from the edge of the hard palate, freed them from the nasal mucosa and then united them in a muscle sling.



WALKER

Dennis Walker of South Africa has devised a conservative muscle-releasing trick which he described to me in 1977:

A sub-mucosal muscular release at the back edge of the hard palate is possible by slipping McIndoe scissors transversely between the oral and nasal mucosal layers.

KAPLAN

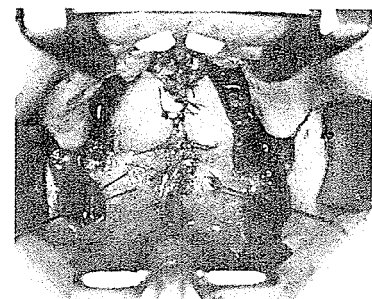
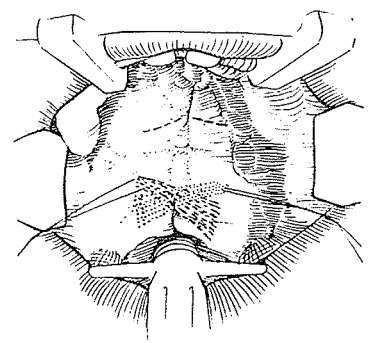
In 1975, while advocating correction of the position of the misplaced levator muscle and contraction of its sling, E. Kaplan reviewed the various methods used by surgeons to accomplish this goal. Braithwaite and Maurice, he noted, originally separated the levator muscle from the nasal mucosa and rotated the halves of the levator muscle and attached oral mucosa together as composite units. Kriens (1969), Millard et al. (1970) and Fára et al. (1970) all advocated methods of levator sling reconstruction during primary closure of the cleft. In 1971 Edgerton and Dellon as a secondary procedure dissected the levator muscle from both the oral and nasal mucosa prior to retrodisplacement. Kaplan then chose the only other possibility: separating the oral mucosa of the soft palate from the palatine muscles so that the levator muscle and the nasal mucosa could be rotated as a composite unit. He argued that this lack of dissection of the nasal palate mucosa produced less scar, less resultant restriction and less risk of devascularizing or injuring the levator muscle.


RANDALL AND OTHERS

In 1975 at the Sixth International Congress in Paris, Peter Randall presented an application of overlapping the levator muscles in soft palate closure, similar to overlapping orbicularis oris muscles in bilateral cleft lip. Referring to his overlap, he reasoned:

Hopefully, this tightening of the "levator sling" will produce a better levator eminence and improved V.P. competence.

He advocated a primary procedure with elevation of the usual V-Y mucoperiosteal flaps, dissection with difficulty of the levator muscles from the nasal mucosa, nasal mucosal lengthening with Z-plasty and overlapping of the levator muscle strands prior to replacement of the mucoperiosteal flaps. His design of the criss-crossing muscle overlap following closure was presented along with photographs of the final closure. This much primary surgery in the growing child may not stand the test of time.





John Mulliken

In 1975 John Mulliken, F. Giargiana, G. Claybaugh and J. Hoopes of Johns Hopkins Hospital noted some interesting findings in relation to retropositioning the levator muscle:

In our institution, over the past five years, the levator retropositioning procedure was combined with standard Veau-Wardill-Kilner pushback and superiorly-based pharyngeal flap procedure for velo-pharyngeal incompetence; in most instances, anterior displacement was documented on pre-operative ciné study. This retrospective evaluation of our 20 patients has revealed the following:

- 1.) Combined palatal pushback, levator retropositioning, and pharyngeal flap procedure does not give a change (over 4 mm.) in levator insertion. Only 2 of 12 patients demonstrated remarkable retrodisplacement, and one of these had little improvement in post-operative speech. Yet 10/12 patients demonstrated satisfactory improvement in speech.
- 2.) Levator retropositioning when employed alone resulted in significant retrodisplacement . . . but the subjective improvement in speech was minimal.
- 3.) Pharyngeal flap, either alone or when combined with palatal pushback, resulted in anterior levator displacement in 4/6 patients with normal or posterior pre-operative levator position. Yet, speech improvement occurred in all 4 patients.
- 4.) The post-operative rate of velar ascent was slowed or unchanged following all operative procedures.


These observations indicate that when correcting a pre-operative anterior levator position, the post-operative location of the levator insertion is unpredictable—with the possible exception of levator retropositioning alone. Earlier studies suggest that the island flap pushback and pharyngeal flap also may give predictable levator retrodisplacement.

In conclusion, they made these observations:

Patients with normal or posterior levator insertions pre-operatively all demonstrated post-operative anterior displacement following pharyngeal flap procedures, either alone or in combination with pushback.

Anterior levator displacement may be the result of scar contraction or division of the levator sling (during inseting of a pharyngeal flap).

Toyomi Fujino of Keio University, Tokyo, who trained in the U.S.A. under Bernard, Hoffmeister, Bakamjian and Converse, tries to live by "Ki Shu Butsu Shin," which he translates as "A surgeon uses a devil's hand but with the mercy at the heart of



Toyomi Fujino

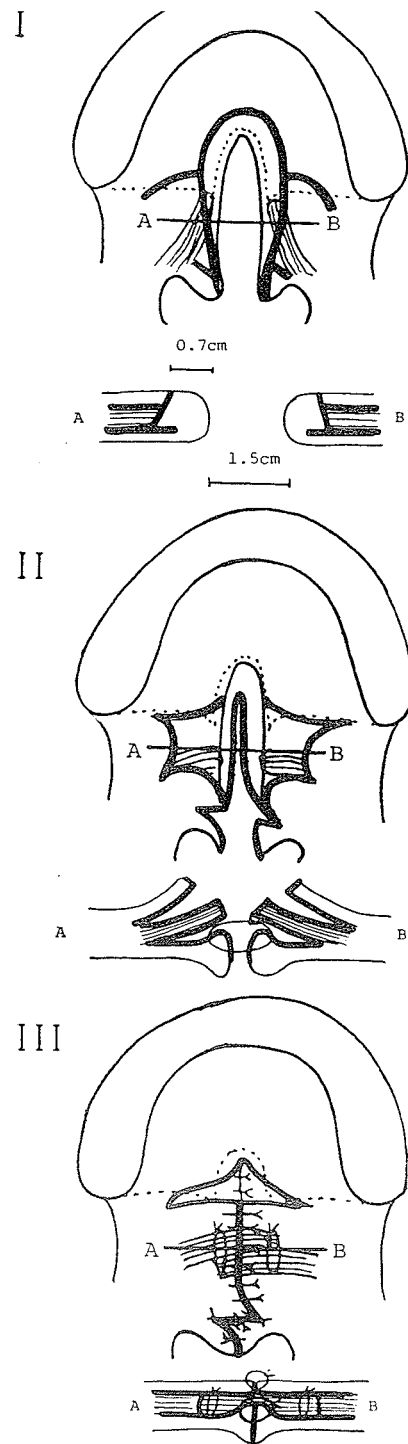
Buddha." In the 1977 *Keio Journal of Medicine*, after 20 years' experience with the Wardill operation, he presented a microsurgical closure of the soft palate cleft in 10 cases. The operation involved a U incision made around the cleft, a whole-layer Z-plasty over the palatopharyngeal muscle just in front of the uvula and oral mucosal flaps (A and B) at the level of the posterior edge of the hard palate (I). Under the operating microscope (5-6 × magnification), the levator muscle fibers were dissected with excellent visualization from the oral and nasal mucosa only two-thirds of the length from the cleft edge to the retromolar region, preserving the lesser palatine nerves. The muscle bundles were transposed into normal position, flaps A and B were rotated and advanced and a full-thickness Z-plasty of the distal velum was accomplished (II). Following suturing, there was an anterior oral raw area between the hard and soft palate (III) which was reported healed in one month. By not exposing the retromolar region and not severing the lesser palatine nerves, Fujino predicted:

We expect a better growth of the maxillary and palatal bones, and less chance of anesthesia of the soft palate and of atrophy of the mucosal glands.

The uvular muscle function would also be preserved, but contraction of the raw area is a *drawback*.

Fujino cites a testimonial for his operation from a mother 11 days after surgery on her 19-month-old girl: "Doctor, my child speaks so clearly after the operation." Then speech therapy was discontinued after seven months because of normal speech.

Leonard T. Furrow, Jr., of the University of Florida, who has suggested testing for velopharyngeal incompetence using a film of soap solution over the nares, suggested that his epitaph might read: "His ingenuity was obscured by his procrastination." At the 1978 Southeastern Society of Plastic and Reconstructive Surgeons meeting, in typical low-key manner, he presented his ingenious rendition of palate lengthening and levator muscle repositioning by means of composite oral and nasal Z-plasties with mucomuscular flaps. One of the nasal mucosal flaps carries the right anterior half of the levator muscle while one of the oral mucosal flaps carries the left half of the muscle. By transposing the four flaps in a double Z he gains 1 cm. in length and lines up



Leonard Furrow

the levator fibers in an intact loop. Here is his description of the method:

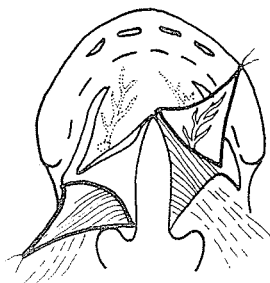
The z-plasty closure is loosest at the end of the lengthened diagonal. Thus one can lengthen the palate, transpose and reposition the palatal musculature, and relax the difficult area at the junction of the hard and soft palate.

The middle limb of each z-plasty lies along the cleft. The ends of the transverse diagonal are at the level of the hamulus, placing one lateral limb approximately along the posterior margin of the bony cleft (A). On the oral side, the posteriorly-based flap is elevated to contain the musculature. The anteriorly-based flap is composed of mucosa only, elevated from the underlying muscle (B). The nasal z-plasty is reversed, so that the posteriorly-based flap contains the muscle of the opposite side and the anteriorly-based flap is of mucosa only (C).

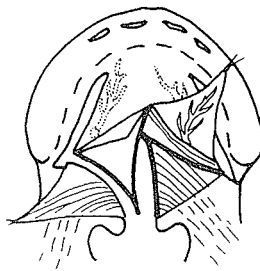
When the flaps are transposed, the muscles are transposed with their posterior flaps into a more posterior and transverse position overlapping to approximate a more normal muscular sling (D, E).



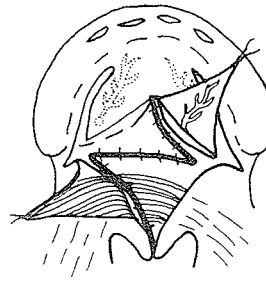
A



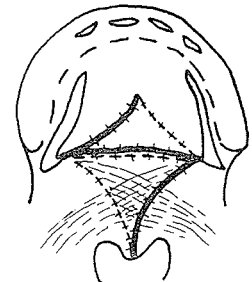
B



C



D



E

The greater palatine vessels are critical to the oral side flaps. They supply the mucoperiosteal flap on one side and the mucoperiosteal flap and the anteriorly-based z-flap on the other, and absolutely must be protected. If, after elevation of the mucoperiosteal flaps and mobilization of the greater palatine neurovascular bundles, there is any question of their continuity, the z-plasty repair should be abandoned in favor of a straight-line or other more standard repair.

At the time of presentation, Furlow apologized for having only three cases with short-time follow-up. He explained, however, that at the rate he was getting palate cases, by the time he had long enough follow-up he probably would have had only three more.

This is an interesting concept which was applauded by moderator Randall and, in fact, may have potential promise.

In 1978 in the *Journal of Maxillofacial Surgery*, Claus Walter and Hans-Henning Meisel of Düsseldorf proposed a similar type Z of soft palate flaps. With less sophistication in handling the muscles, they noted:

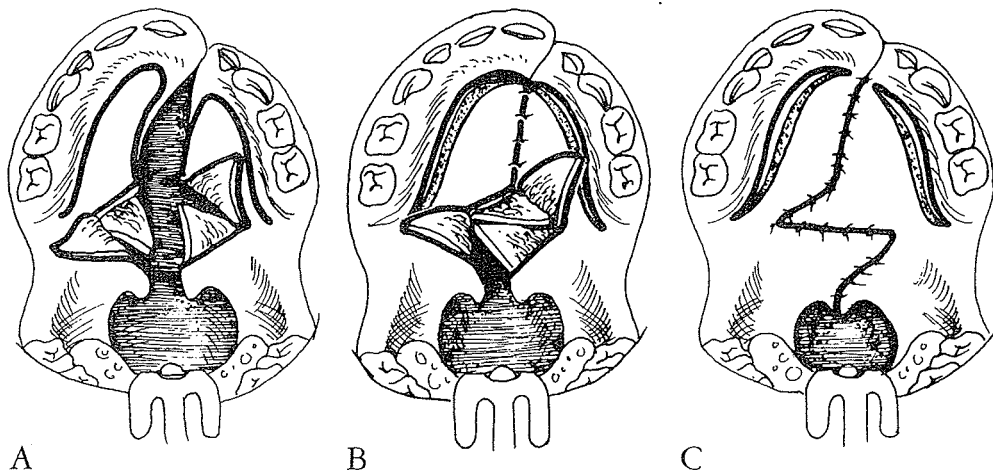
The soft palate is divided into two halves without regard to the muscle fibers involved. This means that no attempt is made to separate the muscle tissue from the nasal or oral mucosa.

They summarized:

With this procedure we are also able to shift the centre of muscle function further dorsally, thus achieving a lengthening of the palate as well.



Claus Walter



Do not forget that many large flaps make much scarring. More important, as in all Z-plasties, the gain in length must be paid for by decrease in width or in side-to-side tightening, which, in even the moderately wide cleft, may cost too much in general restriction.

THE VELAR STRETCH

Obviously, since the hole is open at rest, during velopharyngeal closure the soft palate must stretch backward unless the pharynx prefers to project forward. A bit of both is probably the usual phenomenon. In 1969 S. Pruzansky and Robert M. Mason of the University of Illinois first described the velar "stretch factor":

Lateral cephalometric X-rays showed that in some individuals the soft palate (velum) increased in its intrinsic length during velopharyngeal valving. This

“stretch factor” (SF) is significant since the potential of the velum to produce velopharyngeal closure is not always predictable from its resting length. That is, the resting length of the velum may be shorter than the anteroposterior diameter of the nasopharynx.

Among patients demonstrating varying degrees of palatal insufficiency, the SF for the consonant /s/ generally exceeded that for the vowel /u/. The differential is, in part, related to differences in intraoral air pressure, total cavity size, and the muscular effort necessary for their production. The valving differential between these sounds is constant for a given patient but varies between patients. . . .

In 110 [adult] patients with congenital palatopharyngeal incompetence, the velum exhibited elevation on phonation without complete velopharyngeal valving. The affected soft palates did not differ from the controls as much in resting length as in thickness. Diminished velar thickness suggested an intrinsic defect in the muscular components that constitute the velum. . . . The SF is an active process . . . dependent on the load imposed, the available muscle mass, the range and speed of movement, and the activity of other muscles involved in the synergy.

In 1972 R. K. Simpson and A. A. Austin measured a 20 percent average increase in the length of the soft palate during activities associated with speech in 20 normal adult speakers. In 1975 Arthur P. Mourino and Bernd Weinberg of Richmond, Virginia, made a cephalometric study of velar stretch in forty 8- and 10-year-old children who spoke normally. They found:

Although 36 children (90%) exhibited velar stretch during the production of /u/ and 32 children (80%) exhibited stretch during sustained /s/, in 12 observations velar stretch was not present during speech. . . . On the average, 10-year-old children exhibited significantly greater velar stretch during both /u/ and /s/ utterances than did 8-year-old children . . . [and only half the amount reported in adults]. These observations suggest that the average degree of velar stretch may increase as a function of chronologic age.

It is vital that closure of the palate cleft not interfere with but facilitate the ultimate velar stretch. Detachment from the bony edge, reconstruction and repositioning of the levator muscle sling with careful approximation of the remaining velar musculature with minimal scarring set the stage. Interruption of the straight-line scar of union aids stretch, and maintenance of palate lengthening reduces the amount of stretch necessary. Both of

these adjuncts are increased by oral mucoperiosteal pushback relieved on the nasal side by a Z-plasty or, better, by introduction of new tissue such as an island flap, tip of a long pharyngeal flap or cheek mucosal flap or by sliding the nasal mucosa.