

30. *The Nasal Defect After Pushback*

ONE century ago the American Indian was undergoing "operation pushback" on the frontier of the New World, while in Europe the palate also began to be subjected to "pushback" operations. As Newton noted, for every action there is an equal and opposite reaction: The Indians resisted the push with tomahawks and flaming arrows, while raw areas of pushed-back palates granulated and contracted.

On June 25, 1876, Chief Crazy Horse and his bands of Sioux and Cheyenne warriors wiped out General Custer and his men at the bloody battle of Little Big Horn. Meanwhile, in Paris from 1876 to 1878, Passavant, experimenting with various pushback palate procedures, became discouraged by contracture as did others who followed him. Not until over half a century later and many a "last stand" in palate pushback did surgeons begin to develop a defense against the "Little Big" nasal raw area.

As surgeons became more dedicated to lengthening the soft palate toward the posterior pharyngeal wall, the number of pushback procedures increased. Surgeons like Dorrance, Brown, McDowell and Byars were radical enough and divided the nasal mucosa from the posterior edge of the hard palate, increasing the immediate effective pushback lengthening. This left the nasal side raw for the exact amount of pushback, and gradually the length obtained at operation diminished.

In 1952 Wallace Steffensen reviewed the palatal lengthening operations and expressed a feeling that more accurate records of





Randell Champion

end results of various methods of lengthening should be kept for future evaluation.

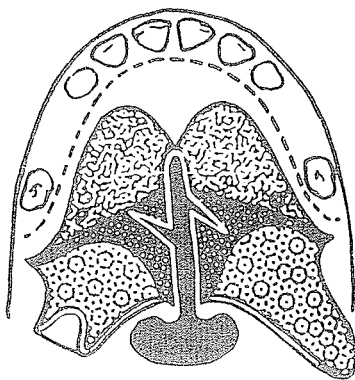
Randell Champion of Manchester, England, noted in 1957:

In the standard V-Y closure of a cleft palate the palatal mucous membrane of the soft palate is lengthened by reflecting the mucous membrane from the hard palate and then suturing the hard palate mucous membrane in a more posterior position, incorporating some of it in the soft palate. The nasal mucous membrane is reflected from the medial and posterior edge of the hard palate but is not lengthened or transposed backwards. . . . Thus with healing the palate mucous membrane tends to return to its original position because there is no corresponding lengthening of the nasal membrane to maintain the lengthened velum.

In 1960 James Calnan of London observed that after certain V-Y retropositioning operations there was failure to obtain the expected length. He offered the presence of midline fistulae at the posterior border of the hard palate as evidence of breakdown and fibrosis with contracture of the soft palate. Even in the absence of a fistula, he presumed a hidden breakdown and scarring of the nasal mucosa with resultant contracture. Thus, as the evidence mounted, more surgeons were stimulated toward more sophisticated efforts of coverage of this nasal area.

Z - P L A S T Y

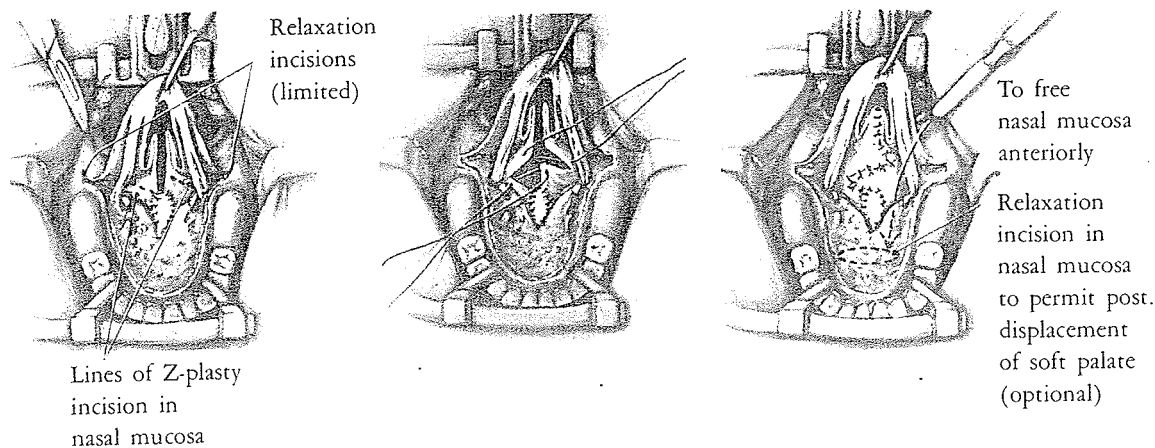
A standard lengthening procedure, of course, is the Z-plasty, and some surgeons have advocated this principle for lengthening the nasal lining. In 1957 Champion wrote in the *British Journal of Plastic Surgery*:



The nasal membrane may be lengthened by undertaking a Z-plasty of the nasal mucous membrane. This small plastic manoeuvre is of utmost importance in the primary repair of a cleft palate and may make the difference between normal and imperfect speech. The Z-plasty also tends to reduce the palatopharyngeal opening. In a small percentage of primary repairs it is not possible to perform the Z-plasty, particularly in clefts involving most of the hard palate. . . . In secondary repair of palate the creation of a large Z-plasty or two smaller Z-plasties may materially influence the final result.

In 1962 in *Plastic and Reconstructive Surgery* Edgerton advocated palatal lengthening with sharp dissection of the neurovas-

cular bundles. This resulted in a shortness in the nasal mucosal lining. He chose the Z-plasty principle for lengthening the nasal mucosa.



As the presence of a cleft in the palate usually indicates lack of tissue in the transverse dimension, it is a contradiction in logic to expect to get anterior-posterior lengthening with a Z at the expense of side-to-side tightening.

SPLIT-SKIN GRAFT

Baxter

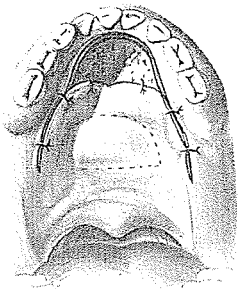
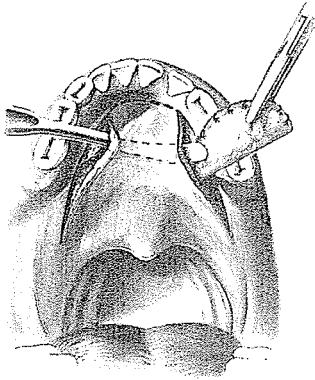
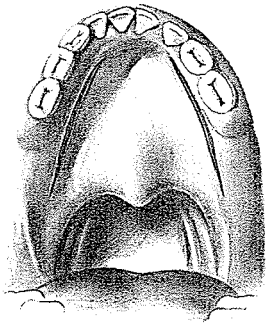
Hamilton Baxter, a Canadian surgeon in Montreal, had also become pessimistic about the fate of the nasal raw area after palate pushback. He had the plastic sophistication to extend the principle of "cover to all raw area" to the superior, "out of sight" surface of the palate. In 1942 in the *Canadian Medical Association Journal* "Happy" Baxter proclaimed the not-so-happy fact that the von Langenbeck procedure not infrequently failed to achieve normal speech and gave his explanation:

This is due to the anterior pull of the contracting scar tissue on the nasal side of the mucoperiosteal flaps so that the velum cannot be brought into contact with the velopharyngeal wall, and speech assumes "cleft palate" characteristics.

In the severely shortened palate, where all the length achieved by a pushback was essential for good speech, Baxter devised a method, in 1942, which he said would



Hamilton Baxter

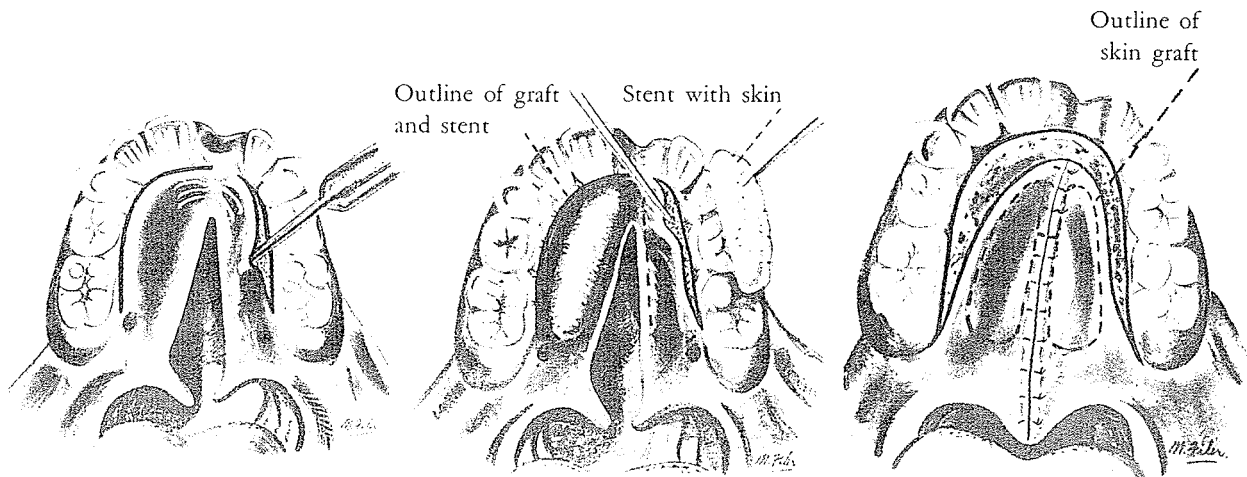


avoid the thickening and shortening which an unlined flap with its raw surface exposed will always undergo, irrespective of its situation in the body.

Inspired by Gillies' application of Esser's principle of a skin graft on a stent to the raw bony surface in the Gillies-Fry pushback, Baxter made two lateral incisions in the mucoperiosteum a few millimeters from the teeth, extending from the tuberosity of the maxillae forward to the canines. The posterior palatine vessels were divided, and the mucoperiosteum between these incisions was elevated. For this tunnel a piece of red wax was fitted, covered with a thick split-skin graft from the hairless buttocks and then inserted as an inlay. The incisions were sutured and left for one month. Finally, the stent was removed and the anterior release completed with a Dorrance incision, allowing a radical pushback of the palate. The nasal surface of the mucoperiosteum, having been lined with skin, was expected to show little or no tendency to contract and foreshorten the elongated palate.

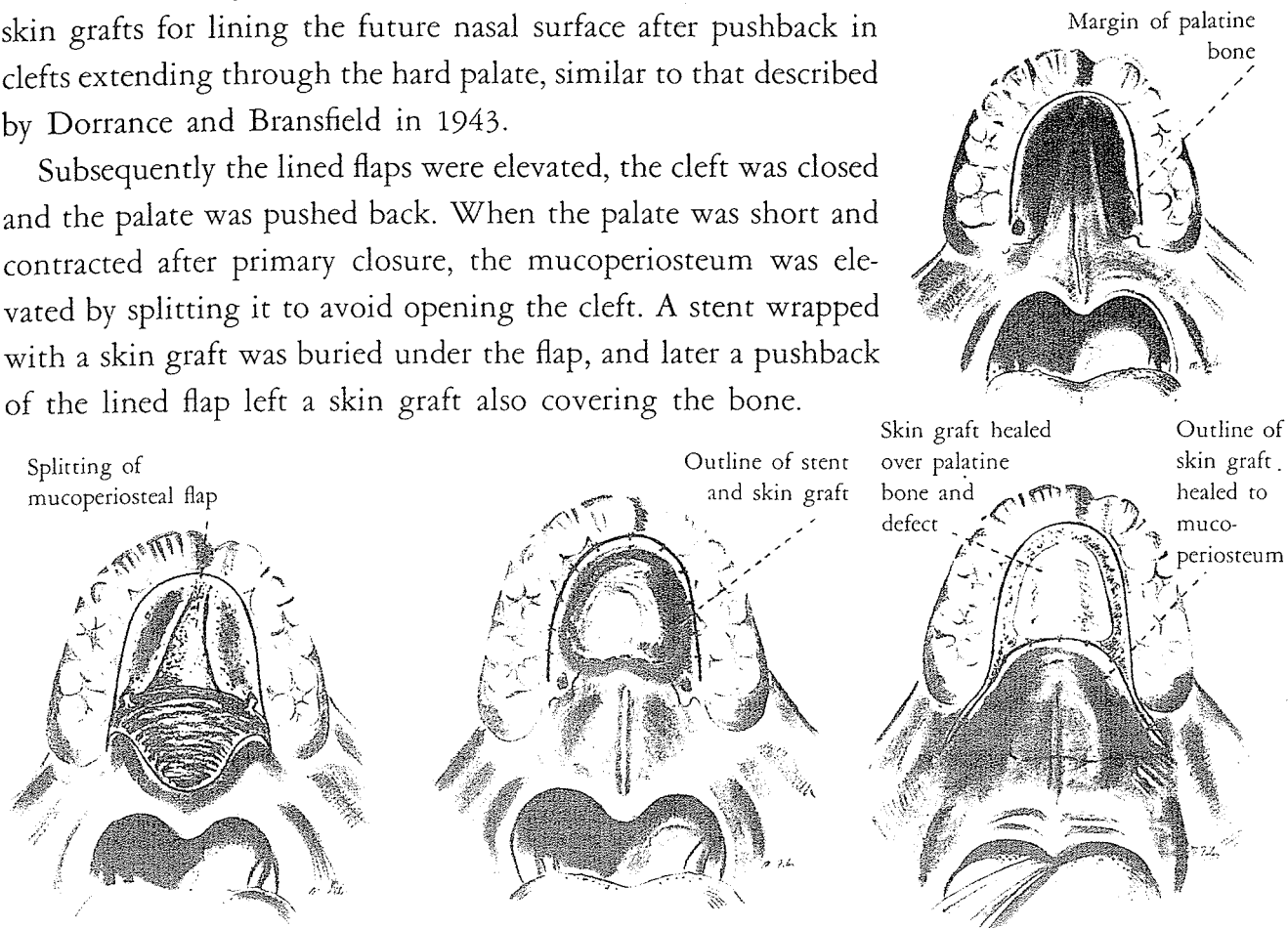
Five years later in 1947, and four years after Dorrance and Bransfield published their method of applying skin grafts to line the raw nasal surface of mucoperiosteal flaps for pushback in *seven* types of palate defects, Hamilton Baxter and Mary Cardoso of McGill University and Children's Memorial Hospital, Montreal, noted:

Since many surgeons working independently have sometimes reported new methods co-incidentally, no one man can lay complete claim to an operative procedure, since tribute must be paid to the experiences of preceding and contemporary surgeons whose efforts have provided the foundation on which some technical refinement is based.



They then reendorsed their skin graft method in *Plastic and Reconstructive Surgery* and used these diagrams to show bilateral skin grafts for lining the future nasal surface after pushback in clefts extending through the hard palate, similar to that described by Dorrance and Bransfield in 1943.

Subsequently the lined flaps were elevated, the cleft was closed and the palate was pushed back. When the palate was short and contracted after primary closure, the mucoperiosteum was elevated by splitting it to avoid opening the cleft. A stent wrapped with a skin graft was buried under the flap, and later a pushback of the lined flap left a skin graft also covering the bone.



They reported speech results better than those following the ordinary operative procedures. They also noted:

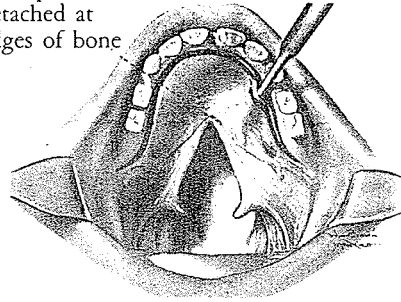
In all cases examined by nasopharyngoscope, the graft was found to be viable and with no evidence of crusting or offensive odor. Grafts over a year old had developed a pinkish color and one graft which was five years old had evidently undergone considerable metaplasia, for only a faint whitish tinge differentiated the graft from the surrounding mucosa.

Dorrance also using skin grafts

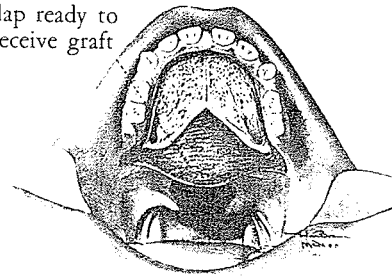
Obviously, Dorrance too had become concerned about the raw area on the nasal side of the lengthened portion of his palates. In 1943, with John Bransfield, he described a modification of his two-stage pushback which applied skin grafts to this area. They designed its use in seven types of cleft defects and published their work in the *Annals of Surgery*. In the first stage the mucoperios-

teal flap was elevated, a split-skin graft applied to the undersurface and the lined flap replaced in its original position. In the second stage the "push-back" procedure was carried out as previ-

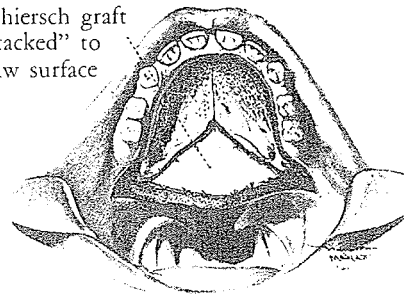
Mucoperiosteum detached at edges of bone



Raw surface of flap ready to receive graft

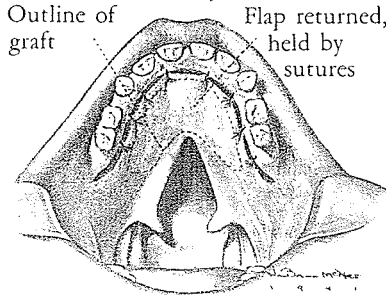


Thiersch graft "tacked" to raw surface

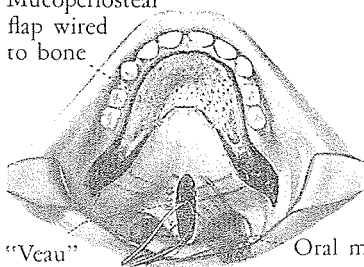


Outline of graft

Flap returned, held by sutures



Mucoperiosteal flap wired to bone

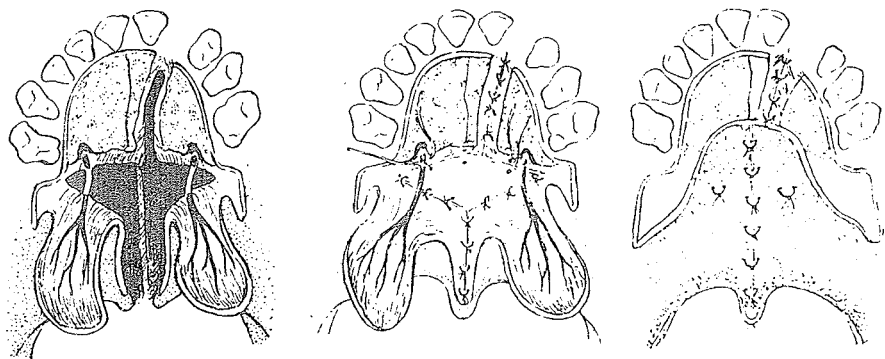


"Veau" wire in position

Oral mattress sutures placed

ously described, but the sliding portion of the mucoperiosteal flap now was lined with skin grafts, which ensured maintenance of the acquired length by reducing contracture. The cleft in the velum was closed at this time.

In 1955 R. Ruding of Amsterdam presented his release of the nasal mucosa and closure with a Thiersch split-skin graft. In 1977 he wrote:



Later on, I saw that the skin transplantation was not necessary and abandoned it for muscle correction, described in 1964.

Brown holds his nose

Barrett Brown's eventual response to this nasal skin graft was not without a nasal grimace. He explained that skin grafts on the nasal surface of the palate pool mucous discharge, resulting in desquamation of epithelium and producing a *foul odor*. As he gladly applied split skin by the yard almost everywhere else on the body, it is noteworthy that he was adamantly against it for surfacing the nasal raw area in palate pushback procedures. Thus any popularity enjoyed by this approach was soon snuffed out.

FREE GRAFTS OF MUCOSA

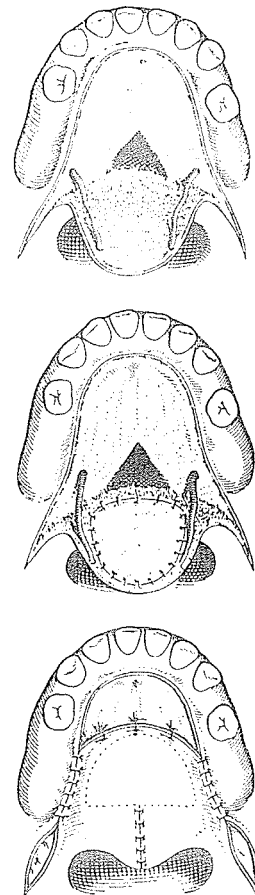
In 1949 Richard C. Webster of Brookline, Massachusetts, commented that skin grafts in palatal lengthening were becoming more and more popular in spite of the reports of contracture and crust formation. He also said:

In addition, there is the possibility that hair will grow on a certain number of these grafts; and hair on the nasal side of the soft palate would be disagreeable, to say the least.


Webster reported his use of free mucosal grafts to line the nasal side of the pushback:

Following a discussion with Dr. Bradford Cannon, the reviewer [Webster] has used mucous membrane grafts applied to the nasal side of the mucoperiosteal flaps. The mucous membrane grafts were taken from the buccal mucosa and applied in the first stage of a two-stage "push-back" procedure. In the second stage, the flaps were elevated and the palatal tissues retro-displaced. There has been no evidence of crust formation where these free transplants of buccal mucosa were made.

Victor Spina, with Lodovici, Pigossi and Faiwichow of São Paulo, Brazil, in 1961 in *Revista Latino-Americana de Cirurgia Plástica*, suggested a one-stage pushback procedure using a free graft of buccal mucosa—Cardoso's method—to cover the open wound on the nasal area of the elongation. Yet the difficulty of obtaining such a graft, the irregularities of the base, the inaccessibility of the area for dressings and the hazards of an unseen "take" and survival have been responsible for little acceptance of this approach.



SLIDING NASAL MUCOSA



Thomas Cronin

Thomas D. Cronin of Baylor University College of Medicine, Houston, is quiet, mild and most unlike a textbook Texan. In 1971 he reaffirmed Dorrance's 1933 and 1943 dogmatic declarations:

Most cleft palates are also short palates, and repair of the cleft alone is likely to leave the patient with an incompetent velopharyngeal mechanism. Retrodisplacement of the soft palate is one of the more obvious remedies, but to achieve this posterior movement it is necessary to sever the nasal mucosa from the bony palate. When the velum is shifted back, however, a raw area is left on the nasal side of the mucoperiosteal flaps. While an effective lengthening can be obtained at the operating table, the scar contracture of the healing raw area on the nasal surface pulls the velum back almost to its original position.

In 1957 Cronin proposed posterior advancement of mucosal flaps from the nasal floor to shift the raw area to a bony surface and reduce the soft tissue contracture. Fourteen years later, he stated:

This operation is recommended as the primary repair in all infants and young children. It may also be used in young children who have a short palate following a simple closure of the cleft. In older children and adults the procedure usually should be combined with a pharyngeal flap or nasopharyngeal implant.

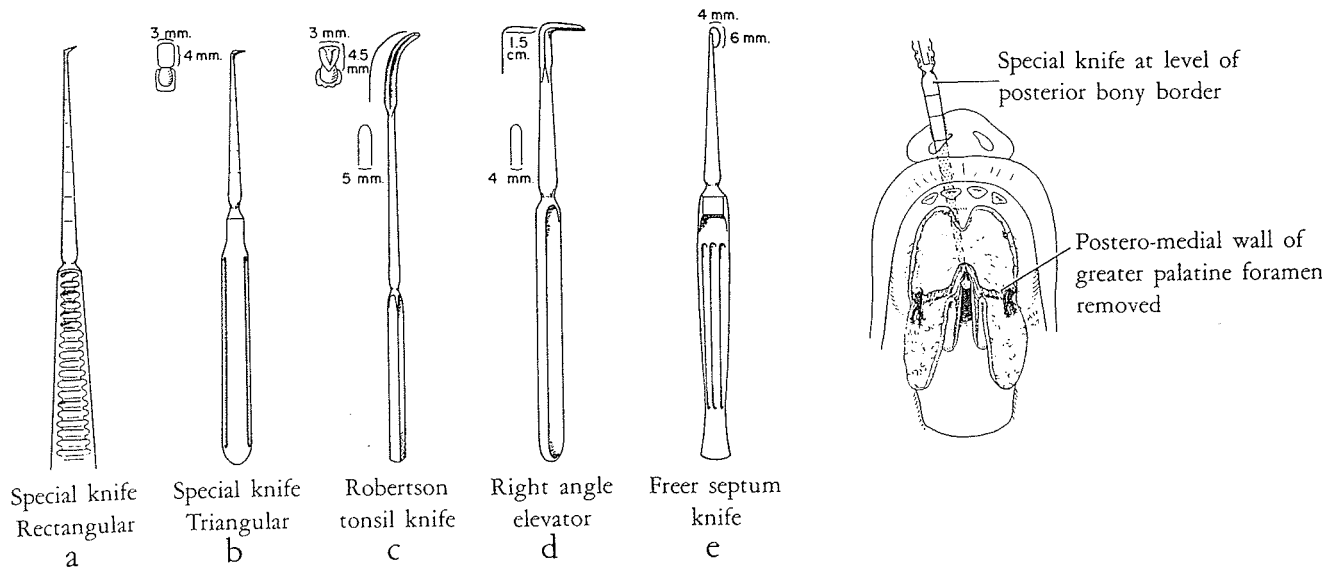
Cronin cautioned:

In order to minimize the adverse effects of scar contracture secondary to elevation of mucoperiosteal flaps on bone growth, the pushback procedure should not be performed before 2 years of age in unilateral clefts of the primary and secondary palates, or in clefts limited to the secondary palate. Repair of complete bilateral clefts should be delayed until the age of 2½ years.

*Probably
not long
enough*

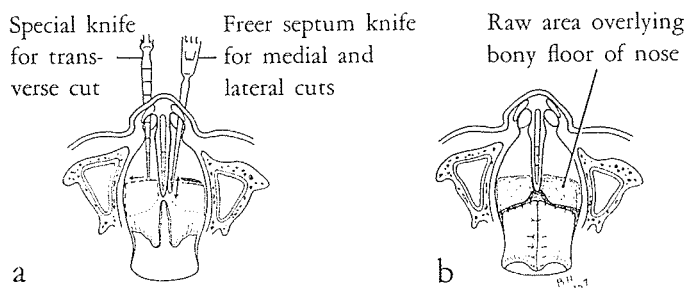
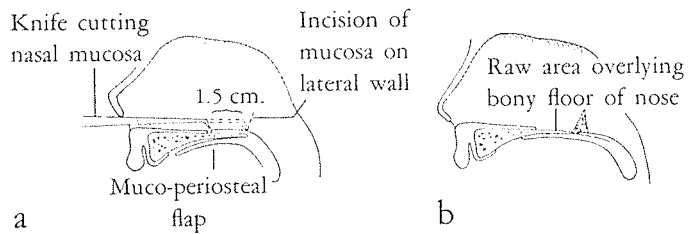
Operative details

The Ganzer-type mucoperiosteal flaps are elevated and Limberg's ostectomy is used to free the neurovascular bundles. Then Cronin gets out his bag of new short irons. First, his right-angle knife is inserted through each nostril and passed backward until seen at the posterior edge of the hard palate in the cleft. The instrument



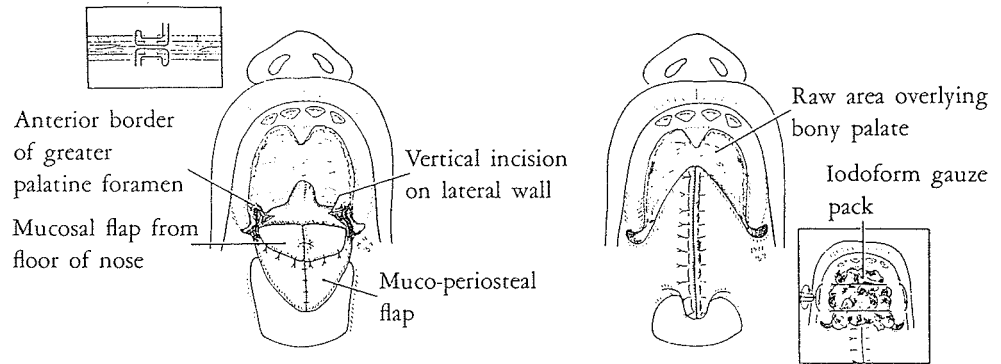
is then withdrawn 1.5 cm., and the blade is moved transversely from side to side several times across the rather irregular floor of the nose. Then the Freer knife is passed through the nostrils and is used to cut the mucosa on the lateral and medial boundaries of the nasal floor.

In incomplete clefts, this action is entirely blind; in complete clefts where access is possible a right-angle scissor may help in the transverse cut of the nasal mucosa.



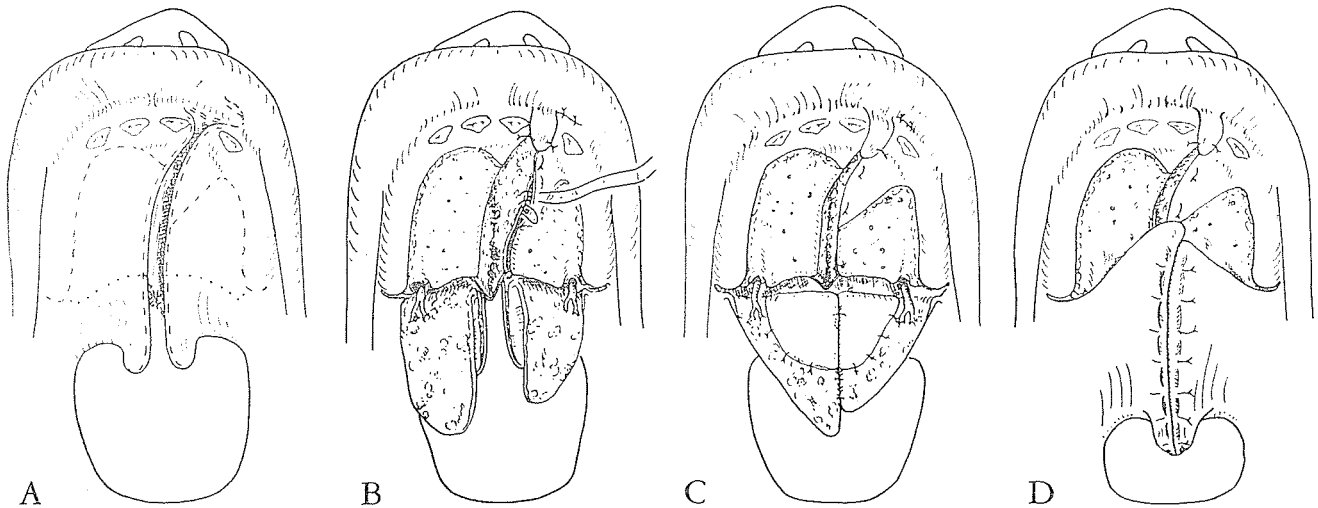
Now, and not until now, the aponeurosis is detached from the posterior border of the bony palate with a Freer septal elevator, being careful not to tear the thin nasal mucosa.

Further nasal mucosal freeing and release will eventually allow the palate to move backward, dragging its thin mucosal flaps with



it like a bridal train. Hamular fracture is used when indicated. Suture of all flaps to one another and apposition of the oral mucoperiosteal flaps with iodoform packing under guy wires passed through the gums complete the operative procedure.

This was Cronin's 1957 design for closing and repositioning the soft palate at one operation in a narrow single cleft. (A) The broken lines showed the mucosal sulcus flap, an anterior triangular mucoperiosteal flap and two remaining asymmetrical mucoperiosteal flaps. The dotted line marked the division of the soft



palate attachments to the hard palate. (B) The vomer flap was turned under the anterior triangular flap and the mucosal flap from the sulcus gave oral closure in the alveolar area. (C) The nasal mucosa had been shifted to cover the advancing mucoperiosteal flaps. (D) The longer mucoperiosteal flap was shifted toward the cleft side to avoid two superimposed suture lines.

Pre-pushback marking

The posterior bony edge of the hard palate and the point in the nasal mucosa detached from this edge are marked with 28-gauge wire knots to measure the actual lengthening achieved at one week and at two months after pushback. A single lateral x-ray view was taken with the central rays directed 1 inch anterior to and 1 inch below the external auditory meatus.

Postoperative measurements

In 1965 Ray Brauer, Cronin's Texas "pardner" for over 20 years, reported on the x-ray examination of 85 patients, 10 of whom had lost their wires before completion of the study. Of the 75 remaining patients, 46 percent revealed a contracture of 1 mm. or less and 37 percent a contracture of 2 to 3 mm. Seventeen percent showed 4 mm. or more of contracture, and of these cases six were posterior clefts (blindest type)—three horseshoe clefts and three wide clefts through half the hard palate. As pointed out by Brauer:

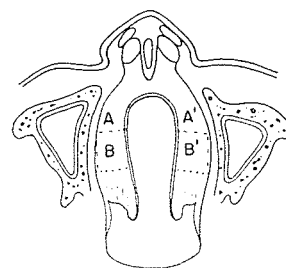
The extremely wide clefts, especially the posterior and the horse-shoe type, coupled with inadequate nasal flaps, are the major factors resulting in excessive contracture.

Here is Cronin's diagrammatic sketch published in *Plastic and Reconstructive Surgery* in 1957, displaying the complex shifting of nasal mucosa in a wide, horseshoe-shaped defect. A flaps swing in together, B flaps swing back, leaving an area (C) still raw on the nasal side.

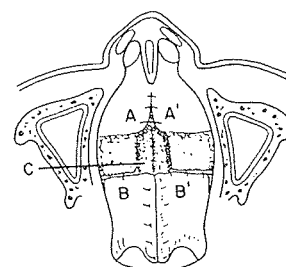
However, it was possible to claim

an overall average for all cases of 12 mm. with a contraction average of 2 mm. or an overall gain of 10 mm.

This approach has its ardent followers because it is logical and reasonably sound in principle. For instance, in 1970 Manchester described his modification of the Cronin nasal advancement principle along with a V-Y retropositioning of the oral muco-periosteum in his second stage of complete bilateral clefts.



A



B

Yet it is technically difficult, because it calls upon *blind* and *bloody* dissection of *thin* mucosa, requiring a whole new bag of clubs. Its only physiological “drawback” is the denudation of *both* sides of the bony palate.

When needled about such plastic acrobatics, Cronin responded:

All of the residents and preceptees in our plastic surgery training program in Houston have learned to raise the nasal flaps successfully.

Whereupon Herb Conway, with typical Irish wit, retaliated:

But I would have to go back through a residency, and even then I doubt if I could ever do it!

Moore and Chong of East Grinstead, England, stated in 1967:

Cronin (1957) advocated the use of flaps of mucosa from the floor of the nose to cover the raw areas of the lengthened soft palate, the flaps being raised by a special knife introduced through each nostril. The technique, though in theory sound, was in practice difficult and did not gain universal approval.



David Stark

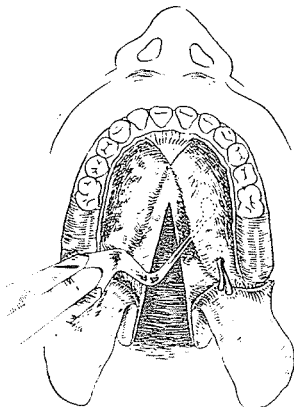
NASAL MUCOSA TRANSPOSITION

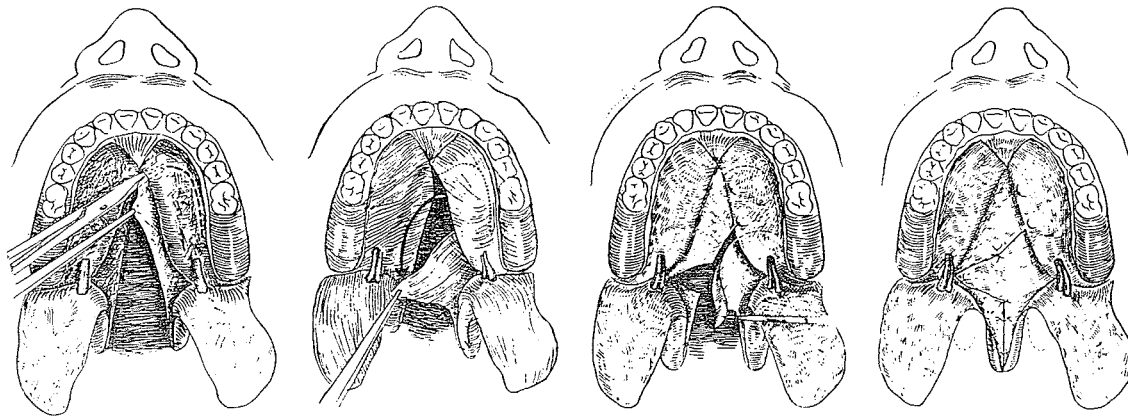
David B. Stark of the State University of New York, Syracuse, in 1963 described a variation in the use of nasal mucosa. Accompanying the standard Wardill-Kilner V-Y oral flap design, he utilized the nasal mucosa to achieve lengthening with closure in a staggered line. He freed the nasal mucosa of one palate shelf, and with its base posterolateral transposed it into the usual transverse releasing incision in the nasal mucosa, along the posterior edge of the hard palate. This is the nasal rendition of the transposition lengthening that Cuthbert described in oral mucoperiosteal lengthening.

In 1976 Stark confirmed his continued use of the nasal flap:

It is the simplest, of course, to do in the partial cleft where the procedure is really a proper Z-plasty.

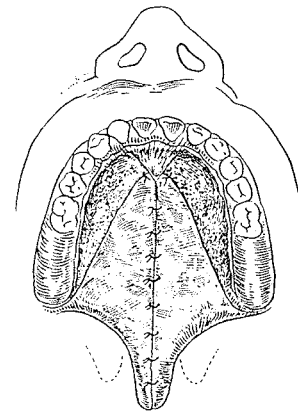
In the complete cleft, I do the anterior palate defect repair with a vomer flap and a labial flap between the alveolar ridge defect to prevent a pre-alveolar fistula. The second stage repair done about two months later will be





determined by the position of fixation of the vomer to the uncleft side palatal shelf. Frequently the repair will be anteriorly with a vomer flap brought across and posteriorly with the nasal lining flap based on the posterolateral area of the cleft side. In most instances this allows for complete closure of the nasal surface and for as much retrodisplacement as you wish.

Actually, my problem has been a deficient length of oral mucoperiosteum if the setback is allowed to be as great as can be produced by the nasal lining. In other words, the restriction of retrodisplacement is due more to lack of length of the Wardill type of oral mucoperiosteal flaps than to a problem of getting coverage on the nasal surface of the lining flap.

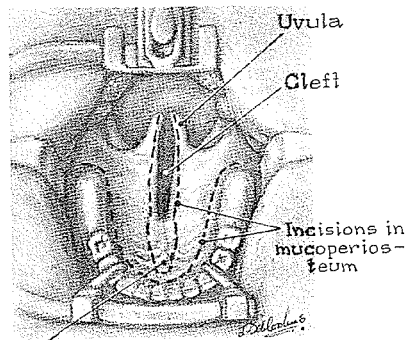


This method seems to suffer some of the problems of the Cronin approach. It requires blind dissection and may offer limited lengthening, but it certainly denudes both sides of the hard palate of its covering mucosa and mucoperiosteum.

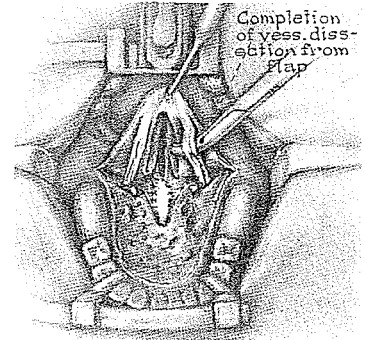
A TURNOVER FLAP FOR HARD PALATE NOTCHES

A mucoperiosteal flap based posteriorly on the edge of the cleft to be turned backward to present mucosa for the nasal lining in the cleft is based on the Krimer principle and was used on a large scale by Bonfils in 1830. Over 130 years later, Edgerton reduced this same flap to fill notches in the hard palate only, as shown in his illustrator's drawings presented in *Plastic and Reconstructive Surgery*, 1962.

The concept appealed to me, but in actual practice, in my experience, the flap has a poor blood supply and does not remain



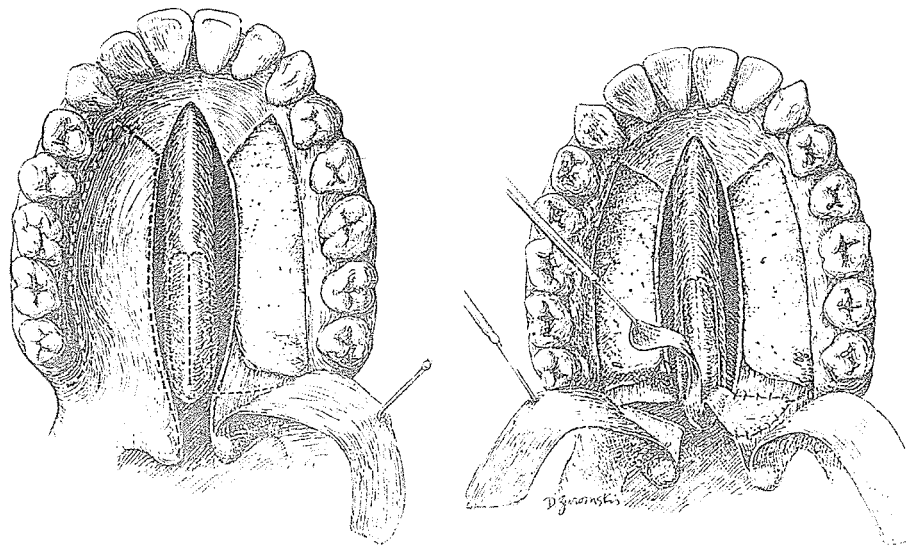
"Turnback" flap for nasal floor



viable. It is interesting that the drawings for Edgerton, by their realistic shading, forecast doom for this little flap by leaving it white, just as I have seen it at the end of an operation. The point being made here is: Beware of flaps on the palate meridian, particularly at the attenuated edge of the cleft.

VOMER FLAPS


Charles Horton of Norfolk is extremely adept at many things, and one of them is maneuvering mucosa into areas of need. In 1973 in *Plastic and Reconstructive Surgery*, with T. Irish, J. Adamson and R. Mladick, he described the use of vomerine mucoperiosteum to be turned as two long narrow flaps based posteriorly and sutured into the transverse nasal mucosal defect created by the division of the soft from the hard palate in a pushback.



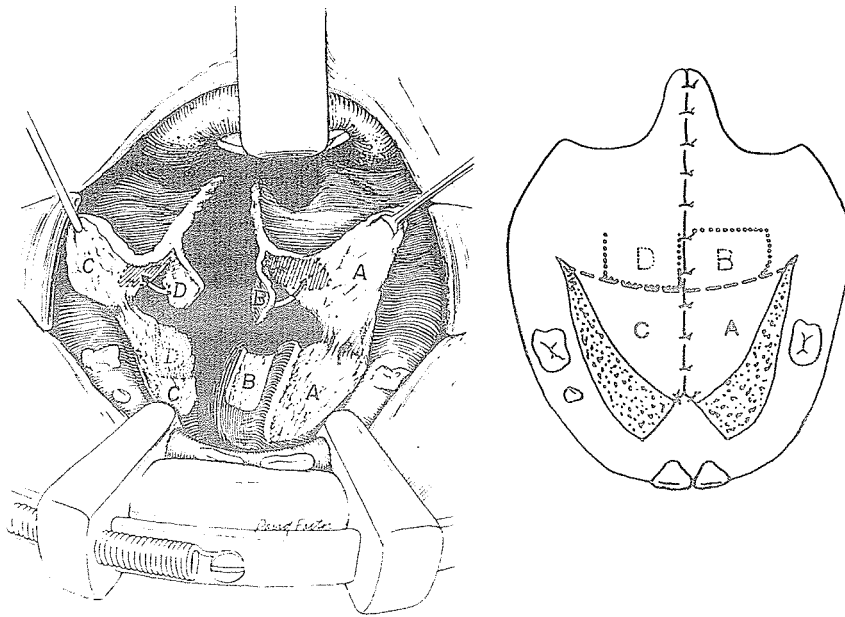
Horton wrote to me in 1976:

I have used this approach several times over the past few years but it requires a particular kind of case with a large vomer and one in which vomerine tissue is not needed elsewhere.

In the 1978 *Cleft Palate Journal* Harold D. Clavin and John Q. Owsley, Jr., of the University of California, San Francisco, presented a posteriorly based vomer mucoperiosteal flap (B) on the cleft side and a nasal floor mucoperiosteal flap (D) (Cronin) on the non-cleft side to supply nasal lining during palatal pushback in unilateral clefts. This combination seems to have some promise. Of course, the disadvantage is the same as with all methods elevating large areas of mucoperiosteum and leaving raw areas: the possible effect of maxillary growth retardation in children below the age of 5 years.

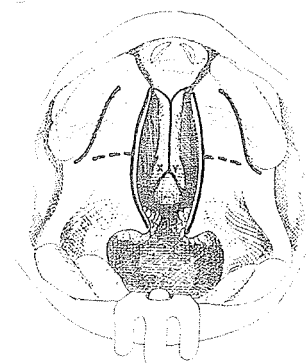


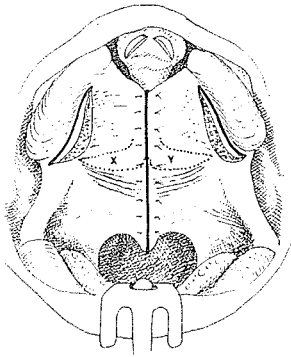
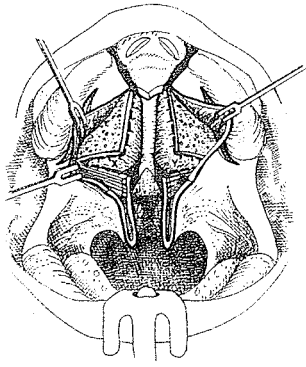
Harold Clavin



Forked Flap from Tail of Vomer

It is possible to utilize the vomerine mucosa for nasal closure of the hard palate in the usual manner and still incorporate posterior extension flaps, shaped like a forked flap, to be transposed bilaterally into velar nasal lining releasing incisions. This maneuver will supply some extra lining for lengthening, without the need for elevation or sacrifice of hard palate mucoperiosteum. It can be



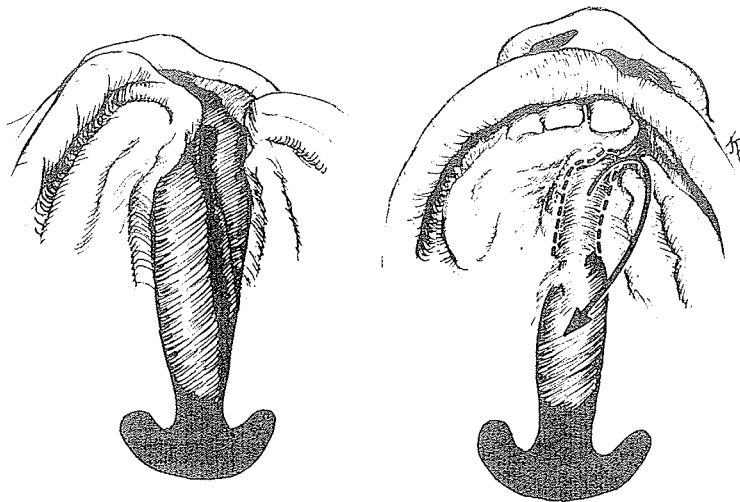


done early and in the primary operation, especially in a bilateral cleft of a short palate where an island flap may never be available.

In 1979 this approach was used in a 3-year-old bilateral cleft of the lip and palate. A midline mucoperiosteal incision along the vomer was extended off the posterior end, circumscribing two posterolateral (forked) flaps (X and Y). This allowed dissection of the usual vomerine flaps which were sutured to the nasal mucosa of the lateral cleft edges of the hard palate. The levator muscle attachments were freed from the hard palate edge and the nasal mucosa divided along the posterior bony border with a release of 0.75 cm. Into these nasal lining defects the forked flaps were sutured and the oral mucoperiosteal closure achieved with von Langenbeck flaps and mattress sutures.

Regenerated vomer flap


Bengt Johanson of Göteborg, combining the principles of "Never throw anything away" and "Get something for nothing," emphasized to me his use of the epithelialized granulation area across the anterior cleft as a flap, no less, to provide some midline lining on the nasal side. It could not, of course, be used to fill a nasal pushback defect.



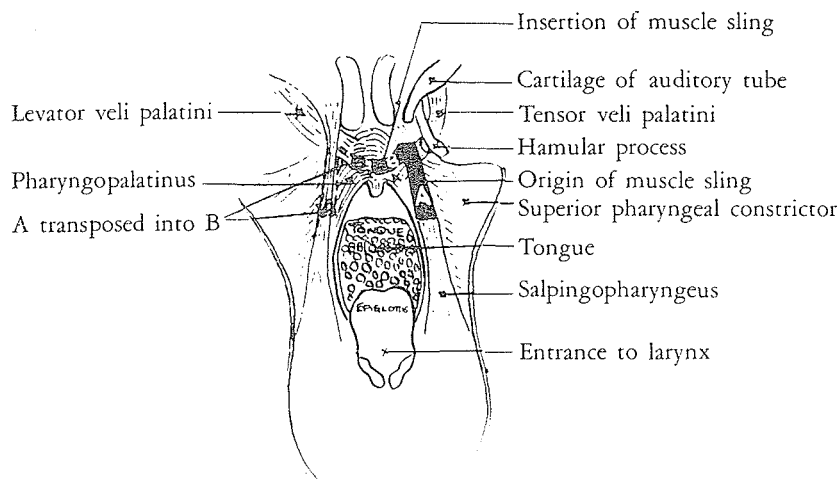
Personally, I would consider this flap a possibility but also a bit unpredictable since it is hidden on the nasal side where its fate is not easily known.

TRANSPOSITION OF LATERAL PHARYNGEAL FLAPS

The feisty F. T. Moore of Queen Victoria Hospital, East Grinstead, England, designed a secondary procedure which transposed the Hynes-type flaps for nasal lining of the velum (*British Journal of Surgery*, 1960). This obliterated the lateral recesses of the nasopharynx, lengthened the soft palate and produced a mass of tissue on the upper surface of the soft palate to facilitate contact with the pharyngeal wall, and augmented the elevation of the soft palate by a contractile muscular sling. He split the soft palate in the midline to facilitate the cutting of two thick muco-



Jerry Moore




muscular flaps, one from each posterior pillar with the base above. A transverse mucosal releasing incision was then made on the superior nasal surface of the soft palate, about halfway between the uvula and the hard palate edge. The two flaps were transposed 90 degrees, as in a Hynes, but let in on top, across the soft palate, instead of across the posterior pharyngeal wall.

Moore reported that out of 15 cases of rhinolalia from various causes such as cleft palate, congenital short palate and suprabulbar agenesis, normal speech had developed in 12 in three months, with three requiring three to six months of speech therapy.

Sullivan

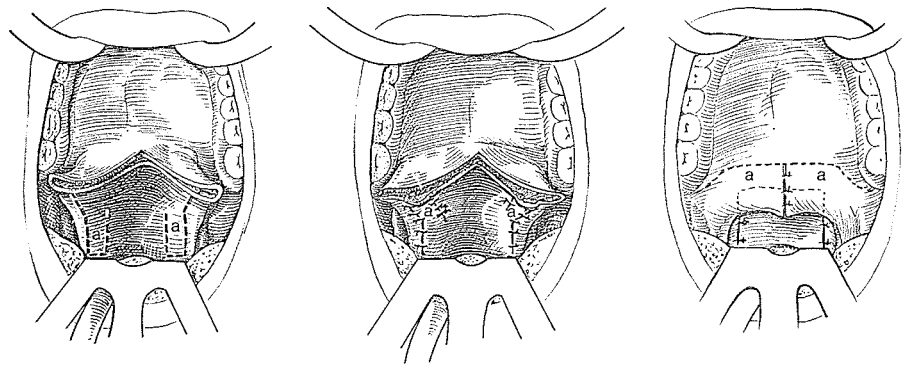
With results like these, it is amazing that more surgeons did not drop what they were doing to follow the same approach. Perhaps the illustrations required too much concentration and imagina-



David Sullivan

tion to decipher the game plan. Fortunately, David Sullivan of Spokane personally observed the deft Jerry Moore demonstrating his bilateral pharyngoplasty in 1959. In 1961 Sullivan endorsed the method and reported on 13 cases with rhinolalia in which he obtained normal speech in six but improvement in all.

A 10-year follow-up report in 1971 by Sullivan corrected the title of the procedure to "Bilateral Pharyngeal Wall Flaps to Soft Palate." He reported 26 additional cases, two of which were overcorrected, resulting in denasality and requiring partial reopening of the constricted nasopharynx. Moreover, since many of his failures occurred in patients 15 years and older, he preferred to operate at 5 to 10 years, and the earlier in that range the better.



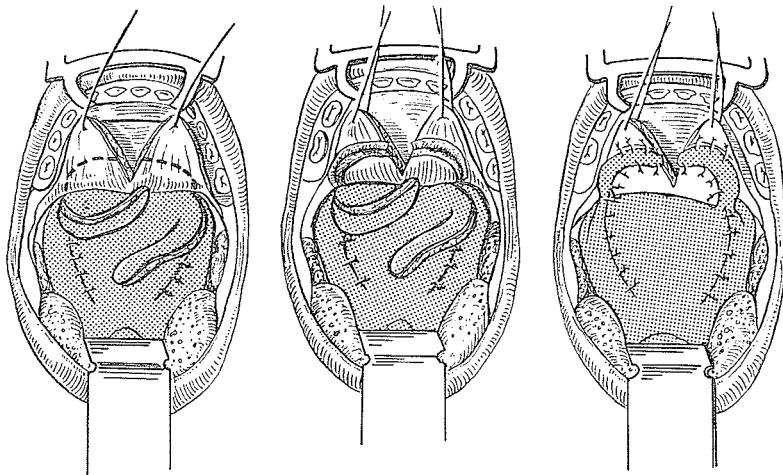
In 1972 Sullivan wrote me more about his experience with this procedure, which he suggested might be entitled "The Irish Connection":

As I have attained experience with this operation, I have noted that I am cutting the flaps broader and not longer. The area I leave undisturbed on the posterior pharyngeal wall corresponds almost exactly with the area which most surgeons use in applying a midline posterior pharyngeal wall flap to the soft palate. The anterior margin of each flap lies immediately behind the posterior tonsillar pillar. Hence the greater the lateral recess, the greater the width of the flap. This has a tendency to standardize the size of the midline velopharyngeal opening which is left. The most obvious correction I would make in my original drawings would be to make the bilateral flaps broader. . . .

After the bilateral flaps have been switched and the donor areas on the lateral pharyngeal walls closed, the suction test is tried and if positive the

surgery is over. If the test is still negative, the need for lengthening the soft palate exists. If the patient's condition is satisfactory, a V-Y lengthening is carried out at once. Your turned-over island flap has been most helpful in closing the defect on the nasal aspect.

Richard Yules, an otolaryngologist in Worcester, in his 1971 *Atlas for Surgical Repair of Cleft Lip . . .*, illustrated the method from a different perspective in an attempt at greater clarity.



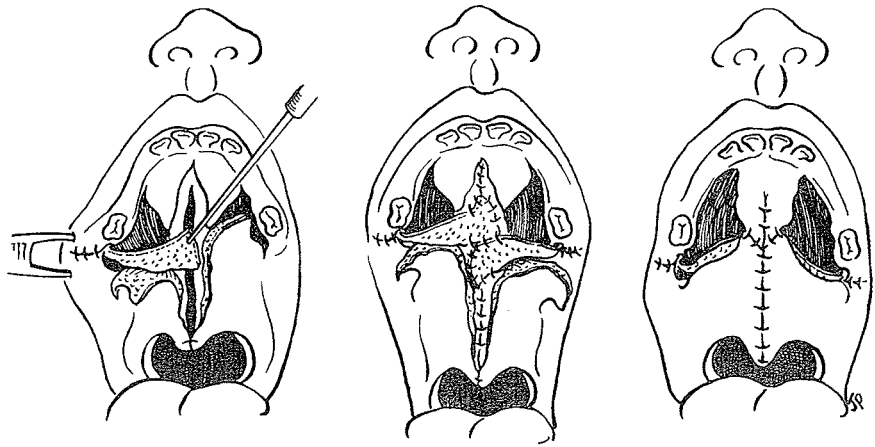
This principle builds another bump against rhinolalia. It has some of the advantages of Hynes' approach with the reduction of the lateral recesses and merely places the bulge on top of the palate instead of at the back of the throat. It also achieves some lengthening of the nasal mucosa.

CHEEK FLAPS

Murari Mohan Mukherji of Calcutta trained in Edinburgh under A. B. Wallace. In the 1969 *Cleft Palate Journal* he proposed cheek flaps as an excellent source of "extraneous tissues" for a number of cleft palate babies. In order to avoid creating abnormal anatomy with a pharyngeal flap or going through the difficult stages of an abdominal tube pedicle—and he has plenty of experience with both—Mukherji suggested mucosal cheek flaps. These pedicles are 1.5 cm. wide and 5 to 6 cm. long, based near the anterior pillar of the fauces; care is taken to avoid the parotid duct.

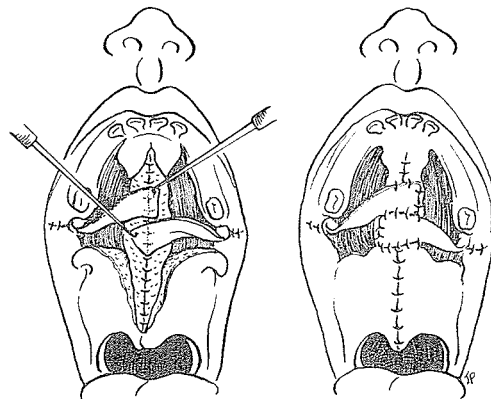


Murari Mukherji



Mukherji noted that these pedicles,

when brought to the palatal region . . . are found to fit comfortably between the soft palate and the hard palate, between the four flaps of the universally accepted Wardill-Veau operation. These cheek flaps are safe even with rotation of their bases and have great versatility. They can be used to line the nasal defect in a pushback and be covered with the standard V-Y oral mucoperiosteal flaps.

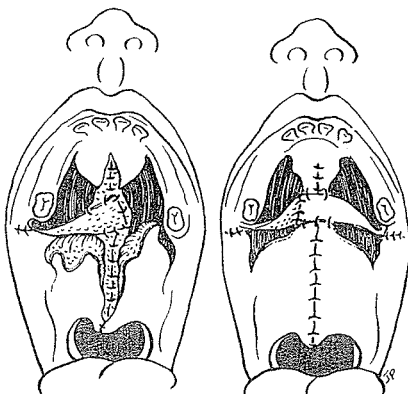


Oral Side

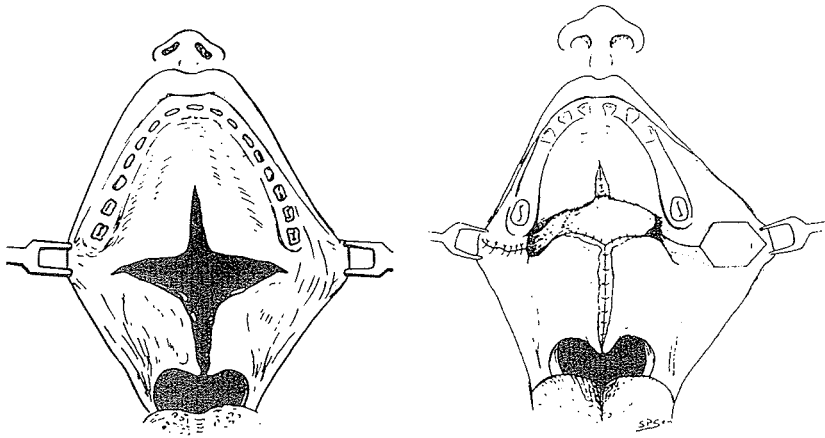
They can be used on the oral side in conjunction with a V-Y procedure.

Combination

They can be used in combination, one for nasal closure and one for oral closure, during a V-Y to insure 1.5 cm. pushback.



In 1971, at the Melbourne International Congress, A. C. Ganguli of the Post-Graduate Institute in Calcutta, India, gave Passavant credit for the first use of a cheek flap from the alveolar buccal sulcus. He then advocated bilateral submucous pedicle cheek flaps for both the nasal and oral lining during a releasing pushback procedure. The soft palate was detached from the hard

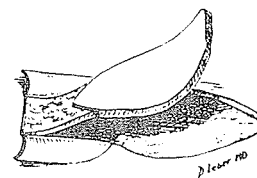
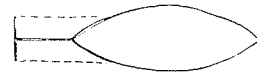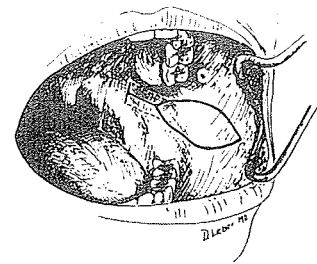
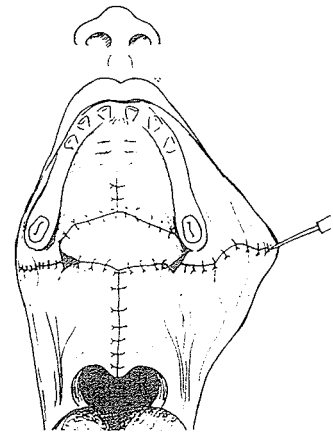


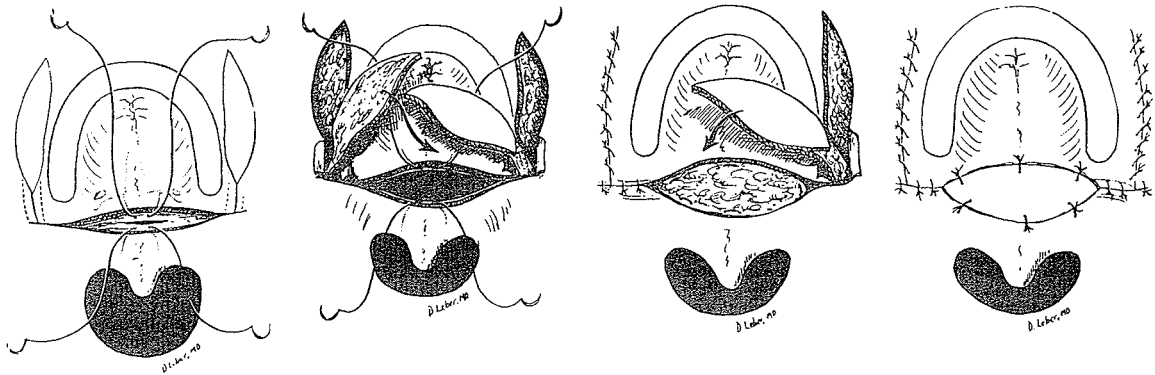
palate with a through-and-through incision and the soft palate retroposed. The margins of the cleft of the soft palate were pared. A hexagonal flap $1\frac{1}{4}$ inches long and about $\frac{1}{2}$ inch wide was cut from the cheek mucosa along the line from the angle of the mouth toward the commissure. The proximal portion of this flap was taken as a submucous, subcutaneous pedicle so that the flap could be pushed under the mucous membrane from the region of the molar tooth into the palate defect with cover to the raw pedicle. The flaps were taken bilaterally, with one for the nasal and one for the oral side. Ganguli noted:

Taking of flaps from the cheek did not produce any functional disability of the mouth. Follow-up study revealed that the length of the palate was adequate and the mobility of the soft palate satisfactory with efficient velopharyngeal closure.

In 1974 Culf, Chong and Cramer of Philadelphia modified the cheek flap for palate defects described by Ganguli. In *Symposium on Management of Cleft Lip and Palate and Associated Deformities*, with illustrations by D. Leber, they presented their design, applicable when bilateral hemi-palate island flaps were not available.

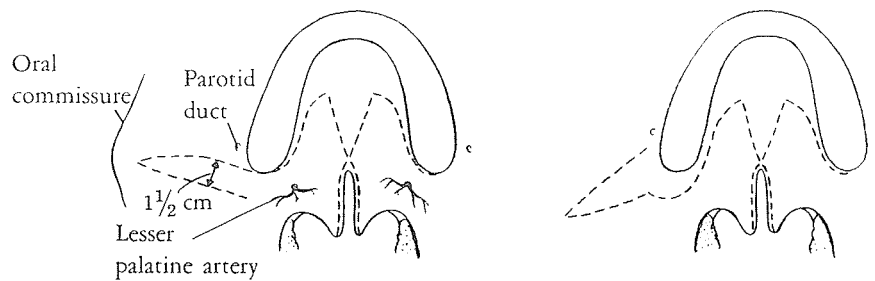
The buccal island flaps were each outlined as an elongated, diamond-shaped flap avoiding the parotid duct, with the base of the pedicle close to the posterior border of the hard palate but not crossing the alveolar ridge or the pterygomandibular raphe. The buccal mucosa was peeled back to facilitate dissection of a broad subcutaneous pedicle. The soft palate was divided from the hard palate edge in the usual pushback fashion, and the two cheek flaps were interposed into the gaping defect on top of each other, sandwich fashion, for nasal and oral lining.





Ernest Kaplan

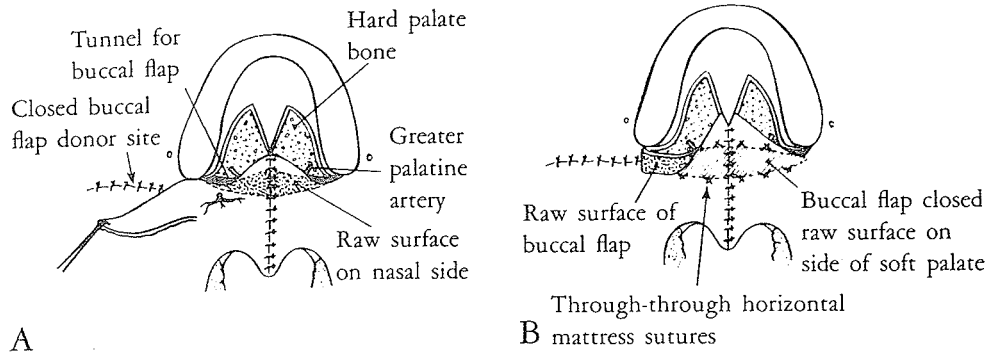
Ernest Kaplan of Stanford University majored in engineering and minored in art at the University of California, Los Angeles. Thus he was trained in the discipline of measurements tempered with the freedom of art. In 1975 in *Plastic and Reconstructive Surgery* Kaplan proposed a unilateral cheek flap to be turned for nasal lining in any type of pushback procedure when the nasal mucosa has been divided and a defect created. He proposed two possible bases for this flap, which in infants, he suggested, should not be wider than 1.5 cm. (A) The retromolar trigone with the lesser palatine artery in the base of the buccal flap was his favorite. (B) The alveolar sulcus can be used as the base of the flap, but in this case a kink is necessary and the lesser palatine artery is not incorporated into the pedicle.



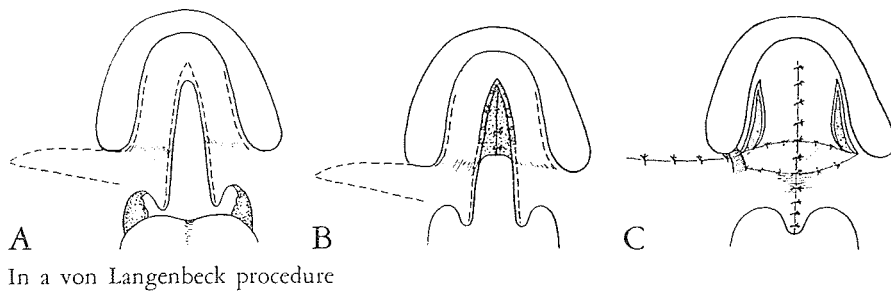
A Retromolar trigone design

B Posterior alveolar buccal sulcus design

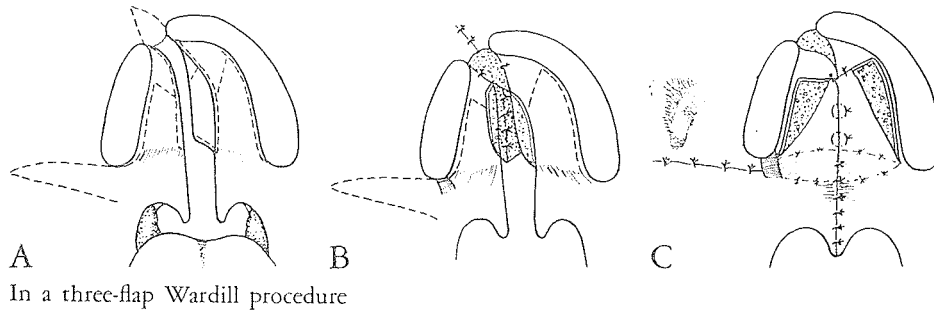
Using the standard incisions, Kaplan elevates the mucoperiosteal flaps, transects the palatine aponeurosis, cleft muscles and nasal mucosa transversely from the edge of the hard palate, preserves but frees neurovascular bundles, fractures the hamulus, frees the levator muscles from the oral mucosa, leaving it attached to the nasal mucosa, and sutures the muscles and mucosa together. The buccal mucosal flap is cut not to include the buccinator muscle, hinged 90 degrees and pulled through a



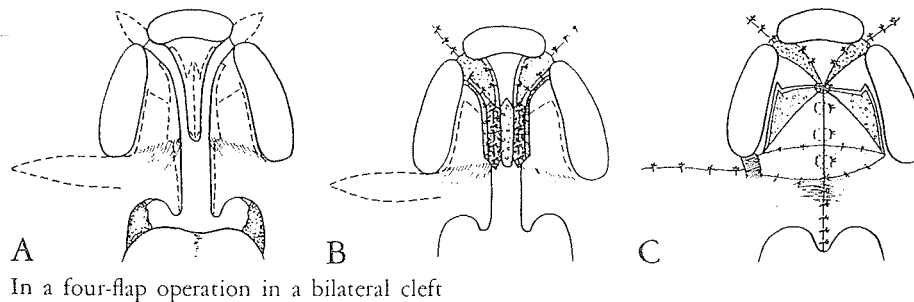
A tunnel lateral to the greater palatine vessels and sutured into the nasal defect. The mucoperiosteal flaps of the hard palate and vomer are sutured. Kaplan presented diagrams which showed the use of this cheek flap for nasal lining in a von Langenbeck procedure.



In a von Langenbeck procedure



In a three-flap Wardill procedure



In a four-flap operation in a bilateral cleft

There are two other principles by which lining can be supplied to the nasal defect following pushback procedures. They are the island flap and the pharyngeal flap, but both of these will be discussed in chapters of their own.