

26. Refining the V-Y Palate Retropositioning

GANZER

IN 1920 innovative oral surgeon Hugo Ganzer of Berlin pointed out that the von Langenbeck operation left the patient with a short velum. He also noted that paring the edges wasted a valuable 2 mm. of tissue. Therefore he designed a closure in two layers after *splitting* the edges. He was the first to execute a V-Y type of retropositioning of the palate with a gain in the overall length of about 1 cm. This principle was to have an important influence on palate surgery.

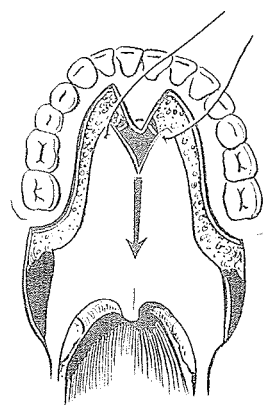
HALLE AND ERNST

Franz Ernst pointed out that in the cleft palate patient the nasopharynx was wider and the maxillary halves were smaller than in non-cleft patients. He observed too that the nasopharynx in cleft palates was longer in the anteroposterior dimension. Then Halle, in a paper to the Laryngological Society of Berlin in 1922, noted that the usual cleft palate operation produced a shortened palate. He reported that since 1915, following the suggestion of Ernst, he had been retropositioning the palate 1.5 to 2.0 cm. Ernst had proposed that a circular narrowing of the pharynx could facilitate the velar approximation to the pharyngeal wall. In 1925 Halle published further details of this procedure.

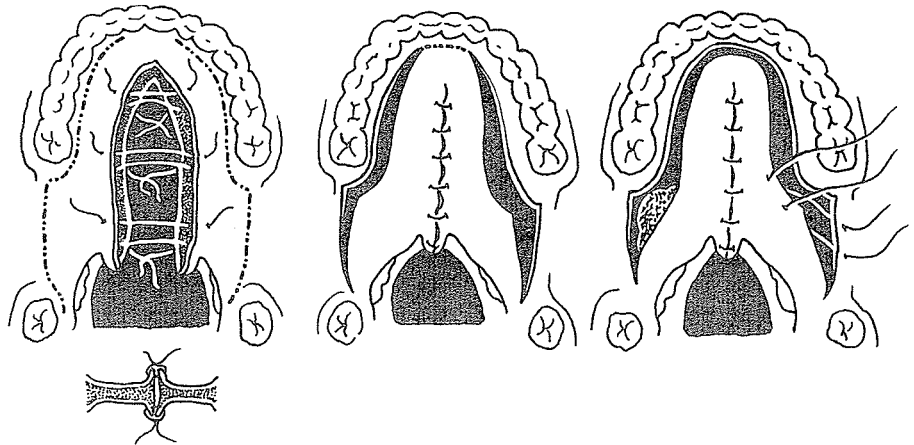
The edges of the cleft were split for a two-layer closure. The long lateral relaxing incisions were made from the incisors to



Hugo Ganzer

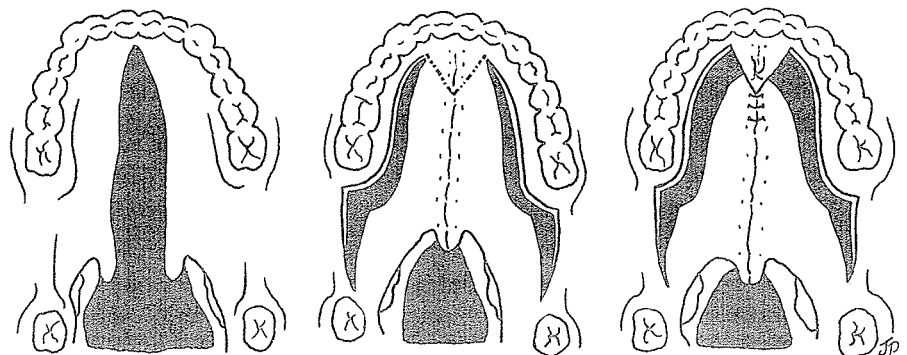


well behind the last maxillary molar tooth and extended back and down to terminate in the palatopharyngeal arch mesial to the last mandibular molar tooth. An elevator was introduced into the space of Ernst behind the superior constrictor muscles of the pharynx; the space dissected was packed with iodoform gauze to



push the lateral walls of the pharynx medially. The gauze was changed from time to time until the cavity had filled with granulation tissue. During this phase the mucoperiosteum behind the central incisors was divided in two stages (dotted line) with small incisions until complete release allowed posterior displacement. The celluloid plate of Ernst was used to protect the palate during the healing phase.

In complete clefts of the palate, Halle and Ernst carried out the same closure and radical release with subpharyngeal wall packing but used the *V-Y incision of Ganzer* anteriorly for more posterior displacement.



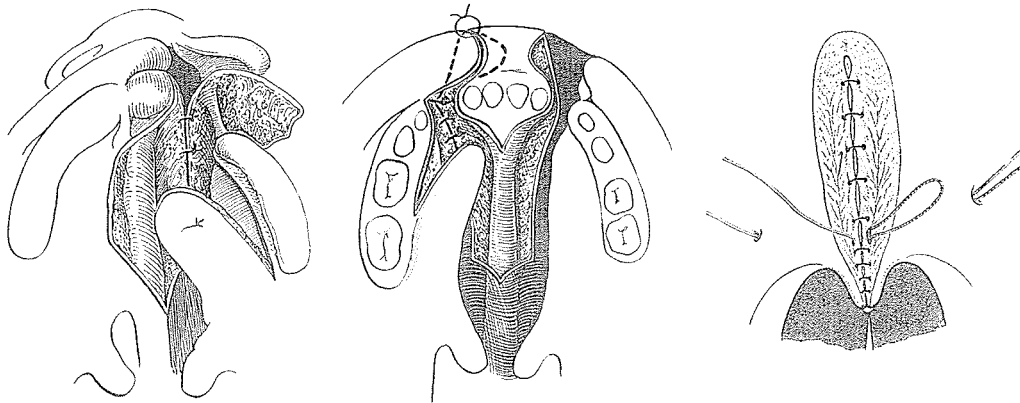
VEAU

Victor Veau was born in a small village of Burgundy in 1871. He was a poor student in school but brilliant in the Medical School of Paris, and became assistant to the pediatric surgical service of Jalaquier. Disenchanted with von Langenbeck's palate operation, he became one of the true innovators of cleft lip and palate surgery.

As early as 1922, with Ruppe, Veau advocated the Ganzer V-incision. With ingenuity and dedication, he operated on an astounding number of clefts. His two major contributions still stand as important milestones in the progress of palate surgery: his nasal mucoperiosteal closure of the hard palate cleft, including the vomerine flap, and his *suture musculaire*. These were described in detail in his elaborately illustrated 1931 book, which recorded 500 personal cases.



Victor Veau




He condemned the Axhausen method and then leveled a scathing attack on von Langenbeck:

Langenbeck's method results in short immobile palates due to sclerosis caused by cicatrization of a large bleeding surface on the nasal aspect of the palate which, in turn, is related to the wide undermining necessary in order to lower the flaps.

He backed his attack with final proof, by analysis of his results by his speech therapist, Mlle Borel. She reported speech effects twice as good as any published by von Langenbeck.

A counterattack was led by a formidable antagonist, Erich Lexer, another of the German giants of surgery. In 1927 he



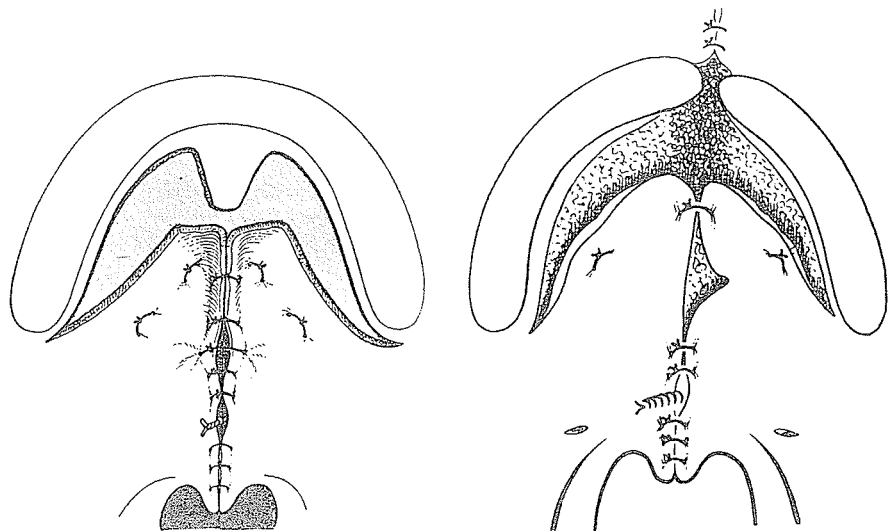
Erich Lexer

condemned Veau's principle of suturing the nasal mucosa, arguing that leaving an open wound on the nasal side maintained drainage and prevented the accumulation of pus between the united muscle layers of the palate.

Preferring his own modification of the von Langenbeck method, Lexer referred to Veau's procedure as

the French method which works only for Frenchmen who speak with the mouth but not for Germans who speak with the throat.

Veau, suspecting that Lexer had never tried his method, sent him a copy of his *Division Palatine* with an invitation to come to Paris. Lexer responded, "I shall not cross the Rhine!" It was then that Veau, with his typical *savoir faire*, sent a Parisian invitation to Mrs. Lexer and their two daughters. In 1932 *all* the Lexers crossed the Rhine! They were wined and dined in Burgundy and then taken to Paris, where Lexer was shown an astounding number of clefts collected for his examination. Mlle Borel played impressive comparative sound tracings recorded on the patient's diction preoperatively and postoperatively. Led to the operating room Lexer then was assisted and supervised in a Veau palate operation by Veau! The following year, when Veau visited Lexer in Munich, he found that the great German surgeon was using *bis* method.



For incomplete clefts

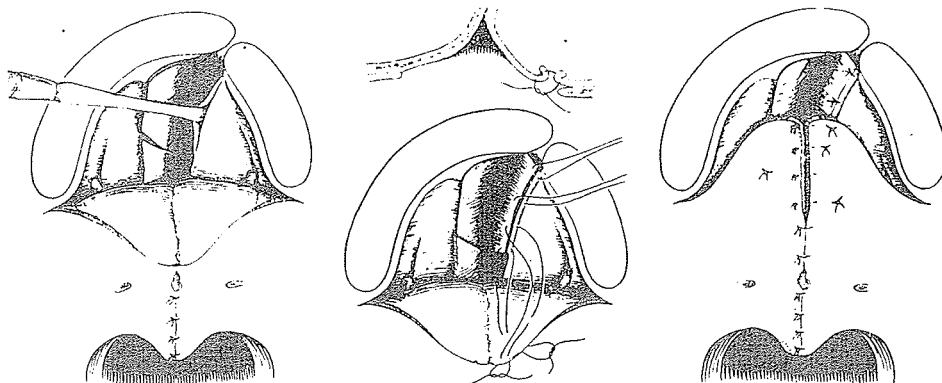
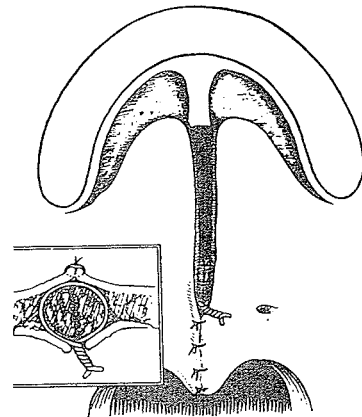
For complete clefts

Veau's first-stage closure turned vomerine flaps for nasal lining and mucoperiosteal flaps to overlap partially this one-layer clo-

sure. In the second stage or in soft palate clefts, Veau used a modified Ganzer V-Y closure of the oral mucoperiosteum without actually lengthening the nasal mucosa or dividing the posterior palatine vessels. He placed a metallic suture around the muscles with a Reverdin needle.

LeMesurier

In 1935, in the *Canadian Medical Association Journal*, A. B. LeMesurier of Toronto published his use of Veau's operation in incomplete clefts of the palate and in complete clefts.




Veau's influence was worldwide, and his general principles are still popular today.

Personal observation

In the summer of 1948 I went over to the Continent for a month and in 1950 recalled:

In Paris, not far from Gare St. Lazare, I found the flat of Victor Veau. A saucy French maid ushered me into a dimly lighted room with the curtains drawn. I was left to feel my way along the wall and finally sat down, not without a start, on a lion skin with its snarling head draped over a couch. Presently, the gaunt and ailing Veau, in silk robe and gray goatee, came rushing in, kissed me on both cheeks, gave me three reprints written in French, a requested photograph of himself and invited me to return again one day. I did not even get a chance to ask if he still used wire for his "*suture musculaire*."

At l'Hôpital Saint-Michel, where Veau did much of his later palate work, I found Jacques Récamier. He explained that Veau's



lip and palate technique, except for insignificant detail, had not changed for many years. In fact, the technique I saw Récamier use seemed identical to that described by Veau in 1927.

Less than a year later, on May 16, 1949, the *sympathique* Victor Veau had died of the illness incapacitating him during my visit. All the cleft palate world mourned his passing. Jacques Récamier at l'Hôpital Saint-Michel and Pierre Petit at l'Hôpital Saint-Vincent de Paul carried on his great work.

PETIT

At the 1964 Hamburg International Symposium, Pierre Petit of Paris, once a student of Veau, described the method he used as that of Veau with a few changes. He outlined the different stages of the procedure:

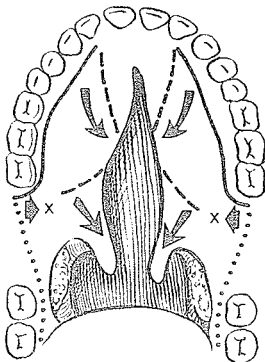
1. The medial edge of the soft palate is divided longitudinally
2. The two palatal mucoperiosteal flaps are dissected and the two neurovascular bundles elongated
3. The hamuli are infractured. The palatal aponeurosis is detached and the nasal mucosa liberated and pushed medially.
4. The dorsal [nasal] mucosal layer is closed (from the anterior to the posterior part) by catgut sutures, leaving the knots exposed nasally
5. The buccal mucosal layer is closed and muscle simultaneously sutured from back to front with silk mattress sutures. Then the mucoperiosteal flaps are fixed to the roof of the osseous palate to avoid any dead space.



Alexander Limberg

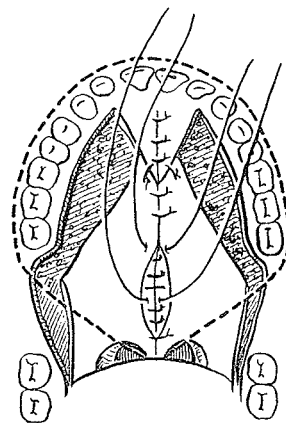
LIMBERG

In 1926 at the convention hall in Philadelphia an International Dental Congress was held, and many famous palate surgeons —Brophy, Gilmer, Ivy, Blair and Brown—were there. Dorrance explained his 1925 pushback procedure. Then a Russian named Alexander Limberg presented a variation of the V-Y pushback, which he published in 1927. Limberg used the Halle-Ernst design with the Ganzer V-incision and Blair's soft palate release(x), and advocated interlaminal osteotomy of the pterygoid process and pterygomaxillary osteotomy. He criticized Halle and Ernst for dividing the posterior palatine vessels and nerves. To facilitate the lengthening maneuver and preserve the neurovascular bundles, he proposed osteotomy of the bony palate wall of the foramen with



a chisel or bone-cutting forceps, removing a section of bone mesially and posteriorly. This ostectomy of the posterior wall of the foramen enjoyed popularity for many years and even today is used in some clinics.

In 1959 I had a chance to visit Limberg in his Leningrad clinic, see his patients and discuss his method of lengthening the palate. He was most proud that he postponed final palate surgery until about 10 years of age to protect teeth and maxillary growth, a conservatism natural in a surgeon with his dental background.



WARDILL

William Edward Mandall Wardill had become intrigued with the problem of cleft palate during his association with Professor Gray Turner. Turner's speech results were appalling, and his claims of a considerable proportion of "normal speakers" appeared dishonest. Cognizant of Turner's high integrity, Wardill suddenly realized that the professor was hard of hearing and not acute enough to pick out the faults in the speech of his patients. Wardill began to study the anatomy and physiology of normal and cleft palate individuals. In 1928 he described a palatal insertion of the superior constrictor muscle of the pharynx. It was confirmed two years later by anatomist Whillis, who labeled the pterygopharyngeus portion of this muscle inserting into the palate the "palatal pharyngeal sphincter."



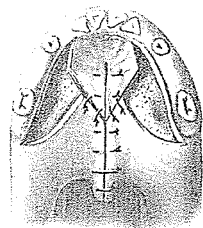
William Wardill

Wardill, however, continued to follow the teaching of Gray Turner and cut his flaps according to the von Langenbeck method but adding his "transverse-to-longitudinal" pharyngoplasty. He spent hours trying to teach his patients to speak correctly, and finally it became obvious to him that a better surgical design was needed. To get the best results, he felt, the operation should be carried out before speech age since once the patient learned incorrect speech habits the difficulties increased a hundredfold. Yet this early surgery seemed unattainable at the time since Ian McGill had not yet developed endotracheal anesthesia.

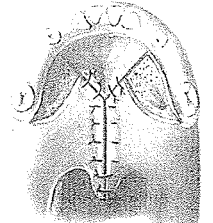
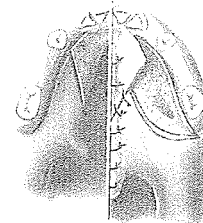
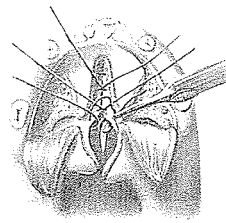
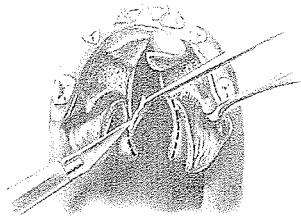

Over the next few years Veau's influence had extremely beneficial effects across the Channel, for by 1937 Wardill in Newcastle upon Tyne and Kilner in London upon Thames independently

published more radical and perfected V-Y repositioning operations than what had originally been described by Veau. Whether justifiably or not, more often than not this principle bore Wardill's name. Yet Kilner's rendition probably enjoys more popularity today. Wardill and Kilner remained friends through it all.

In 1937, in the widely read and respected *British Journal of Surgery*, Wardill, following Veau's suggestion that raw surfaces should always be covered (at least over parts concerned with the movement of the soft palate), described his dissection of the mucosa from the nasal surface of the hard palate edges. He fractured the hamulus, *divided* the posterior palatine vessels and modified Ganzer's V-Y by transecting the mucoperiosteal flaps in their mid-length to ensure adequate blood supply. By freeing and stretching the nasal mucosa, he obtained about 1 cm. in apparent length at the operating table. He used a three-flap method for incomplete clefts. Then, for a complete cleft, he chose a four-flap procedure, shown here in detail, continuing to use his pharyngoplasty in conjunction with his semi-lengthening procedure.



Three flap



Four flap

As I wrote in 1950:

Socialized medicine was scheduled to take over in Great Britain July 5, 1948. As this time approached, it was rumored that Wardill was emigrating to South Africa. When it was reported he was finishing up his waiting list of prostates and palates, I caught the night train to Newcastle and was waiting in his nursing home. Luckily it was a palate day. He arrived in high rubber boots, said "If anyone has just cause why these two palatal edges shall not be joined together, let him speak now or forever hold his peace," and proceeded to do a V-Y closure. I noted the main differences were that he hummed while he worked, divided both posterior palatine vessels and did a pharyngoplasty routinely on all cleft palates.

Wardill and his magic carpet

When socialized medicine finally did take over, Wardill packed up, took flight and landed, to everyone's surprise, at the Royal Medical College in Baghdad. Wallace Steffensen, interested in just how effective lengthening operations really were, traced Wardill to Iraq and extracted his latest thoughts in 1952. Wardill admitted using his pharyngoplasty in all cases since it had done no harm. When asked if he still used his Y-Y retropositioning procedure, he answered, revealing his bias for judging cleft palate operations by their speech results:

Up to the present time the operation I described produces the best speech results and I shall remain of this opinion until someone in the future can produce a new operation and demonstrate by results something that is better.

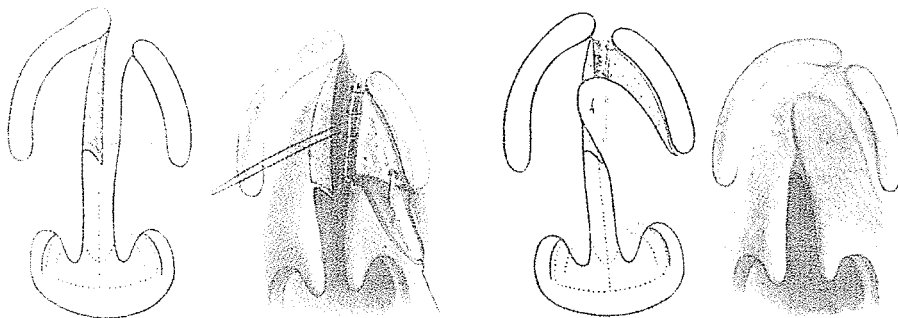
KILNER

Also in 1937, but in the more local *St. Thomas Hospital Report* and then in *Postgraduate Surgery*, T. Pomfret Kilner described a remarkably similar and possibly better procedure. The important difference lay in his refusal to divide the posterior palatine vessels, depending on freeing them from their attachments around the foramen. He did not consider the pharyngoplasty necessary in all cases. He gave Veau special credit, mentioning

free separation of nasal mucoperiosteal flaps and approximation of these as far as possible throughout the cleft . . . employment of vomerine flap or flaps, when available, to assist in this nasal closure [of hard palate] (Veau).



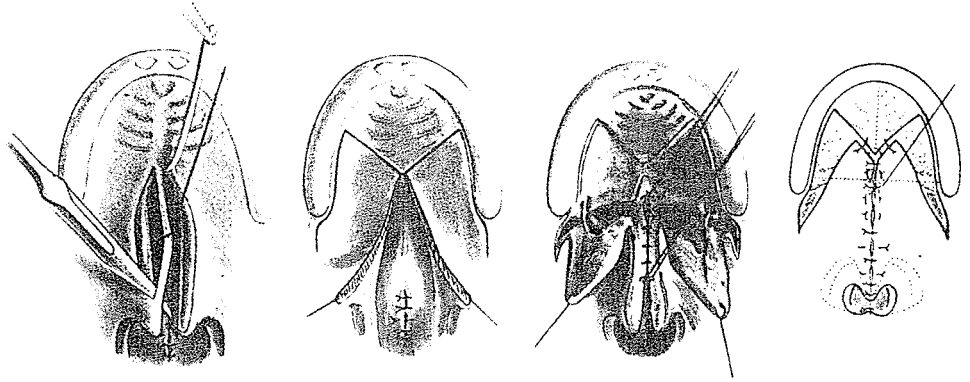
Pomfret Kilner



As he wrote in 1937:

I have freely borrowed from the work of my contemporaries, gradually evolving a procedure which for several years now has been giving me most gratifying results at the Princess Elizabeth of York Hospital for Children, Shadwell.

The essential points may be summarized as follows:



1. Pharyngoplasty (Wardill).
2. Rotation flaps from the hard palate (Veau).
3. Extensive freeing of the soft palate tissues from the posterior borders of the palatal process (but no division of the mucosa!).
4. Hamular process fracture, a procedure introduced many years ago by Billroth and re-introduced by Wardill and certain American workers (Dorrance particularly) in comparatively recent years.
5. Free separation of the lateral pharyngeal wall from the internal pterygoid plate and its immediate neighbourhood (Ernst and Axhausen). . . .

. . . The reference after each is given not as indicating so much the original introducer as the surgeon in whose work I first observed this part of the technique.

Kilner also acknowledged:

Wardill has recently introduced what he has described as a "four-flap method," and I have found this useful for closing wide clefts which extend far forward.

An Oxford dynasty

Kilner's meticulously skilled technique, set routine, congenial teaching of the transient foreign student, tyrannical schoolteaching of his own house staff and assistants, aided by the prestige

of his Nuffield Professorial throne at Oxford and its convenience by rail and road from London, brought him a stream of students, old and young. Those who came to watch returned home inspired to try to duplicate Kilner's precision. As Marcks, Trevaskis and Tuerk of Allentown, Pennsylvania, stated in 1955:

Soft palate clefts and partial hard palate clefts are repaired exactly as described by Kilner.


Even at his last palate operation before his retirement, as seen in a memorable photograph kindly sent me by Kernahan, Kilner was surrounded by observers. It is interesting to see him in his characteristic seated position with the patient's neck extended and his head reclining almost in his lap.

More important, he produced a dedicated core of second-generation captains who have carried out the tradition of the V-Y Corps to the third, and now even the beginning of the fourth, generation. Kilner kept fastidious records, but balked during his later years at the task of compiling these into a book, and the same task has been bypassed by others. Possibly a fifth-generation surgeon will go back and correlate the vast experience recorded by Kilner at Oxford and Alton.

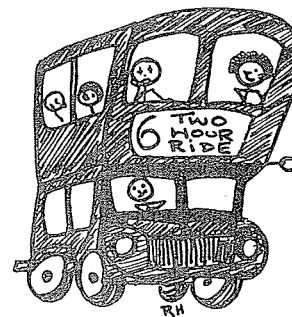
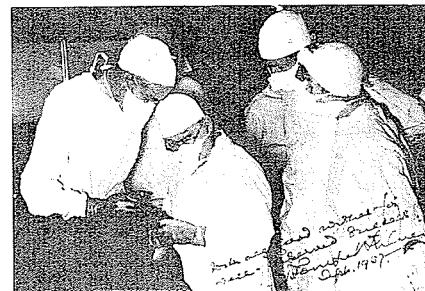
Personal experience

By 1948 I was training with Gillies, but since his palate surgery was confined mostly to secondary work, I used weekends, holidays and odd times to visit other palate surgeons.

Every other Saturday, Kilner and Peet took off from Oxford to put on an exciting cleft lip and palate show at Lord Mayor Treloar Children's Hospital, Alton. From Basingstoke it required a two-hour ride on a red double-decker bus through English countryside to arrive for the morning clinic. Here Professor Kilner, with a carnival blower and an attentive ear, demonstrated the excellent velopharyngeal closure and speech results of his palates. "What is this, little boy?" asked the professor, pointing to a cigarette and listening for the coveted sound of "s." "Fag!" said the complete group III bilateral cleft lip and palate, grinning on his slightly prominent premaxilla. It was estimated that 80 percent of his palates could pronounce s quite nicely.

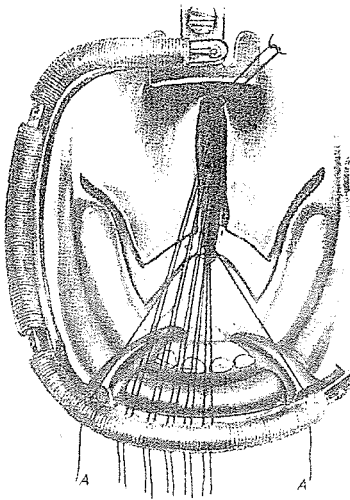


Oxford
University



In the operating theater when the genial little professor sat down to a cleft palate, all nationalities collected about him like drones buzzing around the queen bee. I became quite adept at working my way through the Indians, Italians, Belgians and British in order to see a technique carried to its perfection. Kilner reveled in honing a routine to regimental precision. Once I was allowed to scrub in as first assistant and experienced his knuckle-cracking instruction, as he indeed turned into a tyrant when in the theater.

It was thrilling to watch Kilner or Peet develop the V-Y flaps, stretch the posterior palatine vessels out of their foramen, dissect the nasal mucosa from the medial pterygoid plate and along the posterior border and free edge of the hard palate. This freeing of the soft tissue from the bone, which the professor called "filleting," when completed on one side revealed at least a temporary gain of 1 cm. in length as compared to the unoperated side. Emphasizing the importance of this dissection and his preference for it, Kilner would describe how he had observed Victor Veau place his "*suture musculaire*" and then cry "*Tirez! Tirez!*" as he dragged the palate halves together with force. One of the most disciplined aspects of Kilner's surgery was his suturing. He used the French Reverdin needle, which although a little too big for fine suturing was extremely well adapted for awkward closure of the nasal and oral palatal mucosa. He would place an entire row of sutures for one layer and hang them in an orderly array on the spring coil on his gag. Then he would tie them all and cut the ends before placing the next entire row of stitches.



Joseph Reidy

REIDY

Joseph P. Reidy, a student of Kilner, presented as his Hunterian Lecture in 1957 an exhaustive study of 370 personal cleft lip and palate cases. He favored Kilner's V-Y repositioning and, comparing it to von Langenbeck's method, said:

It must appear obvious that detachment of palatal flaps anteriorly will allow more movement of flaps in a posterior direction in the V-Y procedure.

He reported some interesting statistics on the primary use of the V-Y palate procedure: In 1949 Oldfield (another Kilner student)

reported 113 cases with 61 percent normal speech, 32.8 percent fair; in 1957 Reidy reported 193 cases with 77.2 percent normal speech, 20.2 percent fair.

Reidy concluded with the observation that the plastic surgeon is concerned with early palate repair and normal speech, while the orthodontist bemoans alveolar collapse following early palate surgery. Meanwhile the parents worry about appearance. The patient is in danger of becoming a *misguided missile* moving back and forth between the surgeon and the dentist. Reidy suggested that the orthodontist and surgeon change places in time:

Early correction of the arch deformity [should be] followed by later repair of lip and palate.

Pigott, who trained under Reidy and gained much from his discipline, recalled:

Reidy was enormously experienced, quick, methodical, unquestioning of Kilner dicta. I never saw him make a palate fistula in five years. When I would be absentmindedly sucking up blood somewhere away from the field he was working on, he'd say, "Suck, suck, suck, no, suck here—use it like a search light, not a vacuum cleaner—I can get charwomen at ten a penny."

In 1962 Reidy set 1 year as optimum time for palate closure, Kilner V-Y retropositioning as the primary procedure and Hynes pharyngoplasty as the secondary procedure of choice. Under these circumstances he recorded a failure rate of 20 percent and noted:

There is no doubt that scarring following breakdown, minor perforations, or repeated surgery plays a great part in reducing mobility of the palate.

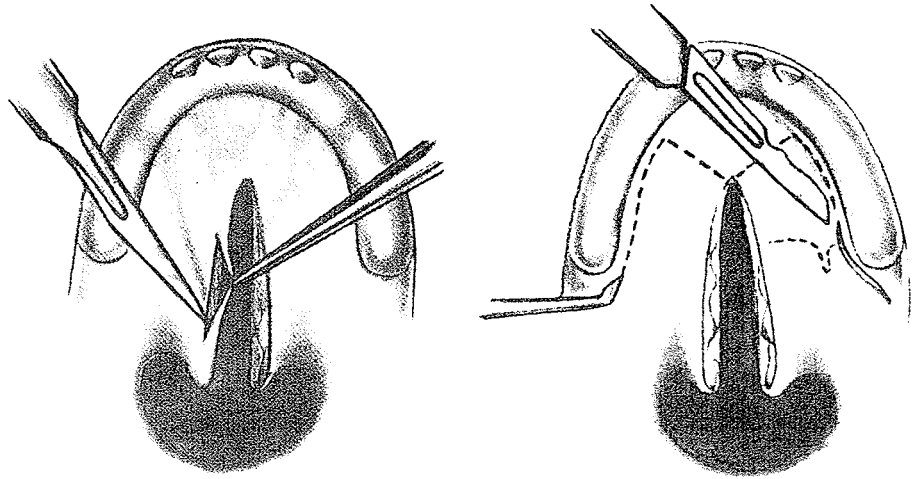
PEET

Eric Peet, who was trained by Kilner, (and became his heir as director of the Nuffield Department of Plastic Surgery at Oxford), perfected the Kilner method. He executed his surgery with the same precision that he used in constructing stringed instruments in his free time, his last remarkable feat being the completion of a quartet of two violins, a cello and a viola. Peet presented what he termed the "Oxford technique" to the American Society of Plastic and Reconstructive Surgeons in 1961, citing his 500 cases of primary palate repair over the previous 20 years. As he explained:

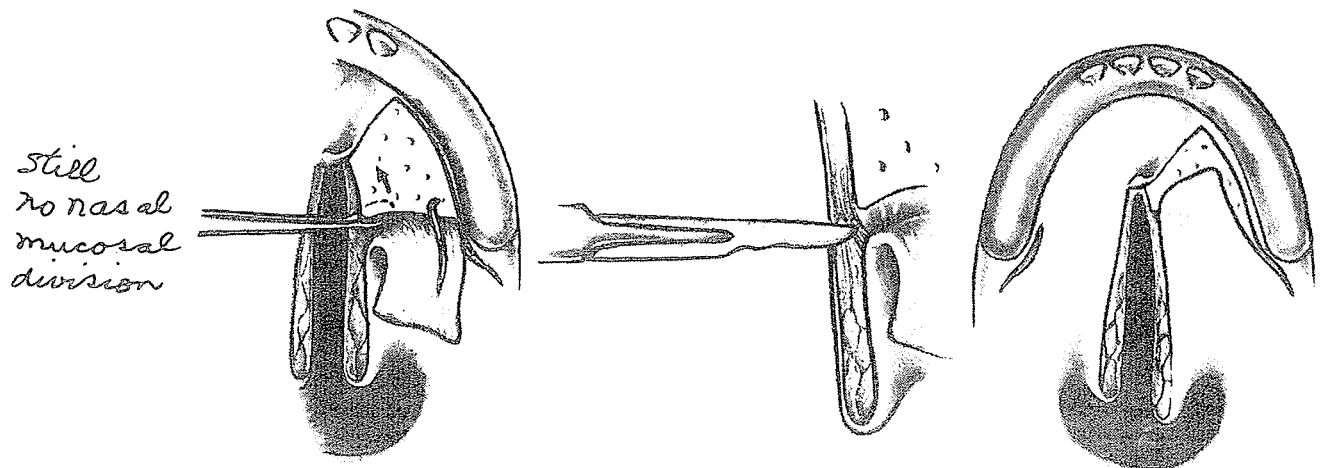


Eric Peet

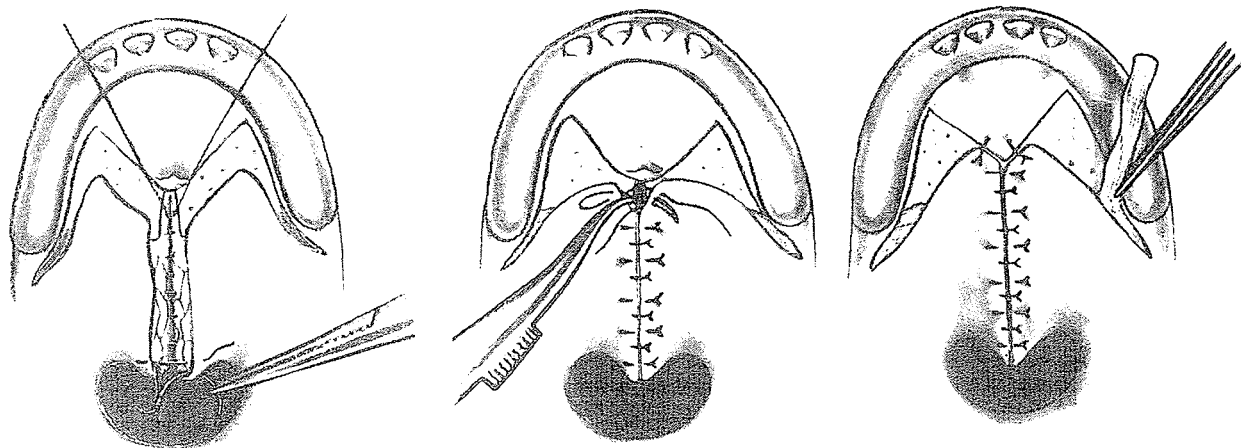
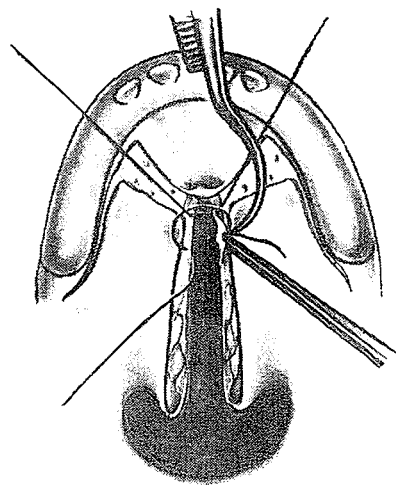
Most of us are influenced by our early teaching and by those men we respect, under whose guidance we have served our early apprenticeship. . . . One's tendency has been to try gradually to improve the technique rather than alter it.



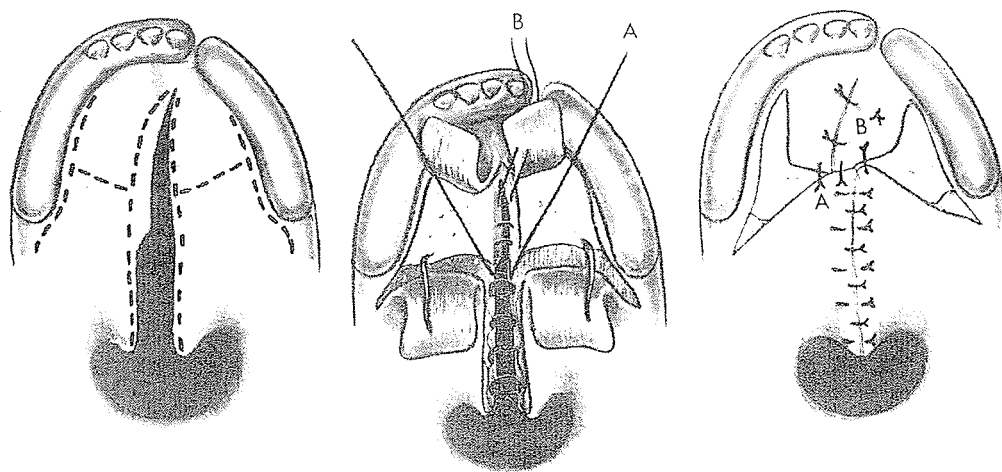
Quite lucidly, he described the paring of the cleft edges, stab incision and fracture of the hamulus with a Cumine's scaler, V-Y mucoperiosteal incisions and dissections of the mucoperiosteal flaps from the bone, mobilization of the nasal mucosa with the sharp and blunt crochet and Wallis's finisher, better known as the "golf club." He emphasized the importance of the dissection of the muscles medially from the medial plate of the pterygoid down to the base of the skull and the division of the palatal aponeurosis along the edge of the hard palate to give the backward release. The effective lengthening is seen after one side has been dissected.



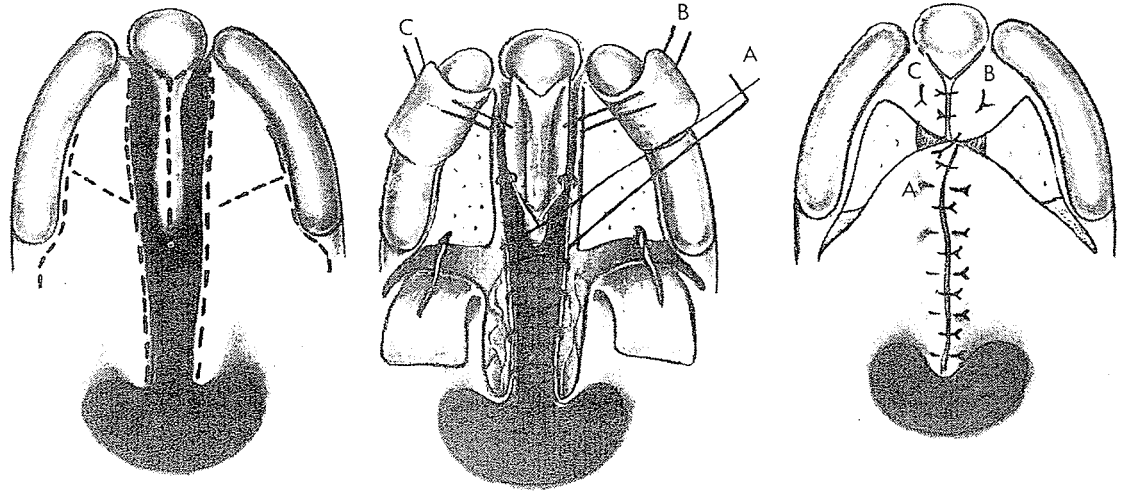
The first suture in the closure, destined to be the anchoring stitch, was a 3-0 chromic catgut mounted on a small, curved Reverdin needle and passed through the nasal mucosa anteriorly. The nasal layer was then closed, and mattress suturing of the buccal layer followed. The final key tie was a figure-of-eight of the anchor stitch. Iodoform gauze packing was inserted on the medial side of the medial pterygoid plate.



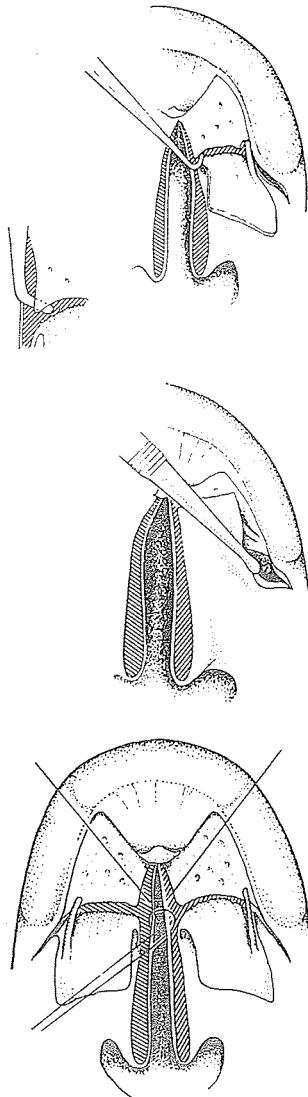
The four-flap method was used for clefts extending well forward in the hard palate and for complete clefts after the anterior portion of the cleft had been closed previously with a Veau vomerine flap.



It was also used for complete bilateral clefts, the vomerine flaps being employed for nasal closure.



With this technique Peet reported, in 1961, 82 percent normal speech results in a series of 107 patients operated on between the ages of 12 and 15 months.



CALNAN

Another of the elite Kilner Corps is James Calnan, professor, Royal Postgraduate Medical School, Hammersmith Hospital, London. A critical thinker with a bit of the rebel in him, he sometimes enjoys challenging accepted tradition. While still at Oxford under Kilner in 1954, he sided with Veau to destroy the myth of the importance in speech of Gustav Passavant's pad.

For the fine book by Grabb, Rosenstein and Bzoch published in 1971, Calnan described each step of the Kilner V-Y palate operation previously presented by Peet, in identically meticulous detail. One variant was his preference for the spoon-shaped Mitchell trimmer for hamular fracture and flap elevation. Also, in one of his diagrams during the early suturing, Calnan shows the limited extent of the actual posterior lengthening following complete dissection—the shaded distance between the hard palate edge and the folded-back mucoperiosteal flap.

It is of interest that in 1960 Calnan questioned the consistent effective long-term lengthening achieved by the V-Y pushback. In 1971, after 245 cleft palate operations on infants, Calnan reported a mean age of 13.4 months and an incidence of fistula at the posterior border of the hard palate of 11.4 percent. Speech

results were assessed at 75.5 percent \pm 2.74 with normal articulation and 64.4 percent \pm 3.06 with no escape of air down the nose (mist on mirror). As to actual posterior lengthening, Calnan is a little more optimistic:

However, a radiological study on a limited series of adults with cleft palate has shown that some lengthening of the velum is obtained, although the amount is usually less than 8 mm. Perhaps of greater interest was the finding that the amount of lengthening obtained at operation was inversely related to the original length of the soft palate.


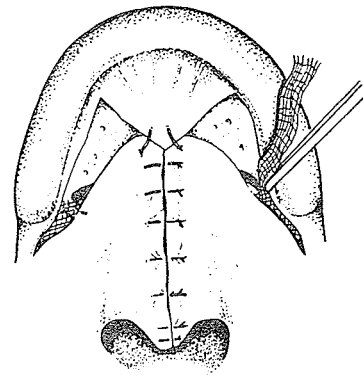
INNES

Frank L. F. Innes of Norwich, England, is also a member of this elite line, having had both Kilner and Peet as his mentors and having been influenced by Calnan, another of their students. In 1976 he wrote:


The operation which I have always done for the primary repair of the cleft palate is the Kilner-Wardill operation and I am satisfied with this procedure. This operation does not push back the soft palate very much, but it does permit the soft palate to rotate upwards towards the roof of the nasopharynx. The maximum upward rotation is obtained if the palatal muscles are freed deliberately and radically, not only from the hard palate but also from the nasal mucosa. . . . The upward rotation of the soft palate enables it to make firm contact high up in the nasopharynx, which is where its point of contact in the young child should be. In older patients the soft palate makes contact with the posterior wall of the pharynx at a lower level, a little above the line of the floor of the nose. . . . If a surgeon has a failure rate with speech of more than 15-20%, he ought to question the type of operation which he is doing and whether he is doing the operation at the optimum age. I am unable to offer a definition of speech standards, but I find it hard to accept a result which is in any respect short of normal.


BATSTONE

And unto the third generation of Kilner through the teaching of Peet, suave country gentleman-surgeon John H. F. Batstone, living in a sixteenth century Elizabethan cottage (complete with authentic prisoners' stocks) near Oxford University, has taken over as cleft chief at Churchill Hospital where Kilner and Peet



Frank Innes





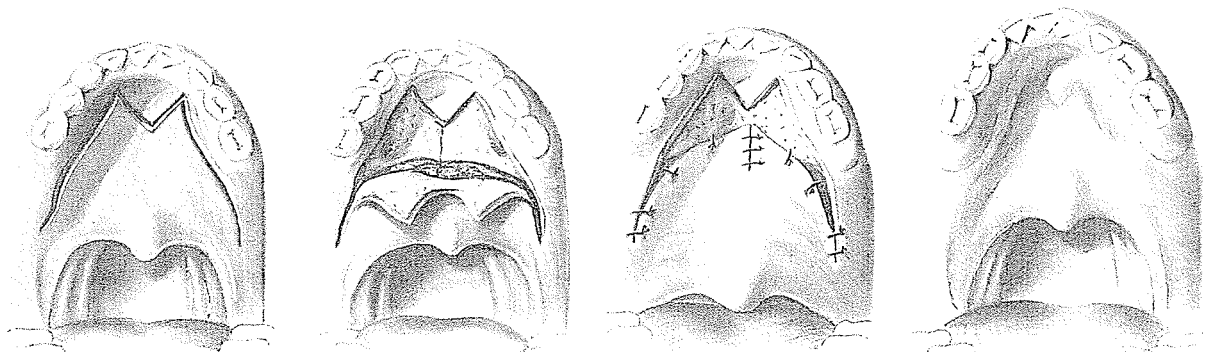
John Batstone

once reigned. Trained in the standard V-Y by Peet but partially uprooted from this routine during 1966 while a Robert W. Johnson Fellow in Miami, Batstone has become what Kilner would have considered enough of a renegade to sentence him to a stint in his own stock. It is true he still champions the V-Y, but, as he said after a ski on Biscayne Bay in Miami in 1977:

The key is *flexibility*. In the complete cleft I close the lip and the anterior palate at 3 months—using a Stellmach vomer flap for the anterior palate, and rotation advancement for the lip. At 6 months the rest of the hard and soft palate cleft, if favourable, is completely closed by a 3- or 4-flap V-Y retroposition technique. If unfavourably wide, however, then the soft palate only may be closed at this stage, with an interval of several years (with or without a plate) before closing the residual hard palate cleft. Often it is found that the gap has narrowed sufficiently over the years to make a Langenbeck procedure both practical and effective. If the palate is still short, then a V-Y procedure is relevant and one might slip in an island flap at this time. When there is palate involvement only, as in the post-alveolar clefts, then I often revert to the simple Langenbeck method so as to achieve closure with a minimum of dissection and interference. Later on, in all grades of palate cleft where there is a persistently unacceptable degree of “nasal escape” speech, some form of pharyngoplasty becomes obligatory. At present I am not over-enthusiastic about most types of flap pharyngoplasty, but encouraged by use of retropharyngeal silastic implants inserted via a lateral incision.

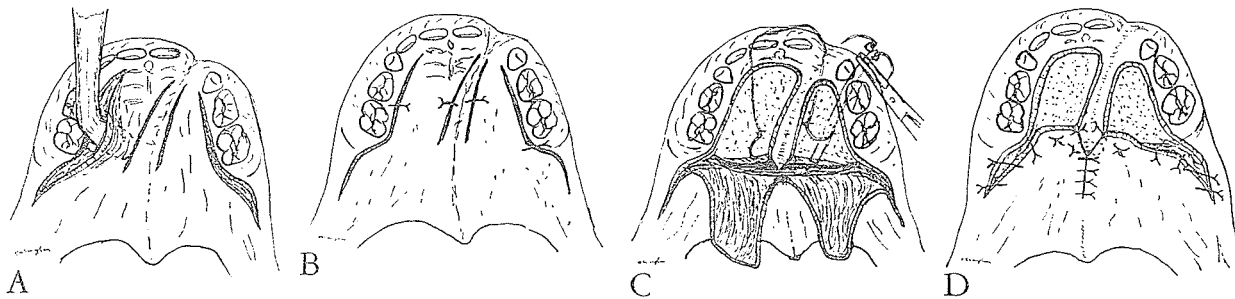
V-SPLIT FLAP PUSHBACK

When there was only moderate shortening of the velum, Hamilton Baxter of Montreal in 1942 combined the Ganzer V-incision with the Barrett Brown horizontal splitting dissection under the mucoperiosteum leaving a layer of scar tissue beneath. He warned that much of the lengthening would be lost following contraction of the raw surface on the nasal side.



VAUGHAN

Nova Scotian Harold S. Vaughan of New York, in 1944 in *Surgery Clinics of North America*, described his method of V-Y pushback in complete clefts. His first two stages involved closure of the posterior part of the cleft, then the anterior portion. This was followed by a variation of the V-Y principle in a two-stage pushback. First he made incisions on either side of the previously closed cleft in the bony palate, leaving a narrow bridge of tissue, and then made lateral incisions along the line of the alveolar ridge through which the mucoperiosteum was elevated. The mucoperiosteum was replaced and held loosely by sutures for three or four weeks.



Then Vaughan re-elevated these two mucoperiosteal flaps and *divided them from the palatal aponeurosis*, leaving a rim of tissue at the posterior edge of the hard palate. He fractured the hamulus but did not divide the nasal mucosa, consequently limiting his lengthening. Finally he advanced his mucoperiosteal flaps in a V-Y action, suturing them to the midline section of tissue.

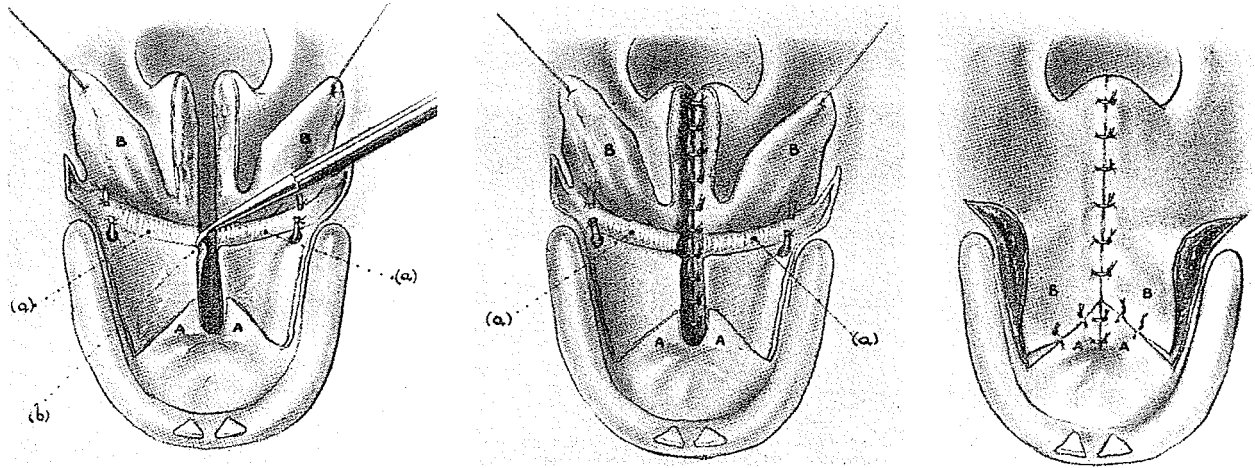
HYNES

In 1954 Wilfred Hynes of Sheffield, England, advocated less traumatic V-Y palate closure. He started with a Hynes pharyngoplasty and then outlined the principles of his palate closure:

- a. The attachments of the palatine aponeurosis to the posterior borders of the bony elements of the hard palate are not disturbed.
- b. The lateral pharyngeal dissections are avoided and the levators palati are therefore not exposed.
- c. The anterior attachments of the upper part of the superior constrictor to the hamular processes, to the posterior borders of the internal pterygoid plates, and to the palatine aponeurosis are left intact.

*but
vascular
bundles
cut.*

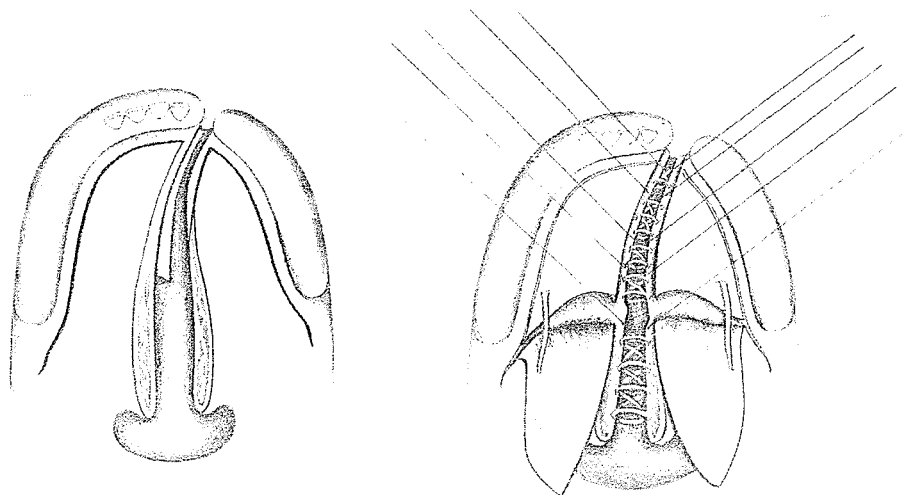
d. The attachments of tensores palati to each side of the anterior part of the palatine aponeurosis are not interfered with.



PINTO

In 1972 H. S. Adenwalla of Trichur, India, wrote of his former chief Charles Pinto's experience with the V-Y palatal procedure:

His execution of the palate was on the well-tried principles laid down by Veau and Wardill and the technical improvements made by Kilner and Peet. In his last year he began to do less and less of the "four flap" operation and began to teach the advantages of the "two long flap" operation which we now call the "Pinto modification of the Wardill repair." This eliminates the weak point at the junction of the anterior and posterior flaps, the commonest site for the formation of a fistula. We in this department do not do routine culture examination on palates. In spite of this we have not had a single fistula in the 57 consecutive cases operated on since January 1971 by this modification. He did not have time to evaluate his own results with this "two long flap" operation, though he anticipated the elimination of breakdown and fistulae. We do not perform the "four flap" operation anymore.



KERNAHAN

Early palatal mucoperiosteal flap dissections have been blamed more and more as possible causes of retardation in maxillary growth with subsequent deformity. The mucoperiosteal V-Y retropositioning procedure has come under slightly more fire than the von Langenbeck operation. At the Cleft Palate Symposium in Chicago in 1977, Desmond A. Kernahan, a Kilner disciple and now chief of plastic surgery at Children's Memorial Hospital, Chicago, argued that there is no convincing confirmation of a difference in maxillary development following the von Langenbeck and the Kilner-Wardill V-Y pushbacks. He stated frankly that the only differences were better exposure with the V-Y as the flaps are elevated and facilitation of the dissections by easier access under direct vision.

DEMJEN

Gentle Stefan Demjen of Comenius University, Bratislava, Czechoslovakia, came to England in 1948 to study with Gillies. He and I became friends and spent many a Saturday at Lord Mayor Treloar Hospital, Alton, watching Kilner and Peet adroitly execute their V-Y palate operation. Demjen was an experienced general surgeon with dexterous fingers that enabled him to pick up plastic surgery techniques quickly. During his sojourn at Iowa University before his final return to Bratislava, he developed his modification of the W-V-Y palate retrodisplacement operation and wrote a learned thesis in its defense. *The Bratislava Project* thoroughly evaluates the method.

Demjen noted that Kilner, Peet, Reidy and Osborne did not divide the posterior neurovascular bundles, and consequently their pushbacks were limited. He wrote:

In 1951, I decided to produce maximum possible elongation of the soft palate by severing the neurovascular bundles. . . . Professor Burian and I made a sort of agreement. He in Prague would preserve the bundles and I in Bratislava would cut them, and after 5 to 10 years we would compare results.

Demjen quoted Arthur Barsky's 1964 book:



Stefan Demjen

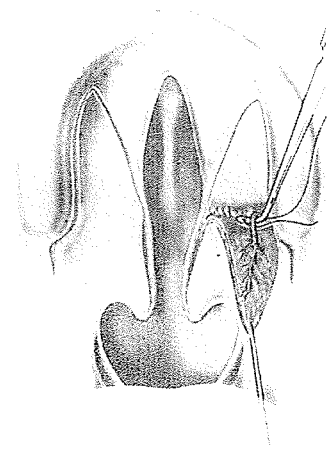
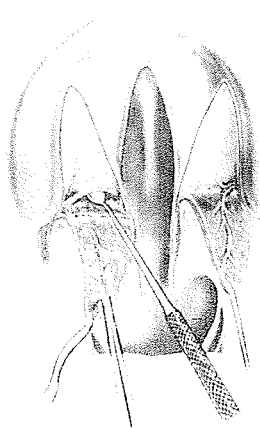
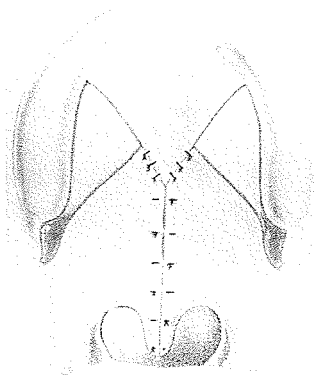
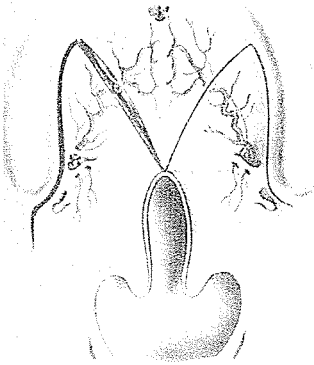
While V to Y and pushback procedures are capable of achieving a limited amount of backward displacement, there are two deterrents that prevent the surgeon from obtaining the optimum amount of retrodisplacement: (1) the neurovascular bundle which cannot be mobilized as freely as is desirable; and (2) secondary contracture of any raw surface left on the nasal side. If one could sever the neurovascular bundle, the first difficulty might be solved, but possible complications are so obvious that this step should not be considered (Broadbent and Hochstrasser, 1959).

Demjen then noted:

At the time of reading this statement from a very experienced plastic surgeon, I had already cut the neurovascular bundles for this purpose more than one thousand times without complication in healing, growth or function of the palate.

He defended his stand with anatomical facts:

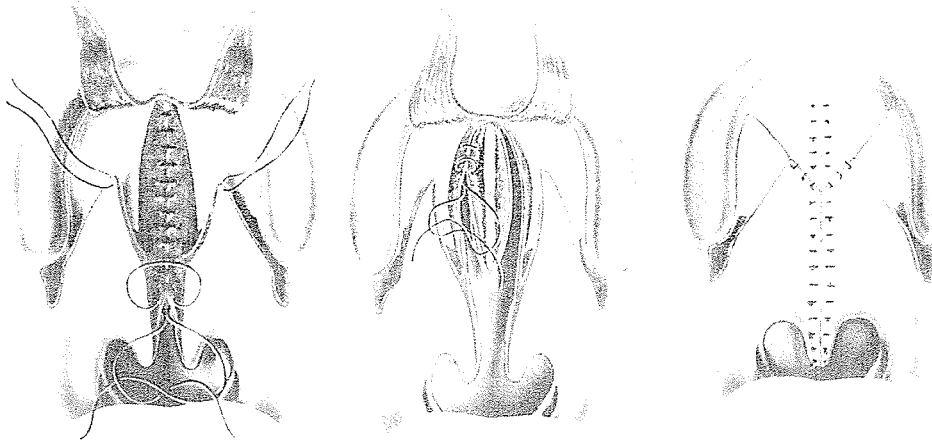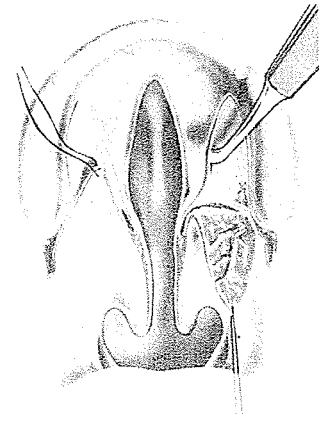
The anastomoses of the vessels in the nasal cavity and in the soft palate suffice to supply the palate after ligation of the greater palatine artery. This is certainly true in the Wardill-Kilner type of palatoplasty where the oral mucoperiosteum is divided by the oblique incision into two equally large flaps. The anterior flaps retain their blood supply from the nasopalatine arteries and short posterior flaps survive the sectioning of the posterior neurovascular bundles without trace of ill effect from diminished blood supply.



In the descriptions of his V-Y operation, the use of three flaps for incomplete clefts and four flaps for more extensive clefts and the division of the vessels were in line with Wardill's operation. His lateral dissections were similar to those of Kilner and Peet.

His description of this mobilization of the soft palate, accompanied by drawings, was excellent:

This is done by entering the lateral pharyngeal space (Ernst's space) and detaching the entire soft palate from the attachments to the maxillary tuberosity and medial pterygoid plate. . . . After fracture of the pterygoid hamulus medially and detachment of the superior constrictor from the medial pterygoid plate, the soft palate, along with the tensor palati, the superior constrictor and the mucosa of the lateral pharyngeal wall, can be pushed medially to allow suture of the cleft margins without undue tension. The depth to which the plane between the medial pterygoid muscle and tensor palati muscle is entered must not be too high, because it is in that plane where the nerve of the tensor palati may suffer damage if it is forcibly or too highly entered or packed. (Many years ago, we completely abandoned packing of the lateral pharyngeal spaces.) Twenty-four hours after surgery one does not see any more gap in the tissues in this region. The space is most likely filled in by the tissues of the cheeks.

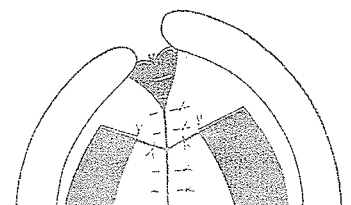
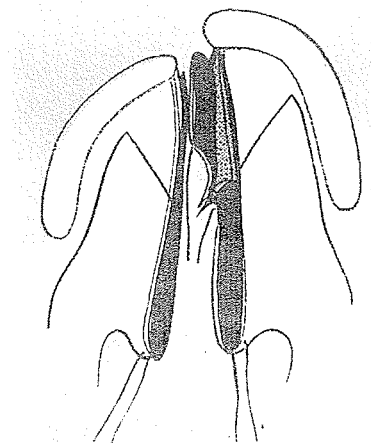



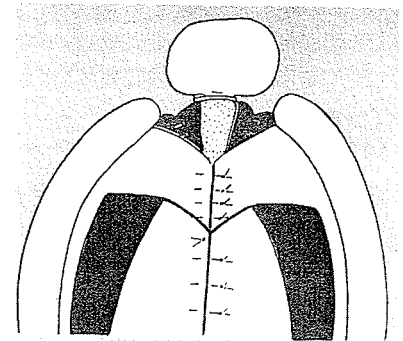
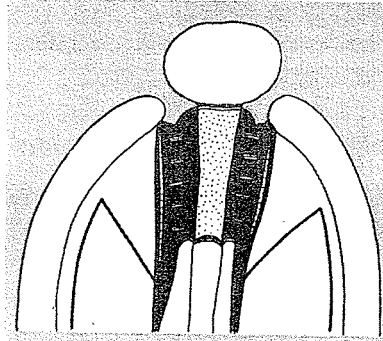
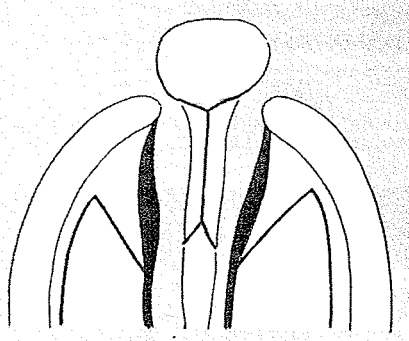
Closure of the nasal mucosa, if the cleft is not too wide, can be achieved by side-to-side suture, or, if available, the vomerine mucosa can be split and turned laterally to assist in suturing.

BURIAN

In his *Plastic Surgery Atlas* (Vol. 2), published in English in 1968, Burian presented his rendition of the Veau-Kilner-Wardill four-flap procedure, preserving the vessels, in complete unilateral clefts.

This is his rendition of the same principle for complete bilateral clefts:





Robert McCormack

YOUNG TO McCORMACK

Robert McCormack of Strong Memorial Hospital, University of Rochester, New York, was a halfback and safety at Swarthmore College and was one of 20 football players of the 1939 season who later made significant contributions in their careers to be honored by *Sports Illustrated* with the Silver Anniversary Football All-American Award. Trained by Forrest Young at Rochester, he worked with him on the paper entitled "Arterial Flap Repair in Cleft Palate" which was presented to the American Association of Plastic Surgeons in Ann Arbor in 1949. McCormack describes this modification of the V-Y which he has continued to use:

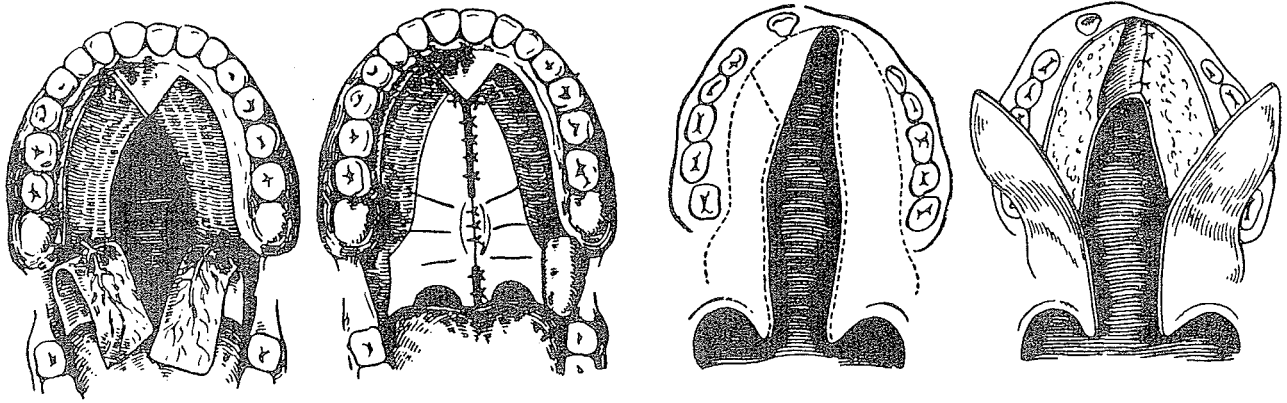
The major points were the extensive incisions from the retromolar fossa laterally continuing just medial to the alveolus and *completely around* the anterior end of the long arterial flap, then posteriorly along the edge of the cleft. The design of the flap violated the safe dimensions of a random flap so the major palatine vessels were left intact by careful dissections of the vascular "stalk" and teasing the vascular pedicle from its foramen. After this extensive mobilization of the arterial flaps closure without tension was possible with fine suture material and eversion of the pared edges.

The anterior ends of the repaired arterial flaps were secured by horizontal mattress sutures to a small triangle of mucoperiosteum left at the extreme anterior portion of the hard palate.

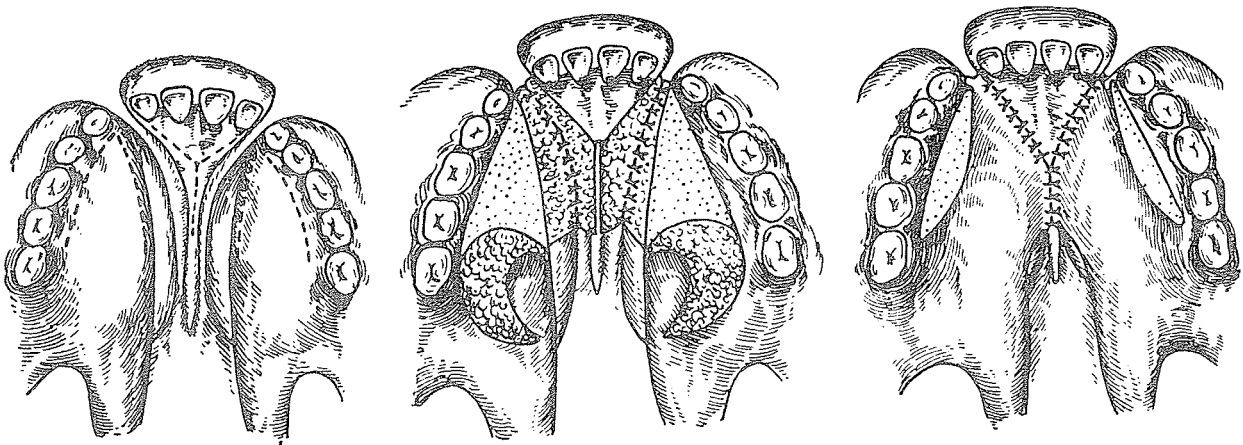
This type of cleft palate repair has been continued at the University of Rochester for thirty years. Analysis of results have included speech assessment, bony growth, orthodontic cephalometric follow up and the criteria for any secondary pharyngeal flap surgery. The speech analysis has shown highly satisfactory results in over 80% of the cases.

RUSSIAN V-Y'S

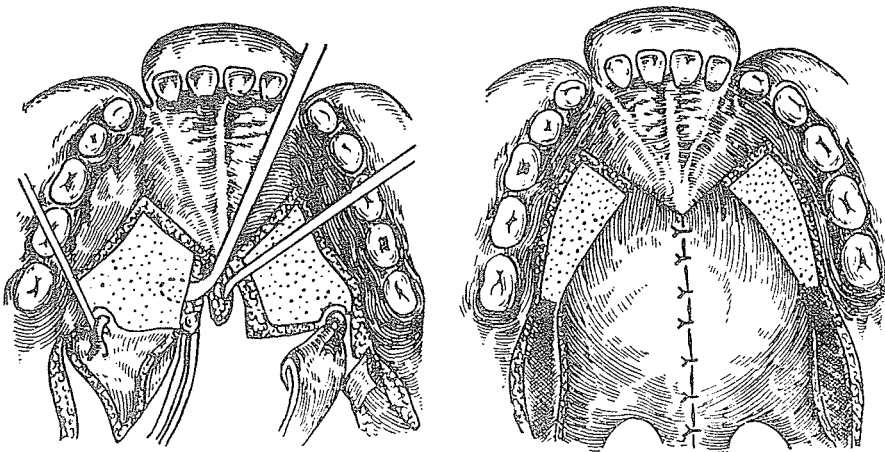
In 1970 A. A. Kolesov gave us a glimpse of Russian repositioning of the palate. First he presented the radical V-Y pushback of Limberg's method, after Rudko. Then he presented variations of the V-Y repositioning in complete unilateral clefts (Zausayev's method).



This is the two-staged design of V-Y procedures for complete bilateral clefts, after A. Khetrov:



First stage



Second stage

All previous V-Y procedures had used mucoperiosteal flaps dissected from the bone of the hard palate to feed into the lengthening of the oral side of the palate. Herfert's rumblings, ignored by the majority, were heard and heeded by a German surgeon, Widmaier, in Stuttgart-Süd.



Werner Widmaier

WIDMAIER

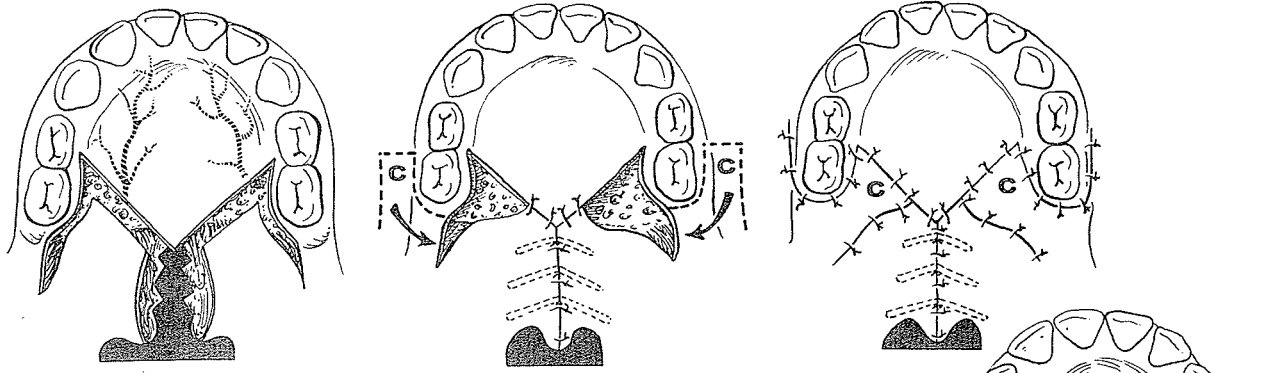
At the age of 20 in 1943, Werner Widmaier of Stuttgart was wounded in the face and jaw in Russia. Treated first in Russia, he was then transferred to a hospital in Tübingen, where Eduard Schmid took over his reconstruction. During his long stay in the hospital he started his medical studies and on vacation assisted Schmid in surgery. As he told me in 1971:

My interest in plastic surgery was a result of my own wounds and living together with many whose faces had been disfigured in the war. It was the possibility of giving back a face to these people that fascinated me. To Schmid, of course, and also to Professor Trauner, with whom I worked a long time, I owe very much. Cleft surgery has always been my favorite field of plastic surgery and still is.

In 1961 Widmaier designed a palate operation which reflected the Schweckendiek influence, avoiding any disturbance of the hard palate and thus any danger of subsequent maxillary deformity, but employing the V-Y principle to provide a soft palate of adequate length and functional competence.

V-Y Lengthening in Soft Palate Cleft

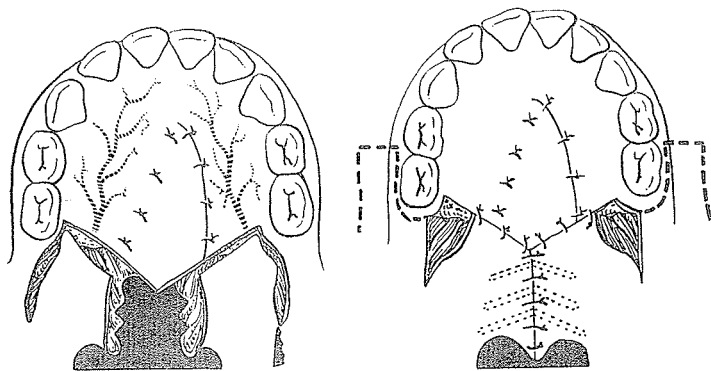
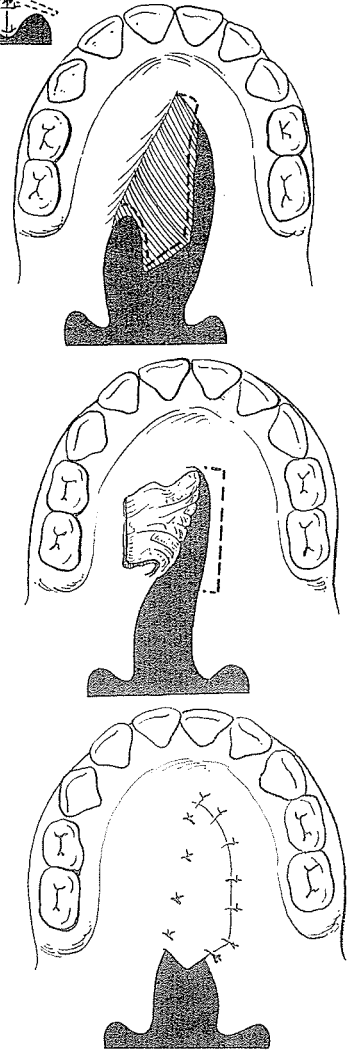
In soft palate clefts, oblique incisions are made at the junction of the hard and soft palate, care being taken to avoid damage to the vessels and nerves. These incisions are released laterally with sharp-angled incisions, which with blunt dissection allow the posterior edges of the soft palate halves to touch the posterior wall of the pharynx. The nasal mucosal layer of the soft palate is elongated by means of the zigzag incisions of Schuchardt. The lateral relaxation defects are closed with the Blair-Schmid transposition flaps from the adjacent cheeks.



Campbell Principle for the Hard Palate and V-Y at the Same Time

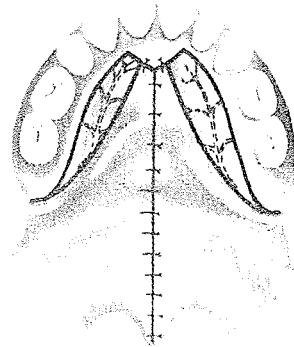
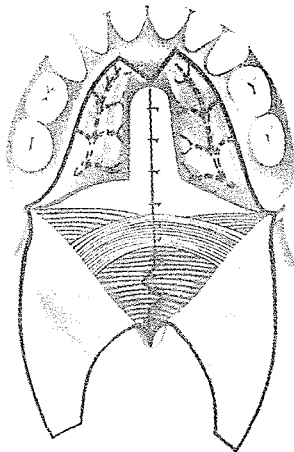
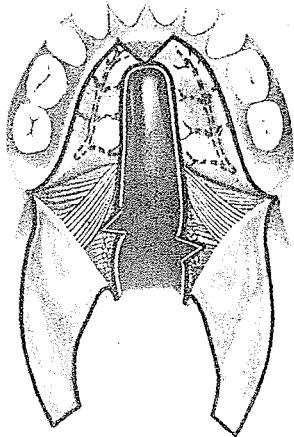
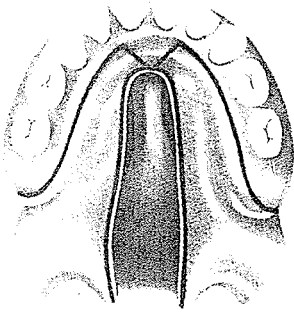
Widmaier adopted the Campbell incision for hard palate closure. A long, triangular vomerine flap is detached in the roof of the pharynx and, with its base maintained along the edge of the vomer, is peeled off the bone to span the cleft. A cuff of oral mucosa is turned over in continuity with the nasal mucoperiosteum bordering the cleft to form a lining flap. These flaps are overlapped to achieve a two-layer closure of the hard palate without maxillary disturbance.

At the same operation the V-Y posterior advancement of the soft palate is carried out, and the lateral defects are closed with cheek flaps. The nasal side of the soft palate cleft is lengthened by the zigzag interdigitations.



PERKO

In the 1974 *Journal of Maxillofacial Surgery* Yugoslavian Milivoj A. Perko of the University of Zurich presented an



operation for isolated cleft palate which he described as basically derived from the Widmaier method. It was indeed another and possibly an even more heroic attempt to prevent maxillary growth impairment by palatal mucous membrane dissection leaving the hard palate mucoperiosteum intact and the neurovascular bundles still attached to the hard palate. In principle, it was a primary palate closure utilizing the freed nasal mucosa as one layer, with a small Z-plasty on its distal portion, correct positioning and uniting of the levator muscle sling, and a V-Y mucosal flap advancement on the oral side.

Theoretically, this plan has many good points. Perko lists them as: (1) intact periosteum with entire coverage of the hard palate bone, (2) greater lengthening without restraining neurovascular bundles, and (3) improvement in muscle position. He also outlined the possible disadvantages:

1. Mobilization of the mucous membrane on the palate is a more difficult technique. . . .
2. The danger of necrosis of the mucosal flap is greater, but should not occur with careful dissection of the mucous membrane. If necrosis should still occur, however, the classical closure with the palatal periosteal flap is always still possible.

Practically, it would seem that the disadvantages would eventually outweigh the advantages. Perko acknowledges only two years' experience with 35 cases, but if after two years he is still happy, then probably so are the maxillae. It is hoped that the distal ends of these mucosal flaps sympathize with the hard palate's getting all their blood supply; otherwise they may simply necrose.

In 1977 Perko explained:

Actually, we perform the mucosal flap only in incomplete clefts or isolated clefts of the palate. In the total cleft we prefer to perform the soft palate closure first and the flap reaches to the first deciduous molar, which means it is longer than in the original Widmaier technique. The dorsal cut of the hard palate becomes closed in this first operation. The hard palate is closed later, in unilateral clefts at the age of 5 to 6 years and in bilateral clefts even later.

A WARNING

As many of the surgeons using lateral relaxing incisions—including those doing V-Y pushback procedures—advocated deep and thorough dissection into the space of Ernst for medial displacement of tissue from the pterygoid plates, a warning is in order.



Ivor W. Broomhead's 1951 work at Cambridge on the nerve supply of the muscles of the soft palate, published in the *British Journal of Plastic Surgery*, gave some important information about the dangers of injury during surgery:

In the plastic repair of a total cleft palate an incision is carried forwards from in front of the palato-glossal arch to the back of the alveolus, and then along the palatal edge of the gum to curve medially to the cleft margin. A second incision extends along the free margin of the cleft to meet the first incision anteriorly. Blunt dissection is performed down to the pterygoid hamulus, just anterior to the palato-glossal arch, and from this point into the plane between the medial pterygoid and tensor palati muscles, these muscles being separated from each other. After fracture of the pterygoid hamulus medially, the soft palate along with the tensor palati can be pushed medially to allow suture of the cleft margins without undue tension. The depth to which the plane between the medial pterygoid and tensor palati is opened up was measured in one case of a child aged 3 and found to be 2.5 cm. from the surface of the incision. A series of measurements was made from the tip of the pterygoid hamulus to the anterior margin of the foramen ovale in skulls of different ages . . . and it will be seen that the separation of the muscles extends practically to the base of the skull.

It is in this plane that the nerve to the tensor palati is found and may suffer damage during this stage of the operation.

The next stage of raising a flap from the hard palate preserves the greater palatine nerve and artery as it is carried out subperiosteally. Following this, the palatal aponeurosis is freed from the posterior edge of the hard palate, and the bone between the greater palatine foramen and the edge of the bony palate is removed to allow greater mobility of the neuro-vascular bundle to the palatal flap. Both these stages must result in damage to the lesser palatine nerves and artery. Section of the lesser palatine nerves would produce some anaesthesia of the soft palate and, if the musculus uvulae is supplied by these nerves as appears to be the case, paralysis of this muscle. The nerves also send branches to the mucous glands of the palate. . . . It has been shown that at least half the substance of the soft palate is composed

of mucous glands. Any reduction of this tissue, possibly by atrophy of the glands following denervation, would result in a substantial diminution in the thickness of the soft palate and in the size of the uvula. This may have some detrimental effect on the efficiency of closure of the nasopharyngeal isthmus and on speech. . . . At no time during the operation are the nerves to the levator palati, palato-glossus, and palato-pharyngeus likely to suffer damage, as the courses pursued by these nerves are well removed from the operative field. The final stage of inserting a pack between the medial pterygoid and tensor palati muscles could again lead to damage to the nerve supply of the tensor palati.

LIMITED USE

The V-Y principle is still popular. Yet as an early primary procedure, although it provides excellent surgical exposure, it requires too much mucoperiosteal elevation, leaves residual raw areas and achieves only modest lengthening. It also burns the bridges for possible later use of an island flap by cutting across the pedicles. For these reasons I seldom do a simple V-Y pushback any more except in a modified form, after 5 years of age in conjunction with the insertion of an island flap for nasal lining lengthening in a short but mobile palate.