

19. Increasing Uneasiness among the Bone Grafting Troops but Increasing Interest in Late Grafting

THIS impressive Germanic gathering in front of the Royal College of Surgeons, London, in 1959 during the Second International Congress, is composed of various palate experts. From left to right are Steinhardt, Rosenthal and Trauner, and on the other side are Schmid, Schuchardt and Rehrmann. All are obviously still quite happy about early bone grafting. Yet against the almost arrogant avalanche of surgeons grafting bone primarily into alveolar clefts, there began to appear a scattering of skeptics even among the surgeons themselves.



PRUZANSKY'S DISSENT

In 1963 at the convention of the American Cleft Palate Association in Washington, D.C., orthodontist Samuel Pruzansky leveled a provocative *dissent* from presurgical orthopedics and bone grafting implants in cleft lip and palate. He launched his attack by accusing an army of surgeons buttressed by orthodontists and prosthodontists:

Their battle cry is a cabalistic mumbo-jumbo invoking the mystique of embryology and growth and development.

Instead of research with documented results, he claimed,



Pruzansky

We have been fed opinion, anecdotal pap, wishful thinking, and empirical trivia.

He gave as the basis of his dissent a longitudinal growth study of children with cleft lip and palate begun in 1949 involving casts, roentgencephalometric, laminagraphic and other measures on more than 1,000 children from the time of their birth and explained he had no motive to support or fault any philosophy or method of therapy:

The only objective is to report the facts as they are!

and

Not all clefts are alike!

In a large series of complete unilateral clefts of the lip and palate, Pruzansky found 37 percent without crossbite and 40 percent with complete buccal crossbite on the affected side. The rest showed varying degrees of incomplete crossbite.

Since a significant number of patients do not develop cross-bite at all, is there justification for treating all patients by presurgical maxillary orthopedics and bone grafting?

He answered his own question:

In our judgment, there is none. Moreover, the malocclusion present in the preschool child can be readily, quickly and less expensively treated by simple expansion procedures.

He summed up the arguments for and against bone grafting:

For. Mesodermal deficiency.

Against. A static concept that does not allow for change as a function of growth and development.

For. Prevents malocclusion.

Against. Many cases do not need orthodontic treatment. The majority can be treated by conventional procedures.

For. Closes off anterior fistulae. Binds the segments and prohibits their orthodontic manipulation at a later age.

Against. Produces and maintains excessive width of the cleft posteriorly, a disadvantage to velopharyngeal reconstruction. Potentially hazardous operation (pleural puncture, pathological fractures of the tibia, scarred leg) not warranted for an elective procedure of dubious merit.

*This give 'em
hell Jeremiah
battle cry:*

*Scepticism
and
argumentation
supported by
documentary
evidence!*

Pruzansky noted with irony that

nearly the same reasons invoked by Brophy for jaw-compression now seem perfectly suited to justify jaw-expansion.

In 1923 Brophy had been convinced

that an adult, growing up with a cleft palate, has not the full complement of tissue . . . as it has not been subjected to the uses for which it was intended. Besides, the tuberosities spread which contributes to the shortening of the palate.

But the error of Brophy's reasoning stemmed from his erroneous interpretation of the consequences of cheiloplasty in complete unilateral clefts:

Following closure of the cleft lip, the alveolar borders of the anterior extremity of the cleft, by reason of traction of m. orbicularis oris, gradually approach each other. . . . The malar bones act as pivots and the posterior processes, the tuberosities, move farther apart, and the cleft is widened.

Thus, on the basis of the "abnormal separation of the tuberosities" fallacy, Brophy formulated a method of approximating the separated bones prior to the closure of the lip.

Pruzansky argued that collapse of the arch can be treated easily with rapid, complete and inexpensive correction. To the claim that

Excessive medial movement of the maxillary segments . . . is an undesirable side effect of cheiloplasty and therefore should be prevented.

Pruzansky countered with

Collapse of the arches may be regarded as desirable in that it facilitates velopharyngeal reconstruction. Pre-surgical orthopedics inhibits such collapse and thereby may retard velopharyngeal correction at an early age.

Finally, the provocative Pruzansky took a sword swipe at the German orthodontists, devoted to promoting growth by profoundly stimulating development, for providing

soil in which pre-surgical orthopedics and bone grafting can take root and flourish.

In a dare worthy of a duel, he challenged them:

Instead of expending their energies in understanding more about the natural post-natal development of cleft lip and palate, they continue in search of the prosthetic or surgical touchstone that will transform cleft palates into normal palates overnight.

A Pruzansky conclusion:

When the adult dentition has erupted, and orthodontic treatment is completed at about age 13, then it becomes possible to determine whether that individual is indeed deficient in tissue mass at the alveolar process. In such instances, [I] endorse bone grafting. However, such cases seem to be in the minority.

At a social gathering in Pruzansky's suite during the 1963 international meetings, Owsley recalled that the "new" early bone grafting of the maxilla came into the conversation. Husky Bengt Johanson, a stalwart advocate of primary bone grafting, who often looms even larger than he is, got into a confrontation with feisty little Sam Pruzansky. They lined up eyeball to eyeball (Sam was standing on his bed) and Sam snarled to Bengt:

It won't work!

This was a prophecy.

SKEPTICISM OF THE ORIGINATOR

It is important to realize that E. Schmid, the surgeon who initiated maxillary bone grafting in the early 1950's, voiced skepticism when he wrote:

Besides, no experience is yet available to determine whether this procedure will be able to improve the results of cleft surgery. The procedure has merely been presented for discussion.

In his 1964 Gillies Memorial Lecture, Francis Burian of Prague questioned the value of the popular early bone grafting:

There is no doubt that this operation has a logical basis, for the graft supplies the bone tissue to fill in the defect, which is more or less extensive in total clefts. However, I have some doubts about this operation. A bone-graft must be applied to denuded bone. To lift off the periosteum of such young bone is a very delicate operation, especially on the poles of the

cleft, which are most important for the further growth of the maxilla. We must bear in mind that the growing potency of the parts of the maxilla is already weakened in clefts and additional harm may be caused, the consequences of which would appear only after many years. Besides, a bone-graft requires a safe and reliable bed in which it would be perfectly covered. In my opinion, there may be difficulties in achieving this. The taking of the graft itself undeniably imposes a further strain on the infant. . . . Results will become open to criticism only after at least ten years. Of course, in the case of an older child with a reconstructed lip, where all conditions are favourable, there is no objection to secondary bone grafting.

AN EARLY BONE GRAFTING LEADER BALKS

Johanson concluded in 1964 at the Hamburg Symposium that

The primary bone grafting in our hands has not prevented the bite to develop similar to what you will find in carefully treated series without bone grafting. The orthodontic correction of the deciduous bite has, however, been easy to perform, and the stabilization of the premaxilla in the double cleft cases has been of unquestionable value. As a result of our findings, we have now started a new series with every second case treated primarily and in the rest the bone grafting will be postponed until the time of the second dentition.

In 1964 S. Pruzansky and in 1964 and 1967 S. Pruzansky and H. Aduss compared the results achieved at Illinois without presurgical orthodontics and early bone grafting with those from Göteborg reported by Kling with presurgical orthodontics and bone grafting. The comparisons suggested, they felt, that Kling's findings were indeed much worse than those achieved by "less modern" methods, and Kling seemed to concur:

From the point of view of the bite, the results do not seem, at a glance, to differ much from those achieved earlier with less advanced methods of treatment.

In 1965 Johanson, in the Northcroft Memorial Lecture, reviewed over 100 cases treated with his early bone grafting during a 10-year period. The results were so disappointing, he concluded, that he had discontinued this method of treatment. Since 1968 his order of treatment has been changed to: first, a lip adhesion;



at 1 month, closure of hard palate with vomer flap; at 6 months, closure of soft palate; and at 18 months, closure of lip. Only at 12 to 18 years does he bone-graft the alveolus and hard palate. This is his regimen today.

Johanson is a vigorous Viking from Sweden who is intolerant of nonsense and smashes through mincing opposition. His favorite relaxation involves five to six hours of rowing in a small boat to Roslagen in the Baltic Sea. Carrying a 9 mm. rifle in a watertight tube, he slides out of the boat, wades through icy water and climbs onto rocks from which he can shoot 200 pound seals and lift them up onto land for skinning. He considers 10 to 15 a good day's haul and reports that the meat is delicious, particularly the liver. I have seen him handle opposition in a congress as if he were shooting a seal—and in English, no less!

At the Second International Symposium on "The Early Treatment of Cleft Lip and Palate" held at Northwestern University Dental School in April 1969, Sheldon Rosenstein of Chicago's Children's Memorial Hospital, in response to the banter of those for bone grafting and those against it, asked for proof of good results at age 14 to 15 years by conventional methods. Chairman Richard Cole of the Lancaster Cleft Palate Clinic repeated a valuable refrain:

It strikes me again, however, that our concern is and should be making sure that we are now accurately and adequately documenting our treatment results through accurate measures.

This brought Bengt Johanson to his feet!

Yes. . . . I would say that that which started us with primary bone grafting and the new thinking of combining bone grafting with early orthodontic treatment was that results in the early soft tissue repair were not good. . . . We found when we had had about 10 years' experience with primary bone grafting, that our results were much better and so we were very pleased. . . . Then these cases changed from the primary dentition, and we found that we really hadn't gained that much. . . . Everyone here has shown different series of cases, some with orthodontics combined with bone graft, some with orthodontics without bone graft, and some with soft tissue repair only. We have seen that all of us can show very nice results depending on the given case. . . . I can show you beautiful cases with a bone graft, with teeth coming down into position and how with orthodontic treatment

the permanent dentition looked good. But I know in documenting the series which now parallels the bone grafted series that our results are much better today, without the primary bone graft, than they were when we started.

I still say that the bone graft will have a place, in the end, in the final handling of the total cleft. But everyone here is saying, "I just started; I want to find out, in my own group, whether primary bone grafting is good or not." For God's sake, go back and look through everything that already has been done. We don't have to go back and do these things all over again in every little unit in the world. We can use the publications and the information we have; we can rely upon each other.

In his latest follow-up study of children treated with primary bone grafting, Johanson, with Hans Friede in 1974, concluded:

In spite of the inherent fault of small numbers of patients and no actual controls these intermediate data on the effect of primary bone grafting point to the conclusion that this method did not result in the expected normalisation in the growth of the middle face and the jaws. On the contrary our results seem to be inferior to those reported for cleft patients subjected to neither early jaw orthopaedics nor primary bone grafting.

The bone graft of the anterior maxilla healed in every instance but it resulted in an abnormal maxillary development with increased frequency of both lateral and anterior crossbites.

The local and general maxillary growth retardation gave our cleft patients a pronounced maxillary retrognathia which increased with age. When full grown, the facial profile of our patients will frequently be concave; in many cases to such an extent that we cannot recommend primary bone grafting. In our Center this treatment method has not been carried out on cleft infants since 1964.

Also in 1974, Bengt Johanson gave a follow-up on his secondary bone grafting. He had 125 cleft patients (21 bilateral and 104 unilateral) with the mean age of 20 years at the time of bone grafting. The follow-up interval after bone grafting varied from 3 to 14 years (mean interval 7.5). Ninety-three patients were available for final evaluation; with the exception of six of these, all had postoperative orthodontic treatment.

At surgery, particular attention was paid to the filling of the cleft in the alveolar process and hard palate. For at least one year after surgery, a removable retainer was used until permanent prosthetic construction had been completed.

The bone grafts healed in 96 percent of the cases. In 12 patients pinhole-sized fistulae remained. A slight degree of relapse after orthodontic treatment was noted. The cephalometric values indicated maxillary as well as mandibular retrognathia. Even if many of the patients showed straight or slightly concave facial profiles, normalization of the anterior occlusion had occurred by means of the moderate retroclination of the lower incisors without overexpansion of the maxilla.

It was concluded that bone grafting of the alveolar process, and the palate in the adult, normalized and stabilized the maxilla in practically all instances.

DERICHSWEILER AND OTHERS

In 1958 Hans Derichsweiler of Munich reported early orthopedic treatment before bone grafting. At the Hamburg Symposium in 1964, it was reported that Derichsweiler found 90 percent severe malocclusion after bone grafting in 30 bilateral clefts at age 6 months. His cases without grafting revealed a similar percentage of malocclusions, which led him to conclude that bone grafting may have other merits but the prevention of severe malocclusion is not one of them.

In 1965 J. Chalmers of the University of Liège reported work on growth of grafted bone, showing that bone grafts reveal virtually no capacity for growth unless they are subjected to great stress. Only bone transplanted with a cartilaginous growth center will show growth.


In 1966 P. Baumgartner and B. Maeglin questioned the possibilities of detrimental late results following early osteoplasty of the cleft alveolus. They wrote:

Since a graft does not ordinarily follow body growth after transplantation, it would be conceivable that ossification of the cleft could invite impairment of growth of those bony parts in the cleft area joined by the transplant.

In 1967 S. Stenström and B. Thilander of Umeå University, Sweden, reported experiments with bone grafting in guinea pigs. Half of their animals had excision of the maxillopremaxillary suture followed by insertion of an iliac bone graft. Growth was studied by radiographs and subsequent examination of the skulls.

The cleft but ungrafted jaws grew symmetrically and equally compared with normal controls. The skulls of the grafted animals were asymmetrical and showed limitation of growth.

The dynamic Kenneth L. Pickrell of Duke University, who trained with the pioneer John Staige Davis at Johns Hopkins University Hospital from 1937 to 1940, recalled that time as the era of ether and horsehair. In 1968, with G. Quinn and R. Massengill, he gave a typical no-nonsense evaluation of 25 infants followed for a minimum of four years. Although partially conflicting with the findings of others, they summarized their stand quite bluntly:



Kenneth Pickrell

1. Primary rib grafts in the maxilla do not increase in size concomitant with facial growth and development.
2. Teeth do not migrate and erupt spontaneously through a rib bone graft.
3. Rib bone grafts do not form a true alveolar process; a permanent alveolar notch remains.
4. The orthopedic effect of the bone graft decreases as its incorporation increases.

The late J. J. Longacre of Ohio, long devoted to his favorite sport of splitting ribs, might have been expected to jump at the chance to insert a few of his grafts as early as possible. Such was not the case, for in 1970 he indicated reservations at least in the time of the bone grafting. His recommendation for patients with a bony deficit follows: An early retainer is to be used until deciduous teeth erupt, when an expansion appliance is in order. At 4½ to 5 years, a bone graft with split rib is inserted, and the maxillary segments are maintained in position until the bone graft is consolidated. Six months later, a V-Y palate closure is followed by further maintenance of expansion until molars erupt.

REHRMANN CALLS A HALT TO EARLY BONE GRAFTING

A most important result, because of its status as the study with the longest chronological interval between surgery and reexamination, was presented by Rehrmann, Koberg and Koch at the



Alfred Rehrmann

International Cleft Palate Congress in Houston in 1969. The able and untiring Alfred Rehrmann, a classical musician and violin maker, was a student of Wassmund in Berlin for three years. He then became an assistant to Schuchardt in Berlin, served in several maxillofacial units during World War II and finally rejoined the dogmatic Schuchardt in Hamburg for seven years. Having been regimented in the ways of the Hamburg primary osteoplasty, Rehrmann carried on this work, but with comparative controls, when he became professor of the Westdeutsche Kieferklinik, University of Düsseldorf. With Koberg and Koch, he evaluated and analyzed statistically the long-term follow-ups of primary and secondary bone grafting in infants and small children over a 10-year period. Two groups consisting of 50 children each were compared. In the bone-grafted group, 40 children had a primary osteoplasty, 34 percent with a Stellmach flap. The other 66 percent had a surgical procedure using Veau-Axhausen for the nasal lining and Burian-Trauner for the oral lining. The remaining 10 children were grafted secondarily at a mean age of 4.5 years. In the control group the alveolar cleft was closed according to Veau-Axhausen, but in 16 percent a simultaneous Pichler flap was used to close the hard palate, while in 84 percent the mean age at hard palate closure was 4.5 years. All the subjects had LeMesurier lip closure. Forty-seven percent of the bone-grafted group had orthodontia as compared to 48 percent of the controls.

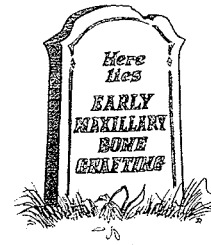Bite relations in all three dimensions of those cases in which the Stellmach tilted vomer flap or the septal mucosal flap of Pichler was used were not worse than those using the Veau-Axhausen method. Rehrmann concluded:

The use of a very great part of the septal mucosa does not influence the forward directed development of the maxilla.

After comparing the bone-grafted cases with those without grafts, Rehrmann drew further conclusions:

Bone grafting in the area of the alveolar processes does not bring about permanent stabilization of the segments. Lengthening of the bony bridge was never observed. . . . Contrarily, the inserted bone becomes shorter over the years. . . . The frontal ends of alveolar processes conjugated by bone are

rather retarding in their development in all three dimensions. . . . The resulting bony bridge . . . keeps these ends of the alveolar segments together comparable to a claw. . . . Malocclusions of grades 2 and 3 in the sagittal and horizontal planes were prevalent in the grafted group in high significance in comparison with the ungrafted group. Therefore, it must be concluded that early bone grafting in nearly all of our cases provokes retardation in development of the maxillary arch and local growth arrest of the maxillary bone. For that reason, we have abandoned primary and early secondary bone grafting and limit osteoplasty to the time after secondary dentition.



After over 40 years' experience, he wrote in 1971:

We must confess that the disfigurements mostly are the consequences of the surgeon's work. To unite the segments in a very early age means to connect the segments—more or less—by a bar of scar tissue hindering the tiny baby's maxilla to expand to an adult width and form. In addition: damaging of tooth germs, depriving the segments of their periosteum, especially of its anterior ends, brutal "realignment" for achieving an instant normal shape, and last, the bridging of the cleft by means of bone transplantation are highly responsible for the undesired results.

My compromise is as follows: . . . bridging of the alveolar and palatal part of the cleft should be made with the cranially pedicled mucosa of the septum by tilting it over the cleft and incorporating its edge into a pocket. The anterior ends of the segments should never be touched or denuded. The premaxilla should never be repositioned by surgical means. . . . The remaining velar part of the cleft is closed at 2 years utilizing bridge flaps and elongation of velar mucosa by Z-plasties.

At the 1969 Cleft Palate Symposium held in Chicago, foxy Mazaheri of Lancaster challenged Cronin of Houston, known to have championed early maxillary bone grafting:

Dr. Cronin, you mentioned that you had 11 bilateral cases and that out of the 11 you had 8 who had crossbites in terms of maxillo-mandibular bite. Are you saying to us that this is a good result, or a fair result? Does this show that you are achieving a better result in terms of maxillo-mandibular relationships as compared to those which most of us show without any early bone grafting or orthopedic therapy?

Cronin responded:

No, aside from stabilization of the free-floating premaxilla, I think that is the only part that is really good. As to the rest of it, I don't think it is any

better. In all our cases the orthodontist has been able to achieve a good occlusion, but whether we have helped him any by these early procedures is open to question.

Mazaheri countered:

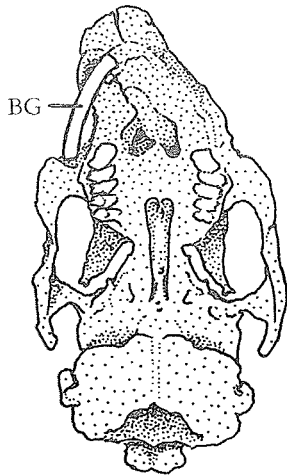
I believe in our experience that the major difficulty with these patients has been the scar tissue which is created by denuding the bone.

This comment reopened the “old wound” about the consequences of maxillary wounds and the subject was met head-on by Johanson:

I think the healing process that you get when you resurface that denuded hard palate with secondary epithelium is not a type of scar tissue in the same respect as the scarring of raising a mucoperiosteal flap and replacing it, which is followed by scarring and shrinkage.

David Davies of South Africa concurred:

It is a great mistake to compare the scarring of skin and scarring of a denuded area inside the mouth which behaves in a different way . . . and 14 days later, the whole anterior palate is healed. . . . It is hard to imagine that a large amount of scar tissue has been laid down, since the healing period is too short.



Skoog, in his 1974 book, noted the animal research of Engdahl and Hellquist and pointed to the deformity developing after subperiosteal maxillary resection and bone grafting. He concluded:

This investigation clearly demonstrates, that within a standardized maxillary defect, the bone produced by bone grafting behaves quite differently during growth than the bone which regenerates from a periosteal lined cavity that has been filled with blood. These observations may well explain the unfortunate results of primary bone grafting in infant clefts.

He then summarized and condemned early bone grafting with three sentences:

To restore maxillary continuity bone grafting techniques were implemented at early ages (Nordin and Johanson 1955, and Schmid 1955). Bone positioned in this way, though providing immediate stability, did not develop with the child (Thilander and Stenström 1967, Friede and Johanson 1974, and others). When retardation of facial growth became apparent this method of treatment was widely abandoned.

Pediatric surgeon Ambrose Jolleys of Manchester recalled in 1977:

At the Royal Manchester Children's Hospital, I worked with a general surgeon who then did the cleft lip or palate work and I became involved deeply in this depressing subject. I was concerned about the possibility that the surgeon aggravated the problem by his surgery and became interested in the possibility of pre-operative orthodontic procedures. After more training under Sir Denis Browne and David Matthews at Great Ormond Street, I returned to Manchester and with Professor Robertson have tried to evaluate the place of bone grafting and correct timing of palate surgery.

In 1972 Jolleys, with N. R. E. Robertson of Cardiff, reported a five-year study of early bone grafting in complete clefts of the lip and palate. At 3 months, after presurgical orthodontic treatment, closure was achieved for the lip, the anterior palate with a mucosal flap and the soft palate with a Wardill two-flap method. A retention plate was inserted until 11 months, when the hard palate cleft was closed and the plate returned until 21 months. In the experimental group, split rib grafts were fitted horizontally into the alveolar gap and surrounded by chips between the ages of 12 and 15 months.

No clear advantageous result could be detected in the grafted group. A notch remained in the cleft area and the grafted bone was insufficient to support a tooth in normal position.


On the other hand, limitation of growth occurred in the upper jaws in the graft patients and was manifested by reduced antero-posterior development, an increased incidence of crossbite, and a reduced area of upper jaw.

Evidence is presented that this deleterious effect became worse between the 4th and 5th years of age, and appears to be due to the presence of bone.


Bone grafting in young patients has been abandoned.

In 1972 Karl-Erik Hogeman with S. Jacobsson and K. V. Sarnäs of Malmö reported a follow-up of 145 cleft patients after secondary bone grafting. In some of the early bone grafting, they noted, the operation was successful, but clinical and radiographic review showed a deepening of the groove, indicating that the growth of the graft had not kept pace with the adjacent alveolar bone. They concluded:

Today we refrain from early operations . . . and now do not operate on patients below 12 years. In our experience, secondary repair with bone graft



Ambrose Jolleys



Karl Hogeman

has proved a safe and effective method for securing stable occlusion with improved lip appearance.

Charlie Horton of Norfolk, who had shown an interest in primary bone grafting, wrote in 1971:

Even if bone grafts do not prevent collapse, they help improve the nasal contour, the tooth environment and provide a symmetrically growing base for the child. I never was a proponent for a primary bone graft, and I still feel that bone grafts in later ages are worthwhile.



Franz Härle

In 1973 Franz Härle and Jürgen Düker of the University of Freiburg, West Germany, following comparative clinical investigation of children with unilateral clefts, found worse occlusion in the group with osteoplasty. Animal model tests in young inbred rats showed that the growth of the maxilla was significantly hindered if a bone defect similar to a unilateral cleft was simulated. Maxillary growth was severely, and in a statistically significant manner, impeded if the defects were filled with autogenous bone grafts. From clinical follow-up and animal experiments they concluded:

The logical consequence of our investigations is to abandon primary and early secondary osteoplasty. . . . The only possible osteoplasty in cleft surgery is a late secondary osteoplasty. . . . The operation should be done after the second dentition and after development of the mid-face, i.e., after the age of 15 years.



Wolfgang Koberg

In 1973, at the International Congress on Cleft Palate in Copenhagen, Wolfgang R. Koberg of the Rhinisch-Westphalian Technical College, Aachen, West Germany, renounced emotion and passion during discussion of early bone grafting and promised to discuss it purely factually, fairly and tolerantly. His last paragraph was pithy:

The first, and unfortunately to date the only exact report on late results following primary and early secondary osteoplasty in the cleft alveolus was made on the basis of a large group of patients and confirmed with statistical data and presented in Houston in 1969 (*Rehrmann, Koberg and Koch 1970*). In this oldest and (with 70 bone grafts) the largest group, it was possible, by comparing alternating rows, to show that after bone grafting in X^2 -test, moderate and most severe dysgnathia predominated highly significantly in

the sagittal and transverse directions on the side of osteoplasty in children. We have incriminated our osteoplasty for these alarming results of iatrogenic arrest of maxillary development, and have therefore abandoned primary and early secondary bone grafting. Similar decisions were also taken by *Hollmann* (1964), *Hollmann and Tomasoni* (1965), *Perko* (1966, 1969), *Manchester* (1969), *Mazaheri* (1969), and *Hogeman and Jacobsson* (1972). The cited disappointing late results were consequent upon osteoplasties which were achieved according to the principle of the Dusseldorf group (*Rehrmann* 1964, 1967, 1971; *Schrudde and Stellmach* 1958, 1959, *Stellmach* 1958, 1959, 1960, 1963, 1964, 1965, 1966, *Schmid* 1967). We have been waiting for the past 5 years for the late results of other large cleft centres (Hamburg and Stuttgart) (*Koberg and Veneziani* 1969), in order to make a definite statement as to whether it is only a question of difference in operative technique (*Pfeifer* 1972) or whether the grafted bone does actually hold the anterior ends of the segments together like a claw and thus stifle their intrinsic growth potential (*Koberg* 1970). Our long-term results were recently fully confirmed by *Härle* (1971) on the basis of extensive clinical investigation and additional animal experiments. Consequently, most severe maxillary deformities are to be expected as late results of primary bone grafting, so that late secondary osteoplasty remains as the only justifiable form of bone transplantation in cleft surgery.

BONE GRAFTING AT 5 YEARS

Impressed by his observations in India, that

the maxilla of adult cleft patients who had not been operated upon showed normal growth and form,

Wilfried Schilli of the University of Freiburg, West Germany, began a research study. At the 1973 International Congress on Cleft Palate in Copenhagen, Schilli, with G. Komposch and G. Munker, reported a study of 34 complete cleft palate cases in which rotation-advancement of the lip and Veau closure of the nasal floor were done at 3 months, Campbell closure of hard palate and Schilli modification of Widmaier method for the soft palate at 3 years. At age 5 with the aid of orthodontia when necessary, the arches were symmetrical. At this time half of the patients had their alveolar arches stabilized with autogenous pelvic bone grafts. First comparative study at 7 years of age revealed a slight tendency to underdevelopment of the entire



Wilfried Schilli

This might happen after 5 years even without grafting?

maxilla in all three dimensions, and deviation of the middle line to the grafted side was significant. At age 9 there was more evidence of disturbance:

90% need orthodontical treatment whereas the control-group after the Vomer-flap-operation only in 14% need orthodontical treatment.

Stellmach of Berlin noted in 1976:

Primary bone grafting in the average case did not show permanent improvement of the late orthodontic results nor could the necessity for later orthodontic treatment be minimized as expected beforehand. With the exception of severe hypoplasia, we postpone bone grafting to the end of the second dentition and maxillary growth.


In 1965 J. B. Lynch, Steve Lewis and Truman Blocker of the University of Texas, Galveston, reported 92 cases of maxillary orthodontics and early bone grafting. They commented:

The value lies not only in stabilizing the maxillary arch and in orthodontic correction, but in providing a mass of bone into which permanent teeth may migrate spontaneously or may be moved orthodontically.

By 1977 J. B. Lynch, now at Vanderbilt University and occasionally enjoying flushing dove, duck and quail from the Tennessee bush was expressing second thoughts:

During the wave of enthusiasm for early maxillary bone grafting in the early sixties, I was involved in over 300 cases. Follow-up of these patients has indicated that presurgical orthodontia and bone grafting has not uniformly prevented maxillary arch collapse, nor has it eliminated conventional orthodontic treatment. The bone graft itself tends to become quite thin and attenuated in the majority of patients. With the exception of an occasional bilateral cleft with a very unstable premaxilla where stabilization with bone graft might be of some benefit, I do not believe that maxillary arch repositioning and bone grafting in infancy accomplishes anything that cannot be better done when the child is older. I do, however, feel that the earlier orthodontic involvement in the care of these patients has had a beneficial impact.

Howard Aduss, orthodontist at Abraham Lincoln School of Medicine, University of Illinois at the Medical Center, Chicago, threw a staggering block against primary bone grafting at the Cleft Palate Symposium at Duke University in 1973. He summarized:



John Lynch

It would be remiss to omit an assessment of the current status of presurgical maxillary orthopedics and bone grafting. On the basis of reports by Rehrmann and co-workers after a five-year follow-up and Jolleys and Robertson after ten years, it appears that presurgical maxillary orthopedics continues to be employed to align segments to facilitate repair of the lip, but bone grafts have not provided the stabilization that has been hoped for; bone grafts have not decreased the prevalence of crossbite; and the grafts have provoked retardation in the development of the maxillary arch and local growth arrest of the maxilla. As a result of their findings and those of others, both Rehrmann and his group and Jolleys and Robertson have abandoned the use of primary bone grafts for infants and children.

EARLY BETTER BUT LATER BEST

At the International Cleft Palate Congress in 1969 in Houston, Bill Manchester of Auckland, New Zealand, accused bone grafters of having

all been led up a blind trail.


David Matthews of London, at the Second International Symposium on Early Treatment of Cleft Lip and Palate, held later that same year in Chicago, took Manchester's stand to task:

This seemed to me to be a most improper remark, however well-intentioned it might have been.

He continued to defend his own position:

The best craftsman that I have ever seen in this work was Tommy Kilner, and I spent a good deal of time as his junior. But as time went by I spent a good deal of time trying to correct some of the quite disastrous consequences of some of the most beautiful operations that he had done. Consequently, I am most reluctant to agree that if we went back to these early methods we would get better results than they did. At any rate, for these reasons, in 1960, I started doing early bone grafting.

Matthews spent several years experimenting and modifying. Always in the front line and with great technical skill himself, he probed the possibilities of early versus late bone grafting. In 1970, after seven years of experience, he reported, with Broomhead, Grossman and Goldin, his results.



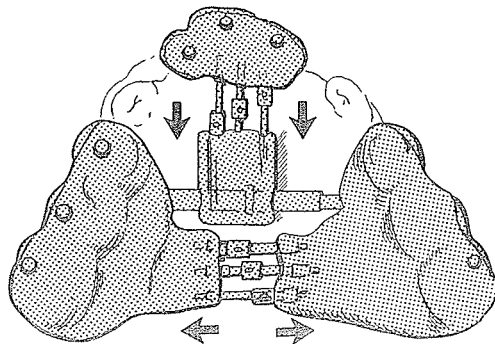
David Matthews

Preoperative orthodontics was begun within the first two to three weeks of life. In severe premaxillary protrusion, a Denis Browne type of setback was used. Matthews feels that the end result was not prejudiced by this radical operation provided the setback was backed up by bilateral bone grafts. In his early grafts, notched split rib grafts were inserted at 3 months of age into the alveolar gap in front of a Stellmach flap, small spare pieces being placed below the alar base. The survey included 84 cases with radiographic evidence of bone graft survival in 88 percent and teeth moving into the area of the graft and erupting in 31.5 percent. Perfect occlusion was found in 13 percent, perfect occlusion after minor orthodontics in 47 percent, failure resulting in maxillary collapse in spite of evidence of the bone graft in 14 percent and small arch requiring further surgery in adolescence in 25 percent. Possibly seeing the handwriting on the wall, Matthews wrote:

If primary bone grafting is ultimately abandoned, it will be because the long-term results do not justify it; not because of technical hazard.

ENTHUSIASTIC ABOUT LATE GRAFTING

In the late grafts the technique of "rapid expansion followed by bone grafting" was used as first reported at the International Congress in Washington, D.C., in 1963 by Matthews and orthodontist William Grossman. Sectional cap splints were applied to the parts of the maxilla and connected by a Fischer expansion screw set in acrylic. In unilateral clefts, a single screw was set transversely to expand the two segments; in bilateral cases, a second screw was set at right angles to the first to move the premaxilla. As Matthews remarked:



The secret of orthodontic success is the rapidity of the expansion.

Expansion was completed in two to three weeks with a turn of the screw three times a day. The segments were slightly overexpanded in younger patients in whom growth was not complete. Following expansion, a thin graft of iliac bone carrying periosteum was wedged well down into the alveolar gap between nasal and buccal mucosa after closure of any preexisting fistula.

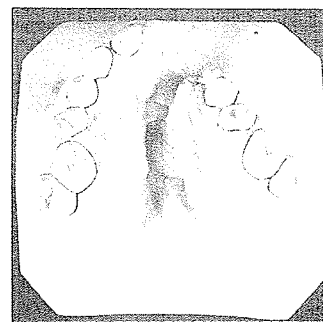
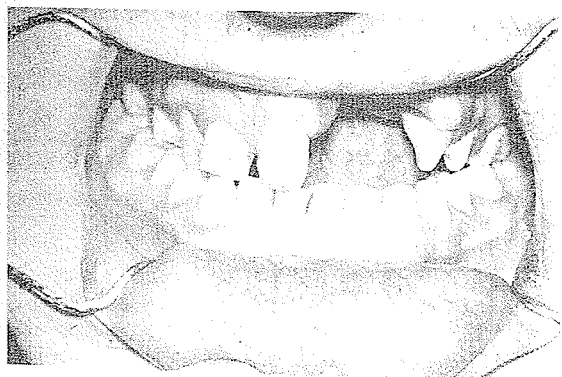
The bone graft extended back the full length of the hard palate and forward to support the alar base. The extension apparatus was maintained for seven weeks for consolidation of the graft, then a removable appliance was used for three months and finally a denture or fixed bridge was fitted. Although the first cases were undertaken at 10 to 12 years of age, Matthews in 1976 preferred to wait until 18 with the intention of setting the maxilla in occlusion with the *fully* developed mandible for permanent adult relationship.

Where rapid expansion and bone grafting failed to obtain normal occlusion because of retroposition of the maxilla, maxillary osteotomy was advocated six months after insertion of the graft. This action involved section of septal bone and cartilage close to the nostril floor and division of the pterygoid plates and lateral maxillary walls at the level of the antral floor.

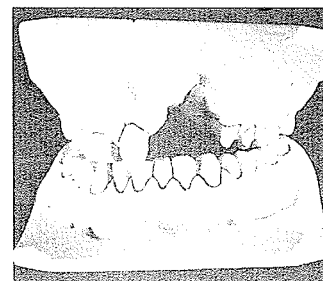
Of the 55 cases, 74 percent have remained in perfect occlusion and 15 percent have shown only minor degrees of lingual occlusion. In 10.5 percent there has been relapse, and thus these were considered failures.

In 1976 Matthews reviewed his position on rapid expansion in the teenage patient and included this case example:

Bone grafts are still used in cleft cases to maintain the maxillary segments in correct occlusion in a teenager, after rapid expansion with segmental cap

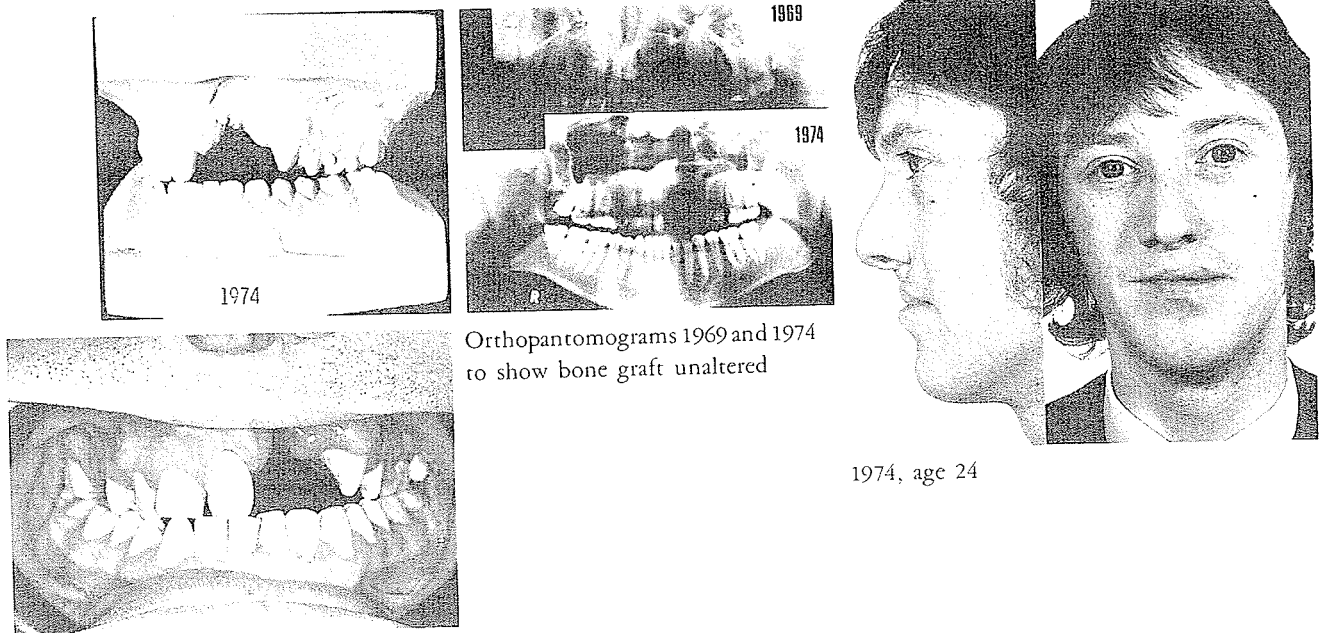


Preoperative—age 12 years



splints and distraction screws. The object of this operation is to restore the collapsed maxilla, after growth has taken place, by producing solid bony union through the full length of the bony defect. In 1969, I reported 50 successful cases out of a series of 55. In 1974, I reexamined the successes and have found that the position has been maintained.

It seems, therefore, that it is reasonable to claim that this procedure does restore permanent normal occlusion. An important additional benefit is the restoration of a patent airway.



Norman Robertson

In 1972 Norman R. E. Robertson of Cardiff and J. Fish of Manchester reported their experience with 40 cleft patients, 8 of them bilateral, who had had the clefts closed in infancy. Forty-eight bone grafts following rapid expansion technique of Matthews had been carried out between the ages of 3 years 6 months and 11 years 6 months, by means of cap splints with expansion screws and rib bone grafts. Robertson and Fish concluded:

1. Later bone grafting after preliminary rapid arch expansion does not prevent collapse and the recurrence of crossbite in the buccal segments.
2. The degree of collapse occurring may be related to the tension in the soft tissue of lip and cheek.
3. Over expansion might prevent relapse occurring but it is suggested that the method described is of limited value when considered in relation to the production of a better occlusion.

4. The later bone grafts remain *in situ* and do not cause interference to the antero-posterior growth in the maxilla. This may be related to the fact that not a great deal of antero-posterior growth is occurring at the ages studied.

They acknowledged:

This is contrary to the claims made by Matthews and Grossman for their series.

BONE GRAFTING AT 12 YEARS

In 1977 at a Cleft Symposium in Chicago, John Owsley of the University of California, recognizing the difficulty of early bone graft *take* and *expansion*, advocated maxillary bone grafting as a later stabilizing effect. At 12 to 13 years, when the patient is unwilling to wear a retention plate any longer and hence promises a propensity for crossbite, he advocates insertion of a bone graft. Using a split rib, a cortical wedge inserted into the cleft along with packing of cancellous chips, he constructs his stabilization of the maxillary arch. This is splinted with a lingual arch wire with spring expansion to throw stretch stress on the bone graft.

PRESENT STAND

Early placement of bone into a bony defect seems sound, but evidently there are other factors involved: (1) Not all clefts require bone grafting; (2) traumatic surgery in the area of young growing bone may affect subsequent growth; (3) scar or bone graft rigidity may retard growth. Yet a number of surgeons still favor primary bone grafting into the cleft followed by orthodontics to maintain arch position. The majority, however, seem to feel that, as this surgery does not invariably prevent crossbite and may retard maxillary growth, it is best postponed until after complete facial growth and permanent dentition!?