

## 17. Early Maxillary Bone Grafting

THE first bone graft to a cleft palate was carried out in 1901 by von Eiselsberg when he grafted an entire little finger—bones and all—into the cleft. The first attempts at bone grafting in growing cleft patients were made by Lexer in 1908, and the first successful bone graft to an alveolar cleft is attributed to Drachter in 1914. Veau's effort in 1931 to fill a cleft palate defect with tibial chips failed. Then there was an interval of indifference to this approach.

In 1952 a subtle preface to the osteoplastic era was provided by Axhausen, who wrote:

All attempts to induce bony healing through excision of mucosa in the area of narrow clefts and freshening of underlying bone surface have proved futile. . . . If there were a means of inducing subsequent bony healing between the premaxilla and the lateral fragments, this approach would be preferred; it would then be possible to preserve well-formed incisors. To find such means appears to me to be the final problem in the repair of complete clefts at present.

Suddenly almost everyone began bone grafting or apologizing for not doing so. In fact, the world literature on alveolar bone grafting read like a roster of the elite in a German Panzer Division as compared with the sparse but strong guerrilla bands from Sweden, U.S.A., Yugoslavia and Britain.

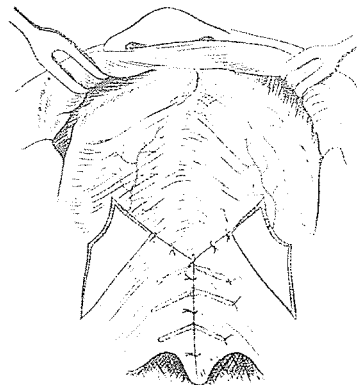
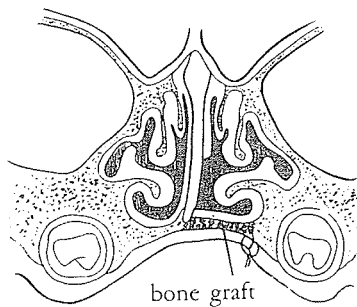
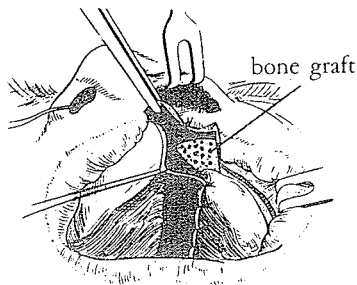
### SCHMID

In the modern era, Eduard Schmid of Stuttgart was the first to implant bone in infants with clefts. On the occasion of the



*Eduard Schmid*

Austrian Meeting of Dentists in 1951 to 1952 at Bad Aussee, Schmid reported several cases of cleft lip and palate in which he implanted small iliac bone grafts between the maxillary stumps after surgical closure of the cleft in order to prevent contracture in the cleft area. With multiple publications on this subject beginning in 1954, he struck the sparks that ignited an intense interest in bone grafts in the cleft maxilla throughout the world.




His follow-up report 23 years later is of great importance. Eduard Schmid, Werner Widmaier, Heinz Reichert and Klaus Stein in 1974 stated their present stand. Since 1962, 87 children with clefts of the lip, alveolus and palate (80 percent unilateral and 20 percent bilateral) have been treated by a modification of primary osteoplasty not only of the alveolus but also of the hard palate at the time of closure of the lip, usually at 8 months of age. Using compact and spongy layers of hip bone for grafting, Schmid and his colleagues noted:

We lay great emphasis to atraumatic handling of the involved tissue, mobilizing two flaps at the vomer and the lateral edge of the gap, which are rotated horizontally, thus obtaining two layers of mucous membrane to line the oral and nasal cavity. The space is filled with bone. Since only the actual margins of the cleft are involved, the blood supply of the alveolus and hard palate remain unimportant. At age 7 years the remaining cleft of the velum is closed, either by the method of Veau (1931) or, if feasible, again leaving the palatine arteries intact by the method of Widmaier (1961).

They concluded:

We now utilise primary osteoplasty in wide clefts, and achieve satisfactory results. However, we do not use this method in cases of primary compression, where the maxillary arch is first aligned by the orthodontist, before we stabilise it later by bone implant as Nordin and Johanson (1955) recommended.



*Bengt Johanson*

## JOHANSON

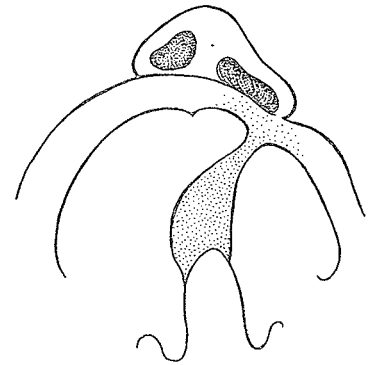
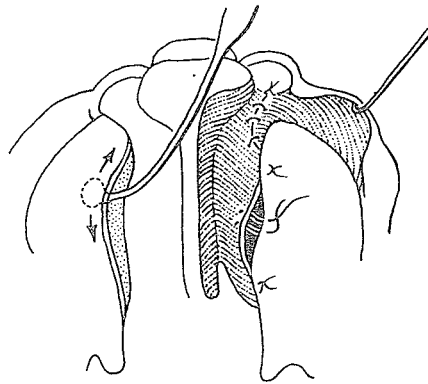
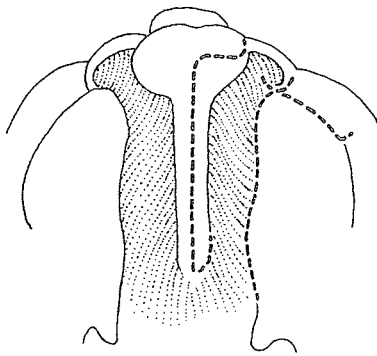
At about the same time Bengt Johanson of Sweden became interested in bone grafting the alveolar cleft. In 1955 Nordin and Johanson used a block of cancellous bone in the alveolar defect and chips of cancellous bone along the hard palate. Their bone

was obtained from the tibia in primary cases and from the iliac crest in secondary cases. In 1961 Johanson and Åke Ohlsson described their three-stage treatment of clefts:

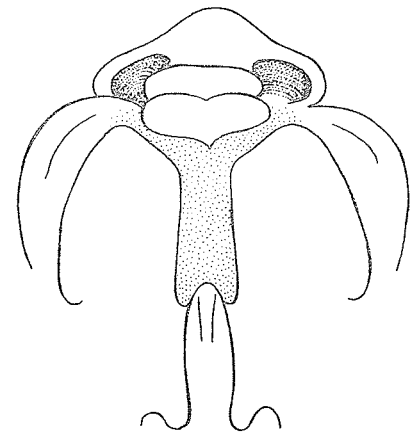
The *initial operation* is performed at the age of three to four weeks without special prior treatment. The nasal floor of the hard palate, in one layer, is closed with a vomerine mucosal flap and anterior to the alveolar process by direct adaptation of the labial soft tissues in two layers. The vomerine flap, which on the oral side is first covered with granulation tissue, has after some few weeks a stable covering of secondary epithelium. At this junction, the



Åke Ohlsson



*orthopaedic correction of the jaw* is started and continued up to the age of six months. Special expansion plates are used, fixed to a head cap by means of extra-oral shafts. At the *second operation*, the components of the upper jaw should be ideally positioned in relation to each other and in correct occlusion. Careful repair of the lip is now combined with transplantation of autografts, chips and marrow, in the cleft in the hard palate and alveolar process. The donor site is tibia. . . . A continuous orthodontic control is subsequently kept until the permanent bite is fully developed. At the *third operation* which is usually performed at one year, the posterior palate is closed. . . . The treatment has been completed in 27 primary and 31 secondary cases. The graft united and a stable homogenized upper jaw was secured in every instance.

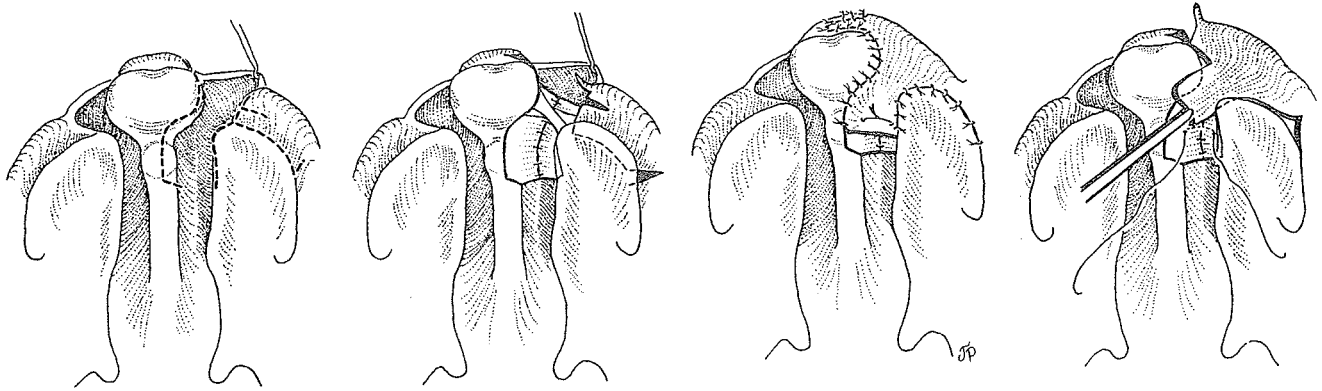


## SCHRUDDE

In 1957 J. Schrudde, while with Rehrmann in Düsseldorf, first published his plan of primary bone grafting to cleft cases using autogenous rib to bridge the defect anterior to the alveolar processes. In 1959 he readvocated this principle with R. Stellmach.



J. Schrudde

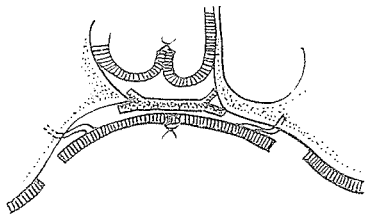


In 1965 Schrudde, now at the University Clinic, Cologne, Germany, reaffirmed his advocacy of primary bone grafting in the *British Journal of Plastic Surgery*, stating:

The procedure, however, had a favourable effect on the development of the upper jaw and the cutting of teeth. The graft also improved considerably the position of the base of the nose immediately above the lip.

He described his more recent approach:

I have of late been closing the palate after primary osteoplasty during the 14th, 15th or 16th month but I have also been performing plastic surgery on the palate at the same time by grafting a rib chip in the hard palate region from one edge of the cleft to the other. This rib chip across the cleft is there to stand up to scar contraction and it therefore guarantees that the upper jaw will develop in a normal way. . . . I apply the bridge flap method as does Axhausen, but I retain both vascular and nerve tissues at the major palatine foramen [which] serves as a more nourishing bed. . . . The important point is that this type of osteoplasty permits a very early cleft palate operation to be performed.



In 1971, after 12 years, Schrudde was still enthusiastic:

Encouraged by our experience of primary bone grafting, we have now altered that operative procedure and advanced the time of operation. The palate is closed by means of primary osteoplasty when the child is approximately 1½ years old and beginning to talk. . . . Under these conditions, the maxilla is able to put up more resistance to postoperative scar tension and is more stable owing to the fact that the alveolar graft has become consolidated, supplemented by the primary bone graft of the hard palate.

In 1972 Schrudde reported follow-up of his primary bone grafts, revealing good and bad results. This stimulated him to

continue the evaluation, which he reported at the Spanish Plastic Surgeons meeting in Las Palmas, 1976. Thirty-six patients from his group of 50 were reexamined while 14 did not return, probably because of satisfactory results. In order to demonstrate the influence of primary osteoplasty on the formation of the maxillary arch, occlusion in three planes (sagittal, transverse and vertical) was presented. The sagittal plane gives information on the degree of pseudoprognathia; the transverse plane reveals the palatine dislocation of the maxillary arch on the cleft side; the vertical plane measures the open bite. From 1972 to 1976 there was improvement in the positioning of the jaws in all planes.

The improvement can be attributed to intensive orthopedic treatment, and, as followed by x-ray studies, the transplants have become fully adapted functionally and firmly integrated in the maxillary arch.

To facilitate the evaluation of the x-ray films, a grade grouping of the transplants was outlined by Schrudde in accordance with their structure and size:

Group 0: Functionally fully inserted chip, clearly structured. The axes of the teeth near the cleft are almost parallel.

Group I: Functional adaption unsatisfactorily advanced; clear convergence of the teeth near the cleft.

Group II: Pseudoarthrosis or considerable loss of transplant substance with pronounced convergence of the teeth near the cleft.

Group III: Loss of the transplant or incomplete bone bridging of the cleft.

In 1972 the transplants were graded by groups and four years later regrouped. The improvement was impressive, as shown in the table.

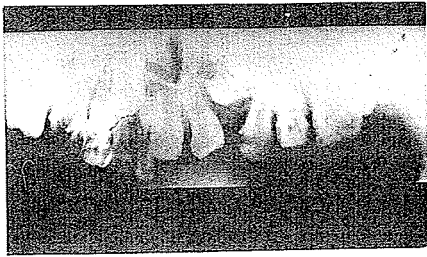A bite imprint of the upper jaw and the Panorex shot increased the reliable assessment of the transplants. Schrudde noted:

X-ray evaluation of the transplants is in many cases made more difficult by dentition and by superimposed parts of the bony facial structure, as seen in this case published in 1973 and re-evaluated in 1976.

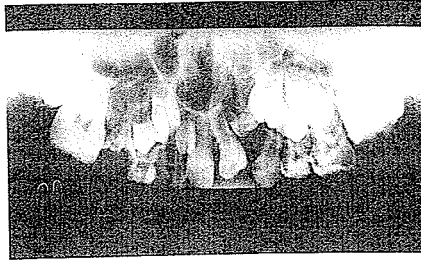Schrudde explained that the positive development on the part of the transplants was the reason for the improvement of the jaw positioning. He also clarified factors in the apparent improvement:

	1972	1976
Sagittal Plane		
normal:	18	23
1 on 1 palatoversion:	<u>4</u>	<u>6</u>
	22 = 61%	29 = 81%
Transverse Plane		
normal:	8	12
3 on 3 palatoversion:	<u>9</u>	<u>6</u>
	17 = 47%	18 = 50%
Vertical Plane		
normal:	25	26
1 on 1 unerupted teeth:	<u>3</u>	<u>5</u>
	28 = 78%	31 = 86%

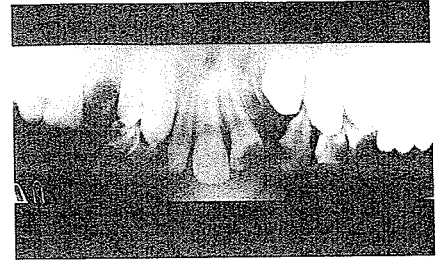
	1972	1976
GROUP 0:	20.4%	55.1%
GROUP I:	39.7	28.5
GROUP II:	22.4	8.2
GROUP III:	18.3	8.2



1971



1972

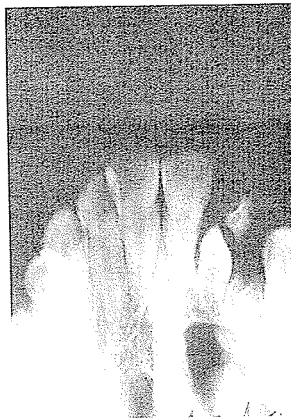


1976


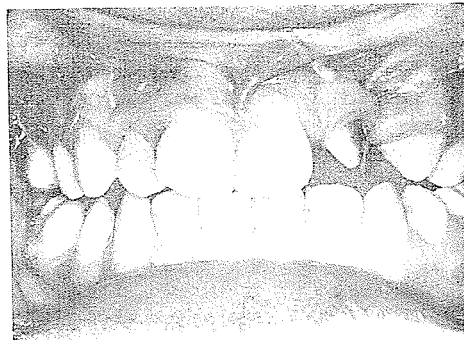


1971

All those cases in which x-ray pictures were taken during the cutting of teeth reveal a distinct reaction on the part of the transplant to functional stimuli. In many cases we found that the tooth piercing its way almost rarified the osteoplasty, till then well stabilized, down to narrow marginal areas. After the tooth had come through, we found in all cases we observed that there was a complete regeneration on the part of the transplant as seen in this 12 year old female.



1976



1976

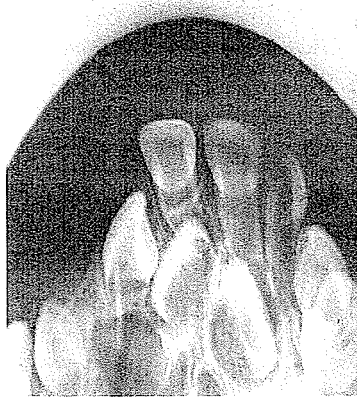Further evidence of adaptation of the transplant is seen in the processes of accumulation and breakdown as well as increase in thickness in certain areas of the transplant. The extreme degree to which an implanted piece of rib-bone can take its place in a stress system is demonstrated in these two x-rays.

Schrudde noted:

The 1963 figure shows a freshly implanted rib-bone, which has been positioned very far forward in the maxillary arch, a place that we do our very best to avoid these days. The 1964 figure shows the same transplant one year later. Processes of accumulation and breakdown have moved the transplant into a position through which the stress plane of the maxillary arch clearly runs. This process of adaptation promises that during further development the original bone transplant will be able to react to local stress in the required manner.



1963



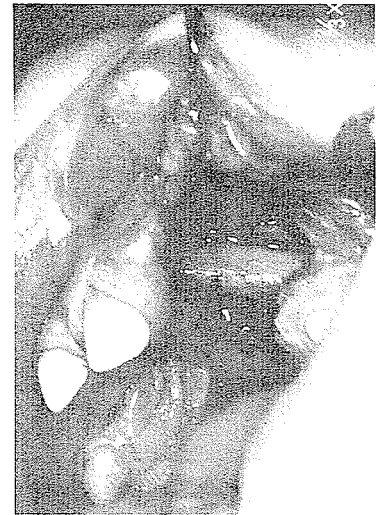1964

Schrudde summarized:


Assessment of primary osteoplasty in respect to its efficiency is completely satisfactory.

1. With increasing age on the part of the patient, there is significant improvement in occlusion.
2. Individual observations during dentition clearly show that the transplanted bone is not a passive bridging element.
3. The analysis of the process of accumulation and breakdown and especially of the spread of thickness shows that the transplanted bone is functionally adaptable. . . .

A cleft which has not been closed using bone will never be in a condition in which the jaw can react in a physiological manner to the demands made. Only primary osteoplasties promise to create conditions under which stress involved meets a system which, by virtue of its bony completeness, can react in a physiological manner to this stress.



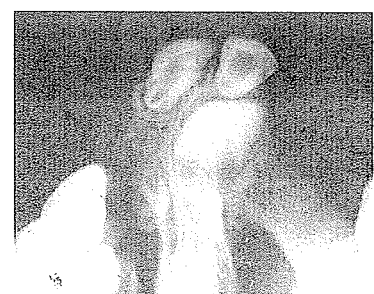Op. 1975



1975, Immediately postoperative



Early 1976




Early 1976

In conclusion, this occurs only if the surgery is correct. First the bed of the transplant must show no gaps, either in the oral or in the nasal direction. Suture dehiscence and infection in recent years has become a rare


occurrence. A complete rib segment is used as the transplant and this is cut in the shape of a V at both ends to ensure better positioning. It is desirable for the rib segment to be inserted under light tension. We have not experienced complications in taking out the rib and have operated on far in excess of a thousand children.

### BÄCKDAHL



Magnus Bäckdahl

In 1961 in *Acta Chirurgica Scandinavica*, musical M. Bäckdahl and dedicated K.-E. Nordin of Stockholm advocated bone grafting both the alveolar cleft and the remaining maxillary defect. This was facilitated by partial resection of the inferior turbinate in preparation for a modified Campbell two-layer cleft closure. They turned the septal flap down to cover the oral side and the lateral flap up to close the nasal side and packed "tib chips" of bone between the two. An x-ray follow-up (a) before bone graft, (b) three weeks after bone graft and (c) 12 months after shows adaptation of the bone structure.



Bengt Nylén

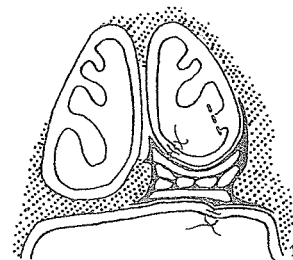
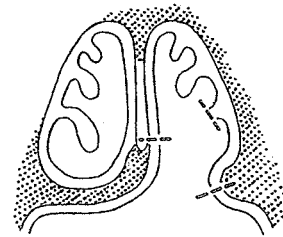
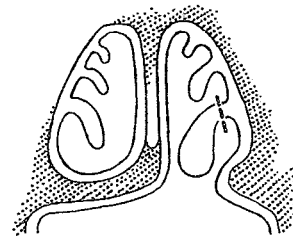
### NYLÉN

Bengt Olof Sixtus Nylén of Karolinska Hospital, Stockholm, an international traveler, was trained in plastic surgery by G. Webster and W. Pierce in California and T. Skoog in Sweden. In 1973 Nylén wrote me:

Bengt Johanson left Stockholm for Göteborg around 1957 but interest in primary bone grafting was maintained by Karl-Erik Nordin and Magnus




Bäckdahl, who in 1959 designed a four-flap method. Mucoperiosteal flaps with their bases along the cleft are brought together in pairs, to form a cavity in which the bone is inserted. In some cases, the anterior part of the inferior turbinate may be partially transected or used if needed. The rib grafts are placed with a large piece on the inside of the oral lining, another on the undersurface of the nasal lining and many small pieces packed between the two main struts. The anterior defect is lined by a mucosal flap from the sulcus.



In 1966 Nylén reported 254 cases, 66 with early bone grafting and 188 with late bone grafting, by this same method. In 1973 he wrote:

We have a special jaw orthopedic unit of 15 beds where the infants are brought at 2-3 weeks of age. The preoperative jaw orthopedics is started immediately by Nordin who is the full-time orthodontist. . . . After good alignment of the upper jaw, the early bone grafting operation is performed. . . . We have followed these cases and believe that so far the results are quite promising. We have not seen any deformities as have been reported in different bone grafted series with other methods. The crossbites found in these cases are about the expected frequency of other series. Cephalometric examinations show development similar to the normal facial skeleton. . . . With this treatment the patient is rehabilitated at a young age with a minimum of operations and with promising results.



*Karl-Erik Nordin*

At the 1973 Cleft Palate Congress in Copenhagen one of the original authors, Karl-Erik Nordin, with Arnander, Barr, Leanderson, Körlof and Nylén of Stockholm, reaffirmed the original 1963 Washington, D.C., Congress approval of early maxillary bone grafting. They gave a 7- to 12-year follow-up on the cases operated on between 1960 and 1966, 70 percent of which had been grafted before 6 months of age and another 22 percent before 12 months. The studies included casts, x-ray films and photos, hearing and speech tests, evaluation of appearance and function of the nose and lip. According to their evaluation of the 73 early primary bone grafts in the bilateral clefts, there were 20 with no crossbite and 36 with only canine crossbite. Appearance, speech, facial skeleton and ear function all compared favorably with those in the non-bone-grafted cases. Nordin went one step farther to describe his approach to transplantation of teeth to the bone grafted alveolar cleft when migration had not occurred. He presented a number of cases.

The endodontically treated and filled root is placed in the split and excavated alveolar crest and surrounded by small chips from the excavation. The root is covered with the mucoperiosteal flap elevated before the procedure. The development of the periodontal structure is followed by X-ray until it is time for applying a crown.

Finally, in 1974, Nylén, Körlof, Arnander, Leanderson, Barr and Nordin reported primary bone grafting in complete clefts and concluded:

From the point of view of appearance, the results were excellent or good in 80% of patients with unilateral complete clefts. The corresponding figure for bilateral cleft group was only 50% and 50% of these patients needed secondary operations. . . . In speech assessment, reduction in open nasality and improved articulation (particularly consonant production) were noted in the bone-grafted group. . . . The results presented . . . appear to us promising and indicative of a need to pursue further this form of treatment.

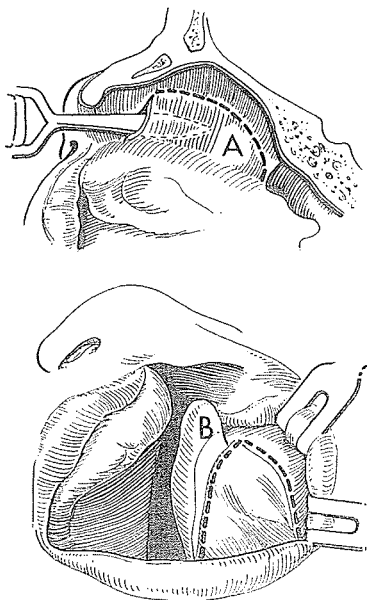
#### W I D M A I E R

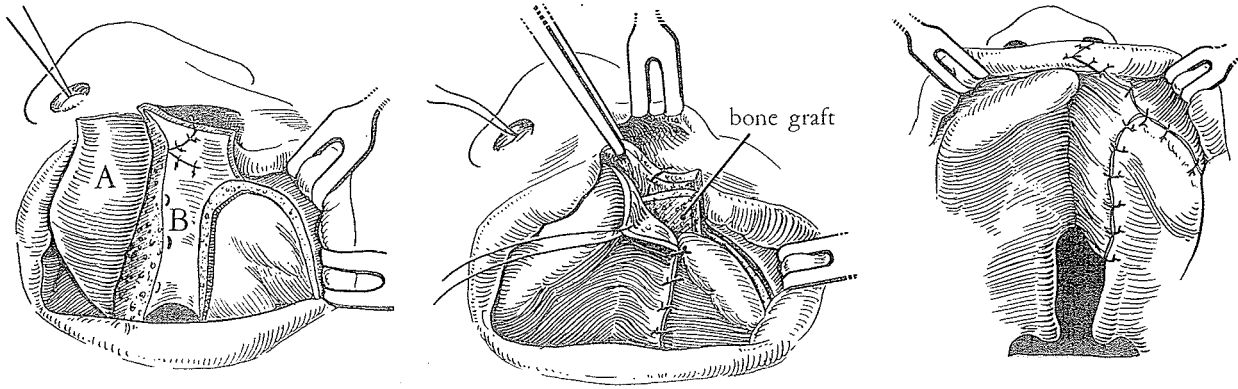
Werner Widmaier, a war-wounded patient of Schmid's, modified the method in 1959. In 1964, at Schuchardt's Second Hamburg Symposium, he and Schmid gave their reasons for bone grafting:

Check-ups of the complete cleft-palate cases showed . . . in a good percentage of the unilateral clefts the dental arch developed normally.

However, mostly in bilateral clefts, contracture of the dental arch could not be avoided. These experiences led us to the primary simultaneous osteoplasty into the cleft of the bony structures.

They presented their method of dissecting the mucoperiosteal flap from the lateral cleft edge. The lateral flap was used for nasal closure and the vomer flap for oral cover, and bone from the ilium or rib was inserted between the two. This maneuver achieved a two-layer closure with bone between both in the alveolar area and all the way back to the posterior edge of the hard palate. They then used Widmaier's method for the soft palate.





## REICHERT

Heinz Reichert, a former student of Schmid, gave an interesting comprehensive review in 1969, putting events in perspective:

The development and method of bone grafting used in 450 unilateral and bilateral clefts at the Stuttgart Clinic will be described. From 1951 to 1955, bone was grafted 3–4 weeks after the primary lip repair. . . . By 1956 both procedures could be done in one operation, as published by Stellmach and Schrudde at that time. The children are 7–8 months old at the end of surgery.

The x-ray controls from 1951–6 and the findings with the 2-stage cases demonstrated that the bone graft, when it “took” on both stumps had suffered a deformation after 2–3 years . . . so that only a small step was left. At the same time the alar bases and nasal floor sunk slightly and at the alveolar process and hard palate the mucoperiosteum contracted upwards. In severe clefts, in spite of bone grafting, we discovered a slight collapse in the premolar and molar region which gave to the alveolar arch the hint of a lyre shape.

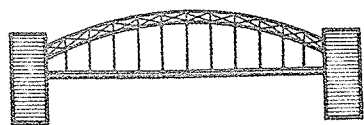
The practical result to come out of these observations was to enlarge the bone grafts in both vertical and horizontal dimensions. In the vertical dimension we now fill the cleft with a “bone span” extending from the nasal floor, alar base and pyriform opening down to the alveolar edge. Horizontally, the bone graft extends from the anterior edge of the maxillary arch to the posterior edge of the hard palate. In areas where resorption is expected since there is little or no functional burden in the first years after surgery, particularly in the nasal floor and alveolar ridge, we have grafted cartilage from the “pelvic edge” (Beckenkamm)—this is usually not resorbed and is not replaced by bone until 14–16 years.

The determining factor for bone graft success is soft tissue coverage of the bone graft. Based on Wassmund's (1939) two-layered closure of the nasal floor, combined with Campbell's and Pichler's techniques for closure of the hard palate, Widmaier (1956) developed his own method which allows bone grafting of the complete cleft area. . . .

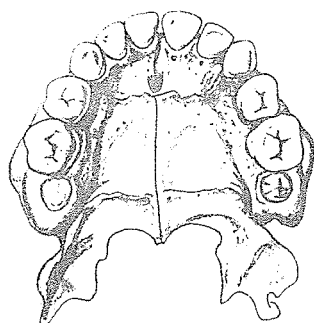
The primary operation works positively not only on the width of the maxilla but also on the nasal symmetry, contour of the upper lip, alveolar edge and palatal vault. We no longer see depressions of the alar base on the cleft side because the pyriform "ring" is closed by a cartilage-bone graft which forms a lasting foundation.

### *Bone Grafting Clefts of the Velum*

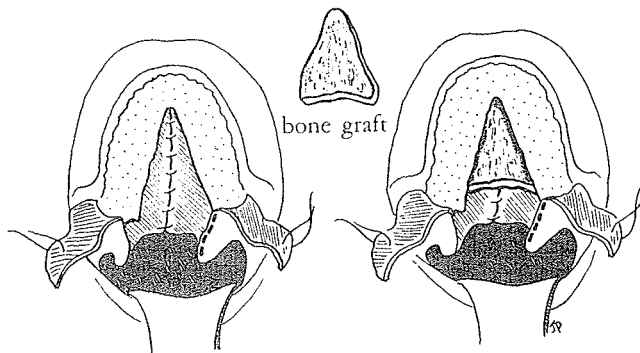
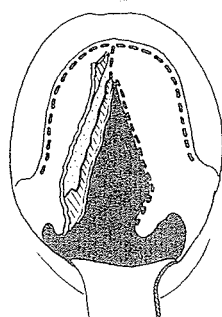
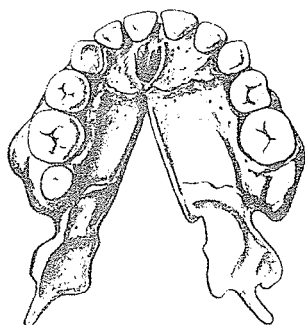

In 1967 Reichert began to apply osteoplasty to wide clefts of the velum alone, since here too he had observed partial contraction of the molar region in the maxillary arch following cleft closure. In 1970, in the *British Journal of Plastic Surgery*, he explained this occurrence and gave his solution:



This is quite understandable when the difference between healthy and cleft palates is borne in mind; the roof of the normal is arched like a bridge from one tuberosity to the other, while in the cleft palate, the frontal part of the maxillary arch is like the middle of a bow, the free ends of which can be bent towards one another by the tension of a cord, in this case represented by the scar. . . .



In wide palatal clefts therefore we now implant a triangular piece of iliac bone, completing the roof of the hard palate, giving the closed soft tissue layers support, reducing scar formation, preventing maxillary compression and shaping the palate to normal roundness.



This indirectly improves speech results since the movable soft palate does not become shortened by contracting scars and has a solid base for the new attachment of the muscle fibres mobilised from the edges of the clefts. If in some extremely short palates a pushback procedure has to be performed later, the result is stabilized far better by the incorporated bone. Furthermore, as cleft patients grow older, the function and retention of a dental prosthesis will certainly be better on a solid hard palate.

Reichert concluded:


It is considered that at least 10 years after operation is necessary before final assessment. This period has already elapsed in some 150 cases of complete clefts (lip, alveolus, and palate) treated with primary bone grafting and we have observed a significant improvement; most cases show no compression at all.

### SCHUCHARDT

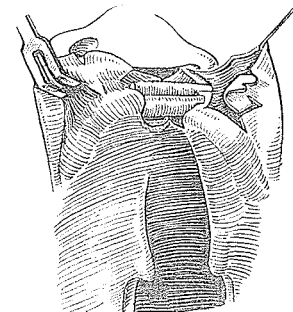
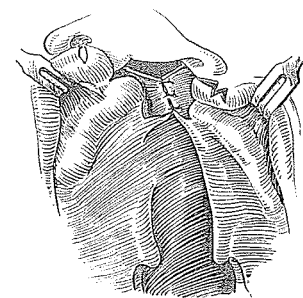

Professor Karl Schuchardt of Hamburg, head of a 450-bed maxillofacial surgery unit in a Berlin military hospital during the entire Second World War, has been a leading force in Germany ever since then. We had the pleasure of visiting his charming home (as shown) during the Second Hamburg Cleft Palate Symposium. Schuchardt has employed primary osteoplasty and bone grafting to the alveolar cleft at the time of lip closure at the Nordwestdeutsche Kieferklinik since 1958. By the time of his report with Pfeifer and Kriens at the Rome Congress in 1967 he had 419 cases.

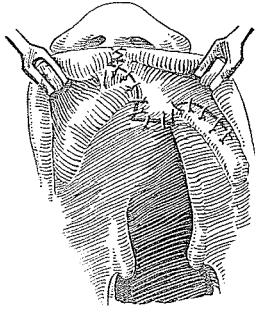
The combined procedure was performed at 6 months of age. He created the alveolar pocket for his bone grafts from local nasal mucosa for lining, like Veau-Axhausen, and from buccal mucosa with his improved modification of the Burian-Trauner flap to get more tissue for oral cover. For wide clefts he admitted using Stellmach's vomerine mucosal flap.

With a typical North German show of strength, Schuchardt advocated the use of two full-thickness rib grafts. These were dovetailed at both ends to straddle the alveolar gap at the edge of the pyriform aperture so as to fill the bony defect and support the alar base.



*Karl Schuchardt*

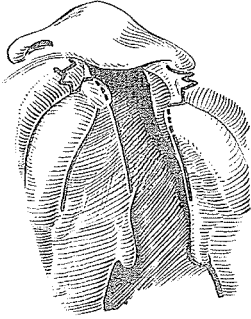




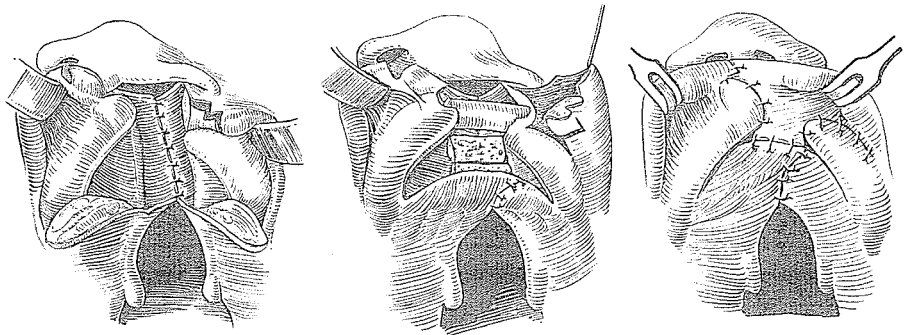
In some cases he extended the bone grafting into the hard palate area, laying cross-strips of split rib.

According to Schuchardt:

A most important characteristic of the solid rib graft is that it is able to withstand the pressure of the united muscles, predominantly the orbicularis oris. Thus the rib graft not only prevents collapse of the lateral maxillary segment but also transmits the pressure from the premaxilla to the lateral segment and forces it outward.



This action improves the development of the alveolar arch. It should be stressed that the implanted rib acts by orthopaedic means, thus eliminating any preoperative orthodontic treatment and reducing the later postoperative treatment to minor orthodontic measures.



Another advantage of solid rib transplants, which keep the alveolar segments at their proper distance apart, is that crowding of teeth close to the cleft will be improved as adjacent teeth migrate into the incorporated grafts. Thus primary osteoplasty is an important physiological means of improving dental alignment. Since the transplanted bone has no inherent growth potential, teeth which have moved into the incorporated grafts favour regional bone growth.

In his enthusiasm for his own regimen, Schuchardt attacked Herfert's opinion:

My experiences are incompatible with Herfert's opinion [based on findings in the dog] that the detachment of the palatal muco-periosteum is the cause for the underdevelopment of the hard palate later on.

He expressed his suspicion that the postoperative deformity was caused not by the detachment of palatal flaps but by contracture in the area of the cleft closed with nasal mucosa only. He reemphasized that his satisfying functional and aesthetic results had been achieved by surgery alone.

## STELLMACH


One of the outstanding German leaders in cleft palate surgery is Rudolf Stellmach of the University of Berlin. His acute sagacity and unusual generosity have made it possible to include several rare portraits in these volumes. One of Stellmach's important contributions has been his modification of the vomerine flap used for oral closure of the alveolar cleft. He first presented this method in 1959, and it has been adopted by many surgeons throughout the world. As he stated in 1964:

In our experience anterior lip mucosal flaps are limited to smaller clefts since branching off a wide lip flap may cause too much loss of inner lining of the lip and a narrow vermilion border.

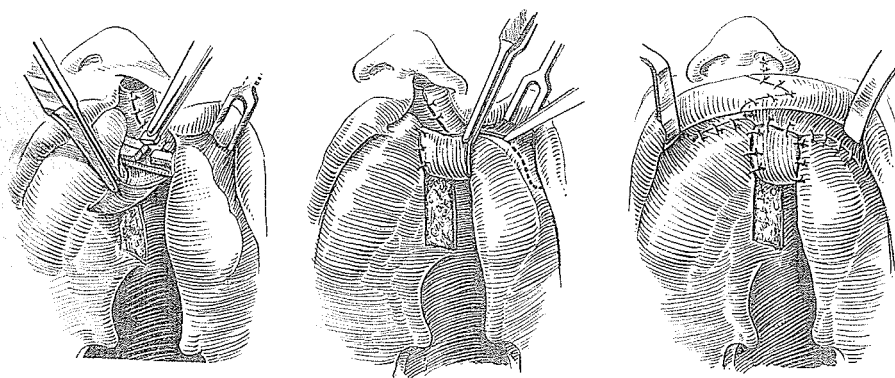
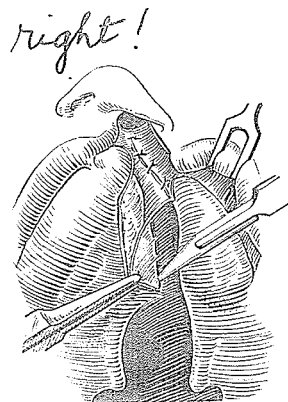
Therefore, in the large type cleft we prefer to cover the bone graft behind. The vomer flap is raised in its full length, but the posterior part is cut in at the cranial base from behind to the front, forming a tongue-like flap. It is turned forward to serve as the back and oral layer of the bone bed.

In 1976 Stellmach wrote:

We still do bone grafts to the alveolar gap and we use the tilted vomer flap [Stellmach] for covering the autogenous rib implant exclusively. Nevertheless the indication for primary bone grafting has been minimized to extreme total clefts. That means clefts with a severe hypoplasia of the alveolar arch bone in the cleft area. Determination can be made on either intraoral x-rays or on the basis of simple clinical judgement or orthodontic measurement of



Rudolf Stellmach




the alveolar arch length in comparison to the opposite side. In these rare cases, the central incisor tooth buds will be absent, along with or without the lateral incisors. Early bone grafting helps to prevent a severe collapse of the arch.

In 1977 he added:

Formerly when we closed the hard palate at the time of lip repair, we often got overriding of the arches and secondary arch malformation. If narrowing is produced strictly between the alveolus of both cleft sides, the alveolar arch will abut end-to-end within a few months' time. It is my feeling the surgeon should assist arch alignment as far as possible by careful selection of his procedures.

### BRAUER AND CRONIN

In 1962 Brauer, Cronin and Reaves reported their first 10 cases of early maxillary orthopedics and alveolar bone grafting. Then at the American Cleft Palate Convention in Washington, D.C., in 1963, Brauer and Cronin were the delegates from Texas promoting the combination of maxillary orthopedics and anterior palate bone grafting. They reported two and one-half years of experience with the McNeil principle: using the motor force of the baby's gumming and sucking from within, working against an acrylic plate, to guide the maxillary elements into alignment.



At 1 to 2 weeks of age the infant was brought to the office, and Brauer or Cronin took an impression of the arch in warm Kalginate. That same evening a dental student poured the impression into stone and later prepared a plate with an expansion screw. The plate was inserted and the mother instructed to turn the screw once a day or once a week, depending on the need for expansion. For a protruding premaxilla in a unilateral cleft, a bypass plate was employed, and an elastic band attached to a cloth headcap was used to bend the premaxilla around. This action took about two months and was followed by lip closure.

In bilateral clefts, the lateral maxillary segments were expanded by the screw plate while elastic traction was applied to the protruding premaxilla.

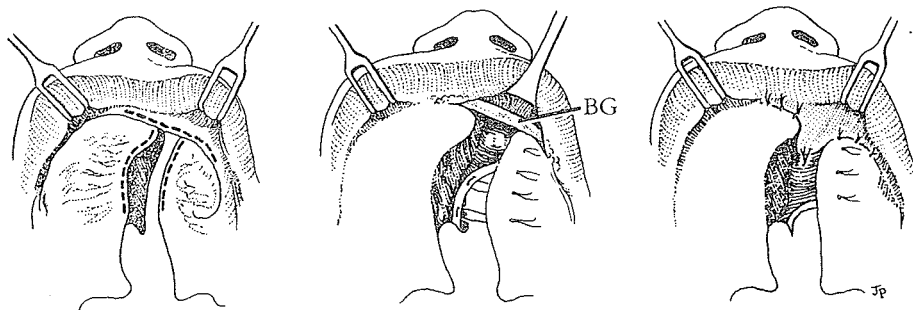
Once the relationship of the upper arch to the mandible was as close to correct as possible, the bone graft was inserted. The insertion had been made as early as 4 months of age, with an average of 8 to 12 months, and had been done before, during and after anterior palate repair.

As Scott of Ireland demonstrated that forward growth of the maxilla occurs primarily along the septal-maxillary junction,



Brauer and Cronin reasoned that fixation of the retarded cleft segment to the normal, growing maxillary segment should provide orderly advance of both elements. They gave their threefold purpose in bone grafting:

1. To fix the cleft maxillary segment to the normal side.
2. To provide support for the teeth in the region of the bony cleft.
3. To build out the flat contour often seen on the cleft side of the maxilla.



They turned a vomer mucosal flap over and sutured it to a mucoperiosteal flap from the cleft side for the nasal closure. Rib grafts were used as onlay strips, wedged into the alveolar gap, and chips. The oral cover was supplied by advancement of the labial mucosa over the bone grafts and suturing to the vomer flap.

#### HORTON AND OTHERS

At the same Washington Cleft Palate Convention in 1963 a Virginia contingent of Horton, Crawford, Adamson, Buxton, Cooper and Kanter reported similar interest in prosthetic prevention of maxillary collapse and fixation with bone grafting. They claimed 63 bone grafts since 1957 and noted that they appear to help prevent maxillary collapse . . . aid in the development of teeth adjacent to the graft and help fill out the alveolar ridge contour.

Georgiade, Pickrell and Quinn reviewed 2,200 of their cleft lip and palate patients at the Duke University School of Medicine and concluded:

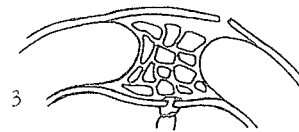
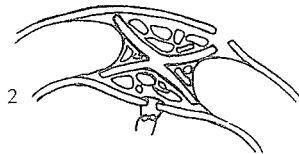
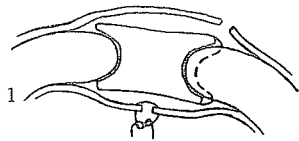


Nicholas Georgiade

It became clear to us that many of our results, particularly in the bilateral cleft and complete alveolar cleft group, were short of our desired goals from both functional as well as esthetic standpoints.

Over a two-year period they visited various European maxillofacial centers in Prague, Göteborg, Uppsala, Düsseldorf and Hamburg and were impressed that, in spite of the enthusiasm of the individual surgeon for a particular procedure,

No one surgical procedure could be used for closure of all various sizes of alveolar clefts . . . but . . . the replacement of the missing segment of the alveolar arch with a bone graft appears to have considerable merit . . . stabilization of the arch . . . prevention of collapse.




Although they expressed preference for cancellous bone taken from the ilium inferior to the crest, they suggested three ways of using a rib graft: (1) H-shaped strut wedged between the alveolar ends, (2) linear separation of the rib ends and insertion into the cleft and packing with chips, or (3) rib chips used to fill the mucoperiosteal pocket.

It was their feeling in 1964, with 42 cases in various stages of orthodontic treatment and bone grafting, that

These procedures singly or in combination will become a part of the overall management of patients both as primary and secondary procedures.

### ČUPAR



Ivo Čupar

Professor Ivo Čupar of Zagreb, Yugoslavia, in 1964 noted that secondary maxillary deformities occur only in total clefts, while in subtotal ones with an intact alveolar arch there is no clinical evidence of such changes. Thus he reasoned:

Primary osteoplasty converts total clefts into subtotal ones and this considerably diminishes the likelihood of developing deformities.

Yet the transplanted bone must be protected from the stress and strain until fully consolidated. Having this precaution in mind, Čupar explains his approach:

In small children 1 or 2 years old following osteoplasty and complete cheiloplasty, I usually introduce an orthodontic plate to maintain the

existing shape of the alveolar arch: to resist for a few months an undesirably strong pressure of the lip.

### PREVOMERINE GRAFT

For special bilateral bone grafting of the clefts, several surgeons turned to thrifty use of the excess bone. In 1960 Oberniedermayr of Munich advocated surgical repositioning of the premaxilla between the lateral segments, using the resected prevomerine bone for grafting. He created a small bone bed with little local flaps and stabilized the premaxilla by Kirschner wire transfixion. In one of his double cleft lip and palate operations the transplanted bone was lost by infection after two weeks, but bone consolidation occurred similar to that described by T. Skoog.

### PFEIFER

Pfeifer of Hamburg, assistant to Professor Schuchardt in 1962 and later in 1964 reported a method of triple osteosynthesis he developed for exceptional cases of bilateral clefts with extreme protrusion of the premaxilla. Mucosa was turned to form a bed for the transplants. A cylindrical piece of prevomerine bone was taken, split into two pieces and inserted into both alveolar clefts to fix the alignment of the retroposed mobile premaxilla. Pfeifer claimed a stable union with symmetry.

### SCHRÖDER

Friedrich Schröder of Würzburg is another who favors early bone grafting. In a 1973 book edited by Schuchardt, Steinhardt and Schwenzer he reported early rib grafts in the form of full-thickness struts across the gaps in both unilateral and bilateral clefts at the primary operation. To the question about subsequent maxillary deformity, he stated:

With orthodontic treatment growth disturbance can be avoided.



*Friedrich Schröder*

## MONROE

Clarence Monroe of the Chicago Children's Memorial Hospital reported in 1969 a four-year follow-up. He had closed the lip under local anesthesia between 2 weeks and 3 months of age, or at a weight between 7 and 10 pounds. A day or two before, Bailey Jacobson and Sheldon Rosenstein had fabricated a prosthesis to cover the hard palate from the canine teeth back to the tuberosity with enough extension of soft acrylic into the cleft on the superior aspect to achieve retention of the plate. After lip closure the plate was inserted. Muscle pull rotated the premaxilla, but the plate prevented narrowing of the cleft until the premaxilla was back in good arch form by 1 to 2 months, or even 4 to 10 months. When the premaxillary ridge was touching the lateral alveolar ridge, the position was stabilized with a rib bone graft. A prosthesis protected the bone graft two months for stabilization of the graft. At 1 to 1½ years, a von Langenbeck closure of the palate was achieved.

In 40 cases treated over four years, no instances of severe contracture of the upper dental arch have been seen. In two cases, when the alveolar ridge lined up excellently, palate closure was done at the same time as the bone graft. This procedure promptly pulled the alveolar ridge off alignment into crossbite. Monroe and Rosenstein feel that

Position of the arch should be stabilized with well-healed bone graft before palate is repaired.

## ROSENSTEIN

Mellifluous Sheldon Rosenstein, holding dual professorships in orthodontics at Northwestern University in Chicago and St. Louis University in Missouri, is also the orthodontist working with Clarence Monroe. In 1967 he described management of the maxillary segments in complete unilateral cleft patients. He reconfirmed his stand at the Duke University Cleft Palate Symposium in 1973, stating:

We claim no panaceas, and we do not think it is *the* only approach. It is *an* approach and carries with it a definitive sequence of procedures. In essence,



Sheldon Rosenstein

it consists of (1) the placement of an intraoral prosthesis prior to lip closure, (2) molding of the arch segments, (3) stabilization of the segments by means of autogenous bone graft, and (4) retention of the prosthesis until palate closure. We are generally finished with the early infant procedures when the children are 15 to 18 months of age.

Two major avenues of legitimate investigation and concern should now be mentioned. First . . . does early maxillary orthopedics and osteoplasty do any harm, and second, do these procedures do any good?

Rosenstein admitted that his oldest patient in this series was only 7½ years and therefore he did not know the answer to either question. He did note that at 5 years of age some good and no harm was evident. He concluded:

Despite disenchantment in some quarters, we are not yet prepared to abandon these procedures. On the contrary, we are still very much excited about them.

Since then Rosenstein has co-edited the comprehensive book *Cleft Lip and Palate*. In 1975 in the *Angle Orthodontist* he concluded:


Thus far, we are able to state that in our sample, using our treatment procedures in the sequence advocated, we have seen no growth attenuation in the posterior/anterior dimension. The maxilla, at least to the ages observed, does not appear to have been attenuated by our procedures.

Further, it would seem that after a limited first phase of orthodontic treatment to align dental units, the degree of crossbite is considerably smaller than . . . those using more conventional approaches; thus it is possible that we are doing some good.

We are still using these procedures on our newborn and continue to feel that we have a real opportunity to be able to do more orthodontically for these children when they possess a full permanent dentition and are ready for comprehensive treatment.

## GRIFFITH

In 1977 B. Herold Griffith of Northwestern University, following Clarence Monroe and joining Sheldon Rosenstein, noted the encouraging results he had seen and was getting with maxillary bone grafting. He is following 118 cases, 36 of them more than 10 years postoperative. Evaluation of the cases includes Broad-



Herold Griffith

bent-Bolton measurements, cephalometric studies, occlusal films and team evaluation. No retardation in maxillary growth and fewer problems with the dental arch are reported. This is the design of treatment: Preoperatively the patient is fitted with a prosthesis by Rosenstein, which is inserted at 2 to 3 months when the lip cleft is closed and the muscle begins to align the segments. At 5 years of age, with minimal undermining and inturning of mucoperiosteal flaps at the alveolar cleft edges, a split rib strut is placed as an onlay subperiosteally across the cleft, a rib block is inserted into the cleft and buccal mucosa is used for cover. In the bilateral cleft, a jackscrew expander spreads the maxillary segments to give the premaxilla a chance to take part in the arch, and then the same method of bone grafting is used. After a wait of six months for bone graft solidification the palatal cleft is closed. Under this regimen, Griffith claims that there is no evidence of attenuation in maxillary growth and there is less evidence of dental deformities previously considered unavoidable.

#### ROBINSON

In 1969 Frank Robinson and Barrie Wood of Manchester, England, admitted that many surgeons of the United Kingdom considered bone grafting of cleft palate unjustified, the main criticism being that the combined soft tissue and bone grafting procedures took more than the classic hour allowed for such surgery. They noted that with good teamwork the total procedure could be completed in an hour and a half and then reported:

In unilateral cases the results have been impressive in that only three examples of alveolar collapse occurred in 21 cases. . . . Bilateral clefts have presented greater difficulty; orthodontic correction has been more prolonged and less satisfactory and only six cases of the nine in the series were grafted. Three of these collapsed. . . . It will take several years before definite conclusions can be made but our interim conclusions on primary bone grafting are:

1. That collapse of the lesser maxillary segment is prevented.
2. That the lesser segment is brought under the growth stimulus of the nasal septal cartilage and the middle third of the face grows as one unit.
3. That teeth which have formed at the margins of the cleft tend to migrate into the grafted zone.

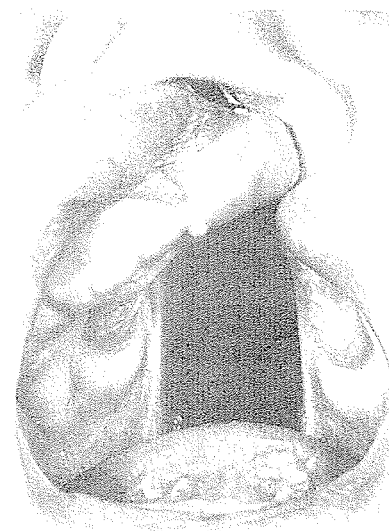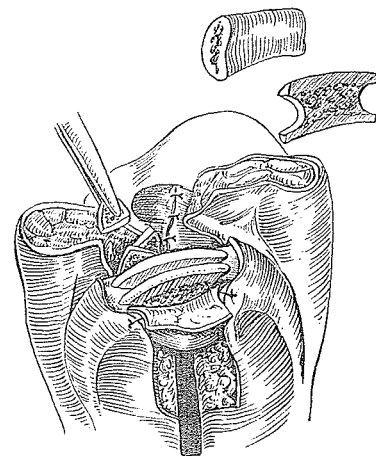
When this paper was given in Newcastle, George Joss suggested that the good results here might be explained by their accurate two-layer soft tissue closure of the alveolar space as described by Muir.

### MATTHEWS


The articulate David Matthews, with Ivor Broomhead, orthodontist William Grossman and Henry Goldin of the Hospital for Sick Children, Great Ormond Street, London, reported in 1970 on early bone grafting in clefts over a seven-year period from 1962 to 1968. The patients were operated on at 3 months of age with the left seventh rib as donor area. The split rib grafts were notched to fit snugly into the alveolar gap and covered with a Stellmach flap. Then small spare pieces of bone were inserted below the alar base. In bilateral cases, which are operated on in two stages at an interval of three weeks, sufficient bone is taken for both sides, and half is stored subcutaneously in the chest wound for subsequent use. When the severity of the projecting premaxilla demands surgical retropositioning, Matthews encourages use of Denis Browne's "set-back" without concern if bolstered by bone grafts. These authors noted:

Preoperative orthodontics is of great value. . . . But it is not, of course, a passport to certain surgical success.


In 1976 Matthews forwarded this case (A. Position before orthodontics. B. After orthodontics. C. Eruption of teeth. D. Clinical appearance) and included the x-ray films to show the eruption of teeth along the line of the bone graft (E. Rib strut. F. Teeth erupting along the line of the graft). He explained his present stand:



A



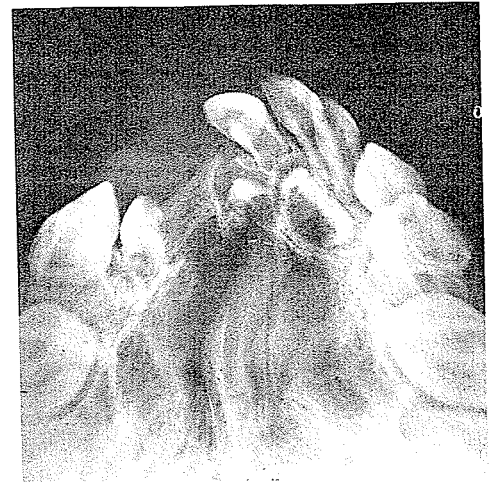B



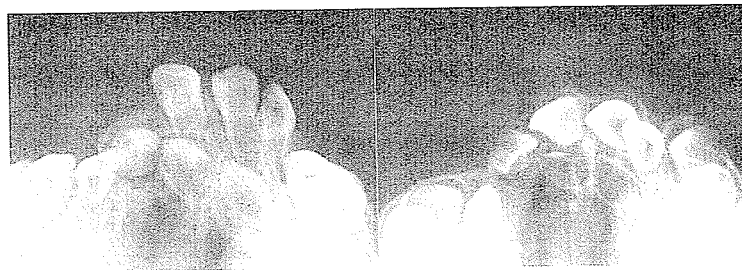
C



D



E




F

I have used bone grafts in the neonatal period to bridge alveolar gaps for 16 years. A rib is used and it is inset as two struts after separating it longitudinally to increase the amount of cancellous bone exposed. Clearly, an alveolar strut cannot be the answer to the problem of maxillary collapse, but it has a value. It assists greatly the maintenance of the alveolar arch, preventing anterior overlap, and it provides a matrix into which tooth buds bordering the defect can migrate. In my series, this has occurred in 31% of cases. . . . In order to achieve maximum advantage for the alveolar arch, it is necessary to position segments with preoperative orthodontics, so that the lesser segment cannot swing medially on the graft as a pendulum. It is probable that this preoperative manoeuvre has given me much better long-term maintenance of the alveolar arch than other workers have reported. The graft provides maintenance of the alveolar gap as well as the arch, but it cannot, of course, prevent medial displacement of the posterior part of the lesser segment. I have never thought it logical to fill the full length of the bony defect with bone for fear of reducing subsequent growth and expansion through childhood. In every other circumstance, a bone graft is used to cause a solid union and I am fearful of the long-term consequences of rigid union promoted in so young a child.



## DELAIRE

The university town of Nantes, at the mouth of the Loire River in Brittany, is the site of Tessier's medical school and the home of Jacques Delaire, a fine cleft surgeon. I had heard he was probably the foremost surgeon in France doing primary bone grafting in clefts and wrote to ask his present stand. This is his 1977 response, along with several of his cases showing results three and one-half years after cheilorhinoplasty and primary bone grafting (two stages in bilateral cleft):

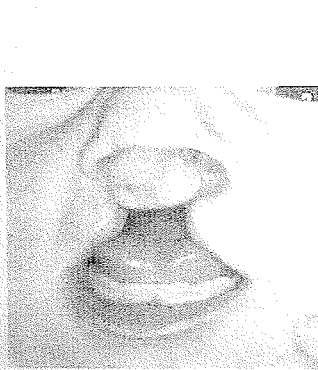
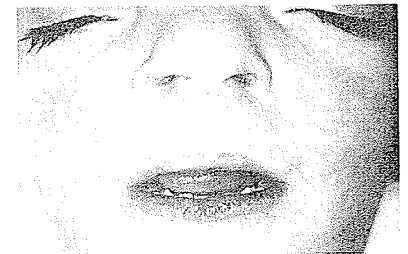
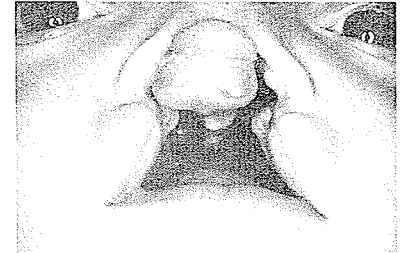*Jacques Delaire*

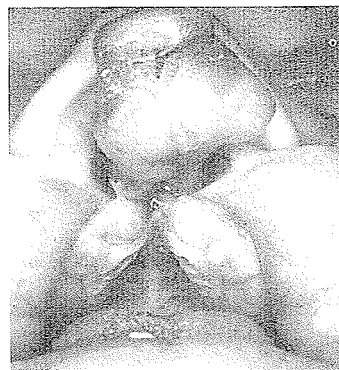
1. I have not done any bone grafts since October 1975 (even though I continue to think that in certain cases they improve the quality of results of my operations), for the following reasons:

—From 1969 to 1975, I adopted your technique of cheiloplasty associating it with a vertical bone graft (in front of the ascending surface of the maxilla), a more extensive subperiosteal dissection, and a primary rhinoplasty.

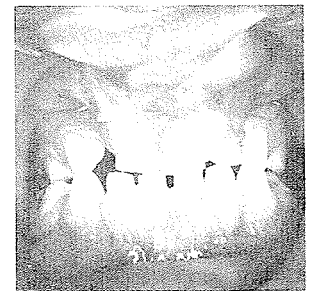—Since that time, I have used a similar technique without a bone graft, with a more extensive reconstitution of the transverse muscles, elevators of the nose and upper lip. The results thus obtained, without grafts, are about the same as those I was obtaining two years ago.



No cleft of the palate



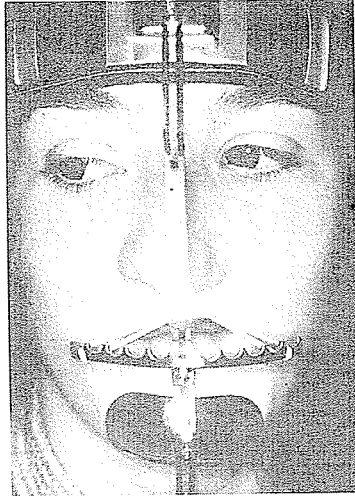
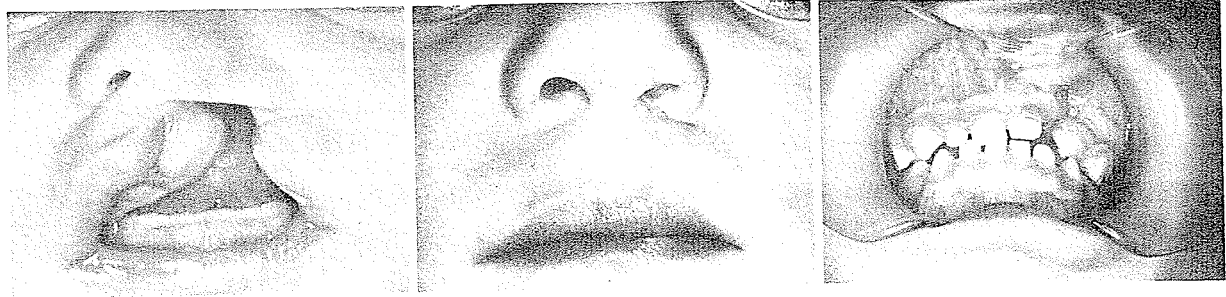Bone graft in two stages



2. My oldest cases of bone grafts in cleft lip are sixteen (16) years old.

3. Altogether, the results that I have obtained with these grafts seem to be better than those where a graft had not been used. The preparation of the bed of the graft accompanied from the beginning by a greater periosteal liberation creating a vertical periosteal sac in front of the ascending maxilla, along with careful reconstitution of the floor of the nostril, may be responsible for some of the improvement.

4. There have been no systematic cephalometric studies, but these patients have been studied by the orthodontists on my service and have been



treated the moment any problem of occlusion manifested itself. In addition, I have developed a method of posterior-anterior extraoral traction using an orthodontic mask (1972) which prevents certain types of maxillary retrognathia.

5. The primary graft has seemed to me to diminish the vertical and transverse problems of occlusion: cross bite, open bite, and deep bite.

#### ALL THAT GLITTERS IS NOT GOLD

It would seem that to follow the principle of "replace missing tissue with similar tissue in kind—bone for bone, etc.," early bone grafting of alveolar and hard palate clefts would be indicated. As it has turned out, the answer may not be so simple, and, after a discussion of donor bone, the arguments against early bone grafting will be presented.