

## 16. Presurgical Maxillary Orthopedics

As explained by Clodius in 1964:


Maxillary orthopedics, . . . in contrast to orthodontics, are essentially the movement of basal bone, its alveolar process and the dental units contained within. If the teeth have erupted, they serve merely to enhance anchorage for orthopedic movement.

In 1772 Levet of Paris was the first to appreciate the orthodontic significance of additional extraoral force. He employed a linen band, not only to protect the suture line but also to align the maxillary arch.

In 1790 Desault, likewise of Paris and often considered the father of presurgical maxillary orthopedics, using a linen band tied tightly over the projecting premaxilla and around the neck in a "dental arcade," preoperatively reduced a 12 mm. protruding premaxilla in a 5-year-old girl, bringing the prolabium on a level with the lateral lip elements.

Eight years after the publication of Desault's collected works, Lefoulon in Paris expanded the maxillary arch of a young English professional singer with an anterior lingual spring. He introduced the term *dental orthopedics*—this part of the dental art being necessary to cure congenital and acquired deformities of the teeth and their arches.

In 1892 Friedrich von Esmarch designed an elastic band attached to a headcap. Its purpose was to keep the premaxillary segment in place after it was repositioned by vomerine section. As Clodius points out, the von Esmarch design is widely used by many modern surgeons throughout the world, including himself,



Friedrich von Esmarch

but as a presurgical orthopedic maneuver to avoid vomer sectioning.



*Kerr McNeil*

### McNEIL

The concept of early orthodontic treatment in alveolar clefts was introduced by C. Kerr McNeil of the University of Glasgow in 1950. There were two facets to his original concept:

1. The diminution in width of the palatal cleft brought about by the stimulation to growth of the palatal shelves under the influence of an oral appliance designed to promote such growth.
2. The control and correction of the displaced maxillary segments seen in clefts of the lip, alveolus and palate prior to surgery, thus assisting the surgeon by presenting him with a more normal bony facial skeleton over which he could perform his repair of the soft tissues.

McNeil advised cutting the model of the upper arch in an antero-posterior direction and shifting the two sections to partially correct the deformity. He then made an appliance to fit the corrected model, which the baby wore until need for a new appliance developed every few weeks. Outriggers on the appliance were attached to a cloth headcap. The plate was retained until after the palate repair. Elastic pressure was used against the projecting premaxilla.

Thus McNeil, the Scotsman, had started a movement of early orthodontic manipulation which was destined to be adopted in units around the world. The concept caused thought, trial and frustration, leading eventually to modifications to fit the facilities available in the specific areas.



*William Burston*

### BURSTON

In 1955, in response to a request by the plastic surgeons of Liverpool, William R. Burston of the School of Dentistry, University of Liverpool, undertook a pilot study of the McNeil approach. By 1958 the method had been adopted as a routine. In 1965, after 10 years of experience, Burston wrote:

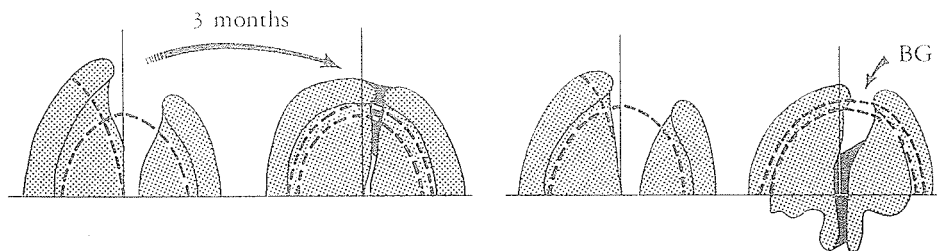
Whenever and whatever orthodontic treatment be given to a case of cleft lip and palate, it is the surgeon who will mainly determine the eventual

result. . . . Early orthodontic treatment of the infant makes its contribution by helping the surgeon to achieve a good primary repair of the lip over a symmetrical and well balanced facial skeleton. If this can be achieved, later orthodontic treatment becomes much more practicable.

In the same year, Burston outlined the method originally advocated by McNeil and being used by himself:

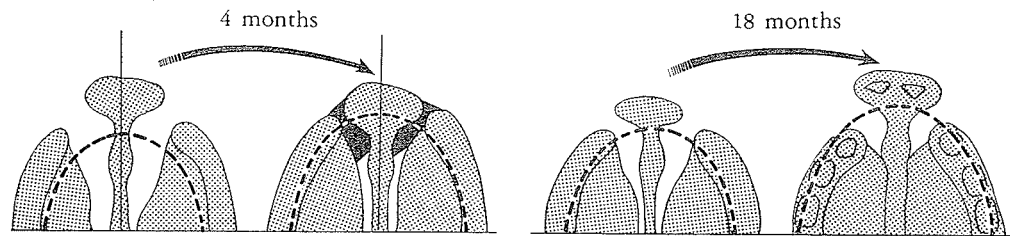
A feeding plate is inserted as soon as possible after birth, preferably before the infant has its first feed; this is a simple plate without bite blocks and can be provided within a few hours of taking the first impression. . . . When early orthodontic correction is judged necessary, a correction plate is fitted which incorporates bite blocks. The bite registration is a very important step in the technique because much of the action of the plate is derived from the child chewing into the plate. The blocks must be high enough to gag the bite and produce reflex chewing. The height is correct when there is a forward pressure on the plate (as shown by the blanching of the mucosa seen through the clear acrylic) during the biting and yet the plate is not dislodged. The time to change or alter the plate is reached when a uniform blanching occurs on chewing. Extra-oral strapping is employed to assist the action of the plate. . . .

The usual pattern in a thriving infant is that most of the improvement occurs within four months and that only in exceptional circumstances is further delay in lip repair justified.



In unilateral cases, provided good arch alignment has been obtained, the anterior palate is closed at lip operation. If, however, there is a significant gap between the alveolar segments, lip repair only is undertaken and an attempt made to improve the defect before the palate operation. Should this attempt fail, the soft palate and posterior half of the hard palate only is repaired and the residual defect closed by a bone graft inserted at age 3-4 years.

In bilateral cases, experience suggests that it is wise to close the anterior palate in most instances, even where orthodontic treatment has been only partially successful.

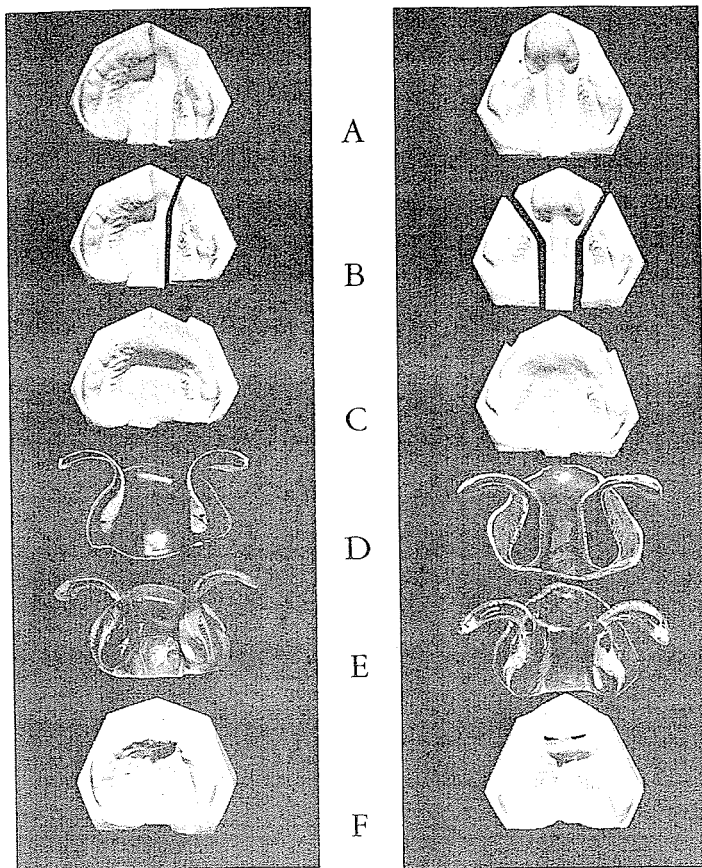


Burston warns that, following lip closure, most children should continue to wear a plate until the time of palate closure, with benefit to arch alignment, to feeding and to possible reduction in the width of the cleft. In a bilateral condition, if the anterior clefts are open without a plate, there is a real risk that the premaxilla will grow forward out of alignment, as shown here after an 18-month period. Explained Burston:

Early bone grafting has not been practiced in Liverpool because of the dangers of fixing the segments in an arbitrary and possibly unfavourable position.

By 1971 Bill Burston, a tireless, dedicated worker, consultant orthodontist and honorary lecturer in child health, had set up two baby cleft units, one at Alder Hey Children's Hospital and the other at Heswall Children's Hospital, the whole setup consisting of cots for 23 babies, plus accommodations for four mothers who may wish to be in with the babies. In 1977 he reviewed the principles of presurgical orthodontic correction of the maxillary bones in total clefts.

1. The deformation of the maxillary and premaxillary bones is brought about by separation of one or both sides of the maxilla from the nasal septum. In the unilateral case, there will be deviation of the midline to the non-affected side; in the bilateral condition the premaxilla remains on the vertical tip of the septum; i.e., the patient has a snout like any other animal. The nose of man is unique.
2. The facial sutures are open and active in the neonate and are thus capable of responding to the force applied to the bones. Growth of the face is very rapid in the first few months of post-natal life.
3. Force may be applied by fitting a plate which has been deliberately "corrected" and which also gags the bite slightly to promote chewing activity. Models are presented to chart the progress in a unilateral and a bilateral case. A. Plaster cast of the maxillary arch at birth. B. Corrected cast. C. Corrected cast with plaster added to relieve pressure on



growing margin of bones. D. Wax preform of plate to determine vertical height of bite blocks so as to gag the bite. E. Finished plate. F. Cast of corrected arch. This action may be reinforced by extra-oral pressure via an elastic strap with a pressure pad, the strapping being applied to a base of micropore tape stuck on the face.

4. The plate obturates the palate defect and this assists feeding. By denying the tongue access to the cleft, the latter closes down markedly, thus helping palate repair. The treatment involves fitting a succession of plates, taking about four plates for full correction of the segments.



This aid to surgery has a natural appeal to surgeons. In 1962 G. Crikelair, A. Bom, J. Luban and M. Moss of Columbia University, New York, reported six patients with complete unilateral cleft of the lip and palate treated by a modification of the McNeil principle, an acrylic intraoral appliance being used prior to surgery. They noted:

The opening in the hard palate decreases to a great degree spontaneously and in one patient disappeared completely.

## THE STAND OF THE SURGEON ON HAND



David Maisels

David O. Maisels, consultant in plastic surgery in Liverpool, with Burston as his adroit orthodontic arm, can afford to be slightly prejudiced. When evaluating a temporary lip adhesion as a method of molding the arch, he commented:

It would seem preferable to achieve the same objective by non-surgical means. . . . Indeed, one might say the sheet anchor of this pre-surgical orthodontic treatment is that by starting it within forty-eight hours of birth, full advantage is taken of the postnatal growth spurt.


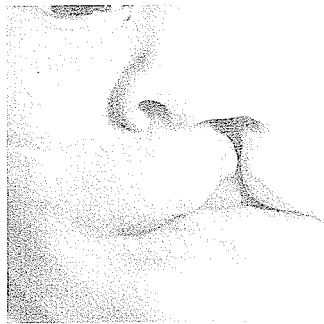

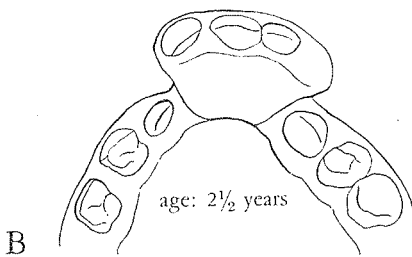
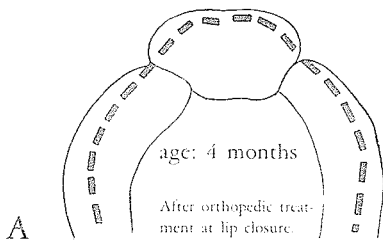
His answer to the fact that 30 percent of cases may never need orthodontia was:

It will not be obvious at first sight which do not need it, but it will do no harm and as soon as relationships are seen to be satisfactory, lip surgery is indicated.

As pointed out by Maisels, some cases respond to orthodontics better than others and by 3 to 4 months are ready for surgery. Some do not respond favorably and at 6 months are still not correct. In these patients the lip is closed, the anterior palate left open. Reexpansion of the arch at 5 years is stabilized with a bone graft.

In bilateral clefts, sufficient alignment has been achieved at 3 to 4 months to allow lip and anterior palate closure (A). Maisels warns that closing the lip but failing to close the anterior palate may not restrain the central stem (B).

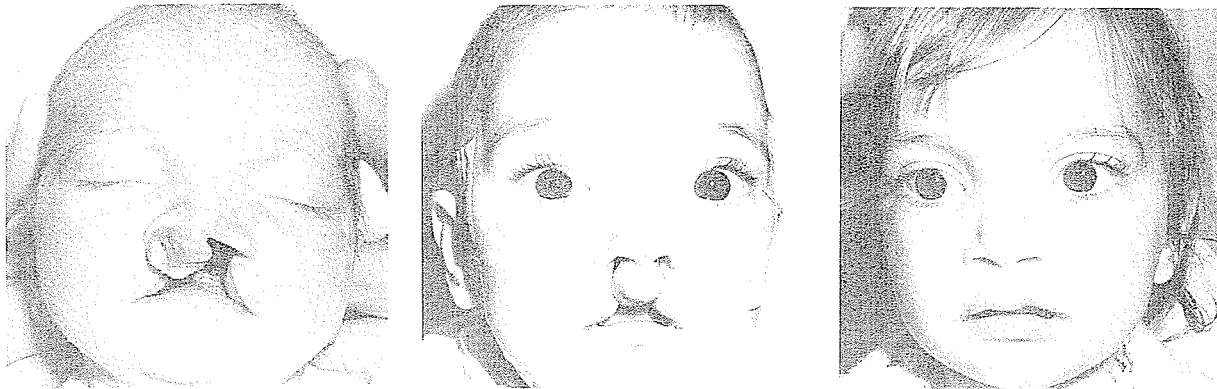In a small group, presurgical orthodontics fails to control protrusion of the premaxilla, and surgical retropositioning becomes necessary. In Liverpool, this group constitutes 6 out of 76 bilateral cases.



In 1974, in the *British Journal of Orthodontics*, Maisels, from his enviable position of having had excellent presurgical orthodontics available for years, verbalized with clarity what most surgeons feel:

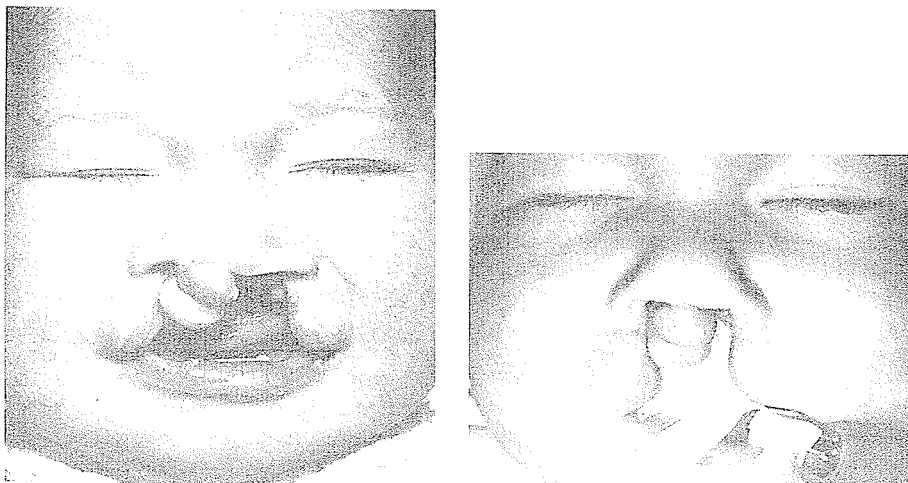
It is axiomatic that for any one surgeon, the easier the operation, the better will be the final result.

Here are two of Maisels' cases, a unilateral and a bilateral cleft lip and palate, presented to emphasize the value to the surgeon and the patient of presurgical orthodontics.



Maisels stated:

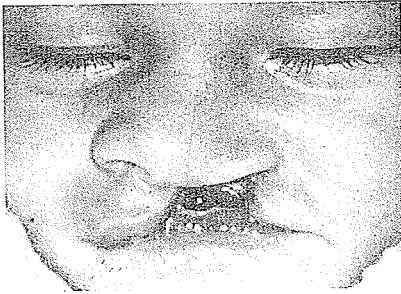Few would disagree that the technical difficulties of repairing this cleft have been greatly simplified in two ways. In the first place, the actual cleft is considerably narrower and the nasal deformity reduced following treatment, but what is perhaps just as important is the reduction in the degree of distortion. . . . In order to achieve closure of a very wide cleft lip, considerable dissection is required to free the soft tissue from the maxilla. Opinions differ as to whether this is best done superficial or deep to the periosteum lest the subsequent growth of the maxilla be jeopardized. This



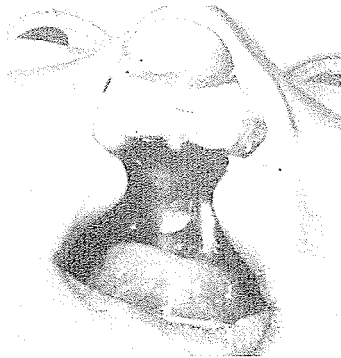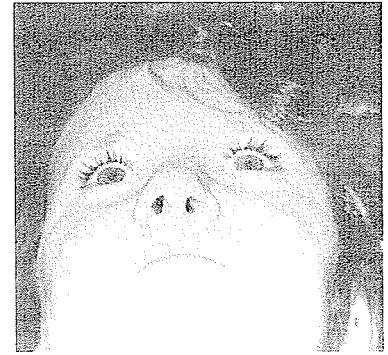*Important* →

difference of opinion is perhaps an indication that neither technique, if performed with care and precision, will have an adverse effect. However . . . there is no doubt that the pre-treated cleft will require less freeing of the tissue to close the lip without tension.

Whenever possible, the lip repair is combined with repair of the anterior palate although there have been instances when the orthodontist has requested the omission of this stage. . . . This practice is becoming less common as we move to the view that any post-operative correction is probably better carried out later by rapid expansion and bone grafting (Matthews and Grossman, 1964).



Here is another example of a unilateral case treated by Burston with presurgical orthopedics, which eased the strain on Maisels when he carried out the rotation-advancement lip and nose correction.

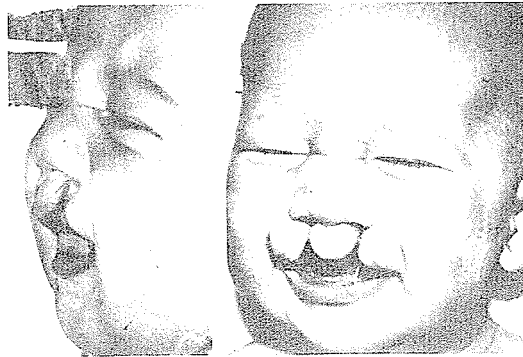


Maisels cautions that it is necessary to give the orthodontist time to prepare the patient:

In practice, we have found in Liverpool that the average case is repaired at 6 months although [this] shows a baby with a fairly severe bilateral deformity who was ready for operation at 3 months. In bilateral cases both sides are repaired at the one operation.



At birth

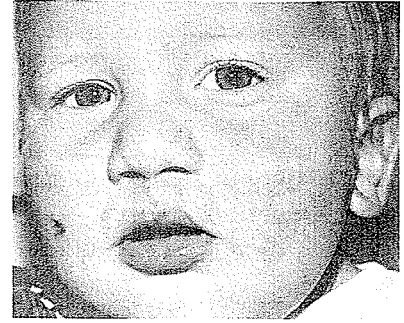

3 months later





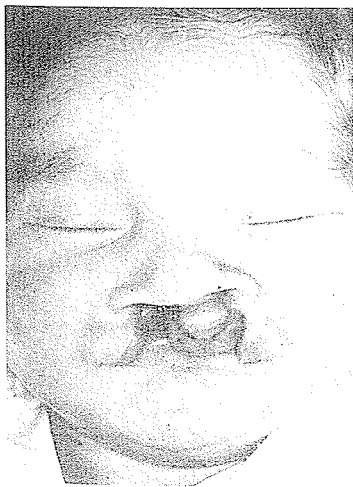Such orthodontia is like manna from heaven to a surgeon sitting down to close a severe bilateral cleft lip. Yet heaven does not rain "manna" equally upon all surgeons. Presurgical orthodontics certainly facilitated the first-stage lip closure of this bilateral cleft. Maisels elaborated:



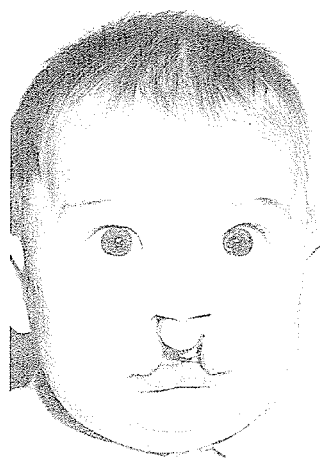Probably the greatest influence of presurgical treatment has been the elimination of the need for excision or recession of the protruding premaxilla in severe bilateral clefts (Browne, 1949; Cronin, 1957; Monroe, 1965). Not only is it possible to correct the forward protrusion and upward rotation of the premaxilla . . . but also any lateral rotational deformity can be adjusted. . . .

I now carry out a simple repair of both lip clefts and anterior palates at the primary operation, preserving virtually all the soft tissue in the lip. Then when the baby is 2 to 3 years of age, the columella is lengthened by a forked flap, as described by Millard (1958).

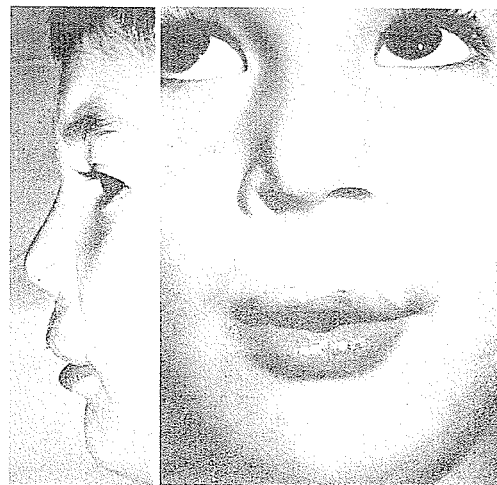
Here are two examples of the Burston presurgical orthopedics followed by one-stage lip closure and later forked flap by Maisels, sent to me in 1976. At this time Maisels wrote me that Burston had suffered a most frightful burn but was back at work with his nose and forehead reconstructed by flaps and his left eye blanked out by a deltopectoral flap. Despite this handicap he gets along well, not only with the children, but with the parents, because, of course, "it is still the same old Bill underneath."



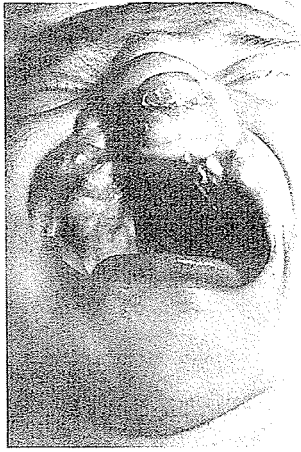Birth



Orthodontia



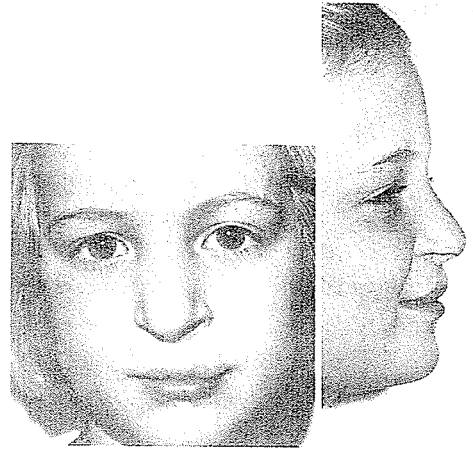Forked flap



Birth

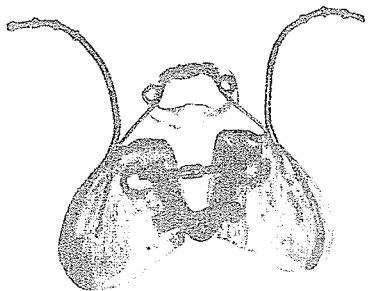
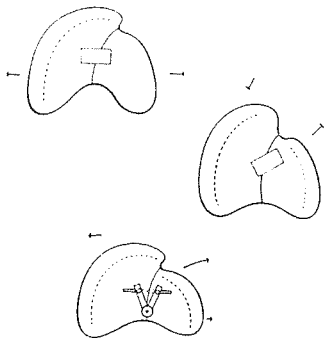
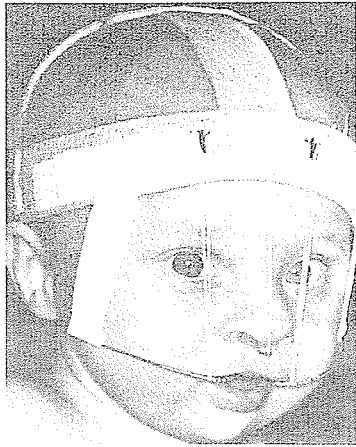

Orthodontia and lip closure



Forked flap

### JOHANSON'S ADVANTAGE



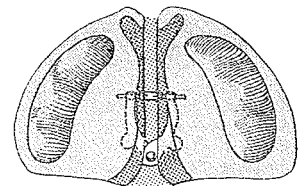
It is likely that most cleft surgeons would welcome presurgical orthopedics if it were available. As early as 1956 in Stockholm, Bengt Johanson was receiving this benefit. K.-E. Nordin was achieving arch alignment with a plate provided with a coffin spring and a little screen resting on a premaxilla and exerting pressure in a backward direction when expansion was in progress. This work was used in preparation for Bengt Johanson's early primary bone grafting. Later, in 1964, orthodontists Åke Ohlsson and Anna Kling reported the orthopedic method used in Göteborg, Sweden, in cooperation with surgery by B. Johanson. At age 1 to 2 months the nasal floor was closed, and 10 days later a plate was inserted. The plate was provided with facial arms for fixation with tape. In unilateral cases with contraction, a screw plate was used and the position of the screw varied according to the deformity and the effect desired.

In bilateral cases, expansion treatment again began 10 days after closure of the nasal floors. The divided screw plate with facial arms and anterior cup for the premaxilla was used from age 2 months until 7 to 8 months, when alignment should be completed. Then Johanson carried out his primary bone grafting. A retention appliance was maintained until after closure of the posterior palate at age 1½ years since a certain degree of collapse followed this procedure.

## GEORGIAD E

At the 1964 Hamburg Cleft Palate Congress, Nicholas Georgiade of Duke University, both dentist and surgeon, noted that since the middle of 1962 he had been using a modification of the expansion screw plate described by Ohlsson and Kling. He explained:


Horizontal expansion can be obtained utilizing parallel expansion devices also incorporated in the acrylic denture, as described, utilizing a split firm acrylic plate with a soft spongy acrylic over the prosthesis as in the solid prosthetic appliance. . . . Following bone grafting of the alveolar cleft area the prosthesis is maintained in position with removal and refitting every few weeks for approximately 2 months.



## GRUBER

Colonel Haskell Gruber of the U.S. Air Force is in favor of maxillary orthodontics in cleft palate therapy. In 1966, while at Lackland Air Force Base, Texas, he noted:

At present, over 100 children with cleft lip and cleft palate, ranging in age from 2 weeks to 13 years, are undergoing active orthopedic or orthodontic treatment. Another group of 68 patients has had primary or secondary bone grafting procedures. . . . A record is kept for long-term and longitudinal growth studies. . . . Complacency, as well as the acceptance and use of older techniques only, no matter how true and tried, should not be tolerated without their continuous re-evaluation.



*Haskell Gruber*

In 1975, at the American Cleft Palate Association meeting in New Orleans, Gruber reported:

With the preponderance of craniofacial growth taking place in the early post-natal months and years . . . it became all the more imperative to achieve normal orofacial growth environment very early in the infant's life. This is accomplished by either repositioning the collapsed maxillary arch segments, or maintaining their normal position and permitting the tension of the repaired perioral musculature to mold them.

The employment of maxillary orthopedics both passive and active accomplishes the following:

1. restoration of a normal maxillary arch contour and maxillomandibular spatial relationships;

2. increase in volume of the oral cavity with better tongue position, improved respiration and speech;
3. more normal skeletal base for cheiloplasty with concomitant ease of surgical repair with less tissue undermining and subsequent tissue tension;
4. decrease in incidence of later arch collapse and cross-bite malocclusion;
5. apparent reduction in posterior cleft width;
6. better infant feeding habits and early parental involvement with habilitation of their child.

In the early restoration of normal form, function and physiology in the orofacial region, a more nearly normal growth environment is achieved for the tongue, the buccinator mechanism and the orbicularis oris.

#### MANCHESTER AND PEAT

Another surgeon who has the benefit of presurgical orthopedics is William M. Manchester of Middlemore Hospital, Auckland, New Zealand. In fact, because of this manipulation of segments prior to surgery, he dares more radical cleft closure than most. As early as 1965, and in the 1971 Melbourne International Congress, he reported having achieved a rather extensive closure of the alveolar and hard palate cleft at the time of his lip closure with the aid of orthodontist J. H. Peat, who presents him with premaxillary and maxillary segments in reasonable alignment. A plate divided in two half shelves overlapped and connected by a wire spring maintains an effective roof to the mouth during lateral expansion, preventing the tongue from pushing on the back of the premaxilla. The projecting premaxilla is restrained by simple elastic traction. At 5 months, alveolar, hard palate and lip clefts are closed, and at 9 months a V-Y palate pushback using Cronin's nasal slide is accomplished. His 1970 comment on follow-up and final treatment is self-explanatory:

Regular attendance at the follow-up clinic continues until about the age of 16 years. Should it be needed, when the appropriate time comes orthopedic over-expansion of the arch is undertaken and secondary bone grafting is carried out. The missing teeth are supplied by means of the chrome-cobalt skeleton denture which also acts as a retention device. At about the age of 15, a complete rhinoplasty, including elongation of the columella, is done.

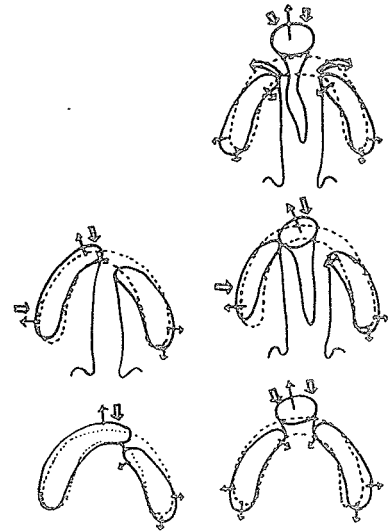
## WOOLHOUSE

Yet another surgeon enjoying an orthopedic adjunct is Fred M. Woolhouse of Montreal. He wrote me in 1972:

We exploit the McNeil-Burston type of neonatal orthodontia by having our orthodontist insert the appliance usually before the baby's *first feeding*, i.e., within 12 hours of birth (we have a very compulsive orthodontist and very cooperative paediatricians). Consequently we usually (but not always) repair the lip over a symmetrical arch. The cases from outside the metropolitan area form a good control series since they do not get the benefit of this therapy.

## SASAKI

In 1972 Motomasa Sasaki of the Sapporo Medical College, in the *Japanese Journal of Oral Surgery*, presented his use of the McNeil-Burston dental appliance with extending phalanges and attached head and cheek bandages to fix the apparatus in position. He also showed diagrams of what this appliance was designed to do in the various cleft deformities.



## O'DONNELL

In 1974 J. O'Donnell, J. Krischer and F. Shiere of Tufts University, Boston, following McNeil's principle of presurgical orthopedics in unilateral cleft lip and palate, concluded:

1. Unilateral cleft lip and palate patients who have been treated with presurgical orthopedics demonstrate lower incidences of arch collapse and crossbite malocclusion than those treated by surgery alone.
2. A program of presurgical orthopedics results in a reduction of posterior cleft width throughout the course of treatment.
3. The greatest amount of reduction (28.5%) occurs during the period prior to lip repair and the total amount of reduction (45.4%) exceeds that of previous reports of patients who received purely surgical treatment.

In 1977 N. Robertson, W. Shaw and C. Volp of the Orthodontic Department of the Welsh National School of Medicine, Cardiff, used serial cephalometric analysis (with the aid of metallic implants) and an analysis of the models of 10 children with

complete bilateral clefts to study the effects of presurgical orthopedic treatment. They noted:

Successful orthopedic treatment reduced the premaxillary protrusion and the width of the alveolar cleft prior to the surgical repair. . . . The changes were brought about by two complementary effects:

(1) Further forward growth of the already forward premaxilla was restrained by the extraoral strapping which we applied with tension across the prolabium.

(2) Forward growth of the remainder of the midface (including the lateral segments) continued, thus "catching up" with the premaxillary element.

If the premaxilla is effectively restrained, the time required for alignment to occur will depend on the rate at which the lateral segments "catch up" as the face grows forward. In our cases this would appear (on the average) to be just under 5 mm. during the first 3 months of life.


. . . Because successful treatment partly depends on normal forward growth of the face, we believe therapy *should be commenced within the first days of life* when the growth rate is maximal—and it should be completed by 3 months, to comply with the traditional surgical program. . . .

Our other observations include the accentuation of the columella during treatment, but an absence of growth at the cleft margins.

Orthopedic treatment which fails to achieve the desired aims in 12 weeks of active therapy should be discontinued then in favor of such surgical setback as may be necessary to allow a satisfactory lip repair.

## PINNING THE PALATE

It is not practical in most areas of the world to hospitalize cleft infants for orthodontic care over long periods as in Burston's unit in Liverpool. Robert Hagerty therefore called upon Willis K. Mylin, orthodontist and anatomist of the Medical College of South Carolina, to help him ensure the maintenance of a maxillary prosthesis with an expansion screw which would require minimal home care. Mylin, who understands construction, having just completed building his large and beautiful house with only the aid of a few subcontractors, turned his attention to this problem and with Hagerty developed the method of pinning the screw plate to the maxilla and sealing off the pins. If fitted and pinned in the early days of life, the expansion plate can be



Willis Mylin

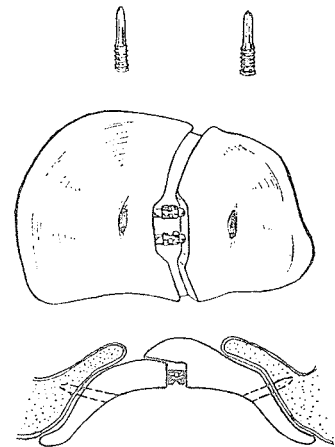
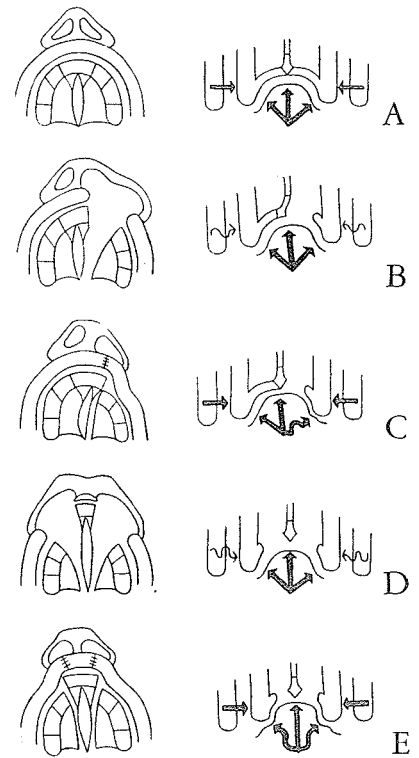
maintained with relative ease and can have a great influence in positioning the maxillary elements. Mylin is content to leave the apparatus at work for two to six years if indicated.

Robert Hagerty, W. Mylin and D. Hess, in the 1965 *Journal of the South Carolina Medical Association*, described their pin-retained expandable acrylic prosthesis. They defended the need for the appliance in cleft palate when the normal "buttresses" are deficient and presented their case with graphic diagrams of (A) the normal, with equilibrium between the intraoral and extraoral forces, (B) unoperated unilateral complete cleft, with greater intraoral forces displacing the maxillary segment, (C) operated complete unilateral cleft, with greater extraoral force at work, (D) unoperated bilateral complete cleft, with intraoral forces greater, and finally (E) operated complete bilateral cleft, with superior extraoral forces displacing the maxillary segments.

They concluded that their

pin-retained expandable prosthesis is most versatile. . . . The advantages of this prosthesis may be listed as follows:

1. Rapid positioning of the maxillary segments.
2. Mechanical closure of the cleft, permitting more facility in taking nourishment and decreasing the amount of food entering the nasal cavity and nasopharynx.
3. Mechanical closure of the cleft, permitting anterior tongue thrust which balances the compressive forces of the lip musculature and also stimulates growth.
4. Mechanical closure of the cleft, permitting anterior tongue tip exploration to stimulate the early development of articulated speech.
5. The pushing compression effect of the tongue on the appliance, stimulating growth at the cleft margins and therefore reducing the size of the cleft.
6. A more normal facial contour resulting from more anatomical positioning of the maxillary segments and vomer.
7. A reduction in responsibility on the part of both patient and parents for the insertion and use of the device.
8. Constant maintenance of the prosthesis in the desired position, eliminating displacement into a non-functional position.
9. Reduction of the nasal quality of the speech.
10. Elimination of parental anxiety associated with external retention and fixation devices, insertions and maintenance of bite plates, feeding difficulties and general appearance of the child.



In 1976 Hagerty informed me that since 1965 he has been closing the velum at 6 months with transverse incisions along the posterior edge of the hard palate, dividing the muscle attachments but preserving the vessels and advancing the soft palate elements medially and posteriorly for union. The screw plate is then inserted, pinned into its position and maintained for six years, at which time the hard palate cleft is closed with the aid of mucoperiosteal flaps when necessary.

In the cleft palate clinic held every other Saturday morning in Charleston's St. Francis Hospital annex, Hagerty and Mylin, with a speech pathologist, an audiologist, a geneticist and invited orthodontists, meet to see 25 to 30 patients. The children with pinned screw plates are seen every six months for minor maintenance, since the prosthesis can become dislodged during an intensive bout with chewing gum.

In 1977 R. J. Jorgenson, S. D. Shapiro and C. F. Salinas of the Medical College of South Carolina, Charleston, reported on delayed closure in 75 of 180 patients treated with a pin-retained prosthesis prior to surgery:

The results of this study indicate that delayed surgery is related to less interference with palatal growth than early surgery and that the pin-retained prosthesis is a useful adjunct in the delayed surgery.

#### PRUZANSKY'S DISSENT

There has not, however, been universal acceptance of presurgical orthodontics. Orthodontist Samuel Pruzansky of the Illinois Research and Educational Hospitals, Chicago, in 1964 wrote a strong dissent against presurgical orthodontics. He noted that, just as

fads of fickle fashion fade and flow,

maxillary constricting wires are *out*, but with no more justification, in his opinion, jackscrews and spring plates are *in*! He pointed to the role of musculature in the growth of the maxilla and remarked that maxillary collapse was fully, quickly and economically correctable in the deciduous, mixed or permanent dentition.



## STELLMACH

Stellmach of Düsseldorf stated in 1964:

We have used early orthodontic treatment of complete clefts since 1954 according to the McNeil technique, but only in a few cases have we used this before lip repair. The procedure is time consuming if not begun within the first weeks of life. . . . Orthodontic treatment, when commenced after lip repair, is aimed at preventing unfavorable approximation of the segments. The plate acts to direct and guide the segments moved by the lip muscle forces into a butt-joint contact. This is obtained within 2-3 months, usually with one correction of the plate. Even outward shifting of the segments can be achieved postoperatively by using several adjustments of the plate or a screw on it.

## HUDDART

Huddart, North and Davis of Wolverhampton, England, studied treated and untreated cases in 1966 and found no apparent difference in the two groups of children in later years. Huddart added an extra thought in 1969:

If I have a severe protrusive premaxilla, I honestly think pre-surgical treatment is a waste of time if it is started when the child is more than 14 days old. I refer it to the plastic surgeon as quickly as possible. . . . The child benefits more by an early lip closure.

## GLASS

Sussex orthodontist Denis Glass of the Plastic Reconstruction Centre, East Grinstead, made similar findings. In fact, he reported his opinion about presurgical orthopedics in 1970:

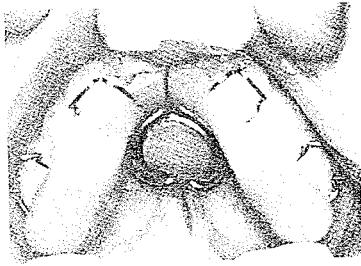
1. It does not stimulate maxillary growth;
2. It does not produce "clinical or bony union" of the segments;
3. It delays the time of lip closure until the child is 9 to 12 months old;
4. It draws attention to the child's deformity at home;
5. It provides added burdens of travel and absence from home to the neglect of the rest of the family;
6. It involves the orthodontist and technicians in work of doubtful value. . . .



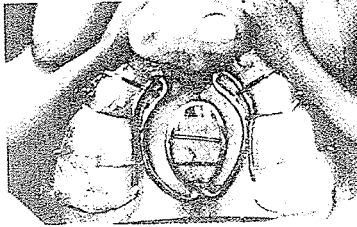
*Denis Glass*



CC spring appliance



Before activation



Maxillary expansion completed in 3 to 4 months

As orthodontist, I am responsible for the final alignment of the bony segments of the maxilla and to join these segments by bone before uniting the soft tissues of the face and before restoring the muscle function of cheeks and lips is, in my opinion, of doubtful value.

Glass concluded:

The successful management of bilateral cleft depends on:

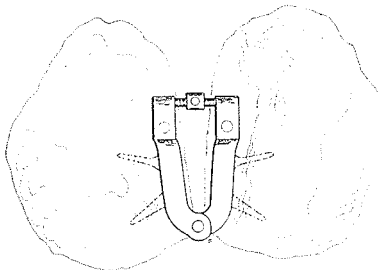
1. A careful study of the soft tissue behavior associated with the cleft.
2. Early lip and palatal surgery by a competent plastic surgeon.
3. Rapid dental orthopaedic correction of the three maxillary segments at 4 to 6 years.
4. A course of treatment as short and intense as possible followed by long periods of rest.

Glass had a rather violent youth. While at the University of London, he earned his colors for rugby and athletics, winning the hammer-throwing championship for the Combined Universities of the British Isles. During the war he was in three assault landings in a field ambulance with the infantry fighting from Sicily to Rome. He has indeed earned the good life and now enjoys gardening, hunting, fishing and painting when he is not working on the facially deformed.

## SKOOG

In reference to maxillary orthopedics, Skoog stated in 1974:

This tedious process involves using cumbersome headgear and various other apparatus in attempts to bend the premaxilla towards the separated lateral segment. The unnatural pressure placed on the premaxilla is both harmful and unnecessary. The best way of producing alignment is to repair the lip. . . . An exception to this practice is made when the original malformation presents with collapse of the lateral segment. Expansion of the maxillary arch to a suitable position is then recommended.



His orthodontist, Hellquist (1971) used a pair of acrylic plates which act through a fan expansion screw. Lateral rotation of the lateral segments widens the cleft anteriorly.

## HARDING AND MAZAHERI

Harding and Mazaheri of Lancaster warned in 1972:

Because the spatial relationships of the maxillary segments spontaneously tend to improve, we have become more selective about using expansion or holding prostheses for their management. These prostheses are possibly essential in those in whom there are plans for alveolar operations. . . . Many of the prostheses being used are designed to correct deficiencies in width and this is not a major problem in early infancy—particularly in patients with bilateral cleft lips and palates.

In 1975 M. Mazaheri, at the H. K. Cooper Institute for Oral-Facial Anomalies and Lancaster Cleft Palate Clinic, continued to endorse the standard lip closure at 10 pounds and two-stage palatal closure at 1 to 1½ years, usually without surgery to the area of the alveolar cleft. This was followed by orthodontic treatment during deciduous and permanent dentition if needed, the expansion of the collapsed arch being simple and without irritation. On the basis of a study of 125 complete unilateral cleft lip and palate patients from birth to 9 years under their standard treatment, he and his colleagues reported:

To date, there has not been data of a similar nature published to reveal a more satisfactory oral-facial growth, arch, dental and occlusal developments. Our investigations have shown that it is not necessary to treat the arch in early infancy with a holding or an expansion appliance, since it appears that the arch and the segmental relationship will undergo favorable change with growth and with eruption of the deciduous dentition, provided that growth is not retarded by surgical intervention and scar tissue. . . . The orthodontic cost for correcting a unilateral cross-bite during deciduous dentition is approximately \$400 to \$500. Primary bone grafting and orthopedic therapy might run into the thousands.

Orthodontist William H. Olin of the University of Iowa, who collects antique music boxes, in the early 1960's became interested in the reports on presurgical orthopedics from Germany, Scandinavia and England. In 1978 he recalled:

I spent 6 weeks travelling in Europe observing the different techniques being used and returned to this country quite excited about experimenting.

After several years of using these techniques and comparing the results of patients that had not had presurgical orthopaedics, my conclusions were that



*William Olin*

this procedure was not indicated in most cases of cleft lip and palate.

I feel that facial growth is best influenced by simple lip repair at approximately 3 months of age, or a two stage procedure if the cleft is bilateral, one side at 3 months and the other side at 6 months with little or no undermining. I also seem to favor palate surgery after the primary dentition is fully erupted, which would be 2.5 to 3.5 years of age.

Occasionally we do have some severe clefts which are very difficult to close surgically and our surgeon sometimes requests that we help him in reducing the size of the cleft. In these cases we cooperate and attempt to reduce the protrusion of the premaxilla or to close the cleft in the alveolar ridge so the surgeon will be able to complete a satisfactory lip repair. This is the only reason why I feel presurgical orthopaedics is necessary.

## H O T Z

In 1976, in the *American Journal of Orthodontics*, Margaret Hotz and W. Gnoinski of Zurich University Dental Institute took a provocative stand. M. Perko was their plastic surgeon.

The controversy for or against early orthopedic treatment of cleft lip and palate patients still continues. American authors especially [Aduss and Pruzansky] "vigorously" deny its usefulness and are trying to prove that their cases, results of "conservative surgery only," provide a yardstick against early orthopedics.

Unfortunately, they generally refer to it in connection with primary bone grafting, the effects of which procedure must be considered separately. Some recent publications advocating early orthopedics [Huddart; Maisels; O'Donnell and Robertson] state that it has definite advantages as concerns both growth and development and primary surgery.

Hotz and Gnoinski outlined their comprehensive care developed since 1957, with changes to 1965:

In order to normalize feeding, a plate of compound soft and hard acrylic resin is made as soon as possible, usually within 24 to 48 hours after birth. . . . The plate . . . carefully adjusted . . . is held by suction and adhesion only. . . . The hard acrylic layer provides stabilization of segments in both the transverse and anteroposterior dimensions. The soft parts adapt themselves to the underlying structures, gradually giving way to the increase of the transverse maxillary dimensions. . . . Handling of the plate decisively influences the effects of early orthopedics. . . . Arch alignment is induced by grinding away material in definite areas: in unilateral cases, on the butt ends of both segments. . . . The margins of the palatal shelves are relieved

margaret's  
glove across  
Sam's face.

medially and vertically. . . . In bilateral cases the butt ends of both lateral segments are relieved by grinding in an anterolateral direction. The margins of the palatal shelves are relieved medially and vertically. The premaxilla is supported posteriorly. . . . No active retrusion of the premaxilla is carried out. . . . Expansion is often necessary in bilateral cases lacking space either for alignment of a large premaxilla, and/or proper accommodation of the fast-developing mandible. . . . For surgical closure of the lip in unilateral clefts, we consider 5 to 6 months as being the optimal time. . . . The alveolar cleft has considerably narrowed by this time as a consequence of guided and undisturbed maxillary growth. The alar base is carried forward and supported by the lesser segment. . . . Current z-plasties are used for closure, mainly Millard and Tennison techniques. . . . The plate is reinserted immediately after the intervention. It lessens the pressure of the united orbicularis oris muscle on the butt ends of the maxillary segments. . . . For lip closure in bilateral clefts, the Celesnik approach in two stages has proved

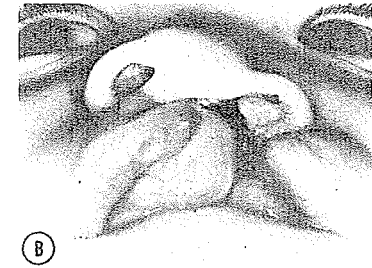
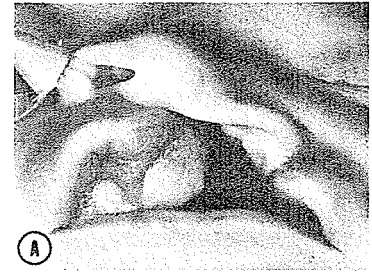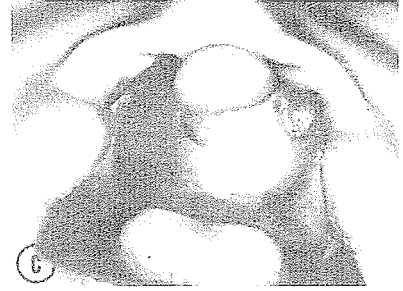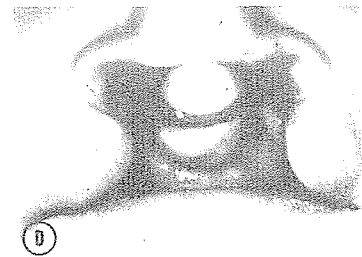



Plate in position




most adequate. . . . Stage I: Symmetrical closure of the nostrils and nasal floor produces approximation of the three segments which are supported and guided by the orthopedic plate; arch alignment ensues. Stage II: Closure of the lip proper is preferably done by Veau or Manchester cut. . . . Palatal tilting of the premaxilla is prevented by the supporting plate, fitted if necessary with a fan screw in order to allow further adjustments of the segments as well as to exert some counterpressure against scar contraction. . . . A new plate has to be made again at 10 to 12 months of age. Serving now mainly as an obturator, it is worn until a few weeks before soft palate closure. . . . Palatal closure in two stages is used for all complete clefts. . . . Velar closure is performed at about 18 months of age for the sake of speech development; hard palate closure is delayed until the sixth to eighth year. . . . After soft palate closure, no retention appliance is worn. . . . If demanded by the speech pathologist for better speech proficiency (plosives), an inactive plate may be used to cover the remaining gap. . . . Only about 50 per cent of the patients actually need it, usually not before four years of age.



After orthopedics



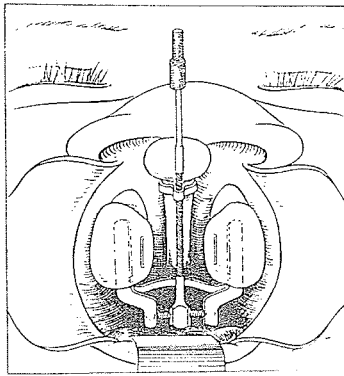
After stage I



After stage II

Hotz's logic parallels that of Cronin with regard to the considerable rate of growth during the first six months of life, total body weight being normally doubled, and advocates that one "take advantage of this quite dramatic rate of maxillary growth" within that time and not interfere with it. Hotz and Gnoinski conclude:

The main objectives of our efforts are: (1) to normalize form and function in early infancy; (2) to permit growth to develop to its full potential with regard to functional and esthetic requirements; (3) to render regular orthodontic treatment in the permanent dentition easier and successful in order to avoid large prosthetic reconstruction and/or major secondary surgery.



Mark III

### MECHANICAL PRESSURE

The ultimate in the principle of compression was developed in the 1970's by Georgiade and Latham in North Carolina. In the bilateral cleft with a projecting premaxilla, they attach a coaxial arch alignment appliance with two concentric knobs, one for arch expansion by a pinned maxillary prosthesis and the other for premaxillary retraction. Every turn of the second thumbscrew achieves a 1 mm. posterior displacement of the premaxilla so that with one turn twice daily the premaxilla is positioned within the arch well enough in 9 to 10 days for surgical closure of the alveolar clefts. More detail on this principle is presented in Volume II, Chapter 3.

Maisels' abstracted conclusion in his 1974 article in the *British Journal of Orthodontics* hits the bull's-eye of the surgeon's dilemma:

One wonders whether there is significance in the fact that most of the criticism of presurgical orthodontics has come not from surgeons, but from orthodontists who are either unable or unwilling to provide this service for their surgical colleagues and through them, for their patients.


During the 1977 International Cleft Palate Congress in Toronto, as I listened to experts in various disciplines argue among themselves, my suspicions were crystallized that rubber bands and surgical adhesions are medieval means of accomplishing what skilled *presurgical orthopedics* can do far better. To ask soft tissue

*In 1980 at the Duke CP clinic these cases are showing minimal distortion with less need of orthodontics!*

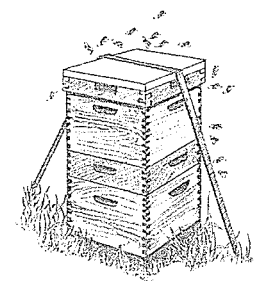
and the young scars to mold bony elements into alignment is an incorrect order of priorities. It is far better to have the bony base adjusted prior to closure of the lip and retained thereafter, if indicated. This maneuver will reduce the amount of surgery necessary, relieve the degree of tension against fresh scars, prevent the beating and twisting suffered by the constructed lip against the jutting asymmetrical platform and limit alveolar collapse in response to closure of the lip muscle band across the cleft. Frankly, *I particularly resent having my lip scars shoulder any unnecessary stress or strain!*

So when Latham made his offer he was welcomed!!

Ralph A. Latham of the University of Western Ontario, London, Canada, who trained with Burston in Liverpool and worked with Georgiade at Duke University, is a research orthodontist with a hobby of migrant beekeeping. He has moved from flower to flower, setting his hives for the bees to feast in the heather of Wales, the blackberries of North Carolina and the clover and goldenrod of Canada. Using Italian queens fed, not on beebread, but on royal jelly, he hopes to get 100 pounds of honey per hive per year eventually. This is his philosophy on treating the alveolar and hard palate cleft in unilateral cases:



Ralph Latham



## UNILATERAL CLEFT

Present management of the complete unilateral cleft lip and palate condition is prone to a poor nasal appearance, malocclusion of the teeth and maxillary growth deficiency in the form of a depressed facial profile. These features do reflect a persistence of the birth deformity and collapse of the maxillary palatal segments in the first months of postnatal life. The present purpose is to focus attention on the main cause for all of these maladies, namely the cleft in the palato-alveolar portion of the primary palate, which in general practice is never surgically closed. There is good reason to regard the continuing cleft in the dento-alveolar ridge as detrimental to the form and growth of the middle third of the face.

Three factors have been conducive to the decision to leave the anterior palatal cleft. First, there is usually malalignment of the palatal segments at the time of lip surgery. Second, closure later is difficult due to the inaccessibility of the cleft borders behind the intact lip. Third, there is a popular attitude based on consideration of maxillary growth and orthodontic treatment that nonclosure of the anterior palatal cleft may be beneficial.

It is well established that the early associated cleft deformities are amenable to corrective manipulation. It is now possible to arrange the palatal segments favourably for surgical closure by orthopaedic treatment. If anterior palatal closure is performed before proceeding to close the lip, accessibility is not a problem. The indications for giving anterior palatal closure first priority for surgical treatment are now such as to commend this approach.

The main advantages include the following: Closure of well aligned segments using periosteal flaps offers the possibility of bone fill-in of the cleft maxilla. This confers stability to the jaw as a whole. It also provides more normal anatomical conditions for growth of the maxillae. The achievement of good maxillary arch form avoids the problem of malrelated maxillary dental bases which eventually require extensive orthodontic treatment.

#### *Surgical principles*

The procedure for gingivoperiosteoplasty described here requires a specific optimum alignment of the cleft alveolar segments. These should conform to an arch form with a cleft width of about two millimetres. The surgical procedure has three important principles:

1. Utilization of only palato-gingival mucosa for closure on the oral aspect, and use of nasal and septal mucosa only for nasal floor construction.
2. Turning out the mucosa within the cleft as flaps to effect the closure.
3. Periosteum to be included in flaps as much as possible.

#### *Requisite of mucosal type*

Palatal and gingival periosteum is associated with prolific osteogenesis on the oral surface of the palate and on the alveolar processes. Use of such periosteum on the palatal aspect of the repair provides an optimum environment for bone growth and the establishment in the cleft site of a normal maxillary growth process. Similarly, periosteum from the vomer and lateral nasal wall has bone resorption function of varying degree, and such periosteum should be kept on the nasal aspect of the cleft site where the continued manifestation of bone resorption would be in keeping with the normal growth pattern.

#### *Mucosa of cleft borders*

Most of the cleft border mucosa is of an oro-palatal or gingival type which is appropriate for the construction of the flaps on the oral side. This mucosa is of the same kind as adjacent gingival mucosa and tends to have a similar growth pattern. However, for the cleft mucosa to adequately reach across



the cleft site, the palatal segments must be within about 2 mm. of each other.

### *Use of periosteal flaps*

It is important to expose bone on both sides of the cleft and to develop a tube-like lining of periosteum from one segment face to the other. A deep repair is of paramount importance. The most satisfactory part of the repair for its osteogenic potential is posteriorly between the palatal process and the posterior premaxillo-vomer area. Properly performed, the surgery should be followed by the filling of the cleft site by osteogenic cells and fibroblasts which would initially support the periosteal flaps and as early as seven days post-operatively give way to their replacement by commencing bone formation.

In November 1976 Latham wrote me:

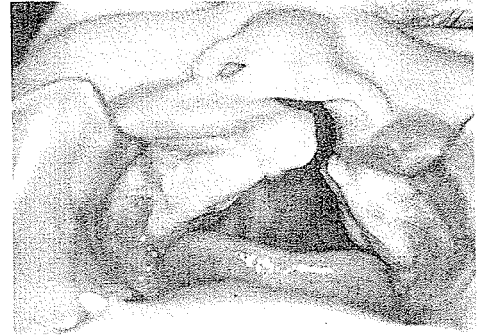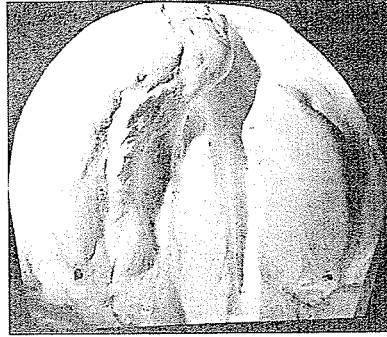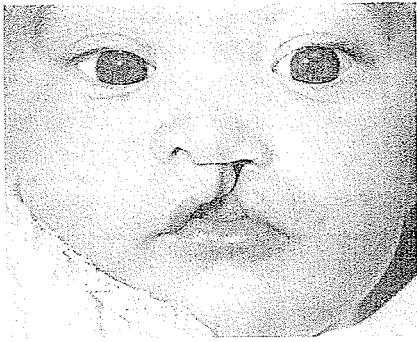I believe I have just the perfect anterior palate surgical design to complement your Rotation-Advancement lip operation. Just thinking of all those beautiful lip operations that conceal behind them an unstable, malaligned, growth retarded, functionally denied and maloccluded dento-alveolar CLEFT that almost no one in North America is much interested in, makes me groan. . . . For ten years, I have known in principle what was needed. This is why this baby is special. With the help of her dentist father, I applied substantial tractional force in a correctional direction with a forward, rather than backward, force vector. The rubber bands and head gear were quite easily handled at home without hindering feeding. Will you do the surgery for this important baby? Gingivoperiosteoplasty should definitely be before teeth start erupting in the cleft area. About 2-3 months appears optimum. Going over 6 months is cutting it fine, although teeth tend to be delayed in eruption in relation to the clefts. This baby is now over 4 months old.

*Latham's offer came at a good time.*

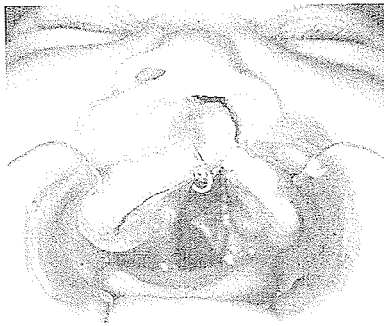*We had to get going!*

On the first day of December 1976, with Latham assisting, I operated on the baby in Miami to develop clinically a method of treatment employing the principle of sutural adjustment during facial growth (Latham 1974). Here is Latham's report of the case:

The main anatomical problem is that both palatal segments are displaced to the same side, the noncleft side. The premaxillary segment is displaced anterolaterally with an upward tilt of the cleft premaxilla; the cleft segment is retroplaced and collapsed. The nasal septum is bent both anteriorly and posteriorly, which is a basic cause of facial asymmetry and nasal obstruction. The cleft maxilla frequently does not appear to be collapsed, but the collapse shows if the noncleft segment is restored to the midline.

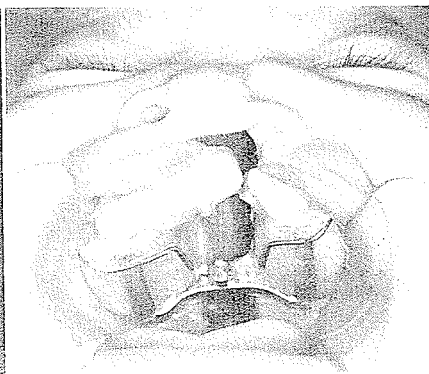
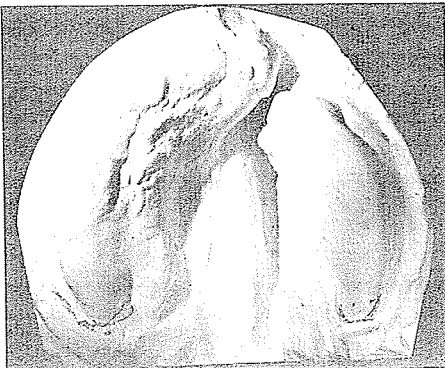
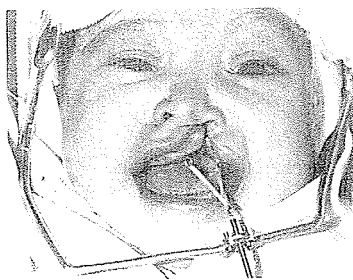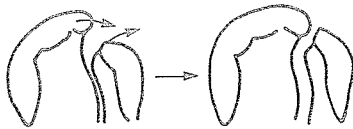


These problems usually preclude surgical closure of the anterior palate and alveolar ridge at the time of lip surgery. Nevertheless, because of his background in basic research in facial growth and development, Dr. Latham thinks that the alveolar ridge should be united at the earliest possible time to optimize normal growth. But the dental arch must be expanded and retained with appliances until the cleft has filled in with new bone that can maintain the dimensions of the palate.

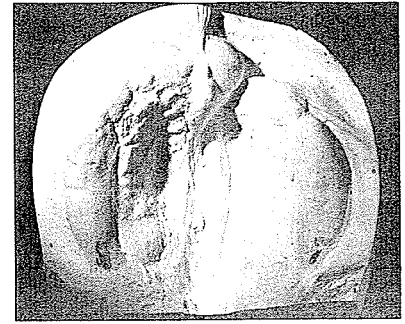


#### *Orofacial Orthopaedic Treatment*

The problem was how to pull the noncleft and the cleft segments downward, forward and into a normal arch relationship. Correction of the arch form requires that both segments be drawn by traction in the same direction. This problem was solved by the use of an acrylic intra-oral appliance which was pinned to the palatal processes and, in addition, tied anteriorly by passing a wire over the floor of the noncleft nostril and then around the appliance. The base from which to apply extra-oral traction was provided by a face bow anchored to a custom-fitted head cap. The traction was then placed with a rubber band from the appliance to the face bow. Both the amount and the direction of force were adjustable. Correction of the premaxillary segment towards the midline was obtained with three ounces of traction maintained over a period of three weeks. The traction plate on the cleft side dislodged early in the treatment, resulting in the corrected noncleft side overlapping the cleft side. A Georgiade-Latham expansion appliance was inserted to displace the cleft side laterally and to establish an operating space of about 2 mm. between the cleft alveolar ridge abutments.



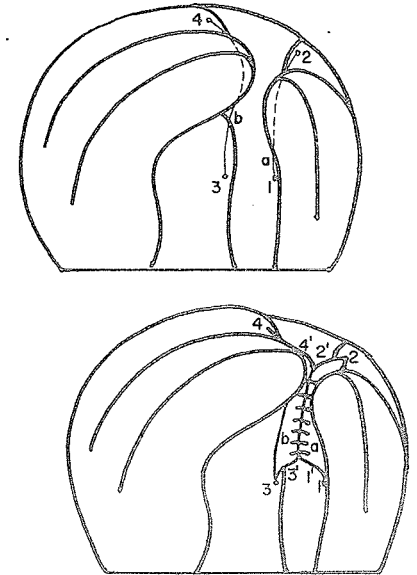
While the alar base asymmetry in the case of the unilateral cleft is due primarily to the deformity of the underlying bony structure and its correction does a great deal to establish nasal symmetry, the infant's face may still look asymmetrical due to hypoplastic lip tissues. Final alar symmetry was simulated by pulling the lips together with adhesive tapes. Thus it was expected that some soft tissue growth would both facilitate the surgery and enhance the result.



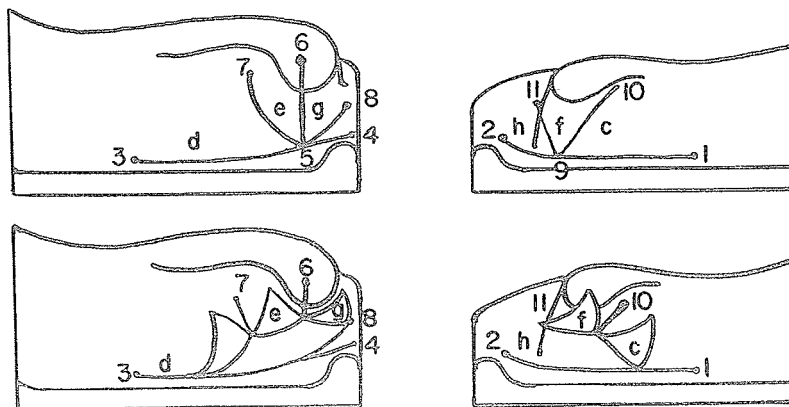
The orofacial orthopaedic treatment worked well and the cleft palatal segments were well positioned for anterior palate and alveolar ridge construction by gingivoperiosteoplasty.

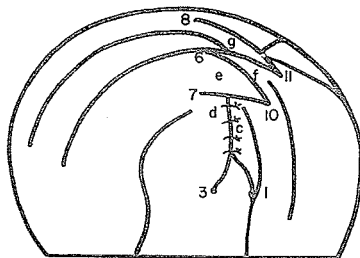
### *Orthopaedics Facilitates Early Surgery*

**GINGIVOPERIOSTEOPLASTY: THE INTERDIGITATING ALVEOLAR FLAP METHOD.** A new modification of the periosteoplasty procedure was used. The distinctive features are closing the palatal aspect of the cleft using only palatal mucoperiosteum, and using interdigitating gingival flaps to construct continuity of the alveolar ridge. This modification involved no lateral relaxing incisions or denuded palatal areas. The basic incisions were at the cleft borders. Flaps from the lateral nasal wall and from the nasal septum were turned superiorly, and flaps from the palatal mucoperiosteum were turned inferiorly to effect a two-layer closure.



The two main incisions were commenced posteriorly. The first (1-2) on the medial border of the palatal process commenced near the posterior border of the hard palate and the second commenced over the vomer bone (3-4). The position of the vomer incision (3-4) was determined from an estimate of how far the cleft side palatal flap (a) would reach medially; the noncleft side vomeropalatal flap (b) was then cut long enough to meet it. Both of these incisions ended anteriorly at the markings for the lip at the alar base point laterally and at the base of the columella medially.





The curved premaxillary abutment was denuded by raising two triangular flaps, one anteriorly "g" and one posteriorly "e." The gingival ridge on the cleft side was raised as flap "f." This went between the two triangular flaps of the premaxillary abutment to give continuity of the ridge crest. The flaps "c" and "d" came together to close the oral aspect of the anterior palate. Most of the reach here across the cleft came from the palatal flap on the cleft side, which was thoroughly elevated from the palatal bone. The vomero-palatal flap on the noncleft side approximated a little, too, after it had been freed from the bone.


#### *Lip Surgery*

The anterior aspect of the palate was closed by the lip tissues. A lip adhesion procedure without l flap was preferred at this stage for two reasons: first, to avoid compression of a tight lip repair on the newly constructed dental arch; and second, to provide a later opportunity to perform the definitive lip closure after the maxillary arch had been expanded postsurgically, the palate repair had settled down, and new bone supported a stable maxillary base. Postsurgical arch expansion of more than 5 mm. would disrupt a good nasal repair.



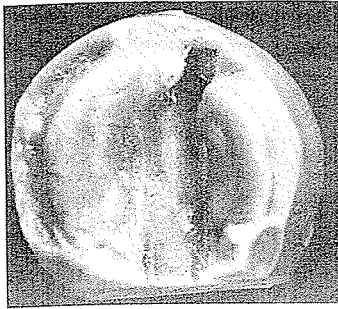
#### *Postsurgical Arch Expansion and Retention*

At three weeks after surgery a new palate impression was taken and another expansion appliance prepared and inserted with pin retention. There then

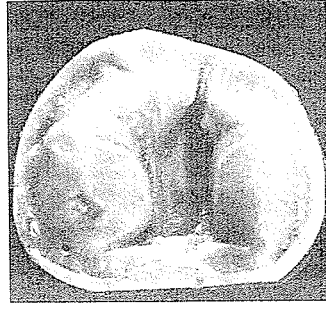


followed rapid expansion of the palate to correct the postsurgical collapse and further expand the alveolar arch. This was a provision to avoid later dental crossbite. In this case, the postsurgical expansion was about seven millimetres in the width of the molar gum pads. The appliance remained in place for the final lip closure by the rotation-advancement procedure, and was removed two weeks later.

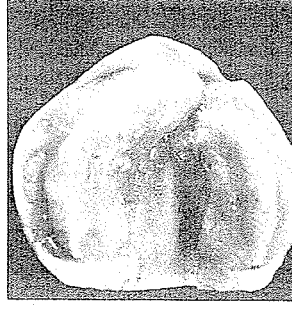
Here is an interesting series of models of this case:



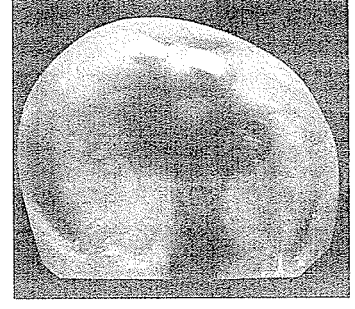
October 8, 1976. Traction applied to pull non-cleft side medially and downward. (2 months 17 days)



November 5, 1976. After 28 days of movement of greater segment toward midline. Cleft segment needs expansion. (3 months 15 days)



December 4, 1976. Expansion appliance in 29 days. Arch well aligned. (4 months 15 days)



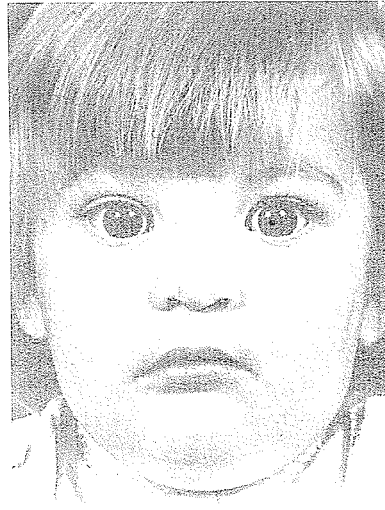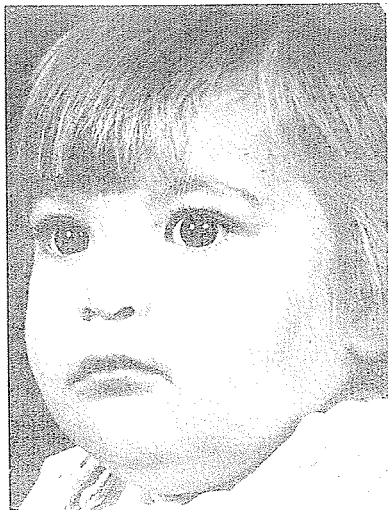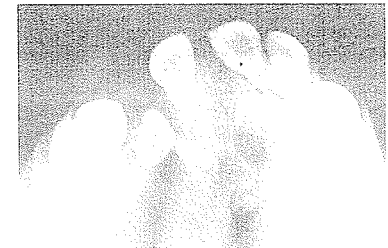
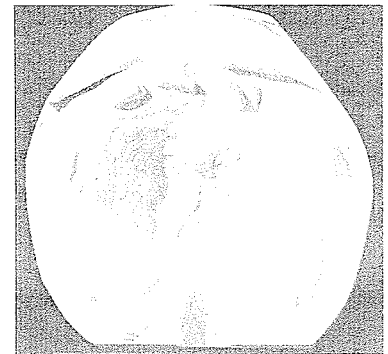July 6, 1977. After definitive lip closure. (11 months 17 days)

In October 1977 Latham wrote:

I am still very pleased with the result of our combined efforts. Three similar infants have subsequently been treated.

Then in January 1978:

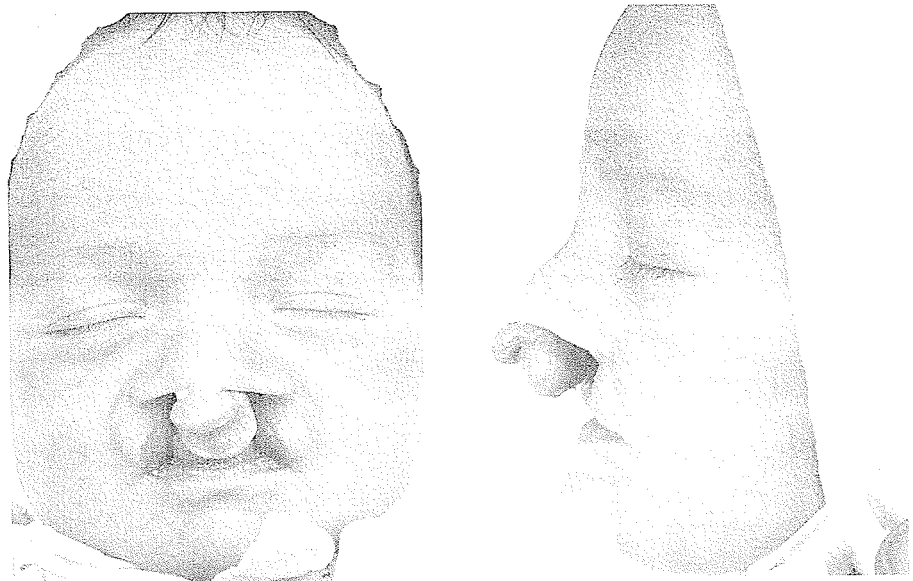You will see in the most recent cast I am sending you the arch form looks very acceptable indeed. On the radiograph there appears to be a bony bridge which is obscured by a supernumerary tooth which comes from the cleft maxillary side, so clear definition of the uniting bone is still difficult to assess. The deciduous first molars are just erupting and in another few months they will give a better perspective on the proportions of the arch in general.



Overall, it appears to me that the sequence and timing of treatment has been close to the very best possible and I feel that this represents an historically important milestone in the progress of the treatment of congenital cleft palate. Don't you think it is essential to get a number of such patients going so that serial records in a long term follow-up study can be obtained to observe antero-posterior growth, the form of the maxillary arch and to see if early prevention of collapse by bone support holds up in the long term?

### BILATERAL CLEFT

Then Latham and I turned our attention to a patient with a severely protruding premaxilla and "collapsed" maxillary segments. The case was shown to Berkowitz prior to our treatment, and he wrote me:



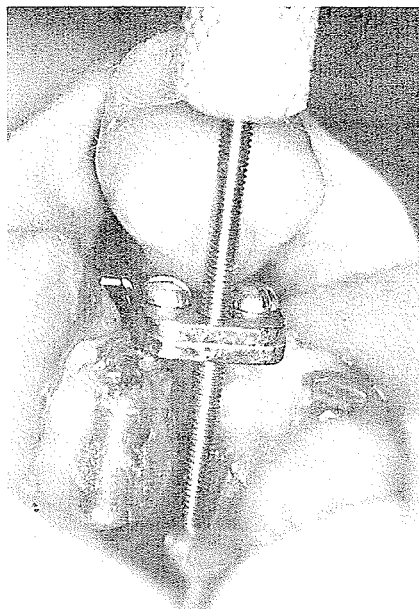
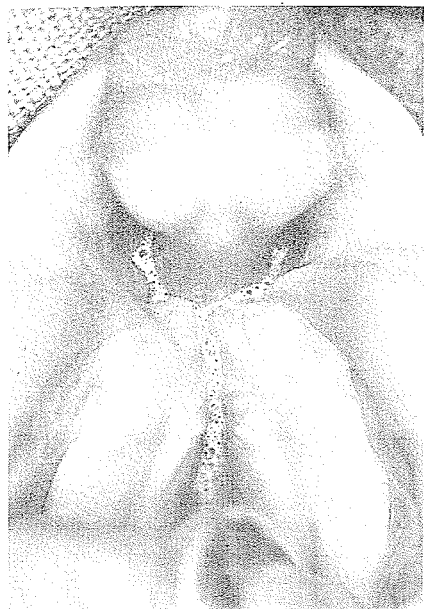
The evidence is in and one can predict the outcome if you should either surgically attach the premaxilla to the palatal segments and/or close the palate. The outcome will be a malformed maxilla.

It may be a good idea to retract the premaxilla half the distance to the palatal shelves just so you can unite the lip. The case will then react like all your other cases and perhaps turn out equally as well; you need not do more. There is no literature written within the last ten years which supports anything else!

Convinced that the status quo was not good enough and always searching for an improvement, confident that the litera-

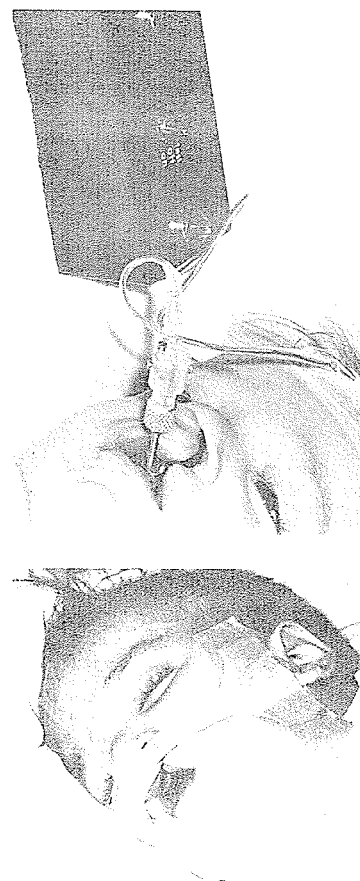
ture in the next 10 years will not repeat all the platitudes of the last decade, we proceeded cautiously. Latham's report follows:

The bilateral cleft lip and palate infant usually shows a protruding premaxillary segment that is a main focus of attention in treatment. However, this problem becomes secondary in those rare instances when the maxillary segments have collapsed to the extent that their gum pads touch in the midline. This extreme malrelationship was the case in the infant Willie M., offering a challenge even for a pinned-screw expansion appliance.



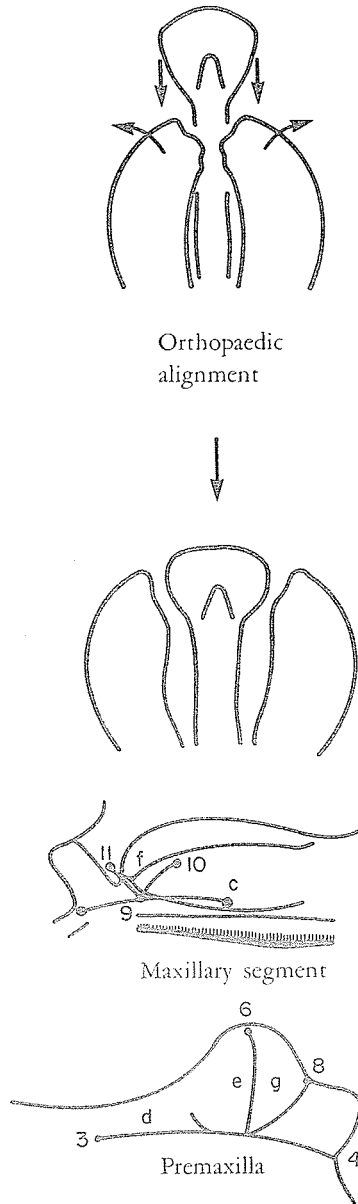
The Miami Cleft Palate Team noted that a lip adhesion procedure by itself could not be expected to retract the premaxillary segment since this was locked out by the collapsed maxillary segments. When Willie was 4 months and 24 days old, Latham inserted a Georgiade-Latham coaxial cleft palate orthopaedic appliance and, by passing a stainless steel pin of 0.036" diameter transversely through the premaxillary basal bone behind the tooth buds, retraction was exerted on the premaxilla simultaneous with expansion of the maxillary segments.

A novel accessory used with the coaxial appliance was the retraction force monitoring system specially developed for this case by Olivier Monbureau at the Dental Research Center of the University of North Carolina at Chapel Hill. This employed a triple light indicator mounted on a black box that also housed small batteries, and its purpose was to show when adjustment of the appliance was required. For the next 4 days treatment progressed well as the appliance was regularly inspected and activated. On the 5th day Dr. Latham was notified that the appliance was not working properly. Subsequently this observation was confirmed and on the 9th day the coaxial



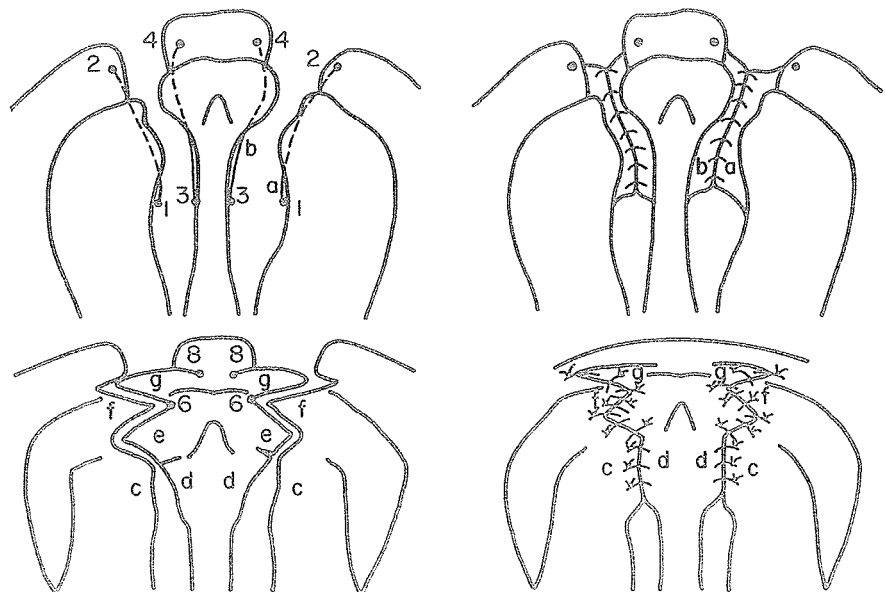
appliance was removed and treatment continued employing a facial strap (Liverpool type) for premaxillary retraction, and a standard Georgiade-Latham expansion appliance for continued expansion of the maxillary segments.

The expansion component used initially in Willie's case was of a design that allowed maxillary rotation in the coronal plane simultaneously with lateral expansion. So much expansion was required that a spreading of the bridge of the nose was a matter of concern with use of the standard expansion appliance. Although previously used with success on an expansion problem, the rotating-expansion appliance developed a fault when used for the first time with the coaxial retraction component. Correction was quickly performed but in the course of a second attempt to obtain expansion, the maxillary segments collapsed to their original positions. Engaging palatal bones with the retention pins had been a delicate matter from the start, but now faced with renewed force for rapid expansion, insufficient pin insertion in bone combined with the rotation facility in the expansion appliance and permitted unimpeded collapse. At this point, 11 days into treatment, resort was made to the standard expansion appliance normally used. Premaxillary reposition was aided by a facial strap (Liverpool type). Effective expansion was resumed and in the three days immediately preceding the surgery date, or after 14 days of orthopaedic treatment, the 12 mm. of expansion was obtained. Ideally, the premaxillary segment should have been retracted further by a few millimetres still to allow for rebound.



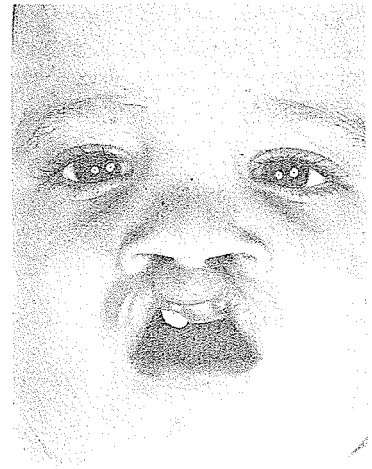
### *Orthopaedics Facilitates Early Surgery*

**BILATERAL GINGIVOPERIOSTEOPLASTY.** The Interdigitating Alveolar Flap modification was used to reconstruct in two layers the anterior palate and alveolar ridge bilaterally, as shown in these diagrams:

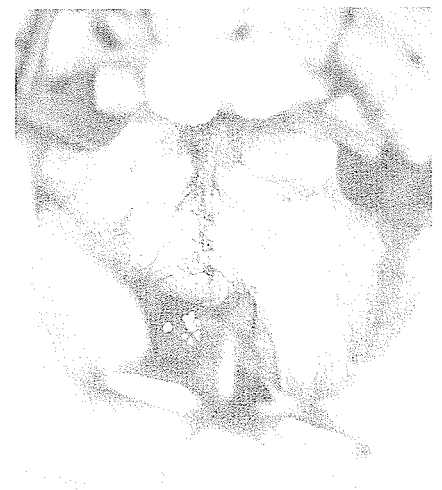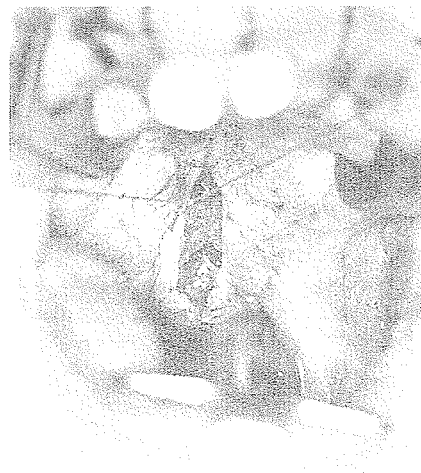

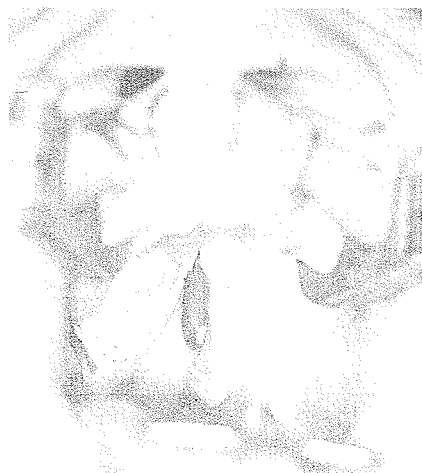


The lip was then closed bilaterally using a lip adhesion procedure. An expansion appliance was made to be inserted post-surgically. The tendency for maxillary relapse was strong since there was no retention for the aligned arch prior to surgery. With this surgical procedure bone tends to form within 60 days, so there is a risk of bone forming across the repair before expansion is achieved. Thus, an expansion appliance to splint the expanded maxillae was inserted several days postoperatively by resident Robert Zaworski and the father instructed to turn the expansion screw  $\frac{1}{2}$  turn every other day. When he had expanded to the limit of the appliance (less than one mo.), it was maintained as a retainer for an additional 2 months postoperatively.



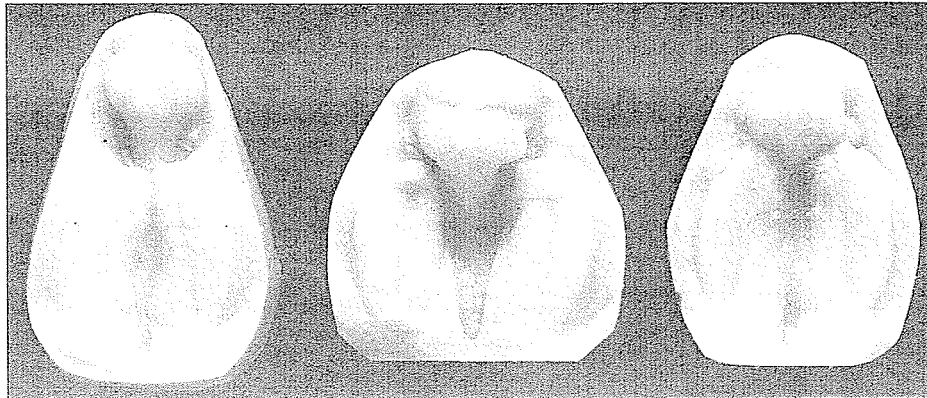
On March 2, 1978, a forked flap was marked over the adhesion union, taking portions of the prolabium, adjoining scars and lateral lip elements. A Millard mouth gag was inserted and the cleft in the soft palate closed by splitting the cleft edges and dissecting out and dividing the abnormal anterior levator muscle attachments to the posterior edge of the hard palate. The nasal mucosa was closed with catgut. The levator muscle bundles were repositioned about 1 cm. and sutured with two 4-0 Vicryl sutures. Then the oral mucosa was closed with 4-0 chromic catgut mattress sutures with one through-and-through suture just anterior to the mended levator sling to prevent anterior drift. The gag was removed and the forked flap banked in whisker position after the lateral lip mucosa and muscles had been joined to each other in the midline behind the prolabium.





Thus, by 1 year of age the forks have been banked for columella lengthening, the lip is closed with muscle union and a mucosal sulcus, the alveolus, hard palate and soft palate are closed and the levator muscle is retropositioned. A retention plate will be used as circumstances require.

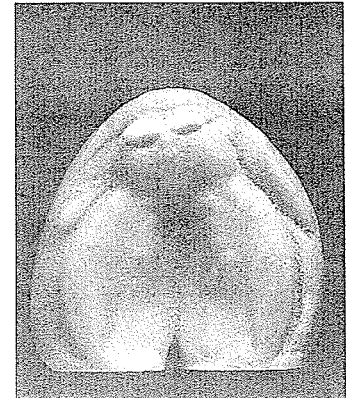
Here is a series of cast models made by Latham and Berkowitz to demonstrate the progress of the treatment.



June 28, 1977. Palatal cast at 4 months 24 days

July 14, 1977. Cast after 14 days of orthopaedic treatment

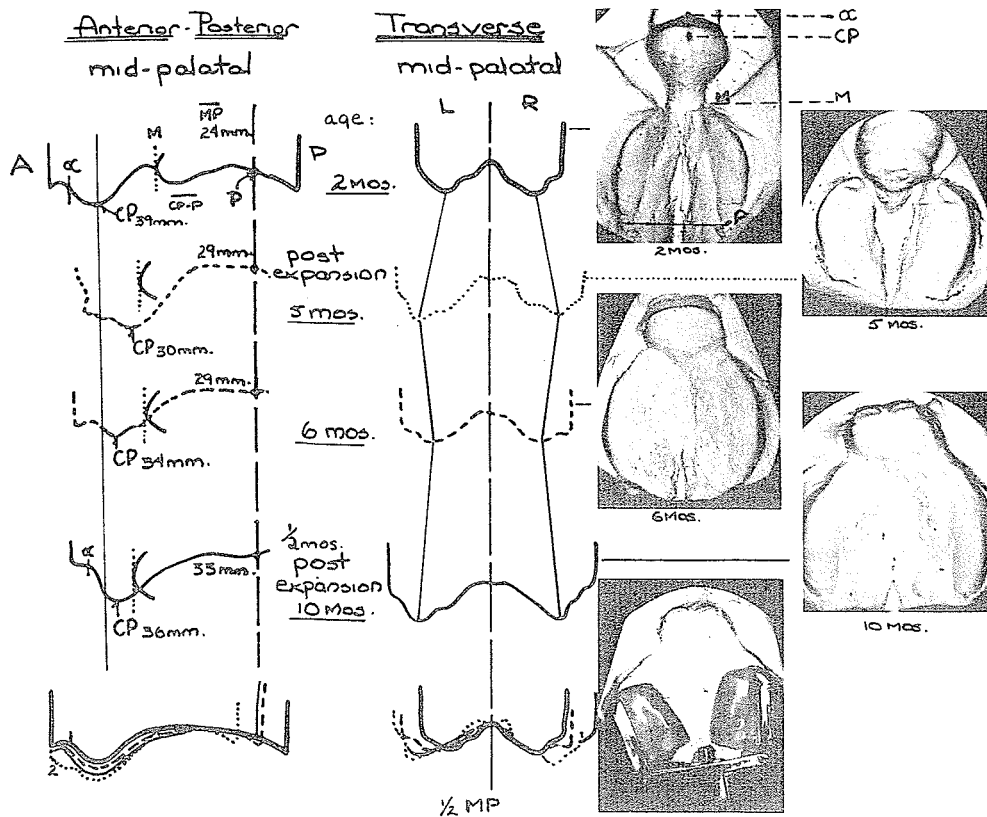
August 10, 1977. Cast one month after gingivoperiosteoplasty and lip adhesions



March 2, 1978. Cast at 1 year 1 month, taken prior to muscle union of the lip, banked fork and closure of the soft palate

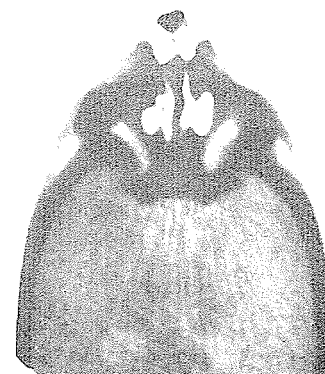Berkowitz's comment after following this case was:

The geometric effect on a neonatal palate of a fixed intraoral premaxillary retractive device designed by Latham was reviewed by analyzing serial casts, lateral cephalographs and computerized axial tomography. This study demonstrated that the nasal septum buckles at the vomer-nasal septum junction, and that excessive premaxillary ventroflexion occurs as well. Anterior palatal growth was mainly responsible for the closure of the anterior cleft space. Straightening of the facial profile was mainly due to mandibular growth. Forceful retraction of the premaxilla accounted for a net retrusion of 3 mm. over a ten (10) month period of time. In this case it is too early to determine the effect of early palatal surgery on palatal growth and development.

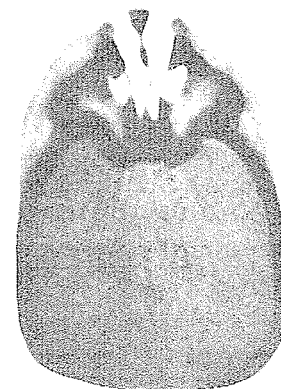

The buckling of the septum is not serious and is shown by Berkowitz's computerized axial tomographic view of the nasal septum, taken through a plane through the superior orbital fissure and the premaxilla. In my opinion the ventroflexion is minimal compared to that in cases in which the lip has been closed like a bowstring over the protruding premaxilla. Although the total premaxillary retrusion might have been only 3 mm., it was about 9 mm. at the time of gingivoperiosteoplasty, rendering the operation feasible. It is heartening that Berkowitz does admit some excitement at studying this approach only for these severely protruding premaxillas and has encouraged Mazaheri and Olin to join him in experimenting with it and recording results. He noted:

There are certain cases that will ultimately need surgical premaxillary repositioning. If these cases were identifiable at the newborn stage, then forceful retropositioning might be of use. Unfortunately, there are still no all-conclusive predictive parameters. Friede and Pruzansky (1973) have reported that in those cases in which the distance between the premaxilla and the anterior portion of the lateral palatal segments is greater than

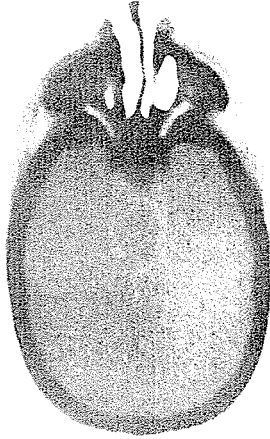


2 months, pretreatment



3 months, postexpansion

*a breakthrough?*



10 months, postexpansion

25 mm., the growth prognosis is poor. Possibly these cases might be good subjects for this approach, always remember that *selectivity* of cases is of prime importance. Forceful retrusion should not be performed for all complete bilateral cleft lip and palate patients. The effects of this procedure on midfacial and septal growth have still not been documented. Other investigators have to monitor these results since the originators of this procedure have failed to do so. In this case the early closure of the palatal cleft will mask the effects of forceful premaxillary retropositioning; therefore, better controls need to be established to more accurately evaluate its utility.

In 1979 Berkowitz added:

I do not see any reason for the lateral expansion of the maxillary palatal segments at the newborn period. This case does demonstrate that after Latham expanded the palatal arch it returned to its original dimension when the appliance was removed. Any further palatal arch width change that occurred was due to growth and not to palatal manipulation. This increase in palatal width is predictive in almost *all* instances, provided there has not been any inhibiting scar tissue.

Berkowitz has since voluntarily used the Georgiade-Latham apparatus on two bilateral clefts with severely protruding premaxillae. I see a hope for progress here!!