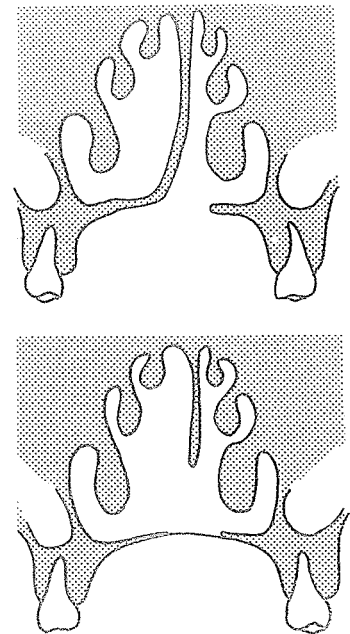


15. Nasal and Labial Flaps for Alveolar and Hard Palate Closure

THE cleft of the alveolus and hard palate has been closed with various mucoperiosteal flaps turned off the vomer. This being a one-layer closure with a raw surface, there is some contracture resulting in varying degrees of maxillary distortion. The distortion depends on the position of the elements prior to surgery and the age of the patient at the time of surgery.

In 1872 Lannelongue closed the hard palate in a wide cleft by utilizing a portion of the vomerine mucoperiosteum which was continuous with one border of the defect. He made an incision on the vomer parallel with the border of the cleft, extended the anterior and posterior extremities of the incision to the border of the defect and elevated the vomerine mucoperiosteum from the underlying bone. The flap created was then held with sutures to the denuded palatal mucoperiosteum of the opposite side.

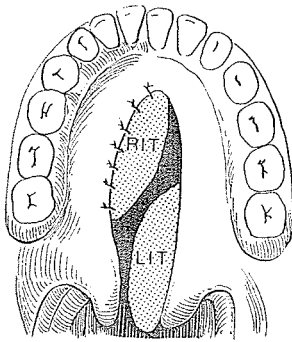
Other flaps from tissues of the nasal chambers have been used to close hard palate clefts. As early as 1851 Gay used a full-thickness flap of septum to fill the cleft, and in 1890 Sabatier moved the septum nasi to the horizontal plane of the palatal vault. Anton Freiherrn von Eiselsberg, in 1901, when he became director of the First Surgical Clinic of Vienna, reported using the vomer and its mucoperiosteum to close unilateral alveolar and hard palate clefts. Anyone tempted to repeat these maneuvers in a child should heed the words of Gillies:



von Eiselsberg



The initial mistake was the opportune but ill-considered manoeuvre of bringing down into the palate defect in a wide unilateral cleft of the alveolus and palate a whole-thickness flap from the septum. The primary object of filling up rather than pulling together the gap in the palate was singularly successful to the extent of perfect speech. But his nose remained juvenile and flat, for the possible effect on the growing centres of the nose had been overlooked.



In 1895 Kraske used the inferior turbinates to close palatal clefts. He resected the inferior turbinate from before backward, leaving it attached behind but fracturing the bone in the pedicle as it was swung forward and sutured to one side of the denuded cleft in the palate. Fourteen days later the pedicle was divided and the remainder of the turbinate attached into the cleft. Kraske advised removing the bone when using this flap for cleft velum.

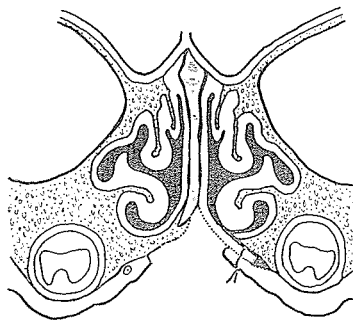
PICHLER



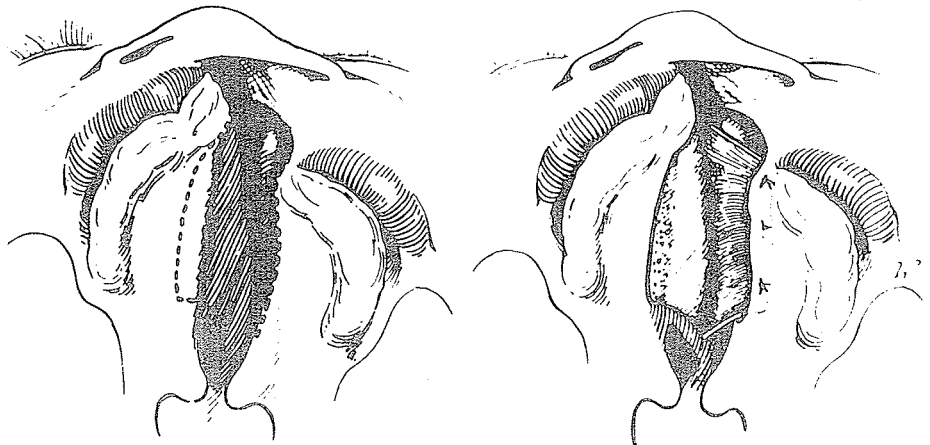
Hans Pichler

Hans Pichler, an Austrian who worked with Esser, was important in the development of maxillofacial surgery before World War I. He was an instructor of Richard Trauner of Graz, who recalled:

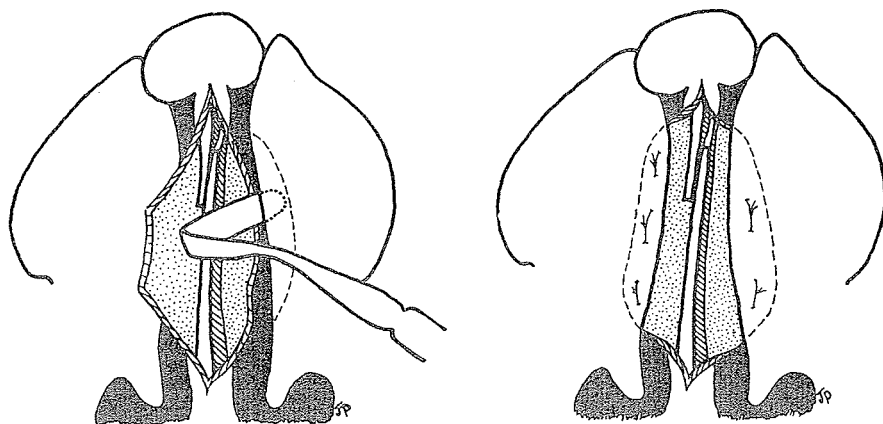
Pichler was a very true and upright man. We were united because of our great love of nature. Pichler fabricated ice sailing sledges on the large but narrow Lake Neusiedlersee near Vienna living there very spartanic but it was great fun for all when one of the pampered elder assistants slipped and fell into the ice water!



In 1926 Pichler first developed dissection of the cranially based vomer flap, which in unilateral clefts he tucked under the mucoperiosteum of the opposite edge of the palate cleft and fixed with mattress sutures to close the anterior hard palate in one layer.




In bilateral clefts he combined von Bardeleben's retropositioning maneuver of the premaxilla with hard palate closure using two mucoperiosteal flaps from the vomer tucked under the cleft edges.



VEAU

Victor Veau was the world leader in clefts in Europe from about 1925 to 1945. In the late 20's he had his own hospital with 75 beds where he treated his cleft lips and palates. Gerald O'Connor of San Francisco, who was training with Gillies in England, often crossed the Channel to observe Veau at work. He recalled:

Veau was a slow, meticulous innovator and rather stubborn—his way was the only way. He was a character, too, sitting in a "high baby chair" with a back, arm rests and feet support. He wore a baseball hat with magnifying glasses and had a large tube constantly passing oxygen under his shirt to keep the ether or chloroform fumes from putting him to sleep. His technique, surgery and judgement were quite good and basically he was a very good teacher and I would have learned and understood more had I spoken French.

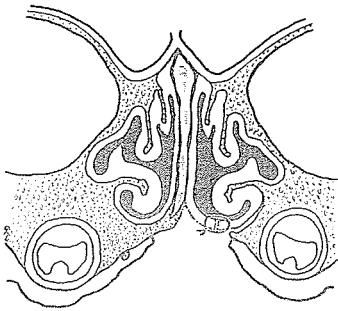
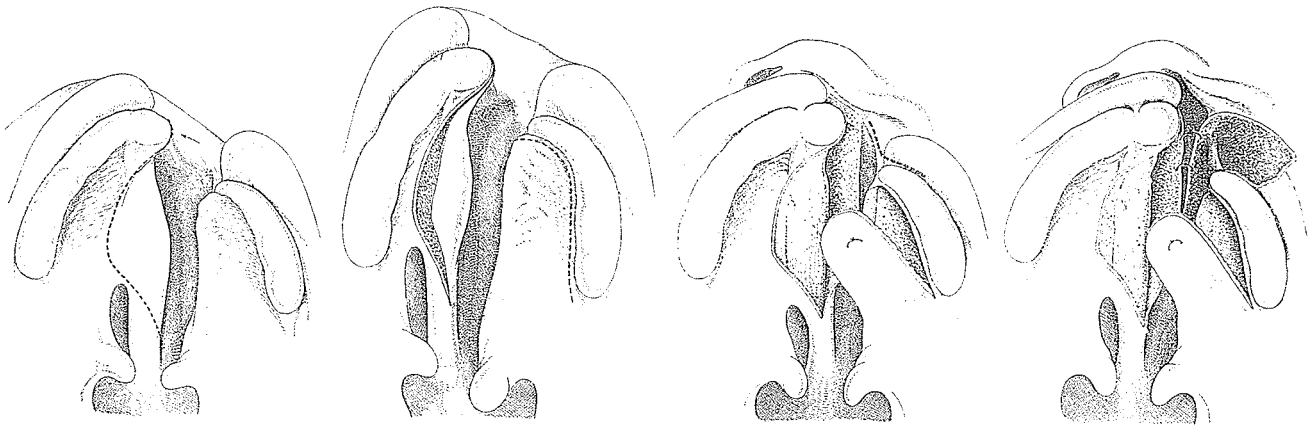


Victor Veau

Another version comes from Rudolf Meyer of Lausanne, who of course speaks French fluently. He recalled Veau sitting on a chair in the middle of the room waiting for the operating table bearing a cleft child to be rolled before him. As Meyer noted, he was

not unlike the famous clown Grock who used to be sitting on a small piano chair under a spotlight, waiting for the grand piano to be brought to him.

The sound surgical principle of closing raw areas was the basis for Veau's greatest contribution. In 1931 he was turning vomerine flaps into the cleft to supply closure for the nasal side and partially reinforcing this with an oral mucoperiosteal flap. Previously, the nasal side had been left raw and subject to contracture and fistulae.



His method varied from that of Pichler in that the vomer flap did not tuck under the mucoperiosteum but was sutured to the freed nasal mucosa.

In 1937 Wardill republished Veau's diagrams to describe his own approach to the anterior cleft. Kilner's approach was also similar to Veau's, employing a one-layer mucoperiosteal flap closure of the anterior palate alveolar cleft and usually accomplishing it at the time of lip closure because of the ease of exposure. When postponed until after the lip has been united and has pulled the alveolar segments into apposition, this procedure becomes an awkward maneuver. The width of some clefts in the alveolar area and the fear lest a one-layer closure distort the alveolar arch by contracture have been the factors causing some surgeons to procrastinate on alveolar treatment at lip closure time.

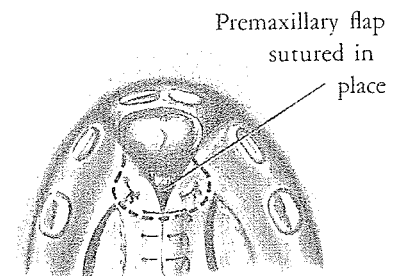
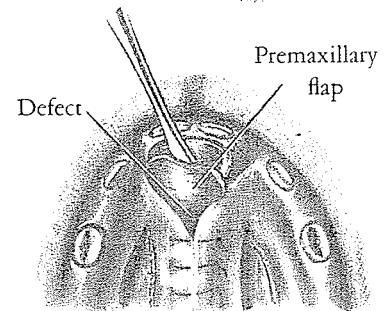
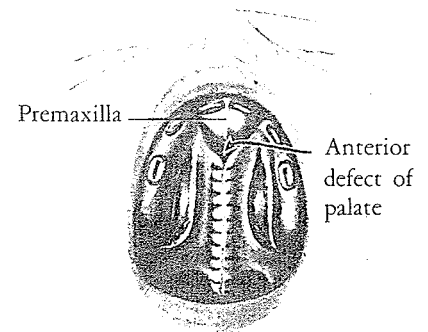
PREMAXILLARY FLAPS

In 1927 Franz Ernst of Berlin advocated eversion of the mucoperiosteum of the premaxilla in bilateral clefts from before backward. It could, he noted, be divided in the midline and

turned leaf-of-the-book-wise to fill the cleft on each side between the premaxilla and the maxillary bone.

COE

Dissatisfaction with the anterior nasal closure of bilateral clefts by the standard Veau method led Herbert E. Coe of the University of Washington School of Medicine, Seattle, to describe a turn-under flap of premaxillary mucoperiosteum. In 1953, in *Plastic and Reconstructive Surgery*, he diagramed the usual von Langenbeck procedure with closure of the palate cleft up to the premaxilla. Then a turnback flap of mucoperiosteum from the premaxilla based on its posterior edge would be turned and tucked under the mucoperiosteal flaps at their anterior cleft closure and fixed with sutures.




DUNN

In 1952 Fred Dunn of New York City advocated the use of vomer flaps to close the hard palate cleft. In two later sessions, first the soft palate was closed as far forward as possible, and finally the remaining defect, by two narrow, bipedicle mucoperiosteal flaps. The entire process was usually complete by 4 years of age, and Dunn reported good results with no interference with bone growth, tooth eruptions in correct position, normal dental and palatal arches and flexible soft palate.

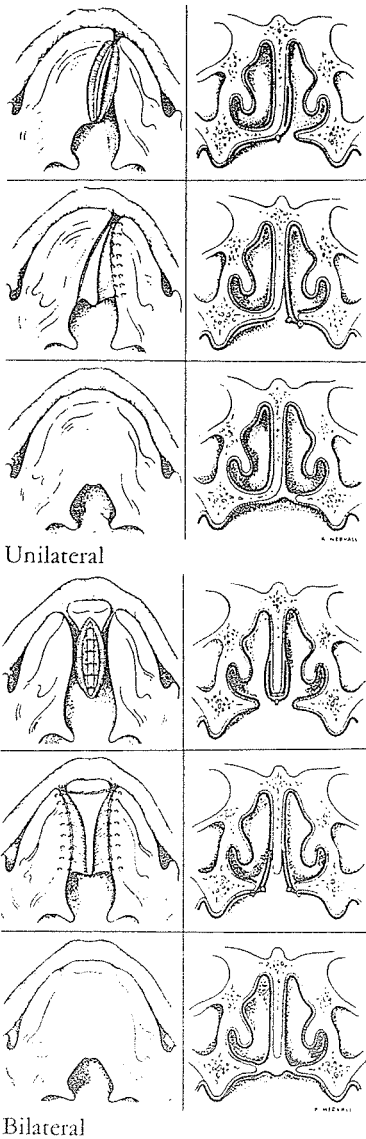
STENSTRÖM

About 10 years later, Stenström, intrigued by Dunn's report, carried out 10 such operations but added his modification. In 1973 he began to make assessment of this approach.

Sten Stenström of Umeå University Hospital, Sweden, is a little man with a short temper, a big heart and the soul of a missionary. He is usually inaccessible, working in his retreat near Lapland, several hundred kilometers south of the north polar circle where reindeer roam in the midnight sun. Yet he has been known to venture forth in missionary expeditions to Abyssinia,



Sten Stenström



and I remember him at the Swedish Red Cross Hospital in Korea. In Copenhagen in 1973, at the Cleft Palate Congress, he presented his interesting use of skin grafts to cover the raw surface of vomer flaps.

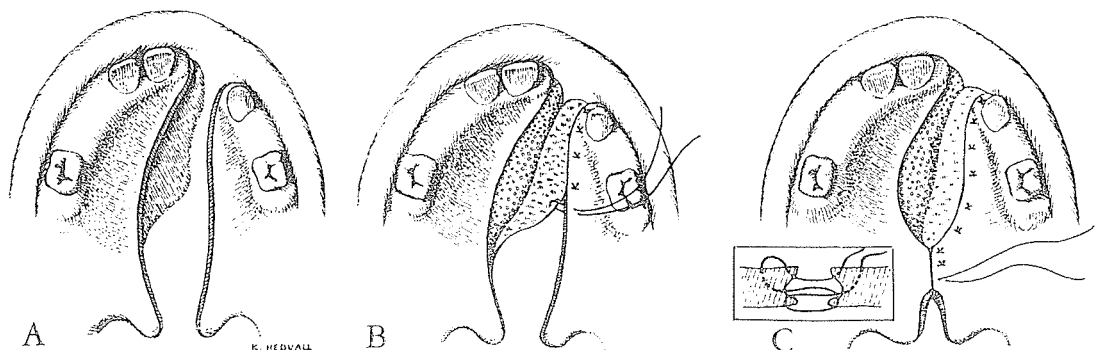
The vomer flap was incised and elevated in the usual fashion, and a full-thickness skin graft from the hairless groin was buried in the pocket with the raw areas facing each other. Twelve days later the lined vomer flap was again released, turned over and tucked under the opposite edge of the palate cleft. Stenström reported that in four weeks the depression on the side of the vomer was mostly filled out. In 1974 with Thilander, in the *Scandinavian Journal of Plastic and Reconstructive Surgery*, he presented diagrams of his method used in unilateral and bilateral clefts.

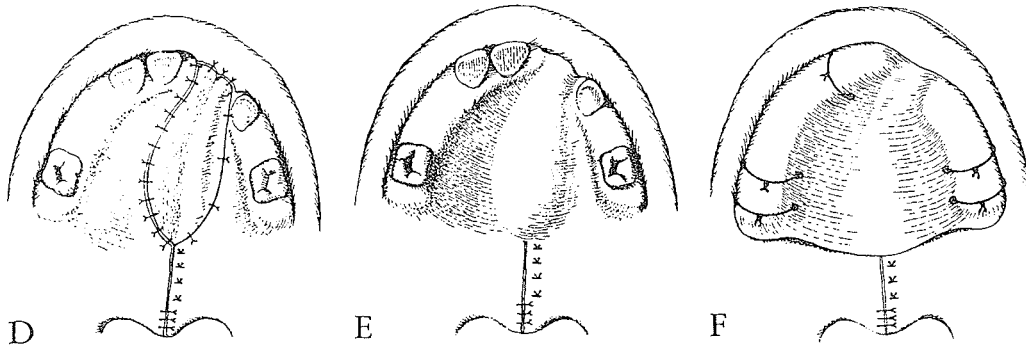
His follow-up of these 10 cases showed occlusion to be perfect except in three, and, although the soft palate appeared short, only three required posterior pharyngeal flaps. Late in 1974 Stenström sent me this note and the accompanying, more modern diagrams:

The report I gave in Copenhagen has been borne out in every detail by our subsequent experience:

The skin-grafted area of the hard palate completely resembles the untouched palatal mucosa; the shapes of the palatal and dental arches are strikingly good and there is almost no constriction of the maxilla in a transverse direction. I have also found that the soft palate can be completely closed at the same time without bilateral relaxing incisions. The usual uneventful healing is in my opinion due to the exclusive use of figure-of-eight sutures. Only in the case of very wide clefts is it necessary to leave a small residual opening at the front of the soft palate for closure at a later stage.

In some cases split-skin grafts were tried for covering the "vomer-pocket" instead of full-thickness skin grafts. Although I have not yet seen any bad effects from this, I have nevertheless reverted to full-thickness skin grafts in





order to eliminate as much as possible any tendency to shrink. A. Unilateral cleft. B. Vomer flap being tucked under opposite edge. C. Soft palate closure obtained without relaxing incisions but with figure-of-eight mattress sutures of 4-0 polyethylene. D. Full-thickness skin graft sutured along medial and lateral cleft edges. E. The vomer-pocket has been filled out with Visco-gel (De Trey). F. An acrylic palate plate has been placed on top of the Visco-gel and fixed with transalveolar sutures.

In 1978 Gunnar Jonsson and Sten Stenström of the University of Umeå, Sweden, presented further confirmation of this approach. They studied 6 to 8 week old beagle puppies in which the hard palate bone and the covering oral mucoperiosteum had been removed, except for a 4 mm. wide strip of bone in the midline. On one side the nasal mucoperiosteum was covered with an autogenous full-thickness skin graft (SGS) while the other side was left raw (RS). At 47 to 52 weeks of age the dogs were sacrificed.

The palatine suture was displaced towards side RS on all dogs, and the height of the nose was in all dogs greater on side SGS. There was a small consistent tendency that the overall growth was more pronounced on the side with the full-thickness skin graft. It is concluded that reducing the amount of scar tissue by covering raw surfaces with an autogenous full-thickness skin graft is one way to reduce maxillary growth impairment after palatal surgery.


In what could possibly be interpreted as an indirect, partial endorsement of his Swedish colleague's effort to cover the raw surface of the vomerine flap, Johanson, with Hans Friede of Göteborg, wrote in 1977:

The development of the face and jaws in cleft patients, treated with a three-stage surgical procedure including a single layer vomer flap, was studied by analysing cephalometric radiographs and dental casts. The

material consisted of 13 patients with complete bilateral cleft lip and palate and 50 cases with complete unilateral cleft lip and palate, operated on 1964-1970. At the follow-up the average patient in both cleft categories demonstrated a maxillary retrognathia and in the unilateral cleft sample also a facial skeletal profile straighter than normal, though not as pronounced as we had found in cases where the vomer flap procedure was accompanied by bone grafting. However, the mean profile for the bilateral as well as the unilateral cleft group was straighter than reported for patients subjected to neither vomer flap nor bone grafting. The occlusal findings confirmed the maxillary growth retardation. . . . In an effort to reduce the restricted mid-facial growth found in the present patients, we have changed our surgical technique and since 1975 exclude the use of vomer flaps.

NEED FOR TWO-LAYER CLOSURE

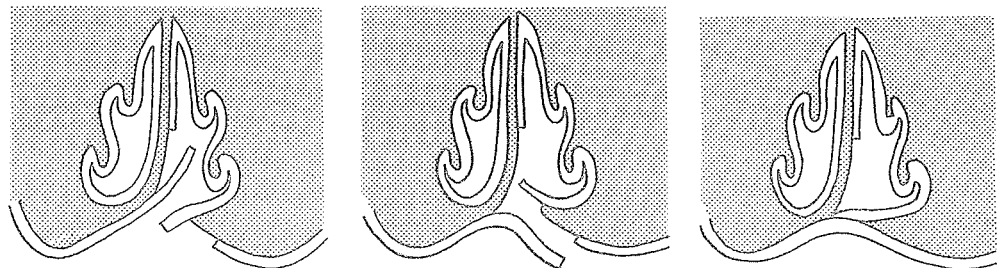
The classic lip closure is done at about 3 months of age. When the clefts of the alveolus and anterior palate are closed at the same time with one-layer closure, faulty molding of the maxillary segment not infrequently results, with the premaxilla impinging on the collapsed lateral segments. Thus, surgeons have devised methods of accomplishing a two-layer closure of the anterior palate cleft.



Andrew Campbell

CAMPBELL

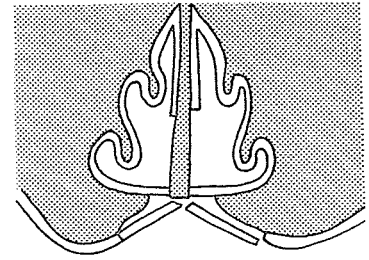
Andrew Campbell of Johannesburg, South Africa, in 1926 tried closure of the alveolar and hard palate cleft with a septal flap, but the cartilage became detached and he then modified his plan and designed a two-stage closure. One flap took mucoperiosteum from the septum with the base on the palate; the other took mucoperiosteum from the cleft side of the palate based toward the nose. These flaps were overlapped across the cleft, bringing raw surface to raw surface with a broad plane of union and leaving no raw area in the mouth or nasal floor and no reason for contracture.



As Campbell said:

So far we have found that the raw surface on the septum is of little consequence. . . . There is no tendency to sloughing of the septal cartilage, and this is not surprising because of the excellent blood-supply from the opposite side. . . . If one deals with a bilateral cleft, the same operation is done on the other side but it is wise to wait until the raw surface on the septum is entirely healed—from four to six weeks.

This principle is the basis of several modern German and American anterior cleft closures.



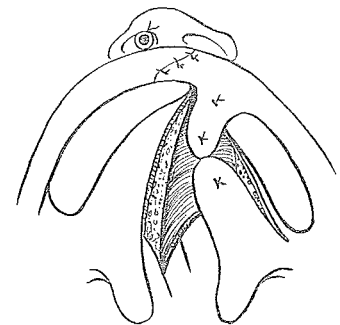
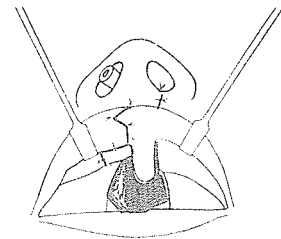
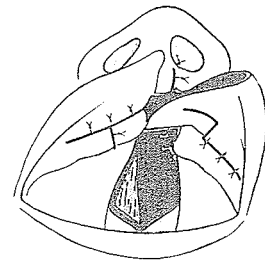
BURIAN

In 1955 at the International Congress in Stockholm, Professor Francis Burian of Charles University, Prague, Czechoslovakia, described an upper buccal sulcus flap to aid in the two-layer closure of the alveolar cleft. He stated:

Severe cases of cleft-lip ought to be operated on later than lesser ones, the more so if greater deficiencies are present. The earliest date ought to be the fourth month of life.

His ideas after 30 years and 3,000 cases are of interest:

With severe cases of complete cleft it is not advisable to bring the poles of the cleft together. On the contrary, prevention of contact seems to be indicated. In 1933 I started to put a flap of lip mucosa between the poles of the cleft as a covering for the oral aspect of the reconstructed floor of the nostril. It was designed at that time as a method of preventing perforations in the anterior part of the palate which were of frequent occurrence in the Veau operation. I dropped this interposition-operation after discussion with Veau, who considered the gap in the alveolar process as an imperfection much worse than a naso-buccal communication. Later on when observing the operated patients I was impressed that on those operated by the interposition method, . . . there was much less deformation, . . . except for the premolar segment of the jaw. . . . [Thus] I resumed a modified interposition method with severe total clefts . . . omit[ting] the formation of the palatinal flap and insert[ing] the vomerian flap as advised by Campbell.



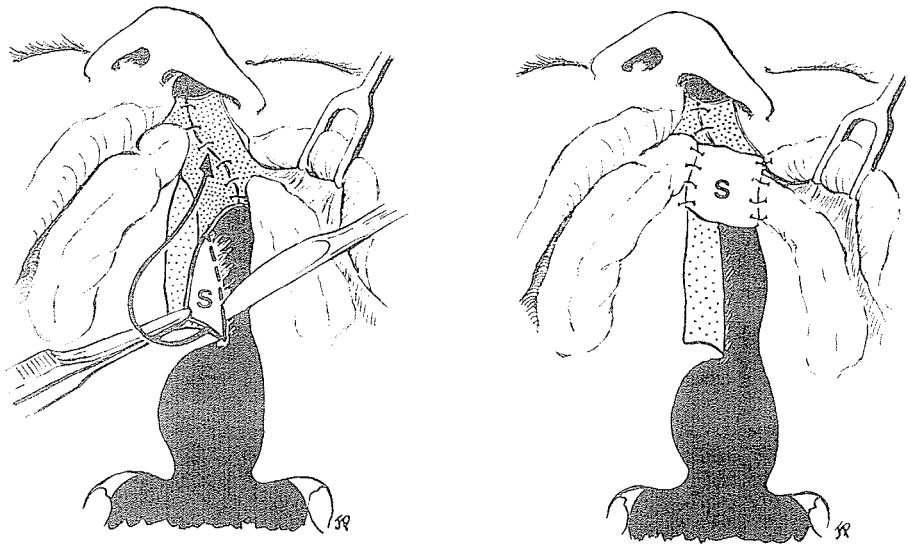
anyway, the lip usually should not be asked to give up this mucosa..

In 1976, M. Hotz of Zurich noted:

However, alveolar closure with Burian flaps (consisting of a small muco-periosteal flap and a larger vestibular mucosal flap) at the time of lip closure seems to affect canine position. Burian flaps were utilized in about half of the present cases of unilateral as well as bilateral clefts. Each one of these patients shows a canine cross-bite. Therefore, this particular variation of procedure was abandoned a few years ago.

STELLMACH

In 1959 the astute Rudolf Stellmach of Berlin, considering mucosa from the upper lip inadequate for closure of the oral layer of the alveolar defect, developed a vomerine flap based anteriorly. This flap was turned 180 degrees to achieve oral closure for the usual nasal flap and an intervening bone graft.



In 1977 Stellmach reminisced:

Around the mid-fifties when we began to bonegraft the alveolar gap primarily in total clefts, we used a flap of lip mucosa for covering the oral aspect of the implanted bone. Flaps of this type, aimed at safe double layer closure of the postalveolar region, were described before by Burian (flap pedicle medial) and by Trauner (flap pedicle lateral). In using this with bone grafting I often found the vestibulum lining diminished, causing some inward traction of the lip. As we had discontinued closure of the hard palate, this brought me to the idea of covering the bone graft with vomer lining from behind. The vomer flap has an ideal quality for this purpose as it is thick and contains periosteum. When incised high at its cranial base

right!

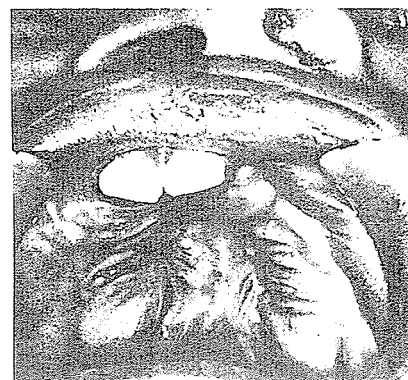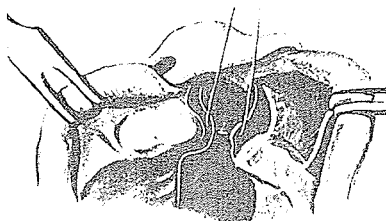
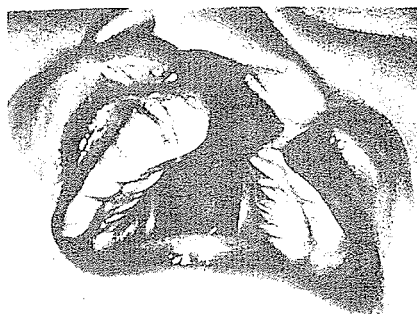from back to front it can be turned forward. A pouch is created within the alveolars which can be filled up by bone chips. Shortcomings from lack of lip mucosa could be prevented.

STEINHARDT

Gerhardt Steinhardt of the University of Erlangen-Nürnberg, Germany, in his 1973 book with Schuchardt and Schwenger showed again his method of two-layer closure of the alveolar defect. He employed a Pichler-type vomer flap for nasal closure and then cut a rather radical alveolar mucoperiosteal flap based above which he used to overlap his nasal closure as a second layer.



Gerhardt Steinhardt



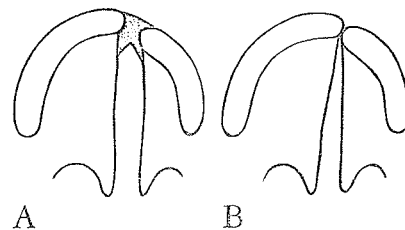
MUIR'S MUCOSAL FLAP

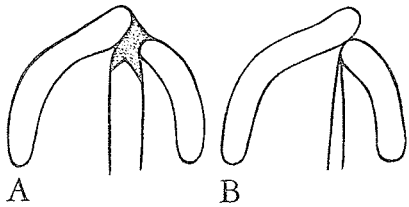
Ian F. K. Muir, a discerning Scotsman, is consultant in Aberdeen. While at Mount Vernon Centre for Plastic Surgery, England, he made several interesting observations and proposed an ingenious solution to the problem of the raw area in the alveolar closure. In the January 1966 *British Journal of Plastic Surgery*, Muir noted that in some babies with unilateral complete clefts the maxillary segments are in good alignment, and, after standard lip and anterior palate closure, end-to-end abutment of the alveolar segments occurs with good arch shape and dental occlusion.

In other newborn babies the premaxillary portion of the non-cleft segment is rotated away from the cleft, and subsequent medial movement of the lesser segment brings it in behind the premaxilla so that the arch is more triangular than the normal



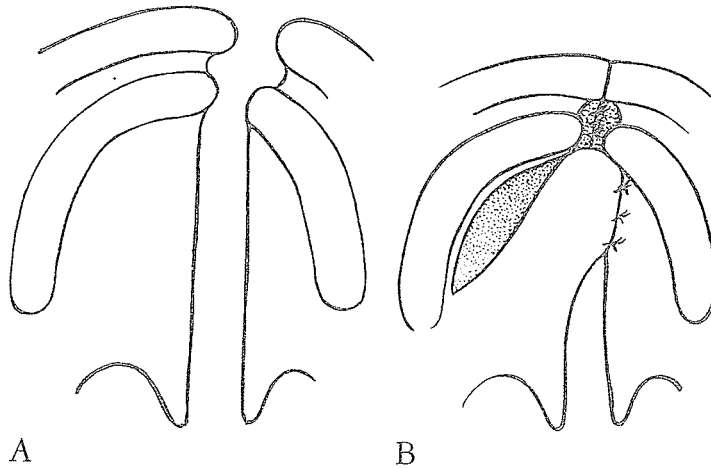
Ian Muir



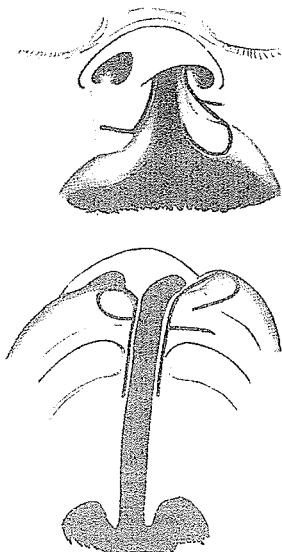


horseshoe shape. The cause of this collapse has been attributed to the tension of lip closure. Muir analyzed the circumstances and laid the blame elsewhere:

The cleft in the alveolar gap . . . is usually closed by a single nasal layer leaving, on the buccal aspect, a raw surface . . . up to 1 cm. wide . . . [which] is . . . left to granulate, and finally to heal by secondary epithelialisation. This process takes place rapidly (although sometimes a breakdown occurs and a fistula is left), but must inevitably be accompanied by the formation of scar tissue . . . [and] results in the rapid in-drawing of the lesser alveolar segment.



In a complete cleft of the lip and palate there is a raw area left during a standard closure, as the Veau flap will not reach forward between the alveolar ends. Muir concluded that if the raw area could be eliminated its harmful effects would be minimized. He then proposed a flap for this purpose that could be better spared than the Burian buccal flap. True to the frugal Scots character, he noted:

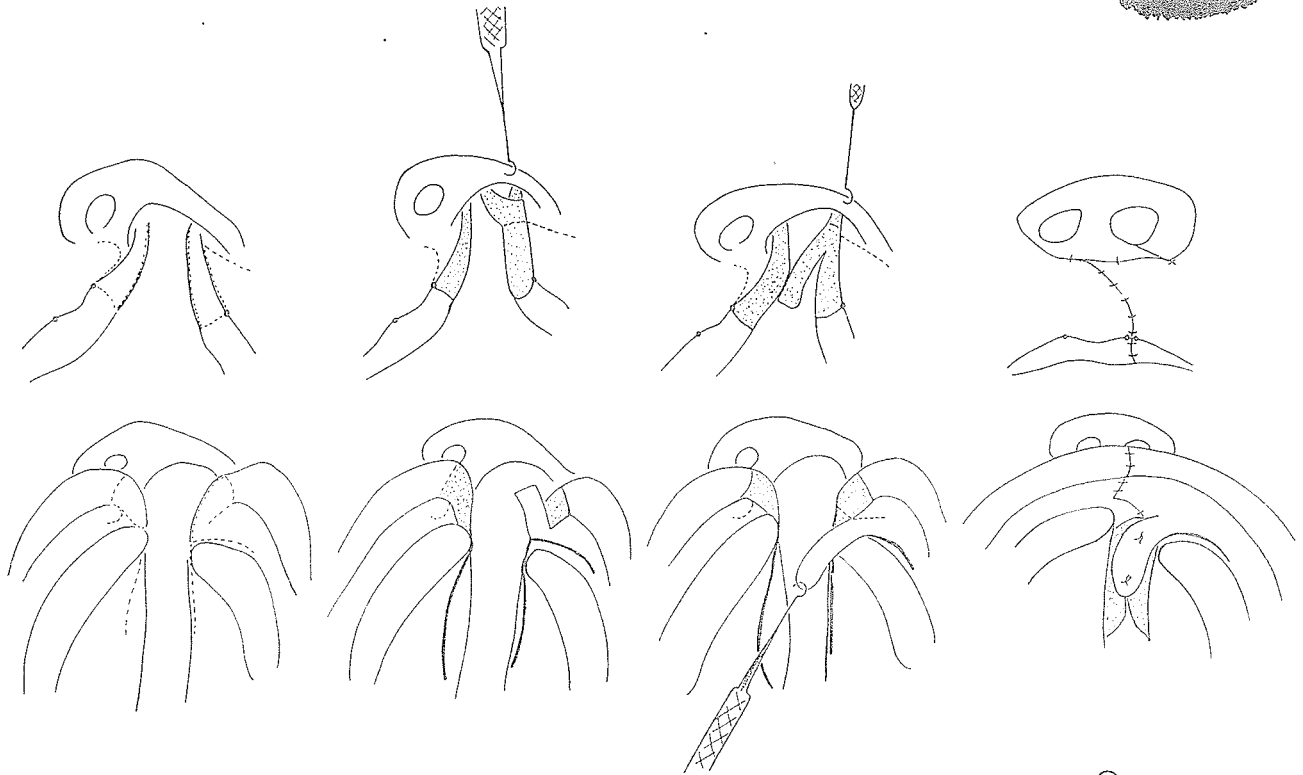
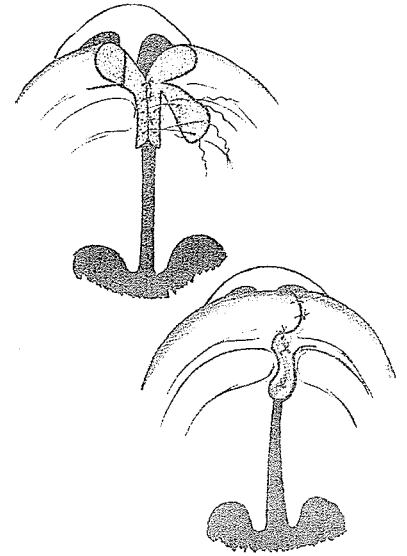


There is, however, a source of tissue which appears not to have been tapped, namely the mucosa of the free edge of the lip which is usually discarded at operation. This tissue can be retained and used as a soft tissue flap to provide a buccal layer for the repair of the alveolar cleft. In practice the tissue from the lateral edge of the cleft lip has proved most suitable. This tissue can be dissected up to a narrow base on the buccal aspect of the lip, and turned back into the cleft where it can be held by two "A" stitches.

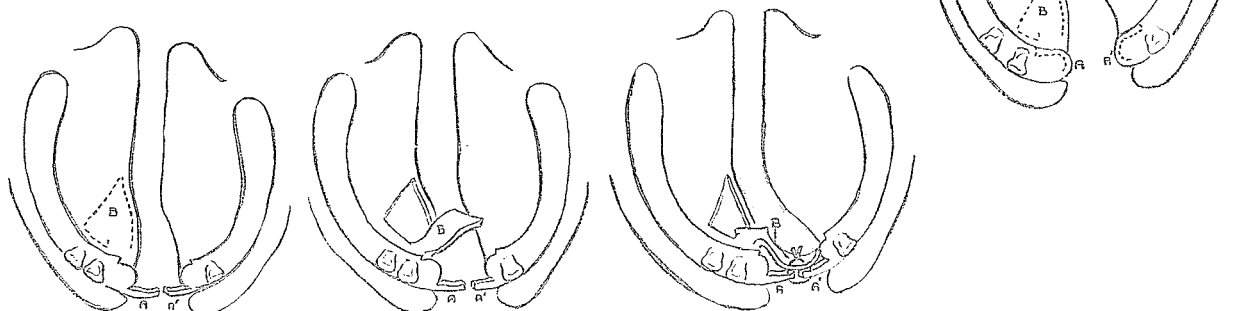
Muir reported no fistulae and no alveolar collapse following this technique. Yet the presence of a lined gap in the alveolar area

presented two problems. There was some difficulty in hard palate closure across a persistently wider cleft, and some patients showed a substantial deficit of alveolar bone. With both cover and lining available, Muir proposed combining closure of the lip with rib bone grafting to the alveolar area.

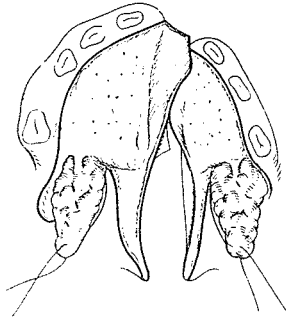
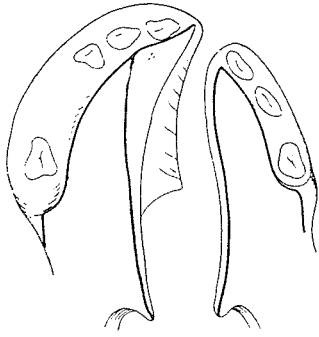
Since the use of his flap was originally incorporated in a Tennison lip design, it was hoped that by 1974 he would have changed to the rotation-advancement approach and indeed he had! He kindly sent me more modern diagrams showing his flap during a rotation-advancement lip operation achieving a two-layer alveolar closure.



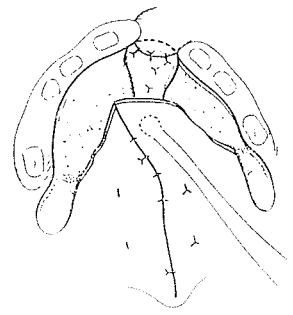
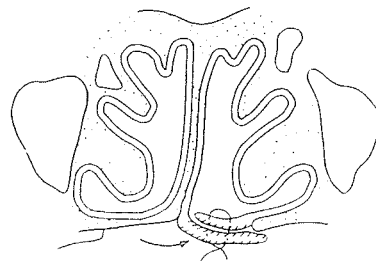
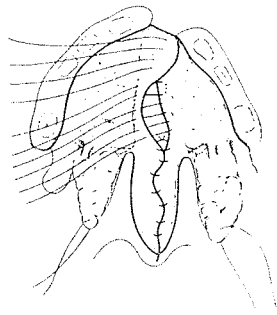
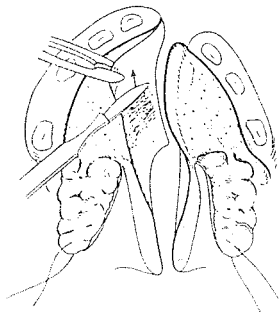
D. H. Walker of Johannesburg, reveling in freedom because, as he said, "consistency is a virtue of small minds," devised another variation of the two-layer closure of the "gap in the gum."



OVERLAPPING THE ANTERIOR FLAP CLOSURE



Nobuhiko Isshiki and Masanori Morimoto of the Otorhinolaryngology Department of Kyoto University designed a reinforcement of the anterior nasal closure of unilateral clefts, reported in 1968 in *Plastic and Reconstructive Surgery*. The V-Y mucoperiosteal flaps were cut narrower than those designed by Ganzer, Ernst, Veau, Wardill or Kilner. Then a wider mucosal flap was freed from the vomer on one side and the standard flap from the hard palate on the other, presenting enough excess for an overlap anteriorly. The mucosa of the flap on the vomer side was shaved raw for adhesion in the overlapping, which was fixed with sutures. The V-Y mucoperiosteal flaps covered the posterior area, and a labial mucosal flap covered the anterior extent of the cleft.



The development of various two-layer closures of the alveolar defect was destined to be of inestimable value during the alveolar bone grafting era.

It is interesting that two relatively new principles in the early treatment of alveolar clefts, *presurgical orthodontics* and *free bone grafting*, were evolved in different centers at about the same time and eventually were adopted for use in conjunction with each other in many more centers. As orthodontic manipulation was originally designed to aid the surgery by positioning the maxillary segments for bone graft stabilization, this aspect will be presented first.