

11. Uranoplasty, Bone Flap and Osteotomies

FIRST URANOPLASTY

PALATE operations had been limited to single clefts of the velum until 1827 when Dieffenbach introduced his operation for uranoplasty or closure of the hard palate. His thoughts in 1826, as translated by Schmid, are of interest:

Several attempts to surgically close the bony gap with the soft cover of the palate have been unsuccessful. However, it might be possible by an operation on the bone of the palate to approximate the bones to one another and thus also the margins of the velum. After incising the soft cover, the palatine bones would have to be cut with a saw along the alveolar process in a curved line from the posterior margin in an anterior direction up . . . close to the cleft. After this, the freshened medial cleft margins would have to be pulled together by a gold or lead wire. The bone would have an adequate blood supply from its superior attachment; one could also expect later closure of the lateral opening, particularly if one provided some help to nature. After successful healing, suture of the palate would still have to be carried out.

Dieffenbach finally carried out his proposed osteal uranoplasty, demonstrating that his lateral mucosal incisions could be extended through the underlying bone with movement of both mucosa and bone toward the midline. First he punched a hole through the bone with a three-cornered awl on each side at a strategic position along the line of his usual relaxing incision. Then he passed a thick soft silver wire through these two holes, joined the ends across the cleft and began twisting. His lateral mucosal incisions were then made along the line where the palate



Johann Dieffenbach

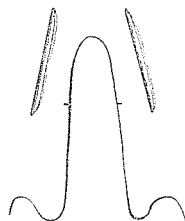
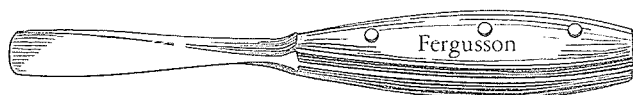
bone meets the alveolus. A smooth, thin, concave chisel was used to chop through the bone along this line. Dieffenbach explained:

The wires are then twisted again, till the edges of the bony cleft approach each other a little or together; the first alone can be generally done.

If he did not first succeed, he twisted again from time to time.

Wutzer, a Swiss, in 1834, and Buehring, a German, in 1850, both used this type of osteal uranoplasty. Loewenhardt combined it with staphylorrhaphy in 1857. Another German, von Langenbeck, although not too happy with osteal uranoplasty, in 1861 pointed out that the procedure should be limited to bilateral lip-jaw-palate clefts and was contraindicated for unilateral clefts in which the vomer was attached to one side of the defect.

By 1868 Billroth was discounting the procedure as no longer being practiced, but in 1873 Sir William Fergusson came back into the act with new vigor and his special osteotome.



He modified Dieffenbach's side incisions, placing them 0.25 inch from the border of the cleft using a chisel for the osteal uranoplasty. Finding that the bony fragments within the flaps became tilted, Sir William made perforations in the bone with a shoemaker's awl to hold the bone flaps together with sutures. In 1874 he combined soft palate and osteal uranoplasty in one operation.

Francis Mason improved on Fergusson's method by boring awl holes along the line destined for bone division. Then with the tap of a chisel the osteal uranoplasty was achieved without splintering. As Mason explained:

The procedure is extremely simple and may not be inaptly compared to the perforated edges of a postage stamp.

Evidently two gentlemen from Philadelphia, Roe and Mears, both did osteal uranoplasties in the late 1800's. By the early 1900's only two surgeons were using the bone flap method, G. V. I. Brown of Milwaukee and Warren B. Davis of Philadel-


phia. This operation has indeed enjoyed a rather discreet lineage, having been handed down almost selectively from teacher to teacher, each of whom, being a gentleman of the old school, always gave due credit to his mentor.

BROWN

In his 1918 book, *The Surgery of Oral Disease and Malformations*, George Van Ingen Brown, D.D.S. and M.D., of Milwaukee Children's Free Hospital wrote:

This method consists in sawing through the palate bones from behind forward, fracturing with forceps, and wiring in such a manner as to approximate the bone fragments sufficiently to bring the soft parts together. It was devised by Fergusson, and earnestly advocated for years by J. Ewing Mears of Philadelphia.

By 1922 Brown was using this method, pleased that it preserved the nerve and blood supply and did not require the severing of muscles which usually healed with shortening and inflexibility. He considered the bone flap method simpler and more certain of success and taught it to his students.




George Brown

HYSLOP

Volney B. Hyslop of Marquette University, Milwaukee, carried on Brown's teaching, used the bone flap and taught it to Sidney Wynn. In 1973 Wynn recalled:

Dr. Hyslop was one of the best intra-oral plastic men I ever knew. It galled him considerably when he heard about all the secondary surgery people were doing on palates as less than 5% of his bone flap cases ever had to have secondary surgery for speech improvement. He was very kindly and did a considerable amount of charity work in the days of the house case and clinic before the time of Title 19 and Medicare.



Volney Hyslop

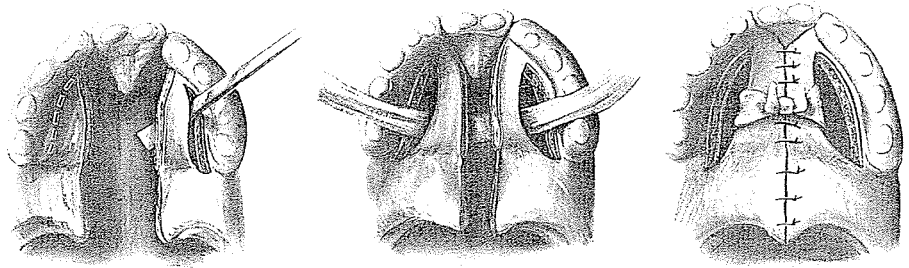
DAVIS

Warren B. Davis of Philadelphia, in 1928, advocated what a Frenchman named Lannelongue proposed in 1877: the combina-



Warren Davis

tion of osteal uranoplasty and the von Langenbeck procedure. In bilateral clefts of the jaw and palate he used the osteal uranoplasty, but in unilateral clefts he used an osteomucosal flap from the free side of the palate and a mucoperiosteal flap from the opposite side which was in connection with the vomer. In either case the resultant flaps were held together by a surrounding tape. Warren Davis acknowledged that William J. Roe taught him the bone flap method.



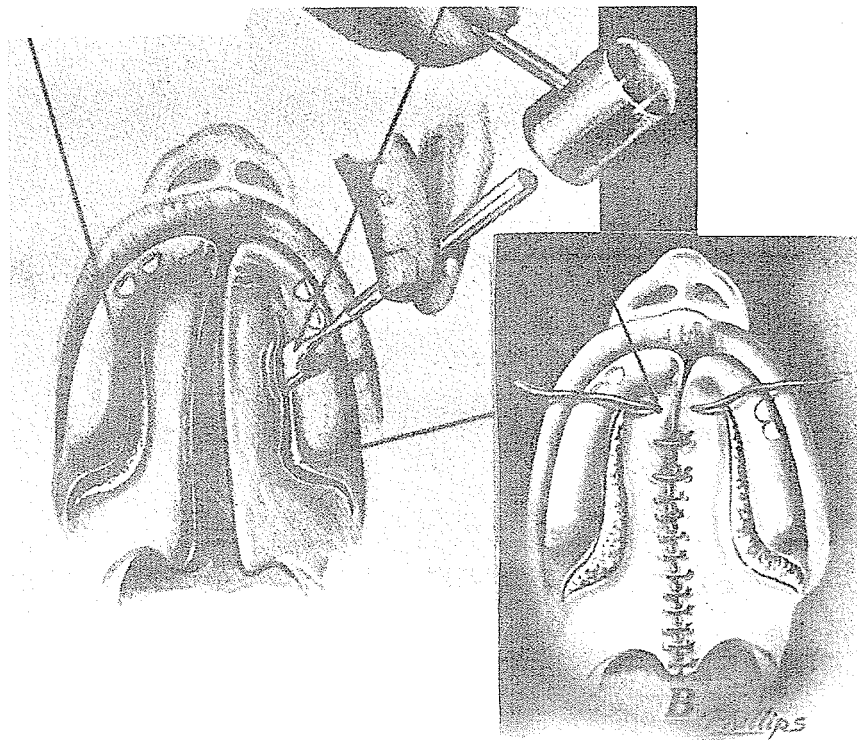
Lyndon Peer

PEER

In 1964 scholar and researcher Lyndon Peer reminisced 25 years back when Warren Davis invited him, along with Staige Davis, Kitlowski and Straatsma, to visit Jefferson Hospital. During the morning Davis performed seven one- and two-stage palate operations and in the afternoon presented cases. The speech results and the palatal appearance and function were so impressive that Peer used this operation from then on at St. Barnabas Medical Center in Orange, New Jersey. In starched white coat and with his resonant and carefully modulated voice, Peer recalled Davis as an exceptional, skillful cleft palate operator who with John [“Dermatome”] Reese as first assistant and some adrenalin packs could complete the first stage in three minutes and the second stage in twenty minutes.

In 1954 Peer of New Jersey, with Hagerty, Hoffmeister and Collito, gave his initial description of this two-stage method carried out two weeks apart. First, an incision was made through the mucoperiosteum in the lateral palate at the base of the alveolus. A chisel cut along this line, dividing the bone and nasal mucosa. At the second stage, the bony palatal shelves were fractured toward each other and the mucosa of thin cleft edges

was split so the halves could be approximated with 2-0 silk sutures passed through drill holes in the bone. In complete clefts the anterior fistula was closed at a third operation. Peer believed that this operation produced better speech than the von Langenbeck method.



Peer's conclusions in 1954 from his study of 133 bone flap cases did not acknowledge deleterious effects on the maxilla. He reported:

1. No fistulae in 113 cases.
2. A majority of patients with very minor retardation in the anteroposterior growth of the maxilla associated with underdevelopment of the mandible.
3. A smaller percentage with "pushed-in" faces with slight underdevelopment of the maxilla but overdevelopment of the mandible.
4. Crowding and crossbite.

Peer considered these deformities typical of the cleft palate and not related to surgical trauma, the bone flap operation or the age at surgery.

Ten years later, in 1964, Peer's report with Walker and Meijer still advocated the bone flap method, with 70 percent of the patients requiring speech therapy. For those who did not respond to therapy and whose palates were short, a full-thickness soft palate Z was used for lengthening. If even better velopharyngeal closure was required, a Moran type, superiorly based pharyngeal flap was added.

In 1971 Peer reviewed the advantages of the bone flap, emphasizing that

it duplicates what nature should have done, for by moving the bones together not only is bony union achieved across the cleft but bone replacement fills in the lateral gaps, which I have seen in hundreds of cases.

He admitted, however, that if he started with a short palate he ended up with a short palate and he could not compare his bone flap method with the von Langenbeck or the Wardill as he had had no experience with either.

right!

Stefan Demjen of Bratislava observed results in New Jersey of the bone flap operation carried out 8 to 10 years before by Lyndon Peer and reported:

The speech results are comparable to other methods presently used. There is no gross disturbance in maxillary growth.

HAGERTY

Bob Hagerty of Charleston, a student of Peer and one of the original authors of the early bone flap work, says today that he uses the bone flap technique in wide clefts and usually in older patients 14 and 15 years of age. He admits that some shortening of maxillary growth is seen but feels that this could be inherent lack from the original cleft deformity. Hagerty expresses more concern over the ill effects of dissecting mucoperiosteum off the bone than over osteotomies and fracturing of the maxillae.



Leo Clodius

CLODIUS

In the 1964 International Symposium on the Early Treatment of Cleft Lip and Palate held at the University of Zurich, historian and surgeon Leo Clodius stated his preference for the bone flap

method. Previously a student under Lyndon Peer in Newark, New Jersey, and representing a Swiss branch of the Peer part of the tree, he commented:

Closure of the palatal shelves and the soft palate is carried out between the 12th and 20th month before speech is started. The bone-flap technique originated by Dieffenbach is used. Unless the cleft is very narrow, this is a two-stage procedure, carried out two weeks apart. At the first operation the mucoperiosteal-osteal flaps are delayed, severing the palatal processes with the nasal mucous membrane from the palatal arch. This produces bilateral pedicle flaps. Their length is determined by extending relaxation incisions postero-laterally, as advocated by Ernst, to ensure tensionless palatal closure. At the second stage the flaps are united in the midline. A three-layer closure is performed for the nasal membrane, muscle and bone, and oral mucosa. The advantages of this method, which of course must be carried out carefully so as not to disturb the tooth buds, are as follows: there is minimal denuding of bone, the soft palate muscle attachment to the posterior bony palatal edge is left undisturbed and no raw surfaces leading to possible antero-posterior scar contractures producing velar rigidity result. A technically easy Z-plasty during the second stage may lengthen a congenitally short soft palate. A solid bony palate vault results. The resulting lateral defects are well healed at 10 days. . . . 70% of our patients are given speech therapy, many of these for minor speech defects.

W Y N N

Descendant of the Brown-Hyslop line and the most enthusiastic of them all, Sidney Wynn of Milwaukee Children's Hospital in 1959 described this method of osteotomy and suturing in one stage and defended its merit:

The bone flap technique provides a simple, relatively safe procedure which restores to the roof of the mouth a new bony vault as nature originally intended.

He further claimed:

Narrowing of the width of the palate is not secondary to early surgery on the palate if the bone flap technique is used.

He cited his work with Hyslop and Zwemer in 1956, which with study casts and cephalometric x-rays showed bone flap cases operated on between 9 and 18 months of age to have:



Sidney Wynn

1. Intermolar width between the first permanent molars within normal limits. . . .
2. The first permanent molars on the side of the cleft in the medial version or Class II relationship.
3. The teeth anterior to the first permanent molar on the side of the cleft in lingual crossbite relation.
4. The incisor teeth in both segments in lingual crossbite in a number of patients.
5. The teeth next to the cleft rotated and tipped toward the cleft.

Wynn continued his defense with:

The anterior crossbite is indicative of the rotation of the bony segments by labial muscular action of the repaired lip and is not due to the growth disturbance subsequent to the palate repair. . . . There is no broad surface scarring over the palate bone as there might be with a von Langenbeck mucoperiosteal type of procedure to interfere with the growth of the palate bones.

Then he went on to claim that not only is there no perceptible shortening of the soft palate but

In fact, it appears that the palate becomes lengthened following bone flap movement toward the midline.

Speech studies by experts such as Leutenegger and Demeter of small samples of postadolescents suggested that speech results following the bone flap method were as good as or better than those achieved with other methods. As noted by Wynn:

From 1936 through 1970 a total of 730 bone-flap operations were counted as having been performed at Milwaukee Children's Hospital. . . . Only nine pharyngeal flap operations were performed on patients who had [a bone-flap] procedure and whose velopharyngeal insufficiency appeared to warrant it.

"Blind" studies by Pionek of the bone flap method compared with other techniques using measurements taken on roentgenographic cephalograms revealed growth and development to be good, with the gonial angle more normal after bone flaps and increased to an obtuse angle after mucoperiosteal flaps. As Ross observed, cleft individuals with severely collapsed superior maxillae exhibited an increased gonial angle. It was postulated that

the higher vault following the bone flap method provided the unsuspected advantage of more room for the tongue. In 1970 Miller and Wynn reported that children with bone flap surgery had better hearing than those with other types of palate surgery and explained it on the basis of maintenance of better control of musculature essential for good Eustachian tube closure.

Finally, in 1976 Sidney Wynn repeated the advantages of the bone flap method but referred to it as "bilateral osteotomy cleft palate surgery," justifying this change in name after 30 years to avoid confusion with earlier bone flap methods. He explained:

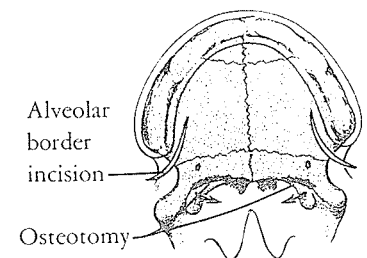
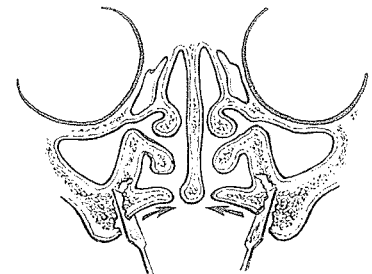
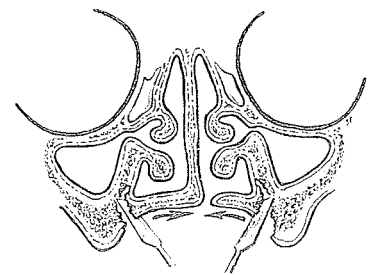
Our method should not be confused with the earlier procedures described by Dieffenbach, Warren Davis, G. V. I. Brown, and Peer. They actually divided the bone laterally, entirely through the nasal side of the palate, to produce a true bipediced osteoperiosteal flap.

His description of certain advantages of the bilateral osteotomy method deserves consideration.

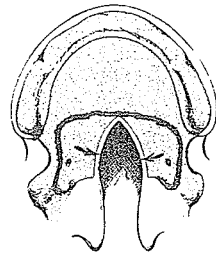
It consists of simple osteotomy wedging of the bone posteromedially leaving all nasal mucosa intact so actually a three-sided rather than a bipedicle-type flap is involved. The soft palate musculature is left attached completely to the bone and the hard palate is not subjected to mucoperiosteal elevation . . . yet when an osteotomy incision is made into a bone, an actual regrowth of bone may take place such as occurs in a fracture site. . . . Bone fill-in happens rapidly . . . Dr. Walter Blount, eminent Milwaukee orthopedic surgeon, has reported that bone deposition has been observed when osteotomies of the bone flap of the pelvis are done in cases of dysplasia of the acetabulum. He stated, "the younger the infant, the more rapidly the bone fills in. This does not produce growth or bone developmental deformity and at times may even produce some bone growth."

Confident that it is safe to do the bilateral osteotomy palate closure as "early as 9 months with good results," Wynn presented his various osteotomies and made statements that warm the cockles of the hearts of surgeons and speech therapists while constricting the orthodontists' coronaries:

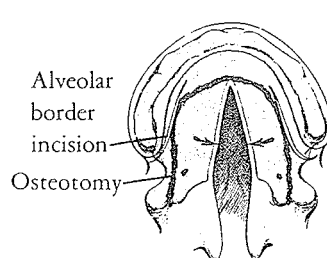
This over-emphasis on simplicity and trauma minimization to assist the maxillary growth, while completely overlooking the early speech results in a child's psychologically formative years, seems to demonstrate inappropriate priorities. . . . Ortiz-Monasterio et al [1974] have reported that palatal



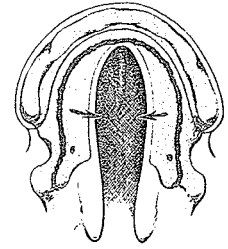
1. Minor soft palate defect or submucous cleft palate. Hamulus osteotomy only



2. Incomplete cleft palate
Small bone defect
Osteotomy into notch



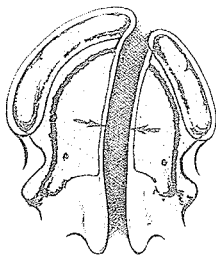
3. Incomplete V-shaped cleft palate
Osteotomy to anterior notch



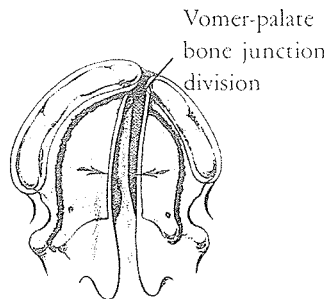
4. Incomplete horseshoe cleft palate
Osteotomy to tip of notch

closure may often be unsuccessful in the older child as compared to what can be accomplished in younger children. . . . Early bilateral osteotomy in cleft palates also encourages more normal physiologic patterns both from the standpoint of speech and development by repositioning and restructuring the palate in the manner that nature originally intended.

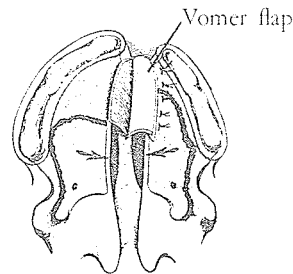
The surgical technique is carried out through lateral mucoperiosteal incisions inside the alveolar area, starting behind the tuberosity and extending forward three-quarters of the length of the hard palate. The chisel osteotomy divides the hamular process off the perpendicular plate and extends forward as outlined in all types of palate clefts.



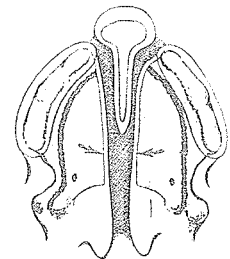
5. Complete unilateral cleft palate
Osteotomy hamulus to anterior



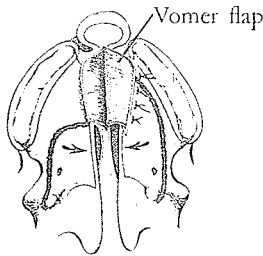
6. Complete unilateral-firm vomer attachment
Divide vomer-palate junction prior to osteotomy



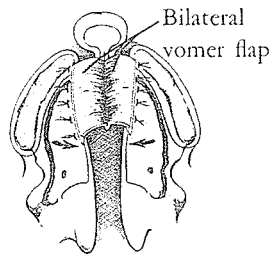
7. Complete unilateral-wide type vomer flap prior to osteotomy
Osteotomy on attached side to posterior vomer



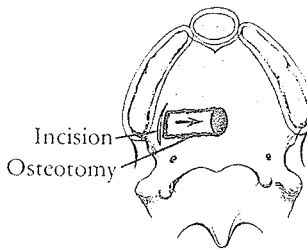
8. Bilateral cleft palate-narrow with free vomer
Osteotomy hamulus to anterior



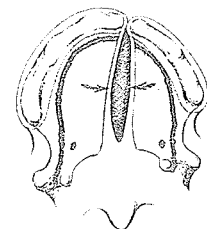
9. Bilateral cleft palate
Unilateral vomer attachment
Vomer flap prior to osteotomy



10. Bilateral wide complete cleft palate
Free-floating vomer
Bilateral vomer flap prior to complete osteotomy



11. Central palate fistula
Use localized osteotomy
Avoid wide mucoperiosteal elevation



12. Anterior palate defect following simple soft palate closure
Bilateral osteotomy to avoid wide mucoperiosteal elevation

The edges of the cleft are stripped of mucosa and freed from the bone for a depth of 2 mm. to ease suturing. No attempt is made at suturing the bone, and packs of Furacin are inserted into the osteotomy sites for five days to relieve tension and control bleeding.

Upon removal of the packs, the large defects fill with granulation tissue in three to five days and are re-epithelialized by mucous membrane after two weeks.

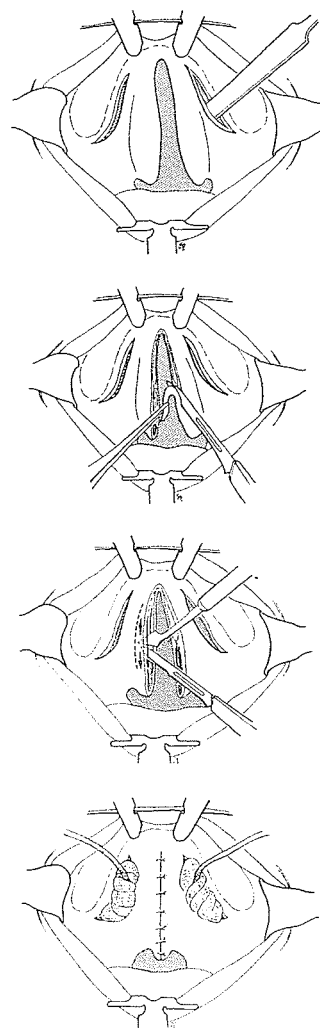
Wynn noted:

Experience has taught us that in very wide (1.5 cm. anterior plus) single and bilateral complete cleft cases, it is easier and probably wiser to precede the osteotomy technique by a single vomer flap technique, as described by Dunn in 1952 [which according to Stenström in 1974 causes minimal maxillary growth interference]. In many cases, the bilateral osteotomy operation can then be used to close the remaining palate at the same operative procedure.

Wynn's conclusions were enthusiastic as he claimed the following as benefits of the bilateral osteotomy method:

1. Reconstruction of the bony vault of the cleft palate. A photograph of an x-ray showed lateral bone fill-in in the osteotomy sites.
2. A soft, flexible and mobile soft palate.
3. Maximum function of the Eustachian tube, as their audiology studies demonstrated 10.6 dB better hearing levels than in children with cleft palate closed by mucoperiosteal dissection methods.
4. Adequate maxillary-mandibular posterior occlusal dental relationship.
5. Vertical and horizontal development of the maxilla comparable to an unoperated cleft sample (McGowan).
6. A high percentage of good speech and voice results.

In spite of the experience of 30 years and 730 cases with what was referred to as "minimal complications," only the nine years from 1966 to 1975 were studied, and out of 298 palate cases only 93 survived the various cuts. The operations had been performed by either V. B. Hyslop, S. K. Wynn or W. Wiviott. Of the 93, 88.2 percent had adequate palatopharyngeal functioning for speech and voice quality purposes. Eleven percent had hypernasal speech related to velopharyngeal incompetence which required secondary surgery; 19.4 percent demonstrated speech and voice deviations unrelated to palatal functioning since they had normal cinephonation findings and were stimulable for normal speech



and quality with speech therapy; 68 percent presented *normal* vocal quality.

This closure makes no effort to correct malposition of muscle insertions by division and repositioning. Wynn defends the omission:

The muscles of the velum are not cut across and therefore a longer, more mobile palate is obtained. . . . Thus, the entire palatal bone with all of its muscular attachments moves in a posterior direction giving length to the palate. . . . Broomhead demonstrated some years ago that there is a nerve supply which comes through the aponeurosis of the palate. This of course would be disturbed if division of the posterior border of the palate bones from the musculature was done. . . . Recent work by Fisher and Mulliken and Kaplan [all in 1975] of the levator muscle repositioning, retrodisplacement and reattachment I think should be reserved for secondary speech problem cases or those who have had intact bony palates with velopharyngeal insufficiency.

*Of course,
Mr. Braithwaite
scooped them
all by 20 years!*

In 1978 in Hollywood, Florida, Wynn with K. L. Lynch reported gross, radiographic and microscopic studies of hard palate osteotomy sites at 7 days and at 12 months postoperatively. They reported:

The findings showed that successful osteotomy in infant cleft palate surgery translocates autogenous fibrous bone and osteogenic cells into a cleft bridging position. Rapid healing and bone formation bridges the cleft with woven fibrous bone initially, and then matures by lamellar bone replacement and Haversian system remodeling. Both the normal palate and the cleft palate have a rich anastomosis of microscopic blood supply that is vitally important in the remodeling process. These facts may help to explain long-term successful results in early cleft palate osteotomy surgery.