

7. Preoperative and Postoperative Care, Including Feeding

PREPARATION FOR SURGERY

AS I noted in the *Nursing Clinics of North America* in 1967,

The patient should be relatively free of upper respiratory infection and possess a hemoglobin level of at least 10 Gm. He should be prepared for a postoperative routine by being fed with a spoon, cup or the Asepto syringe by various people using a good variety of liquids. Two weeks prior to the palate surgery, the mother can use a white cap and gown to prepare the child for hospital nurses [MacCollum].

In the older children and adults, in whom bleeding can be more extensive, a type and crossmatching for 500 ml. of blood is advisable, but seldom used.

POSTOPERATIVE CARE

Again as remarked in 1967,

It is important to remember that this baby has been used to breathing with a hole in the roof of his mouth. After surgery, this hole is closed and a new pattern of breathing is now necessary. The adjustment may not come easily. In addition, there may be some oozing of blood from the operative site. The baby should lie face down and suction should be available at bedside with alert nursing attendance for several days, particularly in the first ten hours.

Here again elbow restraints are applied to prevent the patient from inadvertently disrupting the healing palate. These restraints are maintained three weeks at home with short periods of controlled freedom. Because of

unavoidable and continuous contamination, a systemic antibiotic may be used for three to five days postoperatively.

With the aid of the Asepto syringe or cup, the baby is fed liquids the first two weeks following surgery. Each feeding is followed by a drink of water which serves as a mouthwash. During the next two weeks the baby receives a soupy diet. At one month, a regular diet excluding hard food such as toast and rock candy is begun. No straws are allowed for a couple of months from the time of surgery.

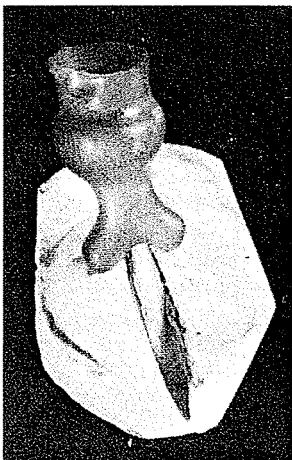MORE DETAILS ON FEEDING

As an intern at Boston Children's Medical Center, I learned from Donald MacCollum the trick of using a special feeding technique for cleft patients. As described in 1967,

The baby is held in the nurse's arm with his head held upright in her left hand. Formula is fed by bulb compression through a 10cc Asepto syringe with a 1½ inch rubber catheter extension. The catheter is slipped over the baby's tongue and the formula is fed as the baby is able to take it. As soon as the baby has adjusted to this routine the mother is instructed in the technique. Once mother and baby are prepared by the nurse, they are allowed to go home.

THE BIFID NIPPLE

Kenneth Adisman of New York University has a 1957 patent on a Dow-Corning Company Silastic bifid cleft palate nipple designed for the infant whose sucking reflex is absent or minimal. As noted in *Cleft Lip and Palate*:



The liquid flows from the bifid nipple in a stream through openings directed laterally against the cheeks. The flared teat head, which serves to partially close the cleft opening, is compressed by tongue action against the maxillary process, expelling the liquid from the nipple. This bifid type of nipple construction enables these infants to suckle while in the usual feeding position without fluid entering the nasal cavity through the cleft opening. . . . The nipple is made in two sizes to conform to different shaped maxillary processes. The nipples may be provided with suitable venting means which will allow air to trickle into the bottle as liquid is withdrawn . . . thereby reduc[ing] the suction requirements for a satisfactory flow of liquid.

A NEW SQUIRT

Here are Betty Jane McWilliams' thoughts on cleft palate feeding:

It is perfectly true that the babies usually do not gain as well as would be hoped if the mothers are left completely alone to develop a feeding plan by a trial-and-error method. Unfortunately, we reluctantly conclude that very little assistance is provided in the average new-born nursery and that the nurses are often quite uncomfortable about feeding the infants and about providing instructions to new mothers.

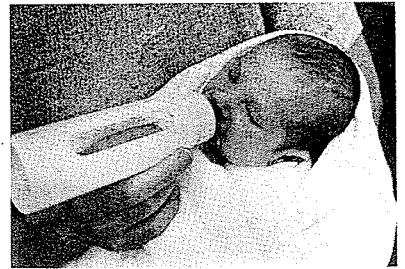
We were using a more complicated feeding system until one evening at a tiny neighborhood drugstore I picked up an Evenflo disposable nurser, plastic bags, and nipples, took them home and experimented. Next morning, Pediatrician Paradise was teaching a mother our old technique. I squirted him with the new bottle; he took it, tried it, and turned to the mother and said:

"Forget everything I've said. We'll use this," and we have ever since.

The system that we found successful for most babies with clefts is very simple indeed:

1. Hold the baby in a sitting position.
2. Use a plastic shell with openings in the sides and with no bottom.
3. Use disposable bags to hold the formula.
4. In the beginning, use a nipple for premature infants.
5. Be sure that the opening is a cross-cut. Never enlarge the hole. The cross-cut permits the milk to flow but also provides a good mechanism for preventing the milk from gushing into the baby's mouth and causing him distress.
6. The mother should learn to insert her fingers into the side slots and the bottom opening so that she can gently express the milk into the baby's mouth—being careful not to provide more help than the infant needs.
7. Burp the child frequently.
8. Attempt to complete the average feeding in no more than a half hour.
9. Follow a normal schedule for the introduction of solids including finger and table foods.

Evenflo disposable nursers (a) are not on the market now but may be ordered in quantities from Questor Juvenile Products, Ravenna, Ohio. In addition, Playtex nursers (b) may be used quite well by enlarging the slots of the sides so that a finger may be inserted. Both of these techniques permit the mother to use equipment that does not look "special" and that is much cheaper than are many of the special devices.



It has always been my feeling that well-planned, careful surgery and simple, practical postoperative precautions as noted are sufficient to achieve a well-healed palate. When in 1971 Sam Pruzansky wrote his approval of *Cleft Craft*, Volume I, he expressed disappointment in the chapter "Postoperative Care," mentioning that his wife, Donna, was an expert in this area. Although our babies were healing and gaining weight, long ago I learned to heed Sam's cry!



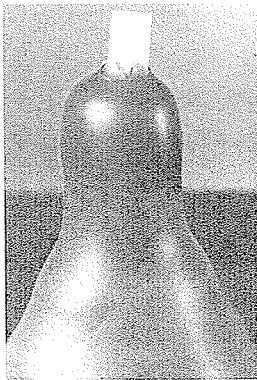
Donna Pruzansky

For 10 years Donna Pruzansky at the Abraham Lincoln School of Medicine, Chicago, had been involved in a nursing outreach program which arranged for

the visiting nurse, trained in the comprehensive needs of the child with an oral-facial cleft, to play an important role in crisis intervention by preventing potential feeding problems and assuring adequate nutritional intake during the critical neonatal period. This entails instruction of the parents, the hospital staff, and follow-up contact with the mother, and including home visits where required.

These were some of her suggestions:

Only minor modifications of the usual techniques used in bottle feeding are required to feed most CLP babies. To begin with, either a premie nipple or a lamb's nipple (DAVOL, Inc., Providence, R.I.) is preferred. The lamb's nipple is necessary in the case of a wide unilateral cleft lip and palate since the broad nipple will not slip into the cleft, thus allowing the infant to bite down against the alveolus and use the tongue to strip the milk from the nipple. This process obviates the need for feeding obturators.



The opening should be enlarged to facilitate flow. To do this, the nipple is turned inside out and a cross-cut is made with a scalpel or razor blade. Enlarging the opening in this manner, rather than merely enlarging the diameter of the hole in the nipple, allows the infant to control the flow of milk. This permits coordination of sucking, swallowing, and breathing and establishment of a normal feeding pattern. Adequate flow is critical to avoid unduly prolonged feeding periods which will exhaust the infant before he can complete sufficient intake. In contrast, nipple openings enlarged by poking holes with a hot needle result in flooding the infant with milk and necessitate a continuous insertion and withdrawal of the nipple to allow the baby to breathe.

There is no need to hold the infant upright, aim the milk at the cheek, or burp more frequently, as is so often advised in manuals for parents.

Helpful Hints

Since the lamb's nipple does not fit onto conventional bottles with screw tops, it is necessary to improvise. A most effective arrangement is to cut the base from a conventional nipple and use it as an adapter.

The anxiety engendered by the malformation often discourages the mother from breast feeding. In our experience, successful breast feeding is contingent upon a number of variables that include the type and severity of the cleft and the dedication of the mother. Previous experience helps. Even then, it requires a longer period of time for each feeding.


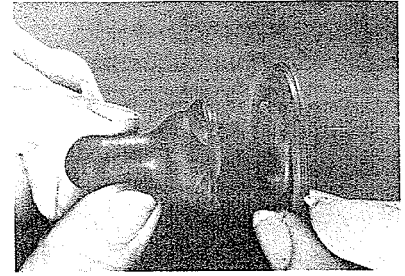
The problem of feeding an infant with a cleft is complicated by the Robin syndrome where the maintenance of an adequate airway is compromised by the micrognathia and glossoptosis. The introduction of the nipple and milk further aggravates the problem.

Depending upon the severity of the condition, bottle feeding may be possible with certain modifications in posturing to maximize the airway. This can be achieved in some instances by holding the infant in an upright position with manual assistance to guide the mandible forward.

Feeding can be accomplished with the infant in the prone position on the nurse's lap with head extended. For the severely compromised Robin syndrome, nasogastric feedings may be required.

Although the foregoing is limited to the neonatal period, parents can be assured that baby foods and table foods can be introduced to the CLP baby at the same age as for the non-cleft child.

It is an obvious but often overlooked fact that the baby with a cleft is first of all a baby. Like all babies, they may spit up, have allergies and a myriad of other problems unrelated to the cleft. Therefore, when problems do arise, it is important to examine the whole child and not focus only on the cleft.



Lamb's nipple

