

6. *Anesthesia in Clefts* (*Gas, Tubes and Gags*)

WITH SECTIONS BY S. MACMAHON
AND A. FREEMAN

ANESTHESIA IN CLEFT LIP

IN ancient times cleft lip was treated by pinning of the pared edges, which never took more than a minute or two. When dentist William Thomas Green Morton introduced general anesthesia in 1846 at the Massachusetts General Hospital, Boston, it was soon used for these quick lip closures. John Snow reported giving ether for a lip repair in 1847 and by the time of his death in 1858 had administered chloroform 147 times for this operation, mainly for Mr. Fergusson of King's College Hospital. Most of the patients were infants between 3 and 6 weeks old. The infants had rested in Mr. Fergusson's lap, and according to anesthetist Snow:

In a few cases of strong children, in whom the bleeding is rather free, the breathing gets embarrassed, and Mr. Fergusson turns the face of the child downwards for a moment to let the blood run out of its mouth. . . . The effects of chloroform pass off very quickly in infants, and it is not often that they last till the operation of harelip is finished, short as that operation is.

Within a year of its presentation in Boston, ether anesthesia was used by Dieffenbach, in the fall of 1847. His stamp of approval had been awaited by the continent of Europe. Over the next 100 years anesthesia for cleft lip surgery progressed fantastically. The highlights were the change to ether, Magill's intubation, Ayre's T tube and Dott's mouth gag. Since all these devel-



William Morton

opments had become well established by 1950, it was a shock to me at that time, returning from England, to find Claire Straith of Detroit operating without endotracheal anesthesia and thus resorting to mild sedation and local anesthesia. Such conditions were not conducive to careful design and meticulous execution of a lip closure. Yet there were times in Korea when my experience with Straith was put to good use in clefts. Fortunately this course is no longer necessary.

ANESTHESIA IN CLEFT PALATE

The cleft in the palate being less accessible, its surgery came later. Even then, the early palate surgeons—Monnier, von Graefe, Roux and Dieffenbach—did not have the advantages of general anesthesia. Von Langenbeck used ice to produce local numbing of the palate.

Gordon Jones of the University Hospital of South Manchester, England, in his excellent 1971 history of anesthesia for harelip and cleft palate, noted early isolated attempts with general anesthesia. The first report of a case that he could find appeared in the *Lancet* of 1850, stating that Mr. Gay, of the Royal Free Hospital, used chloroform in closing a bilateral cleft lip and hard palate in a 7-year-old boy.

The majority of surgeons, however, were against using general anesthesia for palate cases. In 1862 Fergusson of King's College Hospital, who was quite happy with general anesthesia for lip clefts, declared that repair of the soft palate was one of the few operations in which chloroform could not be used. Sansom, an associate of Fergusson, wrote in 1866:

In cases of operation for cleft palate and such manipulations as require co-operation on the part of the patient, chloroform should be dispensed with or else given very sparingly. A few whiffs may be permitted so that the local sensibility may be benumbed. A gargle of iced water is the best local anaesthetic during the intervals of the operation.

John Snow was meeting the same opposition from other surgeons:

I assisted the late Mr. Avery by giving chloroform in two operations for cleft palate. . . . The surgeon, however, much prefers to have the patient awake during this operation, when he can get his assent.

Even in America and at the Massachusetts General Hospital, J. Mason Warren, a friend of Morton's, affirmed that repair of cleft palate

is one of the very few operations in which the use of anaesthetics is inadmissible. Under very peculiar circumstances, I suppose, ether might be administered, but not without some risk to the patient, and much embarrassment to the surgeon, from the constant flow of blood down the throat. . . . It is necessary to wait until the patient is old enough to fully appreciate the importance of the operation and to submit patiently to pain and inconvenience.

This fearful attitude was changed during the 1860's through the work of M. H. Collis at the Meath Hospital, Dublin, and Sir Thomas Smith of St. Bartholomew's Hospital and the Hospital for Sick Children in London. Their heated controversy in competition for priority probably speeded the acceptance of anaesthesia.

In 1868 Smith presented a paper to the Royal Medical and Surgical Society which was reported by a correspondent of the *British Medical Journal*:

The author's object in presenting this paper was to communicate to the Society a plan of operating on clefts of the palate, applicable to all who suffer from the deformity, but especially to children. . . . The chief novelty in this proceeding was that chloroform could be employed. A painless and speedy operation could therefore be performed, and that with more precision and a greater prospect of success . . . while from the painless nature of the operation, the cure of cleft palate could be effected in children, to whom formerly the benefits of staphylorrhaphy were virtually denied.

In the same month a letter was published in the *British Medical Journal* from Collis:

Sir,—let me call the attention of Mr Thomas Smith to the *Dublin Quarterly Journal*, vol. XLIV, p. 345, by which he will see he is anticipated in this improvement. . . . I have used it (chloroform) in all my palate operations for two years and a half. . . . I believe, I was the first to operate with success on young children, and the first to use chloroform.

This suggested that Collis first used chloroform in cleft palate surgery in 1865 and, in support of his claim of having preceded Smith, the *Dublin Quarterly Journal of Medical Science* editor wrote in 1867:

It is now fully established that chloroform can be given in these cases. Mr Collis gives it habitually and has been thus able to operate with success on very young children. The danger from chloroform is no greater than in any other operation and the relief from pain and from subsequent shock and depression is of the greatest importance. Of the advantages of early operation as regards the patient's education, it is needless to speak.

In 1912 J. Berry and T. P. Legg recorded the difficulties being experienced at that time:

The anaesthesia should be deep enough to abolish sensation, but not to do away with cough reflex. . . . The most suitable anaesthetic is undoubtedly chloroform. . . . We have sometimes employed ether for induction, but the tendency to the secretion of mucus and saliva, as well as the increased venous congestion caused by the ether . . . is apt to be troublesome. . . . [Chloroform] should be given through a Junker's tube inserted either into one nostril or preferably at one corner of the mouth. . . . An experienced anaesthetist will often be able to lend a hand with the sponging, and . . . if the bleeding be unusually free, . . . or if vomiting occur, . . . it may be advisable to suspend the operation for a short time while the child is turned on its side.

Berry and Legg concluded, and with feeling:

for the patient too!

The difference to the surgeon, between doing a cleft palate operation with a thoroughly experienced anaesthetist and an inexperienced one, is the difference between pleasure and pain!

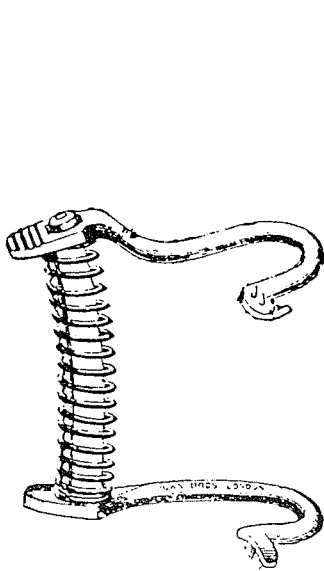
PATIENT'S POSITION

By 1874 Edmund Rose of Zurich was presenting a new position for the patient during the administration of general anaesthesia while operating in the mouth. Rose placed the patient on the back on the operating table with the head hanging over one end while the foot end of the table was raised about 12 inches above the horizontal position. Thus blood collected in the nasopharynx could be sponged and, in later times, suctioned out instead of allowed to run down into the larynx and esophagus. This position became popular and was still being used and taught when I

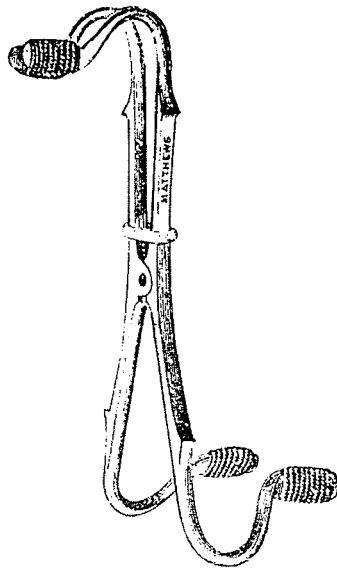
interned with Ladd, Gross, and MacCollum at Harvard in 1944. In fact, Dr. Ladd sat down and operated with the baby's head in his lap, as did Blair, Veau, Kilner and Wardill, among others.

EXPOSURE

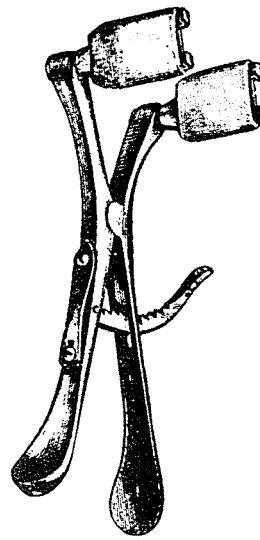
Meanwhile, mouth gags were being designed to improve exposure and later were to assist the anesthetist. Gags by Lane, Rose, French and Doyen-Jensen simply held the mouth widely open, requiring a tongue stitch to maintain an airway and a view for the surgeon.




Lane



Rose

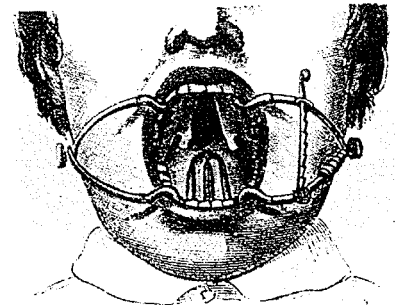


French

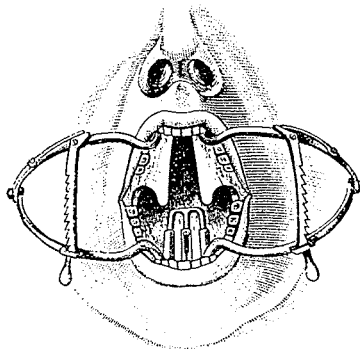


Doyen-Jensen

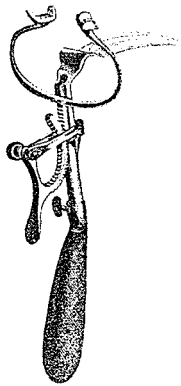
Thomas Smith's 1868 gag incorporated a tongue depressor, as did gags designed by Whitehead, Collin, Geffer and Mahu. Berry and Legg warned of the dangers of obstructing the airway with the tongue depressor.



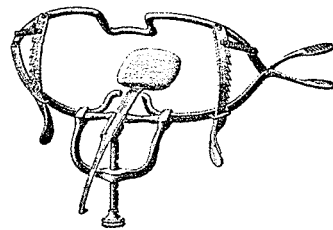
Smith



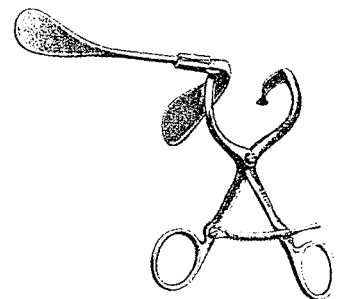
Whitehead



Collin

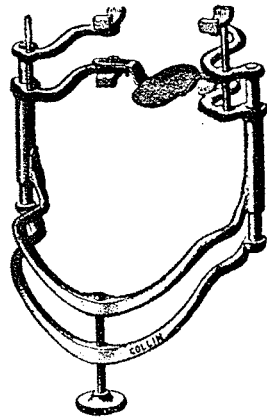


Geffer

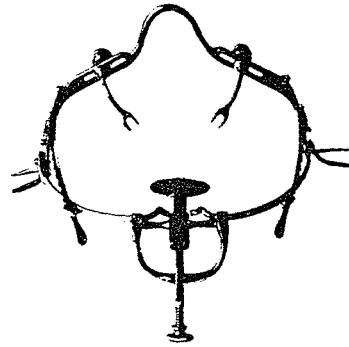


Mahu

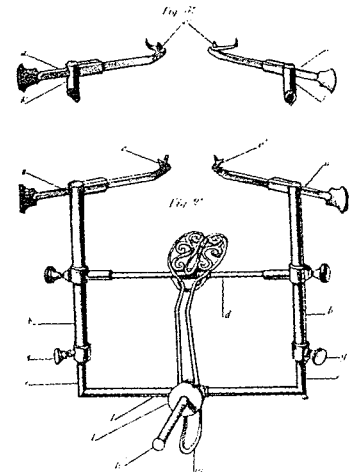
Some of the gags began to get more complicated and, incidentally, to look more like the gags of today. Trélat's, Lexer's modification of the Whitehead gag and the fantastic appliance of Edoardo Bassini are shown:



Trélat



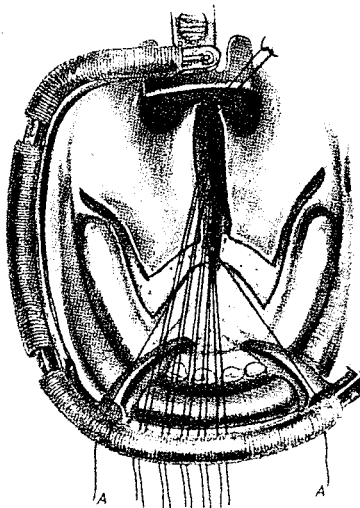
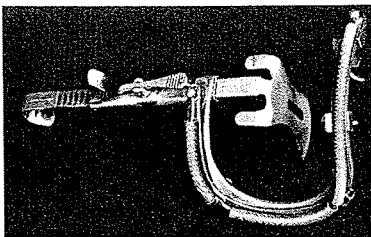
Lexer



Bassini



Norman Dott



Then, to assist the anesthetist, both Mason and Doyen equipped their gags with thin metal tubes fixed to the gag blades through which the anesthetic vapors could be insufflated into the oropharynx.

Dott

Norman W. Dott of Edinburgh started out as an engineer but, convalescing from a motorcycle accident in which he suffered bilateral tibial fractures, became intrigued with medicine. He took his medical degree and for a time was involved in pediatric surgery before he became the first professor of neurosurgery at the University of Edinburgh. During his pediatric experience he did cleft palate surgery and turned his knowledge of engineering toward the construction of a mouth gag that forms the basis of all gags popular today. It was C shaped, with one side open, and incorporated a tongue depressor.

Kilner

One version of the Dott gag incorporated an anesthetic tube in the tongue depressor. Kilner added a spring coil around the top to hold sutures in perfect order prior to tying, in keeping with his tidy surgery.

Dingman

In 1962 Dingman and Grabb reported on a modification of the Dott-Kilner gag as a closed rectangular frame with bilateral alveolar retractors and a tongue blade sliding through a ratchet. The tongue blade supported the gag inferiorly and held an endotracheal tube over the tongue. To this had been added bilateral side retractors which hooked the lips near the commissures to pull the cheeks laterally out of the way. At about the time of this gag's introduction, Reed Dingman, accompanying me on a Caribbean work trip, asked:

What is happiness?

and when none of us came up with the appropriate answer, he continued:

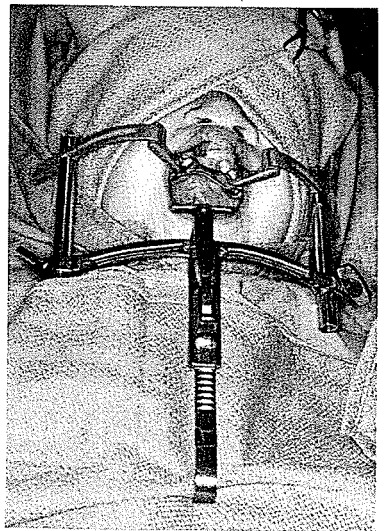
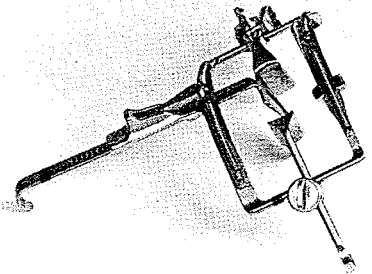
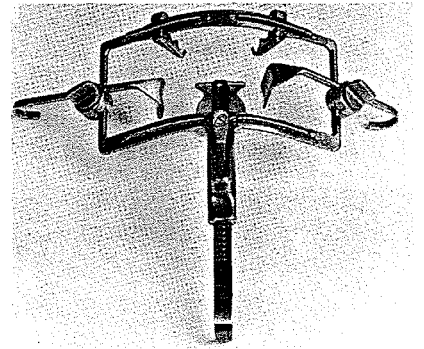
This mouth gag for a surgeon operating on a cleft palate!

He then presented us with one of his brand-new gags, and it has been standard equipment for cleft palate cases at the University of Miami School of Medicine ever since.

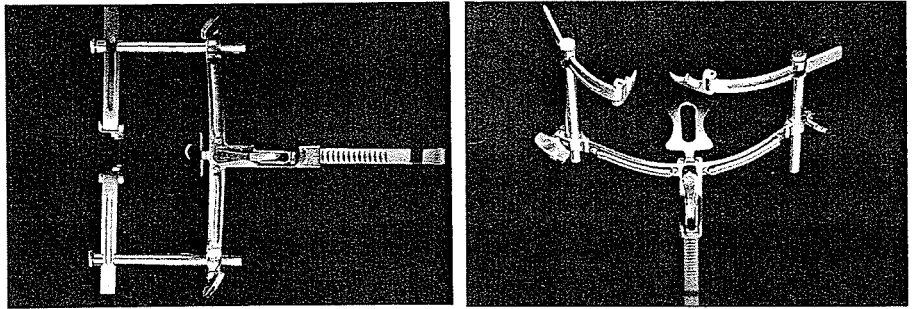

Over the years I have experienced a couple of difficulties with this gag, the major problem being the lack of adaptability of the rigid rectangle to fit the irregular alveolae.

Miami modification

The majority of severe cleft palate patients have abnormal spacing between the maxillary alveolar arches. When there is maxillary retrusion, collapse or a protruding premaxilla, it is difficult to fit both alveolar hook retractors on the irregular alveolae when these retractors are attached to a rigid rectangular frame. Once fitted, the purchase is often unstable because only one retractor can get good contact with an alveolus. The gag may slip midway through the operation. Then too, the frame does not allow the retractors to maneuver into an effective position in the presence of a severely projecting premaxilla. If it is forced on, it traumatizes the premaxilla, or at least the prolabium. Resident David Slepian was challenged to try to improve the gag, and he in turn found Jack Nestor, an ingenious machinist and sculptor, who used the Dott-Dingman tongue depressor and ratchet arrangement with a



posterior bar to hold a pair of telescoping 360-degree rotating barrels. The anterior bar was divided to admit any projecting premaxilla. For more mobility the anterior segments were constructed to slide sideways through the lateral barrels, and these sliding anterior arms were capped with swivel-hook retractors which could be set at any angle to clasp the alveolae. The swivel-hook retractors were made interchangeable—one for infants, one for adults. The adult hook has a beveled radius to present a wedge which fits between the teeth to prevent slippage. A lock-stop screw controls outward rotation of the swivel-hook retractor. This completed the total adaptability the gag to near-ecstatic proportions for any irregularity of the alveolar arch in patients of any age.



The Dingman side cheek retractors can be installed, yet in palate surgery it has been my experience that the amount of vertical mouth opening needed for velopharyngeal surgery will sometimes burn the commissures. Thus one fears that the additional lateral pull for transverse opening, which for palate surgery is unnecessary, may cause even greater stretch burns.

The Miami gag modification, published in *Plastic and Reconstructive Surgery* in April 1977, can be obtained from Jack Nestor, 148 N.E. 29th Street, Miami, Florida 33137, upon request or from Padgett Instruments, Kansas City, Missouri.

ENDOTRACHEAL ANESTHESIA

The most monumental advance in cleft lip and palate anesthesia came with the introduction of endotracheal anesthesia. This was accomplished by a thin insufflation catheter passed by direct vision into the trachea. Ivan Magill first used the method on infants in 1921 and first intubated a cleft palate case for Harold Gillies at Great Ormond Street in 1924.

Magill


Sir Ivan Magill's story is fascinating. He was graduated from Queen's University Belfast, Ireland, and near the end of World War I arrived at the Plastic and Jaw Unit at Queen's Hospital, Sidcup. One look down the wards of bandaged broken jaws and wounded faces was warning enough that anesthesia here would be no picnic. At that time ether vapor was administered through a gum elastic catheter with the aid of an electrically driven pump to create a positive pressure to prevent blood from trickling into the trachea. The surgeon got the blast of the patient's ether-laden exhalations and was often enveloped in a spray of blood. Constantly, Harold Gillies, half asleep from Magill's ether, would growl:

Maggie! You seem to get this ether in here jolly well. Why can't you take it out again?!

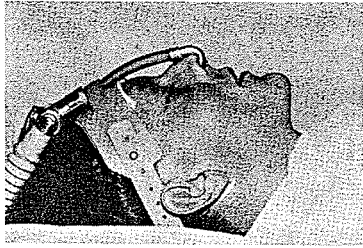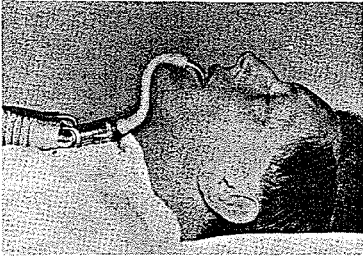
Magill tried two tubes, then one wide-bore single rubber tube which he found could be passed blindly into the trachea through the nasal route when the head was in the position affording the freest nasal airway, as in "drinking a pint." In 1925 in Paris, at the first truly International Congress of Plastic Surgeons, Magill demonstrated his nasal intubation on a cadaver. Later, at the request of a French surgeon, he intubated a patient. The surgeon, accustomed to a porter with a bottle of chloroform crouched over a cyanotic, coughing, struggling patient, took one look at his patient lying quietly with Magill's tube in place and cried out that his patient was not breathing, then that he was dead! Whereupon Magill assured him all was well.

Evidently, French surgeons were not totally convinced. Visiting Paris in 1948 I watched Jacques Récamier do a Veau cleft palate procedure at l' Hôpital St. Michel. With some difficulty from behind a modified gas mask worn to prevent the chloroform from anesthetizing himself, Récamier was forced to pause constantly to allow the patient's cyanosis to pass.

Meanwhile, Magill continued to improve the technique of endotracheal anesthesia. He placed a battery in the handle of the laryngoscope to provide a light without wires and wall plugs, a slot in the laryngoscope barrel to accommodate tubes, mineral-



Sir Ivan Magill



ized rubber tubes smoothly beveled at one end and in 12 sizes. He also designed wide-angled metal tube connectors for oral intubation and acute-angled connectors for nasal intubation, in order to keep the anesthetic apparatus fitted snugly to the profile and out of the way of the surgeon.

Magill found that in cleft lip and palate cases laryngeal edema was not necessarily a danger. The real difficulty was in developing a tube thin enough for an infant that would not collapse. Finally, in 1932 he turned to a metal coil covered with thin rubber cemented to a $\frac{3}{4}$ inch piece of standard rubber endotracheal tube beveled at one end. The other end was attached to a Y metal connector to reduce rebreathing. This principle preceded Ayre's T tube. Such a flexible, unkinkable, armored tube could withstand the pressure of the tongue depressor in the Dott mouth gag without collapse and facilitated oral intubation with the tube out of the surgeon's field. The anesthetist could also relax as his tube was safely stabilized by the tongue depressor. A pharyngeal pack or a Magill inflatable cuff was used to prevent blood and secretions from slipping by the tube down the trachea. Once Magill had his intratracheal tube in position and the patient sleeping peacefully, he would get out some string, cork, tubing and a pocketknife to experiment in constructing gadgets for his anesthetic apparatus with much the same concentration he tied flies while trout fishing the Test River.

By 1936 Digby-Leigh and Fitzgerald of Montreal were using Magill's tubes, as was Ayre for Wardill in 1937 and Gillespie for Kilner at Elizabeth of York Hospital for Children at Shadwell in 1939.

Ayre

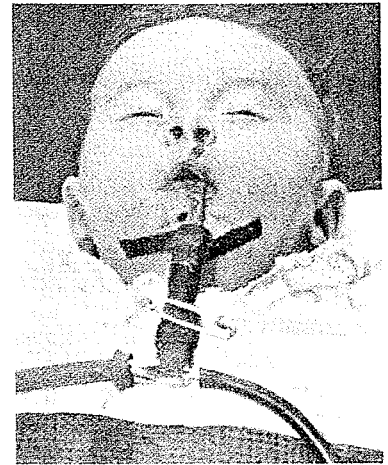
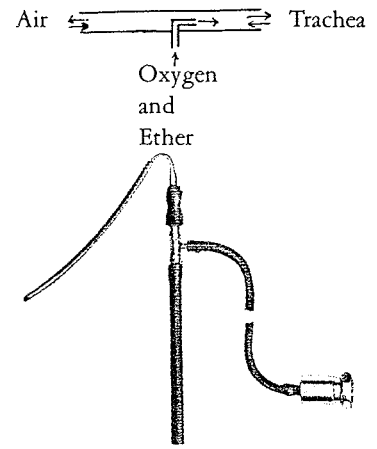
Red-haired Philip Ayre, anesthetist to Babies' Hospital, Newcastle upon Tyne, was a postoperative unilateral complete cleft of the lip and palate individual with only a reasonable repair himself. He found on cleft lip and palate cases that the Magill wide-bore rubber catheter through the mouth into the trachea worked satisfactorily except for the suboxygenation when nitrous oxide was being used in babies and the difficulty in adjusting the amount of rebreathing. No matter how small the rebreathing

bag, there was always too much "dead space". Because of anoxemia and excessive rebreathing, the condition of cleft babies showed marked deterioration within a short time. Ayre was in a state of desperation as he explained in 1937:


In an endeavour to remedy this distressing state of affairs (and spurred on by the caustic criticisms of a candid surgeon!), the writer sought to devise a method by which the endotracheal technique could still be utilized without the drawbacks associated with nitrous oxide and excessive rebreathing. . . . Briefly, the apparatus consists of a T-piece which is connected by a short piece of rubber tubing and a Magill angle-piece to a wide-bore rubber catheter previously inserted into the trachea. Through one limb of the T-piece oxygen and ether vapour is delivered from a Boyle or other continuous-flow apparatus. The other limb remains open to the outside air; for convenience, a short piece of tubing may be attached and allowed to hang down beneath the operating towels. A strand of fine gauze, fixed with adhesive strapping close to the open end of the latter tubing, will wave to and fro with the patient's respirations, thus serving as a useful indicator to the anaesthetist. . . . The excellent colour and quiet, natural breathing of the babies have convinced us that oxygen and ether vapour, administered by the T-piece method, is the anaesthetic of choice for all hare-lip and cleft palate operations on babies and young children. . . . The post-operative convalescence is remarkably smooth and free from anxiety. Last, but by no means least, comparative peace now reigns in an operating theatre formerly the scene of many sanguinary battles!

A final point of finesse came when in 1954 R. M. Davis modified the Dott tongue depressor with a slot to accommodate the Magill tube.

As Gillies was doing very few primary cleft lip and palate operations, I took the opportunity to visit Wardill in Newcastle and there observed Ayre using his happy T tube. Once a fortnight, at Lord Mayor Treloar Children's Hospital, Alton, I had a chance to observe Kilner and Peet operating on lips and palates. Their anaesthetist was John Hunter, who at 240 pounds was the Friar Tuck of anaesthesia. It was fascinating to see huge and jovial John turn an infant fuzzy with N₂O, taking it down with Vinethene followed by ether drip prior to intubation under direct vision. He carried the babies through the operation on pure gas-oxygen-ether with the Ayre open T tube. His anaesthesia was smooth, the baby almost never turning blue or coughing blood



*Wardill
on the
warpath!*



John Hunter

in the surgeon's face. The operation by Kilner or Peet was so organized that Hunter could intubate, leave the room, return in one hour by the clock and, without even looking or asking, it seemed, pull his tube. By 1949 he had anesthetized over 2,000 infants without a mortality.

During the last 20 years the use of controlled intermittent positive pressure respiration, with or without the use of muscle relaxants, has become popular for pediatric cases. Anesthetic agents in cleft surgery have changed from chloroform to ether and now to halothane. Wallbank has shown that in infants and children up to 2 years of age the doses of epinephrine required to aid hemostasis may be safely used in the presence of small concentrations of halothane.

FINDING THE VEIN FOR I.V.

In 1977 Robert Woolf of Salt Lake City suggested an aid to anesthetists attempting to place a needle in infants for administration of intravenous fluids during surgery. If a fiberoptic light is placed under the hand, the arcade of vessels, not easily visualized through the skin in fat babies, will be vividly presented.

MIAMI ANESTHETISTS

It has been my good fortune to have two excellent anesthetists for the cleft babies. Their thoughts and tricks are important.

MacMahon



Stan MacMahon

F. Stan MacMahon received his medical degree at University College, Dublin, Ireland, trained at the Anesthesiology Center, Copenhagen, and then became a journeyman anesthetist around the world, ending up in the Bahamas. For many years he gave superb anesthesia for the cleft babies I operated on at Princess Margaret Hospital, Nassau. Imagine my elation when he decided to come to Miami and became Clinical Director of Anesthesia at the University of Miami School of Medicine, Jackson Memorial Hospital. Here is his contribution:

Ralph Millard and I have been operating together on patients with these problems for over sixteen years. Early in the series I learned that the virtuosity involved in the functional and cosmetic repair of these babies requires the anaesthetist to apply the art as well as the science of his profession. The surgeon demands a clear, uninterrupted operating field with normal, uncontorted anatomy; the anaesthetist must have control of the airway at all times. For both parties on either side of the ether screen to perform smoothly, such a mutual understanding is essential. Compromise is the essence of diplomacy, and, after a few initial skirmishes, Ralph and I signed a "Mutual Aid Pact" and have since worked in perfect harmony.

In attempting to describe the anaesthetic technique which we have evolved over the years, I am reminded of the Ninth Century Irish monk who, in a moment of anguish, wrote on the margin of his scholarly text:

Meisse ocus Pangur Bán,
 cehtar nathar fria shaindán;
 bíth a menma-sam fri seilgg
 mo menma céin im shaincheird.*


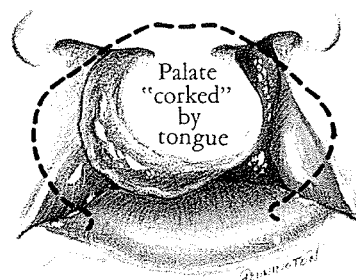
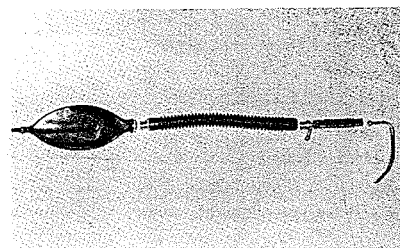
At least Gallarus had his cat for company and inspiration. . . .

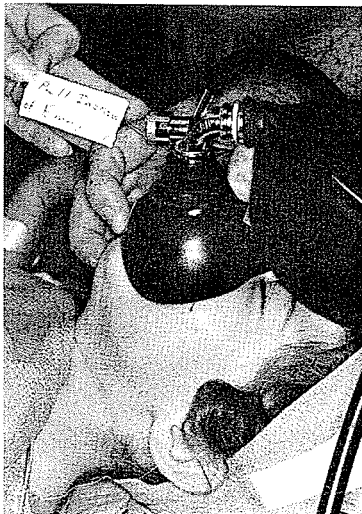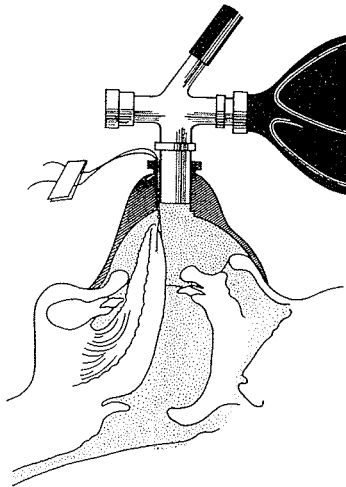
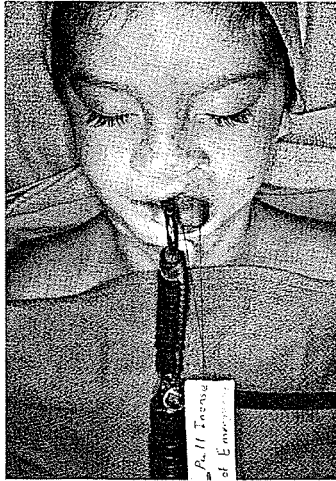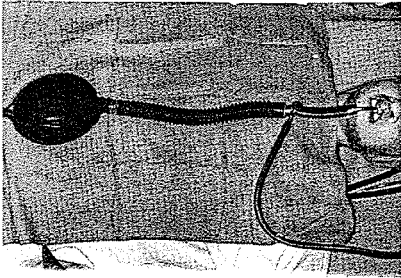
Simplicity usually means safety. For this reason, a modified Jackson Rees system, delivering nitrous oxide, oxygen and halothane on spontaneous respiration and incorporating an artificial sigh, is utilised. During the mask induction it is important to recognise that airway management may prove difficult. The most common cause of obstruction (which, at times, may be complete) is what I refer to as "corking" of the palate by the tongue. When the cause is known, however, the remedy is indeed simple.

When the patient has reached a surgical plane of anaesthesia, laryngoscopy is performed. To avoid even mild trauma to the epiglottis, the author prefers to use an infant Mackintosh laryngoscope blade at first and, in 90% of cases, can obtain a clear view of the larynx. If a clear view cannot be obtained with this blade, then one progresses through the Roberts-Shaw, the Sheila Anderson and the Miller blades until a clear view is obtained. Personally, I never attempt to intubate these children unless I can see the larynx clearly. My reason for this is that I look on these cases as elective, and at no time should the child be jeopardized by injudicious attempts at intubation. Cole tubes cut to the appropriate length, with a Magill type catheter connector, are used. It is essential that the Magill connector lie flush with the chin,

* For the non-Gaelic speaking:

I and Pangur Bán my cat,
 'Tis a like task we are at:
 Hunting mice is his delight,
 Hunting words I sit all night.





thus providing an uninterrupted operating field. To achieve this, tubes of varying sizes and lengths should be at hand.

The introduction of the corrugated tubing between the Inglis valve and the Magill connector is a compromise reached between the anaesthetist and the surgeon. From the anaesthetic point of view, a measured "dead space" of 7 cc's is added to the system, but the flexibility achieved is of great value to the surgeon.

For cleft lip adhesion or closure, a solitary piece of plastic tape placed low down on the chin, combined with a pharyngeal pack, suffices to keep the endotracheal tube in situ. In cleft palate closure, the blade of the mouth gag serves the same purpose admirably.

Pulse, respiration, blood pressure, temperature and EKG are monitored at all times. Maintenance I.V. fluids are given. Hypothermia is avoided by the use of a warming blanket. Accurate measurements of blood loss are made by weight and calibrated catchment trap in the suction line. It is seldom that blood loss exceeds 10% of the estimated circulating volume; therefore, replacement transfusion is rarely indicated.

Positioning the child is of utmost importance to the surgeon, who sits at the head of the table. The extension must be maximal for cleft palate surgery, less extreme for lip repair. I prefer to obtain head extension by raising the whole body on a folded blanket, rather than by placing a folded towel under the shoulders. The work of breathing is decreased by this simple manoeuvre.

At the conclusion of the surgical repair, and following a careful pharyngeal toilet under direct vision, extubation is carried out in the surgical plane of anaesthesia. To avoid trauma to the surgical field, an oral airway is not used. Instead, a tongue stitch, combined with a lateral position, is utilised to maintain a clear airway until normal reflexes return. The insertion of the tongue stitch always seems to cause extreme anguish to the surgeon, but having signed our "Mutual Aid Pact," it is now performed with a minimal show of revulsion.

If it becomes necessary to administer oxygen to the patient before protective reflexes have returned, a simple trick incorporating the tongue stitch, mask and mask connector can be used. The tongue is pulled out by the stitch. The stitch then is passed through the mask aperture, and the mask connected to an oxygen supply. This is quite effective and technically easy.

When normal protective reflexes have returned, the baby is transported from the Operating Room to the Post-Anaesthetic Recovery Room. Here arm splints are applied to prevent damage to the operation site by thumb sucking. Some of the cleft lip babies will have been converted temporarily to complete mouth breathers by the surgical repair. Gentle traction on the tongue stitch may be required in the immediate post-operative period to

remind our little patients to open their mouths and yell a challenge to the world.

Many anaesthetists will ask why we go to so much trouble for these relatively short but challenging procedures. The answer is obvious some years later, when the eye can barely detect a scar on the lip, and the ear hardly detects a nasal tone. That, indeed, is sufficient reward.


Freeman

It has also been my good fortune to have another expert anesthesiologist, Alfred Freeman, M.D., trained at Temple University, available at Variety Children's Hospital to help in the care of these children. He is an extremely smart, dexterous and gentle man and has provided here the details of his approach:

Children's hospitals, because they are relatively small and because their staffs work closely together, provide what I believe to be the ideal environment in which to treat cleft lip and palate patients. It is important to have personnel who are specifically fond of infants and children and who can provide the emotional support that these patients require. Needless to say, teamwork is the keystone to the overall successful outcome in the treatment of these children.

Infants under two weeks of age are usually intubated under deep general anesthesia to allow for an atraumatic intubation of the larynx. Anatomic problems imposed by the cleft palate lead to easy impaction of the tongue against the palate with subsequent airway obstruction. Soft tissue obstruction of the airway will occur earlier and be more pronounced if the anesthesiologist inadvertently presses his fingers under the mandible and causes increased pressure of the tongue against the palate.

Halothane with 50% nitrous oxide/oxygen is usually used for the induction and maintenance. As soon as the patient is unconscious, a plastic cannula is inserted percutaneously into a peripheral vein and an infusion of appropriate fluids started. Monitoring of the patient's vital signs is started at the same time. A water mattress, warmed to 37° C., helps maintain the patient's body temperature at a normal level. When an adequately deep plane of anesthesia is reached, direct laryngoscopy with oral intubation of the trachea is performed. It is advisable not to use muscle relaxants in infants unless the anesthesiologist is experienced and has ruled out the possibility of anomalies which make direct visualization of the larynx difficult. When difficulty in exposure of the larynx is anticipated, it is wise to have the patient deeply anesthetized, saturated and breathing spontaneously at the time of laryngoscopy. During laryngoscopy, it is possible to



Alfred Freeman

*MacMahon
has switched
to the Rae
Tube also.*

insufflate the anesthetic into the oropharynx by means of a mouth hook to lengthen the duration of deep anesthesia and allow exposure of the larynx in a less hurried atmosphere.

The choice of laryngoscope blade varies from one anesthetist to the next. My personal preference has been the # 1 Miller Blade up to six months of age, the # 1 Flagg Blade from six to 18 months of age, and the # 2 Miller or Flagg Blade for over two years of age. The # 2 and # 3 Mackintosh Blades also are useful on occasion.

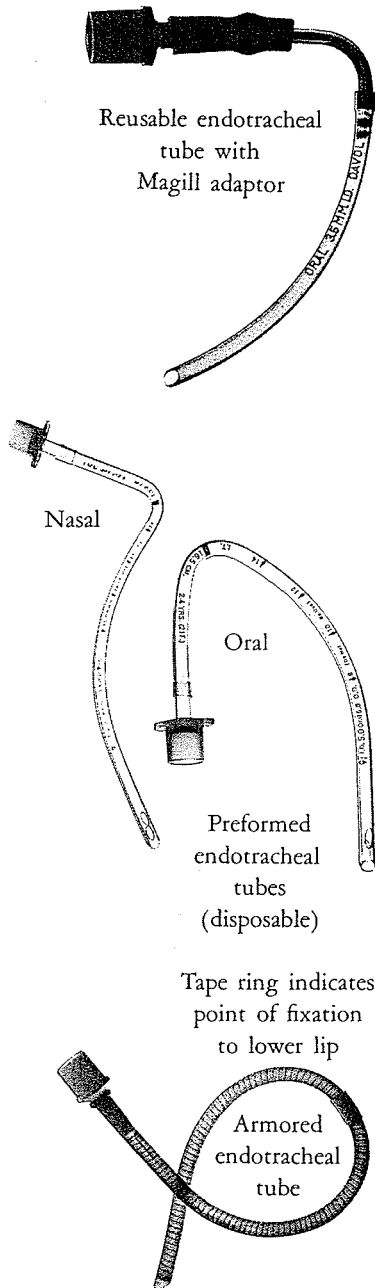
The correct size endotracheal tube is that which will allow a slight leak of air around the tube when an airway pressure of 15 to 20 cm. of water is exerted, but no leak at pressures lower than that. It has been my experience that there have been no cases of post-endotracheal croup when an air leak at these pressures has been assured. Children who have a history of having had croup in the past (whether viral or post-anesthesia) and those with known subglottic stenosis, can be expected to accept a much smaller endotracheal tube than other children of the same age. The proper length to cut the tube will have the upper end of the tube at the level of the teeth or gums, while the bevel of the tube is in the distal third of the trachea, about 1-2 cm. above the carina. A right angle Magill adaptor inserted into the tube and directed caudad can be fixed to the lower lip without distortion of the corners of the mouth.

Recently, pre-formed polyvinyl chloride endotracheal tubes have been available commercially as shown. The pre-formed curves are designed to allow the endotracheal tube to lie flat against the patient and also eliminate the possibility of the endotracheal adapter becoming detached from the tube during the operation.

Where pressure of the mouth gag would threaten to kink (occlude) the endotracheal tube, a latex rubber metal-armored endotracheal tube of branchial length should be used. The ring of tape around the tube indicates the point of fixation to the lower lip to avoid endobronchial intubation. The extra length of the tube permits the anesthesiologist to position the remainder of the anesthetic apparatus at a greater distance from the surgical field.

After intubation an orogastric catheter should be passed to empty the stomach of gas and secretions and the catheter removed before preparation of the surgical field.

For cleft lip closure a small posterior pharyngeal pack is inserted deeply into the pharynx to help stabilize the endotracheal tube. For the cleft palate closure the use of the Millard-Dingman gag allows the surgeon easy unencumbered access to the field while stabilizing the endotracheal tube, without the need of a pharyngeal pack. It is important to properly position the patient to allow for the best possible exposure. For cleft palate repair, the entire body is raised by means of a foam rubber mat, 8 cm. thick, allowing



the head to drop back and be fully hyper-extended into a soft, round head support. This position provides good exposure while allowing blood to run downhill away from the larynx towards the nasopharynx from which it can be removed by suction.

To prevent injury to the eyes, the lids are taped closed by 1" cellophane tape, or ocular lubricant preparation is instilled into the eyes. The use of a 4 X 8 sponge held firmly over the proximal edge of the eye tape during the surgical prep will prevent any of the prep solution from running under the edge of the tape and into the eyes.

During maintenance of anesthesia the patient is allowed to breathe spontaneously. Gentle augmentation of respiration by the anesthesiologist's hand on the reservoir bag is used since moderate depths of anesthesia are required to prevent coughing on the endotracheal tube should it be moved.

In recent years, I have found that one of the newer lightweight disposable carbon dioxide absorption circle systems offers the best anesthetic delivery. If a small extension of latex rubber is used on the Magill adaptor, this system provides minimal deadspace, low resistance, easy assistance of respirations and adequately humidified gases without the use of additional equipment. Scavenging of waste anesthetic gases is also more efficient with this type of circle system.

The goal of the anesthesiologist should be to maintain (1) clear unobstructed airway devoid of secretions, (2) adequately deep respirations, (3) a stable satisfactory level of anesthesia, (4) normal body temperature, (5) adequate fluid balance and (6) proper blood volume. Careful monitoring by the anesthesiologist will indicate proper management to achieve these goals.

There are differing opinions as to the management of the anesthesia upon termination of the operation. Many of these patients will be converted to mouth breathers as the result of the cleft palate repair and must therefore re-learn how to breathe to avoid soft tissue obstruction. It has been my experience that the lowest incidence of post-operative problems is encountered if the patient is extubated after awakening from anesthesia.

At the conclusion of the operation, the oropharynx and anterior nares may be carefully and gently suctioned and a small bite block (made from short lengths of tongue depressors wrapped with 1" adhesive tape) is inserted a short distance between the teeth and gums and taped securely alongside the endotracheal tube. The patient is then turned to the lateral position, taken to the post-anesthesia recovery room lightly anesthetized and allowed to breathe humidified oxygen by T-piece apparatus until awake. When the patient is able to open his eyes, the oropharynx (and trachea if necessary) is gently suctioned and the endotracheal tube removed. This technique does not require the use of a tongue stitch for traction. The use of sedative drugs in the post-operative period is discouraged until the patient can avoid soft tissue obstruction when asleep.

