

# *Cleft Palate and the Face in Which It Exists*

SAMUEL BERKOWITZ

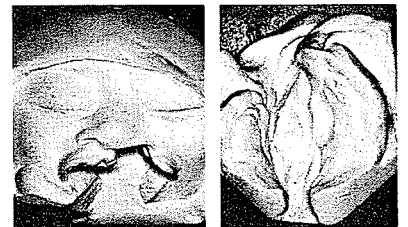
One's enthusiasm for a particular form of therapy should not be regarded as scientifically established when, in fact, it may not have stood up to critical scientific analysis. Treatment fads come and go; unfortunately, when they involve cleft palate it takes at least a decade to determine their effectiveness. A prior belief in a particular therapy often determines the biased selection of evidence to support a concept currently in vogue, and some clinicians show a select sample of cases to prove the theory only in part, if at all.

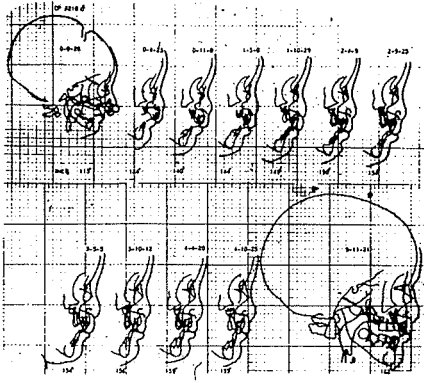
This chapter presents my understanding of the cleft defect and the face in which it exists. It is designed to answer some basic questions previously posed by Drs. Pruzansky and Subtelny. What is the natural history of the cleft defect? How do similarly classified clefts differ from one another? What should be done for a child with a cleft lip and palate, and when should it be done? And finally, how does the treatment vary from child to child? Although selected cases will be shown to develop our treatment philosophy, it must be stressed at the start that the concepts being presented are supported by the findings from many longitudinal facial growth studies already published. The cases offered here are somewhat unique in that they represent the results of only one surgeon who has modified his concepts according to the critical review of the results achieved. Also, no neonatal maxillary orthopedics has ever been done.

Treatment failures as well as successes are presented to develop and stress the physiological principles which are the basis of our treatment philosophies.

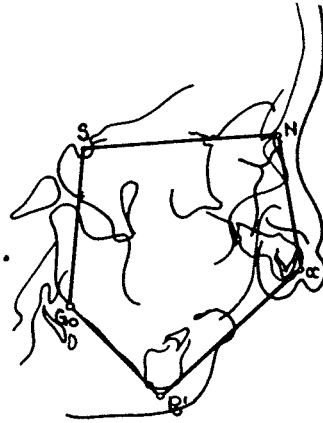## DIAGNOSTIC RECORDS

Longitudinal facial growth records such as cephalorontgenographs, casts of the palate and facial photographs starting at the newborn period demonstrate how surgery may influence the direction and degree of palatal development. This knowledge helps explain how different results can occur even when similar surgical techniques are being employed. It exposes the biological mechanism which ultimately determines the success or failure of reconstructive surgical procedures. This information does not diminish the importance of surgical technical skill but does highlight the many other

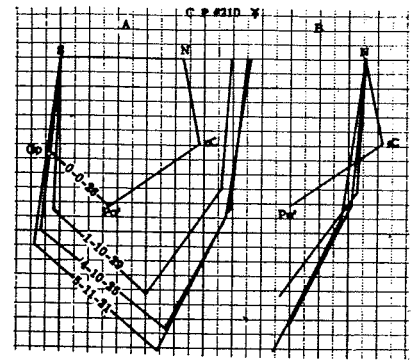




Serial cephalometric tracings used to measure skeletal and soft tissue profile changes



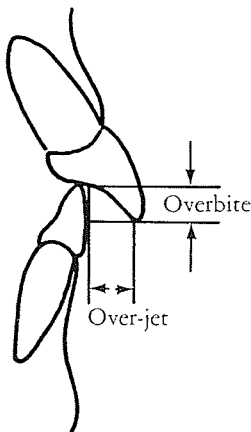
Facial polygon landmarks



Superimposed facial polygons portraying facial profile changes and the mechanism that brings the changes about

factors that warrant consideration in planning treatment. It permits the clinician to appreciate what great allies or adversaries he has in *time* and *growth*.

Serial cephaloroentgenographs and casts expose the rate and degree to which a face and palate can improve or worsen with time. The face with a complete bilateral cleft lip and palate in this case improved as the profile became flatter.

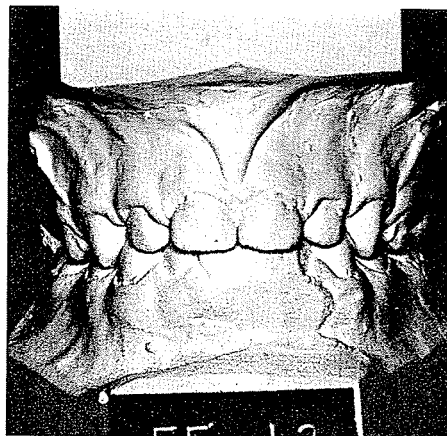


Anterior teeth relationships

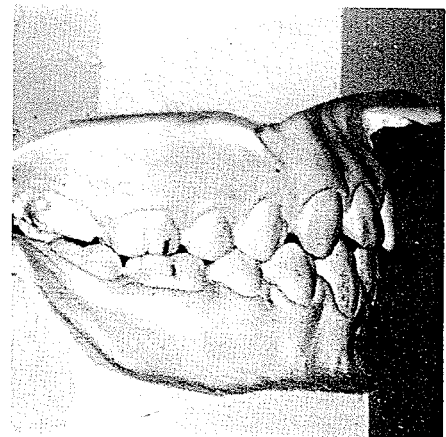
### GLOSSARY OF DENTAL TERMS

Classification of the anterior (incisal) and posterior (buccal) occlusion is based on the interrelationship of the teeth of one arch with those of the other arch. Malocclusion may be present unilaterally or bilaterally. Although there are three basic classes of malocclusion, there is a great variety of dental relationships within each type. For example, a class II malocclusion can have an anterior open bite and displaced teeth as well.

#### Neuroclulsion (class I)



Ideal deciduous occlusion



Ideal permanent occlusion

The maxillary canine (cuspid) occludes between the mandibular canine (cuspid) and first deciduous molar or first premolar (bicuspid), and all the other teeth occlude in their proper interrelationship.

*Distoclusion (class II)*

The maxillary cuspids are forward of their ideal position as seen in neutroclusion. The posterior teeth are out of alignment in the same direction as well. Distoclusion is often associated with severe maxillary anterior overjet and/or overbite.

*Mesioclusion (class III)*

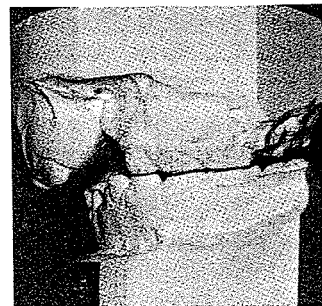
This is the reverse of distoclusion. The maxillary buccal teeth are posterior to their ideal position with the mandibular teeth. The anterior teeth are usually in crossbite.

*Open Bite*

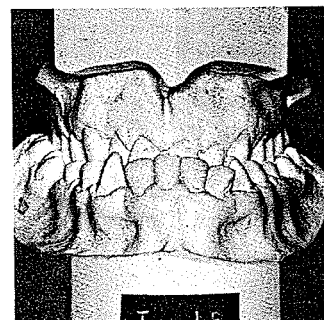
The teeth of opposing arches do not meet. This may occur in either the anterior or posterior portions of the arch and may be due to orofacial habits or skeletal dysplasia.

*Crossbite*

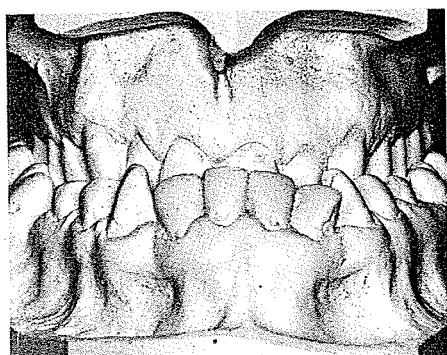
Crossbite may be due to malposition of the teeth alone and/or be coupled with bony displacement. Buccal crossbite in cleft palate is often caused by medial displacement of the lesser palatal segment. Anterior crossbite may be the result of dental dysplasia, mandibular prognathism and/or maxillary hypoplasia.



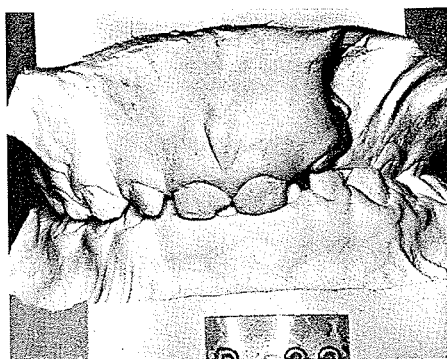
A bilateral cleft lip and palate in Class II dental relationship. Note that the buccal teeth of the upper arch are forward of their proper position when related to the lower teeth.



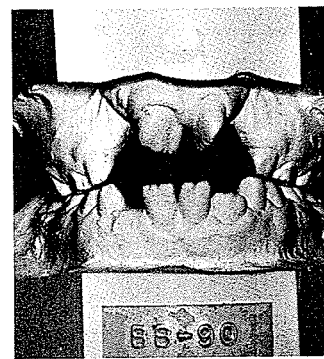Class III mesioclusion



Class III malocclusion with buccal and anterior crossbite

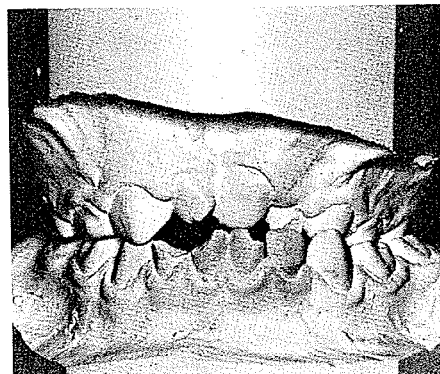
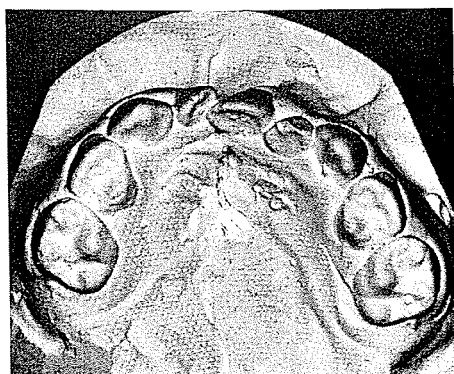


Left buccal crossbite due to medial bony displacement

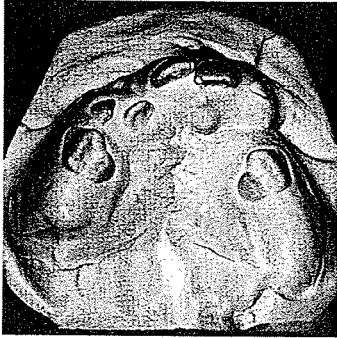


Class I malocclusion with open bite

*Pseudo class III (associated with anterior crossbite)*



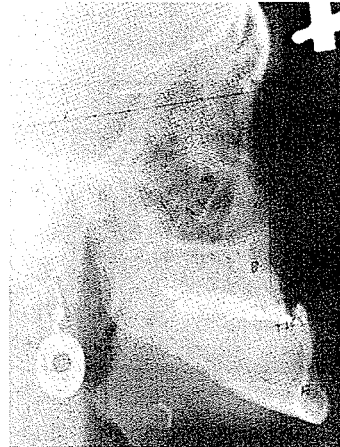This state exists when the mandible is of normal size and in normal relationship with the maxilla but the anterior teeth are still in crossbite. It may be due to the *retrusion* of the maxillary teeth, to premaxillary and/or maxillary hypoplasia or to the forward *posturing* of the mandible (false prognathism) which places the lower anterior teeth forward of the maxillary teeth when in occlusion.



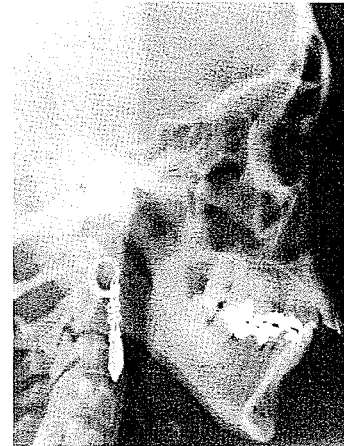*Dental dysplasia*

Individual teeth are malpositioned within each arch.

*Skeletal dysplasia*



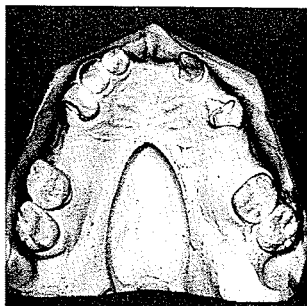
Prognathism with class III malocclusion



Retrognathism with class II malocclusion

Prognathia is a condition in which the mandible is located anteriorly within the skull or is enlarged. It is associated with class III malocclusion. The maxilla may be posteriorly positioned within the skull or be underdeveloped as well.

Retrognathia is due to a small mandible (micrognathia) or to a posteriorly located normal sized mandible. It is associated with class II malocclusion. In some cases a relatively small mandible can coexist with a forward-positioned maxillary complex.

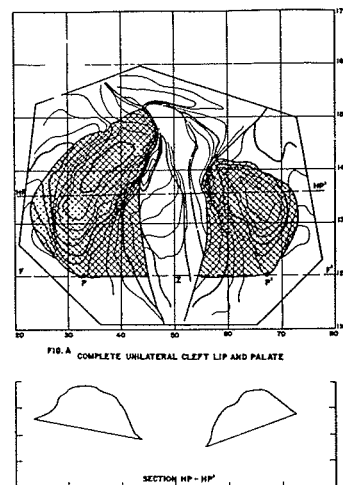


Adult isolated cleft palate; deficient osteogenic tissue

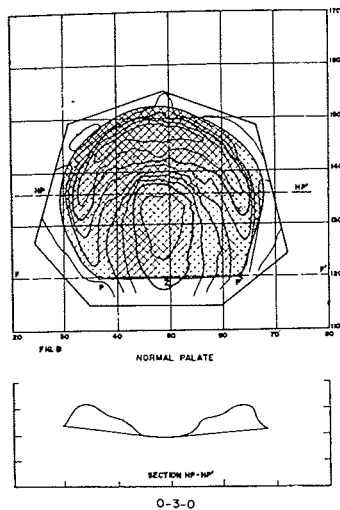
IS THE NEONATAL UNOPERATED CLEFT LIP AND PALATE DEFICIENT IN MASS AND/OR DISPLACED IN SPACE?

While Stark stated in 1958 that all cleft palates show mesodermal deficiency, and therefore adult cleft palates are destined to be small in size, Graber (1954) reported that growth deficiencies in all dimensions were due to early closure and to many surgical procedures. Pruzansky (1956), Slaughter, Pruzansky and Harris (1956), and Mestre et al. (1960) wrote that each cleft

palate patient had the genetic potential for adequate facial growth. Coupe and Subtelny (1960) demonstrated that tissue deficiency can exist in variable degrees according to cleft type. The complete bilateral clefts of the palate had the greatest degree of tissue deficiency and lateral displacement of the palatal shelves. My own findings suggest that the neonatal cleft palate may be smaller in size than a normal palate of similar age, but it has the potential of reaching normal size at a later age. Also, in complete clefts the palatal segments are displaced from their normal position because of the pull of aberrant external muscular forces and the action of the tongue within the cleft pushing the segments farther apart.

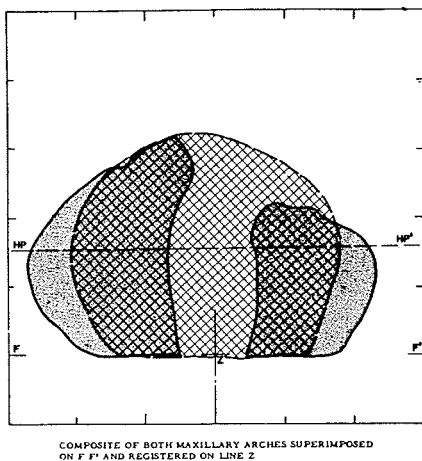


0-3-23  
Contour map of a complete unilateral cleft lip and palate.

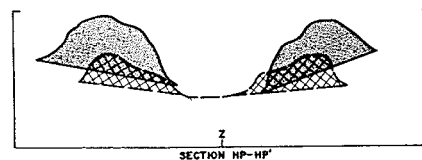


0-3-0  
Contour map of a normal palate

DIZYGOTIC TWINS



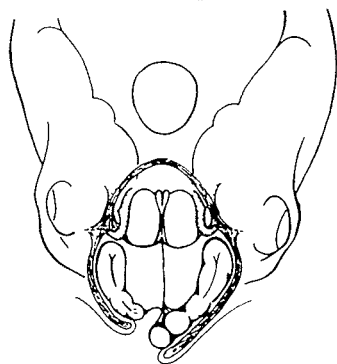
COMPOSITE OF BOTH MAXILLARY ARCHES SUPERIMPOSED ON F-F' AND REGISTERED ON LINE Z  
Effect of clefting on palatal form: The light gray area represents the difference in the width of the cleft palatal segments when compared to the normal (cross-hatching) palate.



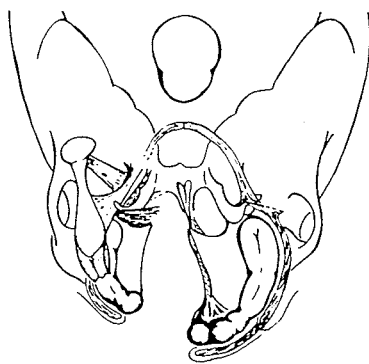
COMPOSITE OF BOTH PROFILES SUPERIMPOSED ON Z LINE AND REGISTERED ON POINT ZERO (THE LOWEST PART OF THE PALATE.)

The composite of normal and complete unilateral cleft lip and palate casts shown here graphically portrays the lateral displacement of the palatal shelves as a result of clefting and uncontrolled muscular systems.

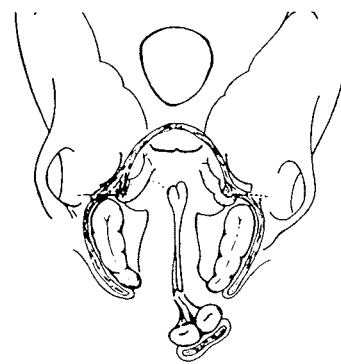
INFLUENCE OF ABERRANT MUSCLE FORCES ON PALATAL SEGMENTS—DISPLACEMENT OF TISSUE



Cleft of lip and alveolus



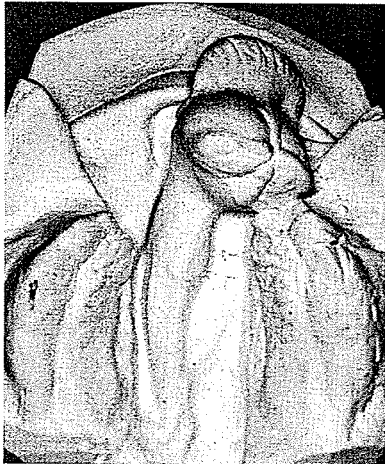Complete unilateral cleft of lip and palate



Complete bilateral cleft of lip and palate (Slaughter et al., 1958)

In the molding of the facial skeleton there are complex muscular systems which influence the spatial relationships of the facial bones. The superior constrictor of the pharynx, the buccinator and the orbicularis oris muscle complex are largely responsible for molding the dental arch and opposing the expansile forces of the tongue. Muscle function is initiated prior to complete ossification of the skeleton and may manifest itself as early as the second month of life.

Since development of the palate involves two separate embryonic processes—the lip and alveolus derive from one, and the palate posterior to the incisal canal from another—it is possible to have any number of variations in degree and locations of clefting.



Incomplete bilateral cleft lip and palate

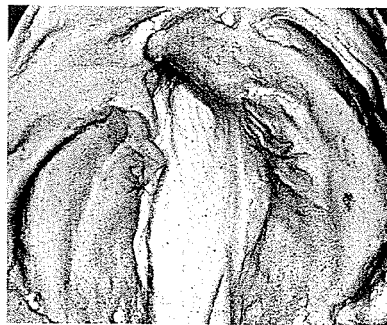*Incomplete clefts of lip and palate*

Any soft tissue bridge (Simonart's band) across the cleft will prevent the aberrant muscle systems from being really effective in distorting the palatal segments. For this reason it is inadvisable to lump together all types of clefts when reporting on surgical results and planning treatment procedures.

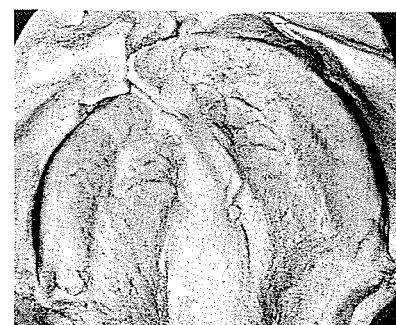*Complete clefts of lip and palate*

When there is a complete cleft through the lip, alveolus and hard and soft palate, continuity of the outer muscular ring and the underlying skeletal structures is lost. Thereafter, the musculature of the cleft lip develops and functions around an aberrant skeletal foundation. The cleft musculature acts in a disproportionate and possibly asymmetrical fashion on the unfused maxillary structures and is unable to restrain the expansile forces of the muscular tongue.

Complete unilateral cleft lip and palate



2 months

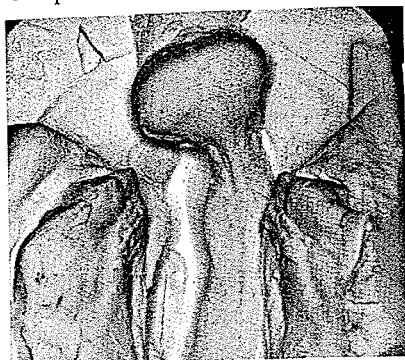

4 months after lip surgery

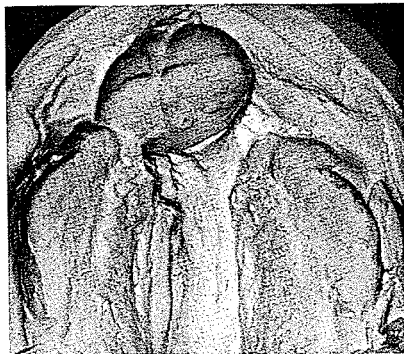In complete unilateral clefts of the lip and palate there is an anterolateral displacement of the non-cleft segment with an outward and lateral rotation of the premaxillary area adjacent to the cleft.

In the complete bilateral cleft of the lip and palate, this disturbance of normal muscular balance results in extreme forward projection of the premaxilla in relation to the facial complex. The projection is due to excessive growth at the premaxillary vomerine suture which occurs in an

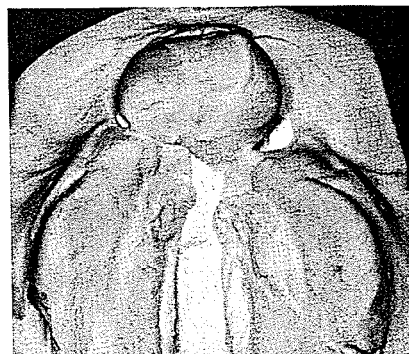
Complete bilateral cleft lip and palate—original distortion corrected by molding action



1 week



6 months after lip surgery



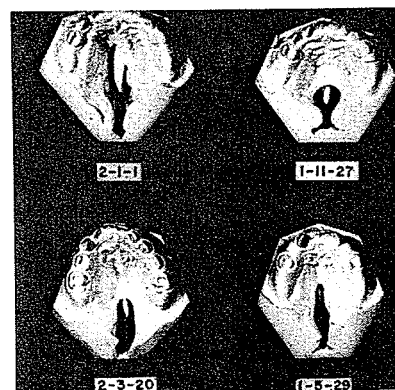
9 months

environment of abnormal force fields resulting from a release of lip muscular restraint. The patient whose premaxilla projects least at birth often has a better profile at the earliest age. A severely projecting premaxilla will yield the poorest immediate results irrespective of who does the surgery. This comment should not be interpreted to mean that a severely protruding premaxilla at birth is to be surgically repositioned.

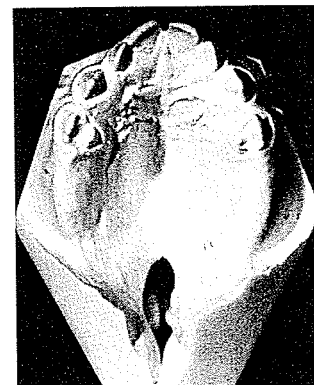
*Not all palates within the same cleft type are alike.* Since a single cleft type exhibits many variations, no rigid formula of treatment applicable to all clefts should be expected. Several kinds of isolated cleft palate are illustrated. The cleft may extend in varying degrees as far forward as the nasal palatine foramen, and in its lateral dimensions the cleft may be wide or narrow. Each case poses different surgical problems and therefore may influence the timing for surgical repair of cleft palate.

*Clefts of hard and/or soft palate*

Isolated clefts of the palate can vary in shape and extent from a slight visible notching of the hard palate to cleft extending up to the incisal canal. There may be a cleft of the uvula alone or it may include the entire soft palate without involving the hard palate.

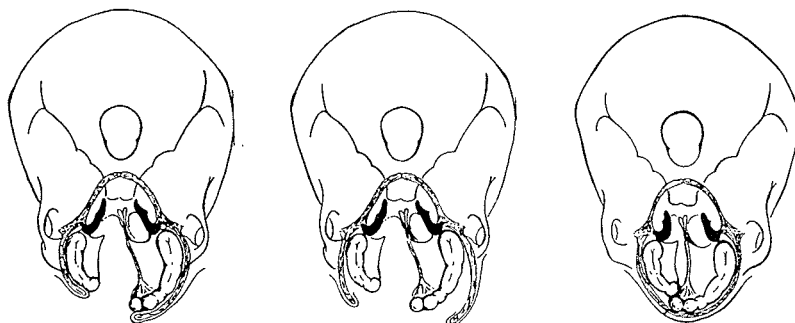


Variations in isolated cleft palate (Lis et al., 1956)



Cleft of the soft palate only (Pruzansky, 1955)

**MOLDING ACTION—MOVEMENT OF DISPLACED SEGMENTS INTO A MORE NORMAL RELATIONSHIP**



Both palatal segments with their connecting perpendicular plates of the sphenoid have been displaced laterally as a result of the aberrant muscular forces. As shown in this basilar view, closing the lip brings the palatal segments, with their respective pteryoid plates, together. (Subtelny, 1955)

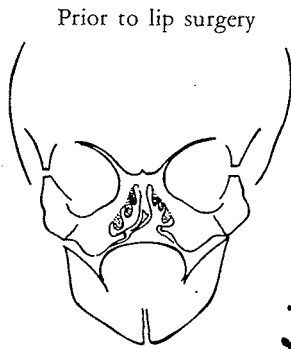
The new force field created as a result of closing the lip cleft induces striking and relatively rapid changes in the architecture of the palate.

### *Cleft of the Lip and Alveolus*

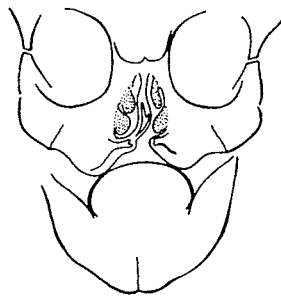
The alveolus is brought into normal approximation within a few months.

### *Unilateral Cleft Lip and Palate*

The palatal segments in almost all instances move medially, resulting in the narrowing of the cleft space throughout its entire anteroposterior length. The posterior width of the hard palate as measured from the base of the alveolar crests is reduced even before soft palate repair is performed. Some additional molding action can occur after soft palate repair which will reduce the cleft space further, but the subsequent lessening of the cleft width is mainly due to appositional bone growth at the medial border of both palatal segments.



Prior to lip surgery



After lip surgery

*this is important!*

Narrowing of the nasal chamber as well as the cleft space

### EFFECT OF COMPLETE CLEFTS ON THE NASAL CHAMBER

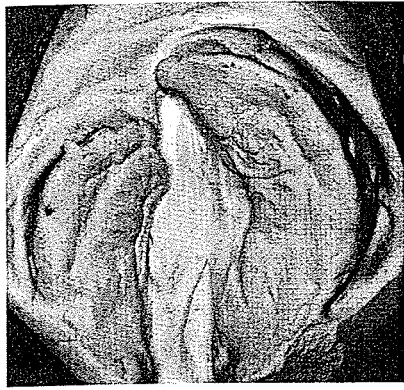
Subtelny (1955), Coupe and Subtelny (1960) and Aduss and Pruzansky (1967) showed that wider nasal chambers are due to lateral displacement of the maxillary bones in the oronasal area, and that the nasal septum is displaced in varying degrees toward the non-cleft side. Closing the lip cleft causes medial movement of the lateral processes, carrying the end of the septum closer to the mid-sagittal plane.

### COMPLETE UNILATERAL CLEFT LIP AND PALATE—3 POSSIBLE ARCH FORMS WHICH CAN OCCUR AS A RESULT OF ESTABLISHING UP CONTINUITY

Pruzansky and Aduss (1964) described the three possible resultant arch forms which can occur: (1) Alveolar segments butt jointing into end-to-end contact producing a symmetrical arch form. (2) Overlap of alveolar segments produces a collapsed arch form. (3) Alveolar segments approximate, but without contact. The last may be a transient relationship; either it can end up in the overlapped relationship or the segments can approximate as a butt joint.

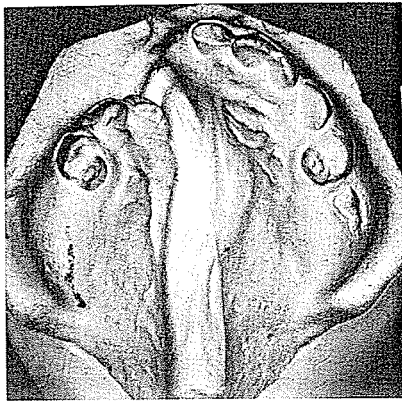

Newborn; unilateral complete cleft lip and palate



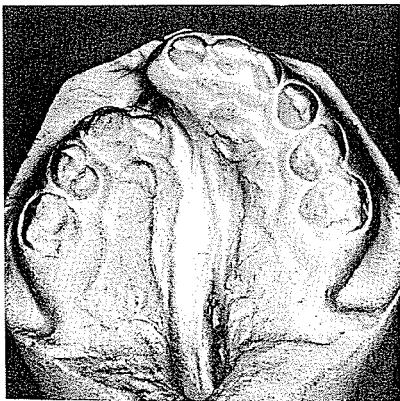
① ↓

2 years

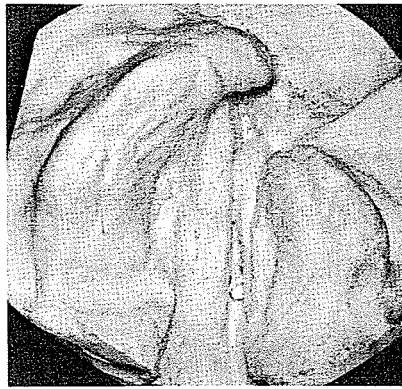


↓

3 years

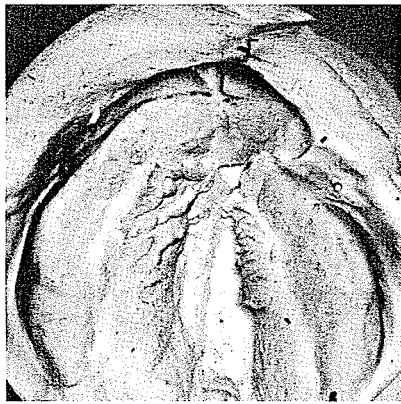


Noncontacting palatal segments



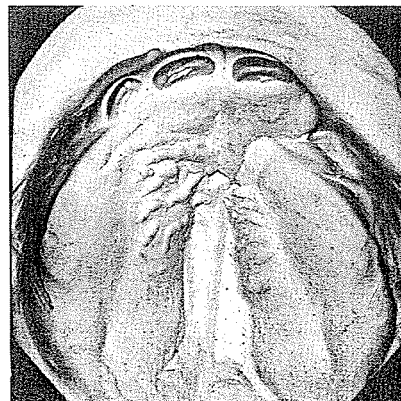
② ↓

2 months

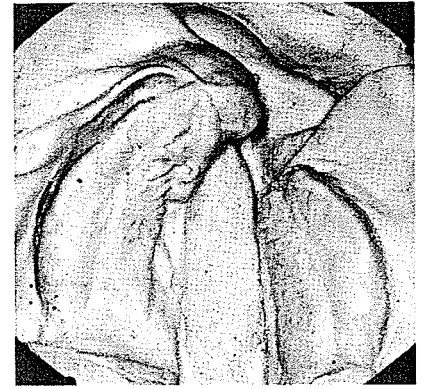


↓

8 months

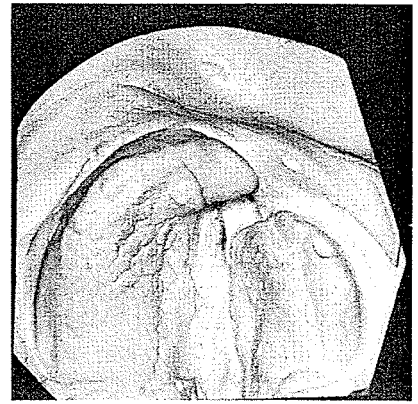


Overlapping palatal segments



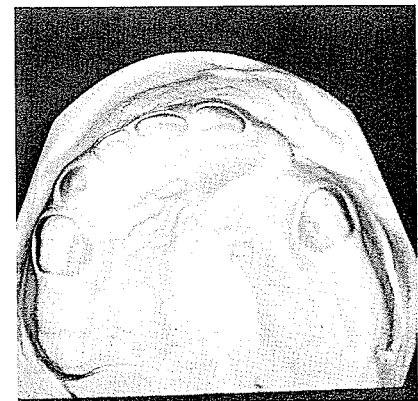
③ ↓

2 months

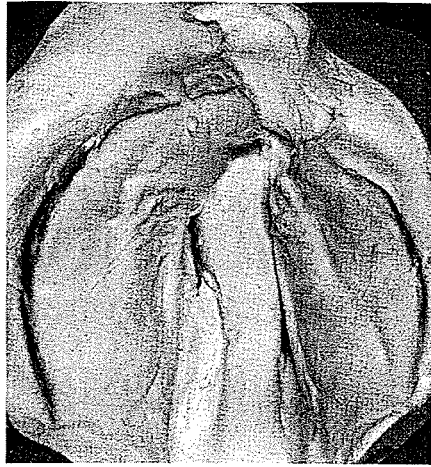


↓

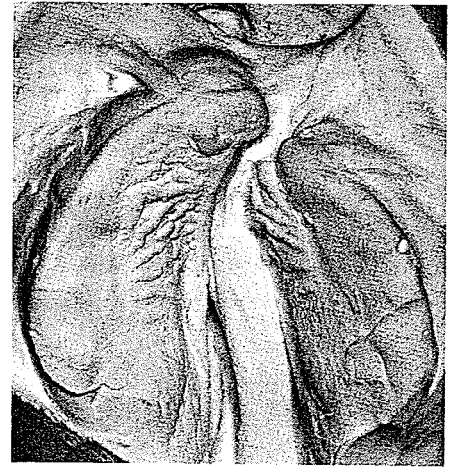
1½ years



Abutting palatal segments



1 month



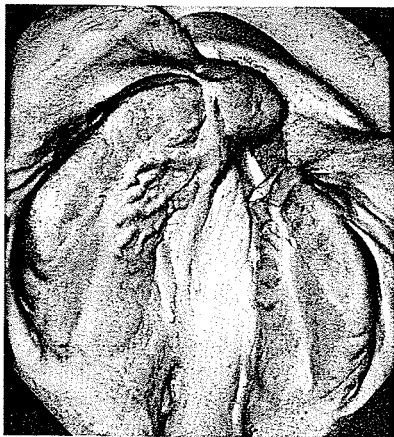
3 months after lip surgery

*Approximation without contact of alveolar borders*

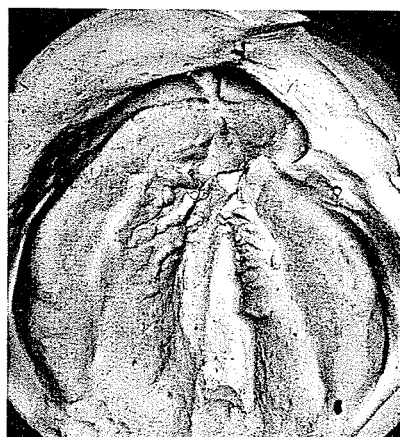
The lateral segments may fail to touch because the inferior turbinate of the lesser segment makes contact with the nasal septum. (Aduss and Pruzansky, 1967). When the inferior turbinate was removed by surgery, the lesser segment moved more medially. When the surgery was done at the age of 4 years with the maxillary buccal teeth in overjet relationship, the occlusion became more nearly ideal. The medial movement of the lesser palatal segment brought the teeth into better relationship. This result supports the belief that in complete clefts of the lip and palate the lateral segments *are overexpanded and not collapsed.*

*Overlapped palatal segments*

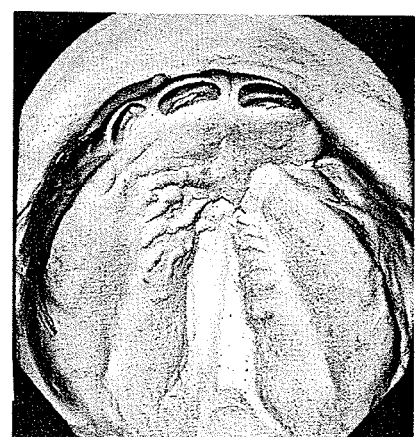
This geometric relationship does not necessarily signify that the teeth in the lesser segment will be in a crossbite relationship at a later date when teeth have erupted. The force of the tongue acting within the vault space can exert lateral pressure against the palatal segments causing them to move outward. Spontaneous correction of overlapped segments has occurred as long as there was an absence of restraining scar tissue. Should a crossbite



1 month



2 months after lip adhesion

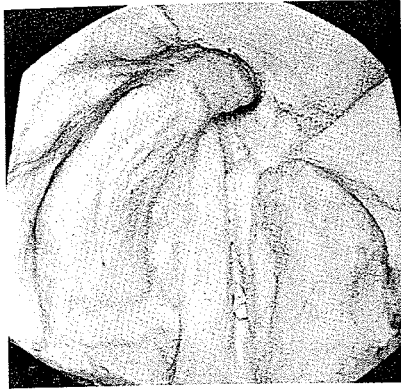


8 months after soft palate surgery

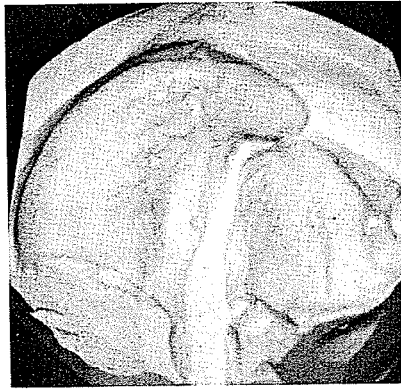
develop, it can be corrected in two or three months by means of tooth-borne expanding appliances.

*Approximation with contact of alveolar borders resulting in excellent buccal occlusion*

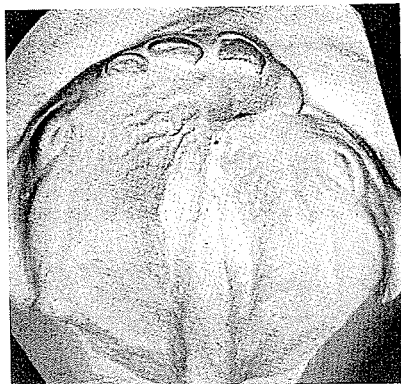
The lip was closed at 1 month and the soft palate repaired at 11 months. The hard palate cleft was closed at 20 months of age.



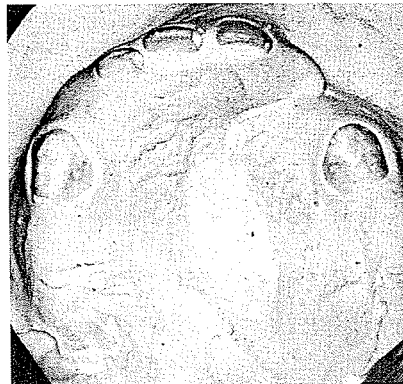
1 month



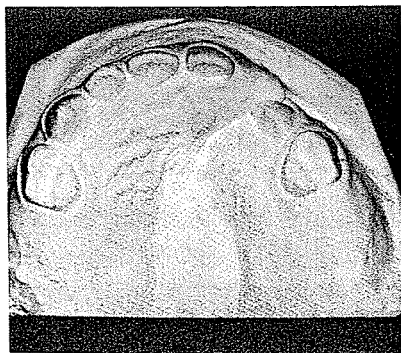
10 months



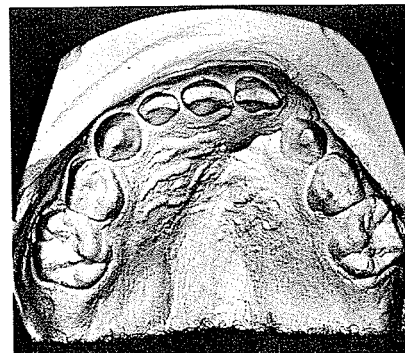
1 year



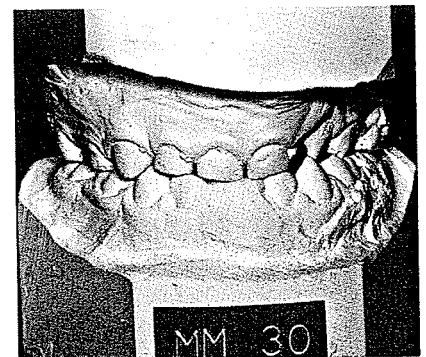
1 year 6 months



2 years 2 months



5 years

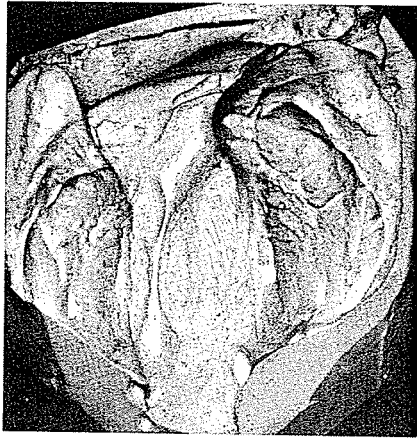


5 years—excellent occlusion

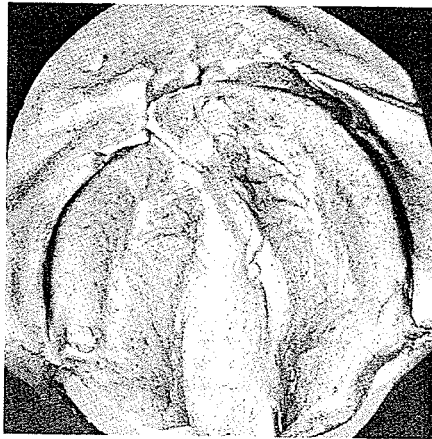
The tip-to-tip buccal occlusion of the lesser segment, first seen at 2 years of age, was still in evidence three years later. The palatal cleft was closed at 16 months.

*Approximation with contact of alveolar borders even with very wide complete clefts*

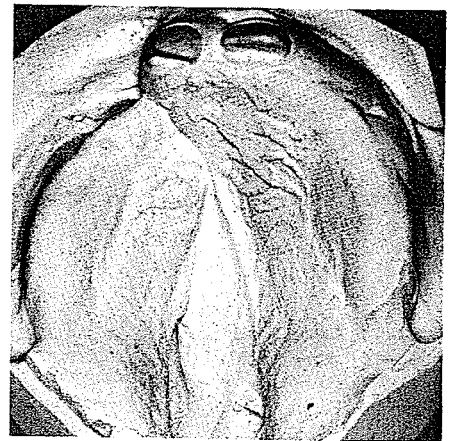
The initial cleft geometric form is not predictive of the subsequent palatal form.



1 month



3 months

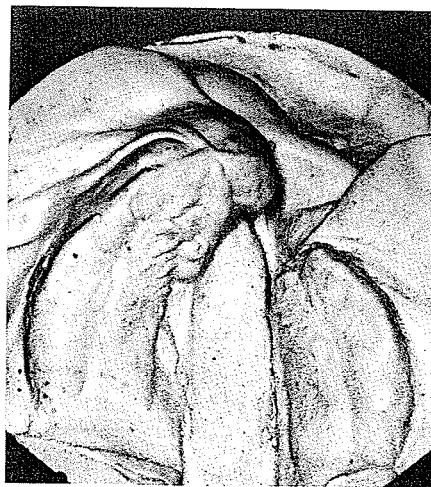

1 year 6 months

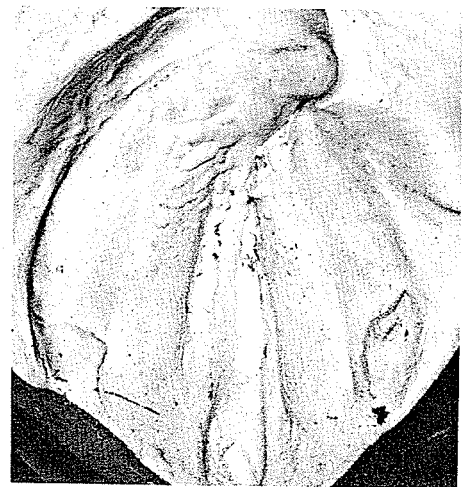#### INFLUENCE OF MOLDING ACTION AND PALATAL GROWTH ON ARCH FORM WITHOUT THE USE OF MAXILLARY ORTHOPEDICS

##### *Palatal growth*

Palatal tissue has the potential of growing to normal size even though at the newborn state it may appear to be excessively small. However, it must be stressed that although the potential does exist for the palate parts to catch up and become the size one would ordinarily expect at later ages, such

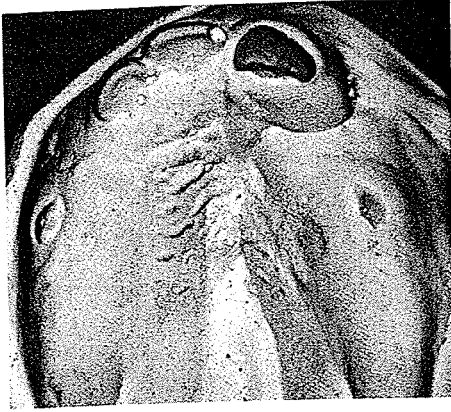


2 months

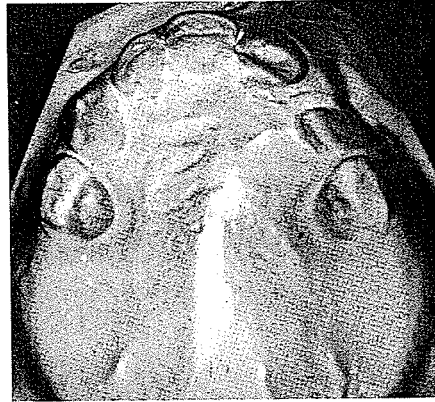


11 months

growth does not always take place either because of surgical disturbances of growth centers or in rare instances because of deficiency in osteogenic tissue.



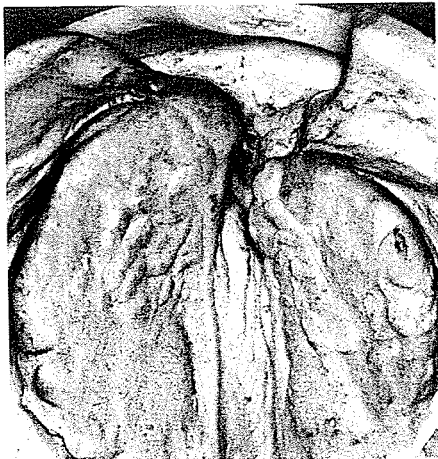
1 year 3 months



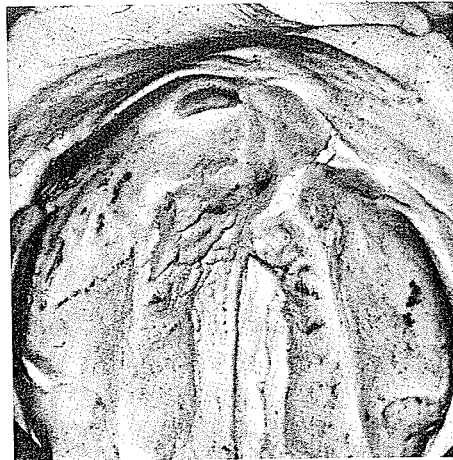
2 years

Increase in palate size occurs spontaneously and at unpredictable times and rates. It is our belief that the palate processes have an innate potential to increase in size and *cannot be stimulated to grow larger than nature intended*. The change in size may occur early in some cases and later in others, but in most instances it *will* occur and the palate eventually becomes the size necessary to close the cleft space rather easily.

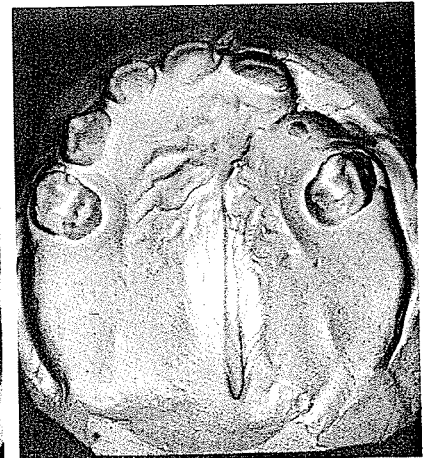
Our clinical findings demonstrate no correlation between the original width of the cleft and the resultant arch form. The amount of tissue undermined in closing the lip may play a small role in determining the ultimate relationship of the palatal shelves, but we are not certain of all the factors involved. There seems to be a contradiction to the findings that wider clefts show a greater tendency toward collapse than did the narrower clefts which were already in a "state of collapse" prior to the lip surgery.



1 month

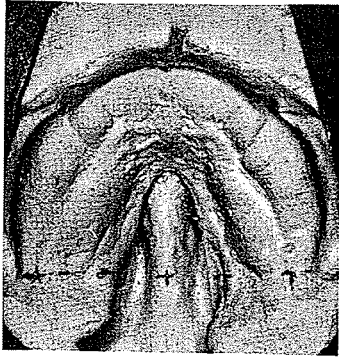


8 months



1 year 8 months

There are no known geometric or quantitative parameters that can be used to predict the ultimate palatal form even when the same surgical procedures are used.



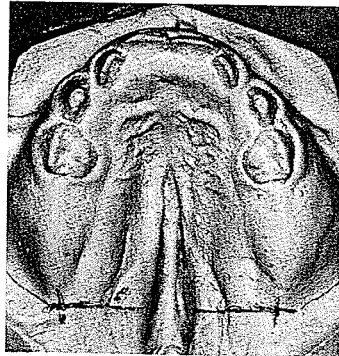
2 months

*Timing of palatal closure*

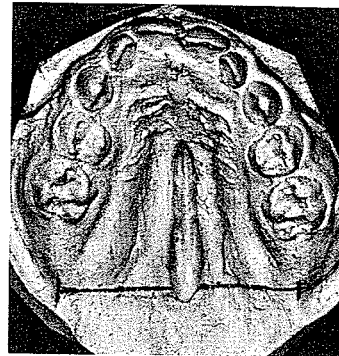Much emphasis has been placed on the need to close the hole before the age of 2 years. Unfortunately age of closure is proposed as the main consideration for the achievement of proper speech production in later years. Timing of palatal closure should be governed by the size of the palatal cleft in relation to the size of the palatal shelves.

Although in some cases it is preferable to close the cleft space before 2 years of age, in other instances it is best to wait until 3 or 4 years of age. We believe that poor speech production is due to many other factors than the mere age when cleft closure is performed.

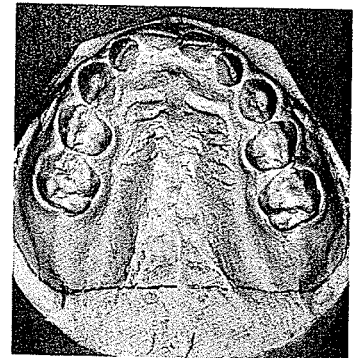
Pierre Robin syndrome; rapid narrowing at the cleft space (Pruzansky, 1955)



1 year 2 months



2 years 1 month

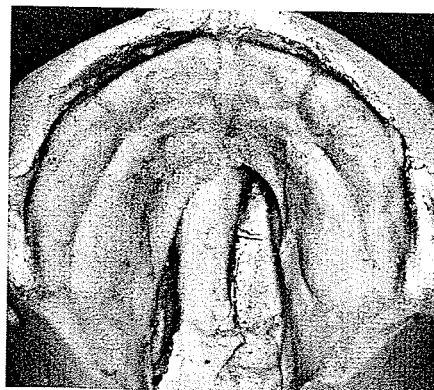


5 years 3 months

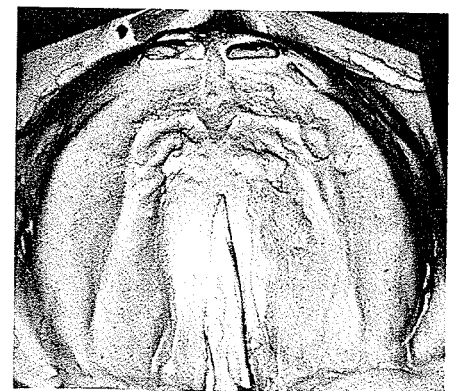
Longitudinal growth studies support the contention that there is no optimal age for repair of the cleft palate. "Timing is an individual matter and is related to the anatomical and functional assets present in the patient." These studies show that a well-designed surgical procedure which is ill timed may lead to long-term failure. Conversely, a technically inferior procedure performed at a proper time can yield superior results.

*Rapid reduction of cleft space in isolated cleft palate*

Early reduction in the cleft space dimensions makes it possible to close the palatal cleft at 10 months without creating growth-inhibiting scar tissue. In some instances it may be advantageous to postpone palatal surgery until 2 or 3 years of age in order to allow for an increase in palatal tissue relative to cleft space.



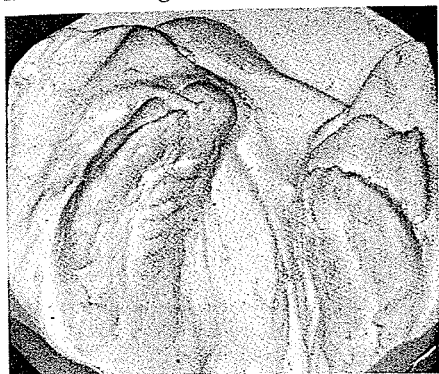1 month



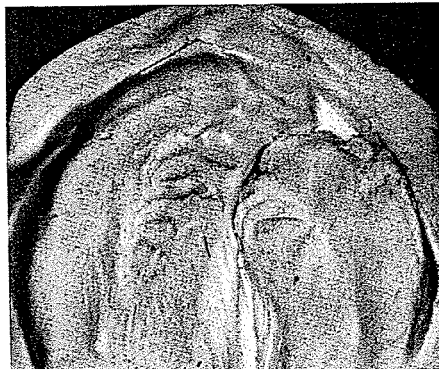10 months

UNILATERAL CLEFT LIP AND PALATE —  
ADVERSE EFFECT OF EXCESSIVE  
PERIOSTEAL UNDERMINING PERFORMED  
AT AN EARLY AGE

In this case excellent arch alignment and closure of the cleft space resulted from molding action and palatal growth.

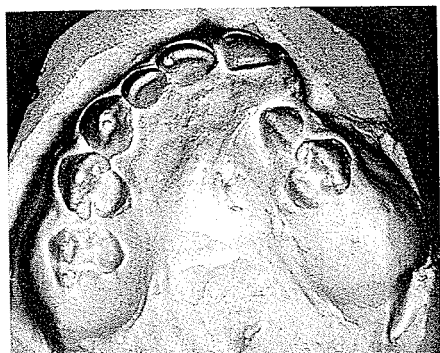


1 month

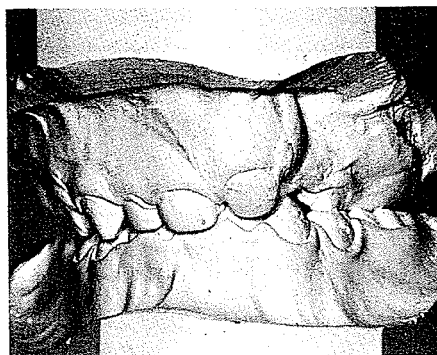


3 months; excellent ovoid arch form, palatal segments abutting

Three months after "island flap" palatal lengthening, there was a buccal crossbite of the left lesser palatal segment. Note the slight transverse palatal scar.

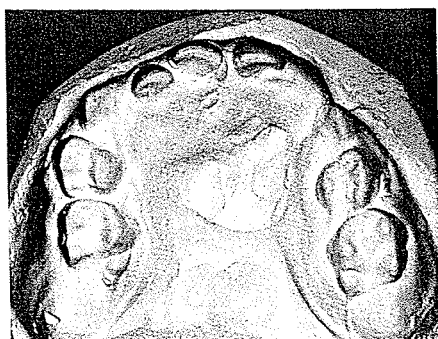


1 year 8 months; arch becoming tapered due to the pull of scar tissue

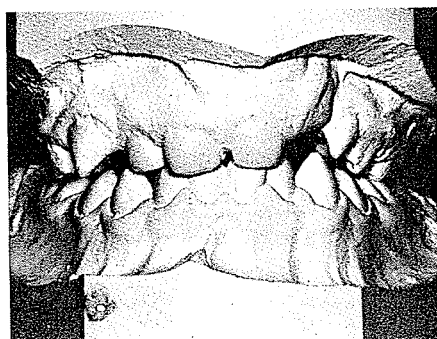


1 year 8 months; buccal crossbite due to medial movement of lesser buccal segment

A fixed palatal expander was used to correct the crossbite; correction accomplished in three months. A fixed palatal retainer was necessary to maintain the new arch form. In the absence of palatal scar tissue the expansion need not *always* be retained by a transpalatal arch. The determining factors are the relationship of the palatal segment and the amount of scar tissue.



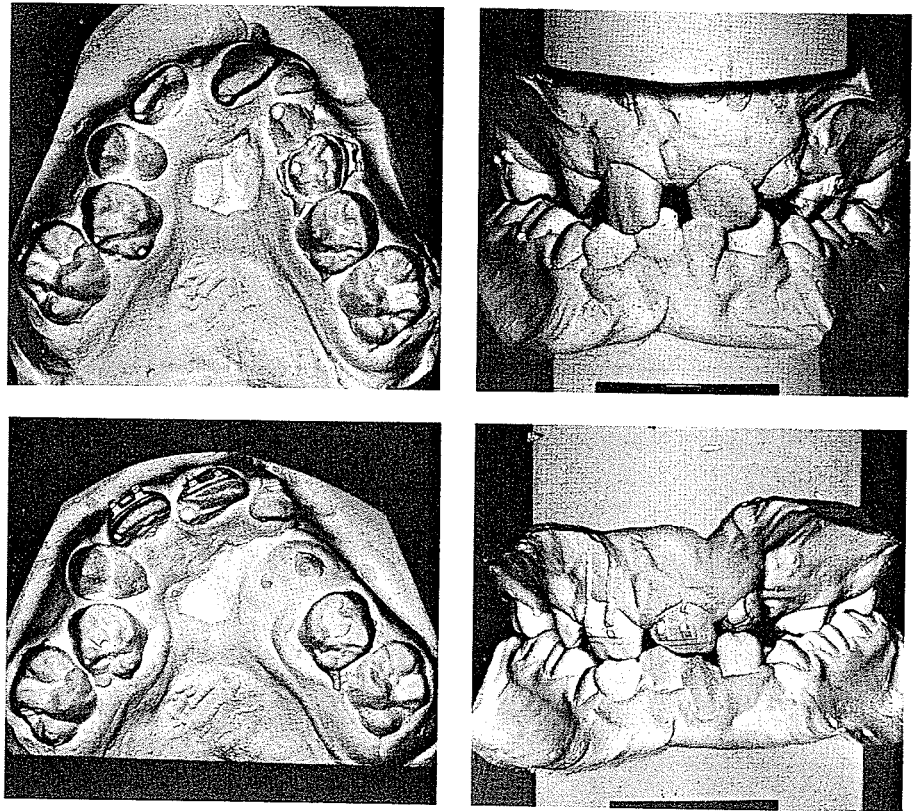
4 years; after arch expansion



4 years; crossbite corrected as a result of lateral movement of lesser buccal palatal segment

The retainer was lost. The transverse scar is very prominent and has drawn the involved teeth medially, causing an hourglass-shaped palate. The adverse effect is also seen in the developing anterior cross-bite and crowding.

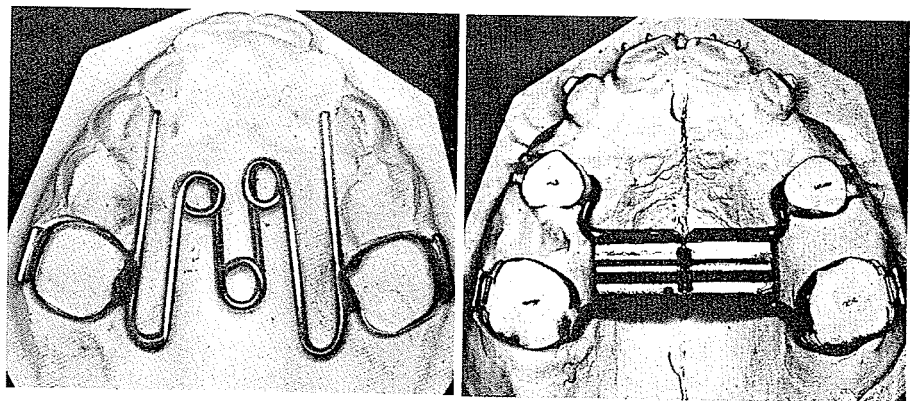
Maxillary development was adversely affected in all three dimensions.



7 years

CORRECTION OF MEDIAL COLLAPSE OF PALATAL SEGMENTS BY ORTHODONTIC EXPANSION—DECIDUOUS OR EARLY MIXED DENTITION

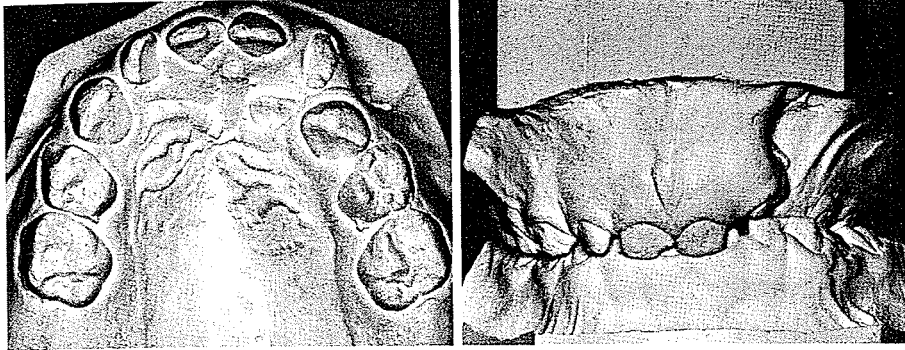
In complete clefts of the lip and palate, the united orbicularis oris, buccinator and superior constrictor pharyngis muscle ring mold the palatal segments which have been displaced outwardly and upwardly by aberrant



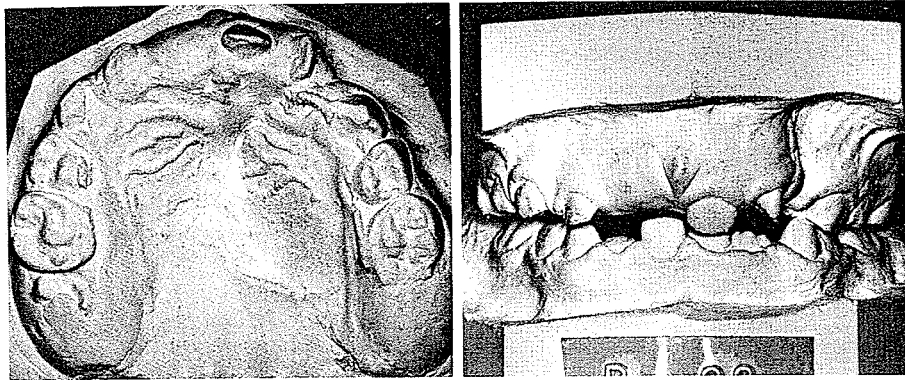
Various fixed palatal expansion appliances



muscle pull. Narrowing of the palatal cleft occurs throughout the entire anteroposterior length of the palatal segments from the incisal papilla to the maxillary tuberosities. This action has been found to take place not only after lip repair but also after soft palate surgery.



5½ years; crossbite of left segment

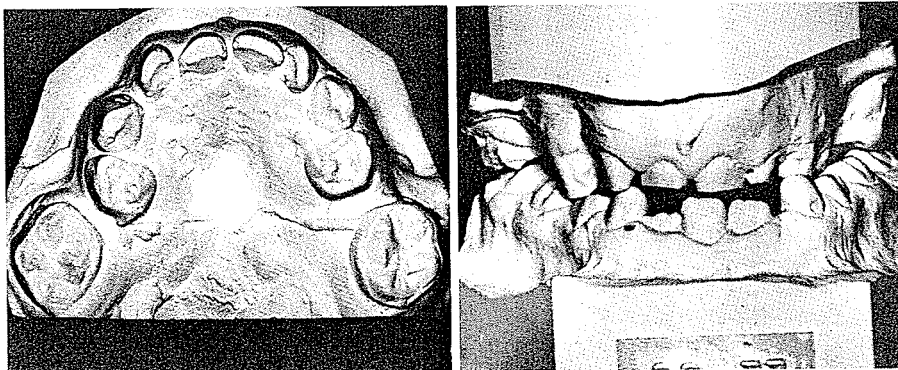


6 years; after lateral expansion

Easy palatal expansion due to absence of restricting scar tissue

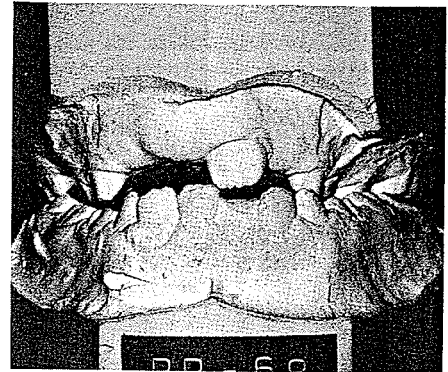
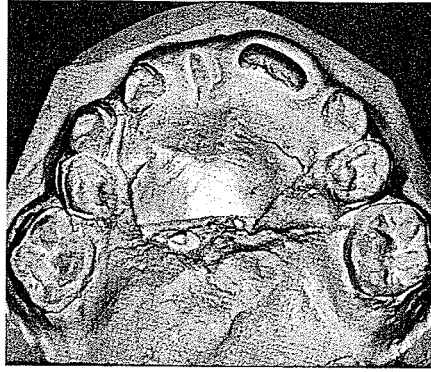
When the alveolar process of the smaller segment becomes contained within the premaxillary alveolar element of the larger segment, a dental crossbite occurs between the maxillary and mandibular teeth. Dental dysplasia may or may not coexist with segmental dislocation.

Correction of a crossbite in the deciduous dentition has been shown to improve dental function, nasal respiration, maxillary alveolar development, speech development and facial aesthetics.



6 years; before expansion

Difficult expansion due to presence of resistant palatal scar tissue

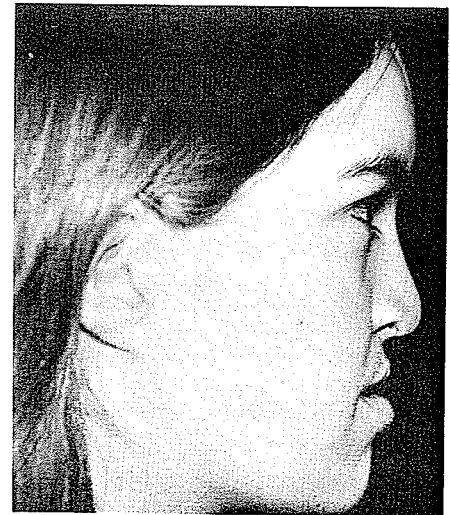
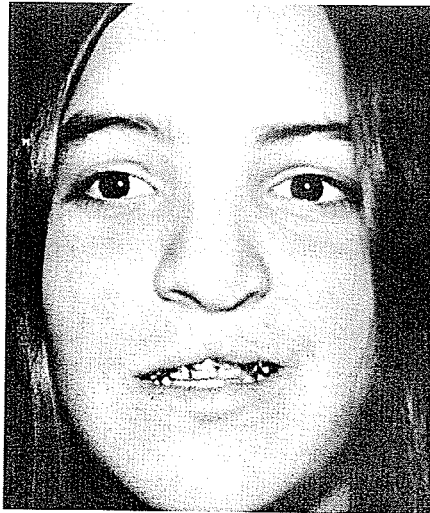

7 years; after expansion. If a transpalatal scar exists, permanent retention is necessary.

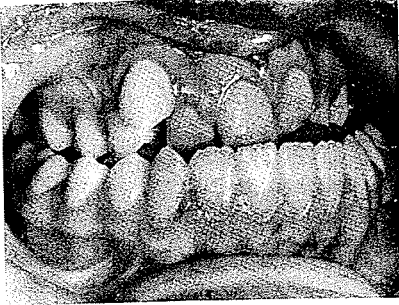
Orthodontic therapy is directed toward counteracting the muscular influences created by lip surgery. An outward-directed force establishes a more normal arch form and widens the nasal cavity. This movement carries the inferior turbinate with it, increasing the distance from the nasal septum (Aduss and Pruzansky, 1967).

#### AN ANTERIOR DENTAL CROSSBITE IN AN ADULT DOES NOT SIGNIFY PRESENCE OF A HYPOPLASTIC MAXILLA

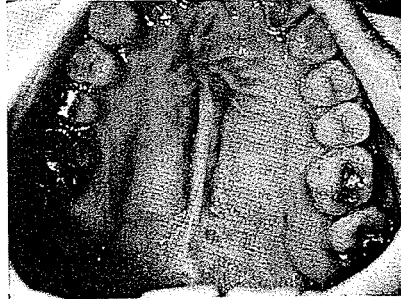
Maxillary dental dysplasia can be due to faulty eruption patterns associated with hypertonic lip and cheek musculature. A non-scarred palate permitted the expansion and advancement of the buccal and anterior teeth with less concern for future relapse.



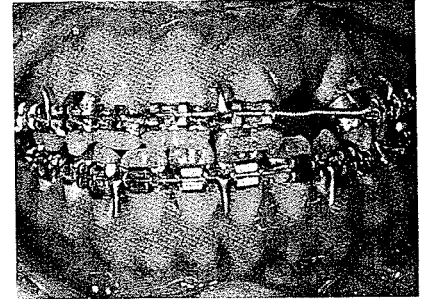
The closed left maxillary lateral incisor space was recovered and a normal anterior overjet and overbite relationship established after two years of orthodontic treatment. The missing tooth was replaced, and the buccal segments were retained with a fixed dental bridge which spans both sides of the cleft.



15 years

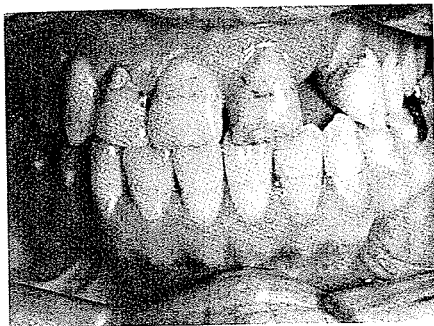


Vomer flap used to close palatal defect

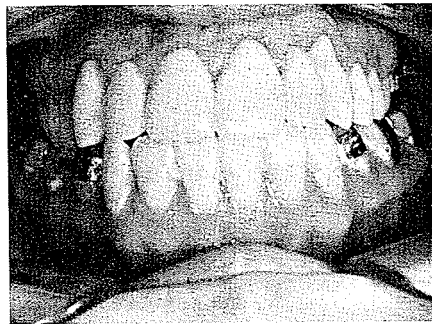


17 years

The ability to advance the maxillary incisors into a proper overjet relationship is the most reliable means for evaluating basal bone adequacy and normal maxillary development.


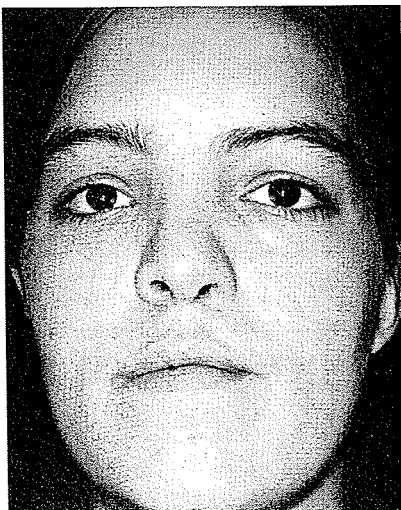


18 years

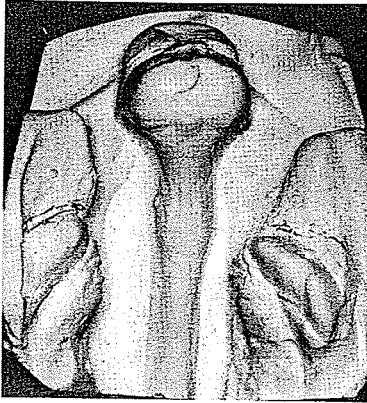

The left lateral incisor space was opened to receive a tooth of equal size as the right lateral incisor. A maxillary fixed bridge was created to replace the missing tooth and maintain the palatal segmental relationship. Placement of teeth in their proper relationship is dependent on palatal segment relocation as well as tooth movement.

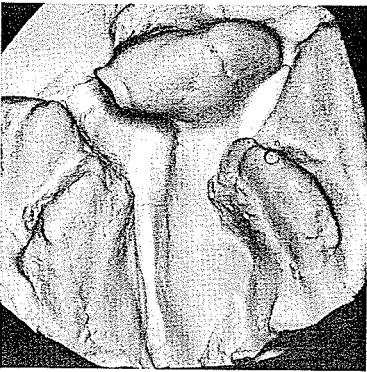
Improvement in soft tissue profile was achieved after the teeth were relocated and the lip and nose revised.



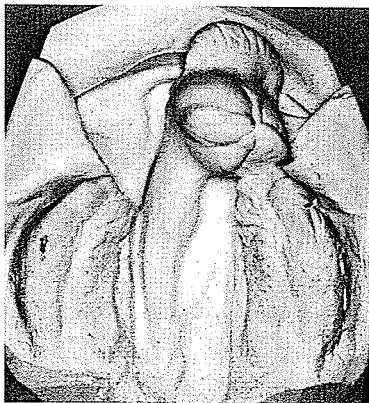Classification based on the presence or absence of soft tissue attachments



Complete bilateral cleft of lip and palate with a severely projecting premaxilla



Complete bilateral cleft of lip; complete cleft of palate on right side and incomplete cleft of palate on left side



Bilateral incomplete cleft lip left side, complete cleft right side; incomplete palate cleft right side, complete cleft on left side

## BILATERAL CLEFT LIP WITH OR WITHOUT PALATE. WHY DOES THE PREMAXILLA PROTRUDE AHEAD OF THE PALATAL SHELVES?

Which of three mechanisms is operative? (1) There is an overgrowth of the premaxillary-vomerine complex response to altered muscular physiology, the result of unrestrained growth at the premaxillary-vomerine suture. (2) The projection of the premaxilla is an illusion created by underdevelopment or retroposition of the palatal shelves associated with micrognathia or retrognathia. (3) A combination of the above factors is in effect.

Recent research has reported that the complete bilateral cleft lip and palate deformity is characterized by an overgrowth or excess of mesoderm at the premaxillary-vomerine suture (Pruzansky). Our own clinical research using serial casts and roentgenographs refutes Burston's earlier statements (1958) that

The bilateral condition is characterized by two retroplaced and small maxillae. The central stem of the premaxilla is relatively protrusive. It should be noted that although this latter element may be somewhat rotated in an upward direction, the actual amount of true over-development is often quite limited and the major defect lies in the retroplaced maxillae.

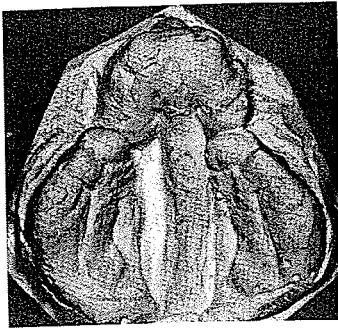
The incomplete bilateral cleft lip and palate shows relatively less geometrical distortion to all three palatal segments, whereas the complete bilateral cleft of the lip and alveolus with or without palate is characterized by an extreme forward projection of the premaxilla and in relation to the facial complex. When the cleft includes the secondary palate as well, the palatal segments are laterally positioned to varying degrees of distortion. In complete bilateral clefts the prominent premaxilla has long been recognized as one of the principal obstacles to successful bilateral lip and palate repair. However, time is an ally, and the singular lesson that has been learned from serial growth studies is the need to be patient and allow the palate and face to grow and develop at their individual rates.

## VARIATION IN GEOMETRICAL RELATIONSHIPS AND SIZE OF PREMAXILLARY SEGMENTS

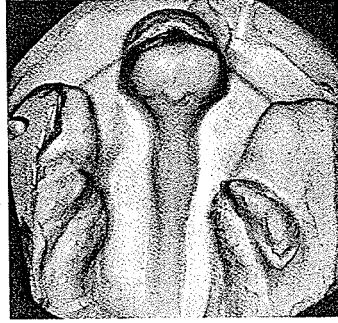
Any number of geometrical variations can exist between the palatal shelves and the premaxilla. For these and other reasons the molding effect of lip repair on the palatal segments and the resulting palatal form will vary from one case to another.

The size of the premaxilla is determined by the number of tooth buds it contains. There may be one, two, three, four or even five buds, either with one or both permanent central incisors alone or with one or both lateral

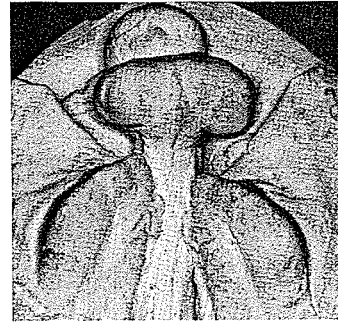
Variations in size and relationships of the premaxilla to the palatal segments at the newborn period



Large premaxilla making contact with well-developed palatal segments

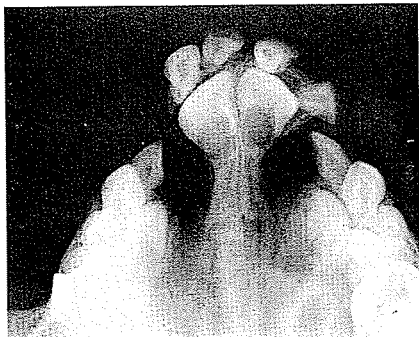

Small premaxilla projecting ahead of small laterally displaced palatal segments

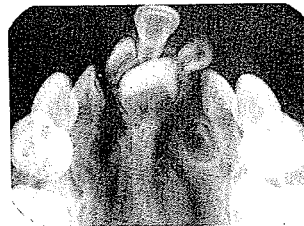


Large premaxilla due to the presence of four deciduous and four permanent tooth buds. The lateral palatal segments have not been displaced because of their attachment to the nasal septum.

incisors. These teeth are sometimes malformed or displaced from their normal position. In rare instances there is only one central incisor, the other being malformed or even missing. In some cases the palatal segments contain extra deciduous and permanent lateral incisors on either side of the cleft. If they are present on both sides of the cleft, the premaxilla may appear to be much wider than the available space between the palatal shelves. This situation can create the illusion that the palatal segments are in crossbite when in fact they may be in excellent relationship.



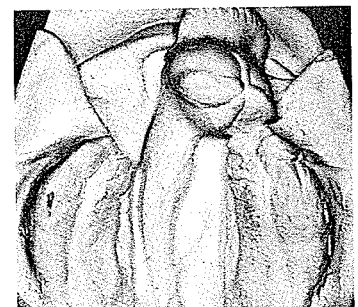A symmetrical premaxilla with four tooth buds. A wire placed through the premaxilla will devitalize the teeth, leading to their destruction.



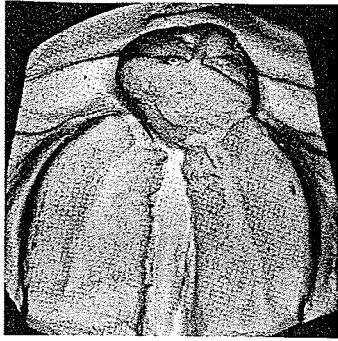
Small premaxilla with three deciduous teeth but only one permanent central incisor. Note extra teeth developing in the line of the cleft.

*Geometrical changes resulting from molding action (Rapid closure of cleft space in incomplete bilateral cleft lip and palate.)*

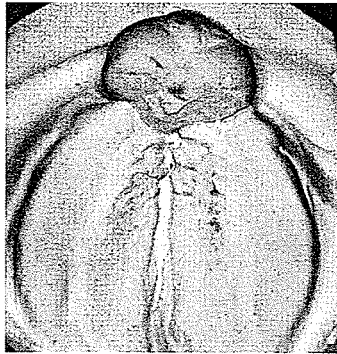
It is not possible to predict the final form of the maxillary arch (the relationship of the premaxilla to both palatal shelves) according to the original size and/or geometrical relationship of the three parts. The premaxilla in complete bilateral clefts may in some instances fit within the



1 week of age before surgery



3 months. Medial movement of the palatal shelves plus palatal growth reduces cleft space.



8 months. Medial movement and growth to all three segments further reduces cleft space.

palatal shelves, but usually it is finally positioned forward of them. For the palatal shelves to fall behind the premaxilla does not signify that they are medially displaced and the teeth will be in crossbite. Only in rare cases will the three segments come together in perfect arch alignment.

Both cephaloroentgenographic and cast analysis demonstrate that lip reconstruction or the use of external traction brings almost immediate reduction in premaxillary projection because of ventriflexion, the fulcrum being the premaxillary-vomerine suture. Septal buckling has been demonstrated in my computerized tomography studies. Marked facial change and reduction in the anterior cleft space result from the ventriflexion.

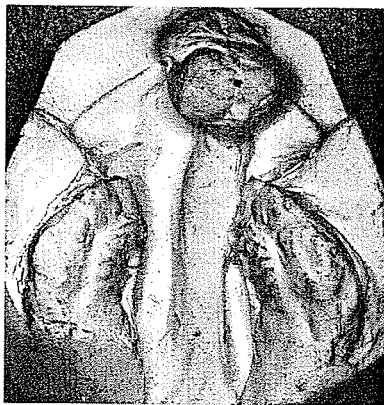The figures demonstrate that excellent arch alignment can occur within the first year irrespective of the degree of premaxillary projection and lateral palatal distortion. In each instance the premaxilla came in contact with the lateral palatal processes although lying well forward of the lateral palatal shelves in the initial state.

#### THE CONCEPT OF "CATCH-UP GROWTH"

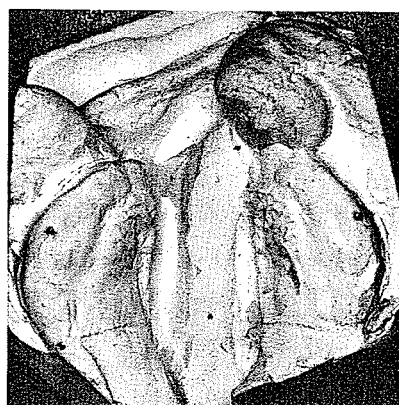
The surgeon, when planning the habilitation of a newborn with a complete bilateral cleft lip and palate, must rely heavily on the following *facts*:

1. At birth, all three palatal segments are geometrically distorted, but after lip surgery the molding action will bring the segments into a more normal relationship.
2. Uniting the lip will reduce premaxillary projection by ventriflexion with or without septum buckling. The profile can continue to flatten because of differential facial growth.
3. Further molding coupled with palatal growth will continue to reduce the remaining cleft space to more manageable proportions.
4. The inherent facial pattern will ultimately determine the handling of the premaxilla.

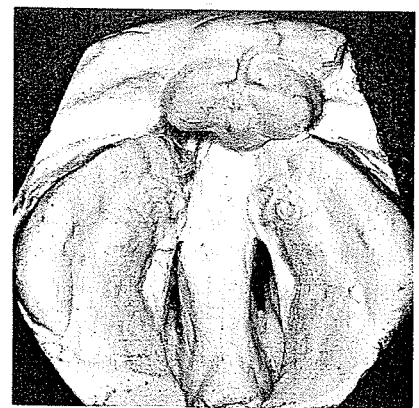
#### Two-stage lip repair



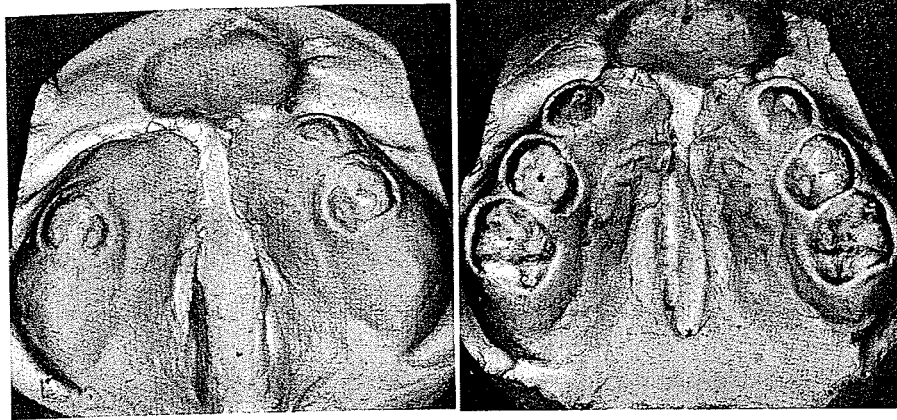
21 days



3 months; left lateral flexion of the premaxilla



8 months; the premaxilla is now centered due to the pull of the united lip musculature



1½ years

3 years 8 months

(After Slaughter and Pruzansky, 1954)

### SERIAL GROWTH CHANGES TO THE COMPLETE BILATERAL CLEFT LIP AND PALATE (after one- or two-stage lip repair)

When judging palatal growth changes from casts, one must visualize an imaginary line (F-F) connecting the posterior end of each alveolar crest as the baseline from which to view anteroposterior growth. This line connects palatal landmark points which are comparable to cephalometric landmarks PTM (pterygomaxillary fissure) and marks the junction between the hard and soft palate.

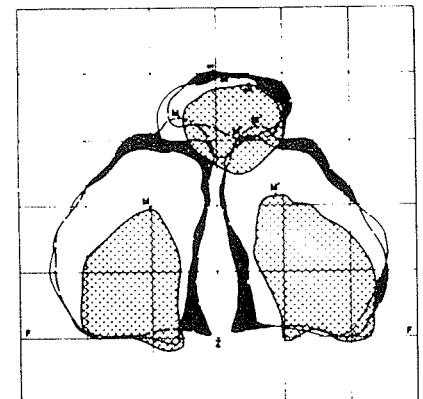
Some workers have said that the lateral palatal segments, since they are detached from the nasal septum, are deficient in size (McNeill-Burston). It is my belief, acquired from looking at many serial casts, that, although the palates look smaller at the newborn period, they grow very rapidly and may approach normal size by the age of 3 years.

#### *Superimposing three palatal stages of the previous series*

Outlines of the first, fourth and fifth cast of the above case are superimposed on the line representing the posterior limit of the hard palate. Point Z is the registration mark for superimposition purposes only. The following conclusions can be drawn from this and other palatal growth studies; they demonstrate the limits of predictability of palatal change.

1. The premaxilla shows little anterior movement after lip repair. The repaired lip appears to retard the forward growth of the maxillary complex, thus contributing to the flattening of the facial profile.

2. The lateral palatal segments demonstrate excessive anterior and medial growth. The anterior growth rate exceeds that at the medial border. *The three-dimensional surface area of the lateral palatal segments doubled in 1½ years.* Between 1½ and 3½ years there was an additional 25 percent increase in surface area.



Antero-posterior growth changes of the midface showing the premaxilla and maxillary outlines of each age superimposed on base line F-F, and registered on point Z.

M = Most anterior part maxilla by inspection

α = Most anterior part premaxilla by inspection

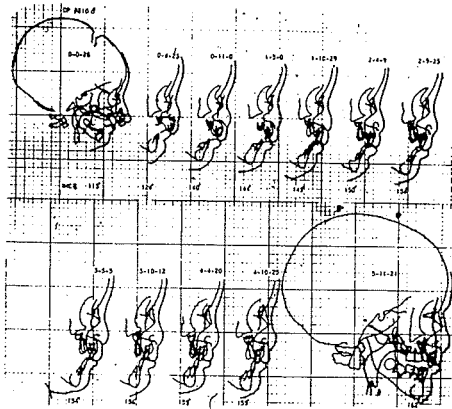
0-0-21	
1-5-0	
3-8-4	

Stereophotogrammetric techniques were used in this study in order to quantify and graphically describe the rate and direction of palatal growth changes.

3. The premaxilla surface area changed only slightly during this same time span.

It is important to reemphasize that the geometrical palatal changes depicted here can be predicted in the majority of other patients. Exceptions are rare. Should the lateral palatal process fail to *catch up* to the premaxilla, then and only then should one consider surgical *setback*.

Why should the clinician want to set the neonatal premaxilla back to relatively smaller lateral processes when all the evidence indicates that within three years these same segments grow forward to reach the premaxilla? Friede and Pruzansky (1972) have shown that when the distance between the palatal shelves and the premaxilla exceeds 25 mm. a poor prognosis exists for conservative premaxillary handling and a retrusion of the premaxilla is in order. The timing for the retrusion is determined by many factors.

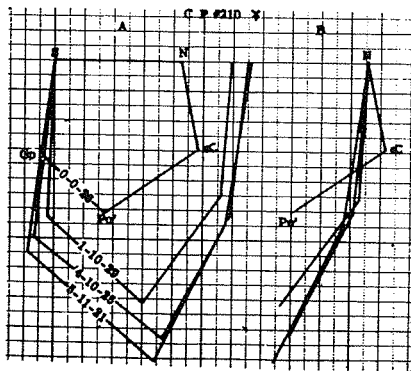


#### THE PROFILE IN COMPLETE BILATERAL CLEFT LIP AND PALATE

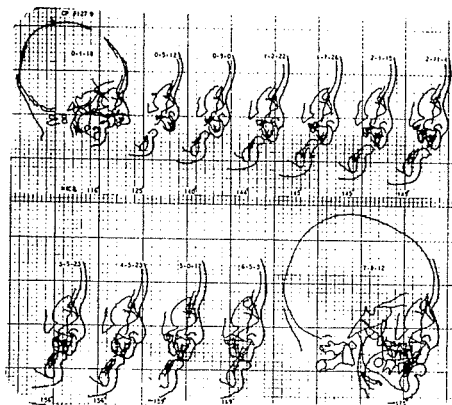
Any number of geometrical permutations may exist between the maxilla, the mandible and the cranial base which will affect the profile. Cephalometric facial growth studies have shown that the skeletal profile becomes less convex with age because of profile remodeling brought on by various growth increments to the upper, middle, and lower face.

Good facial growth occurs where the facial profile flattens with time, and the angle of facial convexity as measured by  $N \alpha Po'$  becomes more obtuse. This change is brought about mainly by the greater increment of forward growth of the chin point ( $Po'$ ) relative to the upper (N) and mid-face ( $\alpha$ ) points. As already stated, lip repair over the projective premaxilla appears to retard the forward remodeling of the maxillary complex (Berkowitz, 1959).

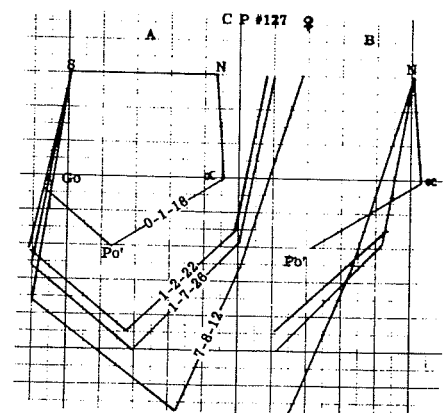
The final profile characteristic will depend on whether the face is prognathic, mesognathic or retrognathic. In different individuals the same bone or group of bones may grow at different rates and at different times. In some



Good facial growth pattern (Berkowitz, 1959)



Poor facial growth pattern necessitating premaxillary repositioning (Berkowitz, 1959)





the same bone will grow rapidly and attain its full potential at an early age while in others it will grow more slowly but for a longer period of time.

The evaluation of success or failure of surgery cannot be made on aesthetic grounds alone and must be postponed until facial growth is nearly complete.

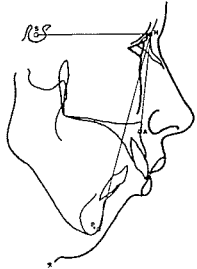*Good facial growth*

The change in the profile was rapid on account of excellent mandibular growth and upper face development. The profile (angle of facial convexity) changed approximately 30 degrees within 1½ years.

*Poor facial growth pattern*

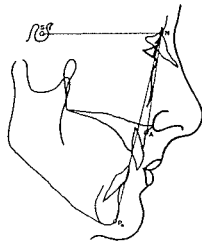
A disharmonious facial pattern represents the extreme of facial variation as seen when the premaxilla protrudes in a retrognathic face. Most faces show a growth pattern leading to reduction in profile convexity, the greatest change occurring during the first year of life. Although mandibular prognathism is the extreme of facial variation in the opposite direction, when found in complete bilateral cleft patients it may be beneficial.

SNA—85° SNP<sub>0</sub>—75°



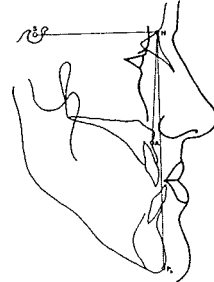A. Retrognathia

SNA—80° SNP<sub>0</sub>—75°



B. Orthognathia

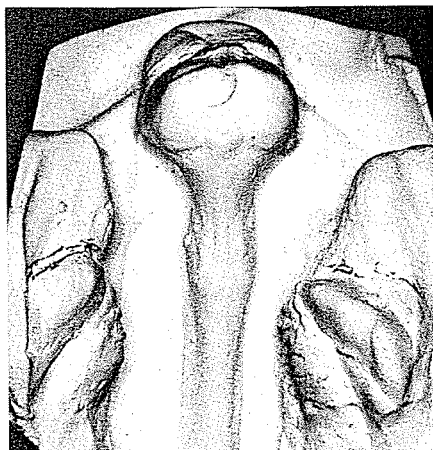
SNA—83° SNP<sub>0</sub>—90°



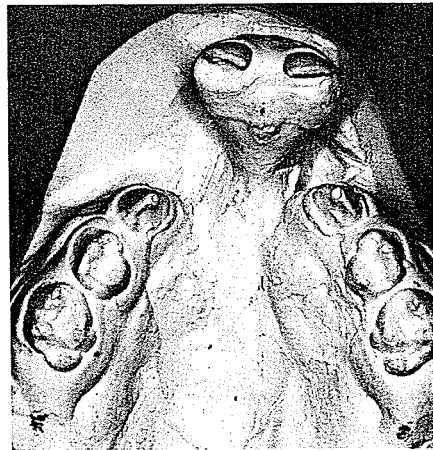C. Prognathia

One cannot predict at an earlier age what the final profile will be. The continuing flattening of the profile until adulthood is a common occurrence. This reduction in facial convexity is mainly due to differential mandibular growth.

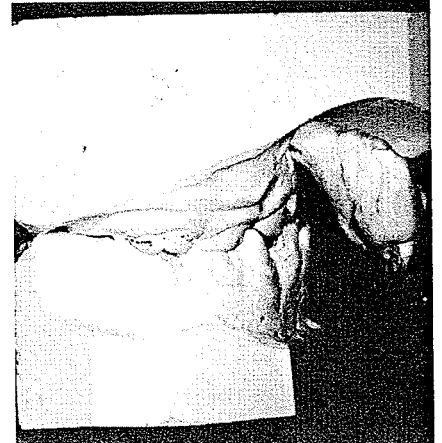
*Poor palatal growth pattern*



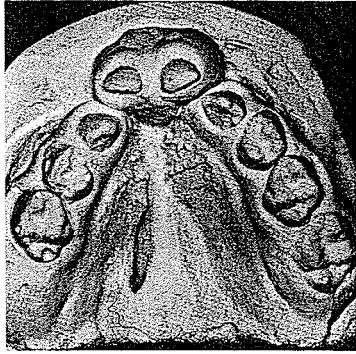
1 month



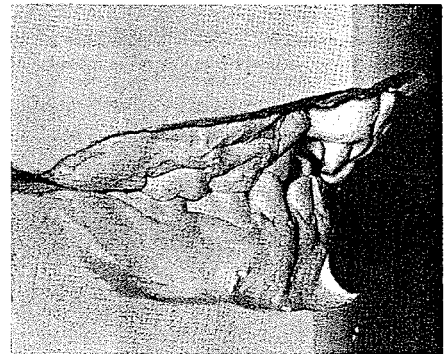
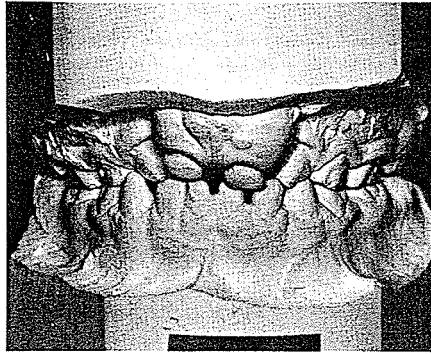
5½ years; excessive anterior cleft space



5½ years; premaxilla is in severe overjet-overbite relationship



6 years; after surgical setback



When poor palatal growth pattern coexists with a poor facial growth pattern, the profile is placed in double jeopardy and retrusion of the premaxilla is warranted.

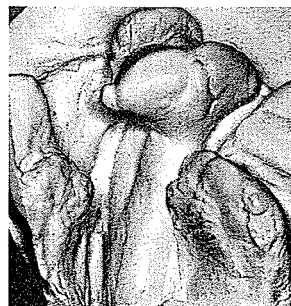In complete bilateral cleft lip and palate the distance between the lateral palatal shelves and the premaxilla is a measure of the palate deformity. If it is excessive at 5 years of age—that is, if the premaxilla is not in contact with the palatal segments—one might have to consider surgical setback at some later date. The ultimate decision is made only after the profile is evaluated as well.

In this case the serial profile tracings showed that the premaxilla needed to be surgically set back since it was demonstrated that there was no further reduction in the angle of facial convexity ( $N \alpha Po'$ ).

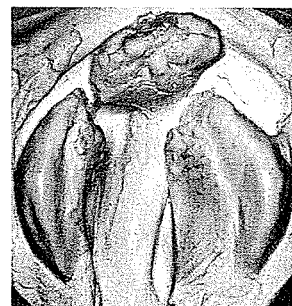*Good palatal growth pattern*

Rapid resolution of the palatal deformity was achieved by molding action and good palatal growth within the first year.

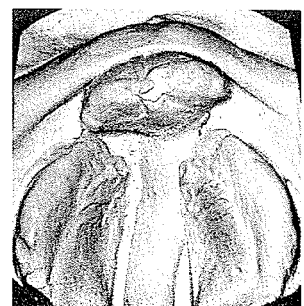
Sequences of molding action brought on by uniting the lip, resulting in almost perfect arch alignment.



2 months

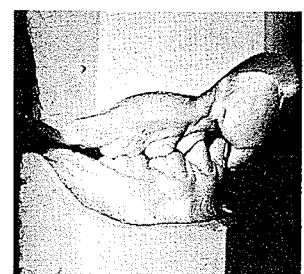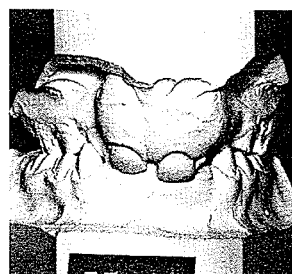
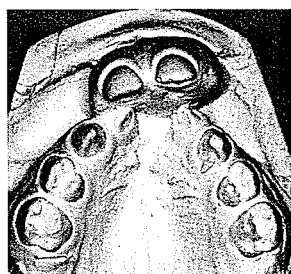


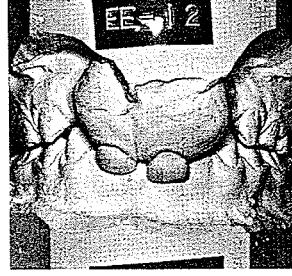
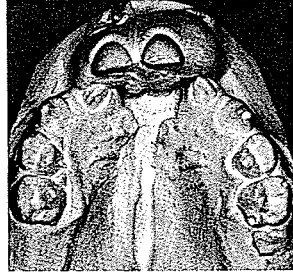
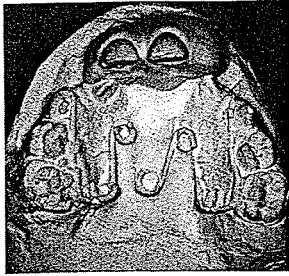
3 months; after lip surgery



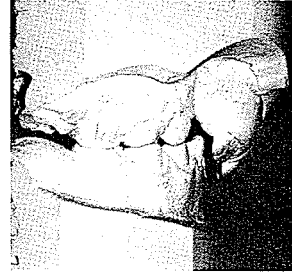
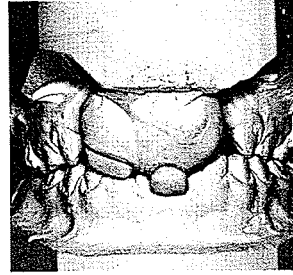
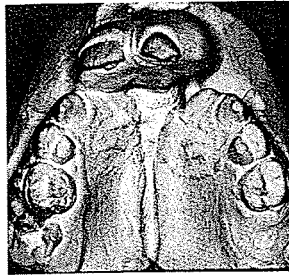7 months

4 years 9 months. Soft palate closed at 8 months. Slight crossbite of the right side. No overjet but steep overbite.





5 years; after three months of orthodontic treatment. Bilateral buccal expansion using fixed tooth-borne appliance. Crossbite corrected by moving the palatal segments laterally.

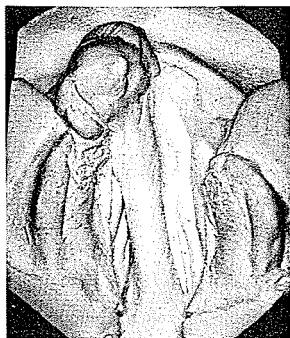

6 years. Deciduous lateral incisors were extracted to permit improved premaxillary alignment. Palatal cleft was closed with no adverse effect to the palatal architecture.

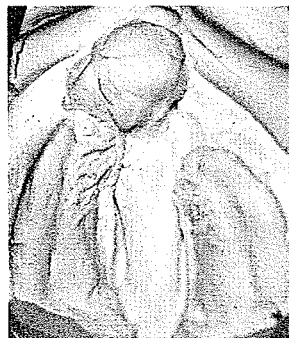*Comments.* The severe premaxillary overbite doesn't pose any functional problems. It will be corrected by orthodontic means in the permanent dentition.

*Incomplete bilateral cleft of lip and palate left side and complete cleft of lip and palate right side. Good palatal growth pattern*

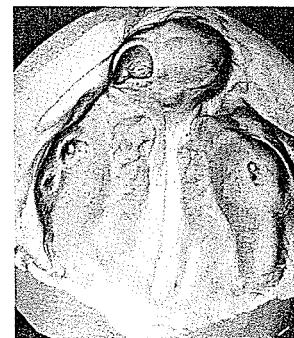
Rapid resolution of the palatal deformity was obtained. The most laterally displaced palatal segment was moved medially and the premaxilla rotated into proper relationship. This movement, coupled with appositional palatal growth, markedly reduced the cleft space. The teeth on the most laterally displaced left segment ended up in a slight crossbite which will be easily reduced with a fixed expander. Correction of the buccal crossbite is dependent on the movement of the entire lateral palatal segment. The correction will have to be maintained by a fixed retainer until the permanent teeth erupt. After final orthodontics, a permanent bridge will be used to replace the missing teeth and to maintain proper arch form. Bony fixation of the palatal segment is, therefore, not essential. Facial growth studies have shown that primary bone grafting has interfered with maxillary development and has failed to maintain arch form.



16 days

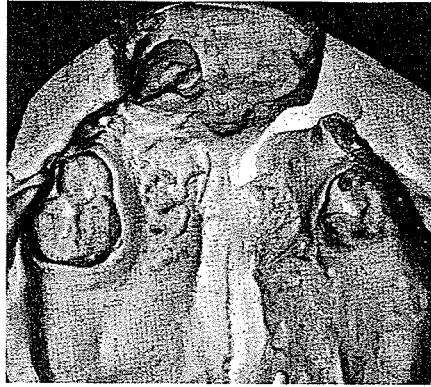


3 months

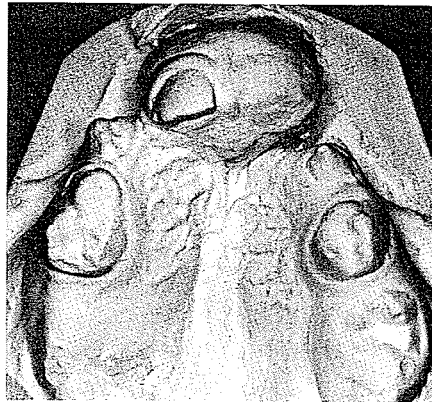
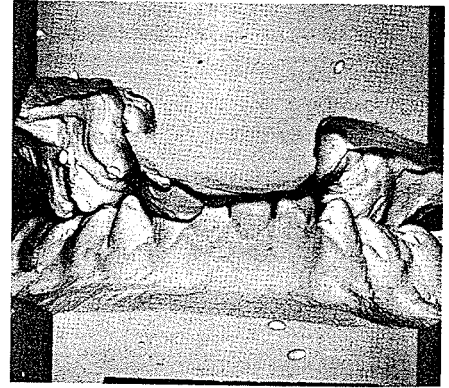


1 year 6 months

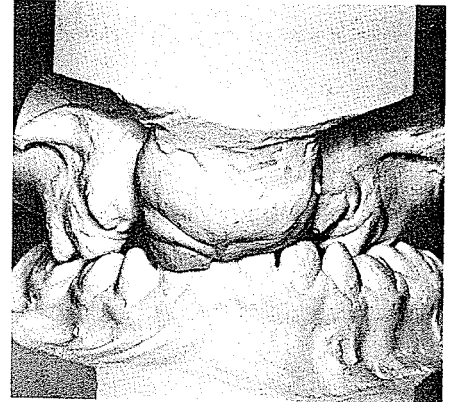
*Comments.* The possibility that a crossbite might occur at 2 years of age does not justify neonatal orthopedics.



2 years 3 months

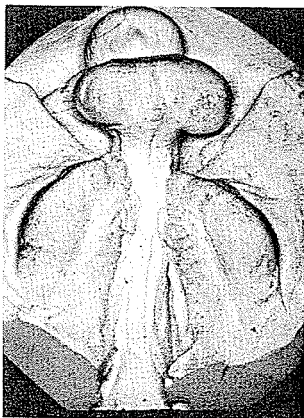


2 years 8 months; after palate closure

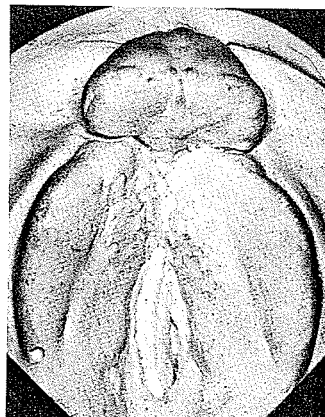


*Complete bilateral cleft of lip and incomplete cleft of palate on both sides*

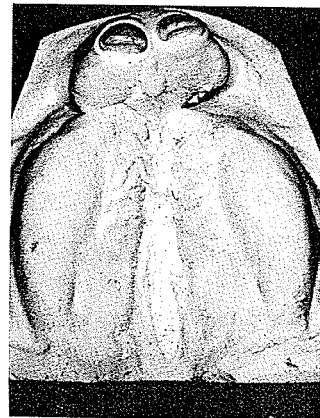The palatal segments, which at first appear to be collapsed medially, are actually in an excellent relationship with the premaxilla. This case dramatically demonstrates the strong potential for palatal molding and growth to reduce the initial geometric disproportion.



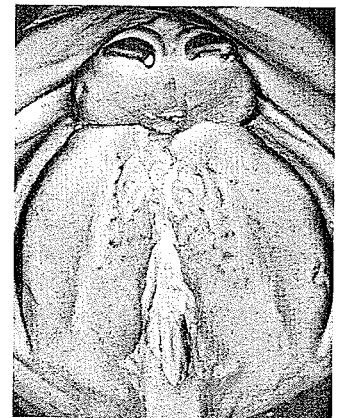
2 months



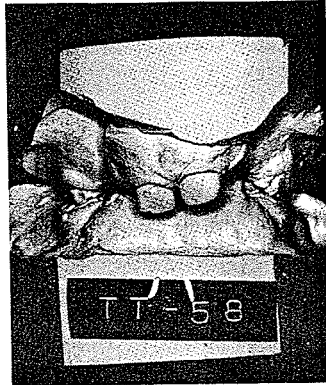
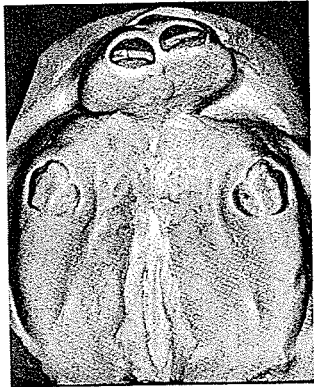
8 months; after lip and velar surgery



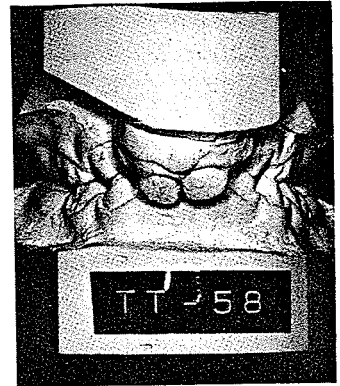
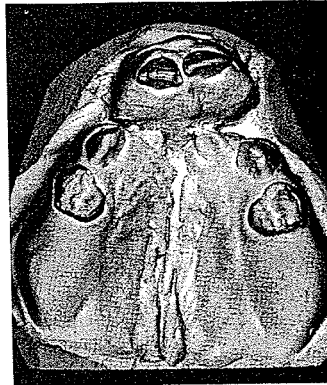
1 year



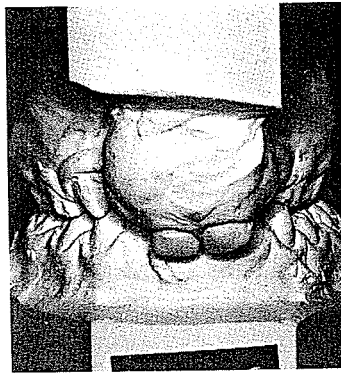
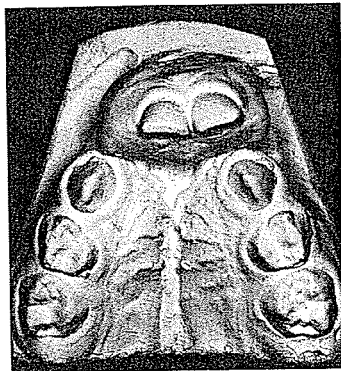
1 year 5 months



1 year 8 months. The displaced deciduous lateral incisors create an illusion that the segments are collapsed.



2 years 3 months. The cleft space is markedly reduced; there is slight buccal crossbite of the left segment.

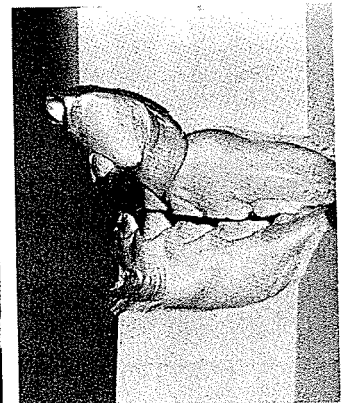
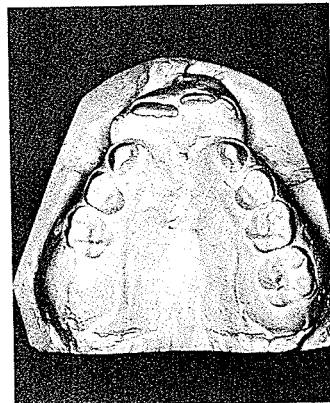
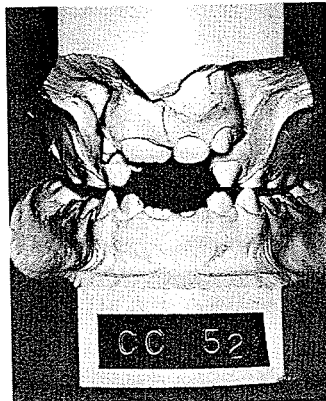
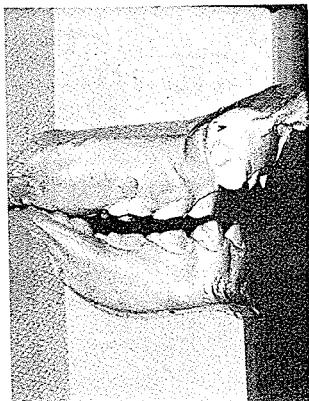


2 years 11 months

*Comments.* The displaced deciduous lateral incisors were extracted to permit the premaxilla to butt up against the lateral palatal segments spontaneously. The palatal cleft is almost completely closed by appositional growth. Except for a slight tip-to-tip left buccal occlusion, the dental relationship is excellent. The overbite will be reduced by orthodontia at a later date and poses no functional problem.

*Correction of an anterior open bite due to a superior displaced premaxilla in a bilateral cleft lip and palate patient*

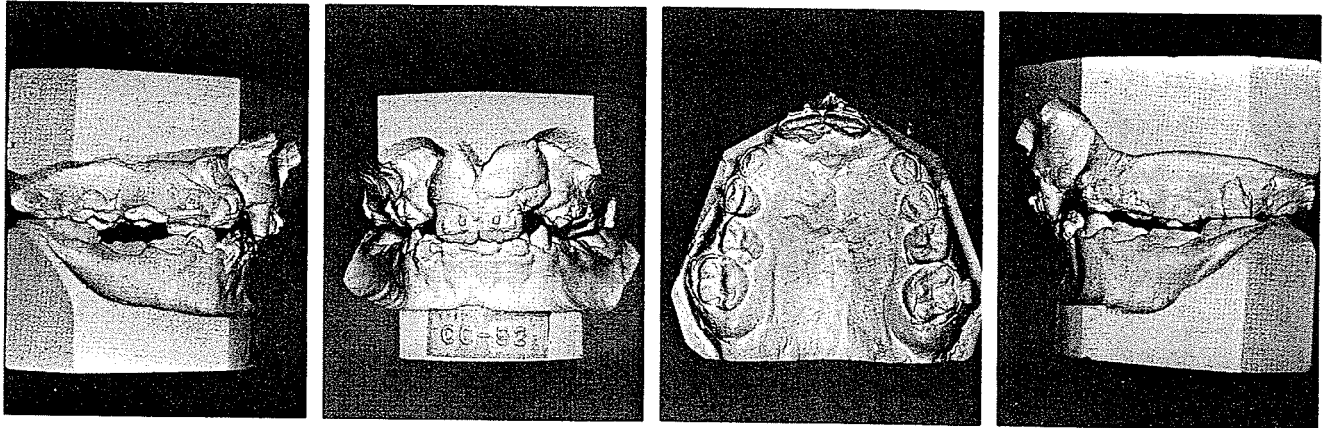
As the face grew and developed the surgically repositioned premaxilla, which was separated from the vomer at an early period, and detached from the lateral palatal segments, ended up displaced high in the nasal chamber. As the premaxilla failed to descend away from the cranial base along with the palatal segments a skeletal anterior open bite resulted. The buccal segments ended up in crossbite as well.



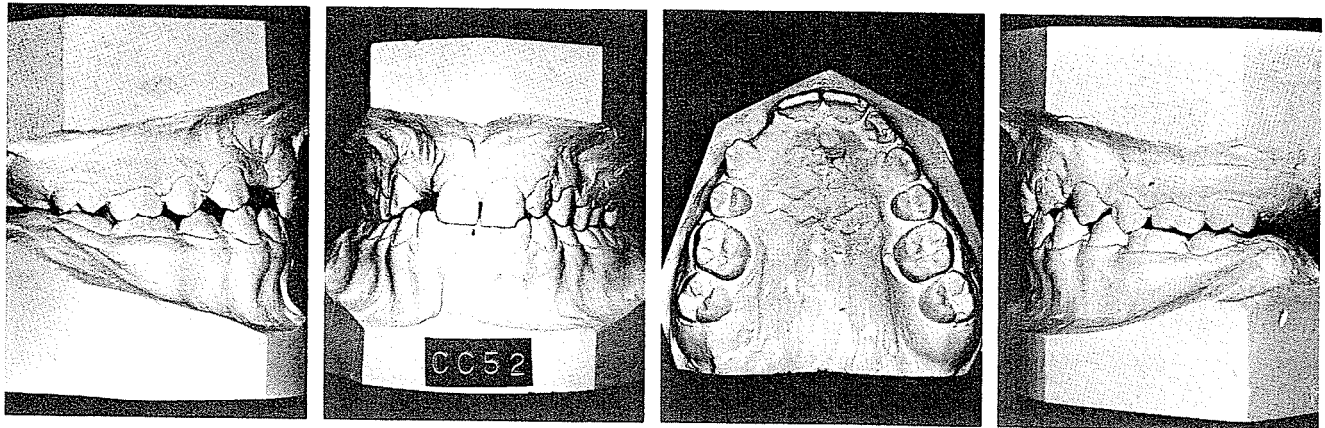
5 years 6 months. Before orthodontic treatment.

As soon as the permanent maxillary central incisors erupted, orthodontics was instituted to reposition them into a normal overbite-overjet relationship. The buccal segments were moved into proper occlusion at the same time.

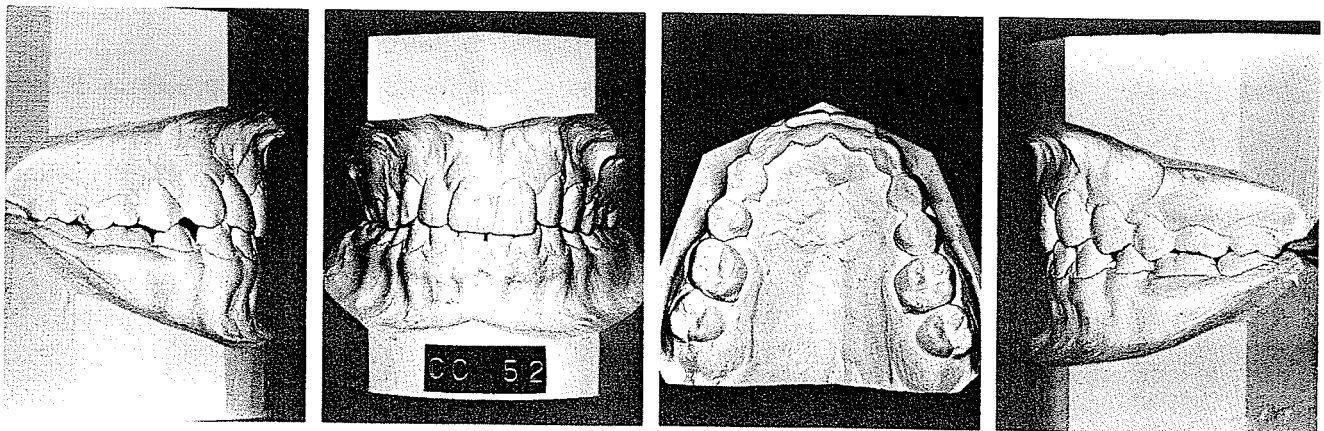
7 years 6 months.



15 years. After final orthodontics.



15½ years. Fixed bridge inserted.



Final orthodontic treatment involved the removal of all first bicuspids in order to uncrowd the posterior teeth and to align the maxillary anterior teeth into proper overbite-overjet relationship. The left lateral incisor was moved into proper position even though a bone graft was not inserted in the line of the cleft. The right lateral incisor was congenitally missing and its space maintained for a false lateral incisor to be inserted later.

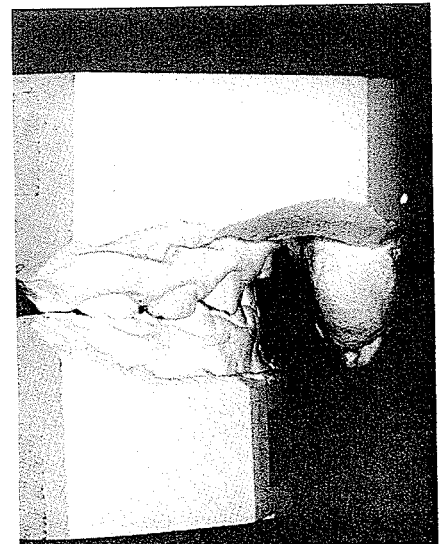
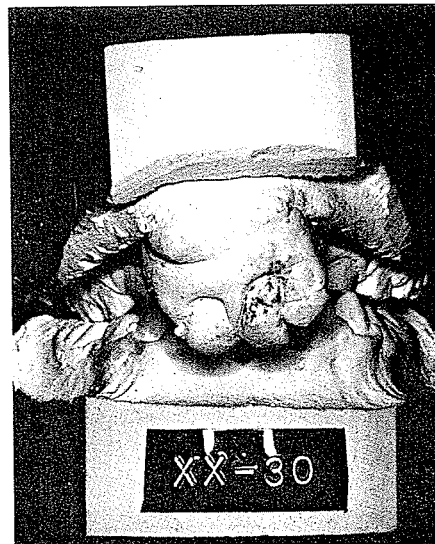
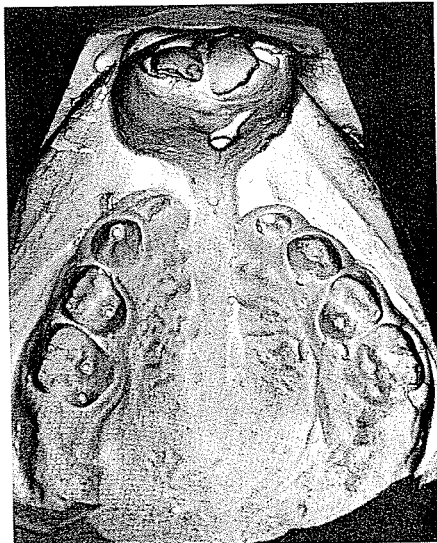
A maxillary bridge was placed between the right and left second bicuspids in order to stabilize the maxillary segments and replace the missing right lateral incisor. Relocation of the palatal segments were dependent upon the absence of restricting palatal scar tissues. Note the excellent vault space which permits normal tongue position and speech articulation.

The excellence of this result does *not* support early premaxillary retro-positioning.

### SURGICAL PREMAXILLARY RETRUSION

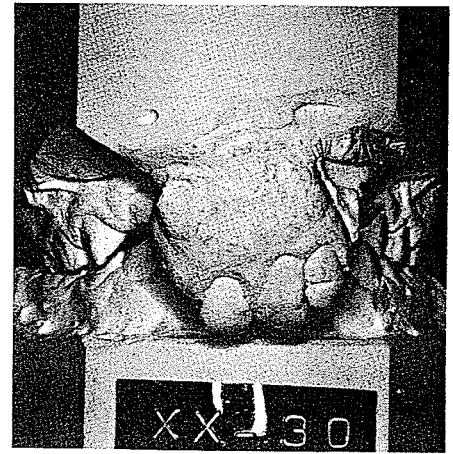
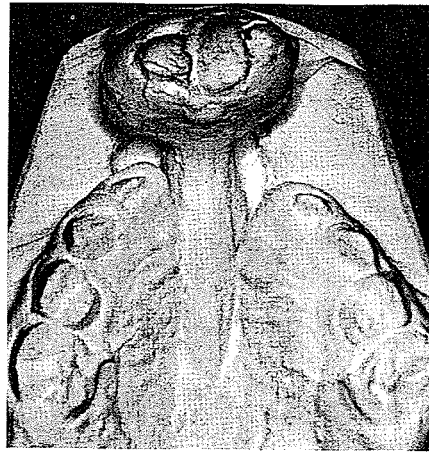
#### *Premaxilla surgically set back in late deciduous dentition*

Because of the severe facial deformity and consequent malocclusion, it was decided that premaxilla setback should be immediately performed, without waiting for the permanent dentition. The objective was to eliminate the anterior cleft space and to bring the premaxilla into physical contact with the palatal segments. The premaxilla was to be stabilized in



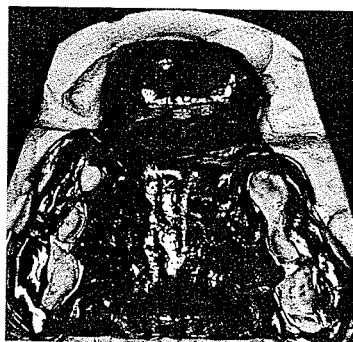
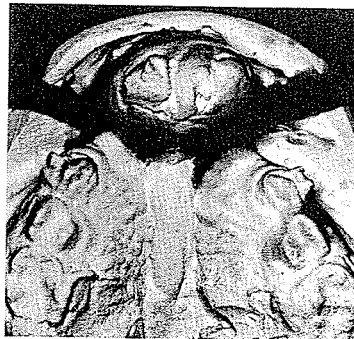
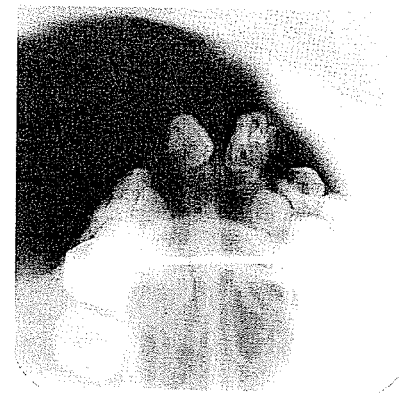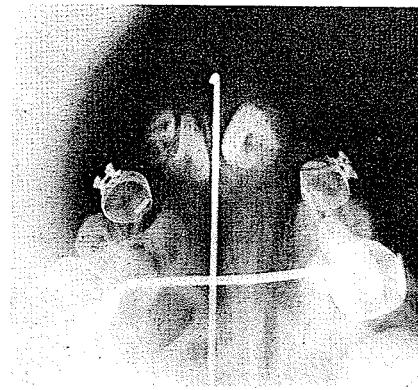
4 years; severe overbite and overjet

4½ years; lateral palatal expansion in order to accommodate the wide premaxilla



three dimensions to allow for a possible bony union with the lateral segments. A removable prosthesis was used for fixation. In my experience a *Kirschner wire* not only fails to stabilize the premaxilla in any dimension but often causes deformations to the central incisors. Its use for any purpose should be abandoned.

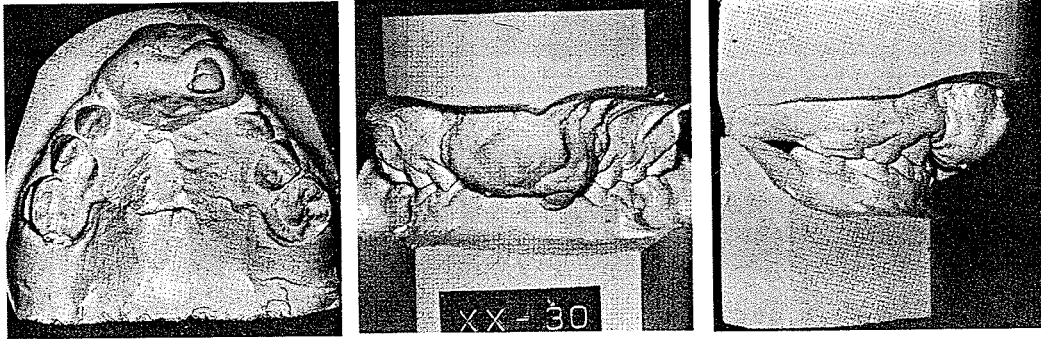
Use of a wire to stabilize the premaxilla (?) Immediately after insertion and 6 months after removal. The wire penetrated the dental developmental sac, disrupting the formation of the central incisors.



Fabrication of a removable prosthesis for premaxillary stabilization

Bands with lugs were placed on the deciduous molars to increase retention capabilities. A working maxillary cast was made and the premaxilla cut and repositioned against the palatal segments. Care was taken to place the premaxilla in proper geometrical position so that a normal overjet-overbite relationship resulted. A combination acrylic and steel prosthesis was fabricated, allowances being made for tissue swelling. The prosthesis was inserted at the time of surgery and worn for three months. It was removed only to maintain cleanliness. At the end of this time the premaxilla became semi-rigid because of unilateral ossification with the palatal segment.

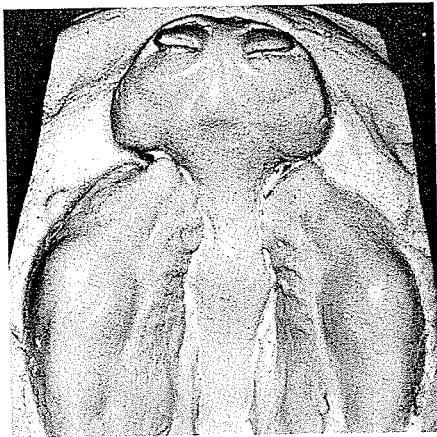




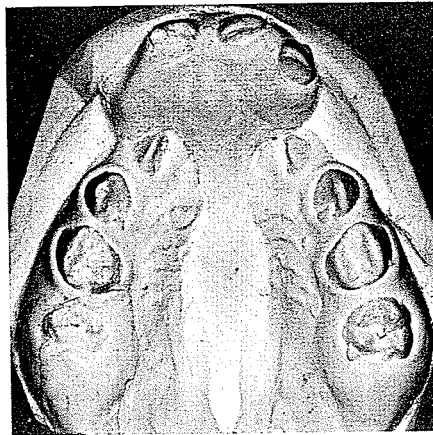
5½ years; 3½ months after surgical setback. Slight overbite with no overjet.

Three months after surgical setback the overjet-overbite relationship appeared to be stable. There was some slight ventriflextion to the premaxilla which posed no long-term functional problem.

*Poor palatal growth with a poor facial growth pattern*

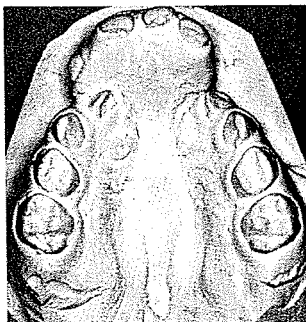


11 months

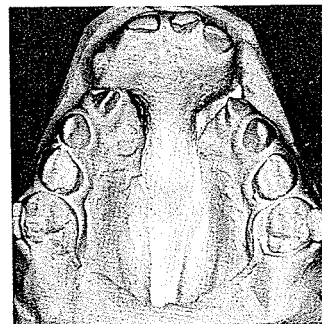
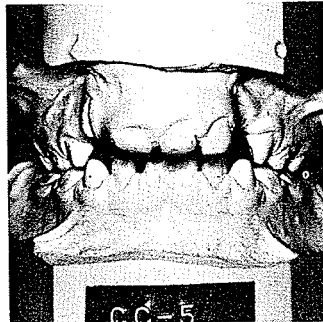

2½ years

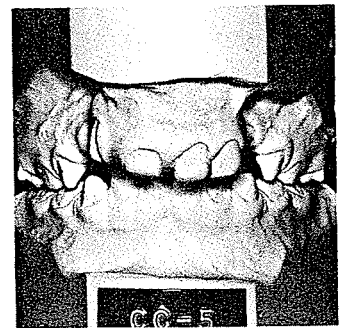
In a case of complete bilateral cleft lip and palate the lip was repaired at 1 month and the soft palate was united at 12 months of age. The deciduous lateral incisors are displaced medially. Although the palatal segments appear to be collapsed when they are related to the wide premaxilla, the occlusion shows them to be in excellent buccal relationship. A moderate-sized palatal cleft remains.

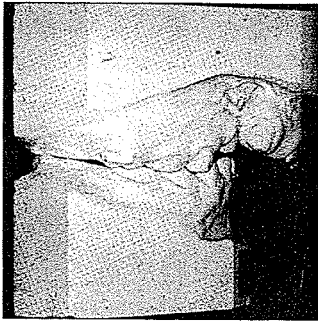


4½ years



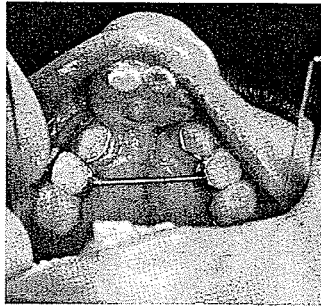
6½ years



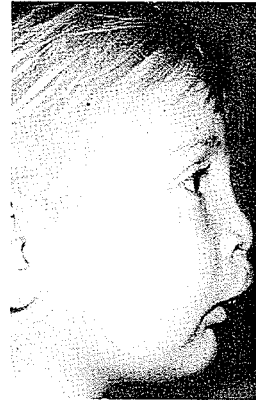
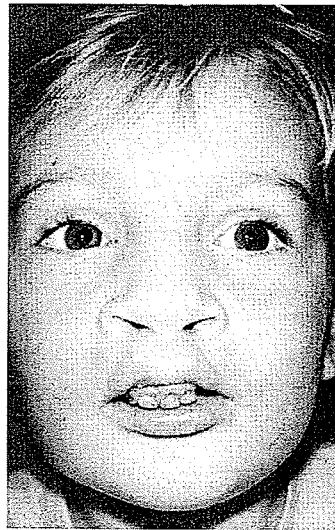
*Presurgical palatal and facial evaluation and palatal preparation*

The premaxilla is to be set back because the anterior cleft space has failed to reduce and is associated with a poor facial growth pattern. The anterior positioned mid-face complex, coupled with a retrusively growing mandible, has created a severe facial convexity. This profile characteristic appeared to be stable at 6½ years of age.

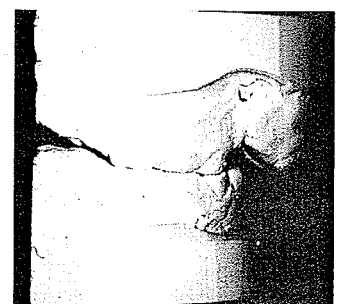
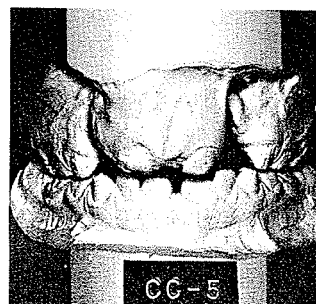
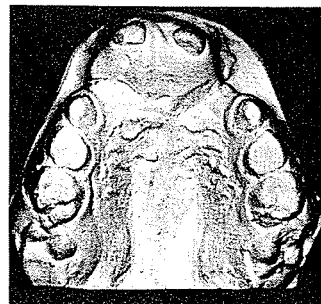


Expansion appliance to widen intra-cuspid distance

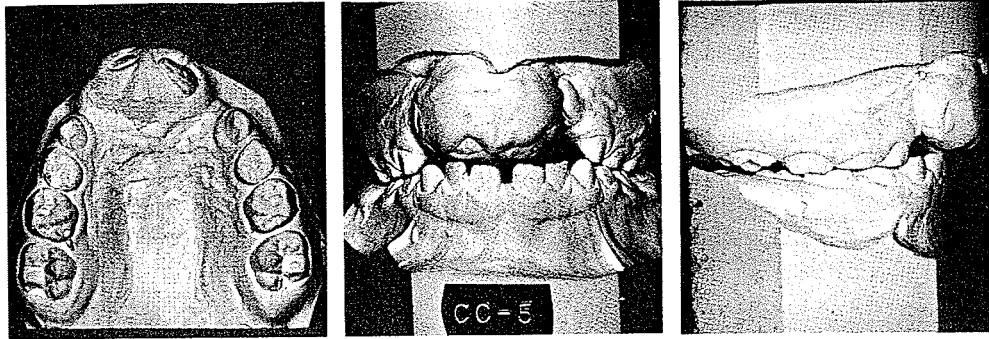


Even with the buccal segments in good occlusion, the arches were overexpanded prior to surgical premaxillary setback in order to permit premaxillary repositioning within the palatal arches. This buccal expansion is not permanent, and it is anticipated that the arches will return to their original position as a result of muscle-molding action.

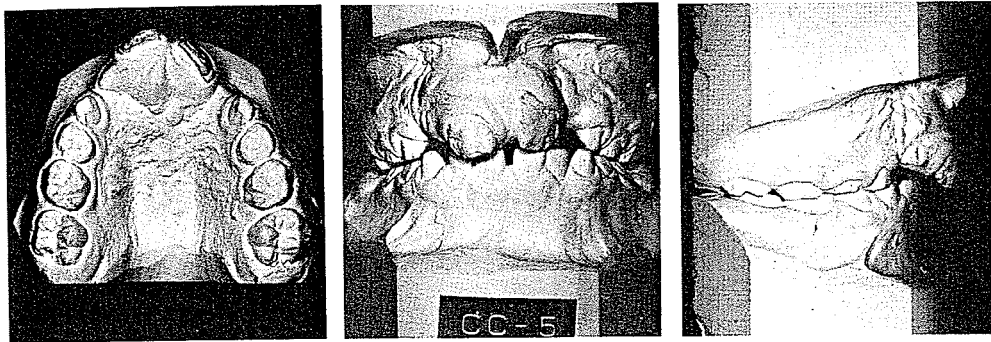
*After premaxillary setback and closure of the palatal cleft*



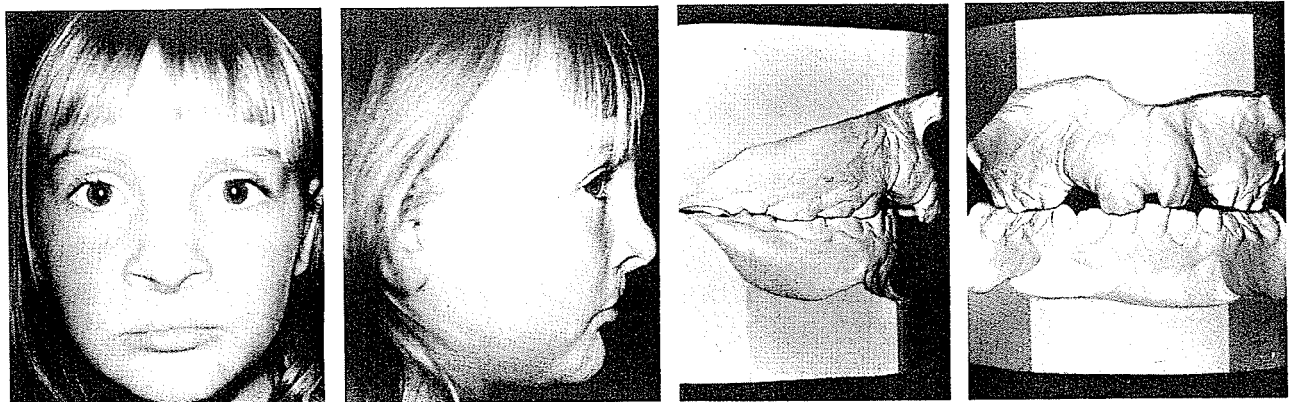
Deciduous lateral incisors were removed and the premaxilla set back. A slight overbite and overjet was established to allow for differential mandib-



ular growth. The overexpanded palatal arches returned to their original dimensions as a result of the muscle molding force.



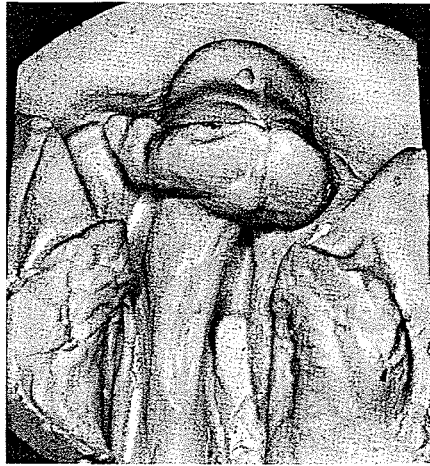
The excellent dental relationship has stabilized.



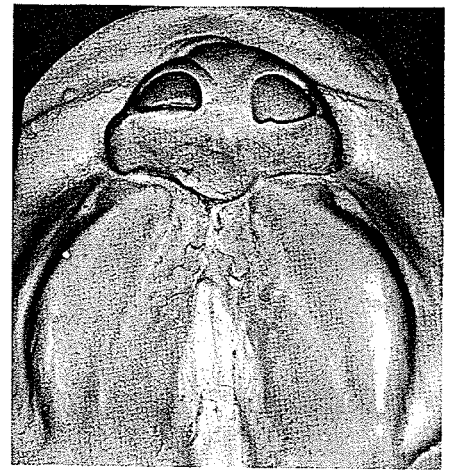
#### DELETERIOUS EFFECT OF NON-PHYSIOLOGICAL SURGERY

##### *A bilateral cleft lip and palate*

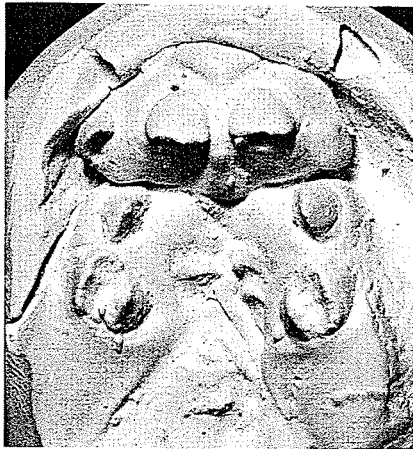
Arch form and size are excellent after reestablishment of lip muscle continuity. Palatal increase in size by appositional growth has further reduced the cleft space. This growth capability is inherent in all cleft palates and will occur but at various times and to various degrees.



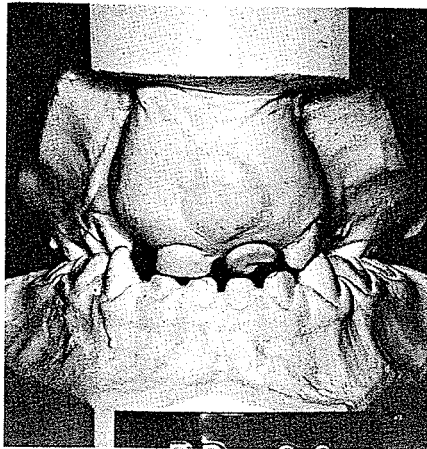
7 days



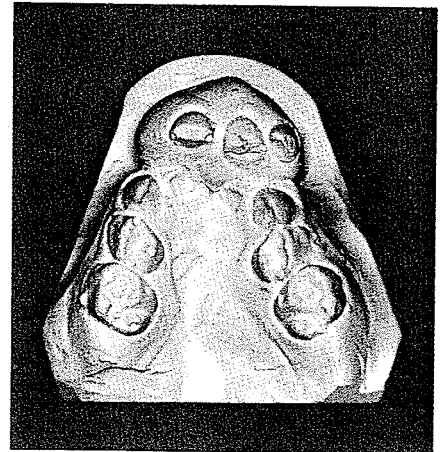
7 months; after lip surgery



1 year 10 months; after palatal surgery. Bilateral buccal crossbite with tip-to-tip incisal relationship.



3 years 5 months; bilateral buccal crossbite

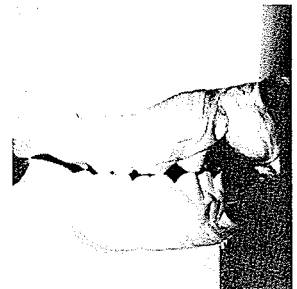
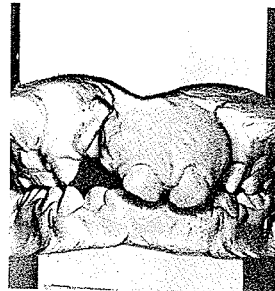
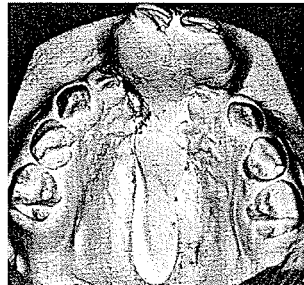


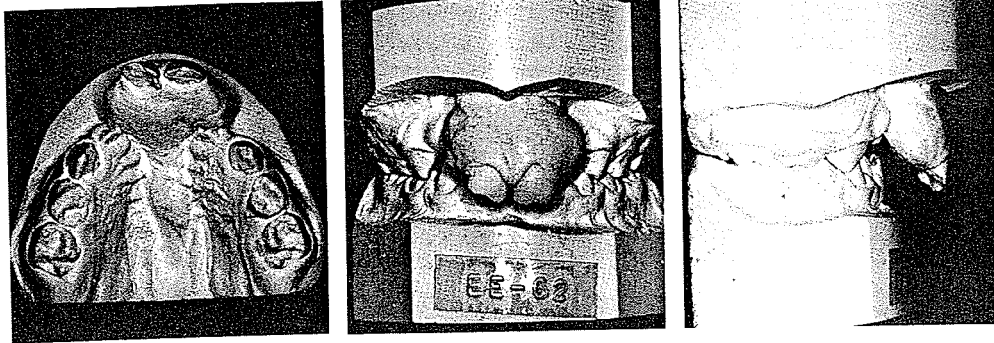
Vault space is obliterated due to scar contracture.

Extensive periosteal undermining performed in an "island flap" procedure at the age of 20 months resulted in severe scarring. The buccal crossbite and anterior incisal relationship reflect the growth-inhibiting effect. Cephalometric analysis demonstrates that growth inhibition occurs in the vertical dimension as well. This case is now an orthodontic nightmare and may require a Le Fort I advancement.

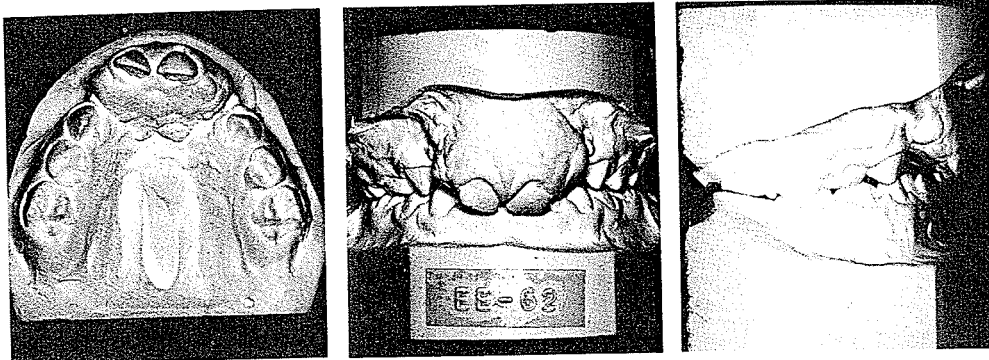
*Premaxilla setback followed by palatal cleft closure resulting in scarred, deformed vault*

3 years. Good buccal occlusion, severe overjet.

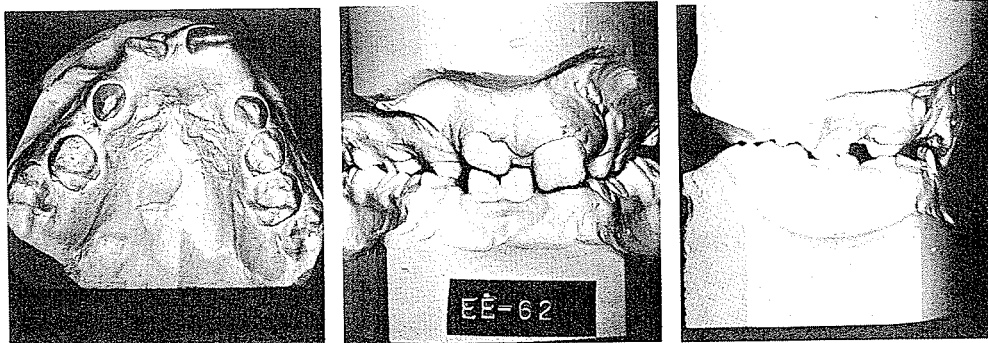




4 years 6 months. Excellent buccal occlusion. The lateral incisors were to be extracted prior to surgical setback.



5 years 6 months; after retropositioning of premaxilla.

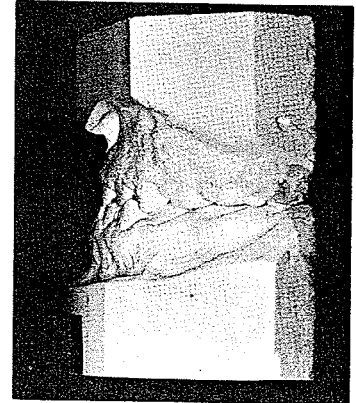
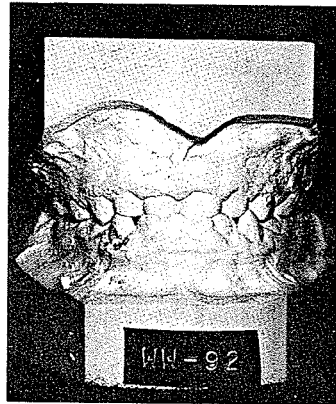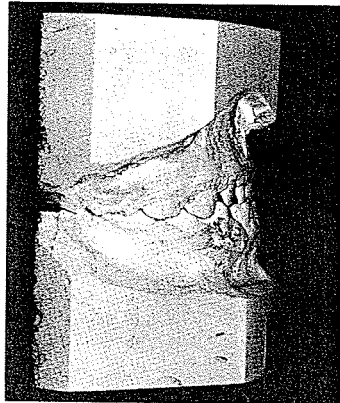


7 years. Right buccal crossbite; asymmetrical tapered palatal arch.

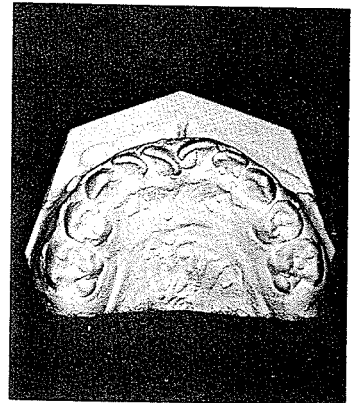
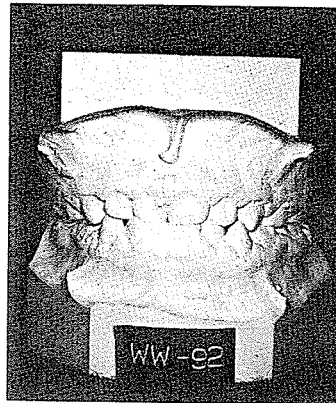
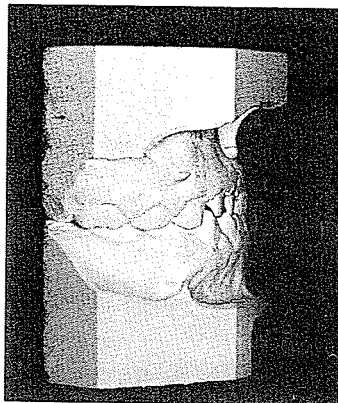
*Comments.* The palatal cleft was surgically closed at 6 years. Palatal fistula closure at 6½ years necessitated periosteal undermining. The resulting scar contracture deformed the palate causing dental crossbite.

NORMAL PALATAL ARCH DEVELOPMENT  
AFTER A REVAMPED ISLAND FLAP  
PROCEDURE WAS PERFORMED AT FOUR  
YEARS OF AGE

*Palate and occlusion analysis*



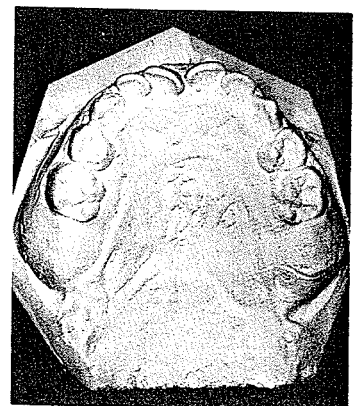
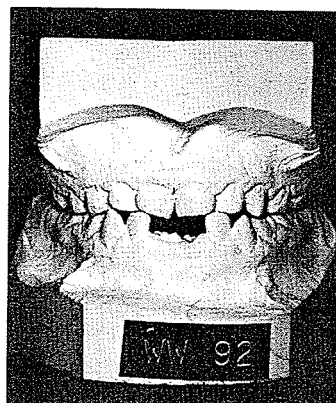
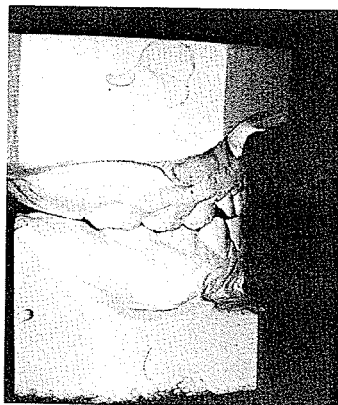3 years; before surgery. Ideal occlusion. Slight incisal tip-to-tip contact may be due to hypertonicity of the lip musculature.



4 years 6 months; one year after island flap surgery. Good occlusion still present.

After island flap, normal arch form.

*Comments.* An island flap will not cause palatal deformation if applied on a well-developed palate with adequate tissue and if the lateral incisions are made at least 5 mm. medial to the dentition. (Charles Kremenak was the first to appreciate the need to keep the surgical incision away from the teeth.)



6 years 6 months; 2 years 6 months after surgery. Good occlusion and palatal development. Excellent arch form.

## IN CONCLUSION

These concepts of orofacial growth present a logical sequence of treatment steps based on the natural history of cleft palate and the face in which it exists. Although the surgeon would like to get on with it and close the cleft space as soon as possible, he must temper this urge with the realization that "Time is an ally" to his reconstructive procedure.

Treatment guidelines can be listed as follows:

1. In complete cleft of the lip and palate the palatal segments are laterally displaced in space.
2. Uniting the lip and soft palate causes medial molding of the displaced segments to a more normal anatomical relationship.
3. The palatal processes have the potential to grow and develop to normal size and shape albeit at a somewhat later date.
4. Non-physiological surgical procedures can inhibit palatal growth and cause structural deformation.
5. *Timing* of surgical procedures must be related to the assets and deficits presented by each case and varies within each cleft type, as well as with the facial growth pattern.
6. The same surgical procedure can yield different results. What might be successful in one instance can be disastrous in another.
7. The surgeon does not always have complete control of the habilitative outcome.
8. Velopharyngeal capability is related not to the degree of palatal distortion or cleft type but to the pharyngeal architecture and to the size and activity of the velum. This functional relationship can change with time.

The 1977 State of the Art in Cleft Palate report sponsored by the American Cleft Palate Association reviewed the recent dental literature and stated that there is no data to support neonatal maxillary orthopedics with or without primary bone grafting. Although it has been well established that palatal segments can be manipulated, the long term utility of the procedures has still not been proven. It has been suggested that since retention problems associated with maxillary arch alignment are a major problem, arch correction should be postponed to when tooth-borne appliances can be used. No data has been published supporting the belief that the overlapping of the palatal segments for 3 to 5 years is detrimental to palatal growth or speech development.



Since all the statements in this chapter are supported by published facial growth studies, we need not *reinvent the wheel* by redoing the same studies. It behooves the surgeon to document his own cases so that he can critically review his results and ask the right questions: Why did the case turn out well or why did it fail? Progress can take place only when the correct answers to these questions are uncovered.

## FUTURE STUDIES

As a result of the development of an accurate automatic non-contact three dimensional measuring device, called an *optical profilometer*, I intend to investigate various research problems which, heretofore, have not been explored due to the absence of a proper measuring instrument. Stereophotogrammetry is an excellent system but it can be too expensive for our purposes. Hopefully, this investigation into changing palatal form and size under the influence of growth and surgery will lead to the development of a new cleft palate classification system which would be predictive of future palatal size and shape.

The optical profilometer concept consists of an optical system and photodetectors which observe the change in the energy distribution of an image spot of light as a function of the depth of the sample surface at the measurement point. The sample surface is scanned to provide measurement information over the complete surface. It can measure a cast within an accuracy of  $\pm 4$  mm in all dimensions in 9 minutes.

By the pooling of quantitative data from a number of cleft research centers which already have a great number of palatal casts in storage we will be able to significantly increase our data base. This will enable us to arrive at more meaningful conclusions about the natural history of cleft palate development.



Graphic display of data

Dr. Berkowitz is setting a palatal cast in the moving carriage of the optical profilometer. Immediately behind the optical profilometer is the voltage adjustment console, and on a shelf above the console there is an "Intellec #4" mini-computer. To the right of the console a "silent 700" terminal-printer is used to control the instrument's operation and will print a graphic display of the data. The data is simultaneously stored on a tape for analysis by a larger computer.