

60. *Oblique Facial Clefts*

THE first report of an oblique facial cleft was made in 1732 by Von Kulmus, and it is not surprising that he recorded it in Latin. Then in 1828 Delpech presented such a case in French, and in 1832 Walter Dick of Glasgow reported one in English.

William Rose of London in 1891 acknowledged his teacher, Sir William Fergusson, as the only English surgeon, as far as he knew, who had observed the rare facial clefts,

the majority of recorded cases hailing from Germany and France.

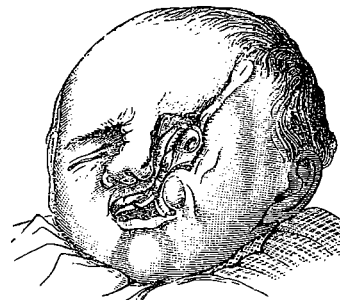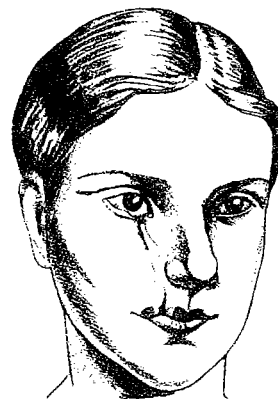Rose noted that several cases occurred with red cicatrices rather than actual clefts and cited this case (Tillmanns after Kraske) of an oblique cicatricial deformity of the face along the line usually transversed by such a cleft.

He also cited a facial cleft in a child, involving the lower lid and eye and with a development of accessory teeth along the cleft margin (Tillmanns after Haselmann).

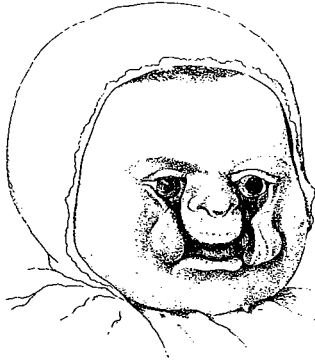Rose wrote of these cicatrices and clefts:

The defect begins at the free margin of the upper lip, and usually at the spot whence starts the ordinary harelip cleft; but occasionally from the angle of the mouth. It then trends upwards and outwards, leaving the nose entire, and skirts round the ala nasi to reach its upper limit at the middle of the lower eyelid which is cleft, or at the inner canthus. The eye itself may show a coloboma iridis, usually downwards and inwards. The facial skeleton may be divided or not; sometimes a large opening into the antrum exists.

Rose noted that the deformity could be bilateral and cited the case of Guersant. He also acknowledged:



Albrecht recorded a most interesting case in a newly born pup of double cleft extending from the lip margin upwards not only into the nostril but also towards the eye on either side, i.e. a double associated harelip and facial cleft. The specimen is taken from the Royal Veterinary College of Brussels.



M. Guersant, in the middle of the nineteenth century, reported a case of bilateral oro-ocular clefts of the face and illustrated the condition. Although the sketch portrays the cleft involving the entire lower eyelid, this probably was a medial type of oro-ocular cleft.

In 1887 Morian collected 34 cases in the literature, 77 percent of which were stillborn. In 1970 Khoo Boo-Chai, reviewing the literature since Morian, collected 43 cases of live-born oblique facial clefts including two of his own. Tessier in 1969 reported three; Bartels, O'Malley, Baker and Douglas in 1971, two; and Wilson, Musgrave, Garrett and Conklin in 1972, seven. According to Wilson's calculations, this rare anomaly represents approximately 0.25 percent of all facial clefts. Then in 1973 Dey of Sydney reported another five oblique facial clefts, and Miller, Wood and Hag reported one case from Nairobi. Also added is a case of Tom Zaydon's, who was my patient for a short time but is now in Bethesda. And, of course, there are an unknown number of patients around the world, like this Jamaican, who are operated on by the local surgeon and never get included in any published statistics.



According to the Nomenclature Committee of the American Association for Cleft Palate Rehabilitation, there are two main forms of oblique facial clefts: the naso-ocular and the oro-ocular. The oro-ocular type is subdivided into medial and lateral, depending on the relationship of the cleft to the infraorbital foramen. Adding to the complexity is the mixed occurrence of these various clefts in the same patient.

Numerous fascinating combinations can occur. Burian had a case with a naso-ocular cleft on one side and an oro-ocular on the other. Dey of Australia also had one case of a boy with both a

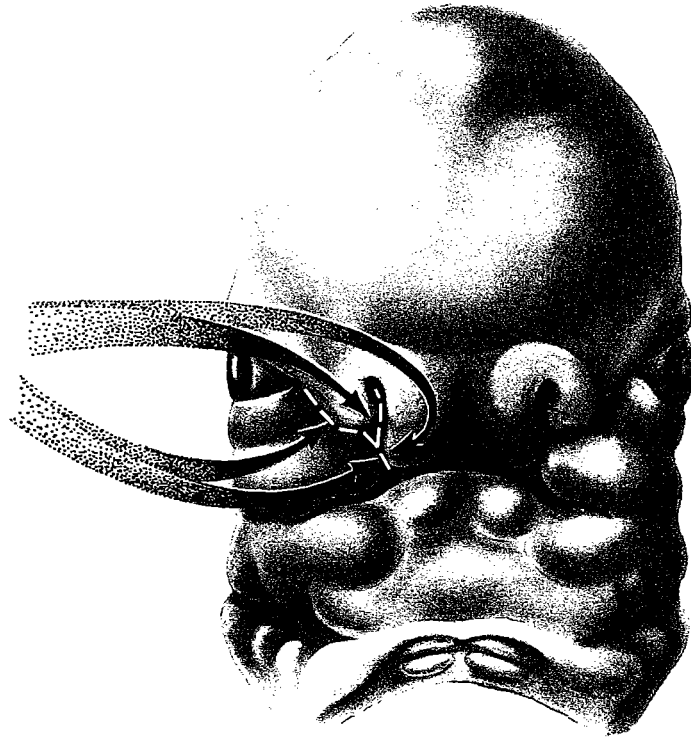
naso-ocular and an oro-ocular cleft. Greer-Walker and Skoog each had cases with both subgroups (medial and lateral) of the oro-ocular cleft. The oblique facial cleft has been associated with a transverse facial cleft in three reported cases—two on the contralateral side, one recorded by Lexer and one by Burian, and one on the ipsilateral side, recorded by McEnery and Brennemann.

Persistence of ectodermal grooves due to retardation in normal mesodermal migration could explain all oblique clefts except that, as Karfik pointed out, the lateral oro-ocular cleft corresponds to no embryonic facial groove. These clefts do not seem to be familial. Wilson, Musgrave, Garrett and Conklin put the blame vaguely on "some environmental insult to the developing embryo," backing this proposal with:

It is not surprising therefore to find multiple anomalies in many of these patients and a high incidence of still birth.

David Dey favors Ida Mann's thesis that the nasolacrimal ducts and apparatus are derived from ectoderm cut off from the surface by a forward growth of the maxillary process, which reaches the inner and outer nasal folds. The naso-ocular group of clefts follows the line of this epithelial inclusion, which at all times maintains connections with the nasal pits, extending any cleft of the lip that occurs in the usual position. The oro-ocular cleft, however, has no connections with the nasal pit, has no correspondence with the site of the ordinary cleft of the lip and may pass medial to the inferior punctum. Dey suggests that Sir Arthur Keith's theory of linear intrauterine necrosis along the watershed between developing vascular areas seems apt. Sanvenero-Rosselli in 1953 blamed the arterial system for congenital anomalies and quoted Kundrat in ancient writings as having found arhinencephaly to be due to a disturbance of the whole region supplied by the anterior cerebral artery.

NASO-OCULAR CLEFTS



Naso-ocular clefts are considered the result of failure of mesoderm migration or merging to obliterate the embryonic grooves between the nasomedial, nasolateral and maxillary prominences each with the other.

The naso-ocular cleft extends from the pyriform aperture to the medial canthal area along the approximate course of the nasolacrimal duct. As the nasolacrimal duct is intact only in the mild cases, it is usually absent or opened.

Daniel Marchac of Paris forwarded photographs of a naso-ocular cleft from an 1828 book by Professor Delpuch of Montpellier. A short excerpt translated from the original French text is of interest.

In the month of April, 1820, we met in the streets of Montpellier, a young boy 12 years old with a singularly severe congenital deformity.

With what is considered to be the first frontal flap used in France, a hemirhinoplasty was accomplished. It was impressive, to say the



least, that an early nineteenth-century surgeon had the sophistication to call upon the Indian forehead rhinoplasty to correct both nasal and ocular defects of an oblique facial cleft.

In 1962 C. S. Harkins, with A. Berlin, R. L. Harding, J. J. Longacre and R. M. Snodgrasse, defined a naso-ocular cleft as a fissure extending from the narial region toward the medial angle of the palpebral fissure,

differentiating it, as Bartels noted, from the oro-ocular cleft, which extends from the mouth to the orbit without involving the nose.

In 1966 Sakurai, Mitchell and Holmes noted that the fissure need not involve the entire line from the lip through the nose to the eyelid orbit with extension to the temporal region. Boo-Chai distinguished between complete and incomplete forms, noting that complete clefts are rare, usually seen in stillborn monsters, often associated with cleft lip and palate. When the bone is involved, there is hypoplasia of the body of the maxilla and only very seldom a complete cleft. When there is a split in the bone, it occurs between the medial and lateral incisors with disruption of the pyriform aperture and extension of the cleft into the orbit, as described by Burian in 1963 and Ergin in 1966.

In 1963 G. S. Gunter of the Royal Children's Hospital, Melbourne, referred to this anomaly as the nasomaxillary cleft and attributed it to the persistence of the naso-optic groove between the maxillary and frontonasal processes. He made several observations:



G. S. Gunter

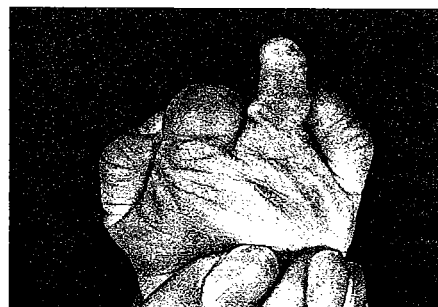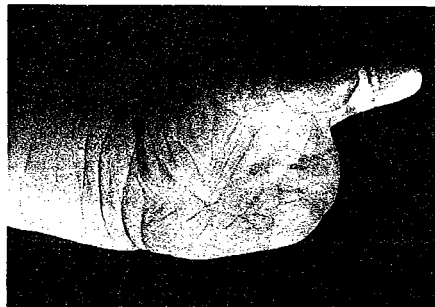
When the cleft appears to occupy the same portion of the primary palate as does the usual cleft lip, it then involves the nostril floor and passes on both sides of the displaced alar base. At the upper end there is involvement of the inner canthus with an upward extension across the brow and forehead.

Gunter was the first to note the various strange disruptions and extensions of the hairline and the hairs of the eyebrows.

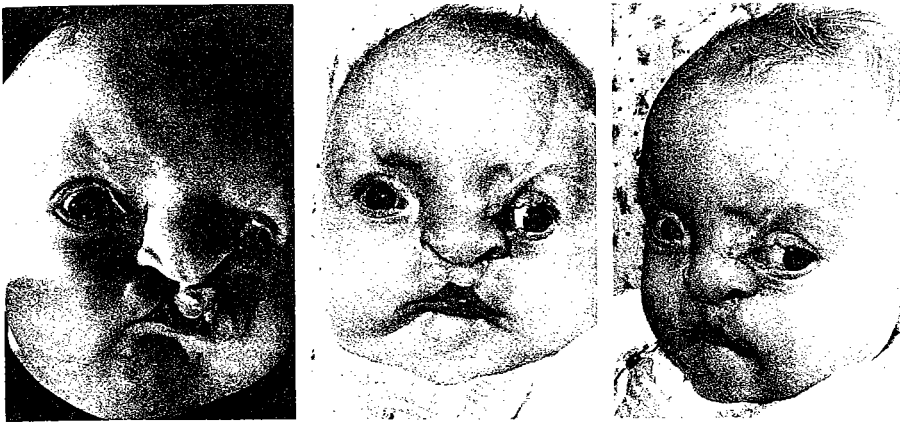Treatment is difficult and calls upon every facet of reconstructive surgery. Gunter did make some specific suggestions. In his experience, blocked nasolacrimal duct and repeated infection of the sac occurred in all cases, prompting him to advocate total extirpation of the sac and duct. He also noted that the normal eye must have early and adequate lid reconstruction. When additional tissue is required in the cleft of the lip and face, forehead and Abbe flaps can be used. The nose on the cleft side is always short between the alar base and the inner canthus; if the discrepancy is great enough, new soft tissue should be introduced. Gunter acknowledged the difficulty of reconstruction in asymmetries of the skull and face. He stressed the importance of having the afflicted children accepted within their family circle and not allowing them to become lost socially and educationally in the multiplicity of surgical procedures.

Gunter, who has added to his interests the breeding of Aberdeen Angus cows and Holsteiner horses, was asked for his current thoughts on naso-ocular clefts. He answered in December 1973:

I used to call this cleft "naso-maxillary" because it appears to lie between those structures. . . . However this is not always strictly true . . . nor does the cleft always lie in the naso-optic (naso-ocular) groove, to use the other terminology, and I wonder if the much older concept of some mechanical band, possibly amniotic, being responsible might not still be worthy of consideration. I've had personal dealings with one more case since my paper appeared in 1963. . . . This child also had anomalies of the hands of the "congenital ring stricture" type. . . .



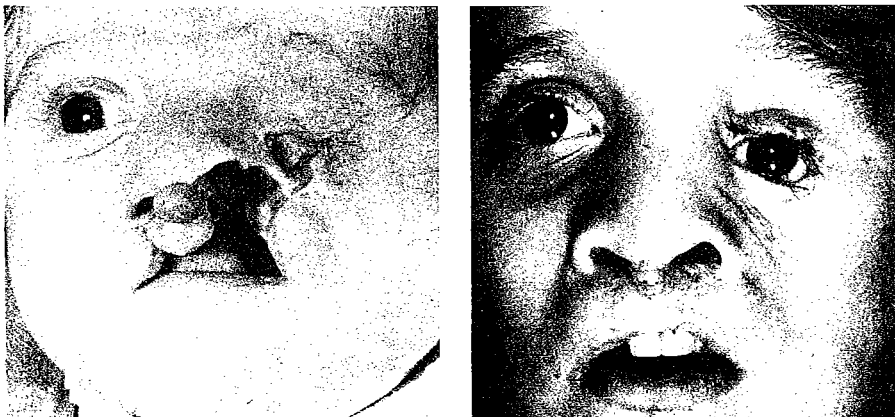This child has had three operations to date. 1. Repair of lip and anterior palate. 2. Z-plasty to left side of nose and inner canthus to lengthen nose on that side and bring the canthus up to a correct level, and 3. Repair of the cleft palate proper.



The complexity of these deformities seems to require many operations, as reported by all involved surgeons.

In April 1971 Roger Bartels, Joseph O'Malley, James Baker and William Douglas, in a paper "Naso-Ocular Clefts" in *Plastic and Reconstructive Surgery*, presented two interesting cases. In 1974 Bartels was questioned about these cases and he kindly sent recent details of their follow-up.

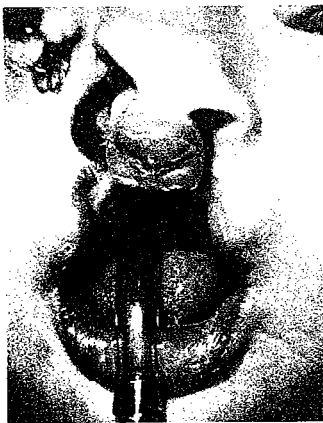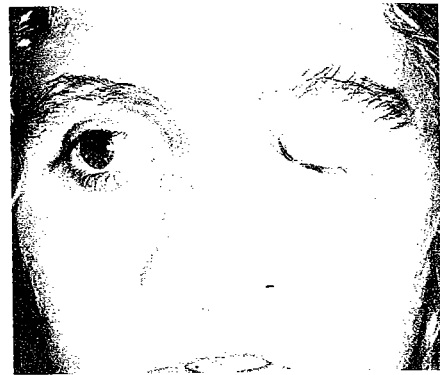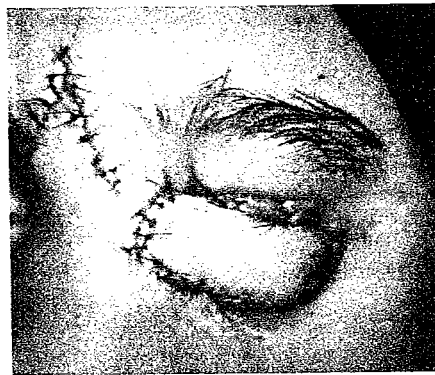
Case 1 was a six-pound Caucasian female with no history of clefts in the family but a record of maternal virus cold in the first trimester. Patient had left naso-ocular cleft, coloboma of the lower eyelid, left anophthalmia and bilateral complete cleft lip and palate. Treatment by O'Malley had included the following staged procedures: (1) right cheilorrhaphy, (2) closure of the naso-ocular cleft with left cheilorrhaphy and a vomer resection, (3) staphylorrhaphy with vomer flaps, (4) Wardill pushback palatoplasty, (5) left alarplasty, (6) left orbitoplasty, (7) composite graft from the right ear to the columella.



At 10 years of age she was reported of normal intelligence, doing well in school, a happy well-adjusted child.

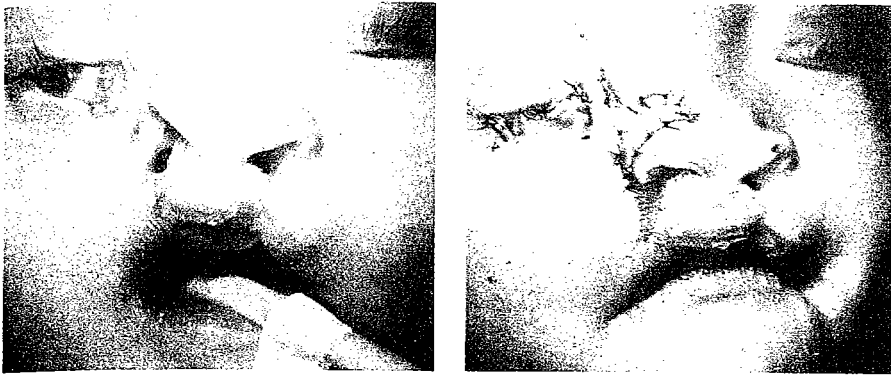Bartels' recent communication noted:

Since the article, Dr. O'Malley performed two additional surgical procedures on this patient using a midline forehead flap to construct a lower lid for this unfortunate girl. As you can see from her photographs, the left eye prosthesis was displaced downward to a considerable degree and this lower lid reconstructive procedure was done in an attempt to give her a more normal appearance. I have not seen her since her last photograph but obviously she needs additional work.



Case 2 was a seven-pound Caucasian female with no history of clefts in the family but a record of maternal viral infection during the first trimester of pregnancy. The patient had a right incomplete naso-ocular cleft with a coloboma of the right lower eyelid, coloboma of the right iris, left anophthalmia, slightly enlarged cranial vault with separation of the suture lines and tense frontanelles, hemangioma of the forehead, bilateral cleft lip and palate, diastasis of the rectus abdominis, abnormal hand lines and hypertelorism. Other congenital anomalies included an extra cervical vertebra and a grossly abnormal brain as revealed by encephalography. A ventricular-peritoneal shunt had to be performed to decrease intracranial pressure.

Bartels carried out two surgical procedures, in the first closing the naso-ocular cleft and the bilateral lip clefts and in the second closing the coloboma of the right lower eyelid and releasing the short ala on the right with a large auricular composite graft.



Bartels' recent report follows:

The child's postoperative care was provided by the physicians at Sunland Hospital here in Orlando and when I returned at a later date for postoperative photographs, I was informed that the child had died of meningitis, apparently related to her ventriculo-peritoneal shunt.

In 1971 Bartels had noted 11 cases of congenital naso-ocular clefts in the world literature, to which he added two. In 1974 he stated:

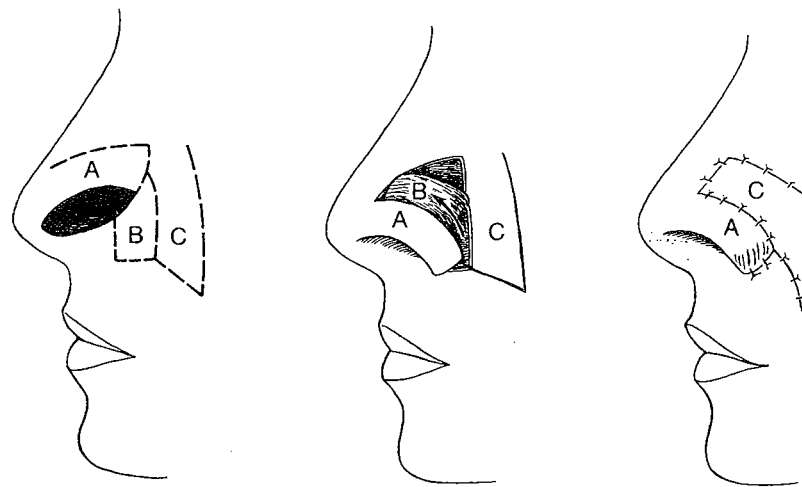
I personally feel that a naso-ocular cleft is a result of failure of fusion between the lateral nasal process and the maxillary process. To the best of my recollection every case of naso-ocular cleft reported also had a cleft of the primary palate, the only exception being the case report by Julio Ortega, appearing in Volume 43 of *Plastic and Reconstructive Surgery*.

In June 1969 in *Plastic and Reconstructive Surgery* Julio Ortega and Enzo Flor of Luis Vernaza Hospital, Guayaguil, Ecuador, reported a rare case of a 16-year-old country girl with an incomplete naso-ocular cleft with no history of clefts in the family and no incidents during the first trimester of her mother's pregnancy. Ortega considered the deformity an underdevelopment rather than an absence of elements, which was consistent with the absence or abnormal development of a specific portion of the mesodermal mass in the naso-optic groove. The deformity included the following conditions: moderate hypoplasia of the orbital and maxillary region, inner canthus of the left eye 15 mm. lower than the right, lacrimal apparatus present but

underdeveloped and abnormally located, lacrimal sac on the floor of the orbit, epiphora present, incomplete bony nasal process of the maxilla consisting mostly of cartilage with a 2 mm. cleft between it and the nasal bone, partial lack of left nasal ala, underdeveloped lateral crura and especially the superior lateral cartilage and hypoplasia of the chin with defective dental occlusion. This was the sequence of surgical procedures:

1. Rhinoplasty to reduce the size of the nose and the size of the alar defect.
2. Silicone implant to chin.
3. Reconstruction of alar defect (two stages).
4. Z-plasty to the left canthus.
5. Dental prosthesis.

The alar correction by logical local flaps in two stages was well executed.



The complex surgical problem offered by these clefts is exemplified again in the four cases reported in 1972 by Wilson, Musgrave, Garrett and Conklin, who stated:

Tissue defects present may be so extensive as to preclude truly satisfying aesthetic results . . . and can be expected to include multiple staged operations. . . . The only generalization possible is that an exposed eye requires immediate treatment.

One of their cases had had nine operations elsewhere and received another nine operations. Their other three cases averaged nine

operations each, including the usual cleft lip and palate procedures and eyelid, cheek and nasal reconstruction. In spite of all this surgery, the cases were considered still unfinished, indicating the severity of the problem.

DEY ADDS FOUR MORE TO THE LITERATURE

Dey reported four naso-ocular cleft cases. One was a bilateral naso-ocular cleft, far worse on the left side, where a small skin tube connected the nostril margin to the eyebrow region. There were associated anomalies such as cleft palate, absence of great toes, syndactyly of the second and third toes on the left side, constricting ring on the left ring finger and left little finger and congenital amputations of the right index and middle fingers. The intelligence was good and social adjustment satisfactory.

The second was a boy with almost complete right-sided oro-ocular cleft and complete left-sided naso-ocular cleft, left cleft alveolus but intact palate. There was also a bilateral posterior choanal atresia. The patient developed normally and has done well in school with a pleasant personality.

The third case had complete naso-ocular clefts on both sides with hypertelorism and blindness (right anophthalmia, left microphthalmia).

The fourth patient was a baby boy with bilateral cleft lip, plus cleft palate. On the left side the cleft was naso-ocular, and on both sides well-marked grooves extended the cleft high onto the forehead with the hair showing associated "cowlick" on the left side.

The first three of these had been treated prior to their coming to Dey, and the last is a patient of George Gunter.

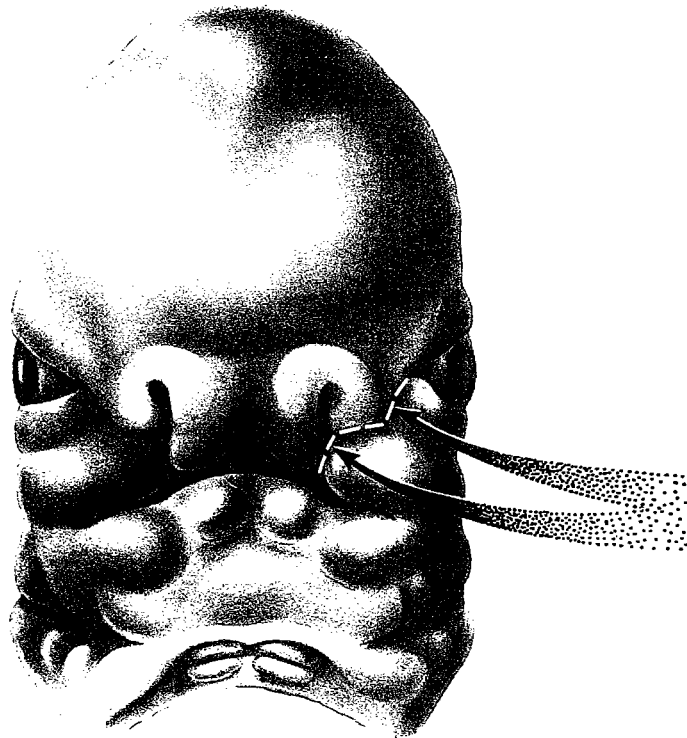
ORO-OCULAR CLEFTS

In oro-ocular clefts the fissure extends from the mouth to either the medial or the lateral canthus leaving the pyriform aperture intact. The subgroup, medial or lateral, of the oro-ocular cleft is

determined by the cleft's position in relation to the infraorbital foramen. These clefts can occur in complete and incomplete forms. Mild incomplete oro-ocular clefts can be confused with mild incomplete lip clefts and can be distinguished from them by two main characteristics:

1. The cleft lies lateral to the peak of the cupid's bow rather than through it, as in the standard cleft.
2. Because of shortening of the soft tissue element on the affected side there is an upward tilt of the alar base instead of the usual downward flare.

THE MEDIAL ORO-OCULAR CLEFT



Medial oro-ocular clefts are considered the result of failure of mesoderm migration or merging to obliterate the embryonic grooves between the nasolateral or nasomedial prominences and the maxillary prominences, the nasomedial and nasolateral prominences having merged with each other successfully.

The cleft lies medial to the infraorbital foramen and, instead of involving the nose, bypasses it, running upward in the region of the nasolabial (cheek) groove to terminate in the inner canthus of the lower eyelid. This fissure may extend up into the forehead, usually in the temporal region, and when the bone is cleft, the split lies between the lateral incisor and the canine.

Although the nose is well formed, in unilateral cases it is usually rotated around its long axis; in bilateral cases the bony and cartilaginous nose is detached from its lateral bony segments, drawn upward with forward protrusion. The orbit is sometimes shifted downward and is capacious because of the irregular and deficient growth of its walls. According to Rogalski, the eyeball may be deformed.

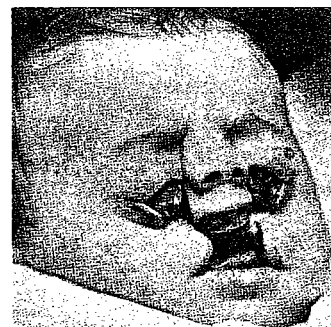In 1935 Warren B. Davis found, out of a series of 1,000 clefts, four oblique clefts with absent nasolacrimal duct and five with coloboma extending into the facial cleft. He published a bilateral example of the medial group of the oro-ocular cleft and described the deformity:

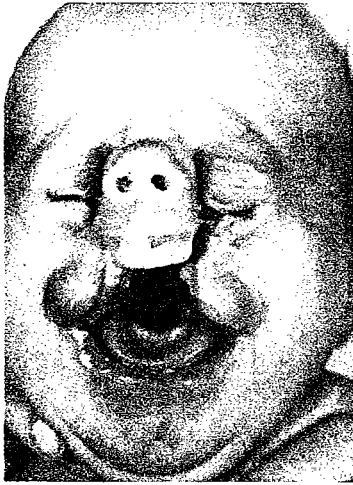The clefts involve the lips, cheeks, lower eyelids, alveolar processes, antero-medial portions of the maxillae and the orbital floors. Posterior to the premaxilla, the palate is intact. Atresia of the posterior one-third of the nasal passages was from a thick mass of tissue, partly osseous. Note the rotation of premaxilla, and the elevation of all anterior nasal structures, which, in association with the prolapse of the eyeballs, placed the anterior nares and the pupils of the eyes on the same horizontal plane.

Harry P. Ritchie spied this strange cleft of Davis' and included it in his surgical interpretation of embryology in 1934:

This case is particularly important for my purpose, as it shows the nose, prolabium and premaxilla normally formed in the frontonasal process. This process is shown to be an embryonal entity, separate from the lateral maxillary processes.

In 1950 John Potter of Newcastle reported a bilateral oblique facial cleft extending from the medial end of the lower eyelid to the lateral side of the premaxilla. There was also a complete cleft of the lip and alveolar margin, but this passed lateral to the nose. The central part of the face protruded at a level much higher than





normal with the nasal tip on a line with the eye. The nasal airways were normal and remained so. The nose was shorter than normal. There was a complete bilateral cleft of the palate. The lacrimal system was grossly abnormal, the inner canthus being unformed and caruncle and puncta absent, with notching of the upper lid. There was no lacrimal sac, and the nasolacrimal duct was represented by an open cleft covered by pink epithelium. The eyes were normal and moved normally.

Potter noted:

On each side the cleft involved superficial parts of the soft tissues only at its upper end, deepening as it descends so as to involve the full thickness of the lip, and being complete in the alveolus and palate.

This case seems to illustrate a view expressed by Frazer in 1939:

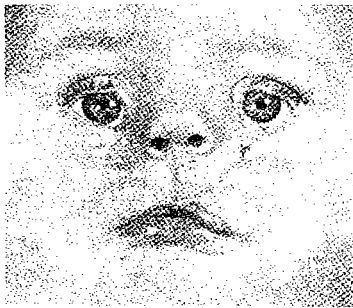It must be understood that the cleft is only present where the maxillary process applies itself, in its growth to the surfaces of the nasal folds. Further back it is never present, the maxillary mesoderm being applied directly to the paraxial mesoderm without any intervention of ectoderm.

Treatment: W. E. M. Wardill closed the left cleft at six weeks of age. He used Veau's palate procedure, suturing the mobilized hard palate flap to the vomerine mucosa flap. He pared the edges of the lip cleft and closed with sutures after wide undermining.

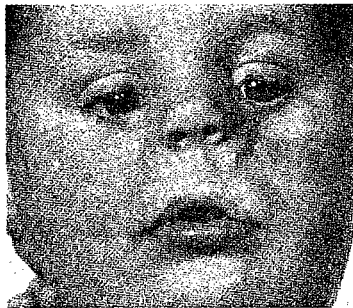Six weeks later John Potter closed the right palate cleft in the same manner but used a modified Blair-Brown-Mirault procedure for the lip. Six weeks later he revised Wardill's lip on the left with the Blair-Brown method. The palate was closed at age 12 months by Potter, using Wardill's V-Y pushback and pharyngoplasty. Then, at age two years, Potter freed the depressed inner end of each lower eyelid and transposed a flap from each upper lid into the defect to correct the inner droop.

This interesting case was published in the *British Journal of Plastic Surgery* in October 1950 with records of the patient up to two years of age.

Recently I wrote my friend Potter for more up-to-date records and he obtained photographs from Newcastle of the patient in 1967 at the age of about 20 years. Although further surgery has been carried out since, these photographs are revealing. The



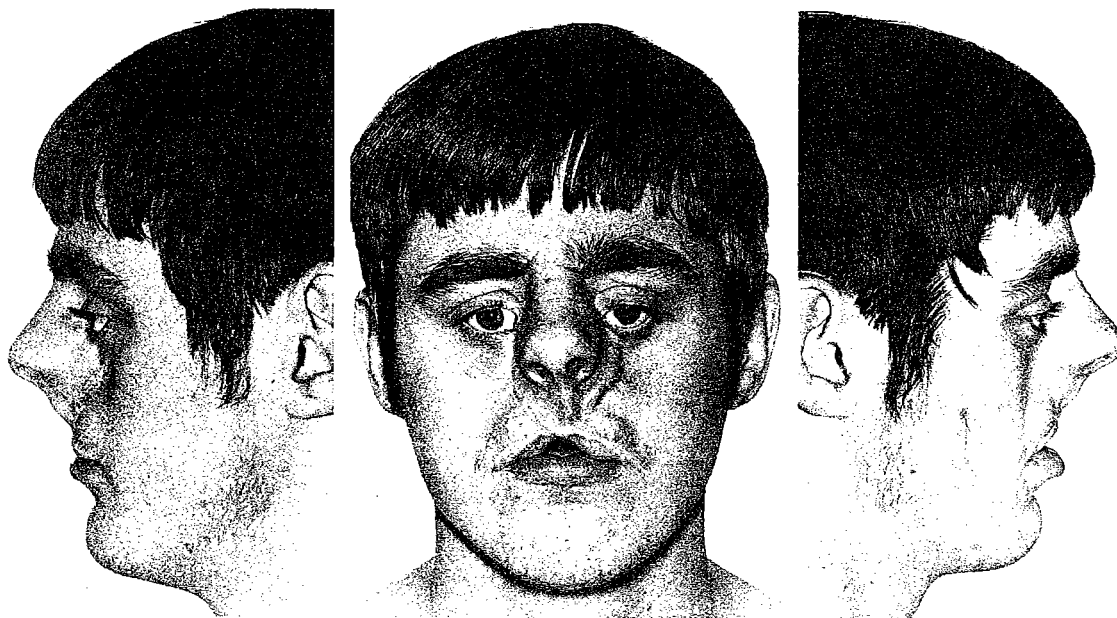1 year



2 years

eyelid construction had been quite satisfactory. Potter, true to his old chief Wardill's dictum "Follow up a few cases well and carefully and keep trying," wrote almost in anguish:

You can see the problem—the premaxilla has grown again in his teens.



It seems that the frontonasal component, being more or less detached from the lateral segments in relation to mesoderm and consequently muscle and bone, has failed in its vertical descent and has continued in its forward growth. Thus this final result has occurred without the benefit of the downward pull of normal maxillary attachments or the constricting restraints of the intact orbicularis oris muscle. At least here is an honest and true follow-up on this rare type of cleft that shows what will happen under certain conditions; it should give some direction toward treatment of the future.

Postponement of early closure of the alveolar and hard palate clefts should prevent any reduction in growth that is caused by surgery but certainly will avoid locking in the short frontonasal component at its undescended position, which evidently is destined to be exaggerated by future growth. Possibly a controlled device as described by Georgiade and Latham could exert the necessary prolonged downward traction to encourage growth of this stunted segment and at the same time position better what-

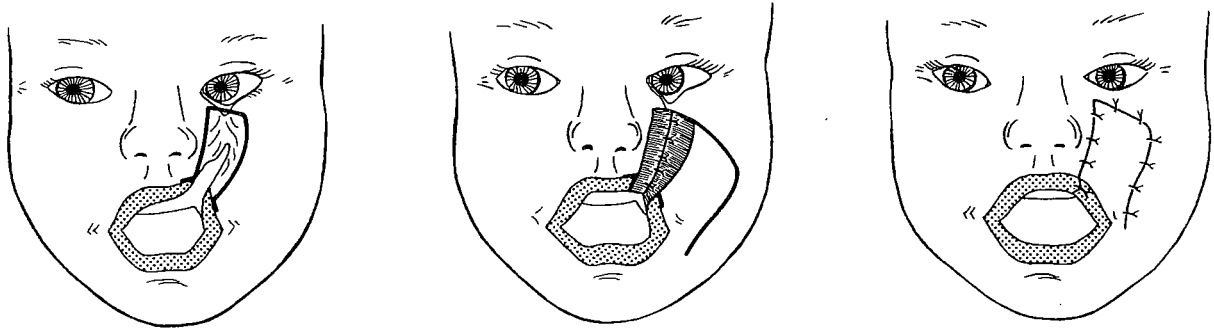


Joachim Gabka

ever is already present. Then, of course, joining the orbicularis oris muscles across the cleft will give further molding benefits.

Few clinics in the world ever see a bilateral medial oro-ocular cleft patient. For instance, Joachim Gabka with his great volume of cases in Berlin borrowed for his book one of these bilateral oblique clefts from the even larger collection of Rosenthal.

In 1964 Gabka, in his book *Hasenscharten und Wolfsrachen*, diagramed his plan for treating a unilateral medial oro-ocular cleft. His design was simple inturning of the edges of the cleft for lining and rotation of a cheek flap for cover while aligning the lateral and medial vermilion of the lip.



Fogh-Andersen in 1965 reported three oblique facial clefts out of 3,988 clefts. One was a severe oblique cleft combined with bilateral cleft lip and palate, nasal defect and preauricular appendages. He also published an account of a less severe incomplete oblique cleft of the lip involving the medial portion of the lower eyelid. His surgery corrected the lip and cheek with a Z-plasty.



Paul Tessier

Paul Tessier of Paris, who seems to gravitate to facial bone pathology, especially in the orbital area, in 1969 reported on 16 coloboma patients with 22 facial clefts. He differentiated between two types of medial oro-ocular clefts, *vertical* and *oblique*.

He noted differential features. In the eyelids, localization of the cleft seems to be outside the punctum lacrimale in vertical clefts and inside in the oblique cleft. The medial canthal ligament is almost normal in direction and insertion in vertical clefts but atrophic, obliquely directed and associated with ectopia in oblique clefts.

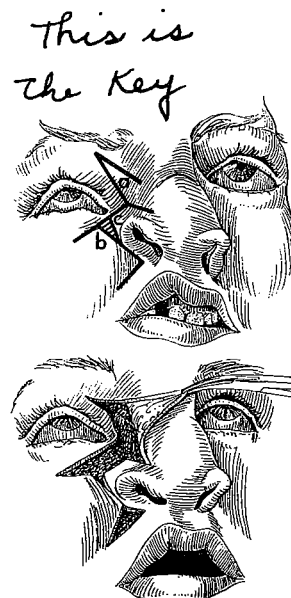
The lacrimal sac and canal are absent in the oblique clefts—but in only three vertical clefts were they salvageable. There is an osseous cleft involving the floor of the orbit and the maxilla with deeper skeletal upheaval in the oblique clefts. The lower edge and the floor of the orbit are always separated by a gap which may vary in both depth and width but is situated inside the infraorbital foramen. The contents of the orbit sink into this fissure and at times reach the palate, causing prolapse of the eyeball. Vertical clefts pass into the maxilla via the sinus. In oblique clefts the internal wall of the maxillary sinus is absent. Skeletal clefts are usually located between the canine and the lateral incisor, although Tessier has also observed an accessory cleft between the central incisors.

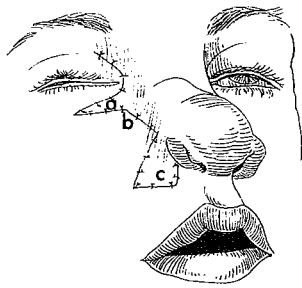
In the nose the ala is normal but tilted up in vertical clefts with the distance between the internal canthus and the foot of the ala short. The same distance is extremely short in oblique clefts since the cleft itself occupies this general site. Then, too, the ala is unsupported with the bone cleft behind it, and the internal wall and the frontal process of the sinus are absent. In the vertical cleft the labial cleft lies outside the ala, not extending to form the usual cleft lip. The vertical-type cleft extends onto the lip as a standard cleft lip and may be accompanied by alar and labial fissures.

Treatment by Tessier is a combined operation consistent with his grand style. The design has a similar format for incomplete and complete oblique cleft correction but is carefully planned for the specific need of the case:

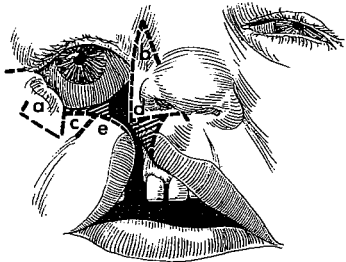
A multi-stage operation is replaced by simultaneous management of the eyelid, inner canthus, floor of orbit, cheek, lip and ala nasi. The point of novelty is this and one which I consider to be of the maximum importance. The treatment of coloboma must be carried out in a single stage because it is much easier to combine the different skin flaps, extensive cleavages, external cantholysis, inner canthopexy and multiple bone grafts.

Palpebral elongation demands total disinsertion of the lower septum and external cantholysis. As correct placement of the eyelid is opposed by the connection of the septum with the periosteum, this must be broken. Ectopia of the inner canthus,

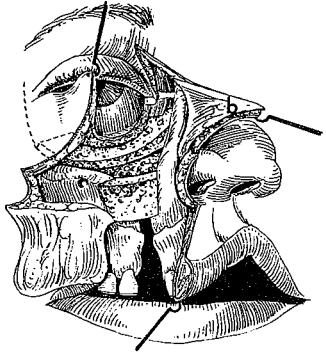




more marked in oblique clefts, deserves transnasal inner cantho-
pexy in most cases. The maxillary cleft through the floor of the
orbit allows the contents of the orbit to sink out of position,
requiring correction and maintenance with bone grafts to estab-
lish continuity of the floor and edge of the orbit, plug the gap
and improve the contour of the aplasia. As noted by Tessier, in
oblique clefts the orbit, nose, sinus and mouth are in communi-
cation, not facilitating the success of bone grafts. He explains:

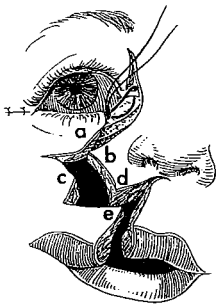


The grafts must be made to rest on the palatine plate and the outer edge of
the alveolar arch (externally) and on the inner face of the orbit and the
remains of the frontal apophysis (internally). Overhang is important
and must be sustained above and externally by floor grafts. In spite of this,
however, resorption may take place and secondary bone grafts may be
required.



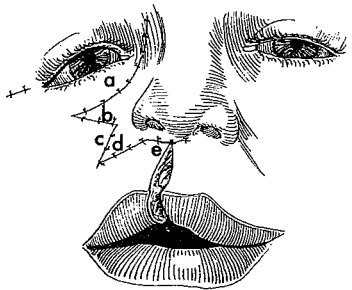
The ala nasi is always atrophied, and for the more severe
hypoplasia a composite graft may be of value later. For the cleft
lip Tessier suggests rotation and advancement:

We have obtained good results from Millard's mark-out for harelip in
external labial cleft accompanying vertical cleft.



The striking shortness of the vertical distance between the can-
thus and the lip requires at least two interdigitations of skin flaps
to reposition the eyelid and drop the ala nasi. Then, with the
rotation-advancement, the cleft lip is corrected.

Six of Tessier's 16 cases had a bilateral coloboma in which
there was considerable protrusion of the "central massif" exag-
gerated by gross hypoplasia of the malar bones and the cheeks.
He accused this deformity of being a "devourer of bone," and the
greater the malformation, the more pressing the need for bone
grafts to reconstruct the normal contours of the face.



David Dey of Sydney reported a case of bilateral medial
oro-ocular clefting, complete on the left, somewhat less than
complete on the right. The eyes were exposed by proptosis and
downward displacement of eyelids. Medial to the point of entry
of the cleft no real lid margin was evident. As usual, the central
upper lip, nose and nostrils appeared basically normal except
shortened and displaced upward. A groove in the maxilla on both

sides extended from the alveolus at the canine tooth to the orbital margin. Bilateral choanal atresia was also present.

Dey's outline of treatment for this case included penetration of the atresia and establishment of airways by otolaryngologist B. Benjamin, rotation of the lower lids as flaps upward and medially to the inner canthi and inrolling of the edges of the complete cleft to form an artificial lacrimal duct. He described his lip closure:

Three months later, the cleft was repaired bilaterally—using a lateral cheek flap (somewhat reminiscent of the Millard advancement-rotation operation) combined with a triangular lip flap used Z-fashion. The flaps of excess vermilion tissue on the lateral margins of the clefts were used in the central lower border, where the vermilion was very narrow.

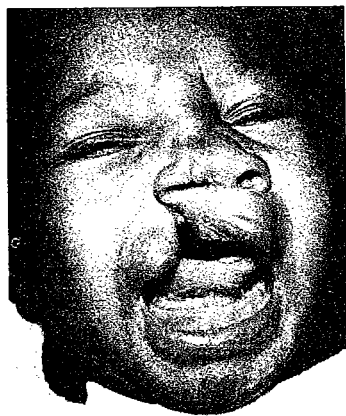In 1973 Miller, Wood and Hag reported a case of bilateral medial oro-ocular clefting seen in Nairobi. The patient had a left complete medial oro-ocular cleft with coloboma and patent nasolacrimal duct. The left globe, covered by an epithelial membrane with "inadequate visual structures present for future sight," had complete range of motion. On the right there was a medial incomplete oro-ocular cleft with skin grooving up to the lower eyelid, anophthalmia with no nasolacrimal system, oblique cleft of the secondary palate and hypoplasia of the left malar eminence and maxillary sinus.

Treatment: Bilateral straight-line closure of each oro-ocular cleft was performed along with attempted closure of the coloboma, which had to be repeated.

In 1973 Poradowska, Jaworska, Dudkiewicz and Reszke of Warsaw, Poland, reported a case of complete medial oro-ocular cleft.

Treatment: The blind hypoplastic eyeball was retained to carry a prosthesis. The surgical construction was carried out in multiple stages rather than in the one grand slam of Tessier. First, the cleft was closed superficially by skin advancement. Then, both lacrimal sac and fistula were excised, and a lower lid was partially constructed. Maxillary mucosa was turned for lining so that the lower orbital rim could be grafted with split rib. Elongation of the vertical shortness of the cheek was treated with multiple

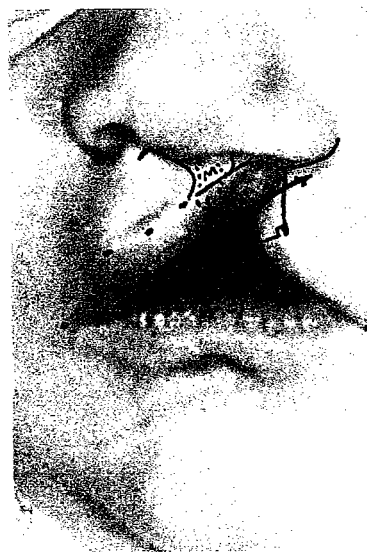
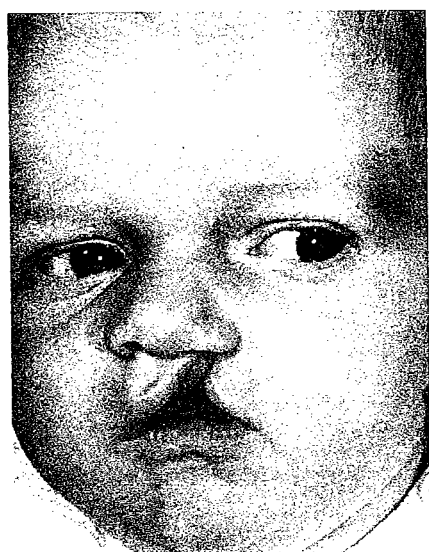Z-plasties, which also adjusted the vermillion border of the lip. The result still left much to be desired since insufficient new tissue had been moved into the area of this horrendous defect.



PERSONAL CASES

In 1957 Max Grob noted the various paths of oblique facial clefts as those associated with cleft lip and involving the nostril and those lateral to the philtrum that skirt the nostril. This case shows nasal ala notches that correspond to Tessier's cleft 1 and 2 and lateral to the alar base in his cleft 3.

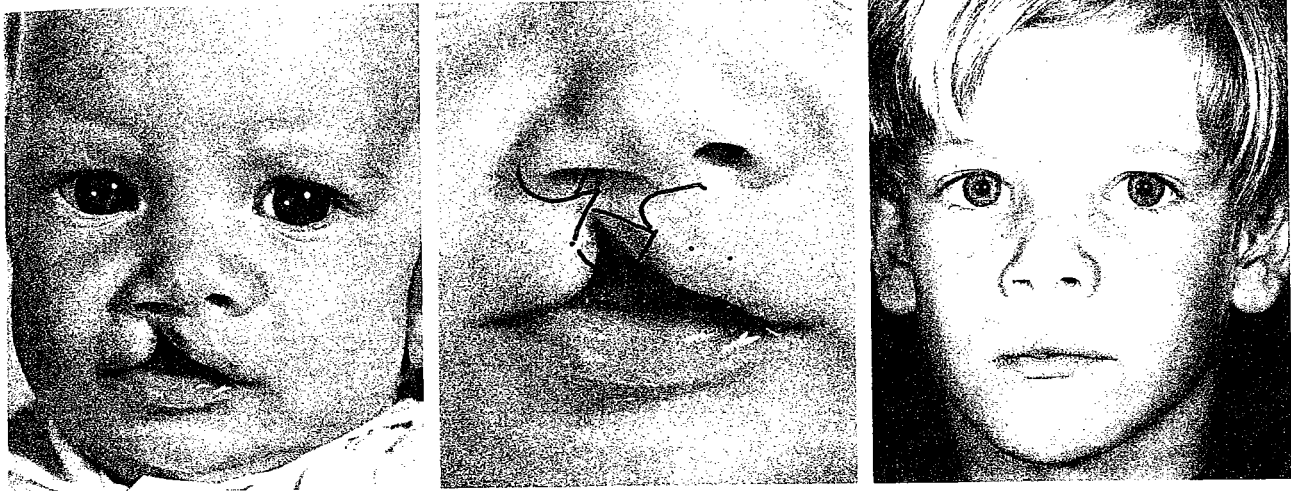
It has not been my fortune to treat many oblique clefts. I have had several incomplete clefts, however, that seemed to show an obliqueness of direction, slanting not into the nasal floor but toward the alar base or lateral to it. These clefts are well corrected by the rotation-advancement principle. The direction of the cleft tends to shear off the point of the advancement flap, but extension of the lateral incision around the alar base releases enough lateral lip element to fill the rotation gap and complete the lip construction.



In this case, a superiorly based muscle flap turned off the rotation edge of the medial element and was inserted into the upper lateral advancement flap to fill out its deficiency. The

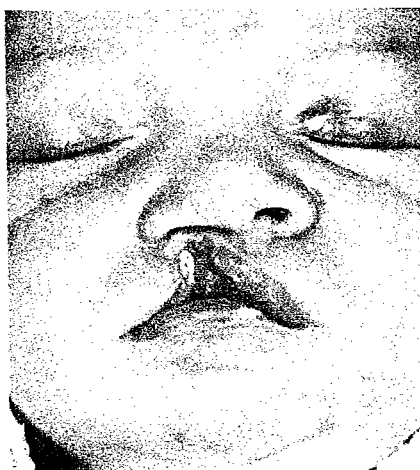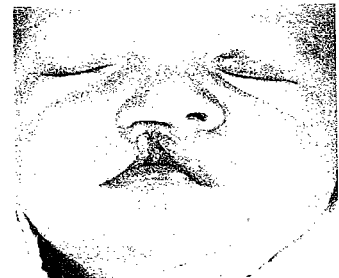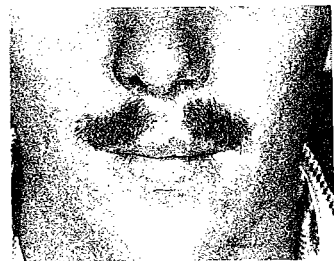denuded end of the freed alar base flap was sutured to the septum for permanent fixation of the alar base and nostril sill.

Here is another oblique incomplete cleft threatening to skirt the ala.

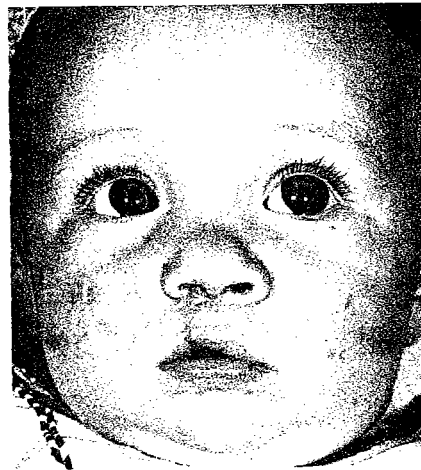

And another!

This little boy had an interesting family history in that his mother's cousin had a cleft of the palate and his father had a microform including a unilateral congenital ridge and groove of the lip with slight elevation of the vermilion of the bow peak and notching of the free border along with a first-degree cleft lip nose. There was no difficulty with rotation in the child's lip as it required only a 5 mm. drop. A small amount of the nostril bridge was used in the advancement flap.



3 weeks



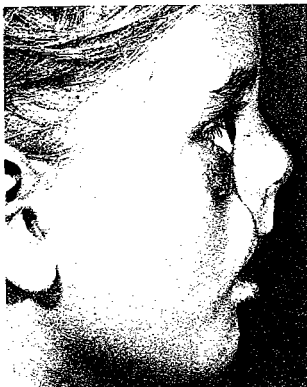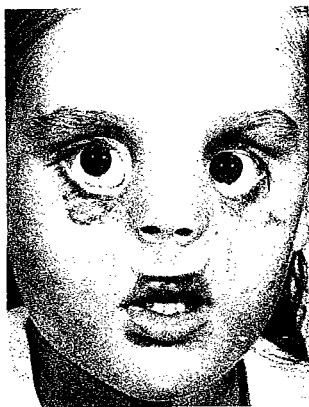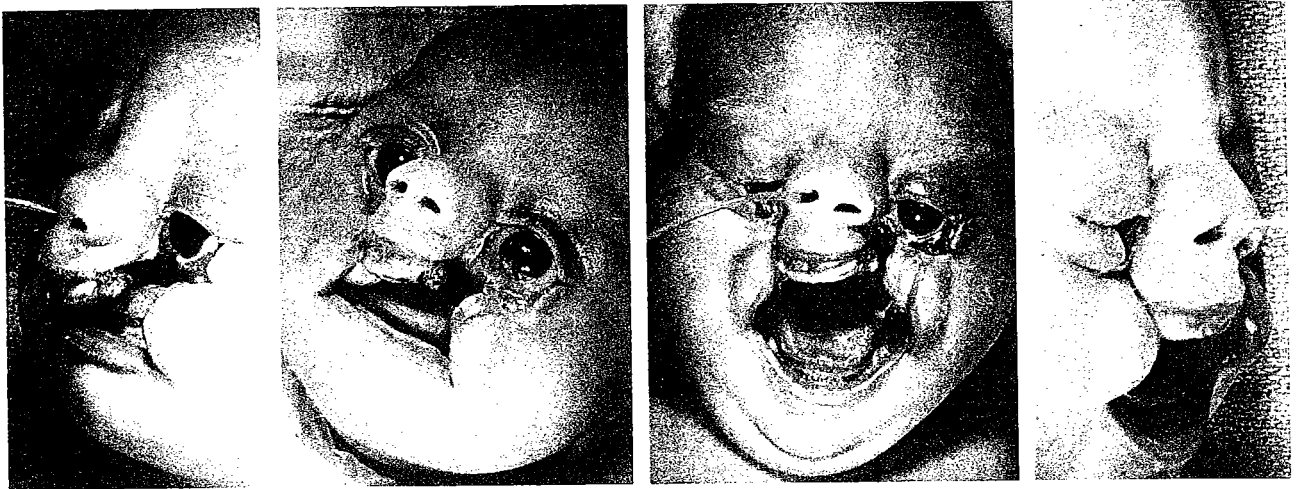
2 weeks postoperative



2 years

BILATERAL ASYMMETRICAL OBLIQUE CLEFTS

Here is a case not previously published as it is still unfinished. This patient (born February 4, 1963) of Thomas J. Zaydon of Miami had a bilateral medial oro-ocular cleft, complete on the left and incomplete on the right, with extension through the hard and soft palate.



As soon as the patient was one month of age, Zaydon operated on the left facial cleft with emphasis on achieving coverage of the left eye. He turned local mucosal and conjunctival flaps for lower lid lining and then, after extensive undermining, advanced a large facial-cheek flap medially for cover. Two months later a similar procedure was carried out on the right side using local conjunctival flaps and advancement of the cheek.

During the next two years five more operations were aimed at creating more conjunctival lining and skin in the area of the eyelids. An upper buccal sulcus was partially constructed, and on December 14, 1965, a Langenbeck-type procedure effectively closed the palate cleft. An operation in 1966 and another in 1967 continued to try for more eyeball coverage and the construction of a philtrum. After four years of Zaydon's heroic effort to correct this horrendous deformity, the patient revealed good progress in function and appearance. On his retirement from the Florida Crippled Children's Commission, Zaydon referred this patient to me.

At age eight, on September 1, 1971, bilateral fistulae were closed through the upper buccal sulcus, and during the process the antrum was opened on the left, allowing the escape of thin, dark, non-odorous fluid. This was suctioned, the antrum irrigated with neomycin-bacitracin solution and the opening closed with muscle. Split-rib grafts and chips were used to fill the bony gap on the left and to overlay the hypoplastic maxilla on the right. The skin of the prolabium was undermined and the unnatural corded subcutaneous vertical ridge split as two flaps based inferiorly. These flaps were shifted laterally into philtrum column positions, and a central dimple stitch was placed in an attempt to create a philtrum concavity out of an abnormal convexity. The straight-line oblique skin scars of the cheeks were interrupted by small interdigitations. Then the transverse ridge of the inferior vermilion of the prolabium was reduced and the adjacent horizontal groove filled with a dermal graft to improve the contour fullness of the vermilion border, particularly in the area of the tubercle.

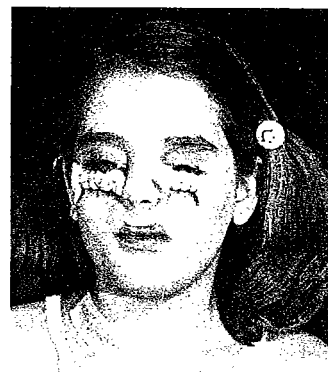Obviously, the next surgical procedure planned was the transport of distant tissue to make up the bilateral lower lid deficiency. During this period a change of homes was evidently in progress, and eventually the patient was taken by a remarkable and talented new parent who adopts only handicapped children. This course of events necessitated a move to Maryland, and her rehabilitation is being continued expertly by Alfred J. Suraci of Washington, D.C. This is part of his 1975 report.

When I first saw her in the latter part of 1972, it was quite evident that the sclera of the eyes bilaterally were becoming damaged due to her inability to close her eyelids. Hence, the first operative procedure on March 27, 1973, concentrated on this pathology and the severe ectropion was corrected on both sides by utilization of a full thickness right clavicular skin graft. In addition, adhesions of the lower eyelids to the sclera bilaterally were removed surgically and the upper and lower eyelids then sutured to each other for support. Fortunately, there was a 100% take of the skin graft and her eyes took on a much improved appearance, the severe hemorrhagic conjunctivitis disappearing with the ability to close her eyelids and protect the sclera.

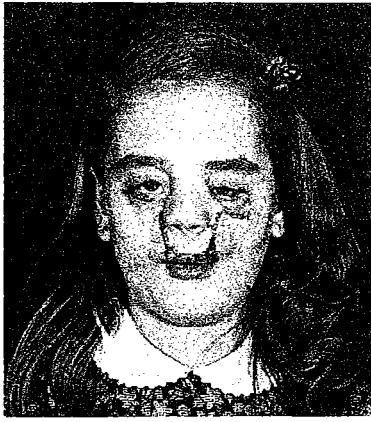The next surgical procedure was performed on July 13, 1973, at which time the severe scarring of the cheeks bilaterally, infraorbital regions bilat-



9 days postoperative



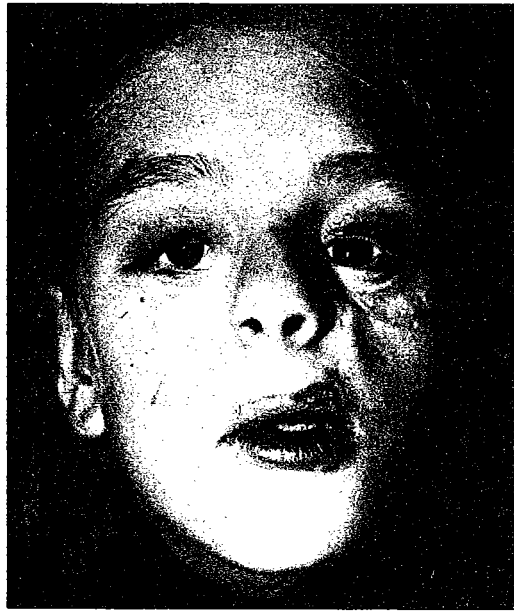1973



1973

erally and particularly on the left side was excised in their superficial portion, utilizing the underlying dermal scars to build up the cheeks. A "V-Y" advancement of the vermillion border on each side was accomplished. . . .

On January 29, 1974, a pharyngeal flap based superiorly with attachment to the nasal surface of the severely scarred soft palate was accomplished and this operative procedure has turned out quite well, her speech having improved remarkably.

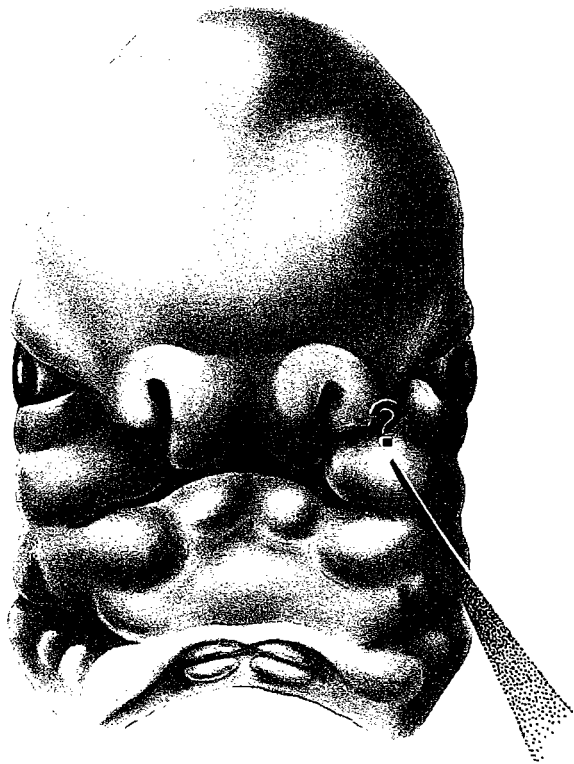


1975



In retrospect, techniques to "pull" growth and encourage downward positioning of the frontonasal component, as with the most modern Georgiade-Latham Mark III apparatus, and early side-to-side union of the orbicularis oris muscle might have been beneficial. This would be an effort to avoid a final result with a short central segment only moderately apparent at present but probably destined to increase proportionately in the late teens, as observed by Potter in 1974.

THE LATERAL ORO-OCULAR CLEFT



Lateral oro-ocular clefts do not correspond to any embryonic grooving??

The lateral oro-ocular cleft extends from the angle of the mouth upward to the orbit terminating in the lateral canthus or in a coloboma in the mid-portion of the lower lid lateral to the infraorbital foramen. More often than in the naso-ocular type, incomplete forms occur in which the central portion of the cleft in the region of the cheek is replaced by a scar-like groove. In mild cases the nasolacrimal duct is intact but in severe cases it is defective or absent. This is a mysterious cleft. It has the same origin as a transverse cleft, but its direction turns oblique, not corresponding to any of the known embryonic facial grooves. Karfik in 1969 called it the "true oblique cleft."

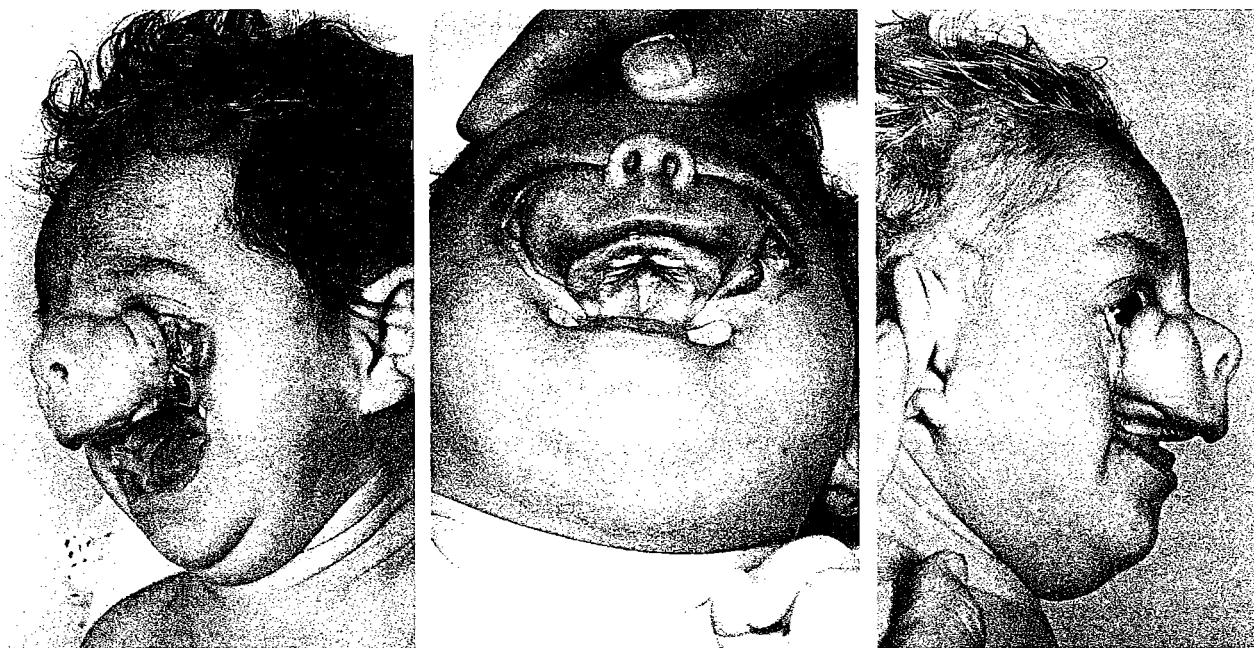This is the rarest of all clefts; six such clefts are reported in the world literature. Three examples have occurred on one side in cases of the mixed group reported by Skoog and also by Greer-Walker. One unilateral incomplete cleft reported by Boo-Chai in

1970 was treated by paring and approximation of the edges of the coloboma. The tissue of the cheek along the line of the cleft and scar from the level of the alar base to the eyelid was lengthened vertically by a double Z-plasty, which also interrupted any tendency toward contraction of the oblique line.

Always a little more grandiose than the rest of us, Ivo Pitanguy of Rio, with Franco, reported a bilateral lateral oro-ocular cleft. In fact, he bragged that Brazil's 83 million people produced a higher percentage of rare clefts than reported by Fogh-Andersen in Denmark or Burian in Czechoslovakia. In 1967 he presented this table:

Source	Total Clefts	Rare Clefts	Percentage
Fogh-Andersen	3,988	48	1.20 ± 0.77
Burian	4,000	97	2.42 ± 2.44
Pitanguy	736	25	3.39 ± 0.66

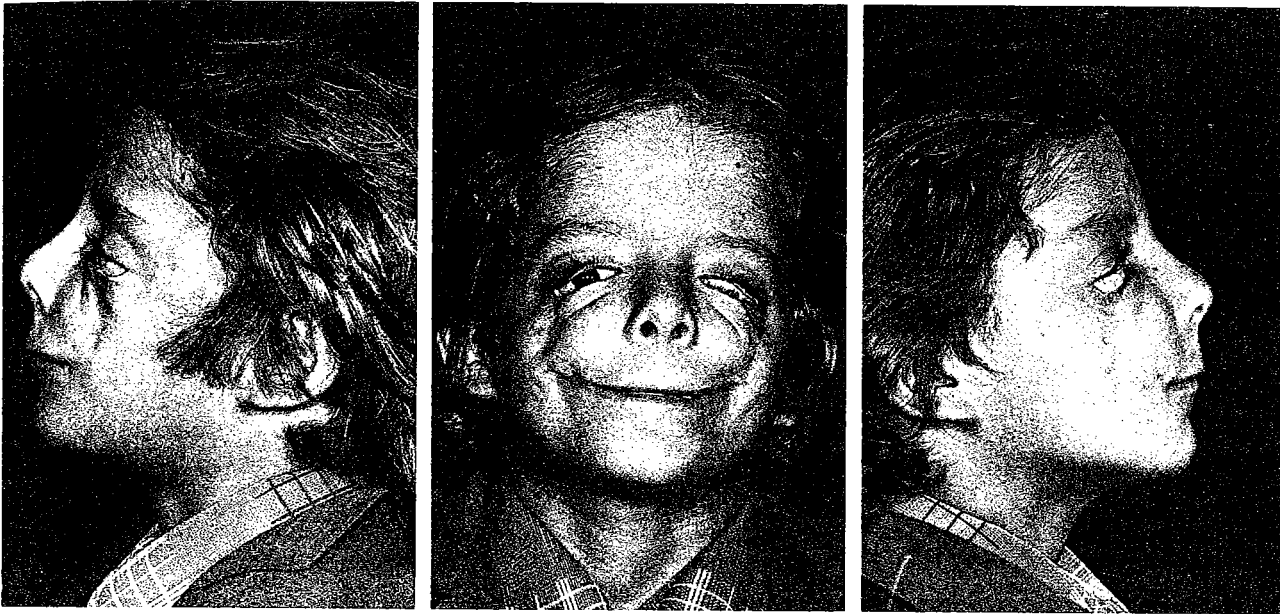Pitanguy's bilateral lateral oro-ocular cleft is the only one ever recorded in the world. In his patient the clefts ran obliquely in the lip from just medial to the commissure through the cheeks and into the lateral aspect of the lower eyelids. There was no cleft in the palate.



1964

Treatment: Pitanguy approximated the soft tissue of the cheeks to the central component on each side with simultaneous positioning of the lower eyelids and construction of the oral commissures aided with Z-plasties.

This case with its early postoperative photographs was published in *Plastic and Reconstructive Surgery* in 1967. Here is a later follow-up record.



1971