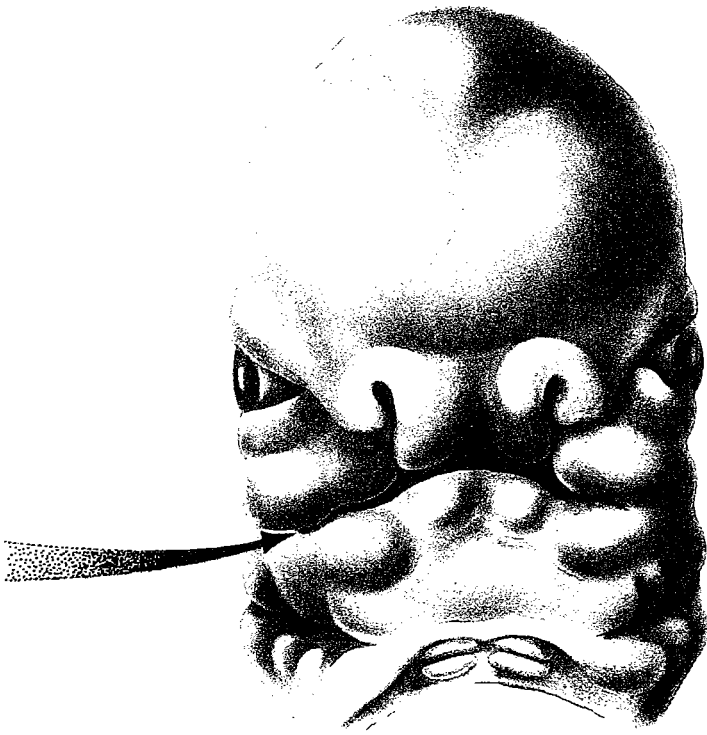


## 59. *Lateral Facial Clefts*



**H**ORIZONTAL or transverse clefts are considered the result of failure of mesoderm migration or merging to obliterate the embryonic grooves between the maxillary and mandibular prominences.

### TRANSVERSE CLEFTS

As these clefts are rare and almost everybody having one has reported it, it is possible to review most of the reported cases and

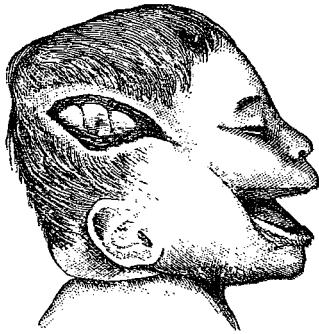
when described note the treatment. After specific case recordings in what may seem a helter-skelter arrangement, generalizations may be of value.

In 1891 Rose noted:

For long the very existence of this macrostomatous deformity was doubted, but cases have been recognized more or less since 1715, when Muralt pictured it for the first time.

One of the first cases reported was by Vrolik, who, in his 1849 work, gave several illustrations of commissural clefts as well as other deformities of the face. Other cases were reported by Reissmann in 1869 and Morgan in 1882.

Macrostomia or commissural harelip, according to Rose, is evidenced by an increased diameter of the mouth which may vary from a slight increase to a considerable distance; in a case reported by Rynd in 1862 the mouth opening extended as far as the first molar on the right side and to the last molar on the left. In 1887 Sutton published the drawing of a child with a very large cleft, the angles of which gradually passed into a red cicatrix. This scar ended in a gaping wound over the temporal region, extending to the dura mater.



Rose also pointed out:

Macrostoma is not only attended by great disfigurement, but is also troublesome from the impossibility of the child retaining its saliva and the food escaping during mastication. Suckling can be performed if the nurse's nipple be long, but is difficult otherwise. This deformity is, perhaps, more frequently associated with defective cerebral power than any other of the facial clefts, a large proportion of the subjects having been idiots.



In 1862 M. Debout first noted the association of macrostomia with abnormal conditions of the external ear—either defective development or the production of accessory auricles. In 1875 Ahfield reported a transverse cleft of the mouth which included the ear. In 1886 Roulland published an account of a double macrostomia with accessory auricular appendages, absence of middle ear and eustachian tube and absence of the temporo-maxillary joint on the left side. Macrostomia with auricular appendages, shown as a sketch, was presented by one of Fergus-

son's patients. Then, in 1895 Ballantyne enumerated 16 cases of macrostomia with preauricular appendages. In 1909 Edington reported a transverse oral cleft that stopped in front of the tragus but with a fissure extending to the external auditory meatus. Sir Arthur Keith in 1920 recorded a case of transverse facial cleft extending to the tragus and external auditory canal, which he reported in 1940. As did many plastic surgery textbooks, Padgett and Stephensen in 1948 reported a transverse facial cleft associated with anomalous pretragal tags. Then in 1937 McEnery and Brennermann presented a case of macrostomia which coexisted with a nasomaxillary cleft. This is a real mix-up, with disturbance of the first branchial cleft and arch and persistence of the naso-optic groove, and enough to give any embryologist a "splitting" headache.

In 1950 Blackfield and Wilde of the University of California reported five cases. One was a three-month-old male with bilateral clefts extending from the corners of the mouth backward and above the ears. Absence of the terminal phalanges of the left hand, syndactyly of the left foot and absence of the right great toe were additional deformities. In the other four transverse facial clefts, one had a sinus of the dorsum of the nose, and two were associated with ear deformities. Treatment: Clefts closed and grooves excised and subsequently correction of syndactyly and excision of sinus or appendages.

Others reporting transverse facial clefts were Sanvenero-Rosselli in 1958, Phoner in 1958 and Piotti in 1958. In 1964 Gorlin and Pindborg surmised that transverse facial clefts seem to appear more commonly in males and when unilateral were most often on the left. In 1965 Fogh-Andersen of Copenhagen reported 13 transverse facial clefts out of his 3,988 clefts.

In 1968 Powell and Jenkins of Chicago reported three cases. A white male had a transverse facial cleft, preauricular skin tags, dermoid cyst of the conjunctiva and thoracic hemivertebrae, a condition they diagnosed as oculoauriculovertebral dysplasia or Goldenhar's syndrome. The other two patients were white females, one with bilateral transverse clefts and the other with unilateral clefts associated with preauricular skin tag and retroauricular dermoid.

Treatment: Early closure was carried out on the transverse clefts. The bilateral clefts were closed with reconstruction of the oral angles with small flaps of vermilion in a modified Estlander technique. Subsequently the cysts, dermoid and skin tags were excised.

In 1970 Eiseman, Walden, Platzer and Hoppe reported a 13-year-old Negro female with bilateral transverse facial clefts associated with maxillary protrusion. Treatment: Closure of the clefts with Z-plasties followed by extraction of strategic teeth for aid in the osteotomy and setback of the maxilla.

Blackfield and Wilde admitted in 1950 that the etiology of these clefts is unestablished and then devoted pages to the possible causes. The most generally accepted explanation was the failure of fusion between mandibular and maxillary processes. Powell and Jenkins noted:

One theory on the genesis of lateral clefts is failure of the mesoderm to penetrate completely the regions of the epithelial fusion at the oral commissures, or they may be the result of absolute deficiencies in quantities of mesoderm.

According to Streeter:

There is no evidence of ectodermal resorption between the meeting surfaces, but rather the surface is simply flattened out by the proliferation of the growth centers beneath.

Blackfield and Wilde also leveled a truly wild "shotgun blast" at all possible etiological factors involved in cleft formation. Such causes were mentioned as Finley and Keith's ideas of placental infarction, Von Winckel's amniotic bands, Streeter's amniotic adhesions, faulty implantation with poor nutrition, diabetic mothers, vitamin deficiencies (vitamin E), rubella infection during pregnancy and radiation. They concluded that the etiology of transverse facial clefts is probably a combination of several of the above-mentioned factors:

It would be well to stop thinking of heredity as a cause of disease and to consider it merely the pattern of incidence of a condition brought about by one or more factors.

## MANDIBLE INCLUDED

In addition to transverse facial clefts and ear deformities, there is often an associated mandibular malformation. This grouping was first reported by Kirmisson in 1902. In 1938 British oral surgeon Martin Rushton reported a transverse facial cleft associated with maldevelopment of the mandible. T. P. Kilner suggested for this case closure of the cleft and at the same time a bone graft onlay to the mandible.

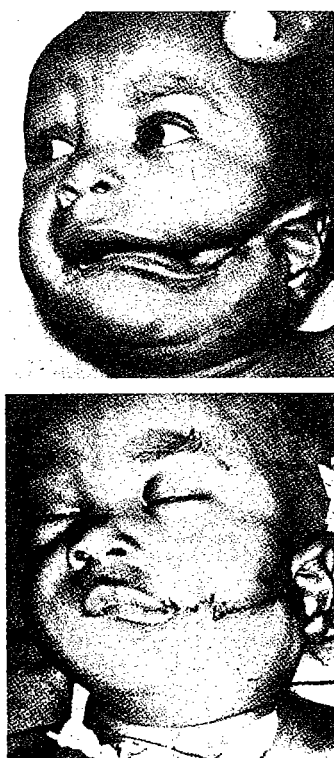In 1939 Kazanjian of Boston reported five cases of congenital absence of the mandible and noted that two of them had macrostomia and four had microtia. He observed that, although this anomaly seemed to be the expression of improper development of the first branchial arch and cleft, as other facial and cranial bone anomalies appeared, they may have been secondary to the absence of the mandibular segment, which deprived the surrounding tissue of normal growth.

Treatment: He advised closure of the oral fissure and reconstruction of the ear only. Surgery of the mandibular defect, however, he postponed until the permanent teeth were available to allow fixation during tibial bone grafting.

In 1950 Michael Lewin reported a case of mandibular malformation associated with an anomaly of the ear and an associated groove-like thinning of the cheek extending from the corner of the mouth to an auricular appendage. In 1955 Hunt and Smith also reported a case of oral-mandibular and auricular deformities.

Lateral facial clefts can be associated with what Gorlin and Pindborg referred to as hemifacial microstomia (microtia, macrostomia and failure of formation of the mandibular ramus and condyle). They suggested that oculoauriculovertebral dysplasia or the Goldenhar syndrome is a variant of this complex characterized by vertebral anomalies, most often hemivertebrae and epibulbar dermoids of the eye.

In April 1961 Ken McNeill of Kingston, Jamaica, and I set off on a West Indian plastic peregrination, having cabled ahead for the local doctors to collect all of their *worst* faces. Among our "touchdowns" was the island of Barbados, "a little England"



with more sunshine, more British color and charm and more people and sugar cane per square mile ( $21 \times 14$  mi.) than any other isle of the Antilles. Here, Jack Leacock was waiting for us with a rare macrostomia extending across the cheek with a groove passing above the slightly deformed ear. There were an associated seventh nerve paralysis and a gelatinous cyst in the cleft between the maxilla and the hypoplastic mandible. First the cyst was excised. Then the edges of the cleft were freed to facilitate a two-layer closure interrupted by a Z-plasty of the skin and a vermilion flap from the cleft to turn the corner of the new commissure, as published in the *British Journal of Plastic Surgery* in 1962. Because of the happy atmosphere on this sunny island, both the main wing of the Z flap and the mucosal commissure flap were turned *upward* in an attempt to suggest a smile in the presence of facial paralysis.

In 1961 J. J. Longacre of Cincinnati, with DeStefano and Holmstrand, also reported a case of oral, mandibular and auricular deformities. They advised Z-plasty of the cleft closure, and Longacre emphasized the importance of early split-rib autografts to the mandible to minimize the psychological trauma.

In 1962 Hans May of Philadelphia reported three cases of transverse facial clefts associated with ear and mandibular anomalies along with other defects. His treatment was of interest. One case of transverse facial cleft was accompanied by a rudimentary left ear in the middle of the cheek, coloboma of the left upper eyelid, dermoid cyst of the conjunctiva, coloboma of the iris, absence of the malar arch and maldevelopment of the mandible. This is getting close to a description of the so-called Treacher Collins syndrome, which, not having clefts, will be bypassed. May closed the transverse cleft directly, and when the scar developed hypertrophy he excised it and used a Z-plasty with what he reported was a success.

Another of his patients was a male with a transverse facial cleft with underdeveloped mandible and forward displacement of the tragus. He closed the cleft and shifted the tragus posteriorly.

His third patient was a female with a transverse facial cleft and underdevelopment of the mandible and ear. In addition to ear

revision and mandibular lengthening, May closed the cleft and reconstructed the commissure.

His summary was important:

Transverse facial clefts seldom constitute an isolated deformity. As a rule, they are accompanied by deformities of the mandible, the ear, and perhaps various other facial deformities, all centering around the first (mandibular) branchial arch. . . . These clefts require closure since the orbicularis oris muscle is divided. Closure by simple fusion of the separated structures overcomes only part of the deformity. The key point in the repair must center upon the reconstruction of a muscular commissure, the closure of the orbicularis ring at the cleft side. This can be done effectively by rotation of a full-thickness vermilion-lined flap from the lower into the upper lip after Estlander.

In 1963 Nagai and Weinstein also advocated the use of a modified Estlander-type flap for reconstruction of the oral commissure in transverse clefts.

Side by side with Hans May in the March 1962 *Plastic and Reconstructive Surgery* was a paper by Richard Stark and David Saunders officially grouping the combined oral-mandibular-auricular anomalies into the first branchial syndrome. They reported five cases of this combination and stated:

Macrostomia, hemignathia and auricular deformities are intimately related congenital anomalies. All are rare but they may coexist, representing a syndrome.

They explained the association:

Embryologically, the mandible develops from the mesoderm of the first branchial (mandibular) arch. A portion of the auricle (tragus and helical crus) also is derived from this mesoderm. Normal development of the mouth depends upon the amount of mesoderm of this arch and the extent of its migration.

Treatment: Their cheiloplasty included paring of the cleft edges and closure in layers. Insurance toward preservation of the corner of the mouth was achieved by mucosal flaps: either a triangular one that fits directly into the commissure or a mucosal flap taken from the upper or lower vermilion and used as a "wraparound" at the corner which shifts the scar out of the

commissure itself. Excision of preauricular tags, ear reconstruction and mandibular bone grafting were mentioned briefly.

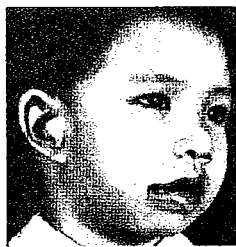### LANDMARKS FOR THE COMMISSURE

In the *British Journal of Plastic Surgery* in 1968 Khoo Boo-Chai of Singapore reported four cases of transverse facial cleft in which the cleft was the presenting complaint in a constellation of other deformities seen in the first and second branchial arch syndrome. William Grabb in 1965 published a classical review of the clinical aspects of this syndrome. For the treatment of his four cases Boo-Chai gave an excellent outline of the essential points in the surgical correction (one case is shown). He wisely noted:

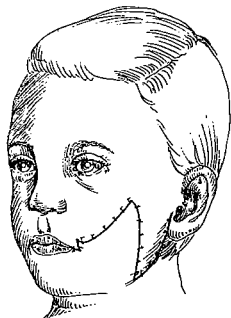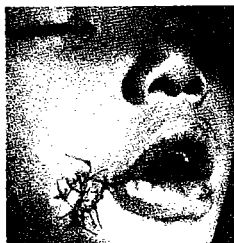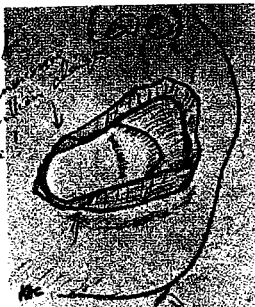
The rim of the cleft is lined by vermillion which is of a slightly lighter shade than that of the normal vermillion. The line of demarcation which we were able to detect in all our four cases marks the beginning of the cleft. Pressure with the examining finger in this region will help to bring out a muscular ridge which corresponds with the line of demarcation in the vermillion. We place importance on this landmark because we believe it to be the correct position of the new commissure . . . . Once this is accurately identified and marked, the vermillion of the rim is excised together with the triangular piece of skin on the buccal surface of the cheek. Beginning intra-orally at the apex of the triangular raw area, the edges of the mucosa are closed with 4-0 plain interrupted catgut working outward toward the new commissure . . . the cut through the vermillion at the site of the new commissure is not vertical but it is made slightly oblique from within out . . . The oral musculature is then apposed on the outside . . . It is important to get the muscle together as close to the commissure as possible. Otherwise, we will get a "goldfish mouth" appearance. A "Z" plasty for the skin completes the operation.

### DOUBLE Z

O. T. Mansfield and D. C. Herbert of England noted in 1972 that unilateral transverse facial clefts are associated with facial hypoplasia and proposed introduction of additional tissue into the plane of the cleft to make up the deficiency. For two cases they designed a double Z-plasty along the line of the cleft from the



Natural landmark  
definitive commissure  
the red vermillion  
colour → pale





commissure to the tragus: a small Z at the commissure and a large Z with thick flaps in the cheek area which they claim not only increased the length of the scar but improved the contour.

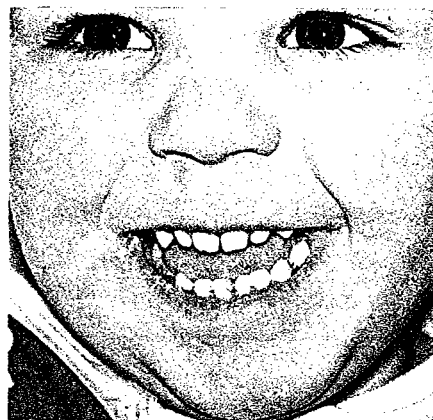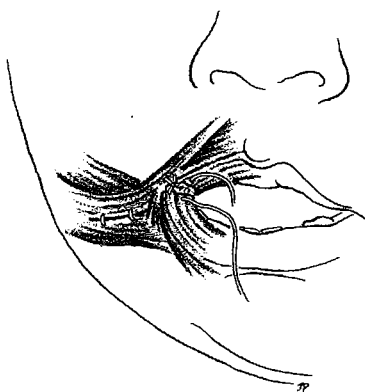
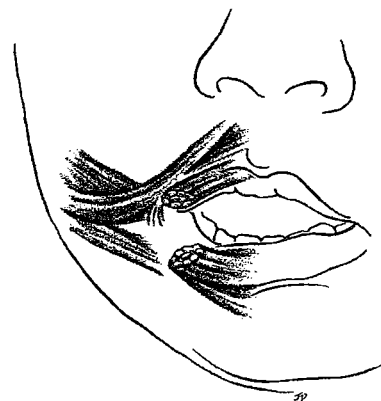
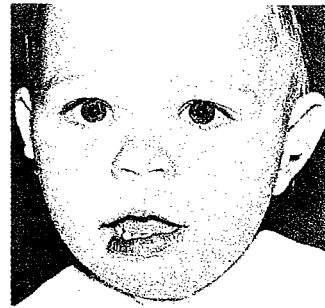According to Tord Skoog of Sweden in his 1974 book *Plastic Surgery*:

Macrostomia should be recognized as a malformation involving several tissue layers. The external defect is always combined with a more extensive separation of the deep tissues of mesodermal origin, i.e., the oral and buccal musculature.

He presented an example of a minimal lateral facial cleft possessing preauricular tabs characteristic of congenital malformations involving the first and second branchial arches. William Grabb noted in 1965 that a distinctive tag just anterior to the junction of the tragus and antitragus was almost always associated with macrostomia.

Skoog's reconstructive design was basic, using mucocutaneous incisions around the commissure defect for exposure, dissecting both ends of the orbicularis oris muscle, freeing the buccinator and then closing in three layers. The oral mucosa was sutured in a straight line and the orbicularis oris muscle stumps were approximated with 4-0 Dexon sutures to construct the sling around the commissure.

The buccinator was sutured with 5-0 catgut and the skin closed in a transverse lateral line except for a small skin interdigitation near the commissure. This technique indeed seems to be a sound and effective approach to this type of cleft.



## TRANSVERSE CLEFTS IN BILATERAL FACIAL MACROSTOMIA

In October 1974 John M. Converse, Donald Wood-Smith, J. G. McCarthy, P. J. Coccaro and M. H. Becker of New York University Medical Center presented their 15-case experience with bilateral facial macrostomia. They divided this congenital syndrome into four groups, the fourth being

macrostomia, transverse facial clefts, absent parotid ducts and abnormalities of the auricles and facial skeleton.

They elaborated in *Plastic and Reconstructive Surgery*:

This group included 4 patients, whose auricles were small and low-set bilaterally. A full complement of auricular elements was present in each. . . . One patient had preauricular pits and appendages, another showed atresia of both external auditory canals on temporal bone tomography. The remaining 3 patients had no hearing abnormalities.

Varying degrees of macrostomia and transverse facial clefting were the hallmark of this group. In two patients, subcutaneous cleft-like mesodermal deficiencies extended across the buccal region in a transverse direction toward the external auditory meatus. In two other patients, the cleft involved full thickness of the cheek—in one patient extending approximately two cm. from the oral commissure—in another patient involving the full width of the cheeks as far as the tragus. . . . The patient with the most pronounced transverse facial clefts also had a wide cleft of the hard and soft palate. Two patients, studied radiographically, also showed extramaxillary foci of bone and ectopic dentition in the region of the pterygoid processes and maxillary tuberosities. In both of these patients the mandibular excursions were restricted, but they improved after intraoral excision of the extra-alveolar segment of ectopic dentition. All 4 patients had pronounced micrognathia and some degree of apertognathia (open bite), with class II. dental occlusal relationships.

*interesting*

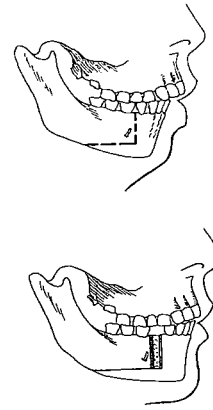
Tomographic studies showed abnormalities of the mandibular condyles, ranging from absence to surface irregularities. Each ramus tended to be shortened, the ramus and mandibular body assuming a straight-line relationship. Two patients in this group had cervical spine abnormalities.

Their plan of treatment for this group involved

(1) restoration of mandibular size and form and (2) correction of soft tissue deficiency.

In the worse of the two cases shown, there had been multiple Z-plasties of the transverse facial clefts in infancy. Further surgery included the following:

- (1) An increase in the anteroposterior dimensions of the right mandibular ramus was obtained by vertical section and iliac bone grafting; a sagittal osteotomy was done on the left ramus.
- (2) An intraoral skin graft was inlaid to remedy the soft tissue deficiency and distend the premental region.
- (3) A step osteotomy and iliac bone grafting was used to elongate the body of the mandible [as diagramed].



In spite of the zigzagging cheek scars, the result shown was excellent.

### SUMMARY ON CLEFT CLOSURE

Transverse facial clefts are associated with multiple anomalies, and the actual cleft is often the least of the problems encountered. Early closure of the cleft in layers is important to the patient's ability to feed. As the cleft transgresses the natural lines of the face, the scar of its closures must also. For this reason and for the added precaution against straight-line contracture by interruption, some form of a Z-plasty can be valuable. It is always happier to turn the main flap upward when possible, as seen on the Barbadian baby.

The other important aspect of transverse clefts, of course, is the reconstruction of the commissure. Various mucosal flap interruptions of the scar at the commissure are useful, but May's use of a small Estlander flap to reconstitute the muscle at the corner of the mouth and, even better, Skoog's reconstruction of the orbicularis oris musculature at the commissure seem sound.