

## 58. Median Cleft Lip with Hypertelorism

IN DeMyer's group II, *the median cleft face syndrome*, there is a median cleft lip, bifid nose, orbital hypertelorism and cranium bifidum occultum. The premaxilla is present except in the severest cases, but it may be cleft, with incisors erupting along the premaxillary cleft. The brain is usually normal or may show hypoplasia or absence of the corpus callosum. Intelligence is normal or only mildly impaired, and life expectancy is normal.

Embryologically, the median cleft face syndrome can be regarded as an arrest in facial development. The eyes begin on the sides of the face and, normally, migrate medially for stereoscopic vision. The nose begins relatively broad and flat, the nares being separated by a cleft formed by the medionasal processes. Somehow, the eyes stop their migration too far apart and the nose remains bifid, but whatever the process, it rarely interferes with forebrain morphogenesis and the brain develops normally.

### TREATMENT

As patients with the median cleft face syndrome usually have normal mentality and longevity, they are candidates for corrective surgery.

In 1968 I attempted a total listing of all cases of this type recorded in the literature and added four that we had treated. This listing of 25 did not include any of Brophy's 23 as no

description of the type of cleft had been made, nor did it include Davis' series, for the same reason. To my list must be added two cases reported in 1934 by Ritchie and one of Vaughan's as well as a case published by DeMyer in 1967 with a median cleft of the lip, bifid nose, orbital hypertelorism and cranium bifidum occultum. Also in 1968, Vilar-Sancho Altet described two more of this type of median cleft.

Then in 1971 Pinto and Goleria added another eight cases and described their treatment. Others have been discovered to a total of 74, as will be noted.

In 1972 L. A. Krikun reported 64 median clefts of the nose, noting the typical deformities such as the groove, hypoplasia of the septal cartilage, cleft of its anterior margin, alar cartilage atrophy and deformity, abnormal position of the triangular cartilage and nasal bones and hypotrophy of the terminal part of the nose and columella. The most frequent abnormalities of the face were found to be hypertelorism, divergent strabismus, a wedge of hair on the forehead, deformation of the frontal bone, wide separation of the eyebrows, median cleft of the upper lip vermilion and abnormal development of the dentomaxillary system.

Then there are the great cases of Tessier and, undoubtedly, there are others. It is of interest that John Converse of New York University Medical Center, as of November 1973, had a series of 26 patients with ocular hypertelorism (Crouzon-Apert). Of these, two had bilateral cleft lip and palate and one a cleft of the hard and soft palate, but none had a midline upper lip cleft.

1. Median cleft of the lip musculature without cleft of skin or vermilion was reported by Pinto and Goleria of India. Treatment: Through midline vertical skin incision, muscles mobilized and approximated across the cleft with chromic catgut. Skin closed with nylon.

2. A vermilion notch was cited in a case of H. S. Vaughan of New York.

3. In a case reported by Braithwaite of England, a median

notch of the upper lip vermilion extended upward to the level of the mucocutaneous junction, which continued upward as far as the columellar base as a flattened shallow depression. The columns of the philtrum were more separated than is normal, but the nose was normal, except for a broad columella. A double frenulum extended from the lip to the alveolus. Although Braithwaite considered his "notch" case a separate entity, subsequent cases show it to be the least of varying degrees of the same median cleft process involving the lip and nose.

4, 5. Similar vermilion notches were seen in two brothers reported by Fogh-Andersen of Copenhagen.

6. A 25-year-old white female had a minimal midline notch of the vermilion and a tiny dimple at its center with its tract extending through the orbicularis oris muscle to a fibrous band attached to the nasal spine. There was also hypertelorism (43 mm. between medial canthi) in this case reported by Bartels and Howard of Orlando, Florida. Treatment was confined to excision of the total tract and closure.

7. A 19-year-old female with a minimal vermilion notch, lack of muscle union, diastema and an ovoid swelling of the left part of the lip was operated on once before being seen by Pinto and Goleria. Treatment: Through midline incision, muscles approximated, fibrofatty mass excised and vermilion notch corrected.

8. Median notch of the vermilion and cleft of the soft palate were reported by Vilar-Sancho Altet of Madrid. Treatment: Z-plasty of the vermilion and Wardill-Veau-Kilner pushback of the palate.

9. Midline cleft of lower quarter of the upper lip with an apparently normal nose was noted by Gabka of Berlin.

10. Median cleft of the vermilion and lower quarter of the lip with groove to the columella and no nasal deformity was reported by Vilar-Sancho Altet. Treatment: Inverted V excision by paring the edges and closure in V-Y fashion.

11. A one-year-old child with partial cleft lip associated with notch of alveolus and bifid frenulum was reported by Pinto and Goleria. Treatment: Excision of central vertical diastasis and use of a double Z-plasty.

12. An 11-year-old male with a partial median lip cleft, a diastema, a vestige of a prolabium and a protuberant polypoid mass from the right nostril attached to the lower part of the septum was reported by Pinto and Goleria. Treatment: Excision of the polypoid mass and simple paring of the cleft edges in an inverted V with approximation in layers of the deeper tissues.

13. A five-year-old boy had a median cleft of the inferior quarter of the upper lip with a vertical submucous cleft extending to the columella associated with two pedunculated club-shaped skin masses, one projecting from the septum out of the left nostril and the other from the alveolus margin between the central incisors. There was also a double frenulum, crescent defect of the left ala, bony depression over the frontal bone and hypertelorism in this case reported by Laxman Sharma of Nagpur. Treatment: V excision of cleft margins closed lip defect. Septal mass used in reduced form to reconstruct alar margin.

14. A median cleft of the lip from vermilion to columella with a normal nose was reported by H. P. Ritchie of St. Paul.

15. A six-month-old boy with median cleft of half of upper lip, short broad columella with median groove, alar cartilages separated in the broad nasal tip and double frenulum was noted in India by Laxman Sharma. Treatment: Three-layer closure of lip cleft after paring of edges and dissection of muscles.

16. A 30-year-old male with a partial cleft of the vermilion, a double philtrum, irregularity of the teeth with a supernumerary incisor just below the cleft and cleft of the left nostril was reported by Pinto and Goleria. Treatment: V excision of middle of lip with approximation in layers and local rotation correction of notched nostril.

17. A midline vermilion cleft with shortened nasal alar cartilages, atypical cleft palate, malformed lobulated tongue and normal chromosome findings (oral-facial-digital syndrome) was reported by Brucker and others.

18. An oral-facial-digital syndrome with a slight median cleft lip, atypical cleft palate and 13-15 trisomy was reported by Fogh-Andersen.

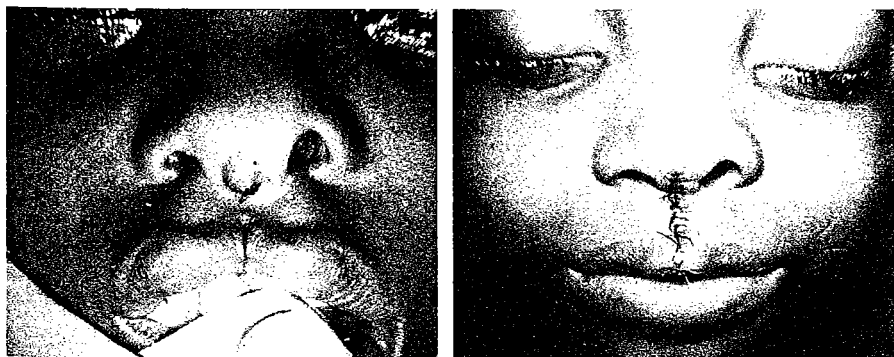19. An oral-facial-digital syndrome with a slight median cleft lip, atypical cleft palate and normal chromosome findings was also reported by Fogh-Andersen.

20. Oral-facial-digital syndrome was associated with cleft in the mid-portion of the tongue with long pedunculated mass of tissue, pseudocleft of mid-upper lip border, total absence of premaxilla, hypertelorism, atypical cleft of secondary palate and encephalocele in palate fissure. Treatment: Encephalocele operated on at six months and lip and tongue at one year. Tongue mass revealed flat epidermal-like epithelium without keratinization covered with nests of striated muscles in richly vascularized connective tissue stroma as reported by Poradowska and Jaworska.

21. Oral-facial-digital syndrome was associated with pseudocleft of the mid-upper lip extending to the alveolar process, short columella, gross mandibular hypoplasia, complete cleft of secondary palate with fibrous band running from buccal mucosa, trilobulated tongue attached to the floor of the mouth and microphthalmus. No treatment because of early death. Case reported by Poradowska and Jaworska of Warsaw.

22. A pseudo-median cleft of the upper lip was found in one patient with Treacher Collins syndrome by Poradowska and Jaworska.

23. A seven-year-old Haitian girl (operated on at Albert Schweitzer Hospital, Des Chapelles, Haiti, 1964) had a median upper lip cleft extending vertically through the vermilion and skin about 1 cm. and continuing as a flattened shallow depression to the base of a broad columella. The philtrum columns were widely separated, the columella was wide and it had a vertical elevated ridge running up its center. The left nostril was larger



than the right. There was no alveolar notch or palate cleft. This is just a more advanced degree of notching, with the same but more exaggerated ancillary deformities. The case was published in *Plastic and Reconstructive Surgery*, July 1968. Treatment: Elliptical excision of the midline columellar prominence narrowed the column. Excision of a narrow inverted shield from the flattened central lip moved the philtrum column into better position, created a suggestion of a philtral concavity and produced the skin lengthening and the vermilion fullness of a cupid's bow and tubercle.

24. A nine-month-old male child with a wide median cleft of the lip, cleft of the alveolus and broadening and flattening of the nose, lip and columella with a fatty mass protruding from the base of the columella was reported by Pinto and Goleria. Treatment: The lip was closed by a vertical excision and a double Z-plasty. A vertical excision of the skin of the polypoid mass allowed use of the fatty tissue to round off the flat nasal tip.

25. A median fissure through the nasal tip, columella and lip was reported by H. P. Ritchie.

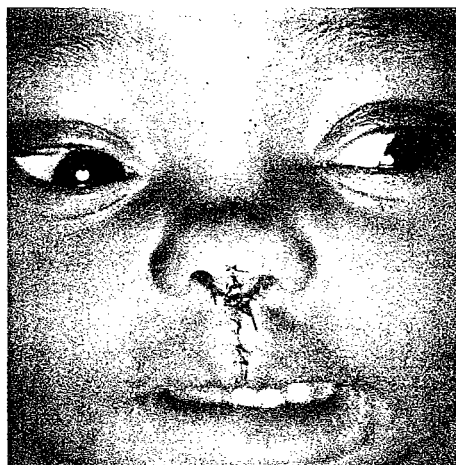
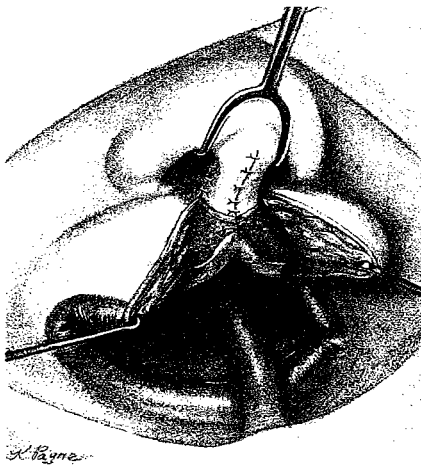
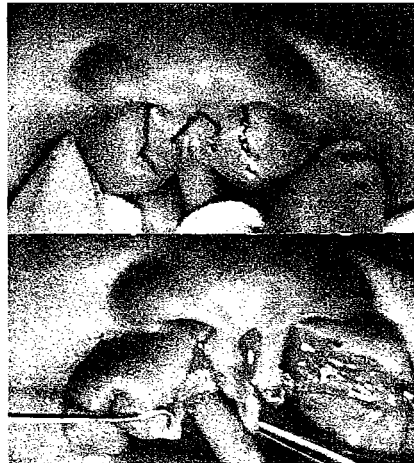
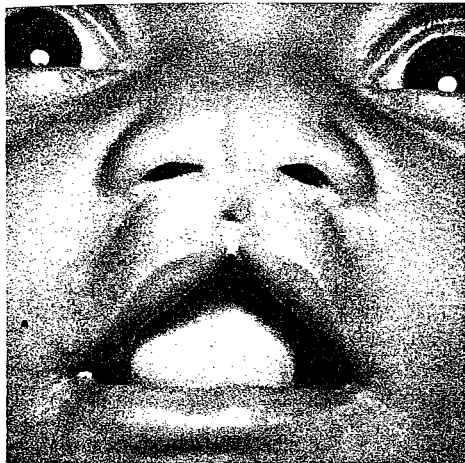26. A case of bifid nose with minimal median cleft of the upper lip extending into the alveolus was reported by Francesconi of Italy for Mustardé.

27. A 19-year-old female presented a partial median cleft of the lip, bifid frenulum, bifurcation of the nose, which was short but broad, and a diastema, as reported by Pinto and Goleria. Treatment: First step in treatment was a forked flap to elongate the columella and a V excision of the middle of the lip with closure in layers.

28. A one-year-old child with a median cleft of the lip and alveolus, a bifid nose with a projection of fibrofatty tissue from both nostrils and a coloboma of the right upper eyelid was presented by Pinto and Goleria. Parents refused surgical correction.

29. An incomplete median lip cleft, cleft palate and meningocele of the septum was reported by Baibak and Bromberg of New York.

30. A six-month-old Jamaican boy (operated on at the Kingston Public Hospital, 1963) had a median cleft of the vermilion and skin about one-half the vertical length of the upper lip. The philtrum columns were widely separated, with a groove extending to the columellar base. The columella was quite broad, contained a raised vertical ridge and was extremely short. There was a slight midline notch in the alveolus. This case was published in *Plastic and Reconstructive Surgery*, July 1968.



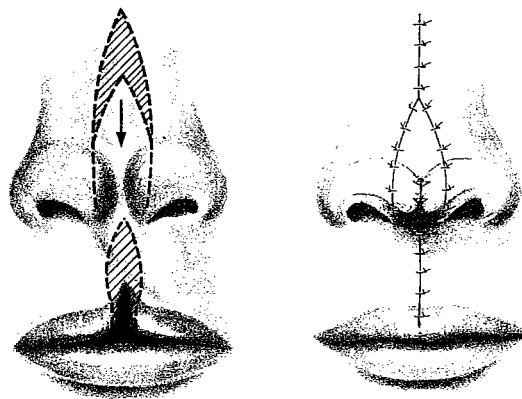
Treatment: A forked flap was marked on the medial flattened edges of the lip cleft. The midline ridge was excised from the columella; it was then narrowed and lengthened by advancement of the forked flap. The freshened lip was brought together effectively in the midline. Sutures were removed on the fourth postoperative day, and wounds were healing well. Patient never returned to the clinic for follow-up.

31, 32, 33. Median clefts, referred to as "true" and associated with malformations of the hands, were in Fogh-Andersen's series.

34. Stephanie in 1939 reported a median cleft of the upper lip with reduplication of the columella and nasal tip.

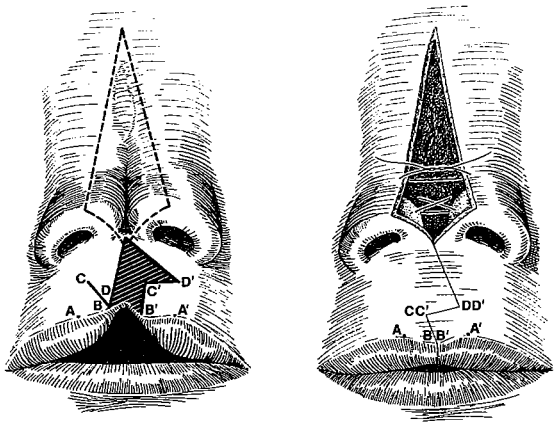
35, 36, 37, 38, 39. Esser in 1939, from Sanvenero-Rosselli's clinic in Milan, reported five such cases of median cleft lip and reduplication of the columella and nasal tip. These five were all in the same family!

40. Peet and Patterson of Oxford presented a bifid nose with a partial median cleft lip but no defect of the alveolus and palate. Treatment: After simple approximation of the lip elements, an inverted V to Y advancement of the excess skin from the wide upper nasal bridge moved tissue into the bifid tip. The alar cartilages were later approximated for an excellent result.



41. An adult with median cleft of the lower one-third of the upper lip and a true bifid nose with flattening and separation of the nasal bones and a cleft between the alar cartilages was reported by Francesconi of Italy in Mustardé's 1971 book, *Plastic Surgery in Infancy and Childhood*. Treatment: His management of this case is of interest. A midline vertical excision of the skin and subcutaneous tissue of the nose and lip was followed by approximation of the separated nasal structures and a modification of the Hagedorn-LeMesurier quadrilateral flap for the construction of the upper lip.







Of equal interest are his thoughts on the causes of the deformity and the timing of the surgery. Giuseppe Francesconi of the Universities of Pisa and Milan developed his early interest in median malformations while in training with Sanvenero-Rosselli. During that time he had followed 12 cases, and since then he has added another unpublished four, one of which with rhinencephalon has been studied in anatomical detail. He tends to accept Sanvenero-Rosselli's suggestion that bifid nose and median clefts of the lip are anomalies produced by disturbance in the fusion of the median raphe or median dysraphia of the face.

In his ancient villa in the Tuscan country near his Hospital of Lucca, Francesconi can escape these depressing malformations long enough to think and write about them. He expressed his leaning toward wise old Kazanjian's "late reconstruction," stating

that extensive surgical procedures performed in childhood on delicate structures such as the nose may be dangerous. Although perhaps producing a satisfying result initially, the late result may be disastrous due to interference with normal tissue growth as the result of the trauma of the operation. Nevertheless, small operations . . . can be performed in childhood to improve nasal respiration and get rid of some of the deformity but a full plastic repair of the nose, which will involve cartilage and bone, must be deferred until late childhood or early adult life when the nasal structures are more developed.

42. A case was reported by Weaver and Bellinger of a median cleft of the lip extending to the base of the columella, with a split in the nasal septum, divarication of the alar cartilages and a bifid nose without skin division. Hypertelorism was present. Treat-



*Giuseppe Francesconi*

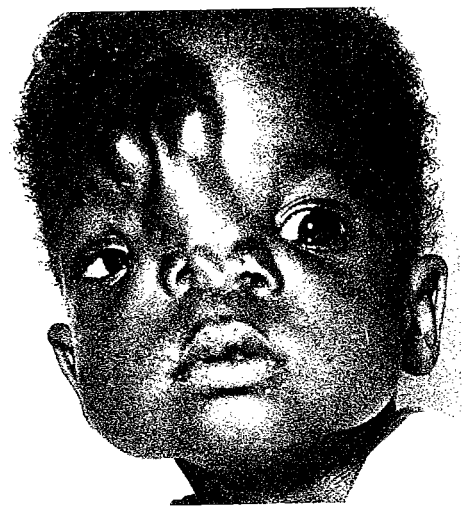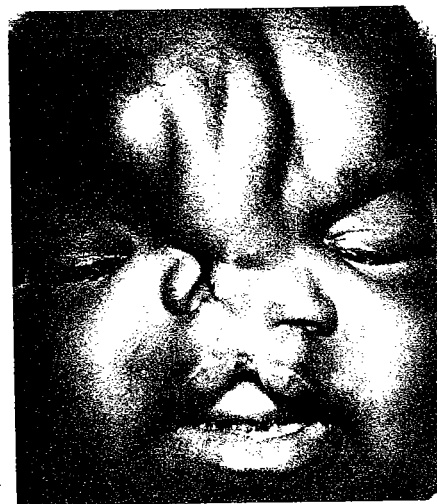ment: This median cleft of the lip was closed by freshening the edges at two weeks of age. At two months the divided septum and alar cartilages were approximated, but no attempt was made to narrow the widely separated frontal processes of the maxilla. At three years the child still had a wide nasal bridge and tip.

43. A similar case (to 42) was reported by Lagos Garcia with a median lip cleft, bifid nose and hypertelorism.

44, 45. Similar cases to 43, and similar to each other except that one was Negro and the other Caucasian, were reported by G. C. Scrimshaw of Oakland. Both had median clefts of the lip and alveolus, bifid noses and hypertelorism.

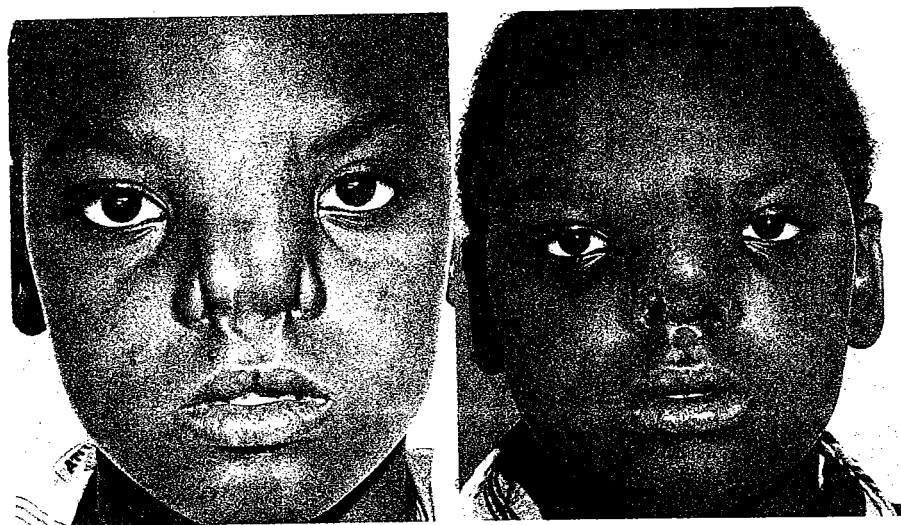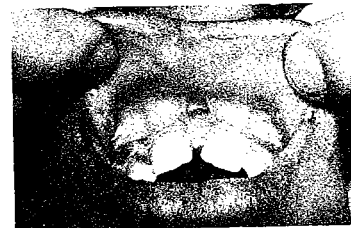46. DeMyer published a case with a median cleft of the lip, orbital hypertelorism, low V-shaped hairline, cranium bifidum occultum, bifid nose, median cleft palate, cleft premaxillary bone and normal life expectancy. No treatment was mentioned.

47. A three-month-old Jamaican girl was seen by us with an incomplete median cleft of the lip and bifid frenulum, but without cleft of the alveolus or palate. There was an asymmetrical bifurcation of the nose with a short wide columella and cleft of the right alar arch, and the right ala was high. Hypertelorism was present, as was a frontal bone defect with an encephalocele and convolutions of excess forehead skin.



This case was published in *Plastic and Reconstructive Surgery*, July 1968. Treatment: Still incomplete. A modified forked flap and midline closure of the lip cleft was carried out, along with alar rotation and transposition flaps by Sydney Williams. A neurosurgeon advised postponing any split-rib grafting to the frontal defect until the patient was older.

48. A 10-year-old boy from the island of Antigua with a median cleft of the lip vermilion was seen by us. He had a developmental confusion of the upper philtrum with divergence of the columns and a columella that was either absent or extremely wide. The nasal tip was wide and flat, the alae were notched bilaterally, the nasal bridge was wide and flat, and there was associated hypertelorism. A bifid frenulum was noted. His intelligence was within normal limits. This case was presented in *Plastic and Reconstructive Surgery*, July 1968. Treatment: A forked



flap of the diverging philtrum columns was used to construct a columella. An L-shaped Silastic implant gave support to the tip and bridge. The alar notches were corrected by rotation into normal position. The patient's return to Antigua postponed further nasal work.

49. A case was reported by Kazanjian in 1959 of a wide median cleft of the upper lip with absence of the prolabium and apparent absence of the premaxilla. Yet, at age three to six years

the patient presented upper incisors which had to be extracted, as their roots were not surrounded by solid bone. The palate appeared to be normal but x-ray films revealed separation of the two maxillae. There was a severely bifid nose with a split columella and small symmetrical functioning nostrils one inch apart. Hypertelorism was also present. Treatment: At four months of age the median cleft lip defect was approximated, and the nasal bifurcation was brought together. Subsequent multiple procedures included surgery of the cartilage and bone; later, bone and cartilage transplants were done, followed by a forehead flap rhinoplasty. At the age of 26 years, the patient had developed well mentally. In retrospect, the surgeon regretted having operated on the bony section of the nose before the age of 15 years.

50. A similar case to 49, with median lip cleft and severe bifid nose, was reported by Baibak and Bromberg.

51. A case of median cleft lip and bifid nose was reported by Patten of Oakland.

52. A case of epignathus associated with a median lip cleft, palate cleft, bifid nose and severe hypertelorism was reported by Hirshowitz, Mahler and Heifetz of Haifa. Treatment: Surgical excision of tumor with postponement of surgical correction of the median lip cleft and bifid nose. Soft palate cleft was to have standard closure.

53. A 14-year-old Filipino boy had a bifid nose, encephalocele, microphthalmus, hypertelorism, median cleft of the lip, cleft of the primary palate and partial cleft of the secondary palate. Tomographic studies revealed an intact hard palate. Case reported by Converse, Horowitz and Becker of New York.

54. A case of marked bifid nose with a median furrow associated with a median cleft of the upper lip and hypertelorism was reported for Converse by Wang and Macomber of Albany.

55. Midline partial cleft of upper lip associated with broad nasal root in an infant girl with orofaciogigital syndrome was reported by Fuhrmann, Stahl and Schroeder.

56, 57, 58. Three siblings, a sister and two brothers, each with a median cleft of the upper lip and associated polydactyly in the girl and one boy, were reported to me in 1974 by Joya Chowdhury of Calcutta.

59. A median cleft of the lip with a normal nose but hypertelorism which was closed "simply" and was progressing well at two years of age was reported by R. Mladick, C. Horton, J. Adamson and J. Carraway of Norfolk, Virginia.

60. A median cleft of one-third of the upper lip with a groove extending to the columella and aptly entitled "The True Hare Lip" was reported in 1974 by James A. Lehman, Jr., and Suburraydu Cuddapah of Akron, Ohio. There was an associated double frenulum and tubercle and a flattened nasal tip and wide columella vaguely suggestive of a subliminal bifid nose. Treatment: Cleft marginal incisions, muscle approximation in the midline, and a "white roll" interdigitation at the mucocutaneous junction, which at one year revealed an excellent result.

61. Median cleft of the upper lip vermilion with hypodontia and occurrence of Ellis-van Creveld syndrome reported by Norbert Schwenzer of the University of Tübingen, West Germany. Treatment: Correction in one operation at age six years.

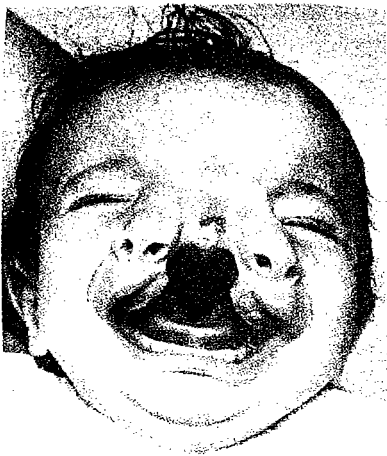62. Unusual median cleft extending from the white portion of the lip to the lower third of the philtrum without complete fissure of the tissue. Treatment: Full thickness V excision correction at age two years by N. Schwenzer of West Germany.

63. A case with bilateral paramedial facial clefting, severe orbital hypertelorism, absence of nasal air passages and deformities of upper and lower extremities was reported in 1974 by Edgerton, Jane, Berry, and Fisher of the University of Virginia Medical Center, Charlottesville. Treatment: Glabella osteotomy, forehead flap for nasal lining and steel wiring at four months in an attempt at early shifting of the canthi. At eight months an abdominal flap on wrist vector was transported to create an adult-size nose. Further correction of orbital hypertelorism was planned prior to school age.

64-68. J. Chowdhury of Calcutta reported five siblings, three males and two females, with V- or quadrilateral-shaped median clefts of the vermilion of the upper lip. They each had postaxial polydactyly. No mention was made of the treatment as the surgery would be simple. It was found that these patients, their normal siblings and their parents all revealed no abnormalities in the chromosome studies.

69. A 57-year-old adult male with a median cleft of half the upper lip, a severely bifid nose and orbital hypertelorism was presented by David Frost on TV on January 18, 1975, from Gibsonton on the Gulf coast of Florida, where the freaks winter. This carnival performer, billing himself as the two-faced man, has been a popular attraction for years in the sideshow. He revealed remarkable adaptation to his untreated condition with not only a successful career in show business but a happy marriage to the lady two tents down exhibiting a peculiar skin condition.

Recently, Riccardo F. Mazzola of Milan University made a remarkable report of frontonasal malformations including five additional midline clefts belonging to this general category and one most unusual *dyprosopia*.



70, 71. Vermilion lip notch and bifid nose. No treatment reported.

72, 73. Midline cleft of the lip, bifid nose and hypertelorism. No treatment reported.

74. Median notch of lip, bifid nose and hypertelorism. No treatment reported.


Here is a very rare duplication of the face (*dyprosopia*) with a wide central cleft of the lip, alveolus and palate separating two well-formed, independent noses. Hypertelorism is present with an extra midline orbit, together with its eyebrow.

In the median cleft face syndrome, there are several general areas of surgery, which will be discussed in the sections that follow.

### MEDIAN CLEFT OF THE LIP

If the cleft of the lip is minimal to moderate, the paring of the edges in an inverted V excision will allow a three-layer closure. A 90-degree angle in the excision is made 2 mm. above the mucocutaneous white roll on each side of the cleft. Approximation of these angles will give the lengthening of the skin in the specific area of the center of the cupid's bow. This will provide not only the skin "spear point" but the heaping of the vermilion of a midline tubercle to create the semblance of a natural cupid's bow.

In cases in which the columella is wide, the V excision should be extended to narrow the column.




If the lip cleft is minimal with a wide columella, then the columella reduction should be carried out separately.

When the cleft is extremely wide, a midline primary composite lip flap switched from the lower lip is available and can be used if direct closure of the cleft would tighten the upper lip relatively more than the lower.

### SHORT COLUMELLA

If the columella is short, the sides of the lip cleft can be taken as a forked flap. This procedure, in turn, will freshen the edges of the cleft and allow closure in an inverted V fashion in layers. Again, if the edges of the cleft are incised 2 mm. from the mucocutaneous junction with 2 mm. transverse cuts, the skin point of the center of the cupid's bow can be created along with the vermilion tubercle.



## BIFID NOSE

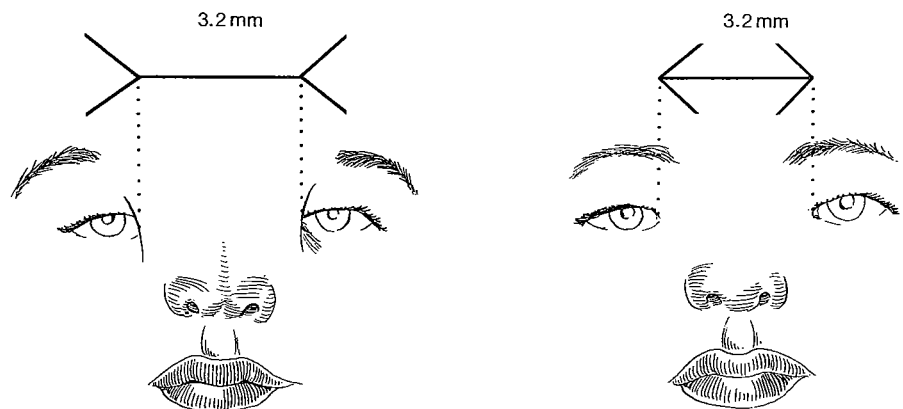
This deformity varies greatly in depth of the clefting, extent of spread and amount of asymmetrical distortion. Surgical correction includes bisection with removal of the excess mid-portion of skin, subcutaneous tissue and bone combined with the shifting of the distorted elements into balance. Closure should bring alar cartilages side to side. Alar notches are usually corrected by local rotations.



Jerome Webster

## BIFID NOSE AND HYPERTELORISM

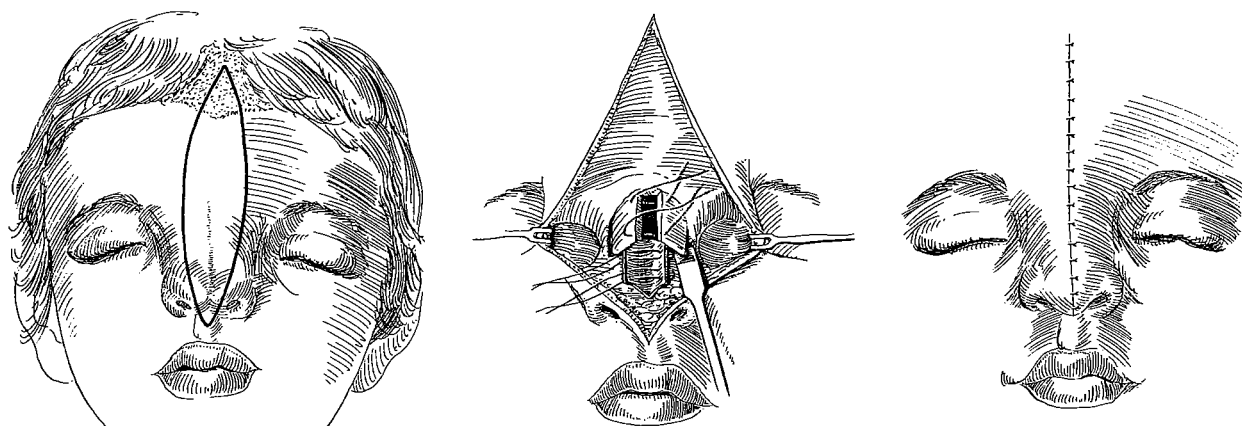
Jerome P. Webster, New York plastic surgery tycoon of Presbyterian Hospital and College of Physicians and Surgeons, Columbia University, in his 1950 classic treatise with Deming in *Plastic and Reconstructive Surgery* on treatment of the bifid nose, pointed out the association with hypertelorism, either true or suggested, in 8 of his 10 cases. Yet true hypertelorism, or actual increase of the interpupillary distance, was present in only 4 of the 10. He pointed out with symbols that the illusion of hypertelorism was produced by wide spacing of component parts of the face adjacent to the eyes, such as increased intercanthal distance, flatness of a broad nasal bridge, presence of epicanthal folds and widely spaced eyebrows.



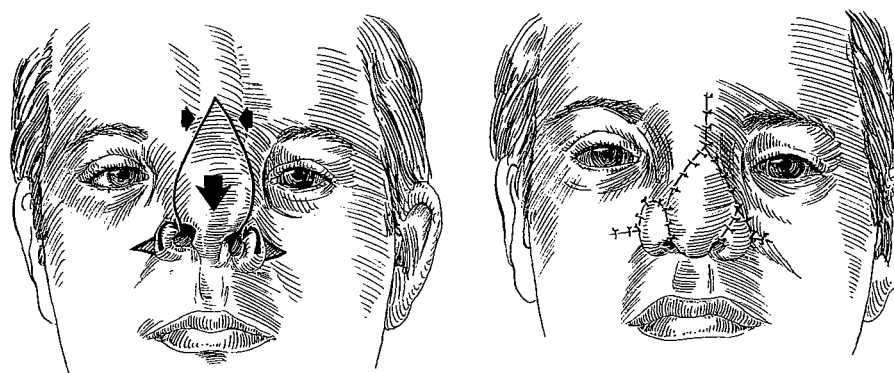
In that pre-Tessierian era Webster focused his surgical action on soft tissue and nasal bone reduction and shifting to reduce the illusion. He excised a wide vertical ellipse of forehead, glabella,



nasal bridge and tip skin from the columella all the way up into the hairline. He also resected the excess of the widened nasal bones, shifted them after in-fracture and fixed them with wiring. In addition he removed the subcutaneous fat at the sides of the nose and achieved medial shifting of the inner ends of the eyebrows by excision of the skin between or by V-Y advancement.



If, in addition, the nostrils were notched or retracted with the nasal tip flattened and the nose short, he advanced the entire skin of the nasal dorsum and glabella downward in a large V-Y, which not only narrowed the nasal bridge and corrected the tip but moved the eyebrows closer together.



As elevation of the nasal bridge is also effective in camouflaging the effect of wide eyes and improving epicanthal folds, onlay bone and cartilage grafts were advocated as a secondary procedure. In order to allow growth through infancy and early child-

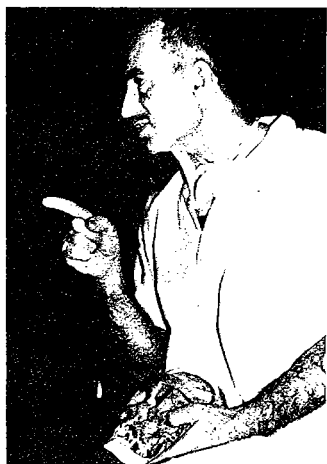hood, this aspect of surgery was postponed, but no longer than late childhood to reduce the inevitable psychic trauma.

Even these less extensive procedures can be time-consuming. J. P. Webster—"Webby" to his friends—was one of the founders of the American Board of Plastic Surgery and a great teacher, as is attested by the products of his renowned students. His meticulous and absolute attention to detail with no concern for time started a rumor that he operated at Presbyterian Hospital by the calendar rather than the clock. This is an appropriate time to repeat a Gillies principle: "Speed in surgery is never having to do the same thing twice." Get it right the first time without concern for the little extra time and beware jubilation over rapidity of action. Have your *result* rather than your speed of execution *breathtaking!*

#### ORBITAL HYPERTELORISM

As noted previously, median clefts of the lip are occasionally associated with orbital hypertelorism and can be treated simultaneously. The orbital hypertelorism with increased distance between the orbits, of course, is the major problem, involving surgical resection of the excess portions of bone and the shifting of the orbits together.

#### THE TESSIERIAN ERA



Paul Tessier

The imposing and dedicated Paul Tessier of Foch Hospital, Paris, a man of quiet poise, subtle charm and natural magnetism, has fathered this specialty, and others are following his inspiration and teaching. In the 1972 *Scandinavian Journal of Plastic and Reconstructive Surgery*, Tessier suggested the term *orbital hypertelorism* (OR.H.) and described it as a congenitally

abnormally wide distance between the orbits and hence the eyes . . . [and] . . . is always a secondary syndrome, generally due to a facial or cranial cleft and sometimes to craniostenosis. Inter-orbital distance (I.O.D.) has to be measured on the skull [as the distance between the two "dacryons" (lacrimal crests) on a telerradiograph] or less accurately by measuring the distance between the medial canthi (I.C.D.). . . . Average normal I.O.D. is 25 mm.

in females, 28 mm. in males. Classification is based on the degree of inter-orbital widening. . . . 1st degree, I.O.D. 30 to 34 mm., is euryopia or telecanthus. 2nd degree, I.O.D. more than 34 mm., orientation and shape of orbits still are nearly normal. 3rd degree, I.O.D. usually 40 mm., orbits appear lateralized, the cribriform plate is often prolapsed, and the distance between the lateral canthus and auditory meatus is shortened.

Tessier concluded his opening abstract with this encouraging note:

We now have the proof that we can safely displace the whole of the "useful orbit" (i.e. within 8 to 10 mm. from its apex) in the three directions: transversely, as in OR.H.; sagittally, as in retrusion of the face or frontal bone . . . ; vertically, as in orbital malpositions secondary to trauma or to some complete orbitofacial clefts, generally unilateral.

Postsurgical review of efforts by Converse and Smith in 1959 and 1962, Schmid in 1966 and his own work with Guiot and Rougdrie in 1963 and 1965 showed that they were doomed to failure for, as Tessier noted:

They only moved a small portion of the orbital rim and practically nothing either of the orbital walls or periorbitum, and therefore had little effect in moving the globe itself.

This and other aspects pointed to the necessity for correction by the intracranial route, which was considered as early as 1960 but, as Tessier later wrote:

Nevertheless, it could not be carried out as long as there was a danger of meningeal infection; therefore, we decided to perform a preliminary operation to explore the anterior cranial fossa and to reinforce the dura by means of a dermal graft.

#### *Infrabasal or cranial routes*

If the medial orbital wall is vertical and if the olfactory grooves do not prolapse, an infrabasal osteotomy under the cribriform plate will be located above the eyeball equator and will promise success.

If the supraorbital rims diverge a good deal, if the nasal wall of the orbit is oblique and if the ethmoidal prolapse is noticeable, infrabasal osteotomy would be ineffective and the cranial approach is indicated.

Translocation of the orbits, including thin medial walls and hence the frontal process of the maxilla, which is the only strong structure, produces an atresia of the nasal airways, precipitating the necessity for full-thickness septal resection. Hypercorrection is suggested to counteract further growth in the child and to prevent possible intercranial hypertension.

*Tessier's general surgical indications*

For 1st degree cases with minimal hypertelorism, treatment consists of palliative operations. 2nd degree cases involve partial ethmoidectomy via infrabasal route when ethmoidal prolapse is not noticeable. 3rd degree cases involve orbital ethmoidectomy via the intracranial route.

It has been said of the results of this craniofacial surgery: "This is herculean effort to transform the hideous into the ugly."

Tessier responds to that vague retort:

It appears that OR.H. has to be taken in consideration much more from an aesthetic point of view than from a functional one [in these mentally normal patients]. The abnormally wide I.O.D. is ungraceful. However, ugliness arises from the primitive malformations which produce OR.H. Here is the stumbling block. We can easily move the orbits and eyes closer together and grossly correct OR.H. but that does not mean that binocular vision is now possible in every case nor that ugly facial deformities and defects are avoided.

In 1972 I asked my friend Tessier how many cases he had had of median cleft lip associated with hypertelorism and whether he would send examples with the outline of their surgery. He responded in June:

Many cases of ocular hypertelorism have a median cleft lip, but this cleft is more or less complete, sometimes rudimentary. Most of them also have a frontal encephalocele.

Some cases have been previously operated on probably because their cleft was complete, but I cannot assess.

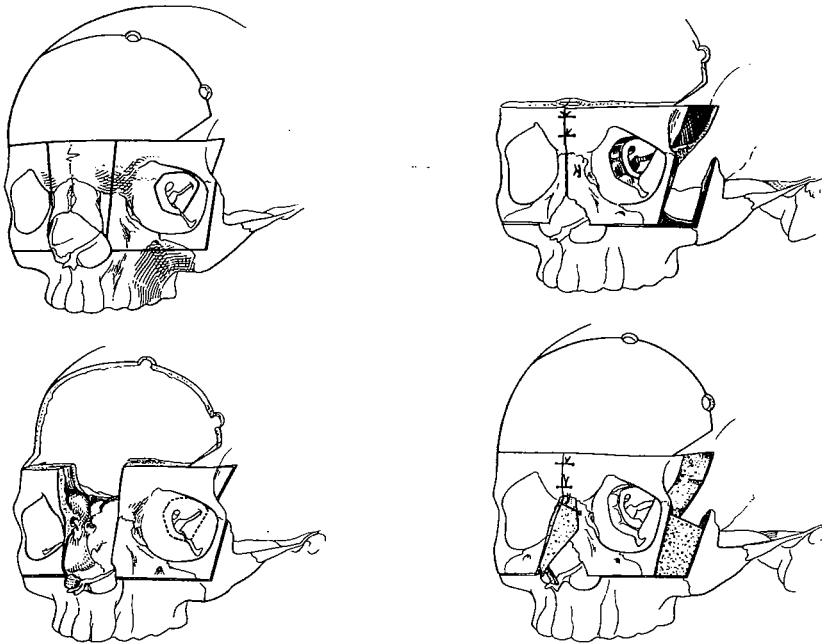
	Observed	Operated
Complete	3	2
Partial	3	3

Enclosed, please find two operated cases: complete and partial.

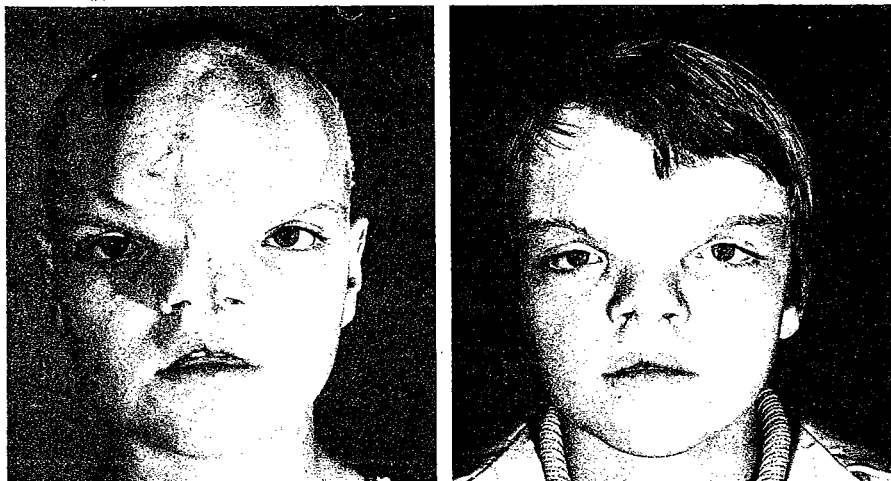Further details were forwarded in 1973:

The same basic procedure has been used for these two patients.

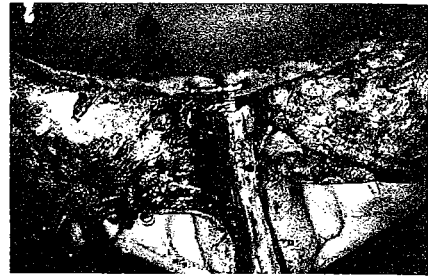
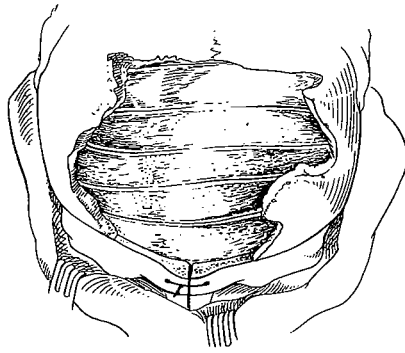
- cranial and facial routes
- fronto-naso-ethmoidal resection
- “square like” osteotomies all around and inside the orbits
- bringing the orbits closer together
- bone grafts of the four orbital walls and of the malar bone
- bone graft of the nose.



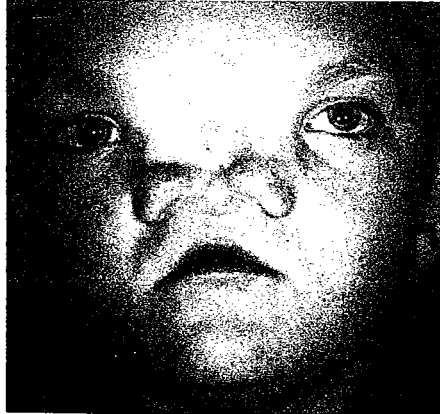*The partial cleft case*



The patient with encephalocele also had rib-grafts of the frontal defect, as figured on the drawing.



*The complete cleft case*



The case without encephalocele had a "crown-like" frontal bandeau used for locking the orbital frames in a backward position in order to prevent enophthalmia, as figured on preoperative pictures.

Paul Tessier, it seems, gravitates toward the "big ones" in both work and play. As a break from his 12-hour-a-day "skull crack-ing" surgery he chose to hunt bull elephants in French Equatorial Africa. In khaki jacket and bush helmet, accompanied by 40 black porters in white loincloths, he set off from Bangui into the

jungle on foot. Days later he reappeared with his line of black porters heavily laden with giant tusks of ivory.

There is a charming story of Tessier and Dingman in Paris after one of Tessier's operations for hypertelorism. Reed Dingman, not only an expert hard tissue surgeon himself but also a well-known big game hunter, in typical generous sincerity, congratulated Tessier on his great operation. Whereupon the quiet Tessier, somewhat out of character, said:

Reed, if you think *that* was good, come let me show you something even better!


He led Dingman to his locker and brought out a giant elephant tusk exclaiming,

What do you think of that one? I have looked up your tusk record, Reed, and this is larger than any of yours!

and they all had a good laugh.

John Marquis Converse of the New York University Medical Center was asked what he considered to be his contribution to the operation for hypertelorism and he responded by recalling that Tessier, in his first stage, opened the cranial fossa and cut through the olfactory nerves placing a dermal graft over the frontal lobe and, in the second stage, proceeded with the necessary orbital osteotomies. He summarized his 1970 work with J. Ransohoff, E. S. Mathews, B. Smith and A. Molenaar with:

In checking over the x-rays of all of our cases, I noticed that the cribriform was not enlarged and conceived the idea of preserving it, thus also preserving the sense of olfaction [and of taste]. We were able to develop the one-stage procedure which is now generally employed.



*John Converse*

## CRANIUM BIFIDUM OCCULTUM

Median cleft lip may be associated with midline clefts of the cranium often involving the scalp. According to J. J. Longacre in 1964:

In the newborn, the management is conservative, and the patient is placed under continuous observation. The necessity for operation on the larger

lesions overlying the superior sagittal sinus has been stressed by Peer and Van Duyn (1948) and Kahn and Olmedo (1950). These authors point out that if the lesion is more than 1 to 2 cm. in width it may become necrotic. Reconstruction with a scalp flap is recommended. In the larger lesions, the skull defect does not close spontaneously and grafting with bone (split-rib grafts) . . . is necessary at a later stage to provide an adequate protection to the brain.

#### WAARDENBURG SYNDROME, OR MENDE'S SYNDROME

In 1948 P. J. Waardenburg precisely described the syndrome of (1) congenital deafness, (2) lateral displacement of the medial canthi and lacrimal puncta with broad nasal root or telecanthus (pseudohypertelorism), (3) white forelock, or poliosis, (4) heterochromic irides and (5) hyperplasia of the medial portion of the eyebrows. In 1926 I. Mende also described the syndrome, as did Van der Hoeve in 1916 at least in part. The condition is inherited as an autosomal dominant characteristic and is seen in an estimated 2 percent of all congenitally deaf persons. R. J. Gorlin and J. J. Pindborg in 1964 noted that neither Mende nor Waardenburg had included lip clefts in the syndrome and mentioned that lack of clefts was also their experience. In 1961 A. Pirodda reported that cleft lip-palate and other palatal alterations were not uncommon in this syndrome. Then in 1965, independently, Feinberg, Hansen et al. and Puxeddu and in 1967 Reed et al. reported cases with cleft lip and/or palate.

According to Gorlin, Cervenka and Pruzansky, the syndrome described by Klein in 1950 was different from the Waardenburg syndrome. As they said,

Deafness, partial albinism, blepharophimosis and bony and muscle deformities of the shoulder girdle, in our opinion, represent another Syndrome.