

54. *Tight Upper Lip*

TIGHT UPPER LIP WITH PROLABIUM

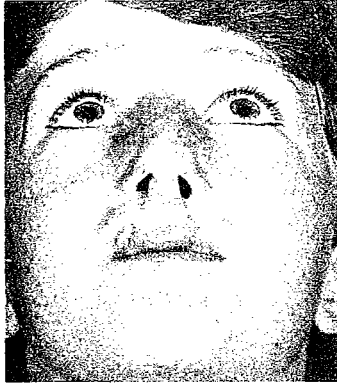IN certain cases the prolabium has been incorporated into the full vertical length of the lip with depression of the nasal tip, but either because of the smallness of the original prolabium or because of the union of the lateral lip elements at the inferior border of the prolabium, this prolabium has not stretched. The general effect is of a relatively tight upper lip exaggerated by a slack, protuberant lower lip. Such a case for some surgeons will cause the thought "Abbe flap" to flash on automatically; then, as no other information is flashed with it, the prolabium is released by being split up the middle, and the lower lip flap is switched into it. This is an unacceptable solution because it immediately increases the vertical scars to four and leaves the depressed nasal tip unrelieved.

Believe it or not, there are other surgeons who jump the track completely and actually place the Abbe flap unilaterally in bilateral cases. The reasoning is difficult to understand, but the correction is even more bewildering.

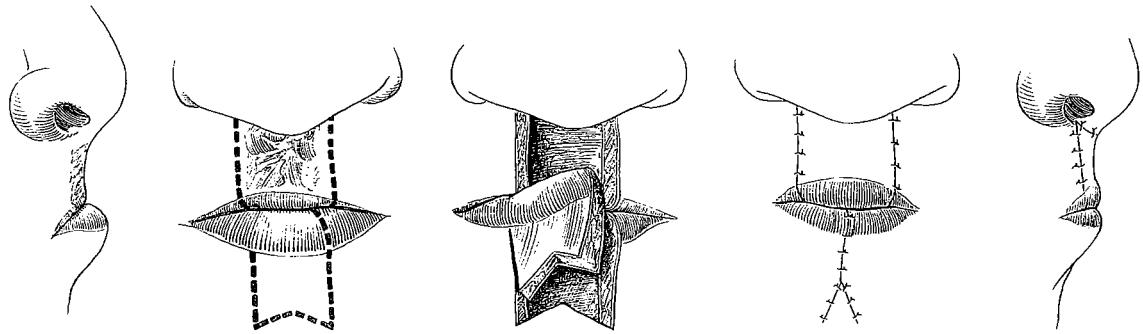
Actually, the best method of handling the relatively tight upper lip with the small prolabium incorporated in it is to shift the entire prolabium up into the columella, and there is seldom a columella that will not welcome the additional tissue. Then an Abbe flap can be transposed into the defect left in the upper lip.

Shifting the entire prolabium is preferred in order to reproduce the philtrum as a single lip-switch flap unit. Prolabium advancement into the columella will call for the standard membranous

septal incision carried up over the bridge of the septum. The prolabium will require thinning and shaping and may have to be rolled on itself with subcutaneous sutures particularly at the nasal tip to simulate a columella. In the male there may be hairs, which can be discouraged by follicle excision. Hairs in this area usually are sparse and any that survive surgery can be kept clean during the morning shave. The end of the prolabium can be split and splayed at the base of the new columella.




With the prolabium slid up into the nose, the upper lip presents a yawning gap which has frightened many a surgeon to cut an Abbe flap too wide, too long, and unimaginatively straight. It plugs the upper lip with an inartistic square segment which in no way can be mistaken for a philtrum.



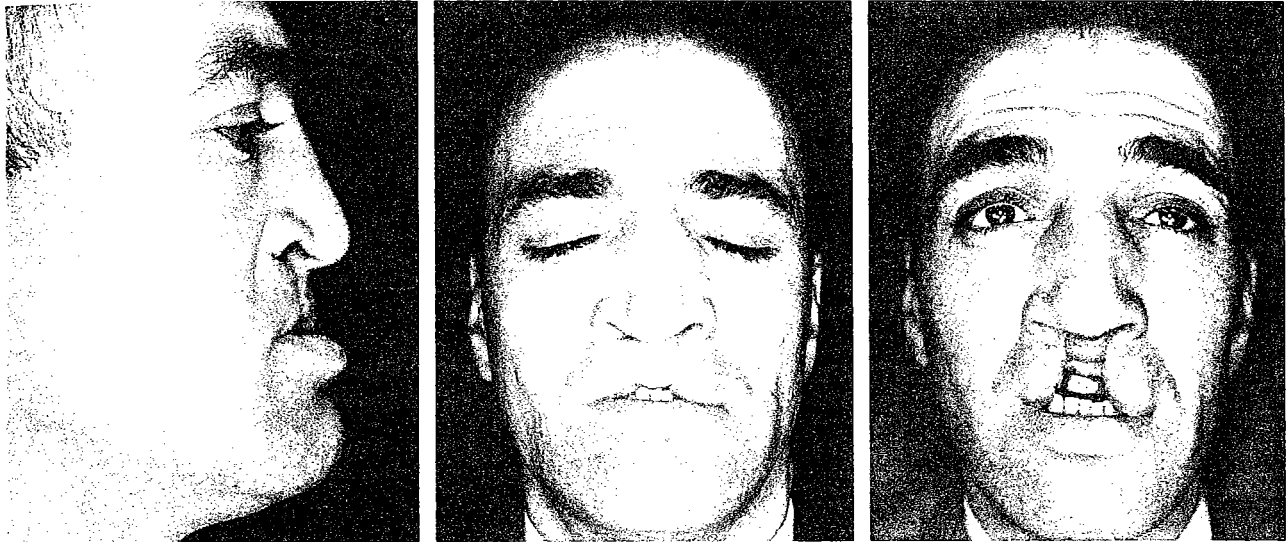
MY FIRST BILATERAL SECONDARY

Anyone who cuts the lower lip flap the exact size dictated by the upper-lower lip relation before the switch, without accounting for the simultaneous reduction in the lower lip at the time of the switch, is in for a shock. This kind of calculating has a double backfire, producing very big upper lips ballooning over their lower lips, now drawn irreversibly too tight. This is the course I took in 1949 in my first Abbe flap case, and Gillies, who used quite large Abbes himself, ticked me off for it.

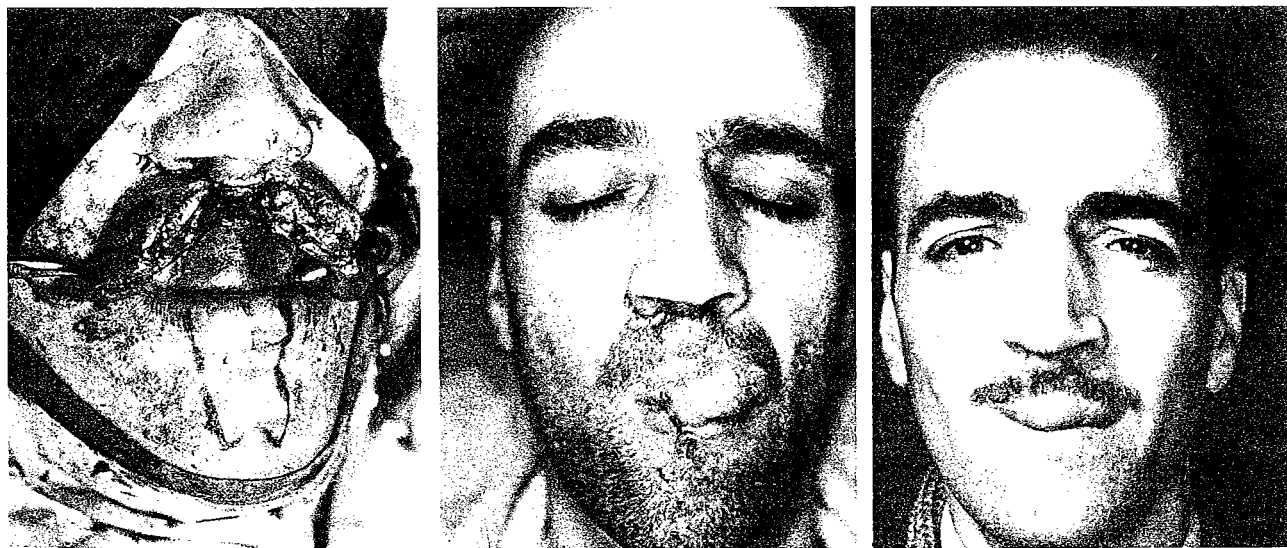


The case was a 27-year-old British army veteran with the typical secondary tight upper lip, flat nasal tip and flaring alae of a complete bilateral cleft lip and palate. He had been the welter-weight boxing champion in both the Egyptian and Italian theaters of war, and the absence of an impressive muscle on his body caused me to suspect that he had terrorized opponents with his

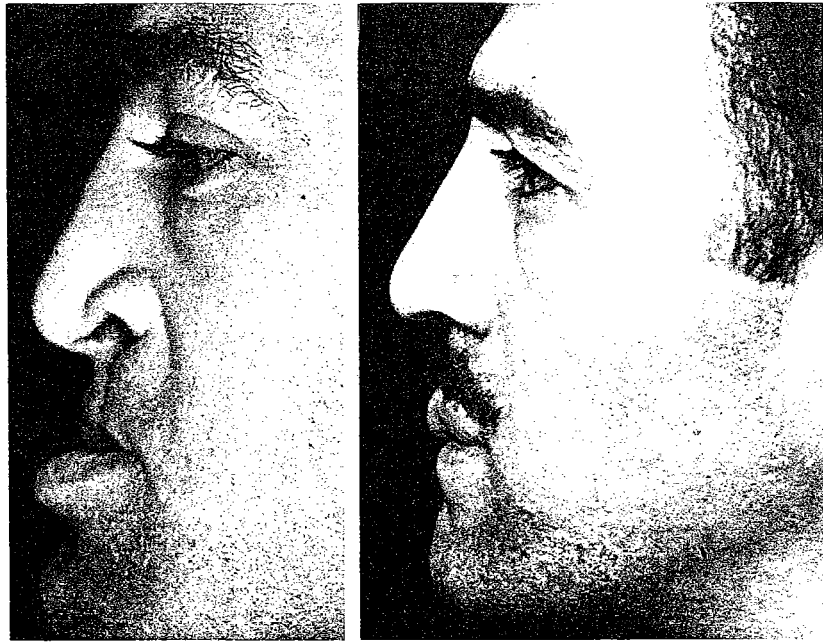frightening flat face. Such a thing could happen in the service even though a smart boxer seldom fears a pounded face as the bearer obviously has repeatedly been an easy target. Having given up boxing, the veteran was anxious for any improvement in appearance. His prolabium was advanced into his columella and a corrective rhinoplasty carried out. This left a gaping upper lip



defect, into which was transposed a huge W-shaped flap planned to fill the hole exactly. It turned out to be too long, too wide and

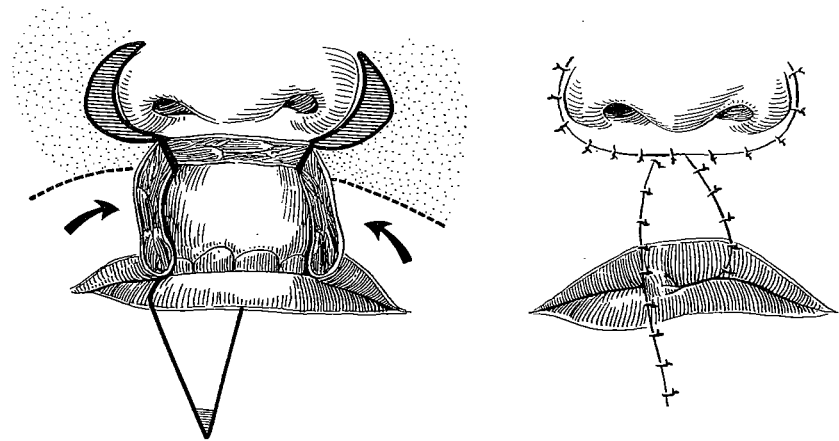


totally unnatural, requiring several reduction procedures. Persistence and a cartilage graft to the nasal bridge finally achieved a happy transformation—yet not without my learning the impor-



tant lesson that these flaps need not be large and, in fact, are best shaped the size of a normal philtrum.

If the defect is just too big in the upper lip to be satisfied with a philtrum-shaped or -sized Abbe flap, then, again, J. P. Webster's perialar crescent excisions will allow the cheeks to aid in the upper lip construction by reducing the size of its defect.

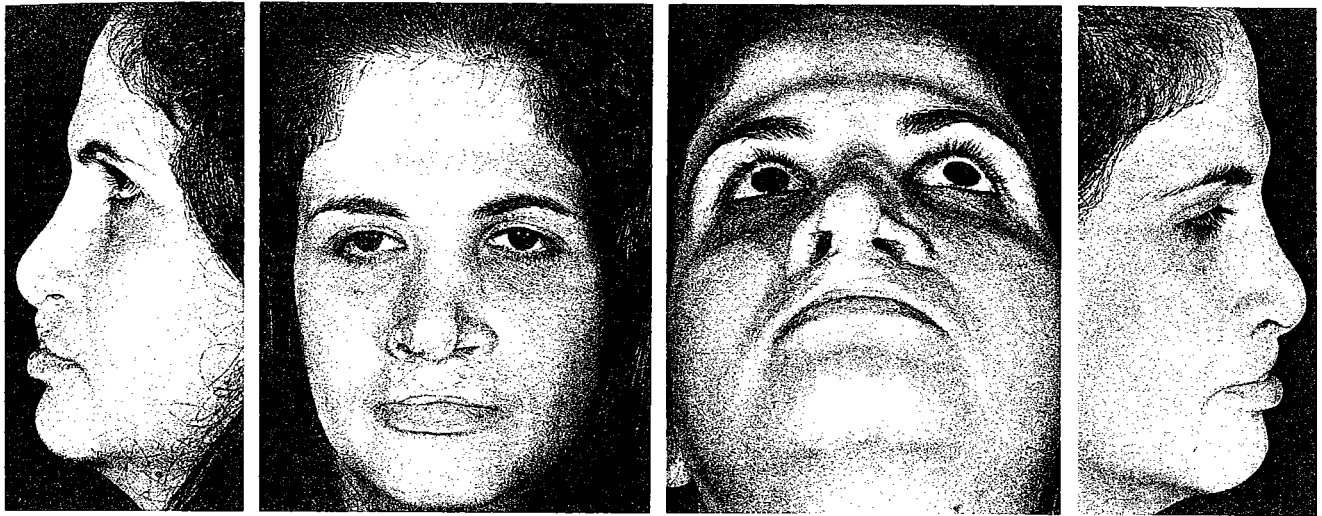

Although some surgeons, more concerned about the position of the pedicle, prefer shifting the Abbe flap donor area off the midline as shown here, it is suggested that a flap taken from the midline of the lower lip not only may carry a dimple but can be maneuvered into the upper lip defect just as easily. Remember to keep the circumalar incisions high and in the shadow of the nasolabial join.

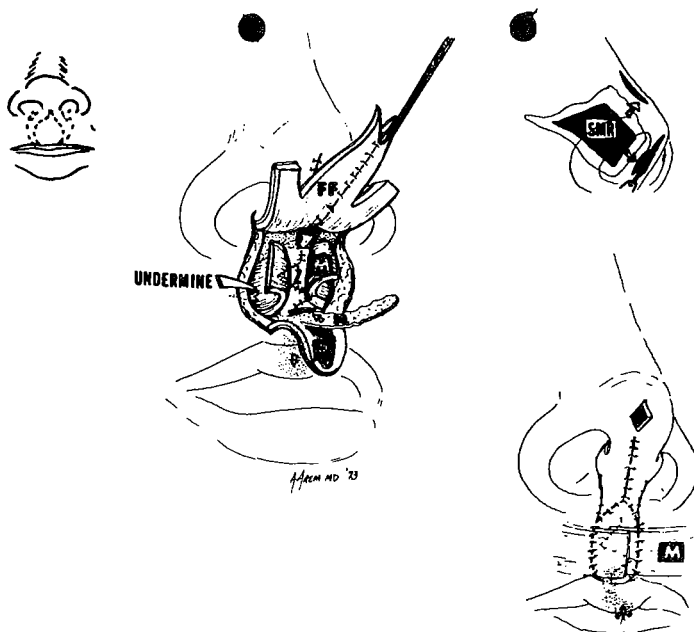
OTHER PERSONAL CASES WITH PROLABIUM STILL IN TIGHT LIP

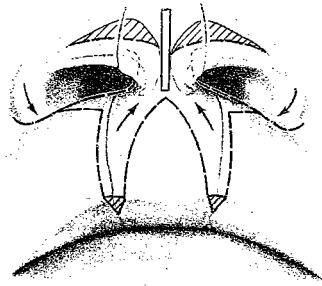
Forked flap and rhinoplasty

This 27-year-old woman, whose complete bilateral cleft of the lip and palate had been treated in Cuba, presented a short columella, flat nasal tip with several external nasal skin scars, asymmetrical nostrils, flaring alae and short, tight upper lip with unnatural scars.



A forked flap with nostril extensions was elevated, and lateral lip muscle elements were freed and joined. A Z-plasty lengthened the short posterior lip mucosa. Septal cartilage grafts were made

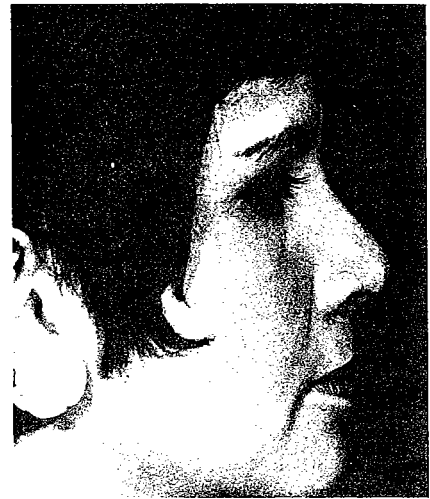
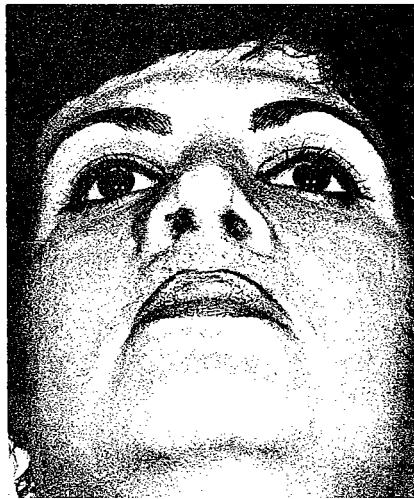


to the nasal bridge and columella. A diamond excision of nasal tip skin and suturing of the forked flap allowed columella lengthening, the lateral wing extensions being folded into the vestibular releasing incisions to elevate the nasal tip.

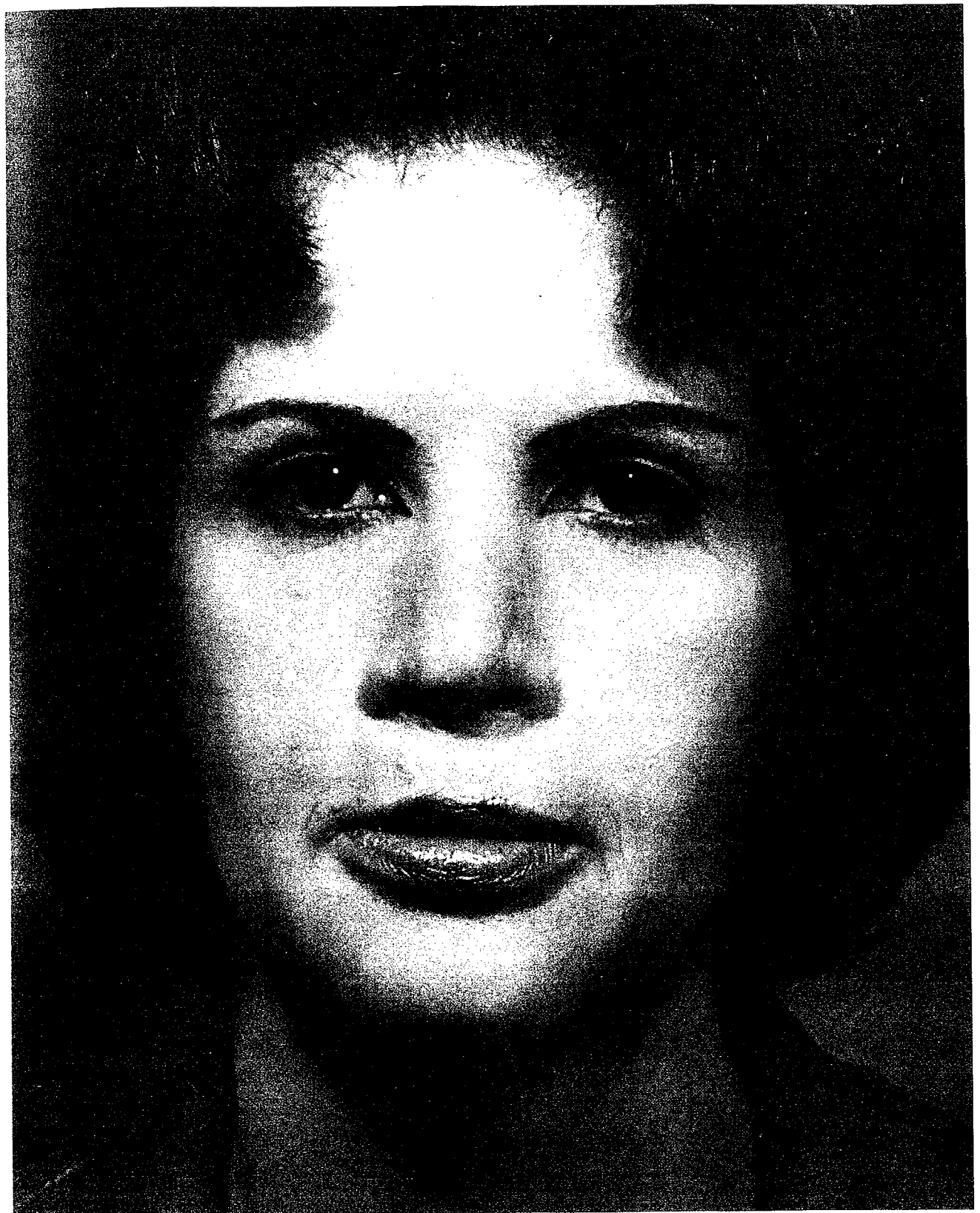Later cleft lip rhinoplasty included reduction of alar cartilages, bilateral osteotomies, septal cartilage strut into the columella and lateral mucosal flaps transposed between columella and membranous septum. The tips of the alar base flaps were denuded of epithelium and sutured to each other with Mersilene behind the columella to reduce the flare.

R.R., S.C.S.1
C.M.F., A.B.2



The final labial and nasal revisions included abrasion of skin scars.

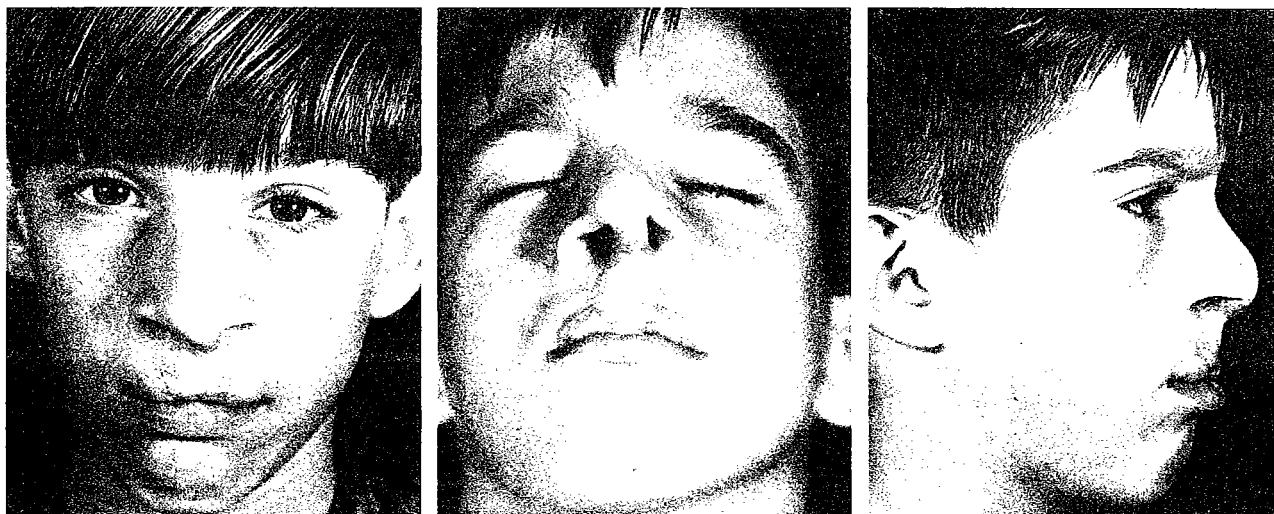




The young lady has blossomed, has learned to use makeup and does the very most with what surgery has been able to give her.

In the next case, complete bilateral cleft of the lip and incomplete cleft of the palate were initially treated in New York. The 1955 operative notes from the Maxillo-Facial Service of New York Presbyterian Hospital described a left-side LeMesurier lip closure and, three months later, the same on the right with mucoperiosteal flap closure of the anterior palate. At three years a partial vomer resection and Kirschner wire fixation achieved premaxillary pushback. Some time thereafter, Dupertuis in Pittsburgh applied one of his auricular lobule free grafts to lengthen the columella.

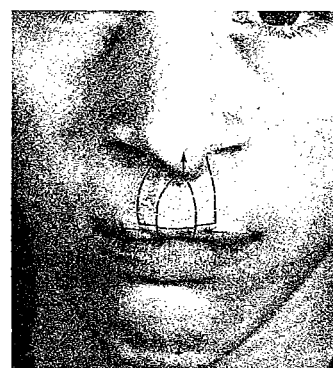By age 10 years the patient showed a moderately depressed, rounded nasal tip, short scarred columella, tight upper lip with scars and stitch marks, a hypoplastic maxilla and a protuberant lower lip.

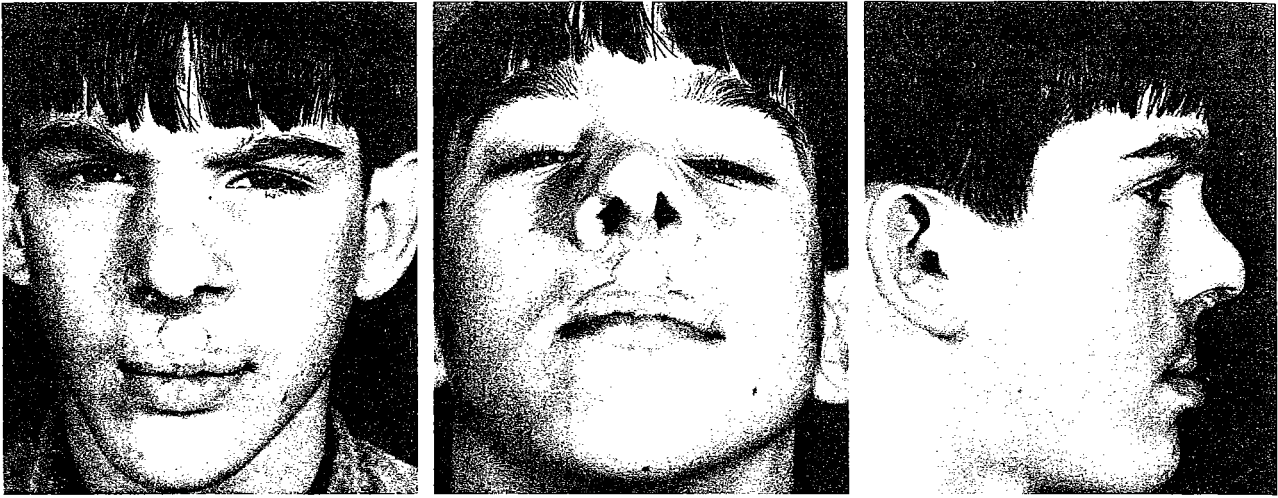


10 years

When he was first seen in Miami, orthodontic manipulation to spread the maxilla was started by Michael Krop.

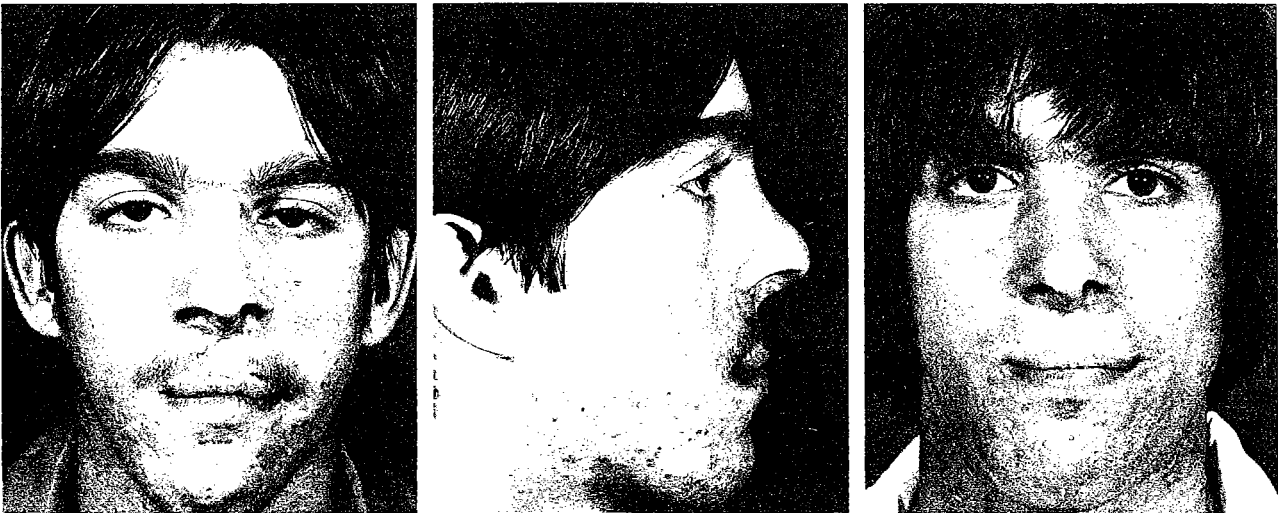At 12 years, a forked flap revised the lip scars and reduced the prolabium. Exposure allowed removal of the nasal hump. The forked flap was advanced along the membranous septum with release of the tip, and the ends of the fork were splayed to join the advancing alar bases to form the nostril sills.





12 years

Two months later, alar margin excisions and reduction of the columella ear lobe graft sculptured the nasal entrance. A Silastic sponge chin implant was inserted through a lower labial sulcus incision. At age 16 years mandibular osteotomy was carried out by oral surgeon Arnold Weiner.

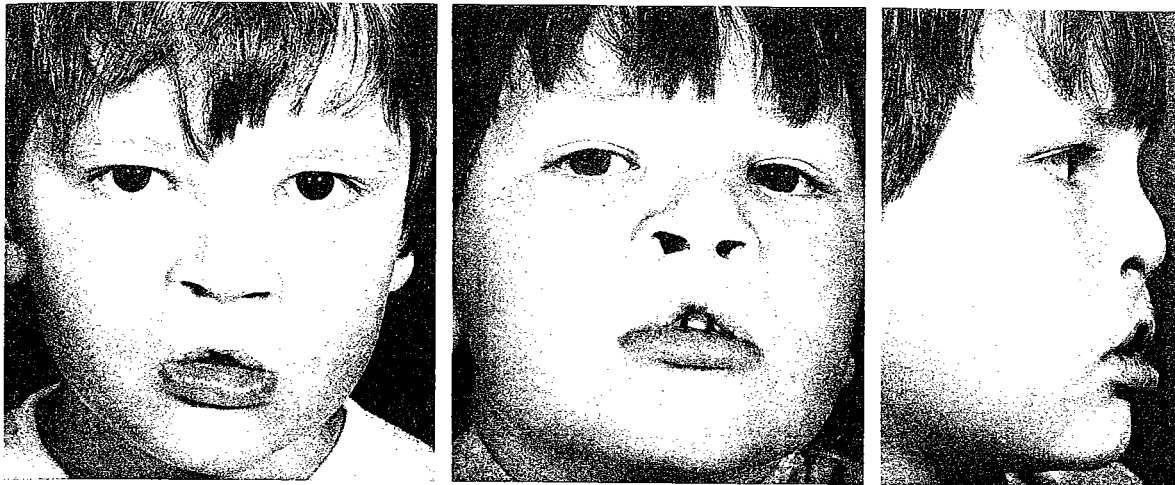

13 years

18 years

Short fork, then total prolabium to columella and Abbe flap

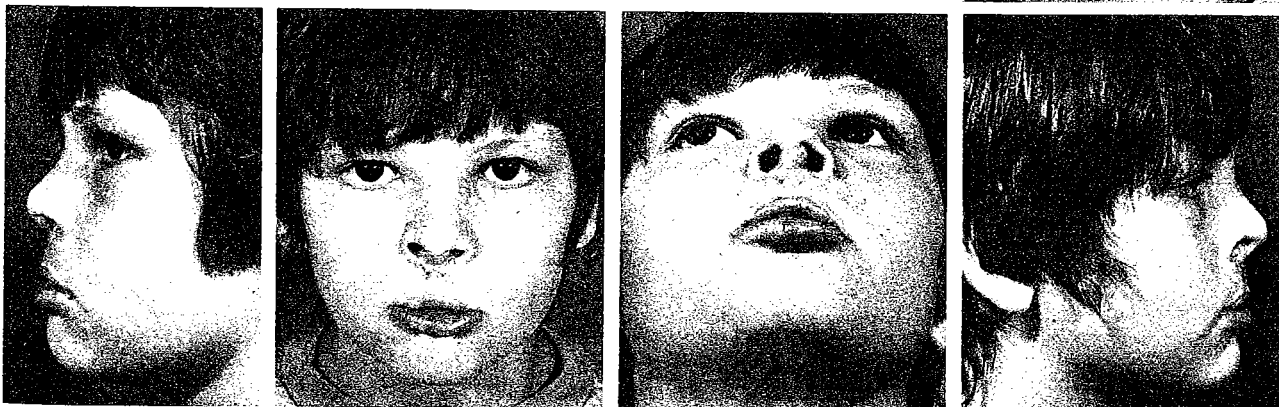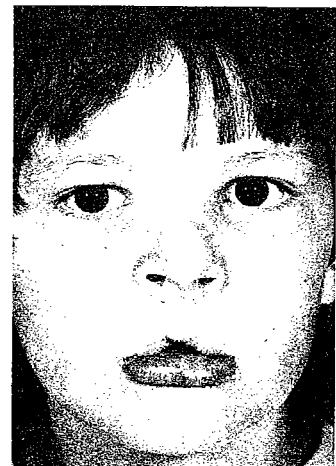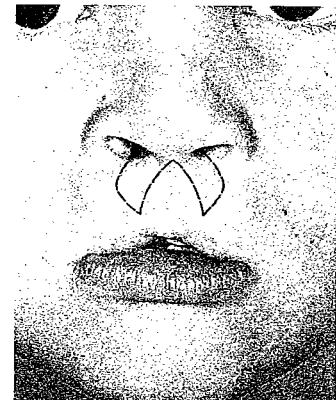A bilateral cleft lip and palate was closed in Boston using a Tennison-type Z-plasty, one side at a time, for the lip. At six years the patient had a short columella, flared alae, a tight upper lip, unnatural zigzagging of lip scars without muscle continuity or natural philtrum landmarks, a vermilion whistling deformity, some lack of maxillary development and a protruding lower lip.



6 years

At seven years a forked flap was taken out of the lip to lengthen the short columella and to shape the prolabium more like a philtrum. The lateral muscles were freed in the upper portions and sutured together in the midline and the flaring alar bases cut free and advanced medially between the forks and the membranous septum. It was necessary to maintain a blood supply to the prolabium through the free border vermilion.

Some improvement was achieved, but the tight upper lip exaggerated by the lax lower lip demanded more radical surgery. At nine years of age the remaining prolabium was cut out of the lip, rolled into a tube and advanced along the membranous septum. The closure was exact enough to allow insertion of a banked homologous septal cartilage strut for temporary nasal tip support. The lateral lip elements were advanced medially and supported by upper muscle flaps sutured to the septal base. Thus the defect was reduced to philtrum proportions so that a 1.5 cm. shield-shaped Abbe flap could be transposed into the defect.



9 years

Time and minor revisions will smooth out the final result. If necessary, at 16 years an autogenous septal strut can be inserted. Further reduction of the lower lip may be required.

TIGHT UPPER LIP WITH HALFWAY PROLABIUM

Bilateral cleft cases closed by the Blair-Brown, Hagedorn-LeMesurier, Barsky and other methods which introduce lateral lip flaps to each other below the prolabium often result in a long lip. There are some lips, however, that are not too long vertically but suffer transverse tightness in the lower portion. With the prolabium in halfway limbo, the nasal tip is still flat and the columella still short. Here the prolabium must go the whole way into the columella, and then an Abbe flap can construct a philtrum.

PERSONAL CASES WITH TIGHT LIP AND HALFWAY PROLABIUM

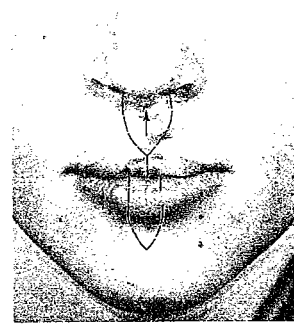
Prolabium into columella and Abbe flap

Bilateral cleft lip and palate closure brought composite flaps of skin and vermilion from the lateral elements below the prolabium. At 11 years, this operation had resulted in a snubbed nasal tip, short columella, tight, unnaturally scarred upper lip and relatively protuberant lower lip.




11 years

At 13 years the scarred prolabium was elevated out of the lip, thinned, rolled on itself into a hemi-column and advanced along the membranous septum to release the tip and elongate the columella. The remaining upper lip was divided in the midline and tailored. Then a 1.5 × 1.25 cm. Abbe flap was transposed into the upper lip defect and the pedicle divided after 10 days. A year later, tips of alar base flaps were denuded of epithelium and advanced to each other at the septum behind the columella. Double-breasted-vest revision of the upper lip scars was used.



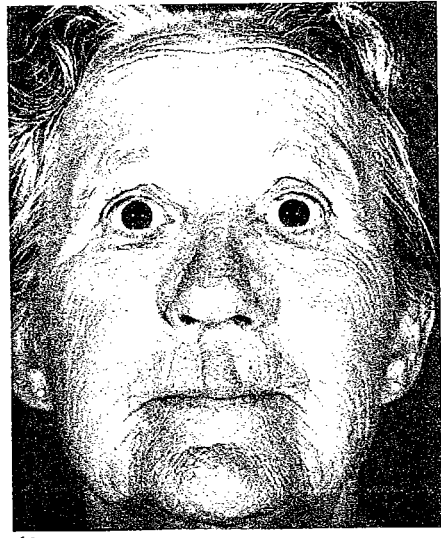
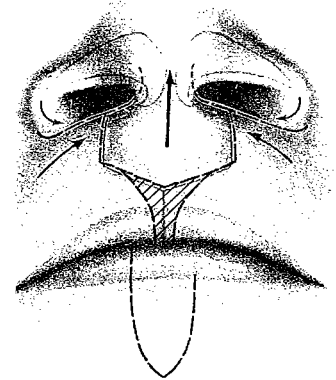
A.B.2



15 years

Prolabium into columella and Abbe flap after 50

This bilateral cleft lip and palate was closed in infancy by approximating the lateral lip elements beneath the prolabium. The palate was never closed but fitted with a plate. At age 53 years, the patient presented for surgery. Release of the lip and slight



53 years

65 years

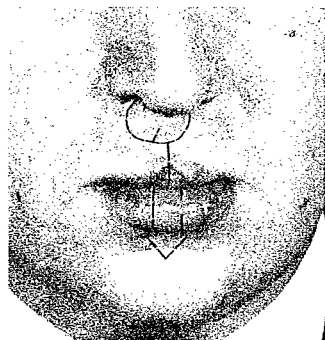
advancement of the prolabium made room for a midline Abbe flap. The pedicle was divided in two weeks. The more advanced age of the patient possibly reduced the flap's ability to blend as a philtrum, but additional years and the Florida sun did bring wrinkles to the face and Abbe alike.

Prolabium into columella and Abbe flap

This bilateral cleft lip and palate was treated by the Blair-Brown method in St. Louis. The photographs at 23 years show the lateral triangular lip flaps joined to each other below the prolabium with a single arc elevation of the vermillion, a tight upper lip, short columella, rounded nasal tip and protuberant lower lip.



23 years



The prolabium was cut out of the lip, thinned and split into a forked flap. The alar cartilages were reduced, the septum was shortened and the columella was lengthened, the ends of the fork joining the alar bases as nostril sills. A midline shield-shaped Abbe flap, 1.5×1.25 cm., was transposed into the defect. When the pedicle was divided after 11 days, a Silastic sponge implant was inserted into the chin through a lower labial sulcus stab incision.



24 years

In the next case, what seems to have been an asymmetrical bilateral cleft of the lip had been closed in Ecuador in infancy by bringing the lateral lip elements together below the prolabium. At 17 years the upper lip was tight and scarred, revealed almost no free border vermilion and compared unfavorably with the protuberant lower lip. The diminutive prolabium bulged at the base of the short columella, which pulled a slight hook in the nasal tip.



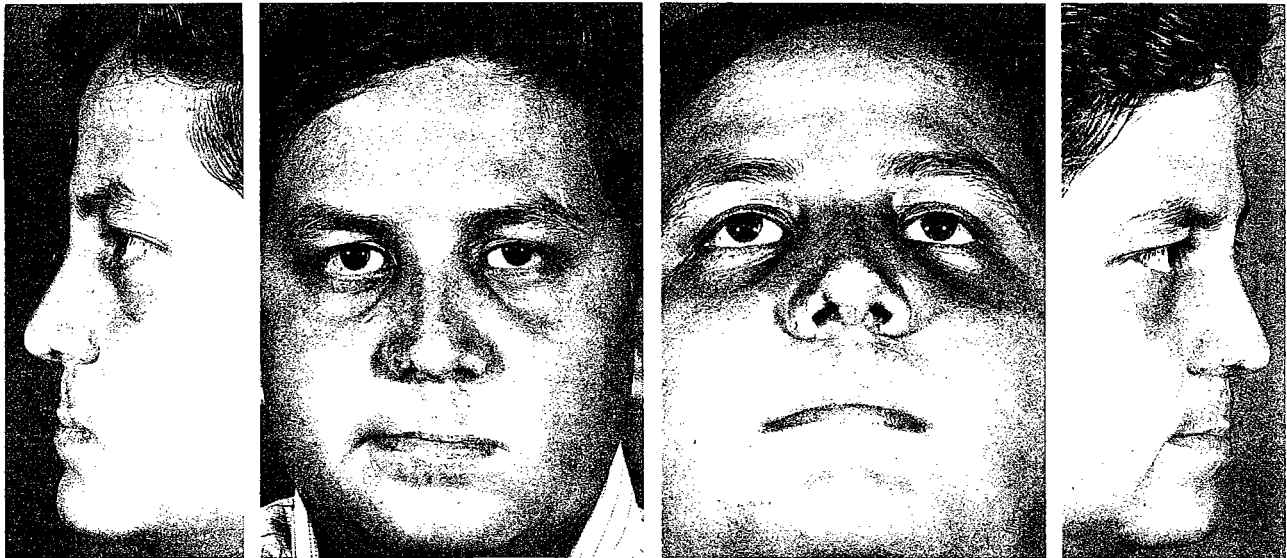17 years



R.R., A.R.1
A.B.1, S.M.R
S.C.S.1

The lip scar was excised, opening a midline full-thickness defect. The prolabium was reduced, split and advanced into the columella. Then a shield-shaped 2 cm. Abbe flap was transposed and the pedicle divided after 10 days.

At 19 years a corrective rhinoplasty included alar cartilage reduction, hump lowering, septal shortening, bilateral osteotomies, alar base wedge resections, alar web excisions, submucous resection and septal cartilage strut in the columella for nasal tip support.



19 years

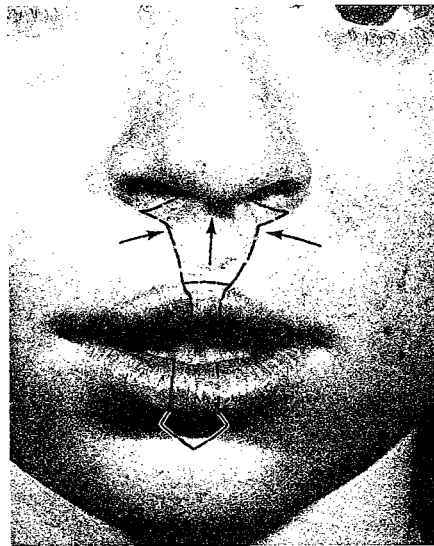
In this case, lateral lip elements were joined to each other below the prolabium in infancy resulting at 10 years in a slightly snubbed nasal tip, short columella, asymmetrically flaring alae, tight upper lip with unnatural scars and no philtrum landmarks.

At 13 years the prolabium with lateral flaps was elevated from the lip, rolled on itself and advanced along the septum to release the tip and elongate the columella. A submucous dissection of the deviated septal cartilage allowed it to be freed from its off-center position on the nasal spine, to have its concavity scored and to be placed in the midline. The upper lip was split in the middle, the alar bases were freed from the lip and advanced to the septum and the muscles of the lip elements were attached to the septum to reduce the central defect. Then a midline shield-shaped

1.5 cm. Abbe flap was transposed into the upper lip and the pedicle divided in nine days.



10 years



14 years

This 13-year-old boy had had a Blair-Brown type of lip closure in infancy in northern Florida. He showed a flat nasal tip, short columella, bulging prolabium without natural landmarks of cupid's bow or philtrum, tight upper lip and relatively protuberant lower lip.

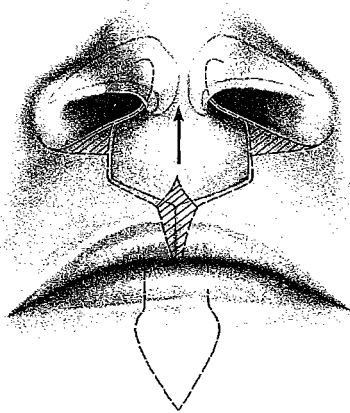


13 years



At age 13, under local anesthesia, his prolabium was elevated T.P. out of the lip, thinned, rolled on itself and split at its distal end. With the aid of a membranous septal incision extending well

over the tip, the prolabium was advanced into the columella and the lip defect filled with a 1 cm. wide, 1.5 cm. long Abbe flap from the lower lip. The pedicle was divided after 11 days.



14 years

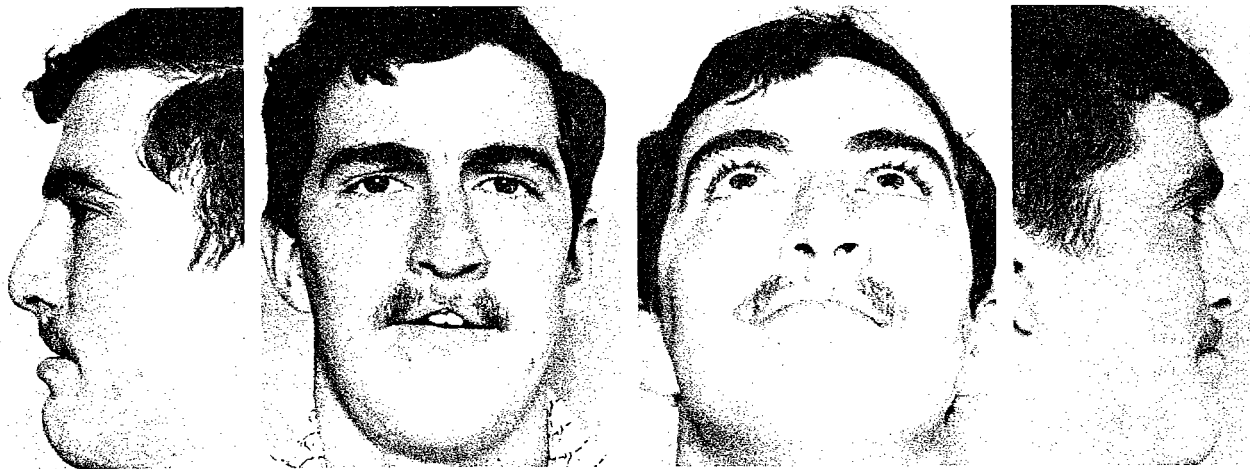
R.R. At age 16 a cleft lip rhinoplasty included reduction of the alar cartilages, straightening of the bridge and septal shortening. The alar bases were cut as flaps, thinned by cutting subcutaneous flaps out of their center, and then advanced medially by suturing their subcutaneous flap extensions to each other at the septal base. A

A.B.4 submucous resection of septal cartilage produced a strut for
S.C.S.1 support of the columella and the elevated nasal tip. Another
S.C.S.4 smaller strut was used along the right alar rim.



16 years

As an infant, this boy had a Blair-Brown type of lip closure in the Navy. At 18 years, he revealed a short, tight upper lip with a humped prolabium trapped by triangular flaps joining tip to tip below it. He had a whistling deformity and a protuberance of the lower lip. The nose was high-bridged and hooked, the nasal tip dragged down by the relatively short columella. The total prola-



18 years

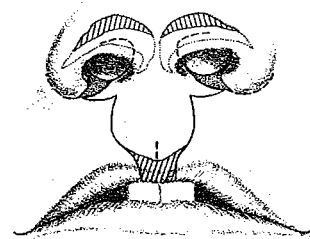
bium was elevated out of the lip and freed for advancement by a membranous septal incision which was extended bilaterally into the vestibules for extra tip release. The alar cartilages were reduced and the hump was lowered. The septal cartilage removed during a submucous resection was sutured as a strut along the end of the septum. After upper lateral flaps were cut from the prolabium as wings to fill the vestibular defects, the remaining prolabium was thinned, rolled and advanced along the septum for columella lengthening. The base of the prolabium was split to receive the tip of the shield-shaped 1.5 cm. Abbe flap. The pedicle was divided after eight days.

T.P.

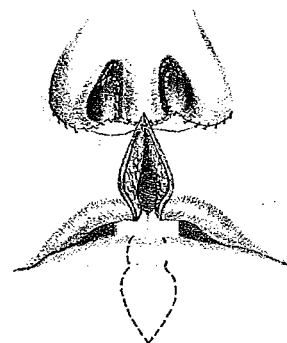
R.R.

S.M.R.

S.C.S.1

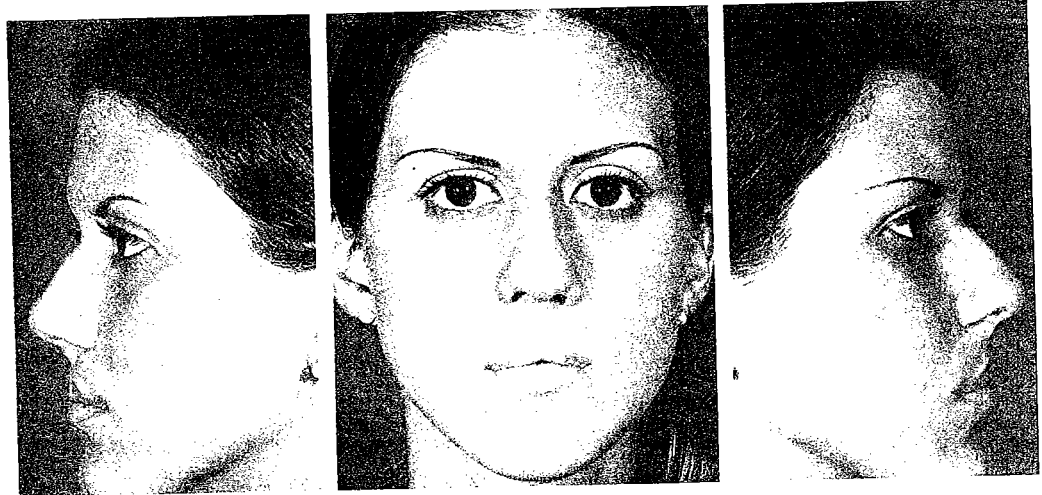

3 months postoperative

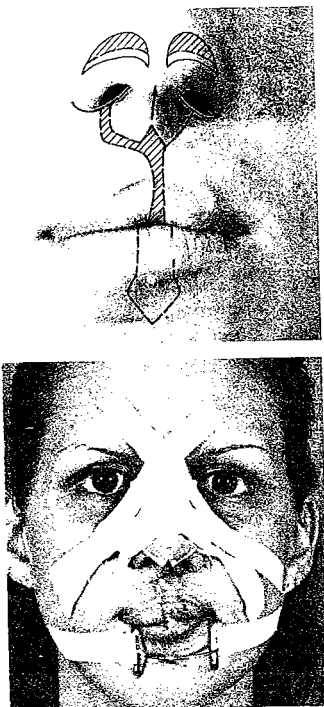


Rhinoplasty and Abbe flap


Born with an incomplete bilateral cleft of the lip, this patient was treated first in Cuba in infancy and later in Florida. When seen at age 21 years, she had a prolabium seated halfway up the lip with lateral lip flaps joined beneath it. This condition produced an unnatural columella, one convex curve of the mucocutaneous line without a cupid's bow, a whistling deformity and a tight upper lip with transverse scars too wide for complete excision. As the nose had a bulbous tip and a slight hump, the usual combined correction of both lip and nose in bilateral secondary deformities was planned.

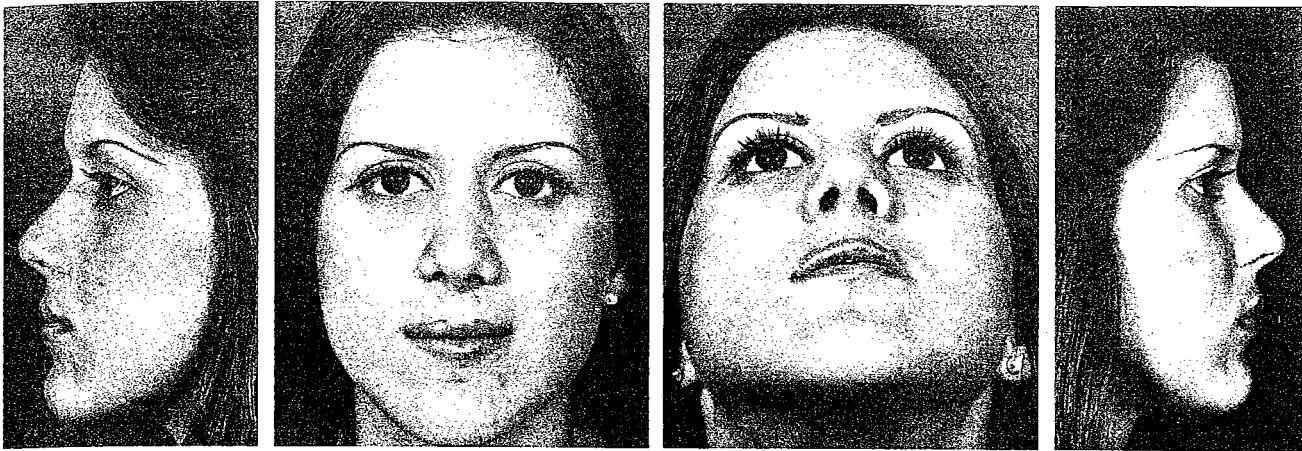

21 years



The prolabium was elevated out of the lip and as much scar as possible excised from the center of the lip. With the aid of membranous septal and bilateral anterior vestibular incisions, the alar cartilages were reduced, the tip was defatted and the hump was lowered. The prolabium was thinned, rolled on itself and advanced into the columella. A V wedge from its base not only sculptured the excess cuff but opened a split for the Abbe tail. The lateral lip elements were advanced medially by suturing their subcutaneous edges together at the tip, thus producing a natural-sized defect in the upper lip. A midline 1.5 cm. shield-shaped Abbe flap was transposed into the gap and the pedicle divided



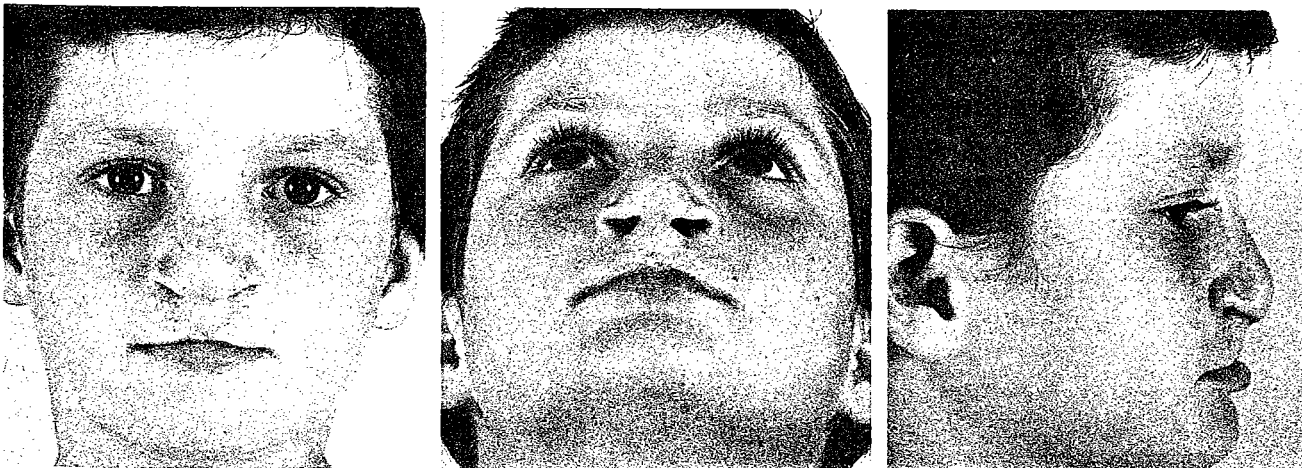

One month after division of pedicle

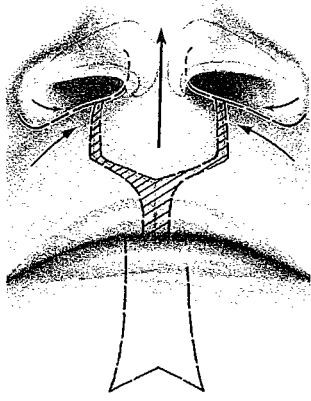
after seven days. Note the ideal length of the upper lip, exposing the lower one-third of the upper incisors.

Prolabium into columella and Abbe flap

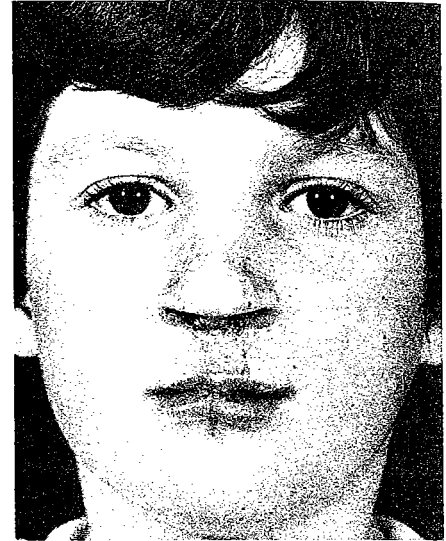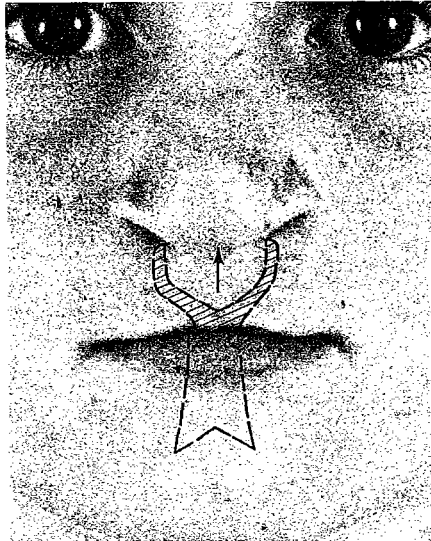
This bilateral cleft lip and palate was closed with lateral triangular flaps brought together below the prolabium. By seven years of age, the premaxilla was gone, the upper lip was tight from side to side particularly along its free border and the prolabium bulged like a trapdoor in the upper central portion of the lip, accentuated by the horseshoe-shaped scar and its "quotation mark" stitch marks. The columella was short, the alae were flared and the nasal tip was so flat that its projection was successfully challenged by the protuberant lower lip!



7 years



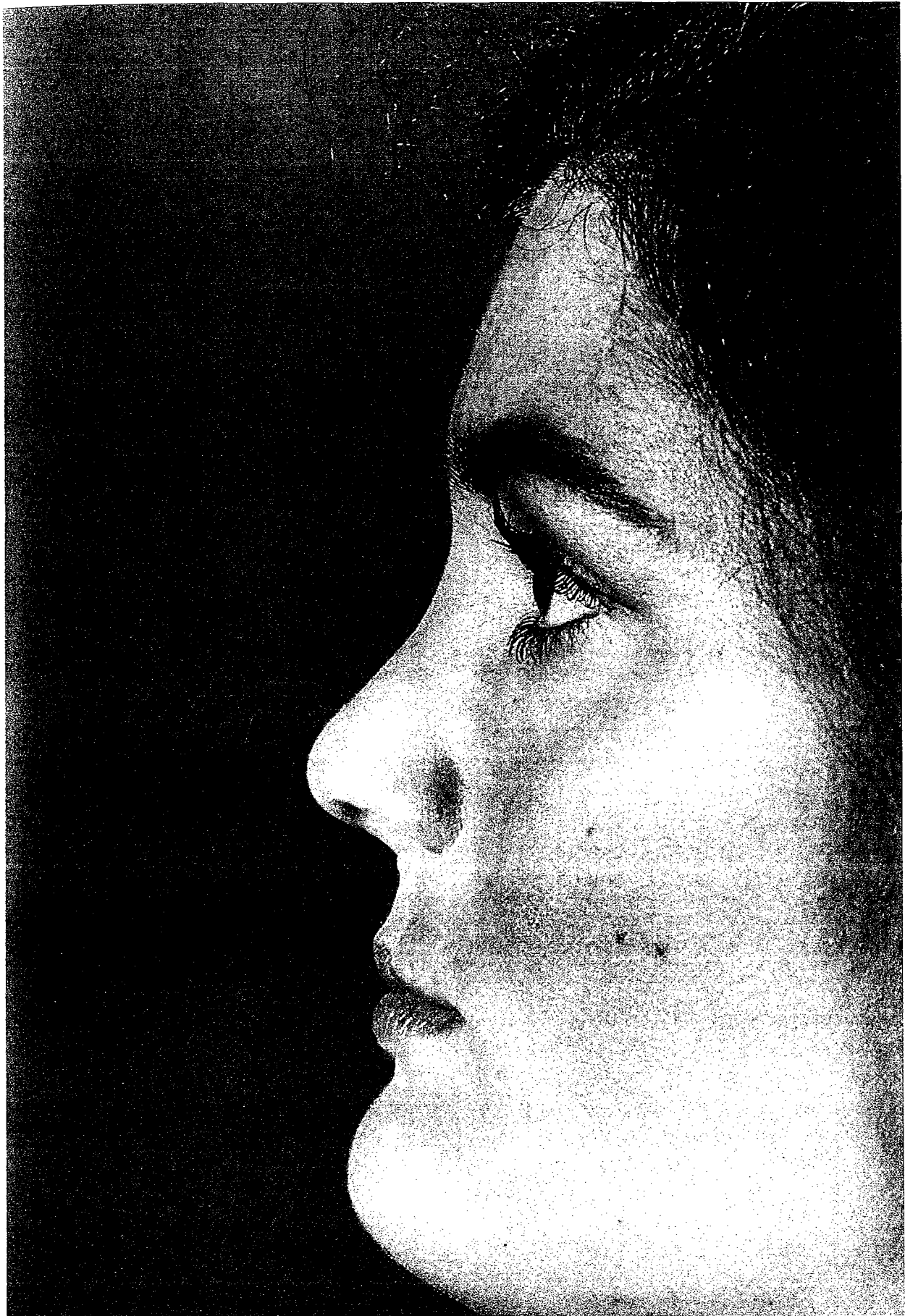
In 1959 the prolabium was elevated out of the lip, thinned, rolled and advanced into the columella. As I had not yet become infatuated with the shield-shaped Abbe flap, an oblong lip-switch flap with a forked tail 1.5 cm. long by 1.25 cm. wide was transposed the usual 180 degrees with the tips of the split tail straddling the columella base.



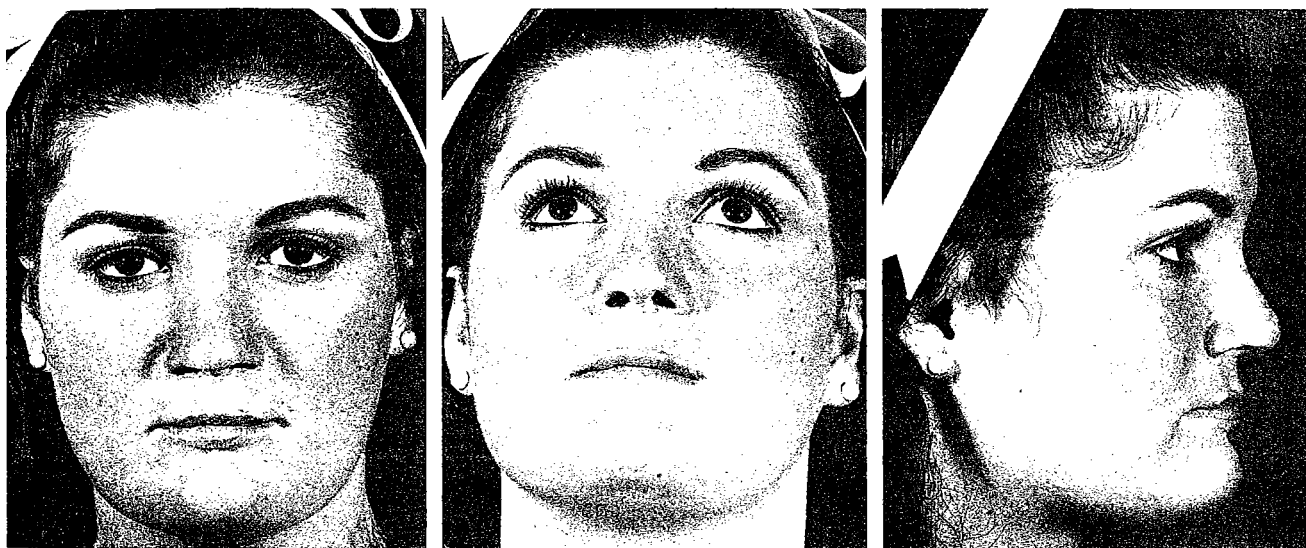Two years later a minor modified cupid's bow operation improved the blending of the Abbe flap along the mucocutaneous border. As the patient grew, so did her nose, especially with the tip free, and this incited me to reduction surgery a little earlier than usual.



11 years



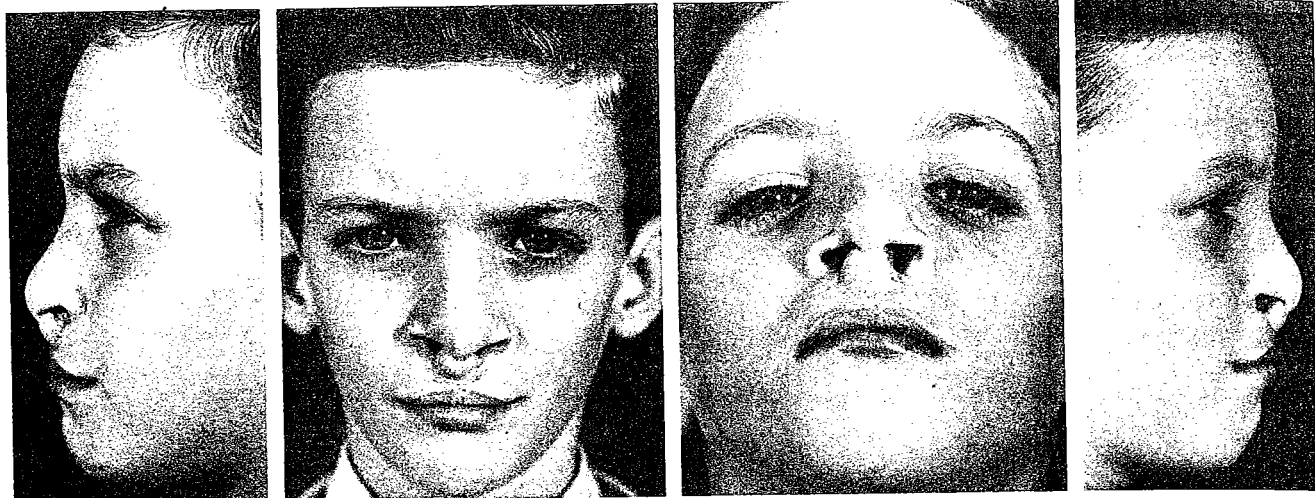By 13 years she was five feet, five inches tall. Thus, at age 15 years her columella was reelevated as a trapdoor, thinned, split for shortening and replaced after standard corrective rhinoplasty procedures of alar cartilage and bridge reduction, septal shortening and bilateral osteotomies. At age 16 years alar base-nasal floor flaps denuded at the tips were advanced and sutured to each other behind the columella base. At 17 years the lip scars were abraded. A subcutaneous pedicle cut out of the center of the Abbe flap was tunneled up into the columella, and a small Z-plasty of the scar join between the Abbe flap and the columella rounded the acuteness of the nasolabial angle.



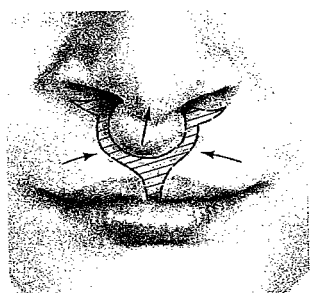
18 years

Prolabium into columella and delayed Abbe flap

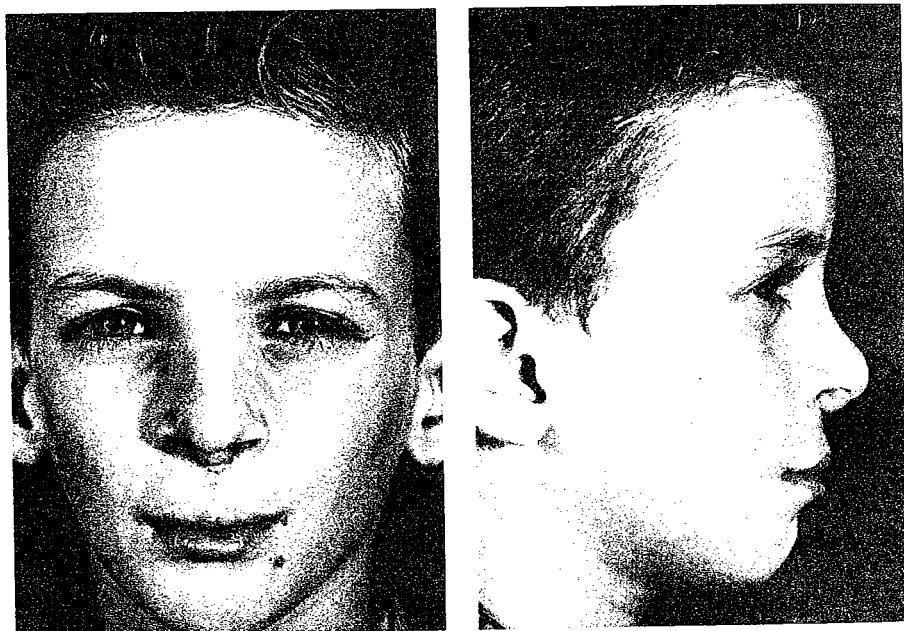In this bilateral cleft lip and palate the projecting premaxilla and diminutive prolabium caused a dilemma for the primary surgery. The lateral lip flaps had been brought together below the prolabium. By age eight years the tug-of-war had caused the prolabium to be suspended between the nasal tip and the lip without benefit to either.



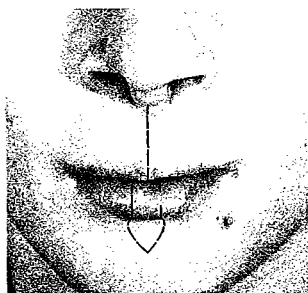
8 years



The prolabium was freed from the lip, thinned and advanced along the septum to lengthen the columella and release the tip. The lip was simply approximated in the midline.

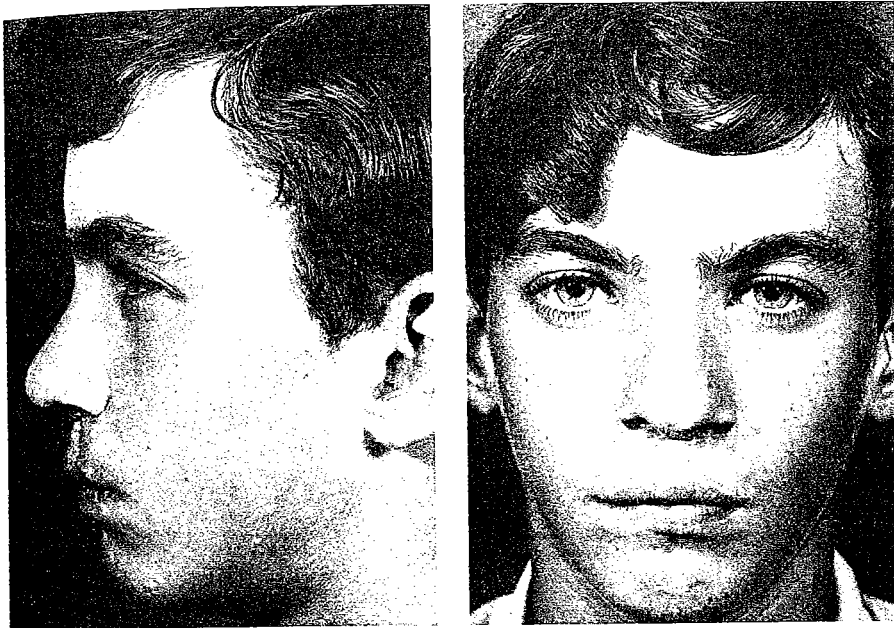

9 years



A.B.2

A year later the scar was excised from the midline of the lip and a shield-shaped Abbe flap inserted with division of its pedicle in 14 days. Two years later the columella bulge was reduced by a vertical elliptical excision and two years after that the tips of the alar base flaps were denuded of epithelium and advanced to each other behind the columella.



13 years

The tissues were now well distributed. Only the refining remained. Upon recall for final revisions at age 18, it was discovered that the patient had died in an automobile accident. This is a terribly sad event to record, as such a part of his life had been shadowed by either facial deformity or a stage of healing between the many surgical procedures. He was a fine boy and had been a good patient, and just as he was obtaining a happy result at the prime of his life, suddenly it all ended for him.

TIGHT UPPER LIP WITHOUT PROLABIUM

If the prolabium was shifted bodily into the columella, the upper lip probably will be tight from side to side, may be long in vertical dimension and certainly will have no central element to suggest a philtrum.

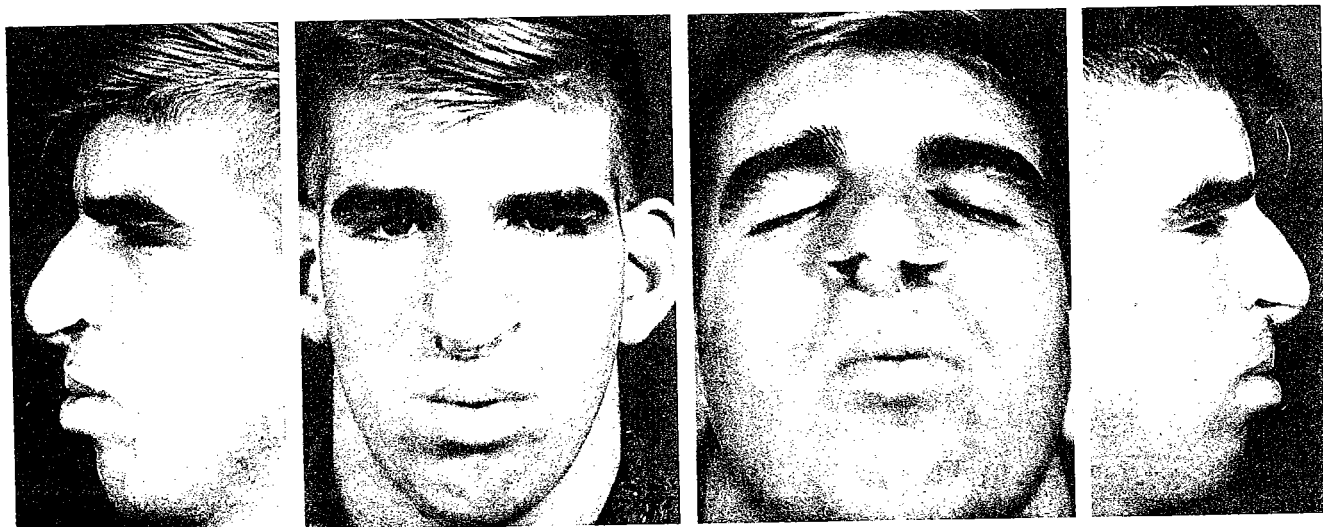
The nose should be satisfied so that most of the surgeon's attention can be directed toward the tight upper lip. Vertical scar excision will release the lip, and it will spring apart in happy relief! If there is excessive vertical length, it can be reduced by bilateral full-thickness transverse wedge excisions along the lip join with the nose. Now there is a gaping full-thickness defect in

the center of the upper lip, and Abbe found the answer in a full-thickness flap from the lower lip as a natural replacement of the missing tissue.


PERSONAL CASES OF TIGHT LIP WITHOUT PROLABIUM

Abbe flap

This bilateral cleft lip and palate had been treated by shoving the prolabium almost into the columella and bringing the lateral lip flaps together below it. At 15 years of age, short bulging prolabium columella, flat nasal tip with kinked alae, flaring alar bases, tight upper lip and protuberant lower lip and receding chin added to the general problem of cerebral palsy.




15 years



R.R., A.B.1
S.M.R., S.C.S.1

The prolabium was freed, thinned, rolled on itself and advanced into the columella with relief to the nasal tip. The upper lip was divided in the midline and an Abbe flap transposed into the defect. The pedicle was divided after 14 days.

Six months later, corrective rhinoplasty included reduction of alar cartilages, lowering of the bridge, septal shortening, bilateral osteotomies, alar base wedge resections, submucous resection and septal cartilage strut in the columella to elevate the tip.

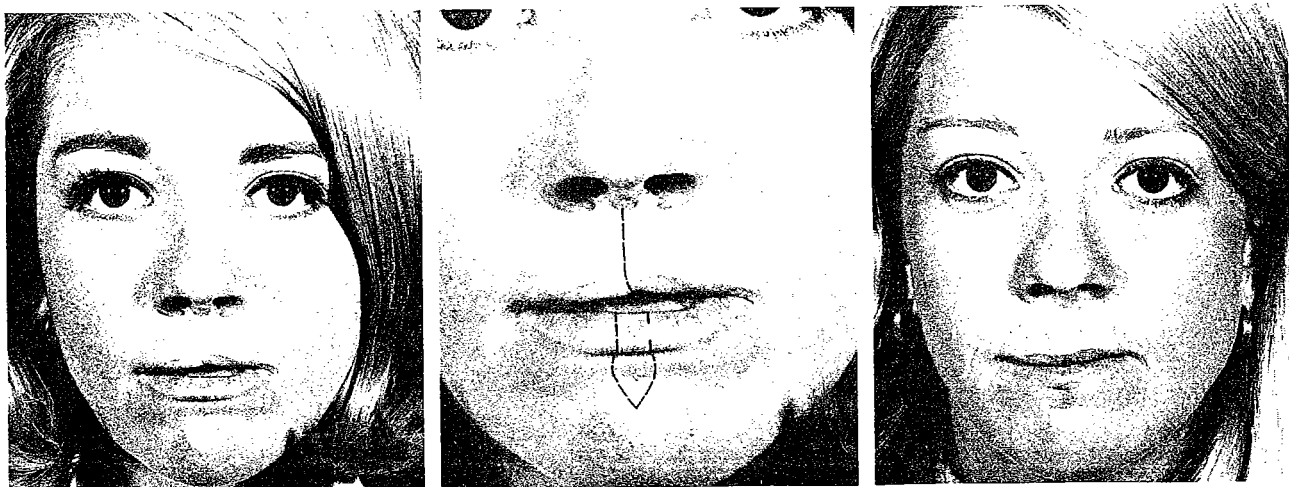


17 years

Prolabium into columella and Abbe flap

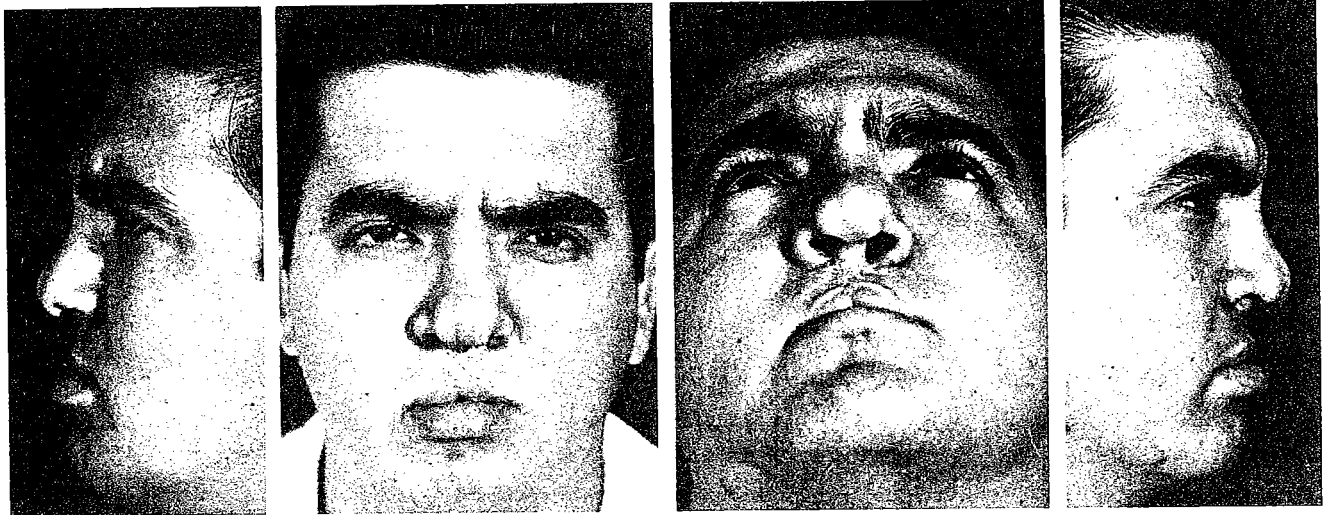
This bilateral cleft lip and palate was treated in infancy with lateral lip flaps joining beneath the prolabium. A central flap was taken out of the prolabium to lengthen the columella. At age 22 years the upper lip had no philtrum or cupid's bow and was flat and unnatural. The slightly short columella ended abruptly in the lip, as did the alar bases, with no natural flow of contour along the nostril sill.

The prolabium was elevated out of the lip, split and advanced into the columella with the tails joining the alar bases across the nasal floors as nostril sills. A midline shield-shaped Abbe flap released the lip, producing at least the semblance of a philtrum. The pedicle was divided after 10 days.



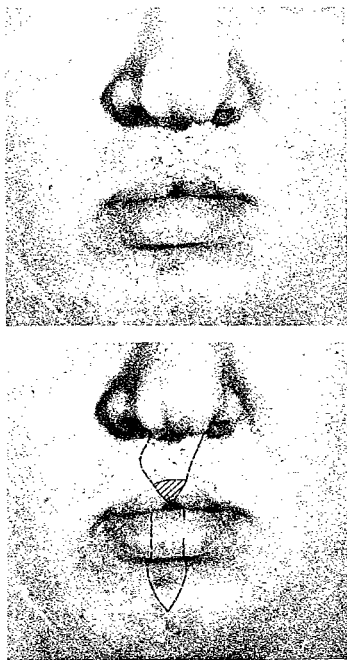
Lip scar into columella and Abbe flap

This 20-year-old Cuban elevator operator, who had had four operations on his bilateral cleft lip and palate, was seen in consultation in Miami in 1963. He revealed a flat, almost bifid nasal tip with flaring, crinkled alae and a short, retracted columella. His upper lip was tight and retroposed. It had a mass of scar in its center and no vestige of the prolabium. The lower lip was protuberant. A plan for surgical rehabilitation was outlined.



20 years

In 1964 this letter arrived:



Dear Doctor,

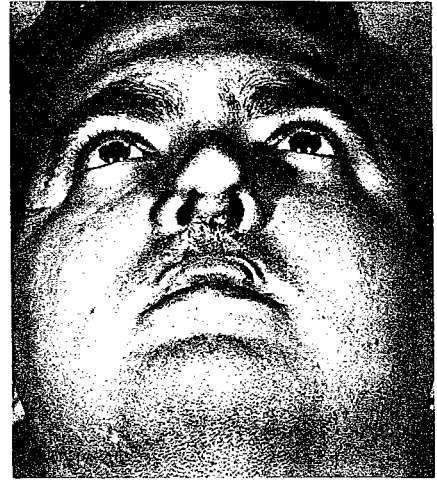

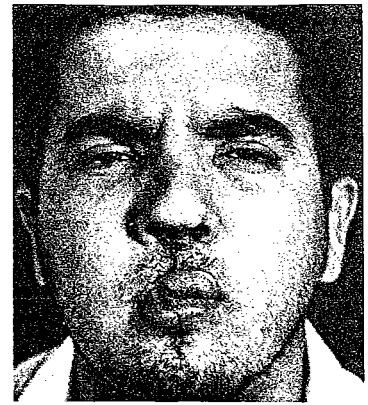
I am writing to you this letter to remind you about my operation. Please, doctor, I hope you don't forget about it, because this is one of my best wishes and hopes in the world.

The other day I saw a girl and I asked her if she wants to be my girlfriend, and she told me "no," you know how I feel after that, because I think because of my defect she didn't want to have anything to do with me.

Thank you doctor for everything that you can do for my lip and I will appreciate it forever.



The scarred central portion of the lip was advanced and rolled on itself to lengthen the columella. The alar cartilages were reduced. The lip was divided in the midline and freed from the maxilla. Into this gap was transposed a 2 cm. (skin length) Abbe flap. The pedicle was divided after 13 days.

Four years later, the alar bases were reduced and alar margins sculptured. As there had never been any cartilage left in the septum, a small Silastic implant was inserted into a pocket in the columella but only as a dormant contour builder and not a working tip lifter!



25 years

The following year the patient had a final island flap pushback of his palate and a minor nasal revision resulting in good facial form and function.



29 years

The patient has flourished, mustached and married!


Prolabium into columella and Abbe flap

This 31-year-old medical student had been born with a bilateral incomplete cleft of the lip and a white forelock. His bilateral lip cleft was treated in Minneapolis with a Blair-Brown-type closure with lateral lip triangles touching under the prolabium. This left the lip tight in its lower border with inversion exaggerating the redundancy of the lower lip. The columella was slightly short with the nasal tip mildly depressed.

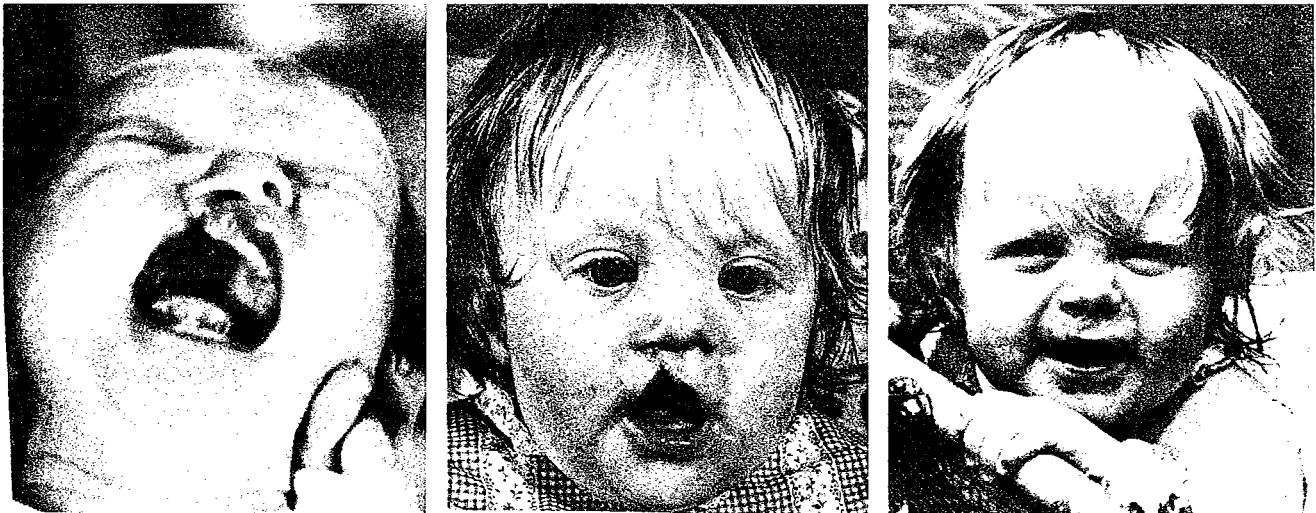

The prolabium was elevated out of the lip, thinned, rolled on itself and advanced along the septum to raise the tip and lengthen the columella. It was split at its inferior end. Subcutaneous pedicles developed under the alar bases were advanced and sutured to each other on the septum at the nasal spine. Then the alar bases were sutured to the split ends of the columella to reduce the alar flare and create nostril sills. The result was a 1.4 cm. philtrum-shaped defect in the upper lip, which, including osteotomies, alar base wedge resections, submucous resection and Abbe flap. The inferior lip flap based on the coronary vessel was rotated 180 degrees and inset, and after eight days the vessel pedicle was divided. Although this action balanced his face and improved his nasal and labial relationship, he proudly proceeded to grow a luxurious mustache.



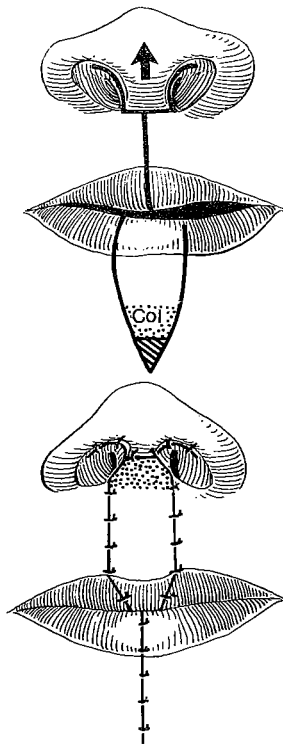


It is of special interest that this patient's daughter was born with an incomplete unilateral cleft of the lip, a bilateral cleft of the palate, normal hearing (at three months) and the white forelock. She had a lip adhesion, soft palate closure and myringotomy with tube insertions at three months, and a rotation-advancement lip and nose correction at seven months and is progressing well.



NASAL TIP DEPRESSED WITH PROLABIUM ALREADY IN COLUMELLA

When there is no prolabium in the lip because it has been shifted into the columella (but not sufficiently to raise the nasal tip), the



columella has to be rereleased, and the alar cartilages must be sutured together to support the tip. The vertical midline scar in the tight upper lip can be excised and an Abbe flap fashioned long enough to extend into the columella to make up the deficit. Depending on the columella defect, the tail of the Abbe flap may be maintained as a point or trimmed as a blunt fork. In 1971 Onizuka of Tokyo specifically designed a longer Abbe flap to be used both for release of the tight upper lip and to fill in the lower portion of the columella after the short columella had been shifted farther into the nasal tip.

It is interesting that in 1968 Vilar-Sancho Altet and I independently designed similar columella construction with an extended Abbe flap in median clefts. Do not forget the value of a couple of autogenous septal struts inserted in the new columella to help maintain nasal tip lift.