

52. Short Upper Lip

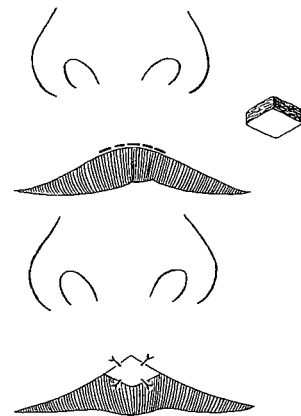
WHEN the upper lip is short in vertical height, it exposes too much of the incisors and requires lengthening. Several methods have been described to increase vertical lip length. They call upon tissue from the ear, lateral lip elements and cheeks. Then, too, as will be demonstrated in specific cases, varying degrees of short lip correction can be achieved without exclusive focus on lip lengthening. Scar excisions, the forked flap, advancement of the total short prolabium into the columella followed by an Abbe flap, with minor adjustments to the lateral lip segments, can achieve not only scar improvement, columella length and philtrum construction but *lip length as an extra dividend*.

E A R G R A F T S

The simplest method of minor central lip lengthening which also ingeniously creates the semblance of a cupid's bow was described by the interesting British team of Muir of Aberdeen and Bodenham of Bristol for Gibson's 1966 *Modern Trends in Plastic Surgery*. They stated:

Occasionally a simple way of lengthening the short scarred lip is required. A through and through transverse incision is made along the mucocutaneous margin . . . and the red margin allowed to drop. The lozenge-shaped defect is then filled with a suitable shaped, double-sided, full thickness lobe graft from the ear, the width of the correction being planned to simulate the natural cupid's bow.

Its only detraction might be the encircling scar and the stuck-on effect of a little ear in a scarred lip.

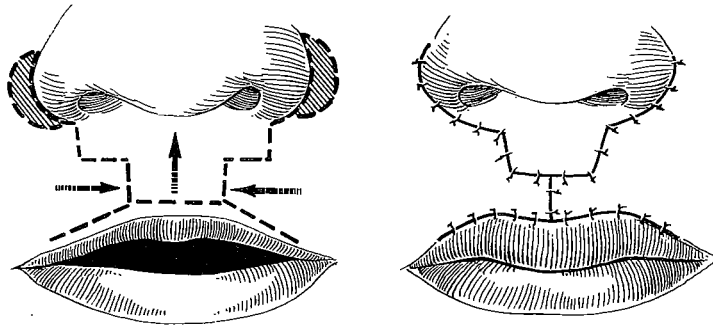


LATERAL LIP FLAPS

The introduction of lateral lip flaps across the midline can, of course, lengthen the vertical dimension of the lip. When this principle is used during the primary bilateral cleft lip surgery, it too often results in a long lip. When the surgery is carried out secondarily after five years of age, it can achieve length under more controlled accuracy. Then the main deterrent becomes the unnatural position of the scars and the lack of muscle continuity.

LOW ADVANCEMENT

G. Ginestet's stair-step method of advancing the lateral lip elements medially under the lower border of the prolabium as a secondary maneuver is mentioned only to condemn it. The cost in unnatural scarring and side-to-side tightening is too great for the vertical lengthening achieved.



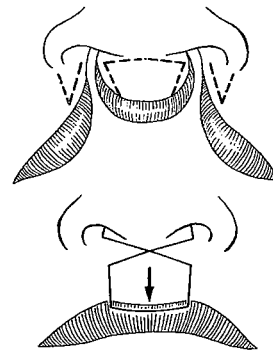
If this is bad in primary clefts, it is just as deforming in secondary deformities!

MIDDLE Z-PLASTIES

The Z-plasty is renowned for its ability to lengthen a short segment along one axis, but remember, this is at the expense of tightening in the opposite axis. Although bilateral Z-plasties have been and will continue to be used in short bilateral cleft lips, in my opinion the scars violate natural lines and landmarks and should be used, if at all, with caution. Remember, the interdigitations will not increase the total center length of the short prolabium but only the zigzagged sides.

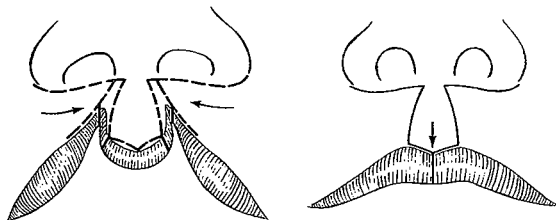
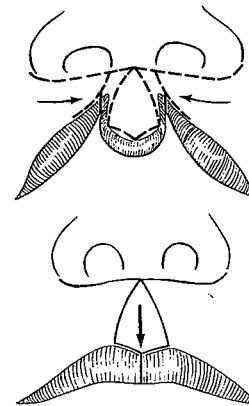
HIGH TRANSPOSITION

The transposition of vertical flaps to the horizontal position, as described by Trauner, Marcks and Wynn, can be called upon to lengthen a short lip even more than to lengthen a columella. There is an unnatural box-like square effect of the scars following the elevation, 90-degree turn and insertion of bilateral flaps.



HIGH ADVANCEMENT

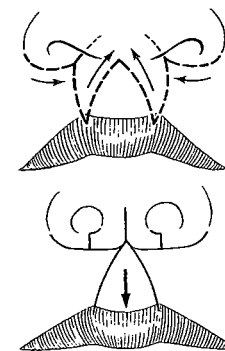
Of all the methods using the lateral lip elements to lengthen the short lip, it seems that the high advancement is closest to achieving the normal. It tightens under the base of the nose where width is usually the most abundant and the least desirable and leaves the lip free border relatively relaxed. Bilateral medial advancement of the lateral lip elements at the top just beneath the alar bases and columella presents scars of union along the natural nasal creases and philtrum curves. Yet, to preserve the full philtrum effect, when vertical shortness is not present, these flaps are better brought *just short of tip to tip*.



Only when the lip is extremely short should the lateral flap tips touch or crisscross even by millimeters.

FORKED FLAP LENGTHENS LIP

Lest the forked flap be considered only a columella lengthener, it is well to point out that it also lengthens the lip vertically as it tightens it from side to side. This effect is obvious if the action during closure of the donor area is studied. After the fork with the scars is advanced out of the lip, there is some release. Then when the lateral lip flaps advance toward each other at the tip of the philtrum's little pointed head, the lip grows longer. This is an



important consideration if a forked flap is planned and the lip is already too long. Action to shorten the lip, such as high lateral transverse wedge excisions, should be incorporated in that specific forked flap design.

ABBE FLAP OFTEN FOLLOWED BY UPPER LIP LENGTHENING

Whether the prolabium is advanced out of the lip into the columella to make room for an Abbe flap or the central scar is excised and the lip divided to receive the Abbe flap, the final Abbe flap insertion not only releases the side-to-side tightness but can allow lip lengthening. The reason is that preparation of the upper lip for the Abbe flap has required the shifting of a short tight prolabium or the excision of scars, and either or both could have been acting to some degree as a shortening restraint. Thus, it is important to note whether or not the lip is of satisfactory vertical length prior to the lip-switch surgery. If the lateral elements, when freed, become too long, they can be tailored. The Abbe flap should be cut to match the correct length and not the released length, for indeed the Abbe is the enforcer which, if fashioned correctly, can keep the lip right.

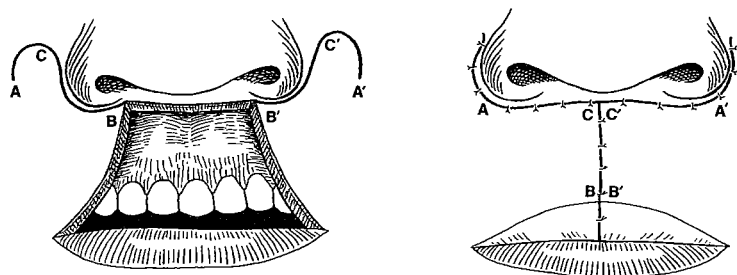
JOINING MUSCLES LENGTHENS LIP

Many of us have noted that when the lateral lip muscle fibers are joined to each other across the cleft behind the prolabium there is some increase in vertical length, often immediate but at least eventual.

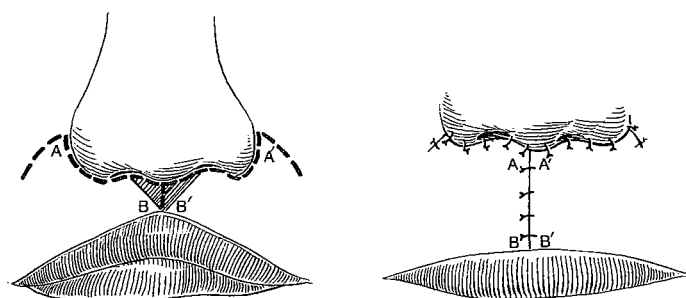
CHEEK FLAPS

When the upper lip is both short and tight and the lower lip is not redundant, the surgeon must turn to the cheek for tissue. Varying amounts are available from the cheeks depending on the need.

Bilateral nasolabial cheek flaps were described by Dieffenbach in 1845 for reconstruction of the upper lip. As he published no diagrams, the scholarly J. P. Webster carefully interpreted this design from the German text.



Esser also transposed bilateral nasolabial flaps into the upper lip, bringing both body and length to the lip without sacrifice of the lower lip. The donor scars of closure hug and are hidden in the alar creases.

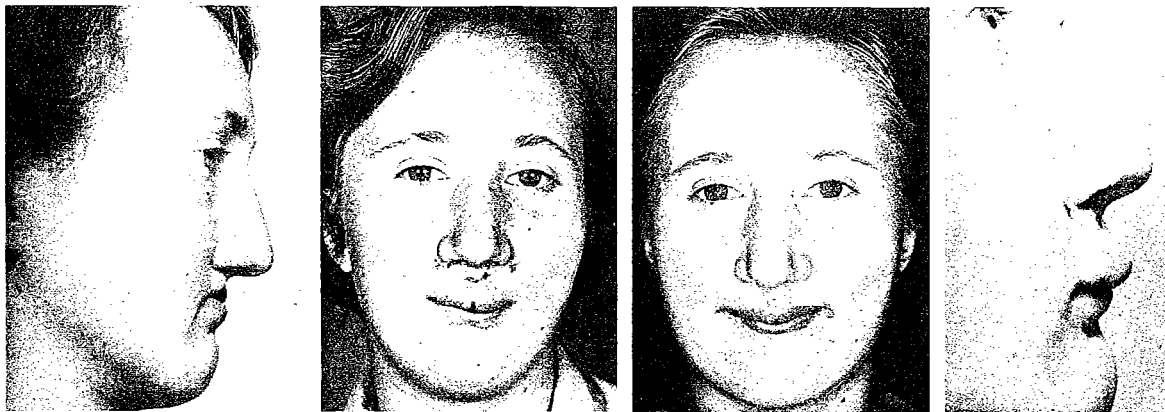

The charming John N. Barron, another New Zealander who became a plastic surgery leader in Britain, trained with Mowlem, served with Gillies and later developed his own super unit at Odstock on the Salisbury Plain within the "shadow" of Stonehenge. Barron, skilled in joinery whether in wood or flaps and grafts, was one of my early teachers while he was at Rookdown House, Basingstoke. I recall vividly his generosity, resonant voice, fluent French, original design of subcutaneous pedicled flaps and this 1948 secondary bilateral cleft case of his in which he cleverly designed Esser cheek rotation flaps.

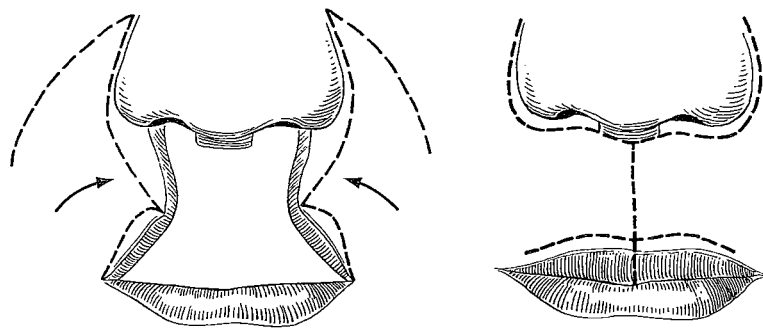


John Barron

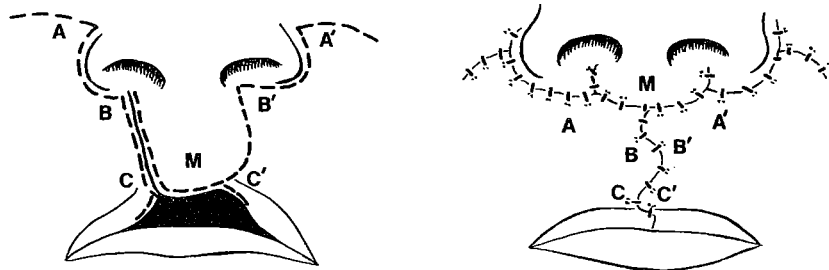




In 1946 August Lindemann advocated cheek flaps for construction of the upper lip and columella in a severe secondary case. His design was, in principle, similar to his primary design for a severe bilateral cleft in which he shifted the prolabium into the columella.



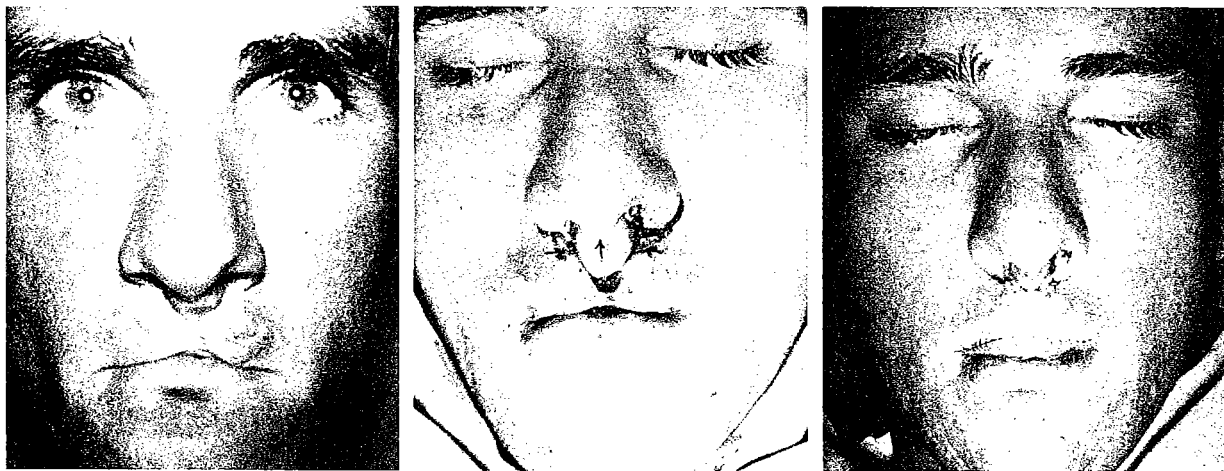
In 1967 Pere Gabarro of Barcelona stated his preference for this bilateral cheek rotation while shifting the prolabium into the columella for his secondary correction of bilateral clefts. He is an artist and these are his own sketches.




PERSONAL CASES


Cheek flaps and Abbe flap

Here is a case in which the prolabium had been partially advanced into the columella and the lateral lip elements drawn together in the midline with retention sutures. The result was a short, tight, scarred lip with an invisible free border vermilion. The correction required a simultaneous thinning and further advancement of the prolabium into the columella, radical midline lip scar excision, *bilateral advancement of cheek flaps*, bilateral elliptical cupid's bow skin excisions above the mucocutaneous junction and midline lip closure of mucosa, muscle and skin with medial advancement of the alar bases.




One and a half years later the lip result was not as good as the early postoperative condition promised.






Improvement in the nose was permanent, but evidently the original lip discrepancy had been too great for local tissue shifting by advancement flaps. The presence of a midline scar, the lack of a philtrum and cupid's bow and the relative tightness of the upper lip in relation to the lower have more or less forced a second-stage small shield-shaped Abbe flap. The pedicle was divided after 14 days, and the patient, happy with his flap and growing a mustache, returned to his island in the Bahamas and was never seen again.



Prolabium into columella and Abbe flap

This patient's bilateral cleft of the lip and palate was closed with the Blair-Brown inferior triangular flaps in infancy in Tennessee. At 26 years he had a short, tight upper lip with a central bulging prolabium, short columella, flat nasal tip, asymmetrical nostrils and flaring alae more marked on the right. The nasal deformity was accentuated by the high nasal bridge and the deviated septum.

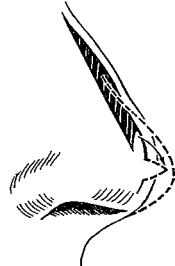
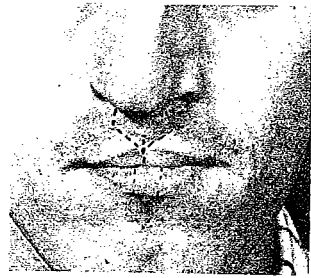
26 years

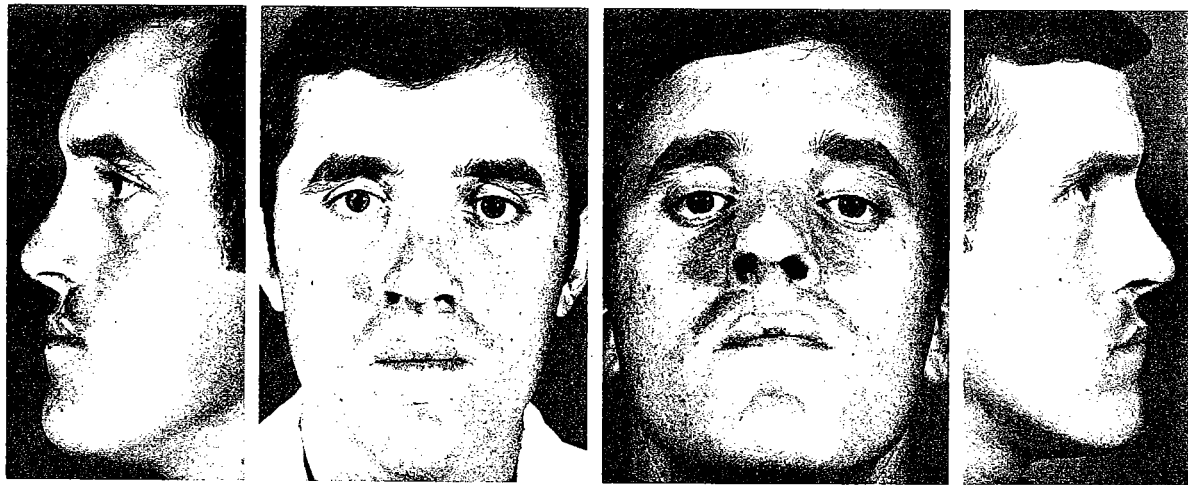
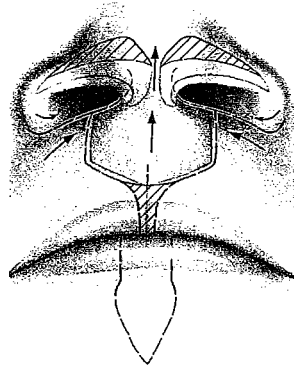
Here is a case in which there is a definite advantage to correcting the nose and lip at the same time.

The prolabium was elevated out of the lip. With the aid of a membranous septal incision diverging laterally as anterior vestibular incisions, a reduction rhinoplasty was possible. The alar cartilages were reduced, the hump was lowered, the septum was shortened and a submucous resection removed the airway obstruction. In the course of lowering the bridge, a cartilage flap was turned toward the tip to offer extra support. The prolabium was thinned and rolled on itself as a hemi-column and, after being advanced along the septum to elevate the tip, was sutured.

The inferior end of the prolabium flap was split and splayed to form a columella base to join the alar bases across the nostril sill. The upper lip was now completely divided in the midline, and a 1.7 x 1.7 cm. shield-shaped Abbe flap was transposed from the lower lip to create a philtrum. The pedicle was divided after 10 days, and 18 months later, sandpaper abrasion of scars gave the finishing touch.



R.R., S.M.R.

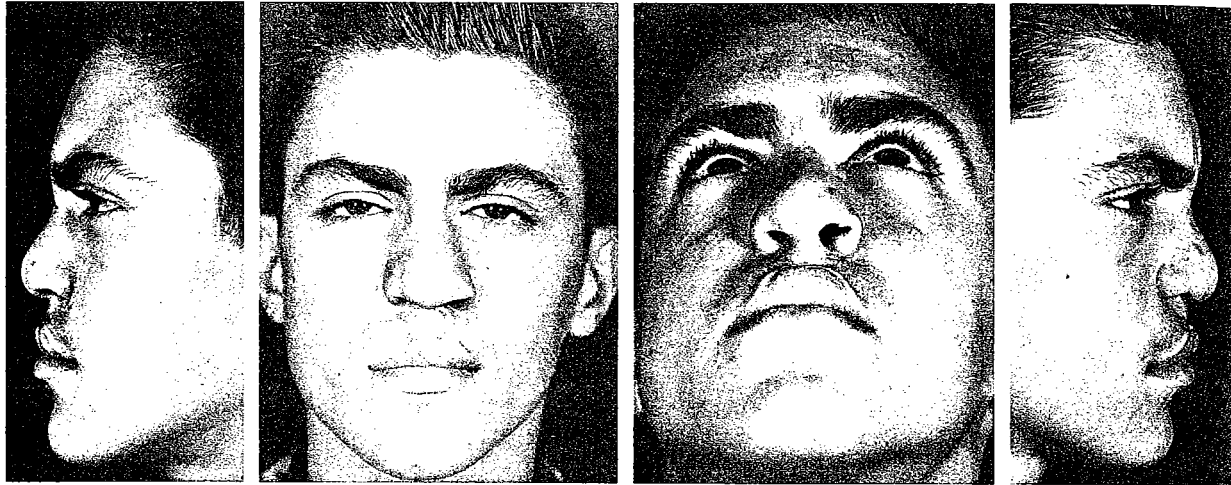


29 years

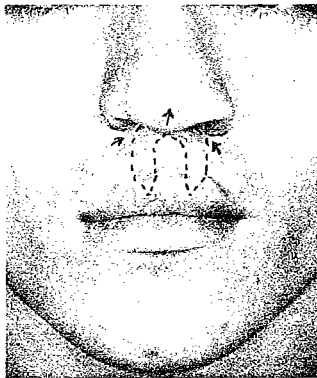
Forked flap and Abbe flap

Asymmetrical bilateral complete and incomplete clefts of the lip had been closed in infancy in California. By the age of 14 years the patient revealed a short columella, snubbed nasal tip, asym-

metrical nostrils, short upper lip with prolabium forming the central segment but with everted, thickened vermilion free border riding high with a single mucocutaneous arc and no semblance of a cupid's bow. There was evidence of sparse hair in the prolabium which, at first, discouraged its use for columella lengthening.



14 years

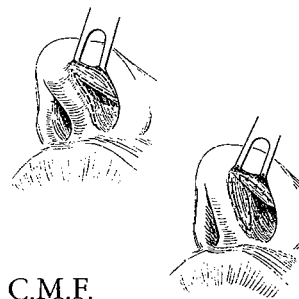


A forked flap incorporating the bilateral scars allowed columella lengthening and release of the nasal tip. Scars and incisions evidently disheartened what hair follicles were included in the fork as they never reared their shoots thereafter. Advancement of the lip elements to close the forked flap donor area did give some vertical length to the lip, yet the inherent shortness of tissue was still reflected in the reentrant nasolabial angle. Subsequent thinning of the vermilion free border and a Gillies cupid's bow operation were only moderately successful.

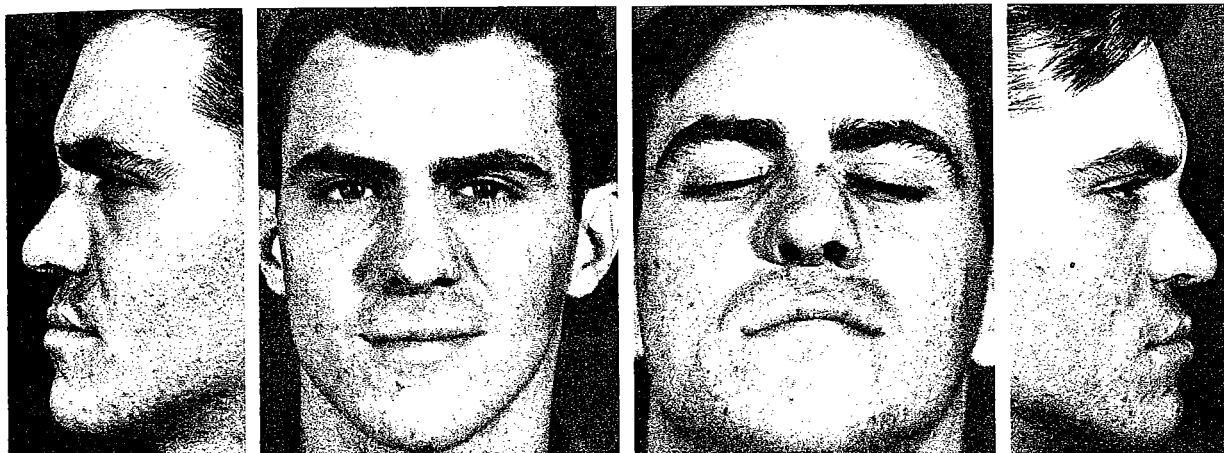


Slight retraction of the columella and long sidewalls prompted bilateral alar chondromucosal flaps based superiorly to be transposed to each other into a membranous septal releasing incision.

The upper lip was split in the midline and released from above by high transverse incisions laterally to give width and length to the lip. A W-shaped Abbe flap was turned 180 degrees into the defect in the upper lip and the pedicle divided after 14 days.



C.M.F.



The excess of columella above and its inferior deficiency was not treated, but a solution to this nasty little problem was later developed, is described at the end of Chapter 47 and is available for this fine gentleman should he ever return.

Prolabium into columella and Abbe flap

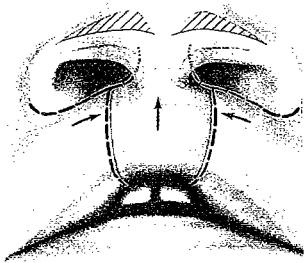
During and after the original operation on this bilateral cleft lip and palate, which incorporated the prolabium in the lip, there had been a 27-year tug-of-war between the nasal tip and the upper



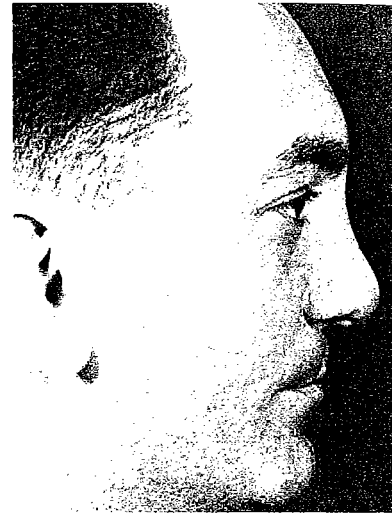27 years

lip. As often happens, both were losers as the lip was pulled up and the tip pulled down.

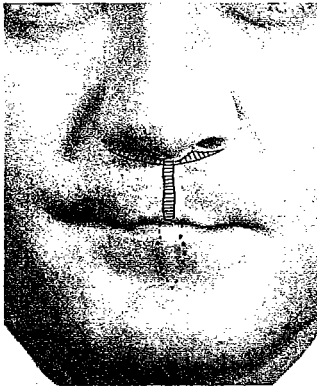
At 27 years the prolabium was advanced into the columella with exposure for alar cartilage and hump reduction, septal shortening, bilateral osteotomies, submucous resection, septal cartilage strut to the nasal tip and bilateral advancement of the lateral lip elements to each other in the midline.





R.R.
S.M.R.
S.C.S.2



28 years




In spite of the slight tightening of the upper lip, the release of the nose presented a face with contented composure which lasted three years. Finally the patient was prevailed upon to accept a small midline shield-shaped Abbe flap. It became functional and was embellished with a mustache, definitely in vogue today.



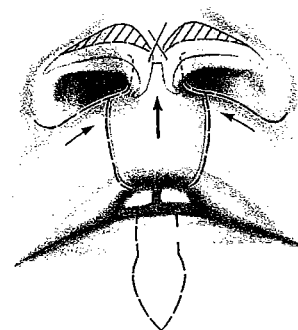
39 years

This bilateral cleft lip and palate had had several operations in Chicago and elsewhere. By age 16 years what remained of the patient's prolabium, after Z-plasty interdigitations of lateral flaps into its sides, was of minimal value to the lip any more. The lip was so scarred, short and tight that even in repose it exposed the entire incisors and compared unfavorably with the protuberant lower lip. The nose, with its flared alae, asymmetrical nostrils and short columella, posed an unusual challenge as its "Roman" bridge rounded abruptly at the flattened tip with a forward projection little better than that of the lower lip: a classic "nose pressed against a windowpane."




16 years

The prolabium was cut out of the lip, elevated and attached to the base of the columella. Exposure through a membranous septal incision extended bilaterally as anterior vestibular incisions made possible reduction of the alar cartilages with suturing of their medial crura at the tip, lowering of the bridge with saw and chisel and narrowing of the nasal bones by bilateral osteotomy. The prolabium was thinned, rolled on itself and advanced as columella. The alar bases and superior portions of the lateral lip elements were advanced medially and sutured with nylon to the septum at the nasal spine. An Abbe flap 1.5 cm. long (skin length) was transposed into the upper lip defect and the pedicle divided after 10 days.



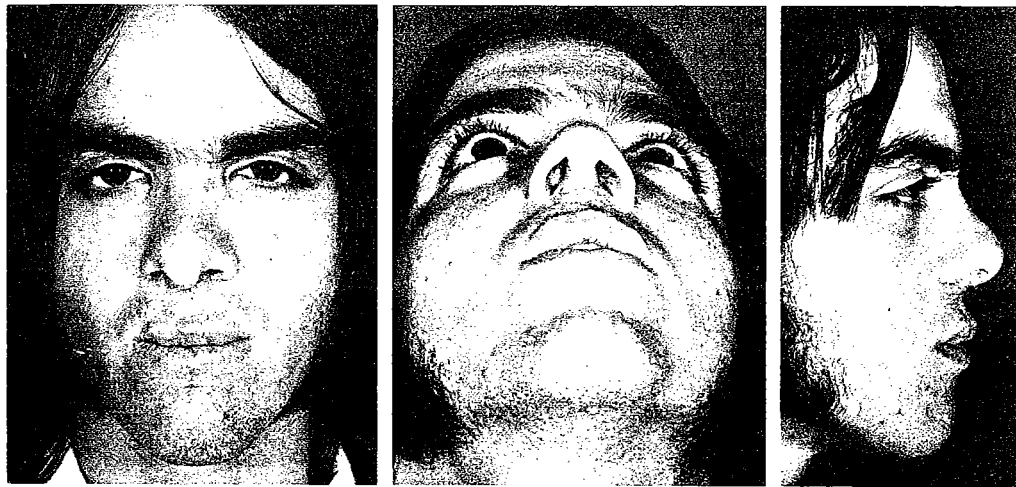R.R.
A.C.S.

*The tissues
have been
shifted -
now the
refinements
begin.*




16½ years

Eight months later rounded tip and hanging columella were treated with alar cartilage reduction, septal shortening, bridge lowering and alar base resections.



17 years

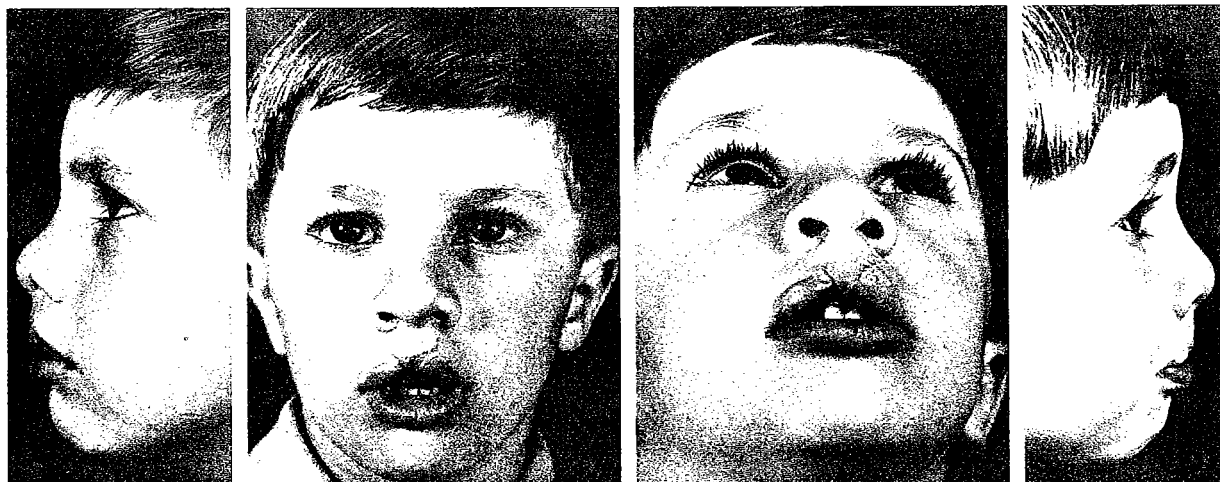One year later final refinements included membranous septal
S.M.R. excisions of columella overhang, submucous resection with septal
S.C.S.2 cartilage struts inserted into the columella to support the tip,
S.C.S.4 another strut along the alar rim and denuded tips of alar base
A.B.2 flaps sutured to each other at the septum with Mersilene.



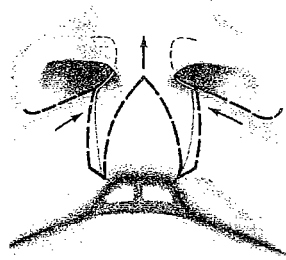
18 years

Forked flap and rhinoplasty

An asymmetrical bilateral cleft of the lip had been closed in infancy in South America by approximation of the lateral lip elements to the sides of the prolabium. At four and a half years of age this boy had a short central segment of the lip with the original prolabium vermilion still present and a moderately short columella with slight drag on the nasal tip.

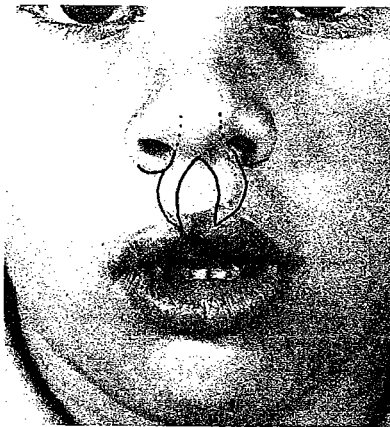

4½ years



F.F.

A forked flap, taking the bilateral lip scars and reshaping the philtrum, was shifted into the columella with release of the nasal tip. Six months later the prolabium vermillion was turned down and lateral vermillion flaps were used to overlap it, creating a more natural vermillion free border and tubercle.



4 1/2 years



5 years



6 1/2 years



11 years

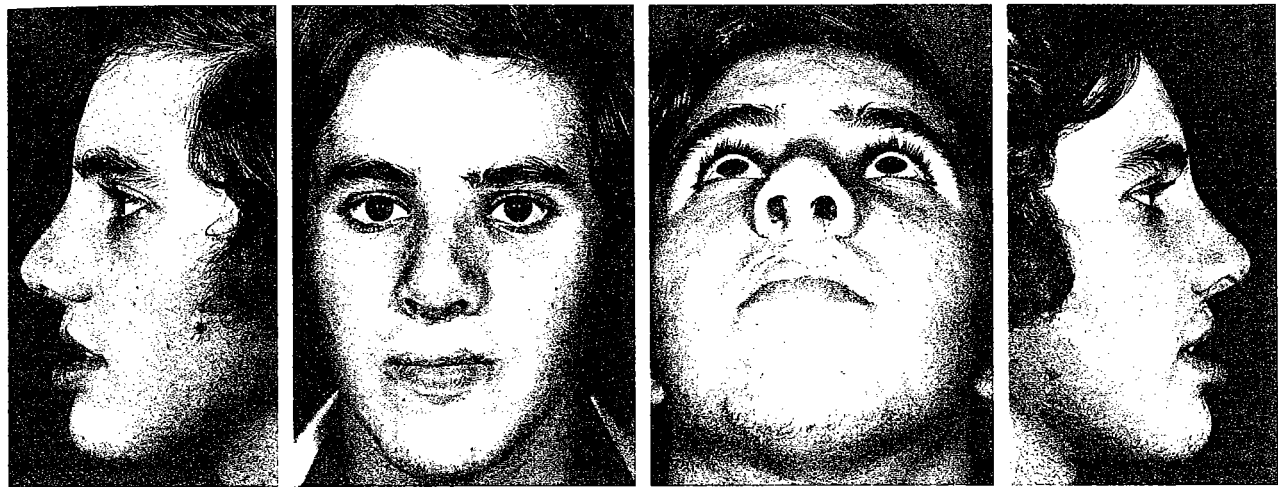

17 years



At 17 years a corrective rhinoplasty included reduction of alar cartilages, lowering of the bridge, bilateral osteotomy, alar wedge resections, columella thinning with an elliptical excision, submucous resection and two septal cartilage struts in the columella to refine the tip. A Silastic sponge implant to the chin was inserted into a pocket through a stab incision in the lower labial sulcus.

R.R., S.M.R.,
A.B.1, S.C.S.2



18 years

Main problems at this point were short, undimpled prolabium with a transverse crease at its join with the columella base and, of course, a severely protuberant lower lip. The patient refused an Abbe flap offered to improve the upper lip while reducing the lower lip because he did not want to risk the extra lower lip scar.

Therefore, a revision of the cupid's bow through a mucocutaneous line incision allowed elevation of the prolabium skin, dissection of a subcutaneous flap out of the center of the prolabium and tunneling of this flap under the upper lip crease into the columella. The prolabium skin was tacked with buried 4-0 Mersilene (Ethicon # R-691G) into the excavation and further molded as a philtrum dimple with a through-and-through suture tied over a cotton bolus. The lower lip was reduced by a long transverse excision of an ellipse of posterior mucosa and orbicularis oris marginalis.

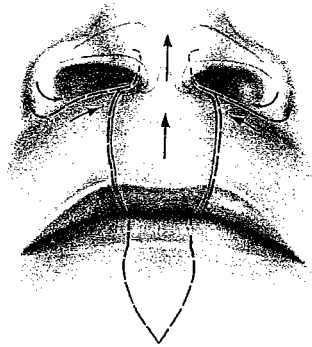


18½ years

It was predicted that a composite wedge resection of the lower lip, including skin, will be necessary to tighten the lip to ideal proportions.

Prolabium into columella and Abbe flap

A bilateral cleft of the lip and palate had been closed in Michigan in infancy with a moderate amount of scarring and a shortness of the columella and lip.



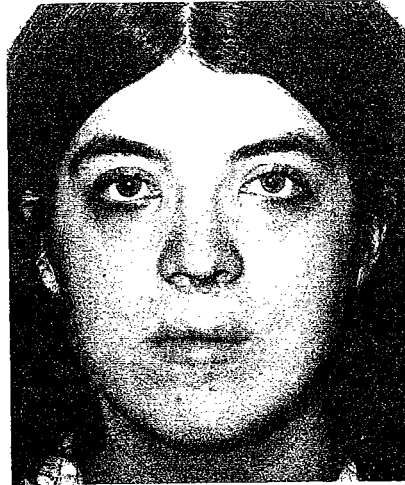11 years



At 11 years the best portion of the prolabium was advanced into the columella to release the nasal tip, and its inferior end was split to receive a midline shield-shaped Abbe flap from the lower lip. The pedicle was divided after 10 days. Minor scar revisions followed.



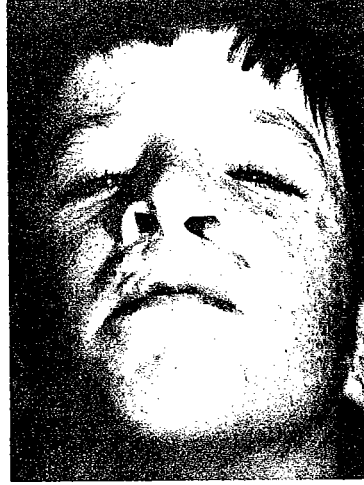
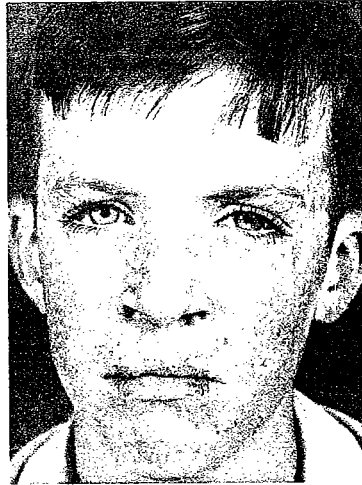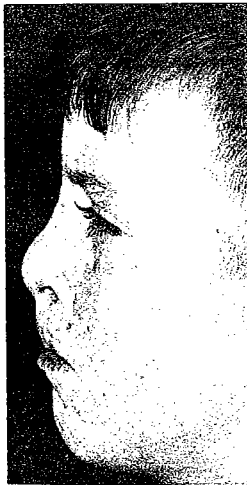12 years



20 years

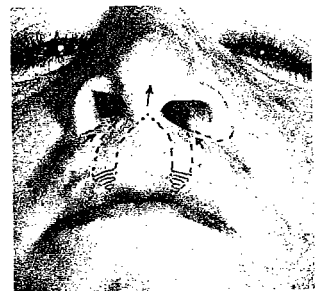Forked flap


This eight-year-old boy had his bilateral cleft of the lip and palate closed by approximation of lateral elements to prolabium with spread of the prolabium, snubbing of the nasal tip and flaring of the alae.



8 years

A forked flap, incorporating the bilateral scars and portions of the prolabium, was advanced along the membranous septum, tubed on itself in the upper portion and allowed to splay at the bottom to join the medial advanced alar base.

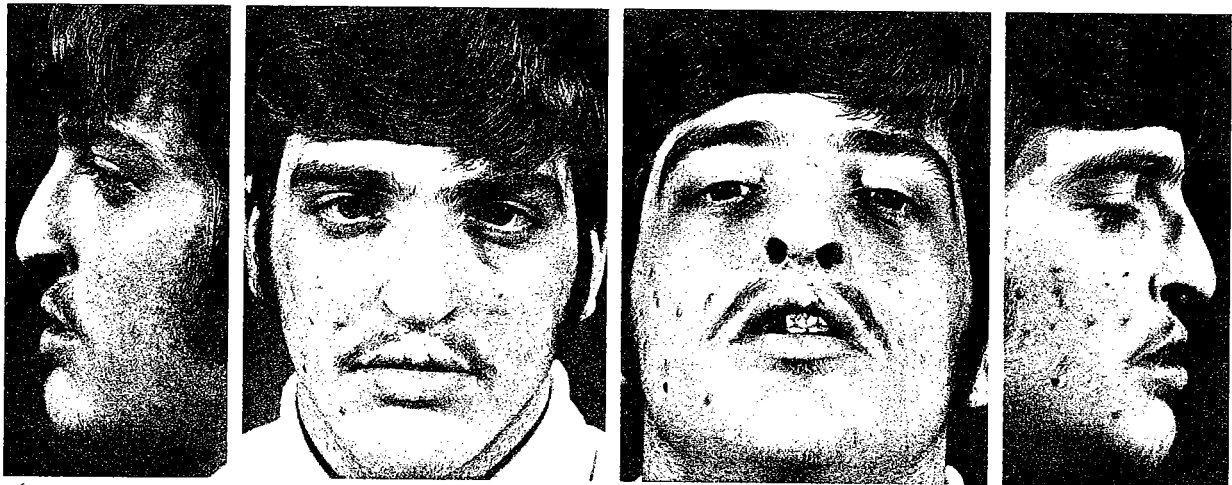





16 years

Rhinoplasty and Abbe flap

This bilateral cleft of the lip and palate was treated by many operations in New York. By age 16 years the patient revealed a high-bridged, hooked nose with large nostrils and a scarred, retracted columella overpowering a short, tight, "whisker"-scarred upper lip which, in repose, exposed both central incisors in their entirety.

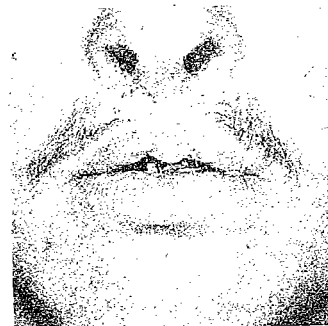

16 years

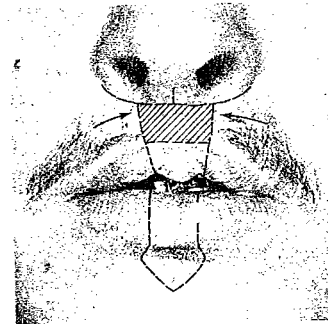


A corrective rhinoplasty included reduction of alar cartilages, removal of hump, slight septal shortening, bilateral osteotomies and cartilage strut from the bridge grafted into the columella for nasal tip definition. The "whisker" stitch mark scars of the lip persisted.

One year later the scarred skin of the central lip was excised, and the mucosa and vermilion were used to cover the raw area of the upper labial sulcus. The alar bases were cut free from the lip elements so the alar bases could be advanced to the columella and the lateral lip elements sutured to each other in their upper portion. This procedure reduced the amount of skin scarring, lengthened the lip but produced a central gap. A midline shield-shaped 1.25 cm. Abbe flap was transposed into the defect and the pedicle divided in 10 days. Other minor revisions included denuding the tips of the alar base flaps and suturing them together at the nasal spine for final reduction of alar flare, V-Y advancement of vermilion of Abbe flap to create a central tubercle and methylene blue painting followed by sandpaper abrasion of remaining skin scars.



R.R., C.S.



A.B.2



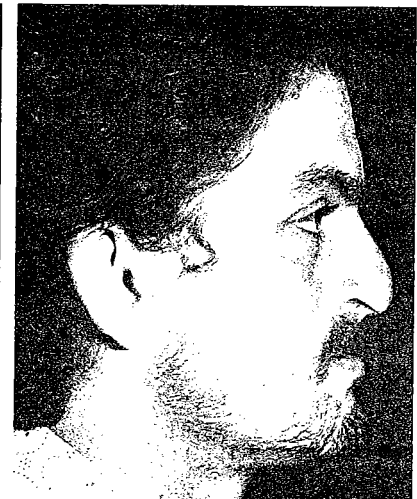
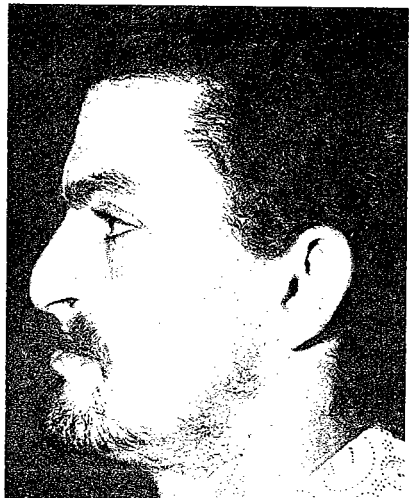19 years

Rhinoplasty, prolabium into columella and Abbe flap

This bilateral cleft of the lip and palate had the lip closed in infancy with incorporation of the prolabium into the lip. Most of the premaxilla had been lost, and the wide cleft in the palate had never been closed, so that the patient had to use a dental plate with a palatal prosthesis and pharyngeal bulb. At age 23 years he presented a short upper lip with a whistling deformity, a hairless prolabium, short columella, depressed nasal tip and flaring alar bases. There was a relative prognathism of the mandible when compared to the lack of premaxilla and deficiency of the cleft maxillary segments. Even a mustache and beard did not help much.

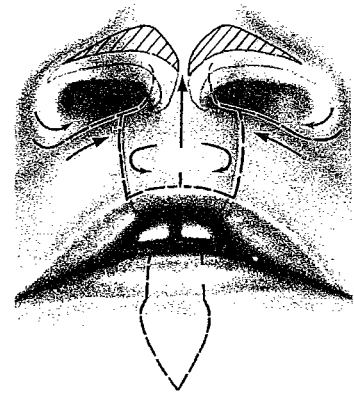


23 years




The prolabium was cut out of the lip and, with the aid of membranous septal and bilateral anterior vestibular incisions, was elevated out of the way to facilitate a reduction rhinoplasty. The alar cartilages were reduced, the hump was removed and the septum was shortened. The small bony knob of the premaxilla was smoothed down and the mucosa used to surface the area. The prolabium was thinned, shaped and rolled on itself with subcutaneous 4-0 chromic catgut sutures to form a natural columella, then advanced along the membranous septum and sutured. Its inferior base was split to receive the tail of the Abbe flap. The alar bases were freed from the lateral lip segments by circumalar incisions; then each was divided into two flaps, a subcutaneous flap and a skin flap. The subcutaneous flaps were sutured to each other at the base of the septum, and the skin flaps were advanced across the nasal floors to the columella to form the nostril sills. The lateral lip segments were advanced medially and hung to the septum creating a philtrum-sized defect.

R.R., A.B.3



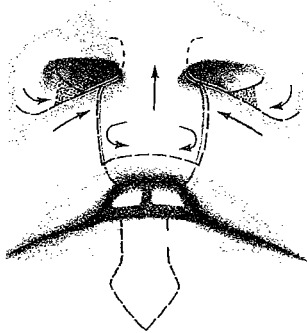
Then a 2 cm. shield-shaped Abbe flap, measuring 1.3 cm. skin length, was transposed into the upper lip with its tail tucked into the prolabium, split to camouflage the new union of lip and nose. The pedicle was divided after 11 days. When the patient was last seen, three weeks after the operation, the possibilities of a maxillary advancement were discussed.



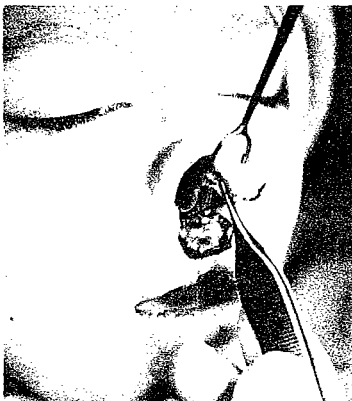
24 years

Prolabium into columella and Abbe flap

This bilateral cleft of the lip and palate was closed in infancy with the Blair-Brown type of lateral triangular flaps introduced above the inferior edge of the prolabium but with a small amount of original prolabium vermilion retained in the center. At 11 years of age, the upper lip was short, tight, with a trapdoor prolabium, a tiny whistling deformity and a large left buccal sulcus oronasal fistula. The short columella, flattened nasal tip and flaring alae gave the usual angry, snorting effect.



11 years



As visiting professor at the Massachusetts General Hospital, I was invited to carry out my usual one-stage nasal and labial correction. The prolabium was freed from the lip, thinned and curled on itself and advanced along the septum as columella with release of the nasal tip. The alar bases were cut as flaps, denuded of epithelium at their tips, advanced and sutured to the septum at the nasal spine. The mucosa of the prolabium was used as a flap to close the oronasal fistula.

Then a midline shield-shaped Abbe flap was transposed into the center of the upper lip to create a philtrum. The pedicle was

divided after 12 days, and the photographs were forwarded by Josh Tofield about two months after the surgery.

