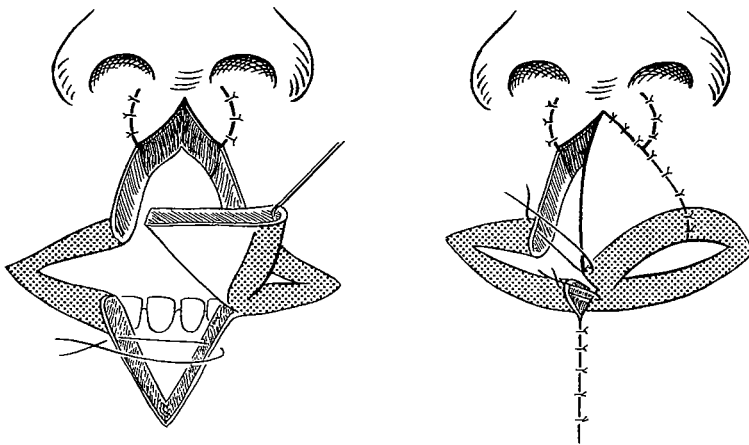


## 50. *Shaping the Abbe Flap for Secondary Bilateral Deformities*

SURGEONS have varied the design of the lip-switch flaps, beginning with the bell shape by Abbe himself. Kazanjian seemed to prefer the triangular shape while Blair favored the oblong. Then there are the cookie-cutter surgeons who copy a set design for all cases.

### SPLITTING THE TAIL OF THE PROLABIUM

Gillies had a favorite little trick of shifting most of the prolabium into the columella, leaving its distal portion in the lip. He then split it and inserted the tip of his rather wide triangular Abbe flap into the slit.





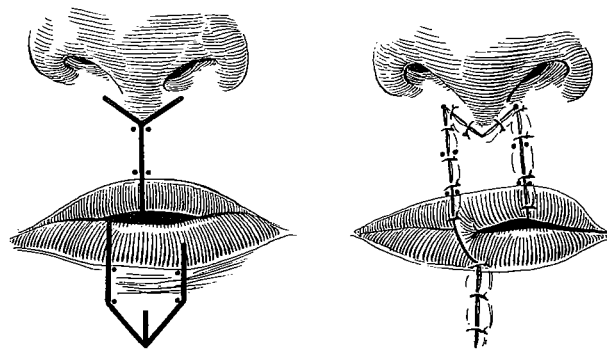
*Bradford Cannon*

## A SPLIT-TAIL ABBE

Bradford Cannon of the Massachusetts General Hospital was the son of W. B. Cannon, renowned Professor of Physiology at Harvard Medical School, and is the father of four expert glider pilots. He was trained by Vilray Blair in St. Louis and later joined James Barrett Brown to help head the plastic surgical service at Valley Forge General Army Hospital in Phoenixville, Pennsylvania. Fellow Bostonian Joseph Murray of the Peter Bent Brigham and kidney transplant fame capsulized Cannon's talents:

His skill as a surgeon, his knack for three-dimensional planning . . . his unassuming low key method of bedside teaching. . . . But in the long run, I think it is his innate ability to reduce a problem to basic components, and then apply general principles to the specific patient's problem that is his major talent.

In 1941 Cannon suggested splitting the tail of the Abbe flap to accommodate a Y incision in the upper lip, with the fork of the Y placed at the base of the columella. This maneuver achieved partial vertical lengthening when the upper lip was short as well as tight.



He presented two cases. One was a tight postoperative bilateral cleft lip. The second was a partial double cleft lip closed in childhood but still showing a diminutive midsection of upper lip. Cannon suggested that his split-tail Abbe be used in such cases at the age of 10 or 12 years to replace the prolabium, which he excised and threw away.

Twelve years later Cannon, with Murray, gave "Further Observations on the Use of the Split Vermilion Bordered Flap," noting:


It has been customary in secondary harelip repairs with vermilion bordered flaps to insert the apex of the triangular flap into one nostril or the other, or to amputate the tip and leave a horizontal scar beneath the columella. By splitting the apex of the flap, a symmetrical correction of the upper lip can be obtained. With such a flap the vertical lateral suture lines of the upper lip lie equidistant from the midline and the scars disappear within the floor of the nose. Oblique suture lines emerge from the nostrils and meet at the base of the columella where they are not apparent.

### THE W SHAPE

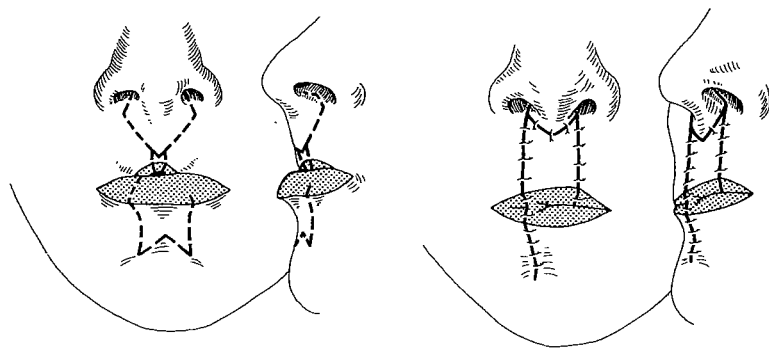
This split-tail design has been elongated and modified and has become popular through the years. Cannon, after personal communication, determined that Gordon New, a Canadian who joined the Mayo Clinic staff in 1910 and served as the head of their Section on Laryngology, Oral and Plastic Surgery for 40 years, deserved priority credit for the W-shaped Abbe. Cannon wrote in 1953:

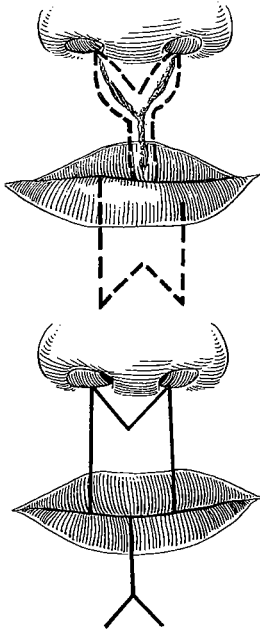
New and Havens . . . have used the split vermilion bordered flap but have outlined the flap on the lower lip in its final form. Closure as a Y instead of a vertical line may reduce the tension on the suture line and minimize the scar.

The W-shaped flap is most appropriate where the prolabium has been shifted into the columella, leaving an M-shaped defect in the upper lip. Then the W-shaped flap, when switched, becomes an M with its prongs straddling the columella and the points entering the nasal floors. The donor area is closed with the scar in an inverted Y. Of course, its shape is best adapted to bilateral clefts as diagrammed by Tessier in 1969.



Gordon New





Another surgeon infatuated by the W-shaped Abbe flap was Onizuka of Tokyo. When the lateral lip elements have been pulled together below the prolabium, there is often a long lip but there is always a tight lip, especially in its lower portion. A Y-shaped excision of the scar releases the purse-string effect as the upper lip springs open into a W-shaped defect. If our goal were simply stamping cookies with a cookie cutter and not the construction of a natural philtrum, Onizuka's W-shaped Abbe would be perfect for a W-shaped defect. However, it brands the upper lip with a strange M-shaped scar which may be an improvement but is not ideal.

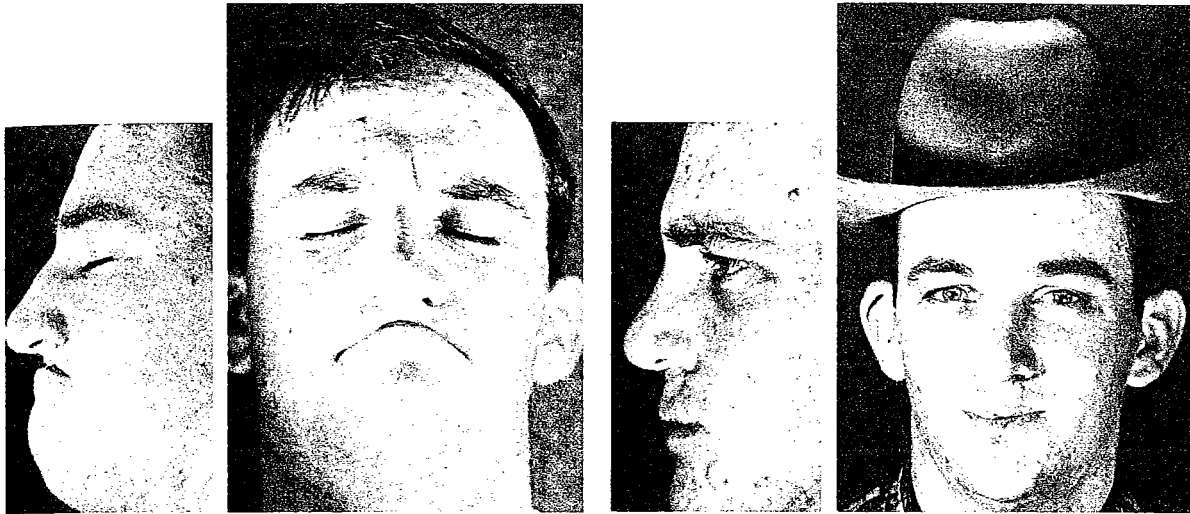Musgrave and Garrett in 1974 expressed preference for the M shape over the split-tail Abbe flap:

When the reconstruction involves the entire vertical dimension of the lip, an M-shaped flap probably will be most satisfactory. . . . Usually the "M" configuration is best achieved by in situ design, with actual excision of tissue from the tip of the flap . . . rather than by just splitting the apex of a wedge-shaped flap.

I was taught the W flap at Rookdown House in 1948-1949 and, considering it both clever and appropriate for bilateral scars, used it in my first few cases—that is, until I was mature enough to get back and look beyond the obvious improvement in the case toward an ideal normal. . .

One of my early cases in 1951 has an interesting story. The patient was a young Texas cowboy who had become a junior rodeo champion in calf roping. As a plastic surgery resident at Jefferson Davis Hospital in Houston, I used to spend my day off each week involved in the same sport and was impressed with this boy's ability to throw his loop and dismount. Starting to get off a quarter horse at full speed while he draws up to a dead stop was always the most difficult part for me in reducing my roping time. I was watching this young champion closely when I noticed that he always went in and came out of the shoot with his hat pulled down over his face. Closer observation revealed a severely short, tight, secondary bilateral cleft lip with the usual depressed nasal tip. After an introduction, we arrived at the happy arrangement of a facial dismantling and reassembling for him in

return for lessons in dismounting from a galloping cow pony for me.



What was left of the scarred prolabium was shifted into the columella, with a dramatic release of the nasal tip. A W-shaped Abbe flap was transposed into the upper lip defect. This arrangement encouraged the cowboy to tip his hat back, and he was soon back "home on the range" demonstrating the tricks of riding and roping.




#### PLACEMENT IN BILATERAL CLEFTS

Central positioning of the Abbe flap in bilateral clefts would seem obvious and is necessary when the total prolabium is shifted up out of the lip into the columella. When the prolabium is halfway up the lip, it would seem expedient to make up the lower half of the lip with a small square Abbe flap.

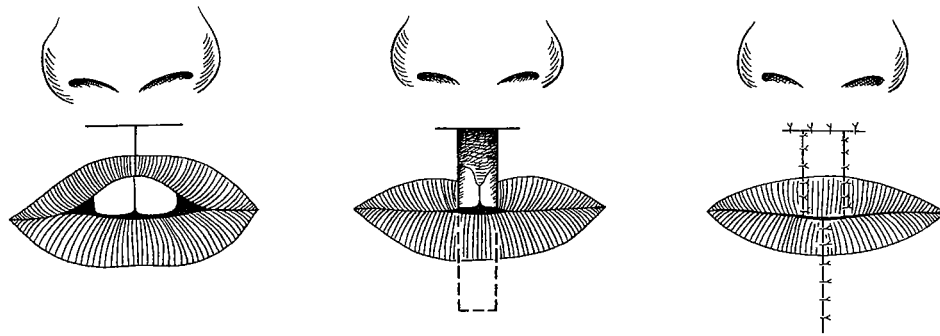
John S. P. Wilson of Great Britain, with hobbies in sculpturing and painting, presented an interesting, if segmental, design in 1964 in Hamburg:

Repaired bilateral clefts of the lip may present with various degrees of tissue shortage. . . . The free border of the lower lip should be taken as the base line. This should ideally be 1 mm. above the incisal edge of the upper incisors (Gillies and Millard, 1957). . . . The rational procedure is to release the scar of the lip and allow the lateral elements to drop to the base line but



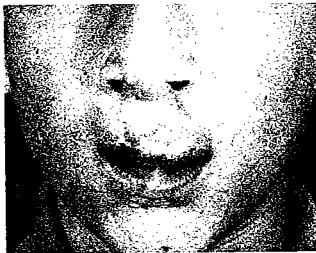*John Wilson*

no further. . . . The exact tissue defect is now established and is reconstructed by a midline Abbe flap cut to pattern.



Wilson showed a rectangular Abbe flap stuck under the prolabium which, indeed, filled his defect and improved the lip but with too much of a segmented effect. If the remaining prolabium in the upper center of the lip has any semblance of a groove, then Wilson's small rectangle, if also carrying a midline groove, can be lined up so that this plug, in spite of its mid-transverse scar, can be camouflaged as part of a natural philtrum. If not, it seems more artistic to shift the rest of the prolabium into the columella or nasal floor and construct a total philtrum with one Abbe component.

When the prolabium is present in the lip but the lip is still too tight, there may be a temptation to split the prolabium in the middle and insert the Abbe. Resist this temptation; it adds two scars to the bilateral scars for a total of four.



An even more unbelievable action is the introduction of the Abbe flap into one of the two bilateral scars in an asymmetrical unilateral position, which then presents a mind-boggling problem! A solution is shown in Chapter 39.

#### MIDLINE PLACEMENT OF ABBE THE TOTAL LIP LENGTH

In the secondary bilateral cleft deformity, when an Abbe flap is indicated, every effort should be employed to have this flap form the total central vertical length of the upper lip. It will then resemble the natural philtrum and, if correctly shaped, can appear quite normal in spite of its scars.

## PHILTRUM-SHAPED ABBE

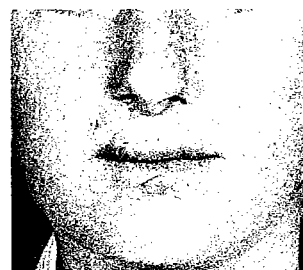Of course, the use of an Abbe flap is decided in the first place by the need of the upper lip. Some might even say that the actual shape of the Abbe should be dictated primarily by the defect in the lip. The various odd shapes that have been advocated are the surgeon's interpretation of what was needed. Some years ago it occurred to me that unnatural shapes such as the W that end up an M or the weird patterns of lopsided sickled Soviet stars are actually more reminiscent of primitive scribblings on the walls of caves than natural lip landmarks. *In fact, to cut odd-shaped flaps caters too much to the apparent upper lip defect and not enough to the shape of the coveted normal philtrum.* There are, of course, circumstances in which the shape of the lip flap must take into account the lip deformity, but in general the lip of a secondary bilateral cleft deformity can be coaxed to accept the shield-shaped philtral flap quite happily. This flap should be taken from the middle of the lower lip, transporting any central depression that might be present to simulate a philtrum even more realistically.

In 1974 Garrett and Musgrave acknowledged:

Millard properly points out that central flaps in patients with prominent central dimples of the lower lip offer an advantage in reconstruction of the philtrum dimple.

Sometimes the upper lip defect seems too wide for a philtrum-sized Abbe flap. Then, rather than cut an Abbe flap that is large and unnatural, as shown, it may be to advantage to reduce the size of the defect. To this end the principle of perialar crescentic excisions has been used. In 1908 Stone described partial closure of a wide central quadrilateral upper lip defect by approximation of the sides of the lip aided by advancement of the cheeks following excisions. This action reduced the size requirements of the Abbe flap and might occasionally be of value in those adult cases in which the entire prolabium is shifted into the columella. J. P. Webster later elaborated on this principle; diagrams appear in Chapter 54.

A cleft lip surgeon must know the beautiful normal by heart and ever work toward its creation with heart and soul. The advice

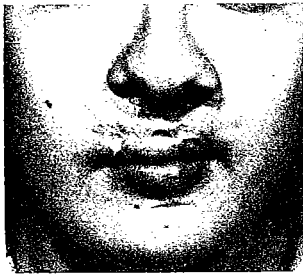

of a wise English Jewish merchant during the post-World War II period was to me pertinent:

You can make a living in fish, fruit, furniture or furs. If you're not in one, get in it.

Here are some rules for those with an artistic sense. Anyone without this sense is in the wrong business and might be better off in one of the above four F's!

Besides the general avoidance of odd-shaped flaps, there are three no-no's in Abbe flaps in bilateral clefts.



1. Do not insert the flap into the middle of the prolabium—four scars!

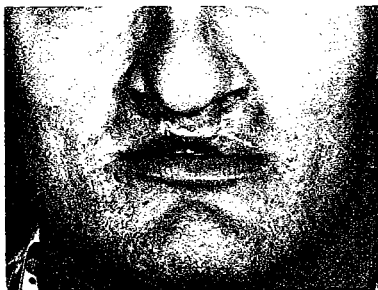2. Do not insert it into one of the bilateral scars in lopsided position.

3. Do not insert it halfway up the vertical length of the lip so that it appears as a stuck-on half philtrum.

There are exceptions to all rules, but beware breaking these.

#### “FRINGE” BENEFIT

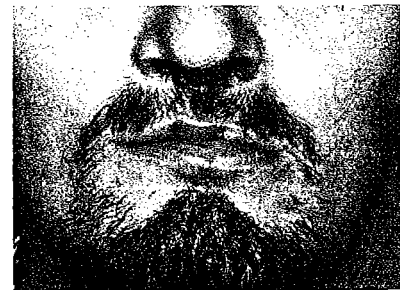When the prolabium is completely bald and the columella is very short, there is no excuse to postpone transfer. The prolabium slides out of the lip into the nose making way for an Abbe flap from the lower lip to bring in hair to amplify the center of the mustache.



Before mustache



Before Abbe



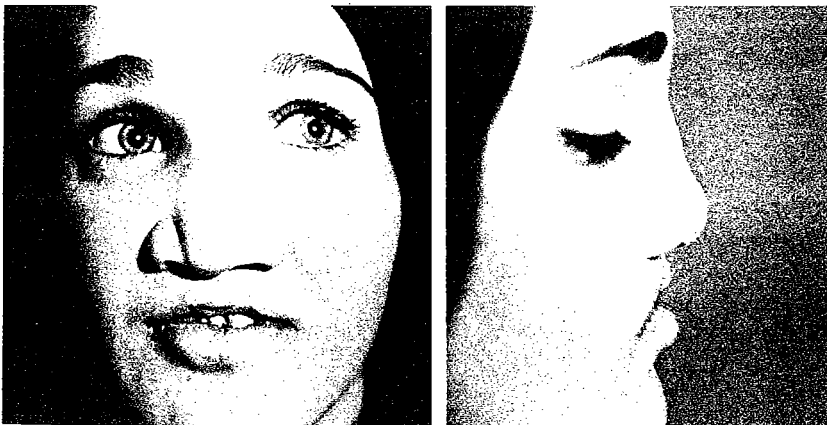After Abbe



## A CHALLENGE FROM BELOW

Rules just set to guide the preparation of the upper lip defect and the positioning of the Abbe flap were suddenly threatened in Boston by a scar of the lower lip. Again the supreme plastic surgery principle of *using what we have to make what we want* was called upon and in the O.R. at the M.G.H. under the shadow of B.C., no less!

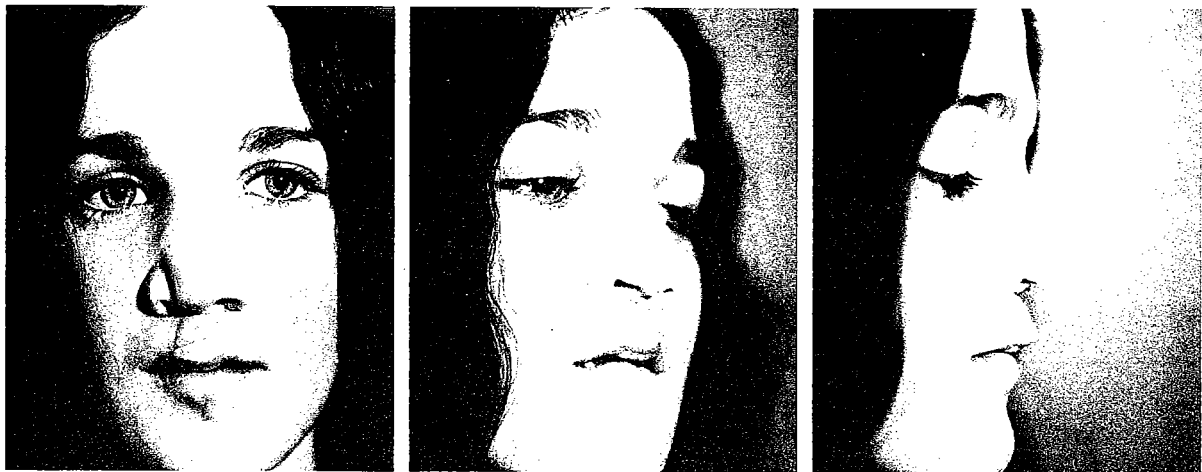
A bilateral cleft lip and palate with lower lip mucous pits was treated primarily by incorporating the prolabium as the entire central segment of the lip. Subsequently the pits were excised with rather severe scarring. At age 15 years, at the Plastic Surgery Clinic of the Massachusetts General Hospital, Boston, the patient presented a marked maxillary retrusion, a tight upper lip with a wide, flat prolabium, a short columella, a broad nose with a snubbed tip and a protuberant scarred lower lip. The chief plastic surgery resident, Joshua J. Tofield, carried out a Le Fort I osteotomy which brought her maxilla forward 12 mm. and achieved normal dental occlusion. This was well healed when the patient was presented to me in March 1974 while I was visiting professor at Harvard.



The flat nasal tip and short columella accompanied by a wide, flat prolabium, of course, tempted me to suggest a forked flap. The tight upper lip and protuberant lower lip were better points in favor of an Abbe flap. Yet destruction of the central, normal mucocutaneous junction with scarring of the lower lip following mucous pits excision posed a dilemma.

The specific procedure designed for this case could be of value in other such cases. It was a pleasure to assist Tofield in his skillful execution of the plan. As much prolabium as necessary to release the snubbed nasal tip was shifted into the columella. Still left was an intact strip of unscarred skin including the mucocutaneous junction line spanning the defect of the upper lip. This bridge maintained its inferior natural curve along the mucocutaneous junction but was cut in a flat inverted V above so that when inset in the Abbe flap the V point would push from above a slight cupid's bow V in the mucocutaneous line. Of course, the V out of the prolabium columella flap merely allowed the prongs to spread and join with the advancing alar bases as nostril sills across the nasal floors. The alar bases were cut as flaps and their tips denuded of epithelium. Then they were advanced medially and their tips sutured to each other and the septum at the nasal spine. This maneuver also reduced the width of the central lip defect. Then the posterior mucosa of the prolabium, still attached to the premaxilla, was folded as a flap over the raw area of the premaxilla to line the back side of the upper labial sulcus. Now the stage was set for the Abbe flap.

A shield-shaped Abbe flap of philtrum dimensions was cut out of the center of the protuberant lower lip. The border scarring was excised from its mucocutaneous junction area. Then the Abbe flap, ducking under the mucocutaneous junction bridge, was slid into the upper lip defect, force-fitted like a piece in a



handmade jigsaw puzzle and fixed with sutures. The pedicle was divided 14 days later, and shortly thereafter a bilateral osteotomy was used to narrow the bony bridge of the nose.

Time and minor surgery will help perfect the final result.

#### RESHAPING THE DONOR LOWER LIP

When the highly touted shield-shaped lip-switch flap is used, closure of its donor area tends to lengthen slightly the line of union, thus offsetting any straight-line contracture. The closure of the lower lip donor area is achieved with 4-0 chromic catgut sutures in the posterior mucosa, one deeply buried 4-0 Vicryl in the center of the muscle, 4-0 and 5-0 chromic catgut in the remaining muscle and subcutaneous tissue and 6-0 silk in the skin. During the 8- to 18-year age period, skin scars often heal here with hypertrophy and may need revision later. Resist any temptation to do a Z-plasty on this scar as the natural line is vertical and the length of the skin edges has already been increased; there is no need for further assistance.

A common but minor problem that arises in maybe one in seven Abbe flaps is a mild midline lump in the free border mucosa at the site of the closure. This is caused by the piling up of excess mucosa plus the tendency for mucosa to hypertrophy at the site of any trauma. Correction of this minor but eye-catching bump is its posterior, transverse, elliptical excision just behind the free border and out of sight. The excision includes what deep tissue and scar are necessary to thin as well as flatten the vermilion edge.

