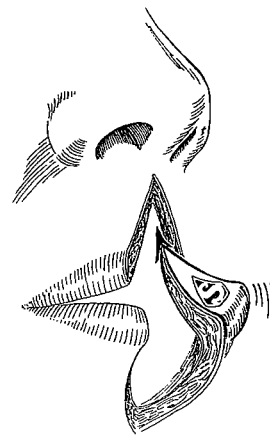


49. *The Lip-Switch Flap Principle*

BEFORE dealing specifically with cases involving a combination of a short columella and a short or long and tight upper lip, I believe it is well to review their constant savior and righter of wrongs, SUPER flap, also known in the specialty as lip-switch or Abbe flap.

The lip-switch principle has been called upon often in secondary cleft lip surgery. It has already appeared in Volume I and in primary bilateral cleft surgery and now reappears in the bilateral cleft secondary surgery, but it first deserves a general basic introduction. Let it be understood that, *had the primary surgery been planned and executed correctly, a lip-switch flap would be most unlikely ever to be required.* Unfortunately, this is not the case because tissue misappropriations, violations of principles, destruction of landmarks and retardation of growth have set up too many bilateral clefts in which tissue must be brought in from outside and used to remove scars, bring in muscle continuity, create a philtrum and even a bow, correct free border defects and, of course, relieve tension.



CAUSE AND EFFECT

In congenital clefts of the lip there are varying degrees of actual missing tissue in the first place. After parings, excisions and scarring have taken further tissue toll, the horizontal shortness may become acute. When primary and secondary maxillary platform retrusion is added, the effect of the tissue lack is multiplied.

SIMILAR KIND OF TISSUE

Only the upper or lower lip has similar tissue in kind for the opposite lip. As a normal lip can usually spare as much as one-third its width, switching flaps from one to the other is a principle that has been found of great value through the years in secondary cleft deformities as well as other defects.



SABATTINI

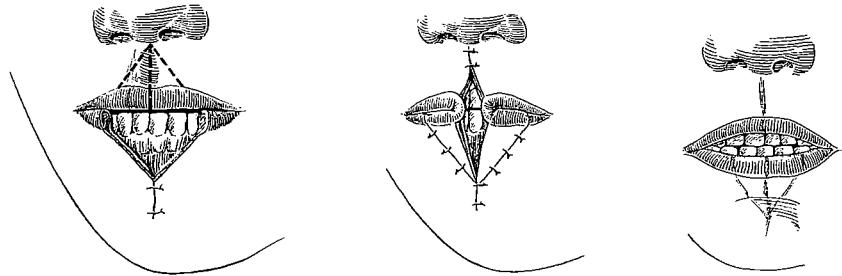
In 1837 Pierre Sabattini of Imola, Italy, carried out what seems to be the first lip-switch flap. A patient had lost the center of his nose and lip by a saber cut. Sabattini used an Indian forehead flap for the nose and a full-thickness flap from the lower lip to fill the upper lip defect. Schuh, Crikelair and Cosman noted in the *British Journal of Plastic Surgery*, 1970, that he divided the pedicle at seven days, goaded by "the incessant prayers of the patient."



Sophus Stein

STEIN

Poul Fogh-Andersen, a Dane, brought attention in 1948 to the hundredth anniversary of another Danish surgeon, Professor Sophus August Vilhelm Stein, of the Royal Fredericks Hospital in Copenhagen, who in 1848 published a "new method of cheiloplasty" in Danish, using the principle of replacing a defect in the lower lip by a transposition flap from the upper lip. Actually, his patient was a 48-year-old sailor with an extensive lower lip cancer which, after excision, presented a huge V defect. Stein used a double transposition-plasty from the upper lip with two vermilion bordered pedicles that divided the oral orifice into a medial cleft. The pedicles were divided after three weeks and the clefts closed.



N. C. Petersen has reported a hospital record of another of Stein's cases in which he transposed a single-pedicled flap of the philtrum of the upper lip to a gunshot deformity of the lower lip, dividing the pedicle after five weeks.

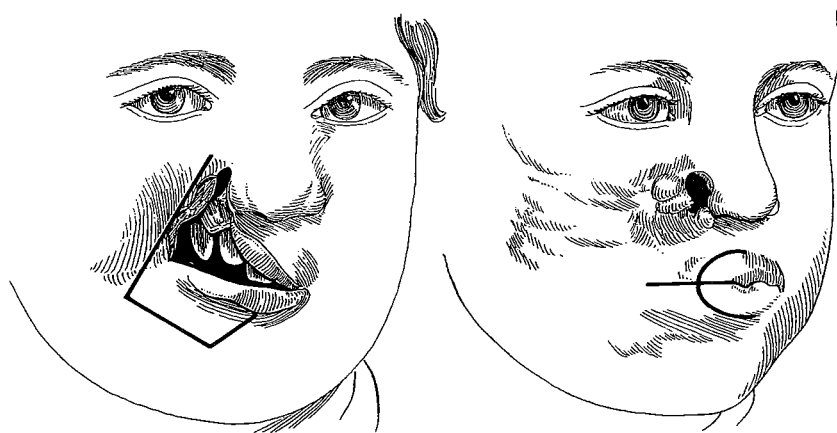
These procedures, having taken the entire philtrum, seem to have created a secondary deformity in the upper lip, similar to a postoperative congenital cleft, while treating a lower lip defect.

BUCK

It is interesting, as noted by Conway and Stark, that in 1862 Gurdon Buck at the New York Hospital was rotating full-thickness lower lip flaps on the coronary vessels to fill defects of the upper lip. His flap was similar in principle to a design used by Gillies during the two great wars and, as it rotates like a fan, became known as the fan flap.



Gurdon Buck



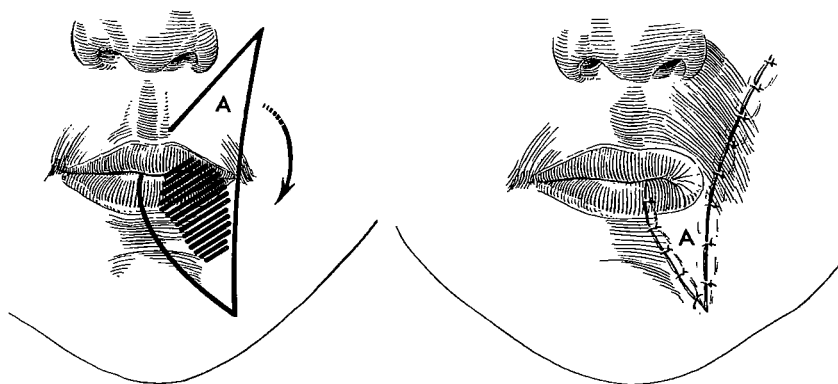
ESTLANDER

The Finnish surgeon J. A. Estlander became professor of surgery and ophthalmic surgery at Emperor Alexander University, Helsinki, Finland, at the age of 28 and died in Italy and was buried there at the age of 35. During just seven years he became famous for a thoracoplasty procedure and a lip-switch flap. In 1865 he treated several lower lip deformities: The first was the result of a resection of an epithelioma; the next two followed typhus with gangrene. Estlander repaired these defects with flaps from the



J. A. Estlander

lateral portion of the upper lip utilizing the coronary artery at the angle of the mouth. As the blood-supplying pedicle consisted of the mucosa and vessels at the commissure, the permanent oral orifice was reshaped at once and the operation usually completed in one stage. Estlander published his method in Germany in 1872 and in France in 1877, and thus it entered the world literature and textbooks.



The present fine Finnish plastic surgeon Borgie Sundell is working in the hospital that Estlander planned.

NEUBER

From Aachen, Germany, Momma, Koberg and Mai noted that a German named Kreche in 1899 reported that another German, Neuber, had been using the lip-switch flap since 1891.



Robert Abbe

ABBE

Yet, as Abbe was the first actually to switch a lower lip flap into the upper lip for a cleft deformity, this flap will be referred to simply as *Abbe* in this book. Richard Stark, also of St. Luke's Hospital, New York, researched and later reported on the life and works of Abbe. A descendant of the French who escaped to England during the Huguenot persecution, Robert Abbe was born on Dutch Street in New York City, destined to become a brilliant American surgeon. He set up his practice at 32 East 20th Street and often drove his horse and carriage past Theodore

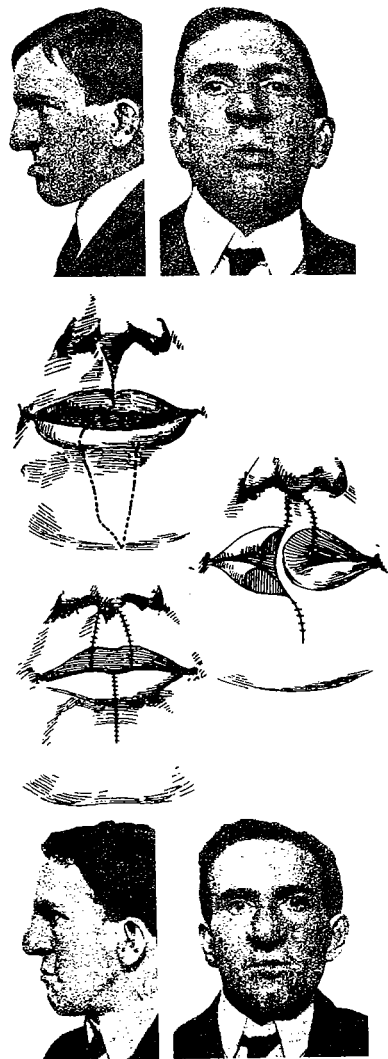
Roosevelt's home, just down the street, on his way to the hospital.

Abbe first considered the lip-switch idea in 1895, and in 1898 he wrote a description of "A New Plastic Operation for the Relief of Deformity Due to Double Harelip" that was published in a weekly journal, *The Medical Record*:

A lad of twenty-one years recently presented himself for a conspicuous deformity of the lips, the sequel of an operation for double harelip in infancy, consisting in an extreme flatness and scantiness of the upper lip, with an enormous pouting and redundancy of the lower one. . . . Their inequality was admirably corrected by transplanting the middle portion of the lower lip into the upper. . . . A median vertical incision was made in the upper lip, and the central scar portion excised so as to obtain edges of an excellent quality of skin. The gap thus created was about three-fourths of an inch in width. A flap taken from the central portion of the lower lip, a little wider than the upper gap, was then made, in such a way as to make a hinge upon one side containing the lower branch of the coronary artery on the left, which flap was turned upward so that its lower edge on the skin was placed beneath the columna nasi. The vermilion border was exactly stitched on one side, as shown and numerous very fine stitches were applied so as to secure apposition around three-fourths of the flap. . . . On the twelfth day, the flap having grown perfectly in its new position, its base was very carefully cut from the lower lip so as to leave an ample portion of the red middle lip. . . . The lower lip was then refreshed and sutured. The nutrition of this transplanted flap by its new capillary nourishment was so perfect that in color and texture, it seemed to have been always a part of the upper lip. . . . The two lips were afterward in about their normal proportion, and gave the patient perfect satisfaction.

This Abbe was a remarkable man, a pioneer in neurosurgery and in photography, the founder of radium therapy in America and an innovator in general as well as plastic surgery. He was as courageous in life as he was in surgery. Conscious of a growing tightness of his hat, he had his suspicions of Paget's disease confirmed by X-ray examination and then, as an aplastic anemia took him down, revealed the true measure of his character in a letter to a friend:

So closely do I note every sign that I almost feel that I have never before done justice to any one. This makes me wish to start life again and to do better.



He died at age 77 and was buried in the chapel of St. Luke's Hospital, where he had trained and later served so brilliantly.

KAZANJIAN

In 1947 Varaztad Kazanjian of Boston noted that secondary deformities in cleft lip and palate cases often are not apparent in infancy and young childhood but become quite marked in adulthood. He stated:

With the improvement in surgical technique the patient as well as the surgeon has become more critical of the final result.

He presented a series of 50 cases treated over an eight-year period which varied from tense, retracted upper lips to cases with loss of upper lip tissue, marked with ugly adherent scars and combined with retraction of the alveolar processes and loss of many teeth. He advised excision of the original scar to allow the lip elements to separate into a triangular defect. Into this defect he transposed a triangular flap of the desired size from the lower lip which he called the Estlander-Abbe operation. In unilateral cases the flap was placed in unilateral position and the pedicle divided after two weeks.

BLAIR

As early as 1925 Vilray P. Blair commented on the value of secondary cleft correction:

The results of operative repair of harelip vary from nearly perfect to plain bad; but unless the original operator has been more than ordinarily inconsiderate in his denudation and suturing, the tissues can usually, by secondary operation, be rearranged to produce an approximately happy result.

Twenty-five years and a horde of lip-switch flaps later, Blair prefaced a 1950 presentation with a typical V. P. B. twist:

The broad idea of switching a flap from one lip to the other is old and one or another pattern of it has been claimed and credited to many people, so much so that Dr. Jerome P. Webster started looking for the original publication. He found first a publication by S. A. C. Stein of Copenhagen reporting a case of lip-switching in 1848. Later in his research he found that

Pietro Sabattini of Bologna had done one in 1837. How these ancients steal our thoughts!

Through all those years Blair did a tremendous volume of secondary cases sent to him from all over midwest America. He was in such demand that he had two or even three tables going at one time. Swathed in gauze and comfortably outfitted in a pair of old white sneakers, he would sit and hum while he worked at one table, then move over to the next. His artist, Hance, recalls:

He had a terrible temper and in a rage would kick over a table but the next day send roses to the operating nurse.

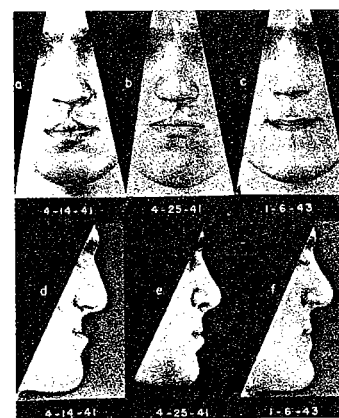
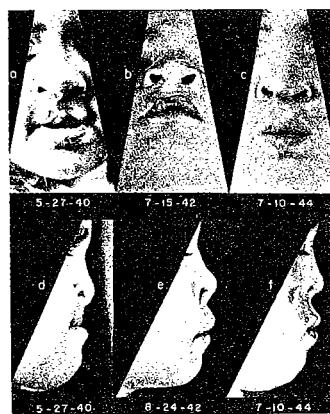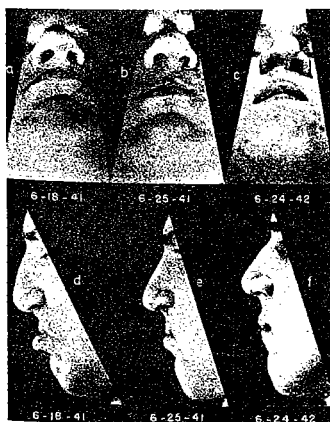
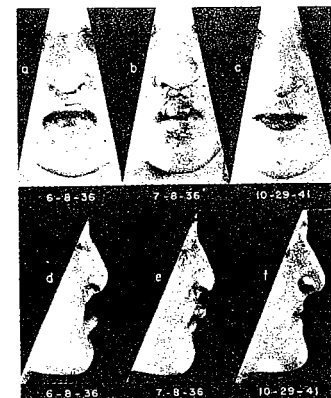
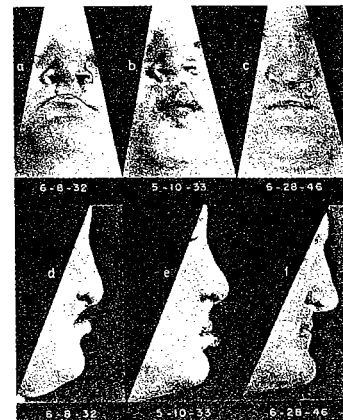
His eccentric combination of artistry and kindness caused him to have the walls of his operating room at Barnes Hospital decorated in color with fanciful jungle scenes and such children's bedtime stories as Little Red Riding Hood and the Three Bears. These were over the head of the infants, but children and adults coming up for secondary cleft work were particularly delighted.

In January 1950 Blair, with Gordon Letterman, published in *Plastic and Reconstructive Surgery* an impressive group of 22 secondary cleft deformities treated with a flap switched from the lower lip. Those that could be reproduced reasonably well have been included here. As the authors noted:

The majority of these cases had had more or less complicating attempts at correction before coming into our hands. . . . Some had had lip pits removed and most have an upper advancing denture to give the desired curves and to hold the upper lip forward in proper relation to the lower. . . . Most of the cases have a real protrusion of the lower lip due to the transverse shortening of the upper and the switch gives both needed fullness to the upper lip and better symmetry to the lower.

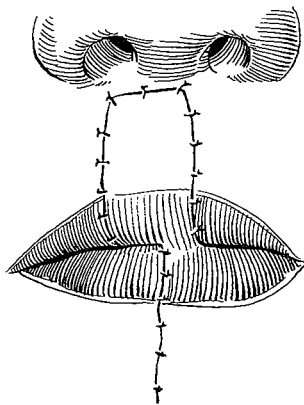
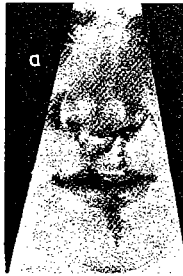


A Note on a surgeon Gertie Hance

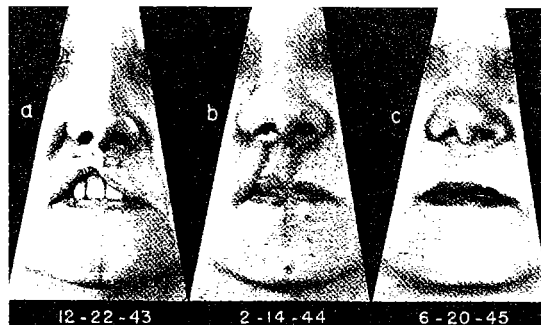


In his typical manner of using eye and hand for preliminary measuring, Blair suggested:

A tentative plan is to mark off on the mucocutaneous border of the lower lip the amount desired for transplant, and then to draw each of these marks in turn to a little beyond the midline. This procedure will give a fairly good idea of the amount available for the upper lip without too much distortion of the lower. . . . The flap is taken from the center of the lower lip where the scar is less noticeable; however, if the upper defect is one-sided, the pedicle is retained on the opposite side.



The cases reported revealed a variety of flaps—some narrow, some wide, others short or long and most *oblong* but occasionally triangular in shape. They were inserted unilaterally in unilateral clefts and centrally or unilaterally in bilateral cases. Portions of the upper lip were shifted by oblong or trefoil flaps into the nose and columella prior to transposition of the lip-switch flap. The results were truly dramatic, particularly considering the secondary problems, but according to modern standards some might be considered unrefined or even rough-hewn.



THE VALUE OF A NARROW PEDICLE

It is well to emphasize that the pedicle required for the transport of these flaps need be little more than the coronary vessels themselves. The main inferior labial artery runs between the mucosa and the orbicularis oris muscle along the upper inner edge of the free border of the lower lip. Thus the flap can be cut loose well across the vermilion anteriorly and down to a frighteningly narrow base. The position of the vessels, varying slightly in each case as it does, only adds to the sport. For those who are

not gamblers, the exact position of the vessels can be spotted, of course, during the complete severance of the lip while developing one side of the flap. Once the base has been narrowed, it allows almost complete inset of lower lip flap in the upper lip position during the first operation.

Writing in 1952-1953 for publication in 1957, Gillies and Millard described in laborious detail this specific aspect:

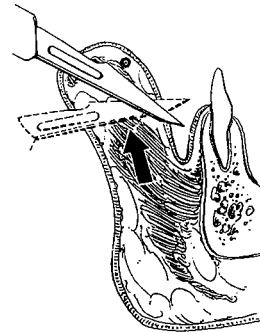
To cut the flap, first ease through the skin and muscle with a No. 10 scalpel, pick up spurters, then divide the remaining mucous membrane with scissors. At the tiny base of the flap the incision should be carried just through the vermilion border in front, so that when the flap is rotated 180° it can be sutured into position plumb vis-a-vis, requiring no important readjustments on division of the pedicle.

In fact, it was Gillies' feeling that, even if the coronary vessels were divided, so vascular is labial mucosa that the flap would survive on a mere mucosal hinge. This prized piece of lip tissue is so valuable, however, that he never challenged his theory by actual trial.

In 1953 Cannon and Murray in Boston emphasized the advantages of cutting through the anterior mucocutaneous junction line on the pedicle side of the Abbe flap to form a thin posterior pedicle and facilitate more accurate inset of their split-tail flap with its tips in the nostril floors.

J.-L. Grignon of Paris described his way of reducing the size of the pedicle for the Abbe flap in 1962. To less daring surgeons this frightening encroachment on the pedicle by Grignon's scalpel might be considered another Grand Guignol theatrical but actually it is both safe and sound.

In 1963 McGregor reemphasized the importance of cutting the pedicle narrow by extending the incision through all skin so that the flap is tethered only by mucosa and the inferior labial vessels to facilitate accurate insertion of almost the entire flap.



AN OPPOSING VIEW

Although most surgeons agree with a narrow pedicle divided early, there are some who do not. Professor Karl Schuchardt, at

his 1964 Hamburg Congress, took an opposite stand with typical dictatorial eloquence:

If you use an Abbe-flap for whatever indication, it is advisable not to sever the pedicle too soon, as the longer you leave the triangle flap from the lower lip attached to the vermilion border, the better it stays and the less atrophy occurs (I leave it at least 4 weeks!).

The professor has always been impressive and convincing, but this seems nonsensical.

John Erich, one of the plastic pillars of the Mayo Clinic, also held to the old standard Abbe rules ignoring philtrum shape, central donor area, narrow pedicle, and early division when he wrote for Converse's book in 1964:

The proposed triangular flap on the lower lip should not be located in the center of lip but to one or the other side of the midline. . . . The incision on the pedicle side of the flap should fall 2 or 3 mm. short of the mucocutaneous border, ensuring that the inferior labial artery will not be severed during elevation of the flaps. . . . When healing is complete—a matter of three weeks—the pedicle is divided.

Conservatism *outside of politics* can hamper effectiveness.

TOO WIDE OF THE MARK

In 1974 Momma, Koberg and Mai of Dusseldorf and Aachen reported their experience with the Abbe flap in detail, presenting one pleasant case out of a series of 204. They noted the width of their Abbes at the vermilion border to be 8 to 30 mm., averaging 18 mm., which is a bit wide for a philtrum. The upper lip width after the Abbe flap of 49.3 mm. compared favorably with the 52 mm. of their normal controls. They found 74 percent satisfactory upper lip scars, with 44 percent of patients having complaints about vermilion border and 33 percent unhappy with the lower lip scar or the vermilion bulge. They concluded with the profound statement that the Abbe flap plasty should be used

*more
common
after wide
flaps*

As seldom as possible, as often as necessary.

In what must have been a language misunderstanding, they made these incorrect statements:

Opinions as to the indications for Abbe operation are diverse in the literature. Whereas Antia and Honig (1964) recommend Abbe-plasty in all bilateral clefts of the lip and palate, Millard (1964), Schuh, Crikelair and Cosman (1970) and Perko (1973) more or less deny Abbe-plasty its right to existence.

OK
so far
not all
not at all

These assertions are nonsense.

POSTOPERATIVE HANDLING OF AN ABBE FLAP

When the usual rhinoplastic procedures have been combined with columella lengthening and an Abbe flap, the postoperative course requires a little closer supervision. Nasal packs for 24 hours ensure adherence of the mucosal lining and prevention of hematoma. Yet they temporarily block the nasal airways, and with the lips attached, free breathing is hampered. Stiff rubber tubes inserted on either side of the Abbe pedicle and long enough to be held by the teeth will facilitate an airway until the patient regains his confidence. Then they can be discarded. A Logan bow is placed across the lower lip to reduce any tension, as this is the only lip that has been tightened. There is no need to wire the teeth or wrap the head to hold the jaw shut, because tenderness of the stretched pedicle is enough warning to the patient that the mouth is open too wide. Feeding during the flap attachment time is limited to fluids and any soft diet that can be sneaked through either side of the pedicle. The patient is allowed to go home as soon as he adjusts to the lip synechia—often as early as the first postoperative day. Skin sutures are removed at 3 to 4 days, and after 7 to 12 days the pedicle is divided.

A FUNCTIONAL FLAP

Not only is the lip-switch flap effectual in achieving an artistic lip reconstruction but also it is capable of regaining its function.

When writing the cleft lip and palate section of our *Principles and Art of Plastic Surgery*, Gillies and I recalled a patient who had

had an Abbe flap placed in his tight postoperative cleft lip. Review of the case caused us to note in 1953:

Recent review of this case suggests that the muscle in the Abbe flap itself has become reanimated. It is difficult to test electrically, but it seems to contract with whistling. He is a flutist.



James Smith

James W. Smith of the New York Hospital-Cornell Medical Center, in 1960 and finally in 1961, studied return of function in vermilion bordered lip-switch flaps. He concluded:

An analysis of 50 consecutive cases is presented in which Abbe or Estlander flaps were used. . . . Fifteen of these cases have been studied extensively to determine the ultimate functional role they play in their new site. Examinations were made on the regeneration of sensory, sympathetic and motor nerves. It has been conclusively demonstrated that complete return of sweating and of sensitivity to pain, touch and temperature occurs within two years. Electromyography has shown that the transplanted muscle is reinnervated within one year.

Smith won honorable mention in the Educational Foundation Essay Contest for his electromyographic studies demonstrating the return of muscle function in the transplanted flaps. Jim recalls that when he was preparing to submit his award-winning paper for publication Dr. Herbert Conway refused to approve the illustrations. His keen eye caught the discrepancy that all the sketches, the preoperative, the postoperative and even those showing the flap in transfer, revealed the same ideal lip relationships. Only after Smith and the artist labored several months sketching in the preoperative deformities did Conway finally give his permission, muttering,

Who were the Foundation judges? Anyone awarding a prize for such unrealistic sketches must have poor vision and should not be selected to judge again!

In 1961 the austere and innovative Noel Thompson of Middlesex Hospital, London, with morbid anatomist A. C. Pollard of Stoke Mandeville Hospital, Aylesbury, Bucks, studied the motor function in Abbe flaps and gave a report based on biopsies taken at intervals of from 11 months to 10 years after separation of the flap from the donor lip. They concluded:

Following histological and histochemical investigation of muscle biopsies taken from the Abbe flap and the normal lateral lip elements of six patients, evidence is submitted to support the concept of motor reinnervation occurring in such flaps. Such evidence is based chiefly on the demonstration in the flaps of:

1. Normally striated skeletal muscle elements.
2. Motor end-plates exhibiting cholinesterase activity of normal intensity.
3. Nerve axons exhibiting some of the characteristics of motor nerve fibers.

Professor K. Schuchardt, in 1964 in Hamburg, reported the findings of one of his assistants:

Dr. Lentroidt, one of my assistants, made an electromyographic investigation on the reinnervation of Abbe flaps after they had been sutured into the upper lip. Twenty patients were investigated and in 15 it was possible to follow up the innervation for from 1 to 2 years. . . . 2 to 4 weeks after the operation there was a total deinnervation, and no electromyographical response. Between the fourth and sixth postoperative week a recovery of the action potential was recorded. This was probably due to a rest-innervation through the unsevered pedicle . . . after the pedicle was severed there was a complete de-innervation . . . After 2 months in most of the patients, mostly after the 3rd month, a slow progressive re-innervation occurred . . . the re-innervation started from around the ala wing and columella . . . nerve growth into the flap was innervated half a year postoperatively, and this was found in all our patients. . . . Muscular function is markedly improved in the second half year after intervention. The maximal result is observed near the end of the first postoperative year and differs only slightly from the function of normally innervated muscle.

At this point Bengt Johanson of Göteborg rose to remind Schuchardt of his studies on the subject three or four years before:

They are really very careful studies over a very long period of years. We have shown exactly where this reinnervation starts in the Abbe flap.

In fact, in 1962 I. Isaksson, B. Johanson, I. Petersen and U. Sellden reported:

Reinnervation of ten Abbe flaps and five fan flaps was studied by an electromyographic technique. Results of the two groups were equivalent.

Voluntary activity was not manifest until at least five weeks had elapsed. Although electromyographic findings evidenced a high degree of functional restitution, in no case was complete normalization observed.

Takahashi, with Koto in 1966 and with Koto and Ishii in 1967, reported studies on the degree of motor function, changes in skin temperature and function of the salivary glands in the transplanted part of the lower lip living in the upper lip. They found that in their series functions became normal within nine months of the Abbe transposition.