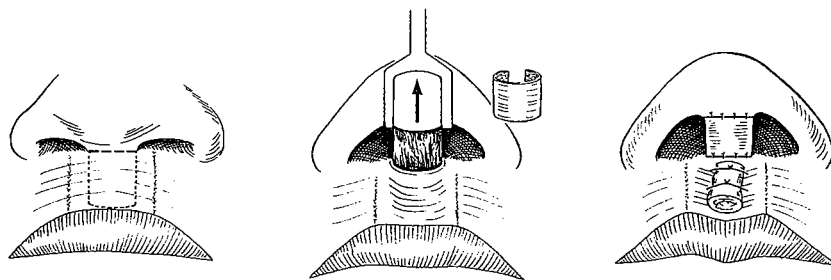


41. Other Odd Ways of Lengthening the Columella

A SUBCUTANEOUS FLAP AND GRAFT

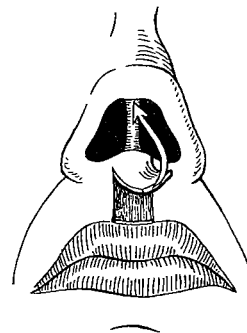
WHEN the upper lip cannot spare skin but would benefit by the production of a philtral groove, a subcutaneous tissue flap continuous with the columella base can be dissected out of its mid-vertical length. Elevation of the nasal tip draws the subcutaneous flap out of the lip the way a robin pulls an earthworm out of the ground. Its raw surface can be wrapped with a free auricular skin graft and the donor area depressed with through-and-through sutures tied over a bolster.

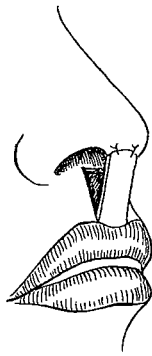


This method was first described by me in 1963, for a luetic absence of columella, and its one advantage was the lack of lip skin scarring. It is quite possible that a thin cartilage strut could be threaded up through the new columella as a secondary procedure.

UNIMAGINATIVE USE OF UPPER LIP SKIN

There were several early methods of obtaining skin from the upper lip for columella reconstruction. In 1833 Dupuytren raised

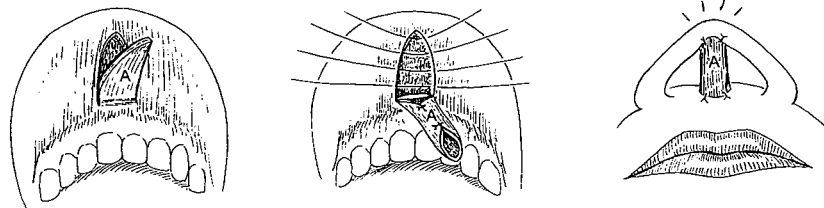




a rectangular flap from the midline of the lip based on the septum, twisted it 180 degrees and sutured its end to the nasal tip with the skin surface forward. In 1842 Serre based his lip skin flap on the vermilion border. Both of these methods were mutilating to the lip and, of course, are now obsolete or should be.

BUCCAL SULCUS FLAPS

Columella tissue can also come from pedicles of upper buccal sulcus mucosa. In 1931 Lexer described labial mucosa, in the form of a vertical tube pedicle, being pulled through an opening in the upper lip to supply the columella. He even denuded the base of his pedicle to avoid a fistula and claimed that this mucous membrane became paler and less noticeable after a few weeks of exposure.

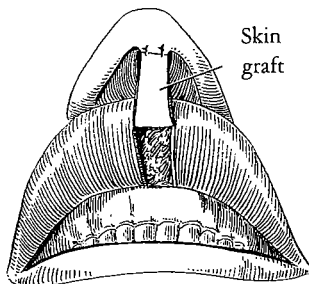


Ferris Smith

Yet in 1918 Gillies was faced with a columella partially reconstructed with lip mucosa. It had had plenty of time to lose its blush, but, as it still looked more like a "nasal hemorrhoid" than a columella, he excised it!

The feisty but realistic Ferris Smith of Grand Rapids, Michigan, one of the American pioneers in plastic surgery, often reminded his residents:

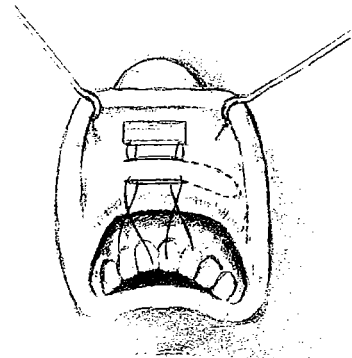
There is nothing new under the sun or a petticoat!



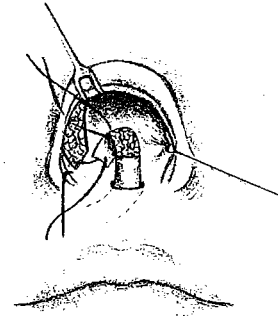
He, too, was with Gillies at Sidcup during the First Great War and later achieved some remarkable results with serial excisions. Smith designed a method of columella construction which circumvented the color problem faced by Lexer. He first lined a mid-vertical lip mucosal strap with a skin graft. Later he divided its upper end and with its base on the tubercle of the free border flipped the flap out of the mouth and up to the nose with the skin graft in front. Finally, the lip attachment was severed and the mucosa-backed skin graft inset as columella.

In rare cases this principle may be of value in the short columella. Variations of the technique were described and illustrated by me in *Plastic and Reconstructive Surgery*, April 1963:

A buccal mucosal flap can be tubed primarily, transported to its final columella position and later resurfaced with a postauricular skin graft. Another approach first lines a horizontal buccal strap flap with a chondrocutaneous graft from the postauricular area. This produces a natural skin color for the future front of the columella and at the same time produces a support and definition to the column. . . . The medial base of the flap is set just past the midline and as soon as the chondrocutaneous graft is well vascularized, the lateral end can be divided, turned over with skin in front, threaded through a slit incision at the future site of the columella base and attached to the nasal tip. Several weeks later the inferior end is divided from the lip mucosa and attached to the lip skin.



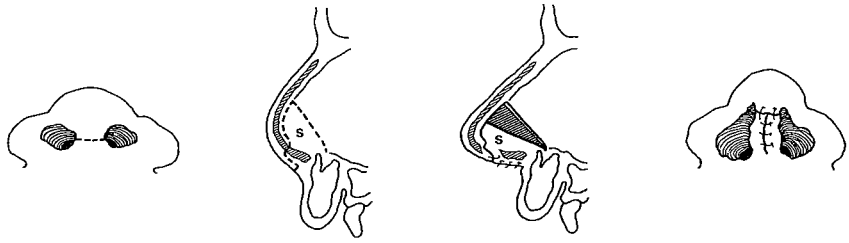
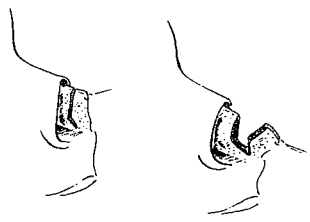
Shilling
1963



COLUMELLA LENGTHENING BY SEPTAL FLAP

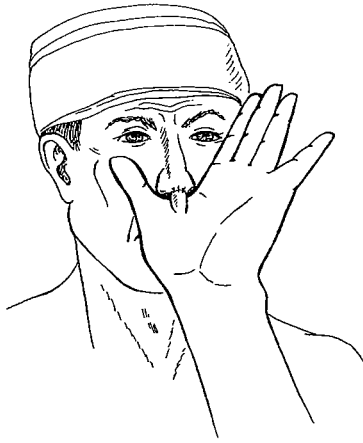In 1975 in the *British Journal of Plastic Surgery*, Miguel Orticochea of Bogotá advocated a septal swing flap similar to that described for nasal tip support by Gillies and Millard in 1957. He released the short columella, then swung out a septal flap with its base below to form the lower two-thirds of the columella, suturing the membranous septal skin together in front and uniting it to the columella stub attached to the nasal tip.

Shilling
1975



This is another method of lengthening the columella, but it leaves a permanent septal perforation and a lack of bridge support, presents a slightly strange-looking columella with a suggestion of eventual adult inadequacy and, of course, poses the possibility of a deleterious effect on nasal growth with such early septal surgery.

Then there are the even more far-out methods that bring tissue



from a distance. The most direct is one described by Labat in 1833 using a flap raised from the skin web between the thumb and index finger. This requires the hand to be held to the nose for at least two weeks in a rather rude "thumbing" position. I used a modification of this once, and once was enough!

THE UBANGI STRETCH

In 1977, Kernahan, considering the nasolabial angle sacrosanct and lacking confidence in his ability to create an artistic columella angle during its lengthening in bilateral clefts, admitted reverting to the Ubangi tribal principle. He makes a slit in the membranous septum and, instead of inserting a ring with graduated weights, introduces increasingly larger plastic prostheses in the hope that he can lengthen the columella. The only trouble is, the columella will thin out as stretched and when the prosthesis is removed, it might contract like a released earthworm and snap back into its hole.