

39. Columella Lengthening by Vertical Scar Flaps Including the Forked Flap

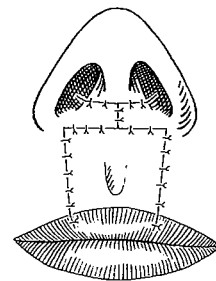
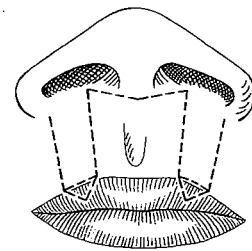
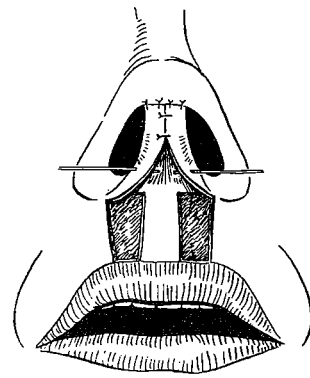
VERTICAL LIP TRANSPOSITION

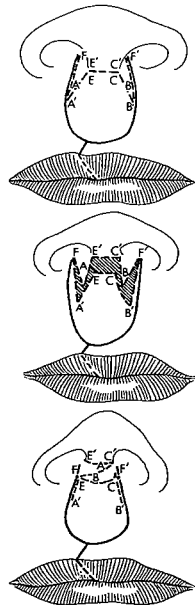
IN 1881 Demons advocated the raising of two rectangular flaps of skin and subcutaneous tissue lateral to the philtrum with their bases above and their free ends reaching the vermilion border. They were turned up and awkwardly transposed 180 degrees so that their raw surfaces were apposed and their ends attached to the tip of the nose. The lip donor areas were closed directly.

In 1955, at the Stockholm Congress, Richard Trauner of Graz presented his vertical lip flap, transposed horizontally across the columella base for columella lengthening in the primary unilateral cleft. At a congress in Hamburg the previous week he had also demonstrated this flap as a secondary procedure in bilateral clefts. In 1967 in Rome, he and his son showed their adaptation of the method primarily in bilateral clefts, which they referred to as a double Z-plasty. In 1972, while visiting in Miami, the senior Trauner mentioned that he got better columella lengthening with secondary procedures and that he had used his flap more than once on the same patient to advantage.

MORE Z'S

Another secondary flap design to lengthen the columella was described by Marcks, Trevaskis and Payne in December of 1957. They cut two single-pedicle flaps from the outer border of the





prolabium along the old scars and transposed them at 90-degree angles crisscross fashion into a releasing incision at the base of the columella in what they called a Z-plasty.

This narrowed the width of the lip, lengthened the columella and had the extra advantage of being a one-stage procedure. It was responsible, however, for a most unnatural columella scar line and at best could lengthen the columella no more than the sum of one width and one tip of the two flaps. In certain cases when the need for columella lengthening is limited, this approach may be of value as it does not add further scarring to the lip.

When the vertical flaps are taken from the lateral lip elements, based on the alar wings and transposed across the base of the columella, then in principle they are the Trauner Z. The same general corrections are achieved, but as the flaps only meet tip to tip at the base of the columella, the lengthening of this element is even less.

In 1966 M. V. Mukhin and A. P. Agroskina of Leningrad endorsed Marcks' design for columella lengthening in bilateral clefts and diagramed their modification.



THE FORKED FLAP

For the same type of secondary bilateral cleft lip deformity, in which the prolabium is wide, the nasal tip is spatula flat, the columella is extremely short and the alae are flared, the *forked flap* was developed originally. It was first used at St. Joseph's Hospital, Asheville, North Carolina, in the mid-1950's on a 12-year-old Tennessee mountain girl who in infancy had been operated on by William Justice, an early student of William Ladd of Boston. Her severe bilateral lip clefts had been closed with the prolabium constituting the center of the lip except where lateral mucosal flaps joined beneath the prolabium as advocated by Federspiel. As I suggested in 1958:



From the moment of the first surgery, the nasal tip had gone down in defeat in its struggle with the lip for the prolabium. By now, the nose tip is spatula flat with no nasolabial angle and, in fact, boasting little to no profile at all. As with any nose that is bursting for projectory growth but is rudely bridled by a short columella, it must bulge in some direction and usually this is evidenced by flaring of the nostrils.

Furthermore:

Even the most radical of us must admit the prolabium has been stretched by the lip pull and valuable tissue gained even if the prolabium is unattractively wide. . . . A natural distance between philtrum columns is actually quite narrow. Thus, an unattractively wide prolabia must be reduced and should be made to "fork up" the needed columella tissue.

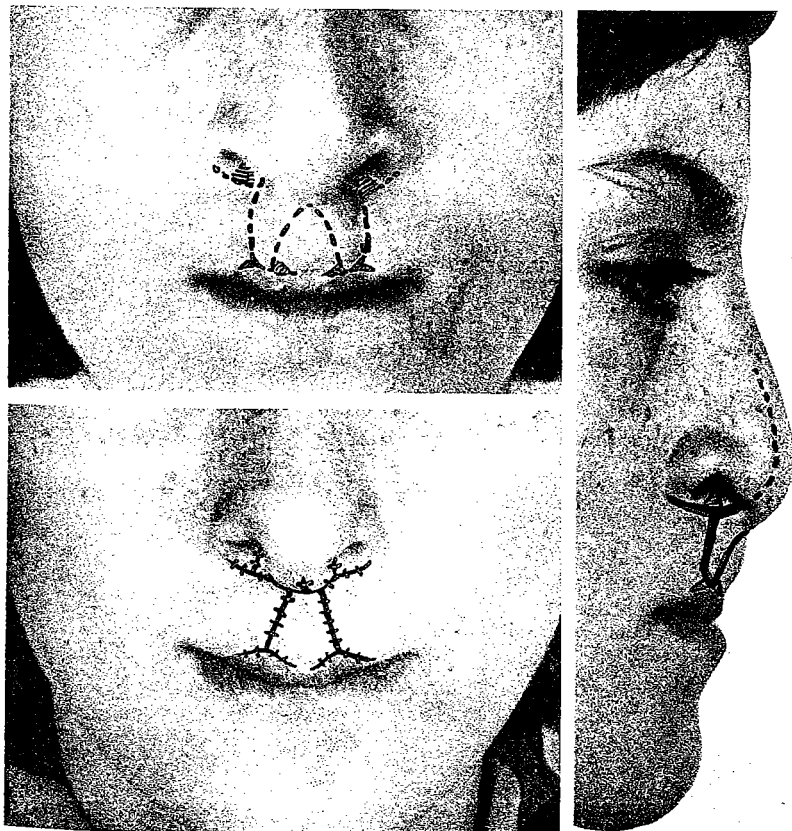
It was reasoned, however:

To take the columella flaps out of the heart of the prolabia in the usual [Gensoul-Brown] manner merely adds another insult to the upper lip and places it in the unnatural position of a midline scar.

Thus, for the common type of secondary deformity seen in bilateral clefts (prolabium wide, nasal tip spatula flat, alae flared and columella extremely short), an inverted V flap forked like the fangs of a serpent was proposed, the logic being:

Why not include the bilateral cleft scars and as much prolabia in each prong of the flap as will give sufficient body for a columella and still leave a natural looking philtrum?

The use of this flap in secondary cases without adding new scars merely improves the original bilateral scars, as seen in the design published in *Plastic and Reconstructive Surgery* for November 1958:



Further description of the procedure was included:

These flaps are skin, muscle, and scar and run smoothly into the true columella at its base. The original columella is then freed from the septum by a piercing incision in the membranous septum which is carried up along the nasal bridge for about an inch. At this moment, the tip of the nose comes really free and sits up smartly. From this position, the flat alar cartilages can be trimmed for a neater tip. Then comes the process of closing the fork which merely entails folding the wings together, suturing them to each other and fixing them in their new and exalted position along the septum. The midline seam in the inferior portion of the new columella will pass unnoticed.

Actually, the two flaps mold into a columella with greater facility than one larger flap, which tends to resist being forced into a hemi-column. The distal extremities of the forked flap are used but not sutured, so they splay laterally as columella bases flowing into the nasal floors as nostril sills.

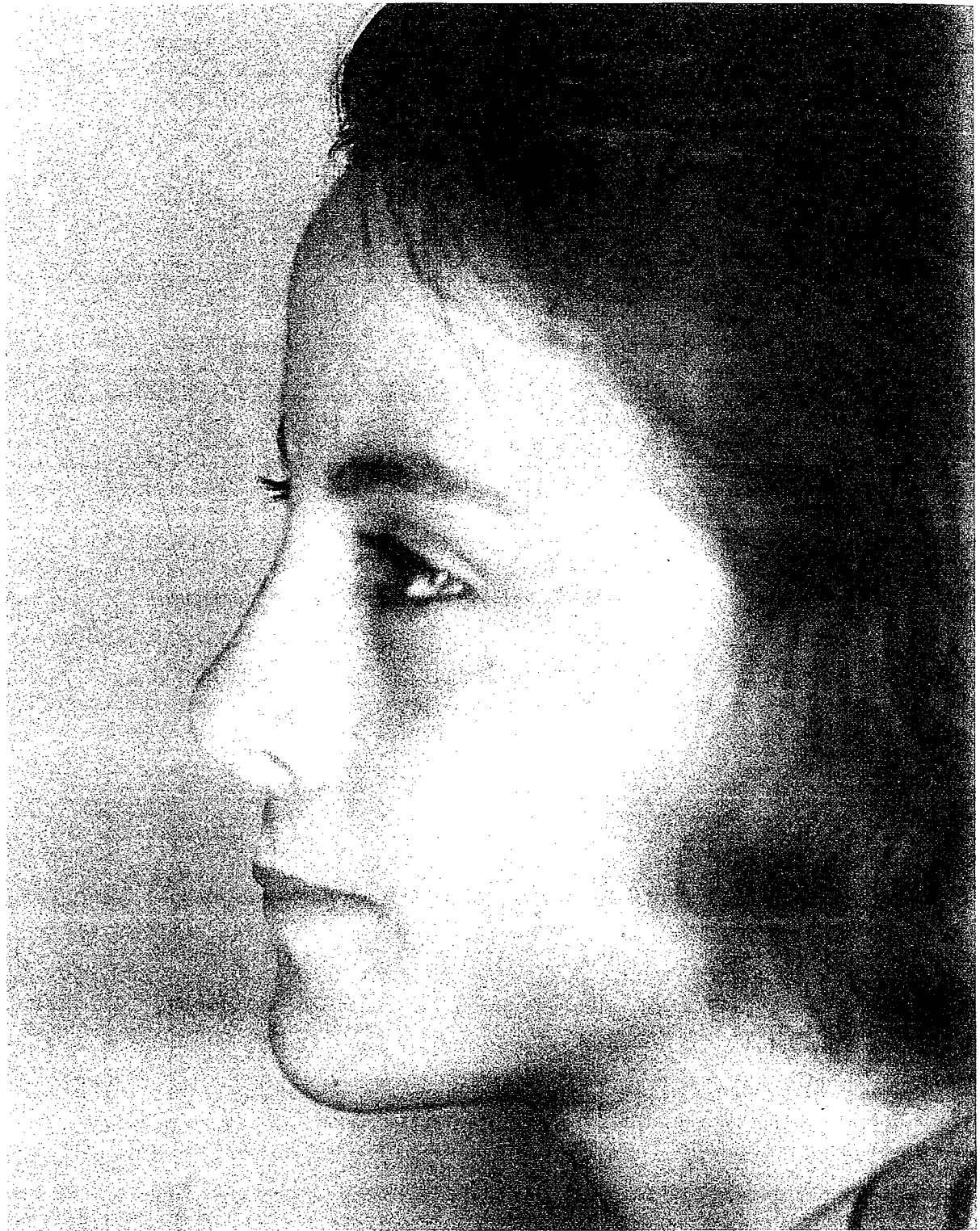Further detail included the following:

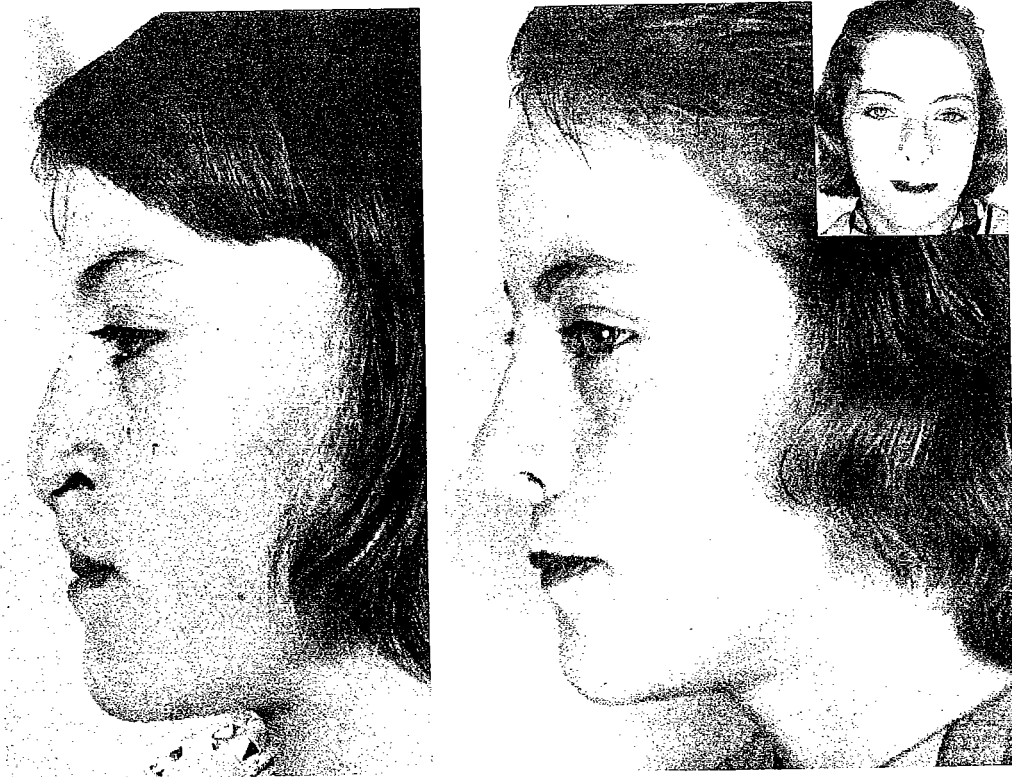Small wedges from the flaring nostril floors and short relaxing lateral incisions under each alar base will allow the lateral lip elements to be advanced medially and joined to the reduced prolabia to make a far more pleasant and natural looking philtrum. This process will also bring about an eversion of the upper lip and in principle is similar to the advancement of the lateral lip element in the radical rotation method of unilateral cleft lip.

If the extremities of the forked flap have been made pointed and extended into the vermilion, direct advancement of the lateral lip elements will achieve good closure. If the ends of the fork are flat and stop at the mucocutaneous junction, the vermilion border will have to be advanced medially on each side along the inferior border of the prolabium to facilitate the closure. There is then the possibility that an excess of vermilion mucosa humping in the midline will be available to correct a whistling deformity or even to create a tubercle.

This approach had a better answer than the Gensoul position to the invariable question of the chance of a mustache on the columella:

Even in the adult male there is usually an area along each of the bilateral lip scars which is sparse enough of hair to serve as a respectable columella.



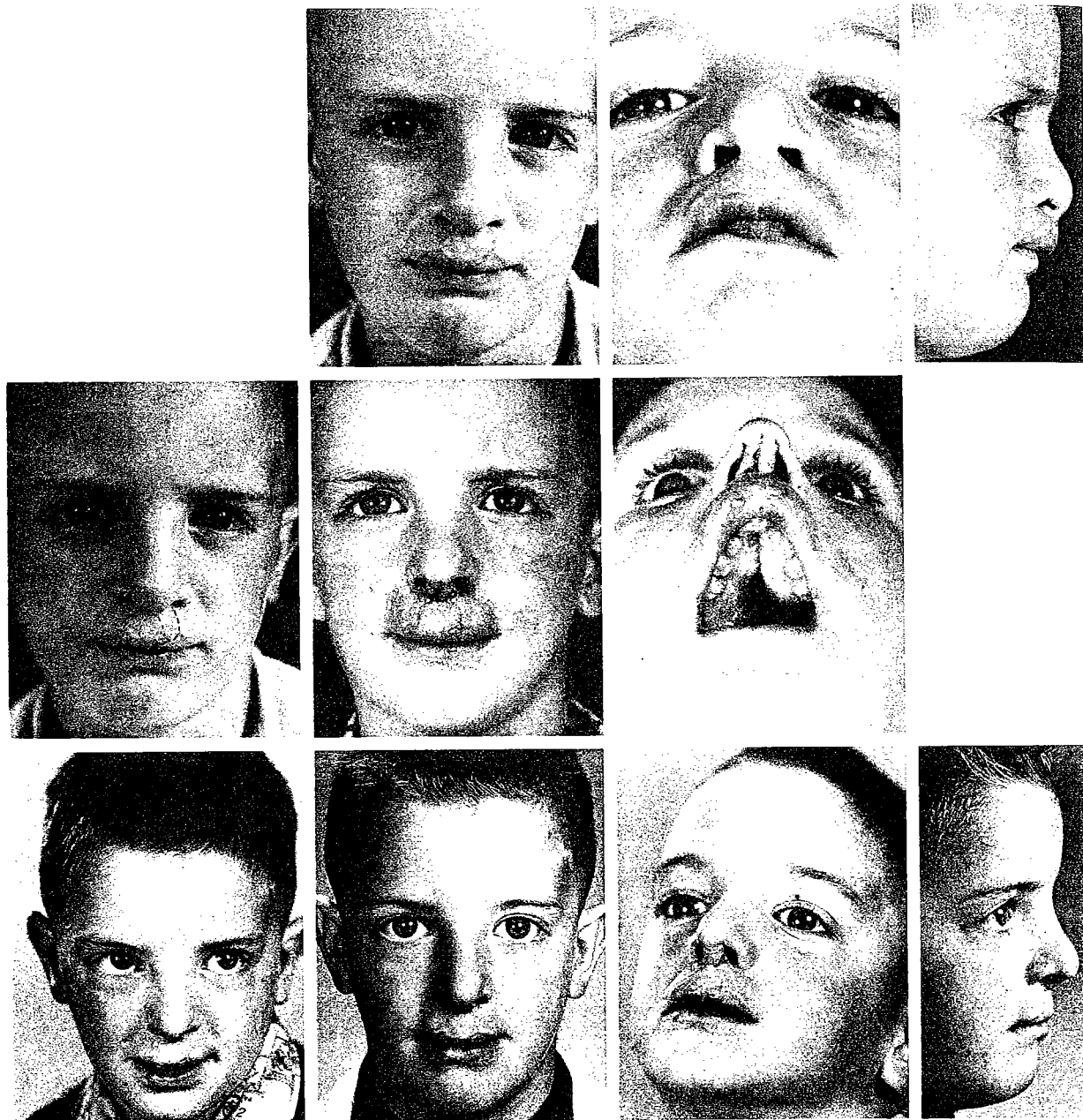


It is incredible how much additional columella skin is required to perk up this type of round nose and, at the same time, avoid kinks just under the tip or that unnatural flatness of the tip itself. During the original planning of the long two-pronged flap, it was considered a certainty that an excess would be discarded. Out of principle, nothing was trimmed, and by the time the flat tip had been uncoiled and the nasolabial angle first created and finally deepened to 120 degrees, there was not one millimeter of excess. It is little wonder that flaps taking only one-half or two-thirds of the vertical length of the lip or depending on the width of the flap for lengthening are in many instances found short.

It has been a source of pride that during the 1959 International Plastic Surgery Congress, held at the Royal College of Surgeons in London, the elegant and artistic John Conley of New York recalled:

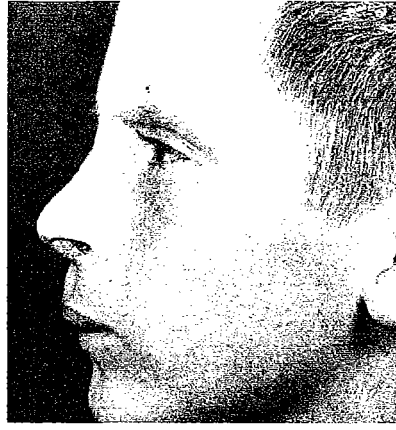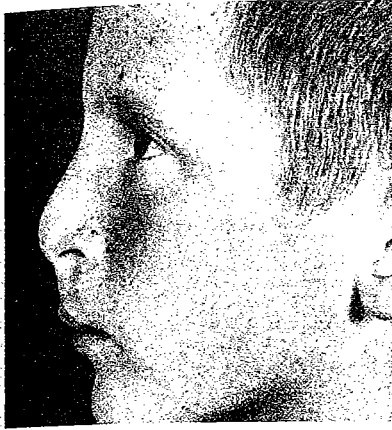There was spontaneous applause twice during the Congress. Once at a lovely ear reconstruction by Rad Tanzer and again at the result of that young girl with a forked flap.

In April 1969 this secondary forked flap case was published in *Plastic and Reconstructive Surgery*:

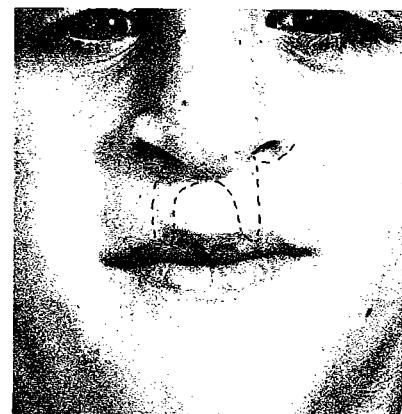
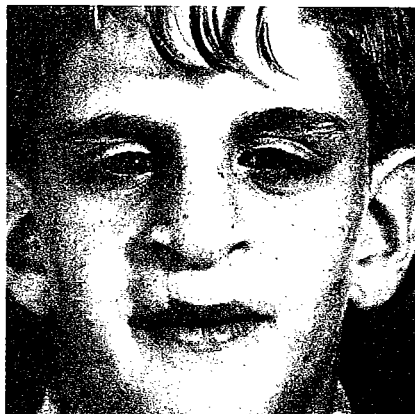
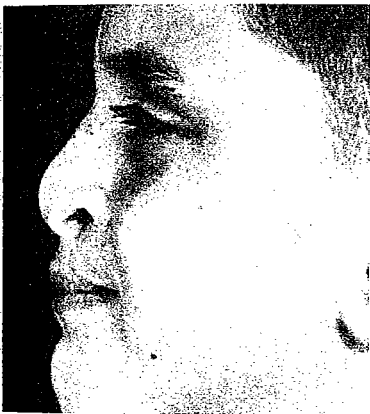It emphasizes the insatiable need of the short columella, requiring a forked flap with its prongs taken from the full vertical length of the lip.

Another dividend of the forked flap, besides lengthening the columella and releasing the snubbed nasal tip, has been improvement in lip conformity and the creation of a more natural nasolabial angle. It can also be used to help narrow a wide lip.

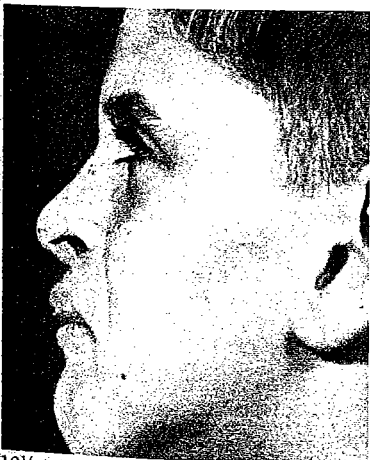

A bilateral cleft lip and palate was closed by L. W. Schultz of Chicago with his method of joining the muscles behind the prolabium. This resulted in a well-functioning lip which, surprisingly, spread to quite a wide central segment. Of course, the columella was short, the alae were flared and the nasal tip was flat.



10 years

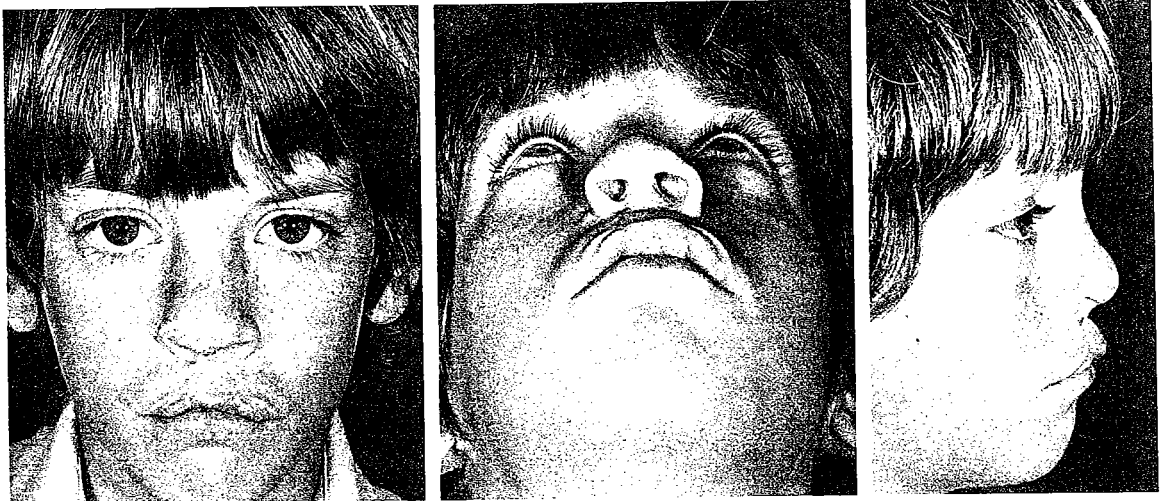
A forked flap, taking portions of the prolabium and the bilateral scars, achieved columella lengthening, nasal tip elevation and reduction in alar flare.



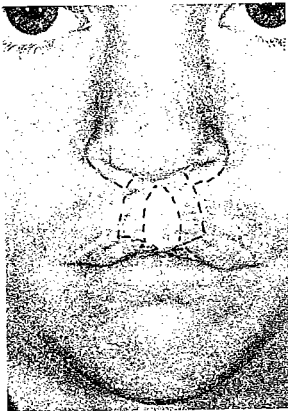
10 1/2 years

Even after adequate columella lengthening and tip release the prolabium was still wider than ideal philtrum dimensions.

Here is an eight-year-old boy with a prolabium that forms the entire central segment of the lip. Not only is it too wide, but the columella is short, the nasal tip is depressed and the alar bases are flared. This is a natural for a standard forked flap.



8 years

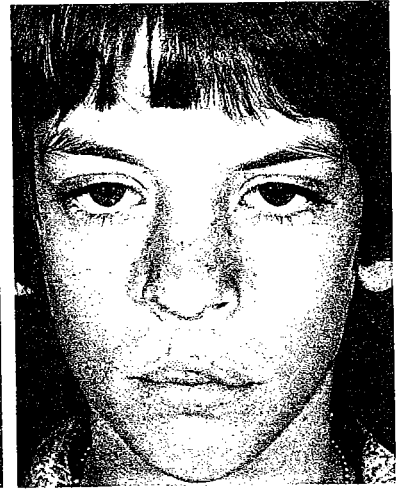
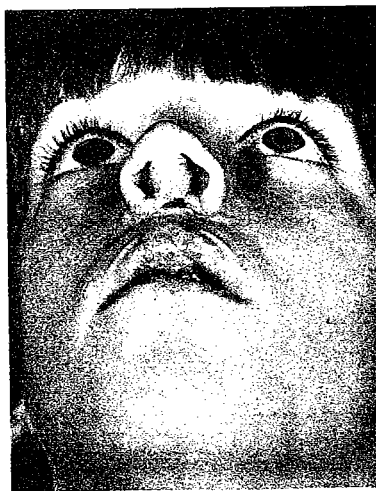

A forked flap including prolabium and scars was advanced along the membranous septum. The alar cartilages were sutured to each other in the tip. The forked flap, sutured and tubed on itself in the upper 1 cm., was sutured to the membranous septum but allowed to splay at the bottom as columella base joining alar base flaps to form nostril sills and reduce flare.

Free border vermilion side flaps were tucked behind a turn-down flap of prolabium vermilion to create central tubercle fullness.



2 weeks postoperative



2 months postoperative

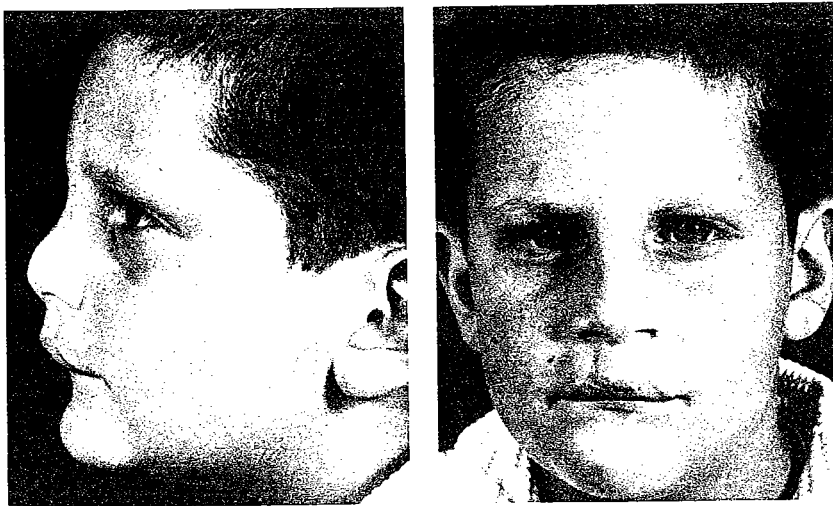
Fourteen months after use of the forked flap, double-breasted vest scar revisions were made and a columella-thinning procedure was done.



9½ years

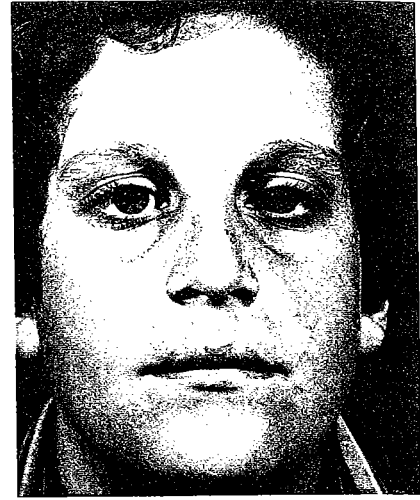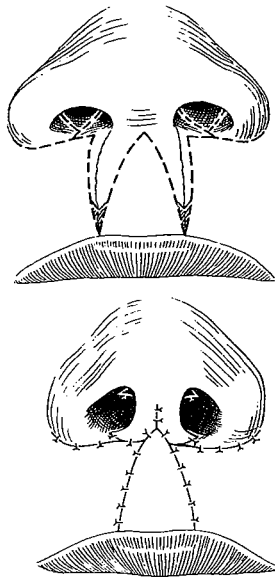
From 8 to 18 years of age there is often an angriness in the healing of scars, but in time they usually settle and smooth out.

This bilateral cleft lip and palate had closure of the lip in New York by the conservative straight-line approximation of the lateral lip elements to the sides of the prolabium. By five years of age, the prolabium had spread to a wide central component, and, of course, with the short columella, the nasal tip was snubbed. Original preservation of a cuff of prolabium vermillion in front gave a segmented effect to the visible vermillion.



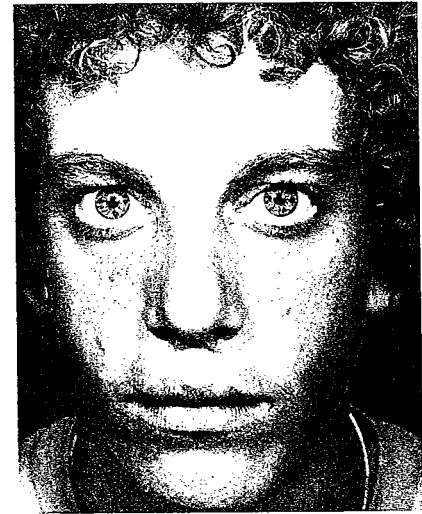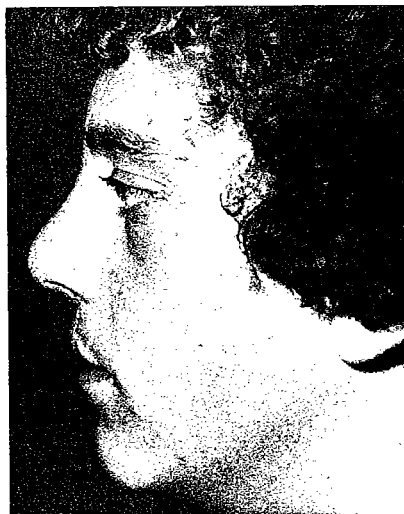5 years

Excision of most of the prolabium vermillion at least smoothed out the central red area of the lip, but columella lengthening was postponed to see what growth alone would do to the nose.



14 years

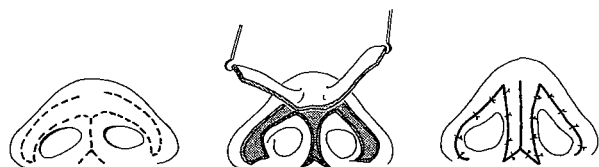
At 14 years, the nose was still showing a flat nasal tip, so a forked flap was used to lengthen the columella and narrow the philtrum. Through the forked flap exposure, a modified nasal reduction lowered the bridge, shortened the septum and reduced the alar cartilages. The patient then proceeded to heal with the typical angry teenage scarring, but as time has passed, the scars have begun to settle.



16 years

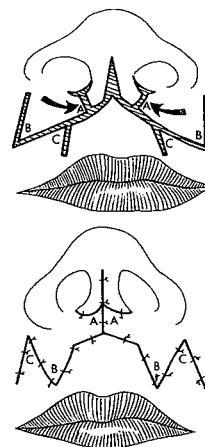
Further nasal and lip revision including a septal cartilage strut in the tip will be carried out as soon as the patient expresses the desire for further improvement.

When I described the forked flap to Sir Harold Gillies, he was pleased with the principle and said it was the reverse of his alar wing flaps.

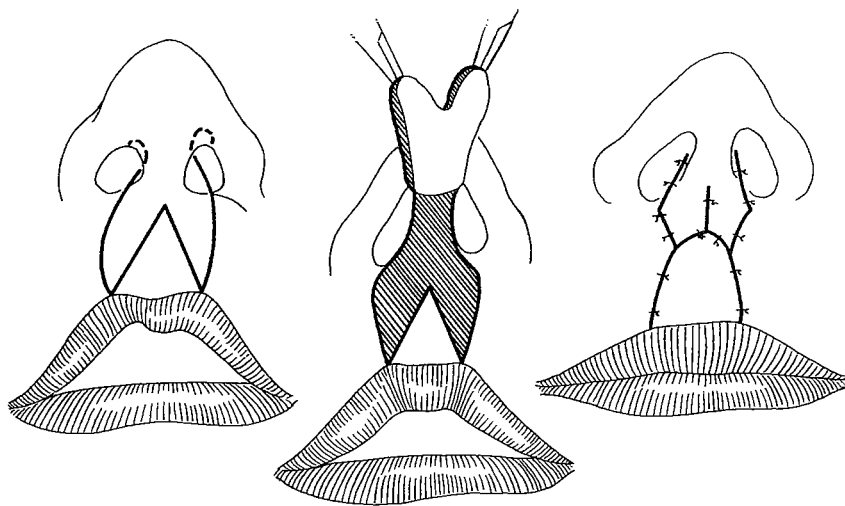


Neither Gillies nor I associated the forked flap with the early example of the "scrambled Z," a frightening case operated on by Gillies which we included in our book section on cleft lips, warning that such radical surgery was not advised as a routine. It had called upon a double Z of the lip which moved the alar bases in and gave less than half the vertical length of the lip as advancement flaps into the columella. Initially horrified with such random chopping of the lip, I had put the case out of mind. Yet, upon reflection, one must note that the upper portion of this puzzle of cuts might be a distant ancestor of the forked flap.

While attending an International Congress in Bratislava in 1965, I learned that the grand old man of Prague, Professor Frantisek Burian, was also using a secondary columella-lengthening procedure similar to my forked flap. The language barrier blocked our discussing the method, and it was not until 1968 that his book written in English diagramed his general procedure.



Frantisek Burian



His release over the tip of the septum was not enough even though he did suture the alar cartilages together. The advancement of his flaps did not go completely into the columella, for the lower one-third remained in the lip, with penalties to both the lip and the nose.

EARLIER USE

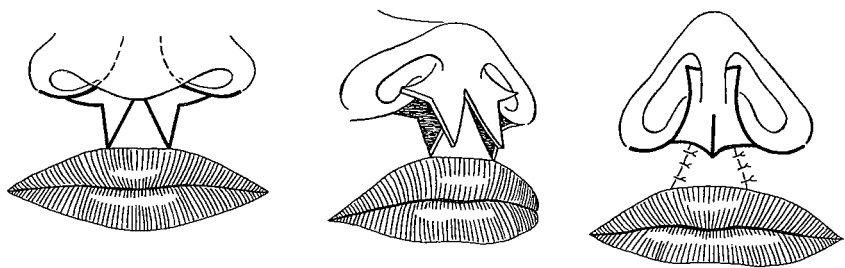
By 1958 I had adapted the forked flap for use as a delayed primary columella lengthening (four months of age) and I presented the design at the 1959 International Congress in London. My original diagrams for this new use outlined shorter pointed flaps, which, as it turned out, were too short for adequate columella lengthening in the typical bilateral complete cleft.

In 1972 Kurt Schneider of Zurich, fresh from a visit to Charles University, Prague, came to Miami for a Maytag fellowship. Informing me of the international misunderstanding about the forked flap, he obtained for my enlightenment an article written in 1960 by H. Peskova and M. Fara of Charles University. Evidently these two had hastened into the literature on behalf of their leader, Burian, who until then had said nothing about this columella lengthening. In the Prague clinic for years, as they reported in 1960:

The columella has been lengthened by using the sides of the philtrum, including the scars, and making use of excess tissue from the nasal threshold.

They diagramed a forked flap of about the same measly proportions as my 1959 design for early use in infancy but added Brown's horizontal

short spurs from the base of the nose.



It is noteworthy that in the same paper they mentioned Burian's preference, in severe deformities, for external incisions through the alae and advancement of the dorsal skin of the nose for columella lengthening. It is also interesting that in his final 1968 book Burian's description of the forked flap was quite unlike their rendition.

As I have never been to Prague and had no idea what they were doing behind the then more rigid Iron Curtain, and as there had been no publications on the subject, even in Czech, little remains to be said. The same thing has happened many times in history; more than one person comes upon an idea—and often almost simultaneously as though the specialty had progressed to the point where this was the next logical step. It is almost ironical that the identical “come lately” claim was made with the tube pedicle. As J. P. Webster noted in 1959 after extensive research:

In 1916 and 1917 three surgeons, independently, recognized the value of closing the parallel skin edges of open pedicle flaps by suturing them together to form tubes.

They were Filatov of Russia, Ganzer of Germany and Gillies of England. It was rumored, subsequently, that Burian of Prague had done it before any of the others but, again, without establishing the fact by publication in the world literature.

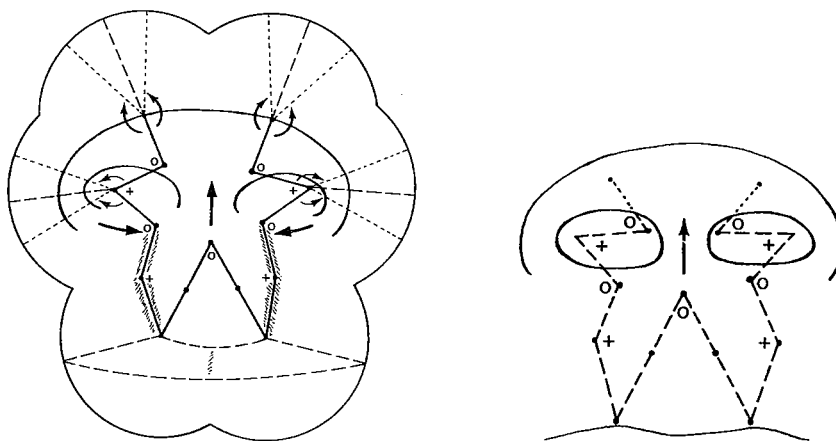
It is unfortunate, if indeed Burian favored the fork, that he did not publish his work. Yet, setting aside priorities for a moment, let me say again, the principle is a good one and its staged primary use will eventually supersede its value as a secondary procedure.

In 1963 Alexander Limberg of Leningrad, in his book *The Planning of Local Plastic Operations on the Body Surface*, gave a mathematical dissertation on the forked flap (Millard, 1958) but adding lateral triangular extensions at the columella base as described for Gensoul by Blair and Brown and for the forked flap by Peskova and Fara:

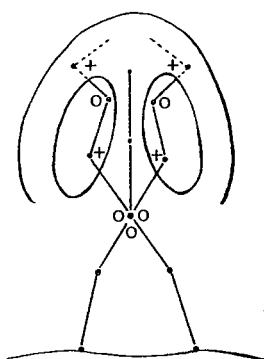
After plastic reconstruction of the lip for congenital bilateral cleft, as a result of growth the child after 8–10 years usually shows some surplus of the tissue in the central portion of the upper lip. This surplus may be well utilized in plastic operations for lengthening the columella. . . .

From the base of the short columella, downward, there extend two diverging incisions, outlining a symmetrical triangular flap, which is kept in the central portion of the lip. The external incisions, forming lateral flaps in the upper lip, are kept if possible in the area of the scars. . . . It is sufficient to add one more component part to the incision in the direction of the lateral surface of the columella.

In the 1966 *Modern Trends in Plastic Surgery* Limberg, with the aid of this paper model, demonstrated mathematically the effect of shifting the forked flap with its opening and closing of angles producing lying and standing cones.



All 14 components of the incision are of equal length and each is equal to half the depth of the upper lip. Two flaps of lip skin, which include the harelip scars, are raised in continuity with the short columella. The advancement of the lateral margins of these flaps is made possible by an additional three-limbed incision along the lateral surface of the columella. The five lateral components of the incision may be regarded as two sets of asymmetrical triangular flaps with unequal angles of 60 and 90 degrees and 120 and 150 degrees, one lateral limb of each being superimposed. Extensive undermining allows the flaps to be moved into their new position.



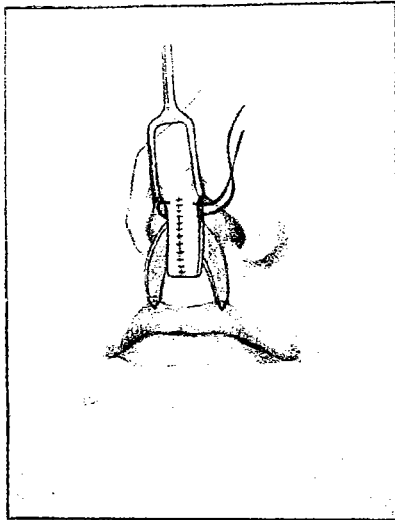



STARK AND OTHERS CONCUR

It was interesting that in 1964 Stark and Washio from New York's St. Luke's Hospital endorsed the forked flap. Later, Stark in his 1968 book summed up the situation and demonstrated a very nice result:

The classical postoperative defect in bilateral clefts of the lip is the overly wide prolabium, the snub nasal apex with short columella, and wide nostril floors. The forked flap columellar advance operation of Millard is ideal to correct all the aspects simultaneously.

At Schuchardt's 1964 Hamburg Cleft Palate Congress, I again presented the forked flap showing a new set of diagrams. A suggestion was made for improving the results with this principle:



It is important to avoid the depressed notching in the new columella just below the nasal tip, noticeable in profile. This is achieved by suturing the flaps of the fork together in front. They are then rolled together in the upper portion (1 cm.) and sutured gently in a loose tube. This portion must not be sutured to the septum but allowed to ride up freely while the lower portion of the lengthened columella is sutured to the septum.

At the same Hamburg Congress, Professor Gerhard Steinhardt of Erlangen-Nürnberg University expressed his dislike of the Gensoul approach and his endorsement of the forked flap, quoting logic from my 1958 paper and adding:

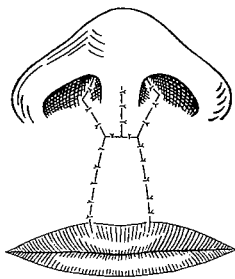
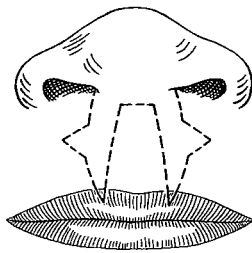
The procedure will also bring about an eversion of the upper lip and elevate the anterior part of the nose simultaneously. We have good results with this modification. . . . What I want to say, in short, is an old request: we should avoid secondary scars as much as possible in cleft patients.



Gerhard Steinhardt

The gentlemanly Steinhardt spoke with cicatricial authority as he himself has a "handsome" dueling scar on his left cheek, received while a student at the University of Heidelberg in the 20's. In Germany, prior to World War I, such marks were a proof of valor.

After Steinhardt finished, Gerhard Pfeifer of Hamburg University rose to give a modification:



Bilateral scar flaps are suitable for prolonging the columella as Dr. Millard and Dr. Steinhardt have just pointed out. In some cases it may be useful to leave a triangle of skin on either side that goes into the incisions at the nasal sill. This incision has to be made to bring up the tip of the nose. . . . The triangles mentioned comprise, furthermore, all extensions of Z-shaped incisions of primary operations and transform the linear scar into less noticeable smaller ones.

During that Hamburg Congress E. Schmid of Stuttgart revealed that he had been using the forked flap for some time and showed a couple of improved columellas.

Over the years, the forked flap has gained in popularity. It has been adapted to unilateral use and modified in shape, size, position of placement and methods of banking. As Mark Gorney stated in reference to his support in bilateral cleft nasal correction:

The gull wing graft can be combined with almost any procedure you may choose. If added columellar length is needed we use a forked flap or one of the other refinements.

Tessier's 1969 suggestion of selectivity for this procedure is partly correct:

no!

The Millard procedure, or forked flap . . . consists of using, not the central part or totality of the prolabium itself, but its edges and adjacent scars. It presupposes good continuity of the orbicularis, and a wide prolabium without transverse scars. The two flaps should reach the mucocutaneous border. Lengthening is less than that obtained with the three-leaved flap; on the other hand, the scars on the lip blend in well with the philtral ridges and the philtrum takes on a pleasing triangular allure.

In 1971 even Tom Cronin, although he usually used the skin

from the floor of the nose and part of the alae for columella lengthening, admitted:

Occasionally, I have used the forked flap, especially if bad scars of the lip needed excision and revision.

I recall with pride that as early as 1959 Reed Dingman personally expressed his appreciation of the method. This specific high level endorsement meant very much because Dingman in his typical kind fairness helped me to withstand some of the oblique political flack that was still flying at that time. Then as late as the 1973 International Cleft Palate Congress in Copenhagen, Hugo Obwegeser stood in open forum and in his typical authoritative style declared:

In my hands Millard's forked flap absolutely is the best procedure for elongating the columella.

After full consideration I did not rise to argue the point.


VARIOUS USES

As has been discussed in primary bilateral cleft surgery, the forked flap has been used in numerous ways. It also can be modified for special problems.

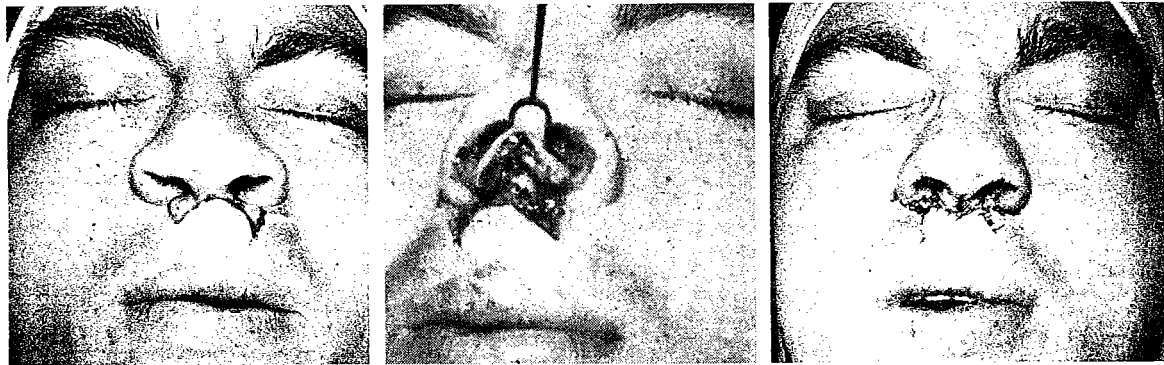
Modified short fork

Many postoperative bilateral cleft lip cases with a tight upper lip and only a moderately short columella are treated merely with a lip-switch flap. The meager scarred prolabium, which had proved to be inadequate in the lip but could have served in the columella, unfortunately has been scrapped, necessitating a secondary scramble to make up for this waste. A modified shorter fork can be of value, taking the scars and tissue from the Abbe flap or lateral to it. Here are two personal examples.

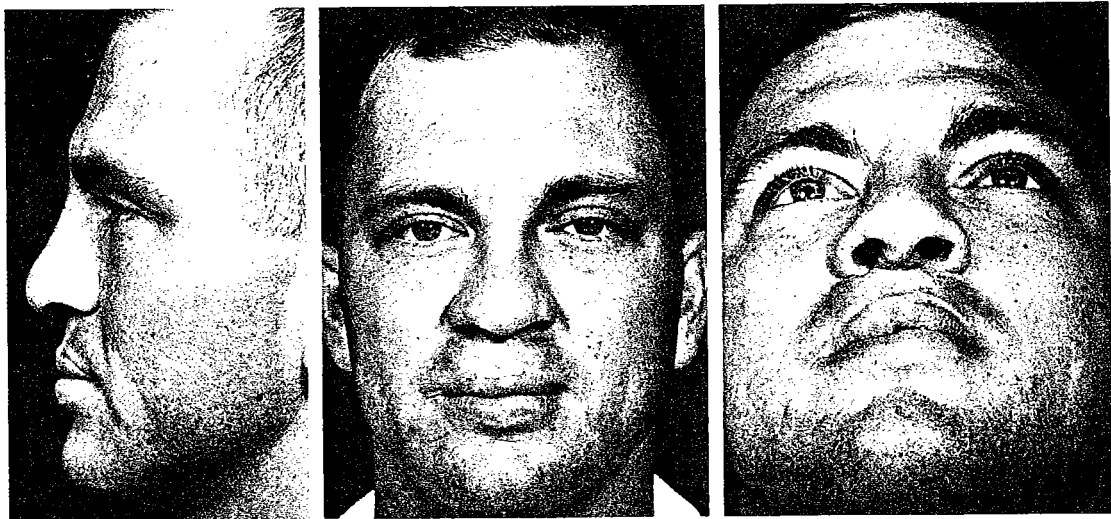
This young doctor had his bilateral cleft lip treated secondarily with a W-shaped Abbe flap which was most un-philtrum-like in its spread at the top. Then, too, the columella was short and the alae were flared. Unfortunately, the prolabium had already been discarded!



Scrutiny soon showed what he had that he could spare to help his columella. A short fork was taken from the scars and the upper excess of the Abbe flap.

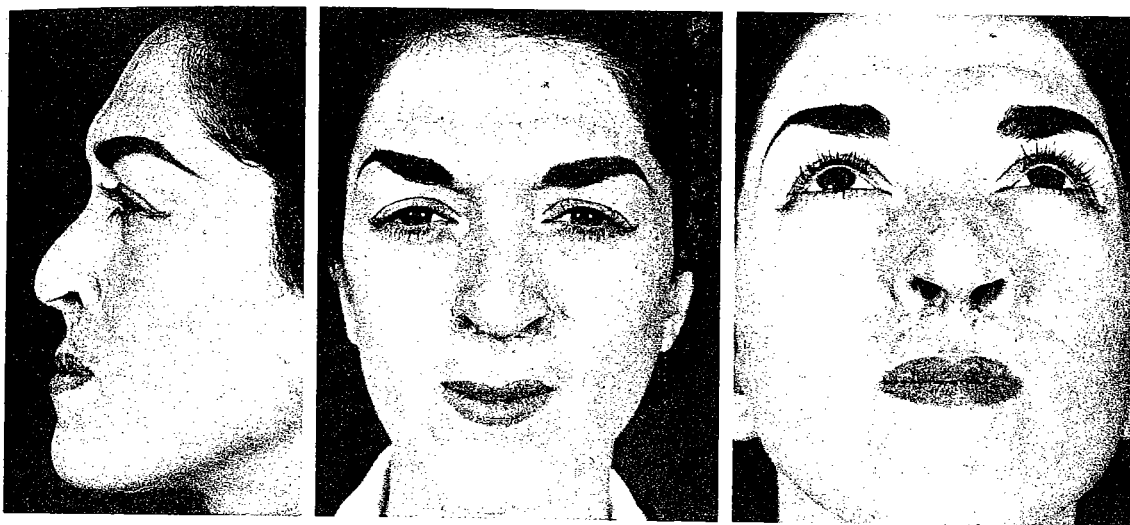

The operative stages of this short fork were published in *Plastic and Reconstructive Surgery* in 1963.

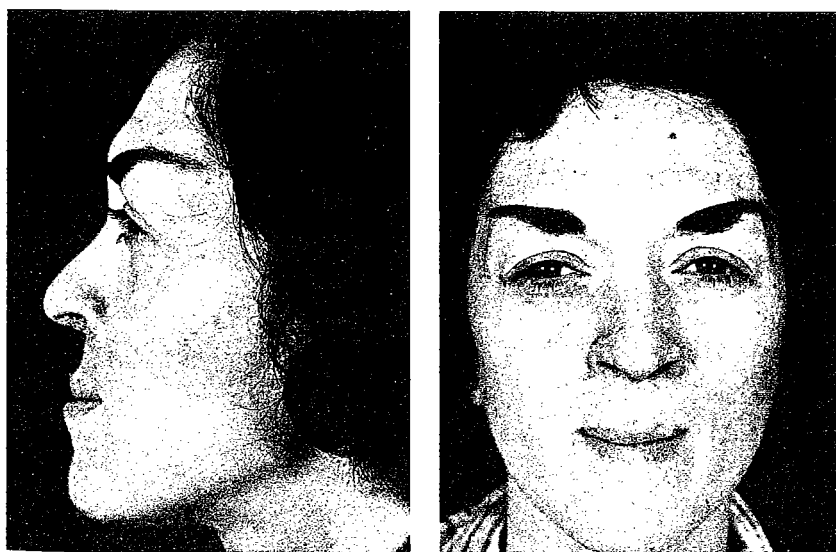

This maneuver shaped the philtrum and released the nasal tip. The reentrant nasolabial angle could have been improved, had the patient desired, by the Cinelli septal flap or by the lozenge-ellipse advancement described in Chapter 47.

The patient shown below with bilateral cleft lip and palate was first seen at age 27 after 34 operations, including check-relaxing incisions and an Abbe flap. The lip scarring was severe, the columella short; the alae were flared and the nasal tip was hooked like a hawk's beak.



A half-length forked flap, incorporating the scars on each side of the Abbe flap, lengthened the columella and released the tip. Abrasion of the lip scars gave some improvement.

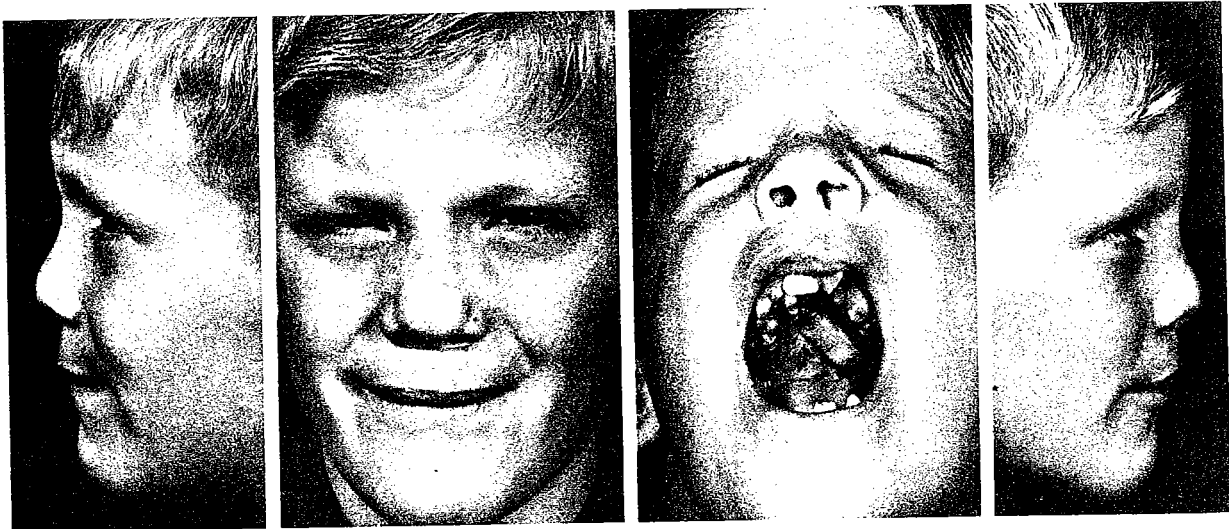


Further nasal and labial work was done, but, as so often happens, the patient moved away before records could be made.

A three-quarter-length forked flap

In certain cases, when the prolabium has been incorporated in the upper part of the lip and lateral lip flaps have been brought together below it, the lip may not be too long and the nasal tip may be only moderately depressed. Yet there is a subtle discrepancy due to the prolabium fullness in the superior part of the lip, with relative tightness in the lower portion and only slight snubbing of the nose. Here a three-quarter-length forked flap reducing the sides of the high prolabium can be of benefit to both the lip and the nose.

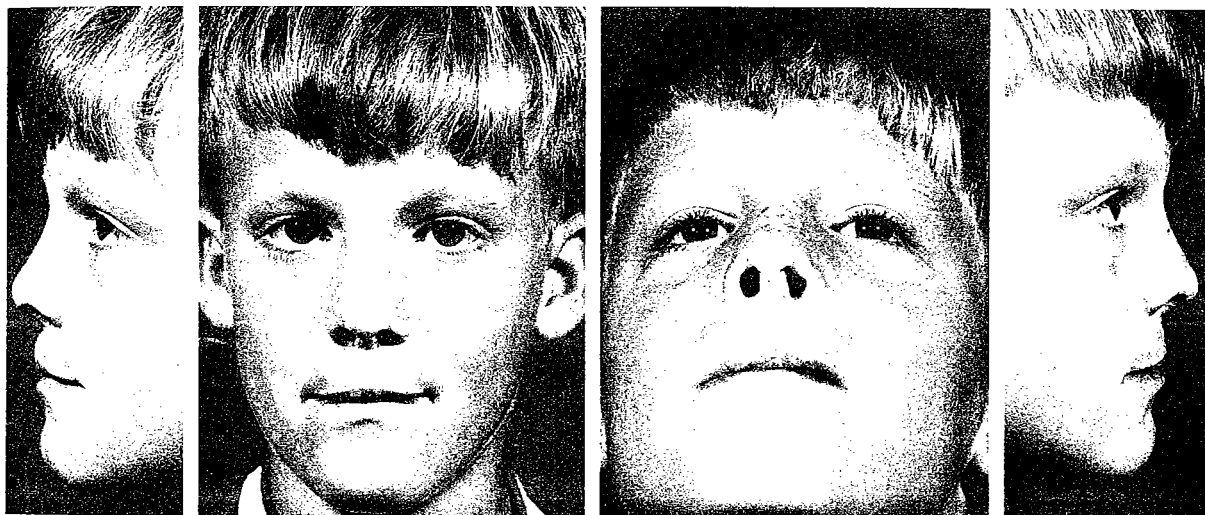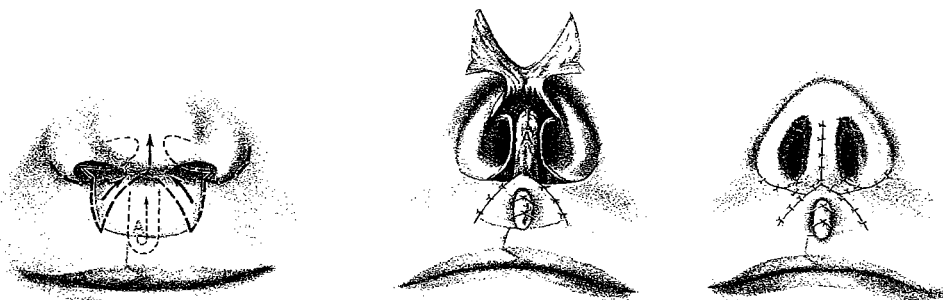
An asymmetrical bilateral cleft of the lip and palate was treated in Washington, D.C., in two stages with composite skin and vermilion flaps introduced below the prolabium. The operation resulted, by age six years, in an asymmetrical nose, depressed nasal tip and a lip with transverse scars and bulging central prolabium but reasonable vertical length.



6 years

At eight years, a left alar base flap was transposed across the nostril floor to create a sill, and a vermilion V-Y was used to create a tubercle. Three months later, a three-quarter-length forked flap was elevated out of the lip and advanced along the

membranous septum with excellent tip release but obvious columella retraction. Thus a subcutaneous flap superiorly based was carved out of the center of the bulging prolabium and turned up to lie on the membranous septum increasing columella contour in profile. The resultant depression in the center of the prolabium improved its philtrum appearance.



11 years

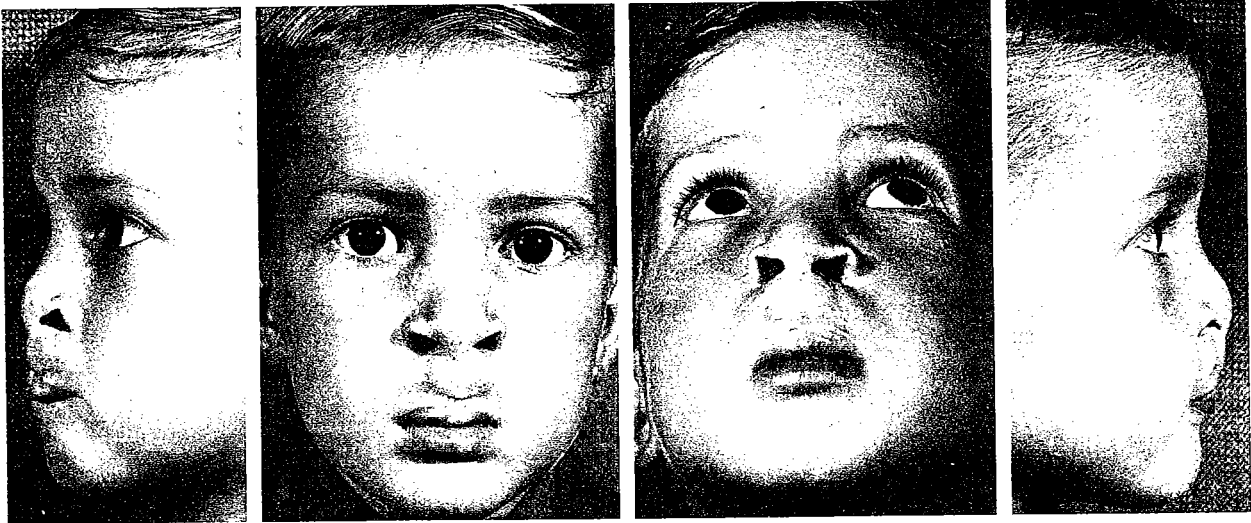

15 years

Return inferior flaps for later forked flap

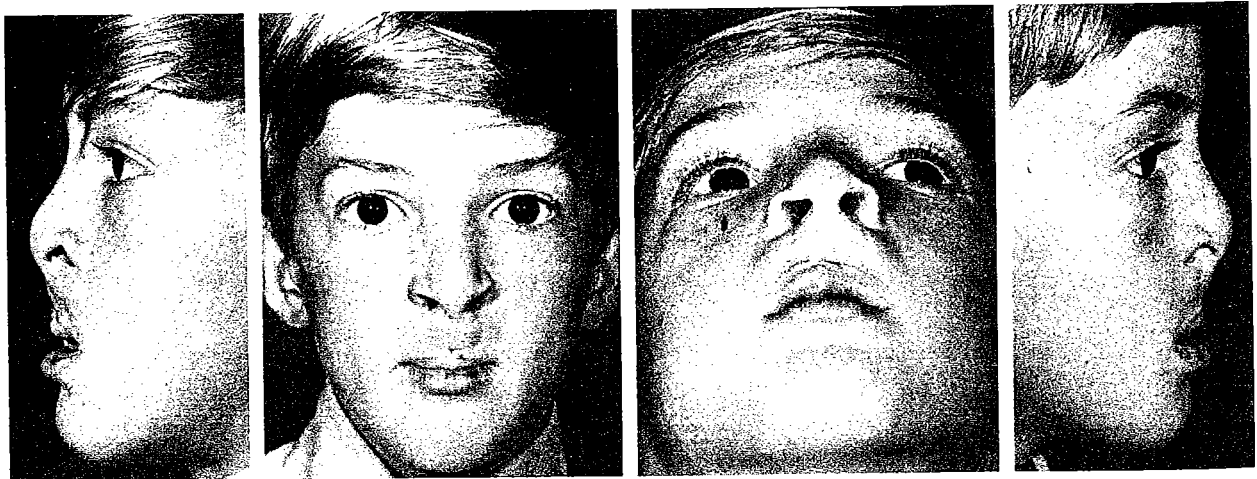
Even when all seems lost and tissue usually allotted to the forked flap has already been stolen and stuck below the prolabium, it can be retrieved. Merely steal it back, reposition it where it came from and then later incorporate it as a forked flap (see Chapter 53, Long Upper Lip). Here is an example.

The patient had had lateral triangular composite flaps transposed below the prolabium in infancy by a surgeon trained in the Brown school. The result at four years of age revealed a long lip in vertical dimension, abnormal position of scars, short columella with snubbed nasal tip and flaring alae.



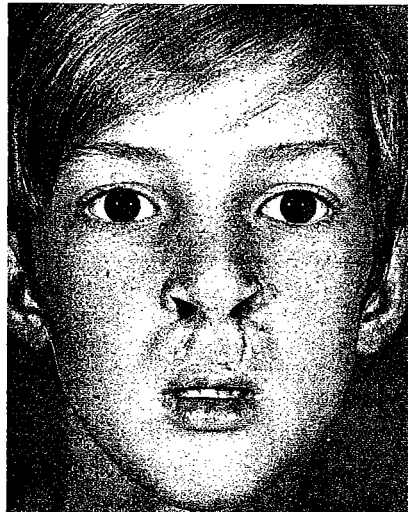
4 years

There was no improvement with time.



8 years

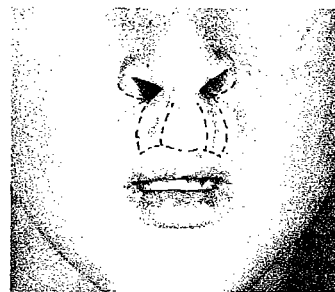At eight years the skin flaps below the prolabium were elevated and transposed 90 degrees into the bilateral vertical scars back where they came from along the sides of the lateral elements. The mucocutaneous ridge and vermillion was sutured up to the inferior edge of the prolabium.



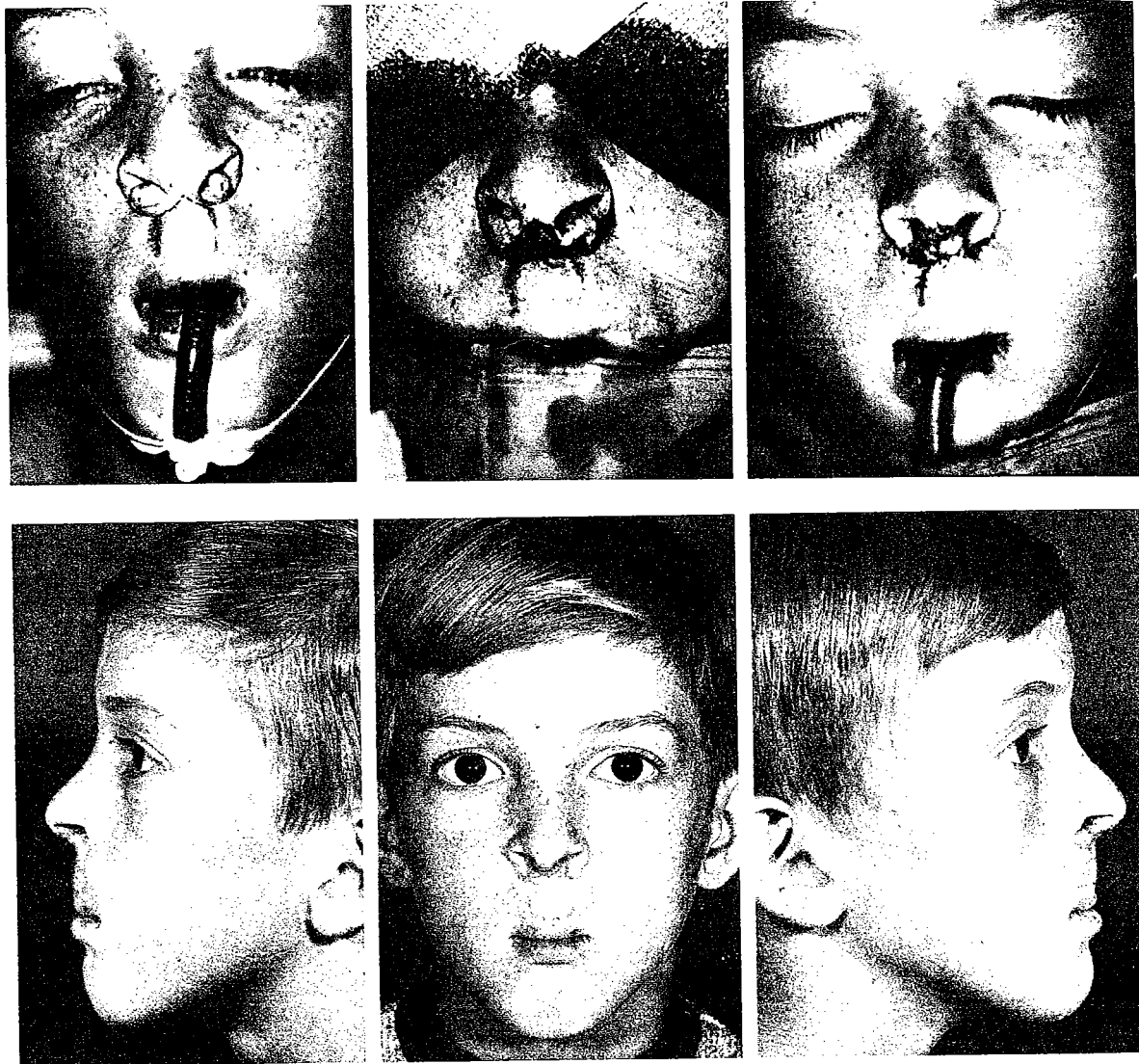
This maneuver shortened the vertical length of the lip, relieved the side-to-side tightness and replaced potential tissue into a strategic position for a later forked flap for columella lengthening.

Six months later a forked flap, incorporating replaced flaps, all scars and portions of the prolabium, was incised and elevated. The prolabium also was elevated and the lateral mucosa and muscles were sutured together in the midline. The prolabium was replaced first with a dimpling stitch and then with regular suturing. The prongs of the forked flap were banked by suturing them to the alar base flaps in a type of "praying hands" position. The patient subsequently struck his lip, with partial separation of his lip incisions. The right side was revised at the time of the next surgery.

Two months later, parallel incisions anterior and posterior to the forked flap-alar base pyramids were made, followed by partial reopening of these pyramids to form longer straps. Then, with the aid of a membranous septal incision extended laterally in the upper vestibule, the straps were advanced together medially and up into the columella. Small extension flaps cut from the upper

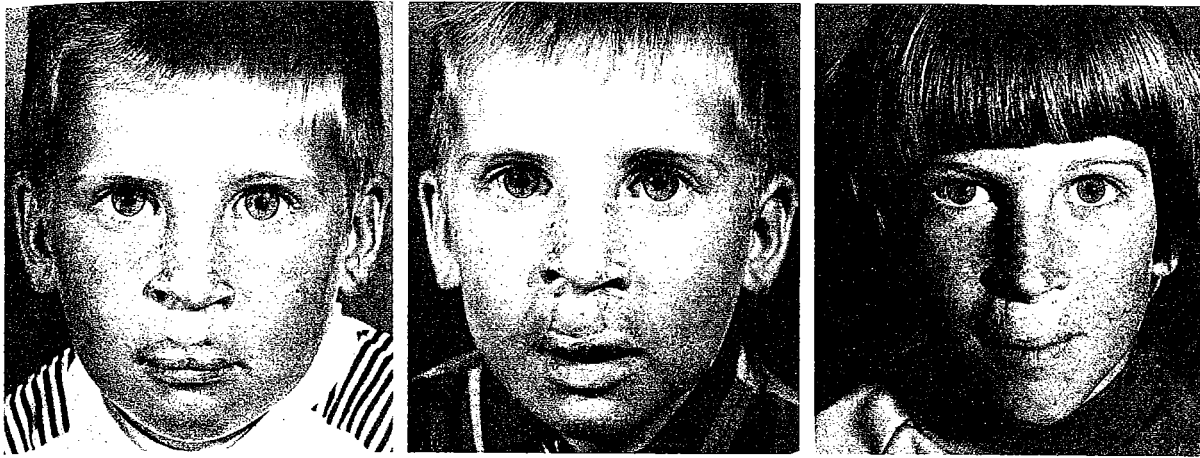

forked flap sides were let into the vestibular defects to maintain nasal tip release. Subcutaneous alar base extensions were advanced to each other at the nasal spine and fixed with a suture. Thus the nasal tip was elevated and the alar flare reduced.



Subsequently the lip was shortened in vertical length by an excision along the entire nasal base and also along the scarred mucocutaneous line as well as the vermilion free border.

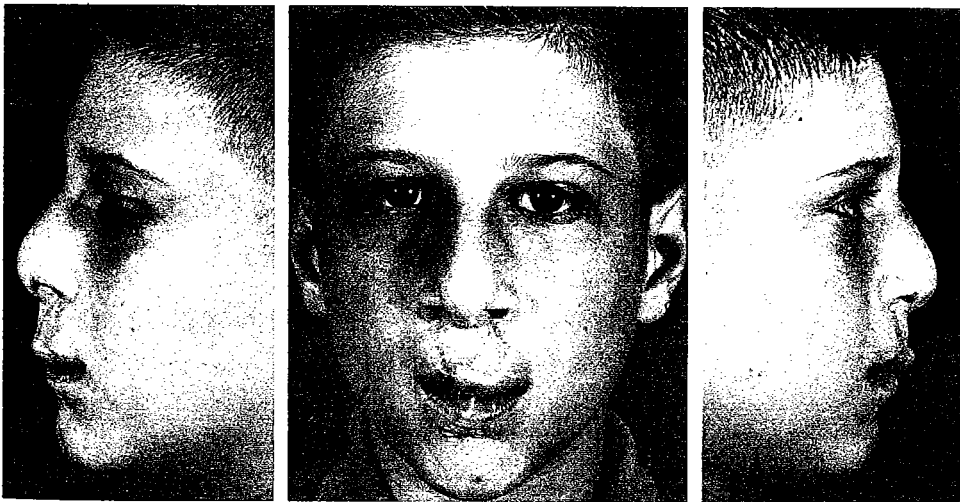Here is another example of the same type of recovery of a forked flap from skin flaps originally misplaced by being transposed below the prolabium. This case is presented in detail in Chapter 53.



Lopsided Abbe

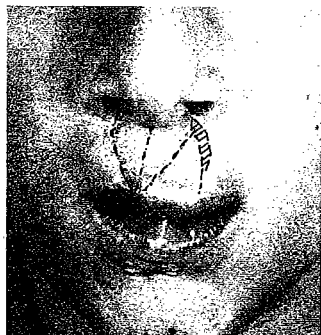Keep your cool and do not overlook the forked flap just because complete cicatricial pandemonium has displaced the usual donor area. Diagnose the short columella, the misplaced prolabium and the potential philtrum Abbe flap in deceptive unilateral position.

A bilateral cleft lip and palate patient had been treated with, among other procedures, a *unilateral* Abbe flap and presented a mind-boggling nasal and labial deformity. He had a short columella, a depressed nasal tip and a horizontal Z scar line of the lip with one limb of an Abbe, along with scarring and even stitch marks in the lower lip.



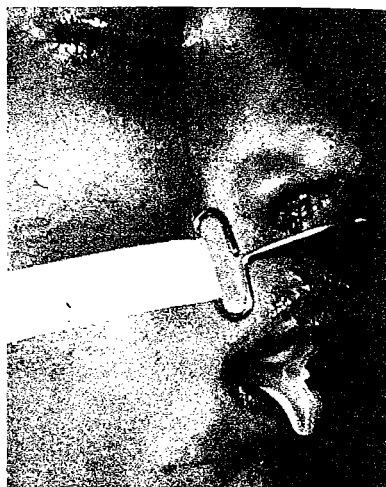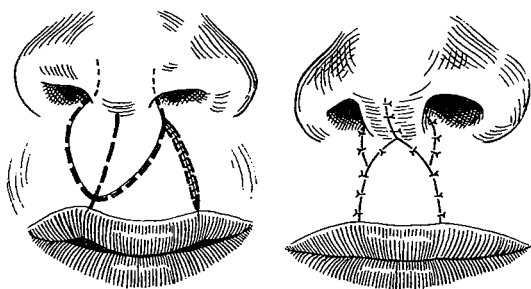
11 years

I studied and stalled for eight months but finally turned to the scalpel with one rather comforting thought: Regardless of what



was done, an improvement was almost assured.

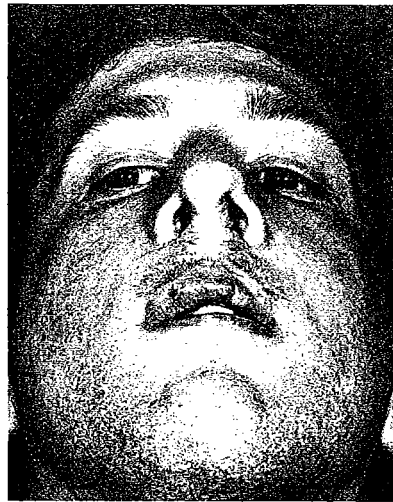
At age 12 years, the remaining prolabium on the right was elevated, split as a forked flap and advanced into the columella with nasal tip release. Then the unilaterally positioned Abbe flap, based on the vermilion free border, was shifted into the midline philtrum position. Improvement in the conformity was partly spoiled by the usual teenage scar hypertrophy.



13 years



Only after minor revisions over several years did the scars gradually improve. Then, just when coming of rhinoplasty age, the patient moved to California, and years later, at age 18 when he returned to Florida, he presented a nasal bridge reduced nicely by Bruce Connell. Further refinements were indicated. The tips of the flaring alar bases were denuded of epithelium and advanced to each other behind the columella, and slivers of septal cartilage were inserted along the alar margins.



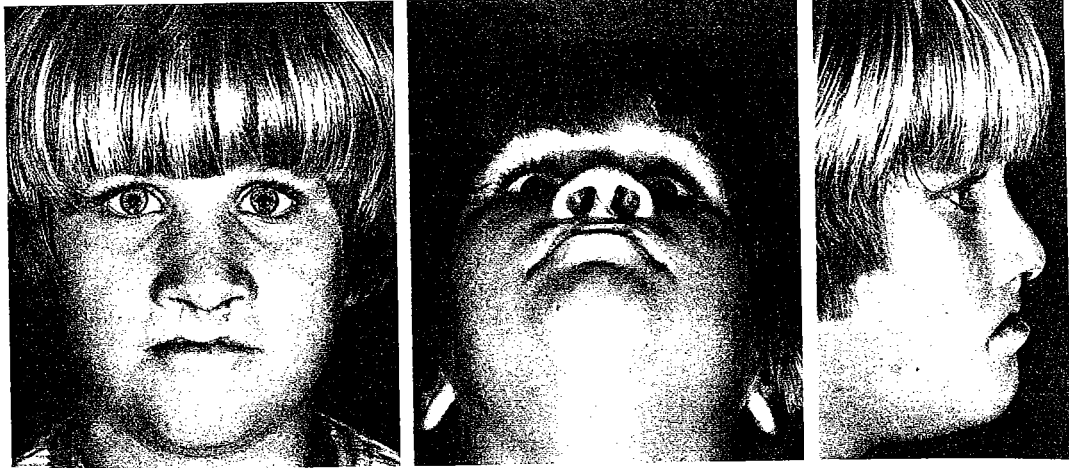
23 years



And finally he is shown as professor in the English Department at a west coast university.

Forked flap forced to crisscross

This 11-year-old boy born with a complete bilateral cleft of the lip and palate and mucous pits of the lower lip had had seven operations in one of the smaller cities of Louisiana. One procedure had been a columella lengthening by division of the short columella from the lip, and insertion of an ear graft. Unfortunately, the graft had been only partially successful, leaving some shortness but a more noticeable lack of contour. There were also flaring alae, lack of muscle in the prolabium, deficiency of maxillary platform, scars of the mucosa of the protuberant lower lip and fistulae in the anterior palate.




11 years

1. Palate fistulae were closed.
2. A forked flap was taken from the prolabium to reduce it to philtrum dimensions and included the old bilateral cleft scars. Because of the previous auricular graft to the columella, the flaps were based on the nasal floor and sides of the columella.
3. The lateral lip mucosa and muscles were joined to each other behind the lifted prolabium to create a sulcus and muscle continuity.
4. The prolabium was reset into the lip with a dimpling stitch and regular suturing.
5. The forked flap was banked under the alae in whisker position temporarily.




4 days postoperative (banking)

Six weeks after the first stage, the second procedure was carried out. Because the columella severely lacked contour and was only moderately short, the ideal "continuous flow" advancement of the forked flap had to be altered. The tip of the nose carrying any normal columella was released by a transverse incision at the join of the ear graft and extended back well into the membranous septum. Most of the remaining brown-colored ear graft was discarded. The banked flaps were reelevated and wrapped around the columella defect, one on top of the other, in the spirit of Marcks and Skoog. The effect was lumpy, but in time it can be improved. The most dramatic action was correction of the alar flare by the now standard dissection of two flaps in each alar base. The dermal subcutaneous underflaps were sutured to each other at the base of the septum, and the upper skin flaps formed the nostril sills.



6 days postoperative (crisscross)



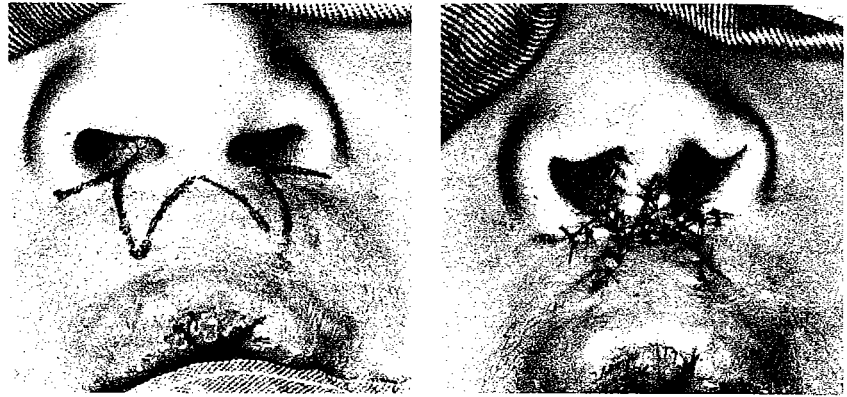18 months postoperative

Time, revision of the lower lip and other secondary corrections should bring improvement eventually.

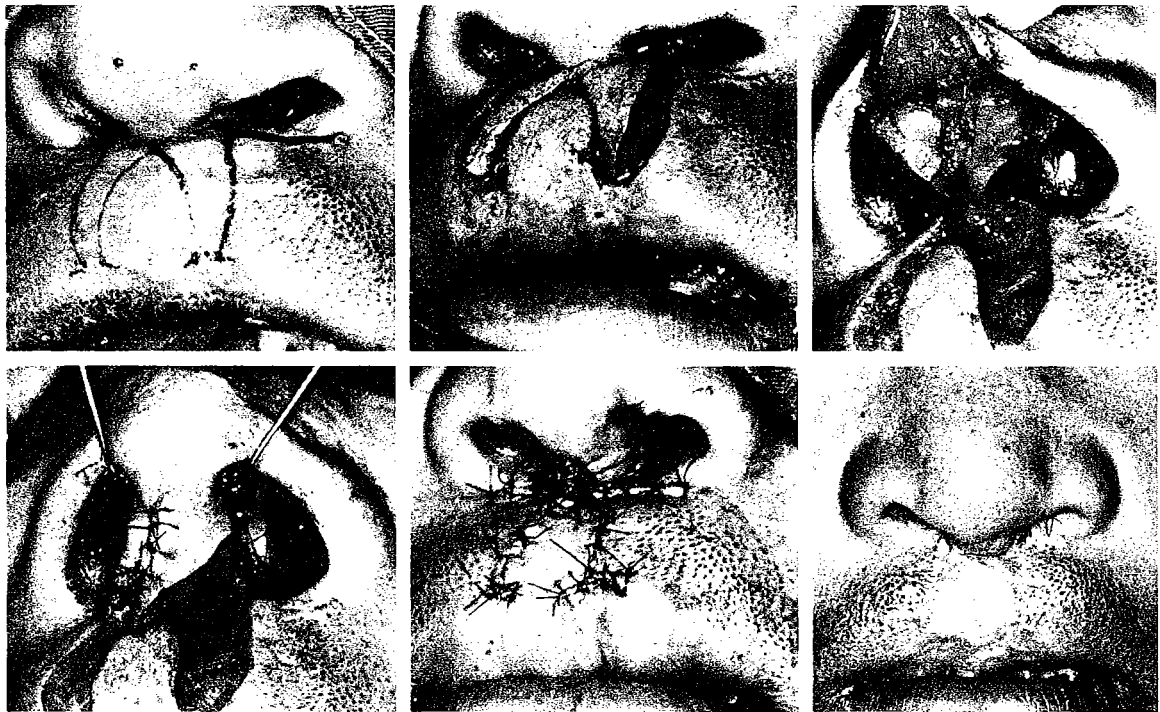
Takahashi

There is one surgeon in Japan who is probably more familiar than anyone else in the world with all my forked flap modifications. Shojiro Takahashi wrote a paper in 1972 with an impressive number of co-authors: T. Shigematsu, T. Furukawa, M. Ohi, H. Tanabe, T. Ichikawa and J. Tachikawa—one more, in fact, than

the number of modifications—(1) long fork, (2) short fork, (3) delayed fork, (4) primary fork, and (5) banked fork. He showed examples of several, including this secondary short fork



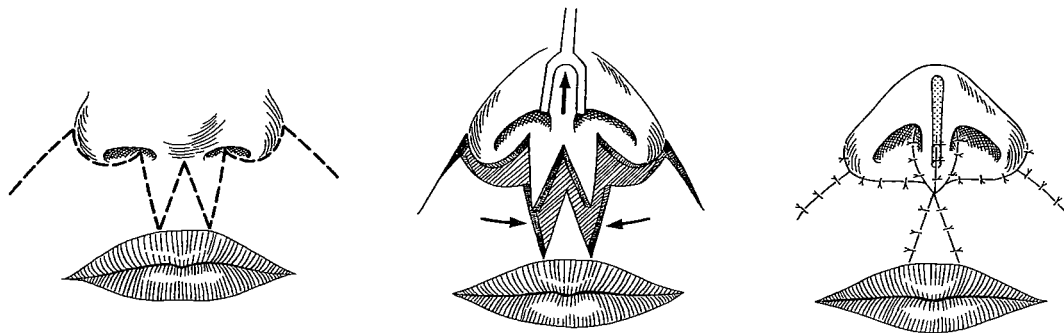
and a longer fork!



Merville

Maxillofacial surgeon L. C. Merville of l'Hôpital Foch, Paris, modified the lip donor area closure following the forked flap by bilateral lip-cheek advancement flaps. This is his plan:

- a) Outline of the forked flap of Millard and extension of the incisions into the nasolabial folds. This is usually only possible with a supple lip.
- b) Lengthening of the columella, advancement of 2 lateral labial flaps.
- c) Placement of a small intercolumnellar bone or cartilage graft to maintain the projection of the tip.

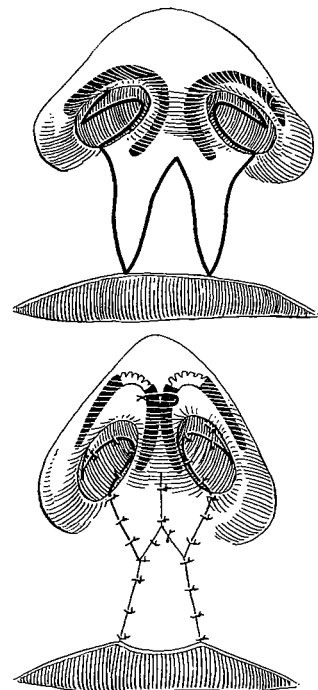


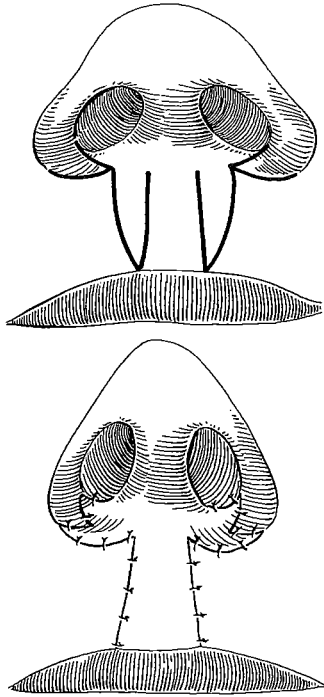
Neuner

It is interesting how Otto Neuner, Professor of Maxillofacial and Oral Surgery, Berne University, Switzerland, became interested in secondary cleft deformities. He recalls:

As a young boy I used to make fun of a hare-lip schoolmate. Years later during the study of medicine I was still ashamed of my mockery and vowed to do my share of rehabilitation. As a young surgeon I followed the lines of masters like Axhausen, LeMesurier, Trauner, Veau, but was never fully satisfied. Then in 1961 in Stuttgart while studying with Schmid I became familiar with your rotation-advancement and forked flap. Since then I have adopted, adapted and sometimes modified these procedures. My goal is always to restore completely a normal esthetic and functional integrity.

It is intriguing to study his artistry. He added to the forked flap Potter's V-Y intranasal advancement, scoring of the alar cartilage domes and suturing of the medial crura. He leaves the tips of the fork tails in the lip, as did Burian, but still achieves elongation of the nasal passage by more than 9 mm. At the second meeting of the Swiss Society of Plastic and Reconstructive Surgery in Zurich in 1966, he elaborated:





We extend the upper incision in a V-Y to approximate the lateral crura with their underlying mucosa, a distinction from Millard's original method. The medial crura then remain in the columella, as recommended by Meyer for Potter's procedure, thus simultaneously correcting the tip of the nose.

When columella lengthening need be minimal, Neuner notes:

As well as elongating the nose it is almost invariably necessary to raise the upper lip.

To do so he used a bilateral forked flap, transposing the prongs as nostril sills and incorporating them by splitting their tails and inserting an alar base into each split.

He has even used the forked flap in transpositions of 180 degrees for the relief of columella retraction. There is no law saying the forked flap should be used only for columella lengthening. The bilateral scars and wide prolabium often need revision and rather than being discarded can be used in the forked flap vehicle for whatever purpose seems indicated.

Summary of Neuner's goals has a familiar and encouraging ring:

Thus our operations are always performed with the aim of leaving only vertical scars which correspond with the edges of the philtrum. This, together with the union of the orbicularis oris muscle over a broad front, restores a full measure of mobility to the lip. We consider ourselves successful when such activities as whistling, pursing the lips and laughing can be carried out in a functionally and visually acceptable manner.

Neuner has published an impressive number of papers on secondary procedures, using the same group of cases repeatedly but with results so outstanding it is a pleasure to see them again.