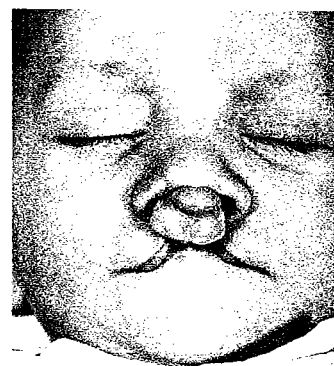

### 33. Correction of Secondary Muscle Discrepancies

IN bilateral clefts, besides the actual clefting, there are two discrepancies in the orbicularis oris muscle of the upper lip. Depending on the completeness of the clefts, the prolabium has little or no muscle. The lateral lip elements have muscle, but the fibers run parallel to the cleft edges up toward the alar bases. When the lateral lip elements are merely attached to the sides of the prolabium in the standard bilateral cleft closure, of course, the muscleless prolabium eventually is pulled wide and flat against the projecting premaxilla by the strong lateral muscle elements bulging with hypertrophy. It is best to count your losses, consider this stage a radical adhesion and at about five to six years take it all apart and start again doing what has been described and should have been done during the primary procedure.



In 1963 Bill Holdsworth of Queen Mary's Hospital, Roehampton, England, cognizant of the importance of muscle continuity, designed a secondary procedure in bilateral clefts. In his 1970 fourth edition of *Cleft Lip and Palate* he explained:

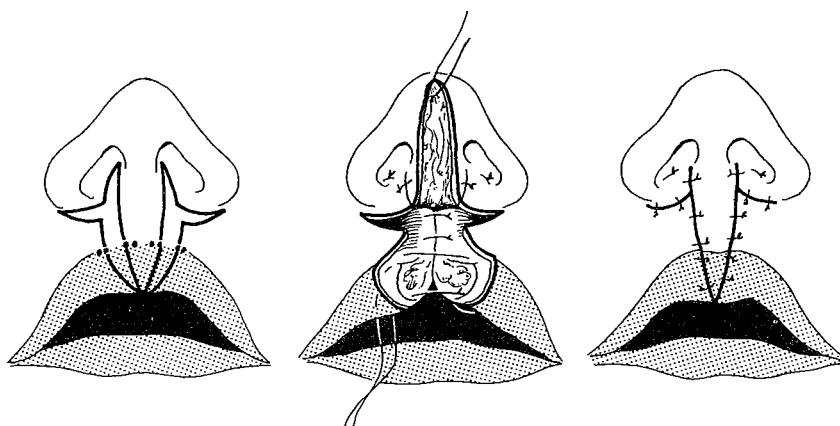
To interfere as little as possible with growth, operation is delayed until the age of eight.

He then reemphasized the values of his procedure:

1. To permit function, it is necessary, as in the palate, to join muscles. Otherwise the lip can never be an instrument of expression, and will remain a passive curtain, with unsightly lateral bulges caused by misplaced muscle. Veau (1938) pointed out that the absence of muscle from the

- prolabium was the principal cause of mediocre results in double clefts.
2. Vertical scars need revision.
  3. The prolabium is too wide to imitate philtrum.
  4. A mucosa sulcus is wanted in front of the premaxilla.
  5. The lateral elements of the lip require vertical shortening in muscle and skin.
  6. A median notch on the edge is to be removed.
  7. The nostril floors are too wide.

Holdsworth considered that all of these matters were dealt with by his 1963 operation based on the Veau III. He excised the scars bilaterally, elevated the prolabium as a trapdoor flap, joined the lateral muscles together across the midline, advanced the alar bases and replaced the prolabium.

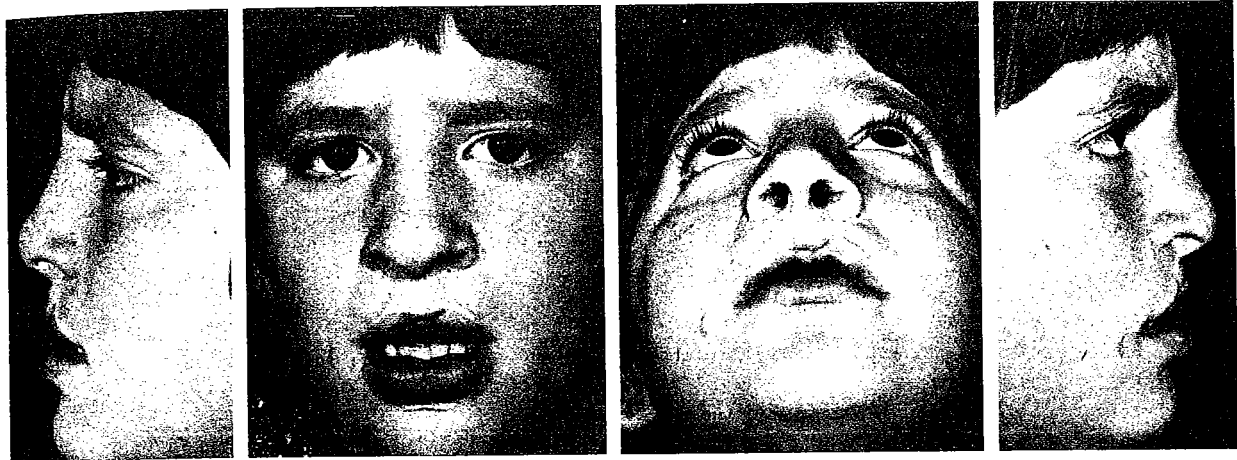

The only possible criticisms are that this maneuver should have been completed during the *primary* operation, and even as a secondary procedure it has made *no* allowance for adequate lengthening of the short columella.

Thus, it is proposed that the best and most efficient approach is to join the lateral muscles to each other across the cleft during the primary surgery as has already been described in the banking procedure. If this has *not* been done, then it should, as a secondary procedure, be carried out the same way. The lip elements should be cut free from the alar bases, brought down and advanced to each other behind the prolabium.

Here is a case treated in New York using the earlier plan in which primary bilateral rotation-advancement had been followed by a secondary forked flap. The columella seemed almost long enough, but the lack of muscle continuity across the prolabium,

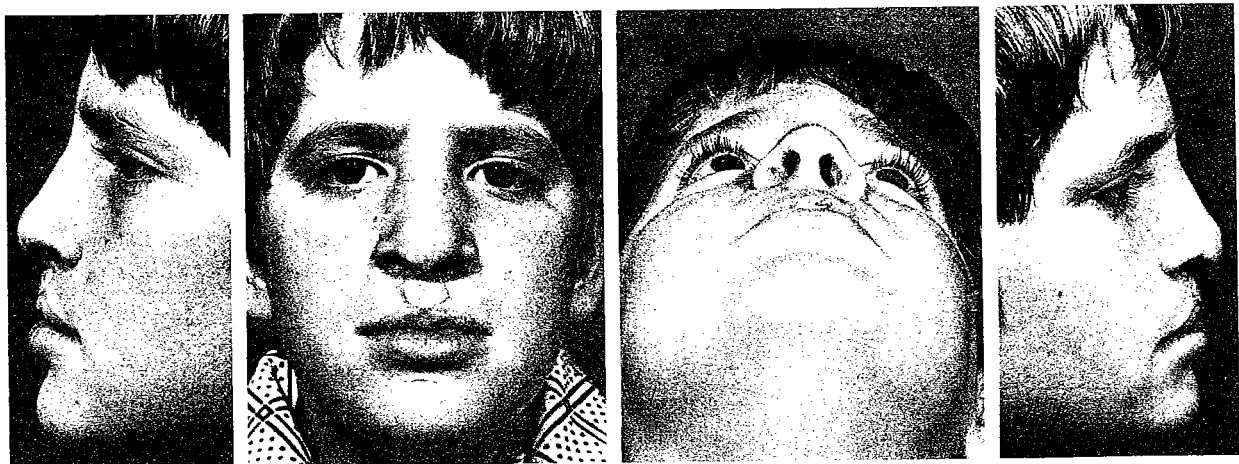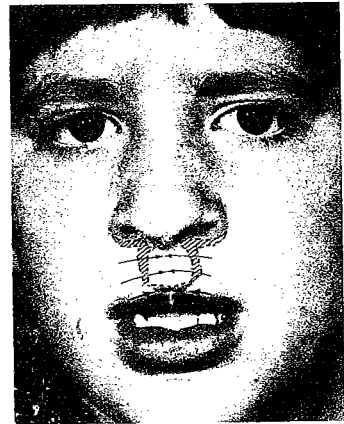lip shortness, the visible preservation of a portion of the prolabium vermillion and a slight whistling deformity spoiled the result.



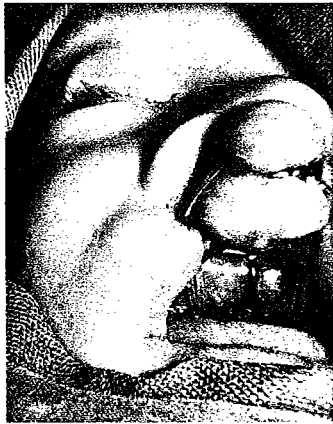8 years

As the columella was almost adequate, the lip scars were excised and the prolabium was elevated. The lateral muscles were mobilized and sutured to each other in the midline, and a Mersilene dimpling stitch replaced the prolabium in better philtrum posture. Maintaining the inferior mucocutaneous ridge, the prolabium vermillion was turned down so that vermillion of the lateral lip elements could overlap it out of sight and create a full tubercle.

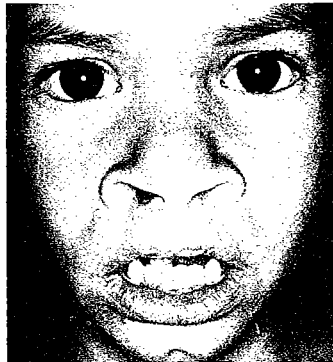The borderline shortness of the columella and the width of the alae will probably be corrected by the advancement of the alar bases and nostril floors into the columella at about 15 to 16 years, when nasal shortening and a septal cartilage strut can be used for final tip shaping and support.



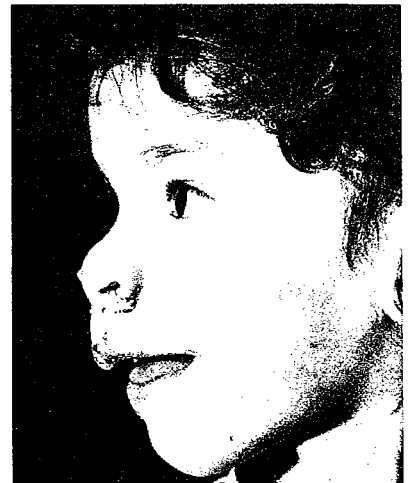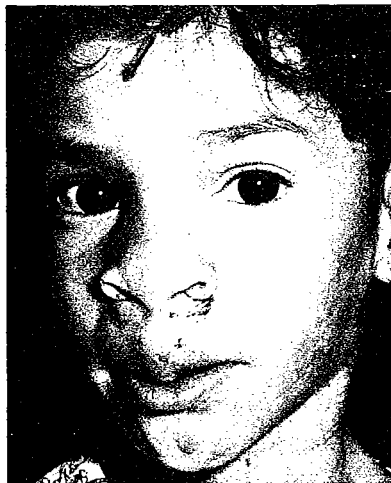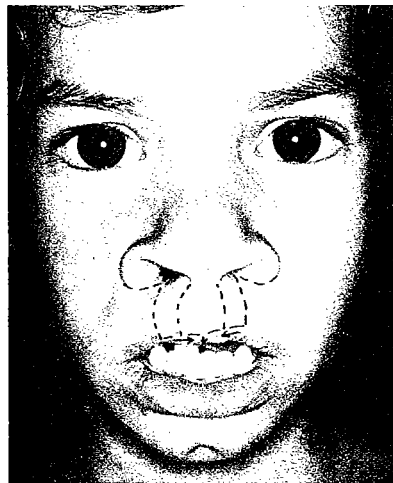
1 month postoperative (9 years)



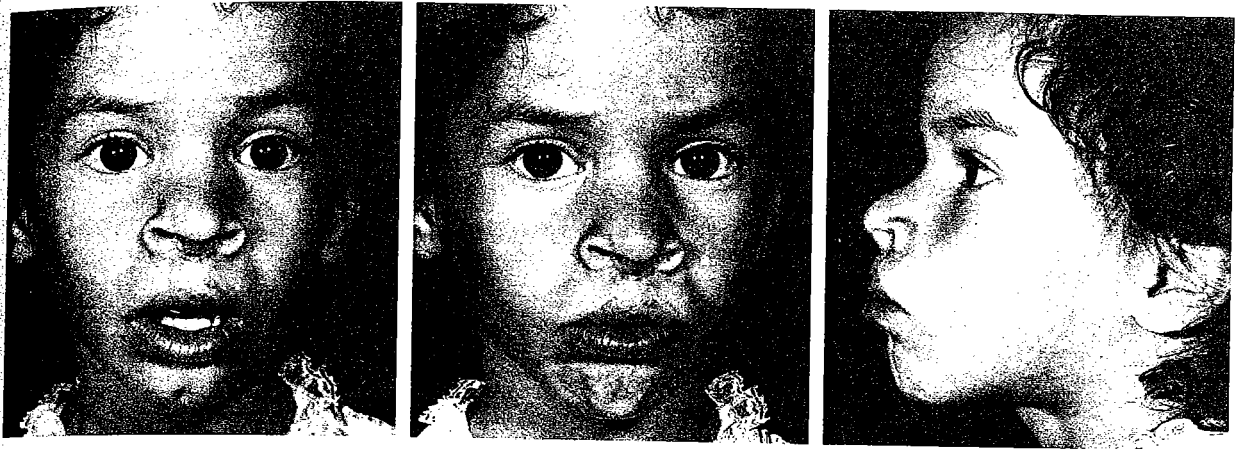If the columella is also short, a forked flap can be banked while the *muscles are approximated*, and three weeks to three months later the *forked flap* can be *advanced* into the *columella*.



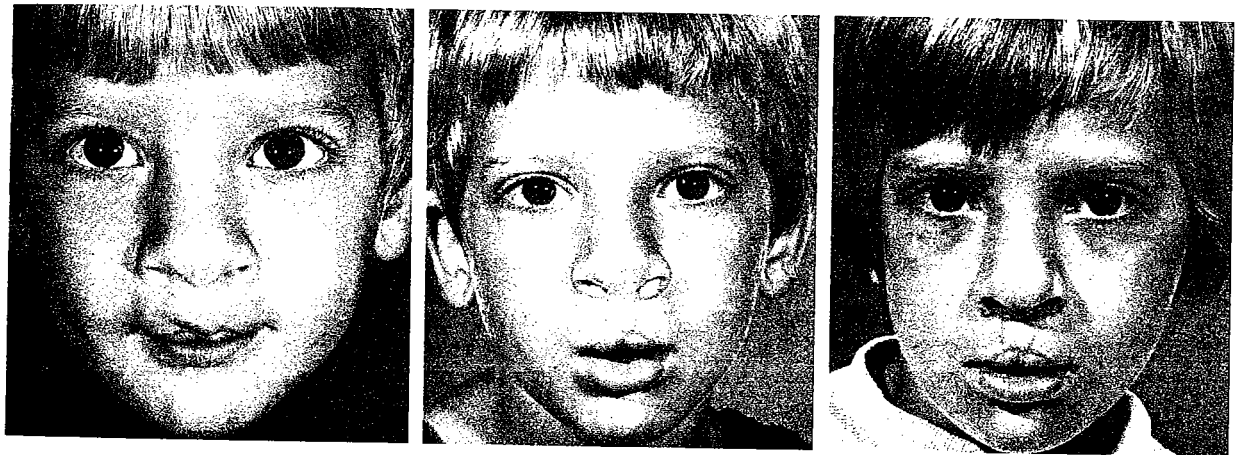This complete bilateral cleft with a severely protruding premaxilla was treated with the early Georgiade-type rubber band retraction. The lip clefts were closed by simple straight-line approximation with no effort to join the muscles or bank a fork. The result was about what would be expected and nearly what would be achieved by a bilateral adhesion procedure. The stage was set for taking the entire lip apart, paring a forked flap, joining the mucosa and muscle of the lateral elements behind the prolabium, advancing the alar bases and suturing their denuded ends together in the midline to the septum, placing a dimple stitch in the prolabium and banking the forks in whisker position.



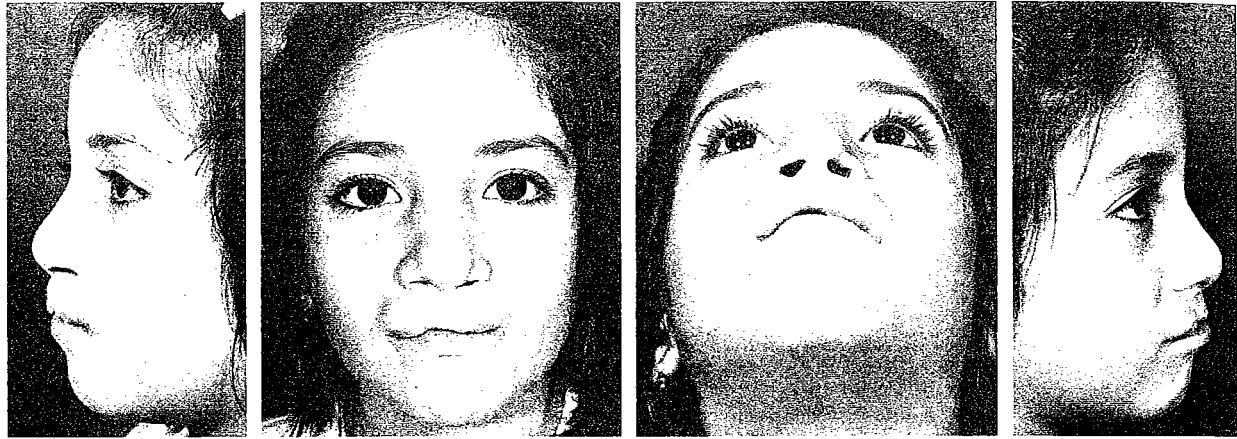Several months later the forked flap was taken out of the lip and advanced along the septum into the columella and the lip elevated to the nostril sill.



Here is another example of secondary correction of the nose and lip which included cutting the forked flap, approximating the lateral muscles together behind the prolabium, and banking the fork in "praying hands" position. Three months later, the forked flap was advanced into the columella.



The six-year-old Central American girl on the next page had been born with a bilateral cleft lip and palate, treated in infancy in San Salvador by surgical approximation of the lateral lip elements to the prolabium. The result was typical for this method, presenting a flat nasal tip, short columella, wide prolabium with lack of muscle continuity, lateral muscle bulges and deficient central vermillion with a whistling deformity.



6 years



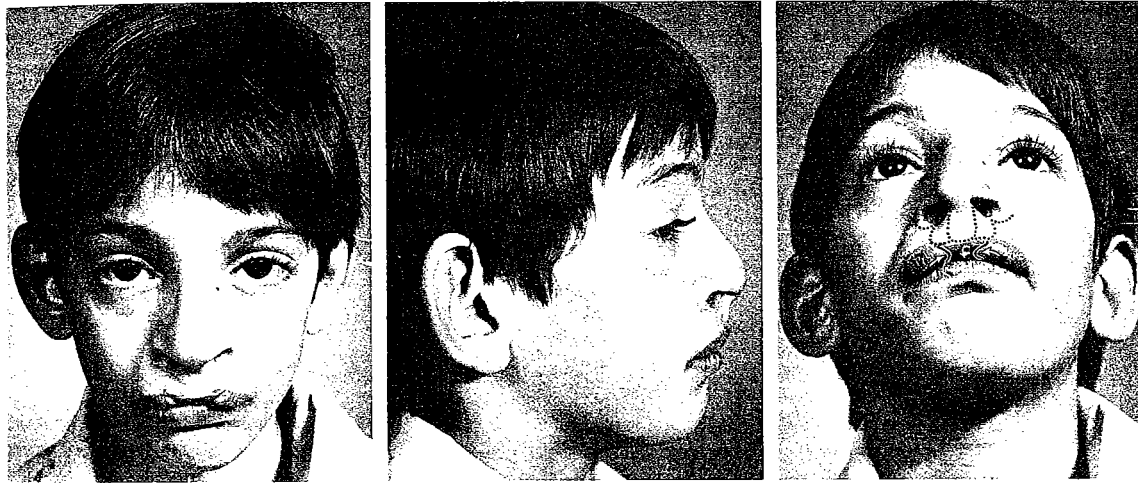A forked flap incorporating the bilateral scars and portions of the wide prolabium was cut up to the base of the columella. The central portion of the prolabium was freed from the premaxilla, leaving most of its mucosa to cover the anterior raw surface of the premaxilla. The lateral lip elements were approximated to each other, first mucosa and then muscles for complete continuity. The prolabium was replaced as a philtrum with a dimpling stitch. The forked flap was banked in subalar whisker position.

Two and a half months later, the banked fork was reelevated and advanced into the columella with the aid of a membranous septal incision, which was extended bilaterally in the vestibules at the tip for adequate release. Small side flaps cut from the forked flap were interdigitated into the vestibular releases. The forks were sutured together in front, rolled into a tube with catgut sutures and stitched to the septum with the tips splayed at the columella base. The alar bases were cut as flaps with subcutaneous scar extensions, which were advanced medially and sutured to each other at the nasal spine. The join of the alar bases to the splayed tips of the forked flap created the nostril sills.



## SECONDARY MUSCLE APPROXIMATION AND FORKED FLAP

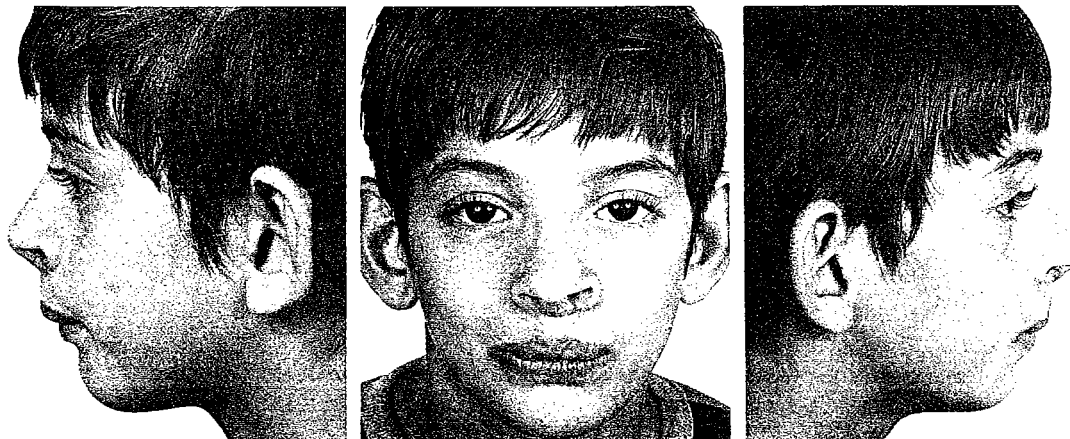
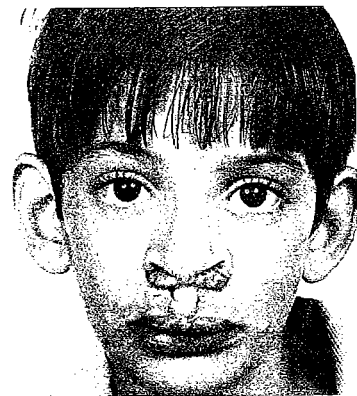This boy, with a complete bilateral cleft lip and palate, had the old standard closure in infancy in New York. At 10 years he revealed all of the typical secondary deformities including short columella, flaring alae, absence of muscle in wide prolabium, lateral muscle bulges, absence of upper labial sulcus and deficiency of prolabium vermillion with whistling deformity. The premaxilla was slightly projecting but the maxilla and palate were reasonable.



10 years

In the first stage of the secondary correction a forked flap was elevated, lateral mucosa and muscles united across the midline, dimple stitch placed in philtrum, lateral vermillion flaps advanced to overlap miserable prolabium vermillion and forked flap banked in whisker position.

Several months later forked flap was advanced into the columella and lip lifted up to the nasal sill.



Ian Jackson of Glasgow, Scotland, is one of the modern champions of joining muscles across the midline in bilateral clefts. In Copenhagen in 1973 he pointed out its value as a secondary procedure:

These methods can be applied to secondary cases where there is shortening of the lip and muscular dysfunction due to lack of reconstruction. Correction of whistling deformities in bilateral cases has been effected without difficulty since this is due to lack of muscle in the prolabium.

Several months later he added:

If one looks at the orbicularis reconstruction in secondary cases, this is where I think the answer lies. . . . It has been interesting that showing these lips prior to operation to other surgeons they have suggested in many cases that Abbe flaps will be necessary to bring in new material. It seems that when one brings the orbicularis into its true position in the midline the need for an Abbe flap diminishes because the whistling deformity is cured in an effortless fashion and the whole lip is lengthened by swinging down the muscle bundles into the midline. In fact, there have been a few lips which have ended up marginally too long after this procedure.

#### MUSCLES ARE JOINED IN MICHIGAN

Robert Oneal with Donald Greer and Gary Nobel of the University of Michigan reported "Secondary Correction of Bilateral Cleft Lip Deformities with Millard's Midline Muscular Closure" in *Plastic and Reconstructive Surgery*, July 1974. They cited nine cases adopting this two-stage procedure in secondary deformities. The sequence of events as they described it is of interest:

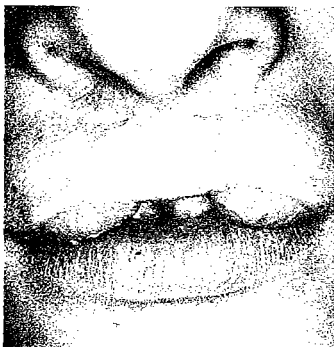We had been doing our primary closures with bilateral lip adhesions. With Dr. Millard's encouragement, we applied his two-stage technique for lip closure in one of these patients. We were encouraged by our results with this patient. Because the lip-adhesion repairs resembled many of the patients coming to us for secondary repairs, we decided to try this technique in a series of patients for secondary repair of bilateral cleft lip deformities.

They noted certain aspects about these deformities:

In some cases during movement of the lip, the deformity is magnified. . . . With an attempt at puckering, the lack of midline *orbicularis oris* union becomes quite striking. In these cases the lateral vermilion is redundant and



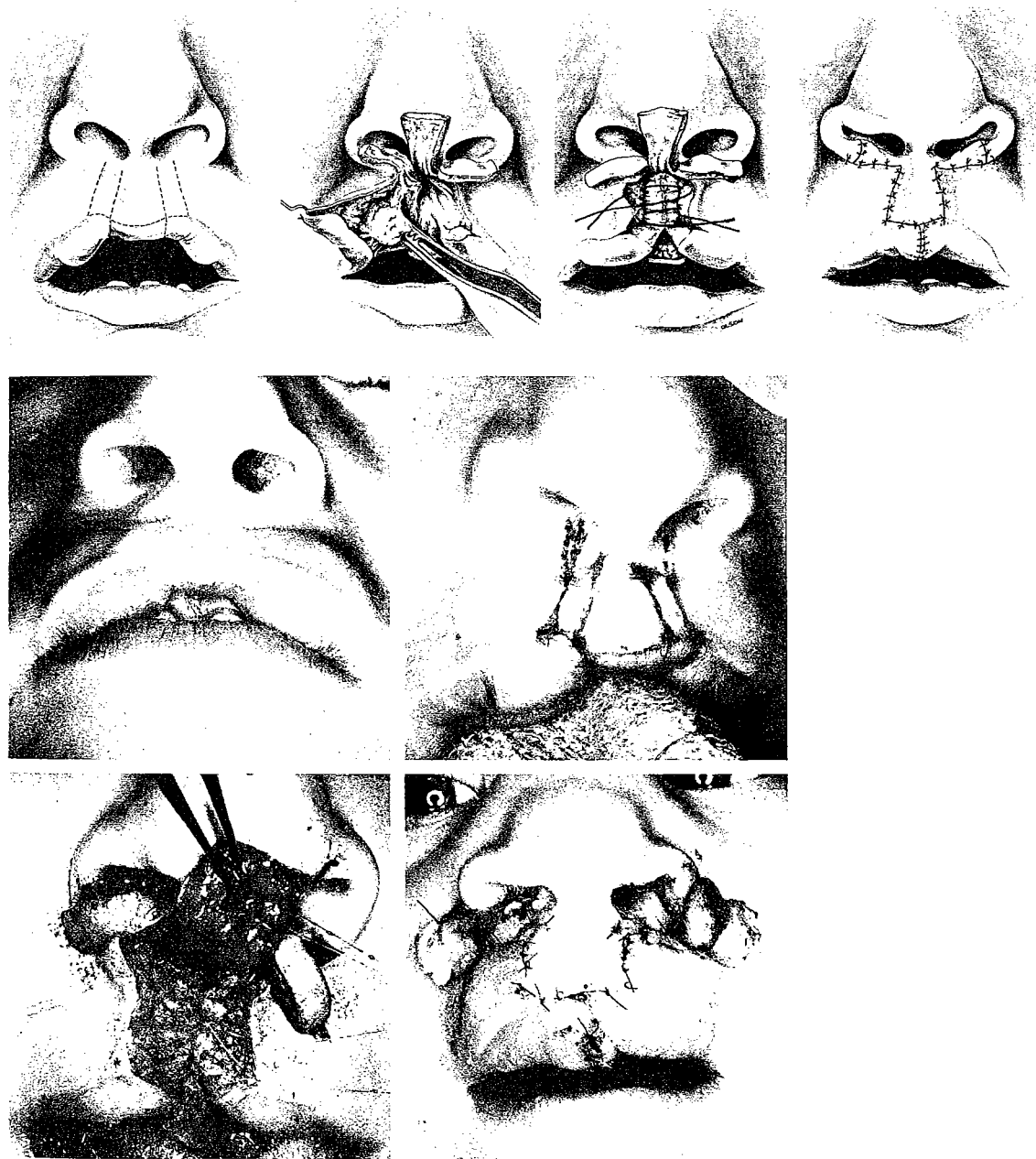
Robert Oneal

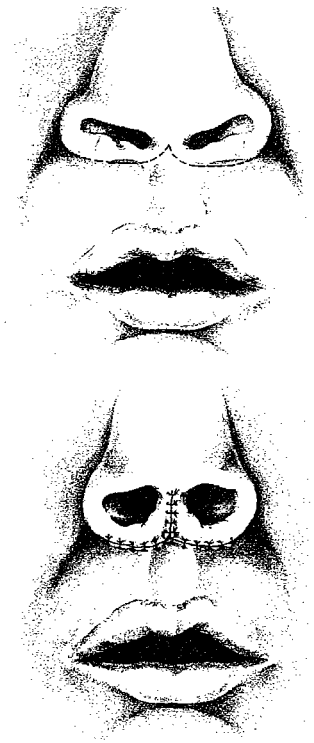




the unconnected *orbicularis* segments bulge laterally beneath the skin; this causes the central muscle and vermilion deficiency to become even more apparent. In addition, many of these patients have a short columella and a tethered nasal tip; these also require correction.

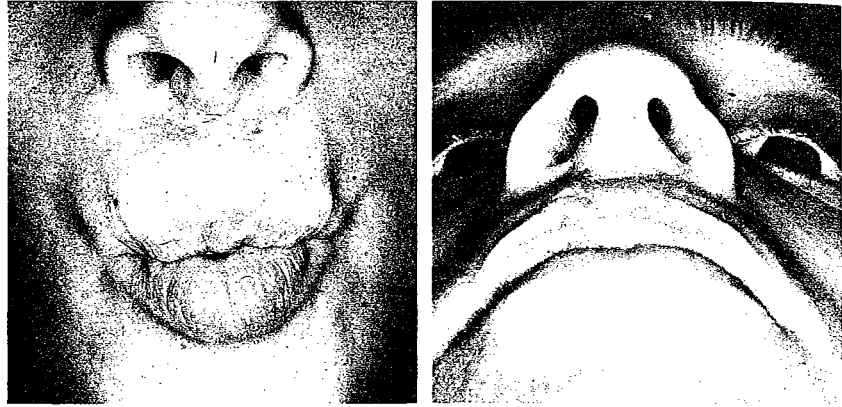
Robert Oneal kindly forwarded me a series of diagrams and photographs, some of which he published in *Plastic and Reconstructive Surgery*. A few of these have been selected to show the secondary deformity, banking the fork, muscle union behind the prolabium and finally columella lengthening.





Their attitude toward banking the forked flap is sound:

If the columella needs lengthening, the extra bulk available from the "banked" flaps and the good results obtained by the Cronin columella raise justified the two-stage procedure.



In summary they noted:

Our review of nine cases in which this technique was employed demonstrates significant improvement in all the basic aspects of the deformities. We have been particularly impressed with the resultant cupid's bow and midline tubercle. The most dramatic change, however, has been in the dynamic function of the *orbicularis*—particularly during active puckering of the lip . . .

Amen!

Once the muscle is united in the midline, the transverse vectors cancel each other out, the vertical vector is doubled and it now acts centrally to elongate the center of the lip. This is potentially helpful when the prolabium is congenitally short. These factors suggest to us that the lack of muscle continuity should be corrected as early as possible.

It was particularly encouraging when sound and knowledgeable Bill Grabb, author of the comprehensive *Cleft Lip and Palate*, voluntarily expressed his "joy" with the functional and relaxing effect of this joining of the lateral muscles behind the prolabium. The reduced prolabium, shorn of the forked flap, snuggles like an intervening piece of a puzzle back between the skin edges of the lateral elements in a better than perfect fit so that the scars of union have absolutely no element of tension tugging against their healing.

In 1976, James Lehman of Akron endorsed this type of secondary muscle approximation during forked flap banking followed by advancement of the forks into the columella as a second procedure.

Tord Skoog of Uppsala is another surgeon who by 1973 in Copenhagen was advocating joining the lateral muscles across the midline as a secondary procedure. He wrote me in January 1976:

In bilateral clefts I am more and more impressed by the results of the secondary lip reconstruction which is described in my book on pages 134-140.


In his 1974 *Plastic Surgery* Skoog shows several cases of bilateral cleft lip with a whistling deformity that had been closed originally by his method. He then presents beautiful color pictures of lifting the prolabium (making fresh skin scars) and joining the lateral muscles across the midline in an effective secondary procedure. This is similar to what many of us have been advocating for years *primarily*—and, of course, secondarily also when necessary.

#### AUTOGENOUS SKELETAL MUSCLE FREE GRAFTS

In 1874 Zielonko, a Russian pathologist in Strasbourg, first transplanted free autograft of skeletal thigh muscle in the lymph sac of the frog and observed rapid necrosis without regeneration. Others experienced similar failures. Lyndon Peer's 1955 suggestion that the entire length of the myofibril be used in the grafting rather than only a segment of the cell, and Hogan, Dawson and Romanuel's 1965 demonstration of reduced metabolism following denervation of muscle suggested two adjuncts to increase the chance of free muscle graft survival. This was the basis of Noel Thompson's Foundation of the American Society of Plastic and Reconstructive Surgeons 1971 prize-winning essay. Then in 1974, in his Kazanjian Lecture, he presented autogenous free skeletal muscle grafts applied to various areas including the bilateral cleft lip.

Research-oriented Thompson, apparently without great experience in primary cleft lip surgery, infatuated with his free muscle grafting and anxious to try it everywhere, made a vague "half case":

Attempts made to restore muscular continuity across the prolabial region by mobilizing the lateral lip musculature (Glover and Newcomb, 1961; Duffy,



Noel Thompson

1971) have the disadvantage of producing a tight lip of excessive vertical height or progressive fibrous replacement in this tissue putting excessive tension upon the transposed muscle (Fara and Smahel, 1967).

He continued:

*two more  
skin scars?!*

A simple and reliable method of successfully restoring the continuity of the orbicularis oris muscle fibers in the bilateral cleft lip is by exposing the area completely. This is accomplished by turning down skin of the already repaired upper lip by bilateral nasolabial incisions joined by a transverse incision below the nostril floors and root of the columella. The lateral muscle masses of the upper lip are exposed; the fibrous tissue of the prolabial region is removed, and a muscle graft (one belly of suitable size from the extensor digitorum brevis muscle [denervated 14 days prior to transplantation]) is applied to bridge the prolabium and sutured directly to the lateral muscle elements. Complete sphincteric contraction of the lips results.

He then presented an adult secondary bilateral cleft. Obviously the patient had never had the lateral muscle elements joined behind the prolabium and could not whistle. His postoperative photo revealed improvement but a rather odd-looking lip while whistling and had this label:

Electromyography. Preoperatively there was, on volition, normal electrical activity in the lateral lip elements, but no activity in the prolabium. At 3 months after muscle grafting to the upper lip, there was well marked volitional activity in the prolabium following reinnervation of the graft.

This is interesting, but his next suggestion is disturbing:

If applied at about the age of one year, it seems possible that the improved muscular activity might affect skeletal development in the premaxillary region beneficially.

Many of us will postpone free grafting of skeletal muscle until its microscopic vessel anastomosis is practical. It will probably never be needed in bilateral clefts anyway as there is already enough innervated muscle present, if handled correctly, to obtain good function and whistling without one's having to lend a *hand* or even part of it to the lip.