


31. Banking and Cashing the Forked Flap

ONCE the excess prolabium skin has been moved out of the lip and stored for later use, the lip need not suffer reentry and the lovely scars of infancy can be retained forever. Whether the forked flap has been banked as tubed polyps hanging free or, better, in subalar whisker position, or in the floor of the nose clasped as "praying hands" pyramids with the alar base flaps, as long as all raw areas are covered the tissue may settle but will remain available.

POPPING POLYPS

In some cases, once the alar bases had been advanced medially and fixed, there seemed to be no place to bank the fork. Each prong of the fork, therefore, was tubed on itself and left dangling as polyps. This was an annoying temporary deformity which invariably was corrected by another surgical stage of opening the polyps and approximating them to the alar base flaps in "praying hands" pyramids.

Polyps



One method of banking tubes (each fork to form a pair of polyps).

For better banking, these polyps can be opened and the alar base flaps D elevated.

Then each fork is sutured to each flap D in the "praying hands" pyramids.

Finally, a method was developed and has been described which allowed deep advancement of the alar bases but still supplied alar base flaps for banking the forked flap.

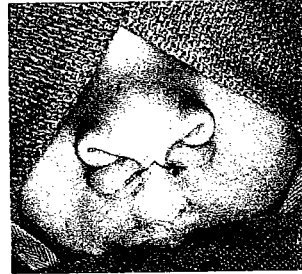
The second-stage columella lengthening calls first for freeing the forks by parallel anterior and posterior incisions. The anterior incisions run in front of the forks to join across the base of the columella in an inverted V while the posterior incisions extend behind the forks in the nasal floor to join and continue through the membranous septum, up over the septal tip and on to the bridge for about 0.5 cm. with lateral extensions in the vestibule to ensure full nasal tip release.

SHIFTING WHISKERS

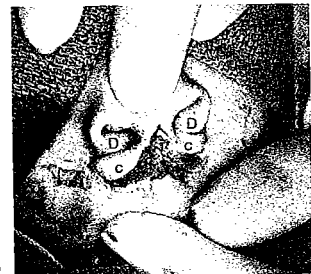
If the forked flap is in whisker position, the prongs are cut out of the upper lip, sutured together, tubed in its upper portion, advanced along the septum and fixed with sutures. The tips of the fork are splayed as a columella base to meet the advancing alar bases.



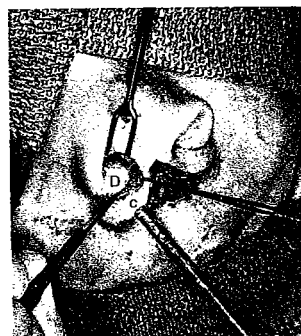
Forked flap banked as whiskers.



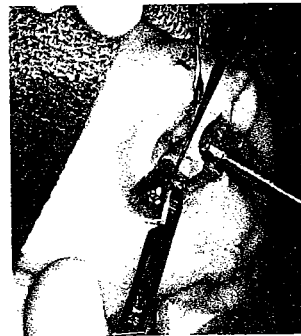Anterior incision crosses the columella base as an inverted V.



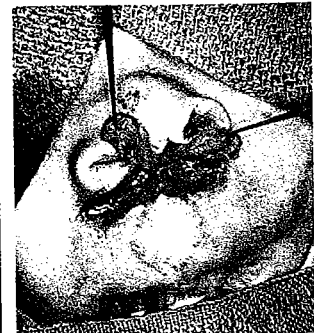The forked flap c and c are incised.



Right flap c freed from flap D.



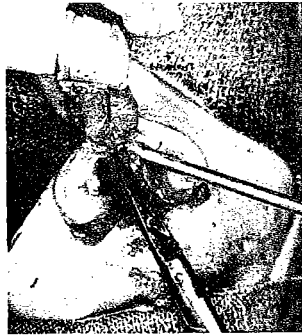Right flap c being elevated.



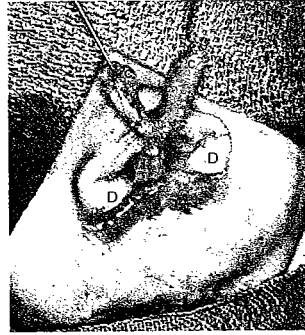
Both c flaps free from lip.



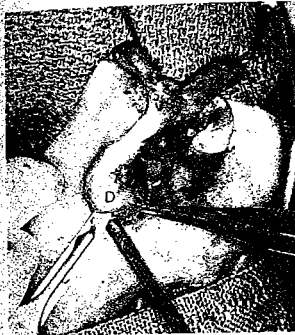Making the membranous septal incision.



Freeing the forked flap along the septum at the tip.

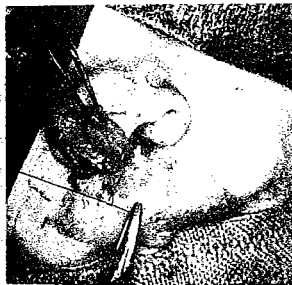
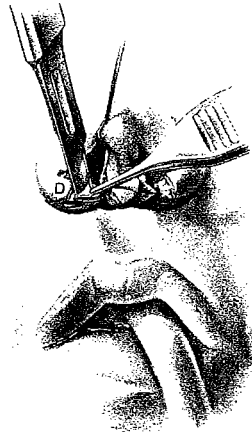


Forked flap c, c free up to the tip.

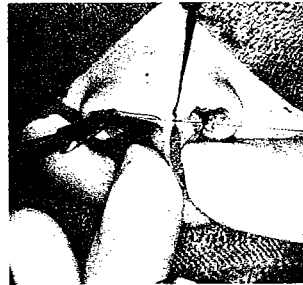


Alar base flap D being freed.

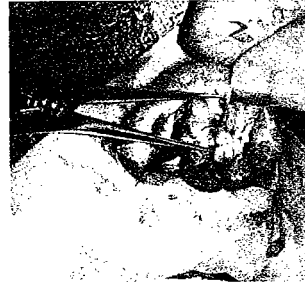
Tip of alar base flap D being de-epithelialized for suture to its mate of the opposite side at the base of the septum.



Tubing the posterior aspect of the forked flap.



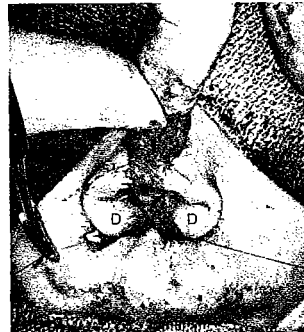
Suturing the anterior skin of the forked flap.



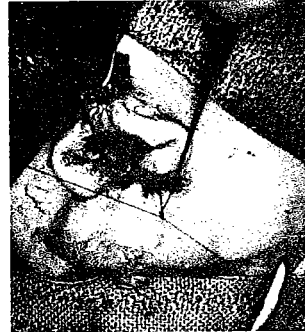Resultant lengthening of columella well over 1 cm.




Placing the key suture through the denuded tips of the alar base flaps D and the base of the septum.



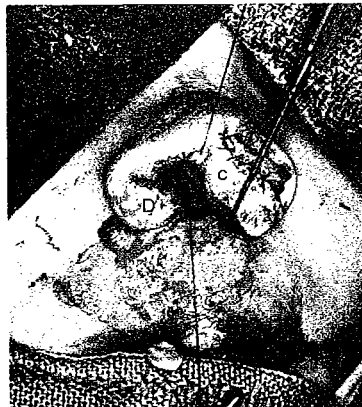
Tying the suture with medial advancement of the alar bases.



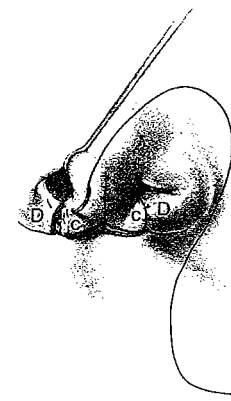
Subcutaneous suture of the alar bases to the lip.



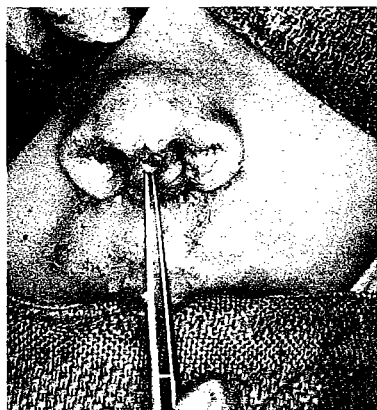
Upper lateral extension of forked flap being let into vestibular releasing incision.



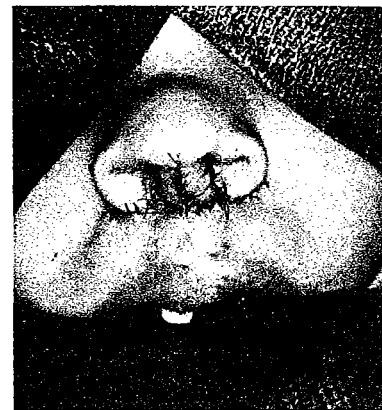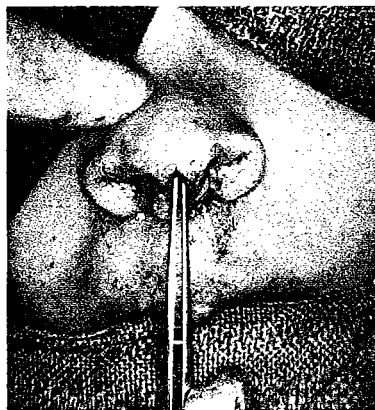
Suturing this maneuver.



Suture of alar base D to the splayed end of forked flap c.



Insertion of subcutaneous free graft into the area of retraction.

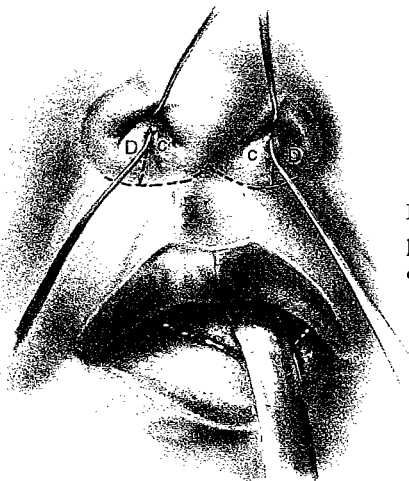


Good columella lengthening without lip reentry.


OPENING HANDS

If the forked flap has been placed in apposition with the alar base flaps in the "praying hands" position, these two components are cut as two humped straps. Anterior incisions made along the front of the alar bases and forks meet in the midline at the base of the columella in an inverted V. Parallel with these anterior incisions are posterior incisions inside the alar bases, across the nasal floors, up the membranous septum and over the septal tip. Thus are created two strap flaps, each with a central pyramid which, when dissected partially open, lengthens the strap as would happen if the hands were pulled apart at the palms but allowed to retain contact at the fingertips. These elongated straps are advanced medially to each other and upward along the septum into the columella in the rotary action similar to the

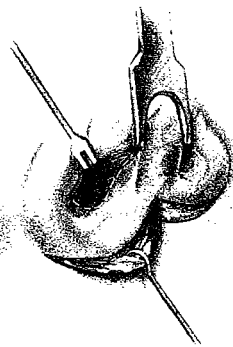
Carter-Cronin motion. The join of the tips of the fork to the tips of the alar base flaps has been maintained and forms a slight swelling which, after medial advancement, imitates the medial alar cartilage feet at the columella base.



Anterior marking in preparation for partial reopening of the "praying hands" pyramids.

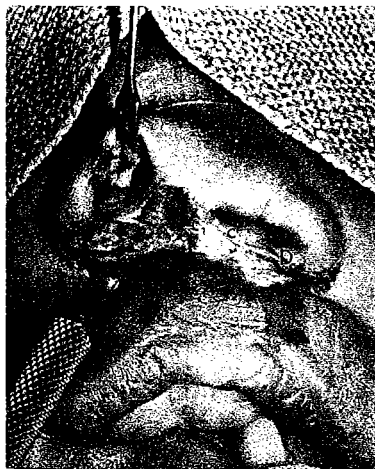

Method of making parallel posterior incision to develop D-c strap flap.

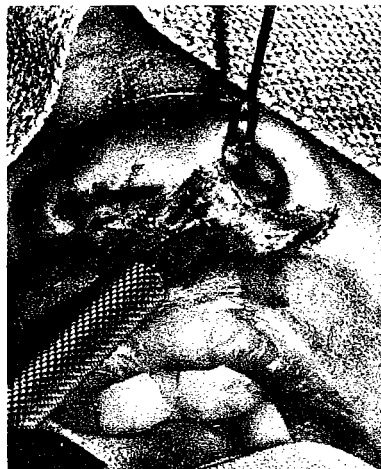


Transforming D-c pyramid into a longer D-c strap flap.

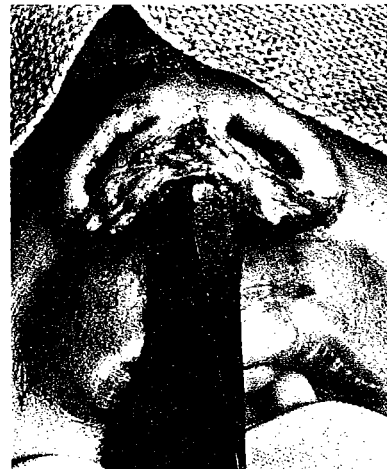← Parallel posterior marking and incising of membranous septal and upper vestibular releasing incisions.



Dissection of the right alar base—forked flap strap through the anterior incision.

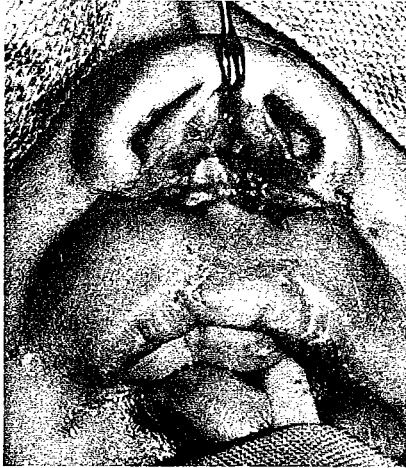


Same on the left.

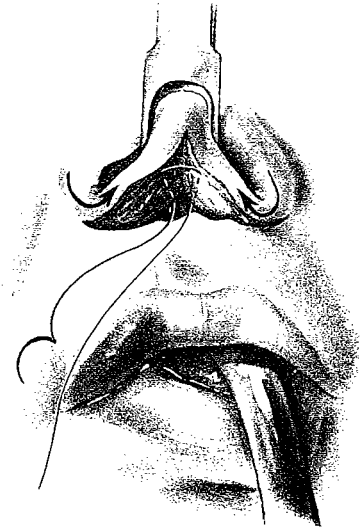

Freeing the columella and the forked flap from the septum.

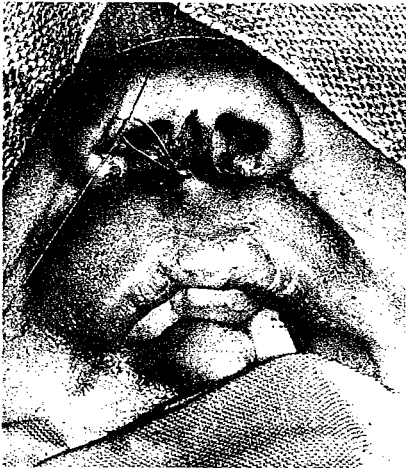Praying Hands 2



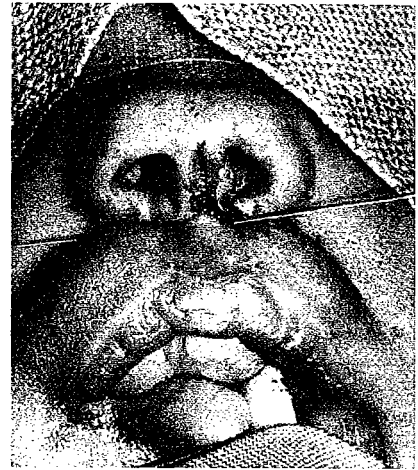
Forked flap portion of the D-c strap flap is being advanced into the columella as the nasal tip is elevated.



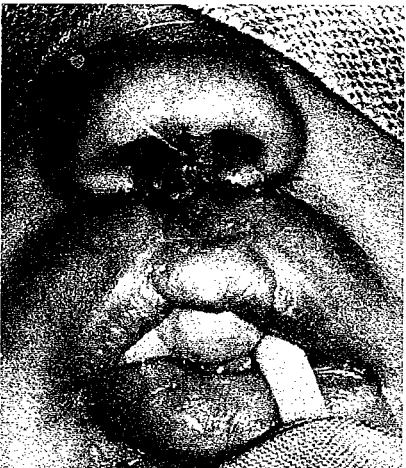Deep subcutaneous suture approximating the fork at the base of the new columella is placed.



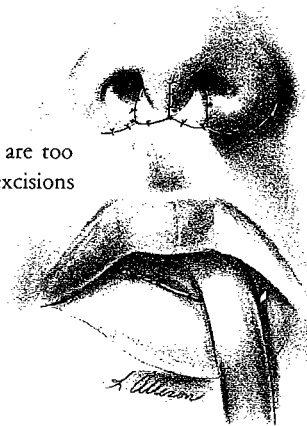
The first loop is thrown



and tied.



Skin sutures have been placed.

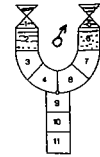
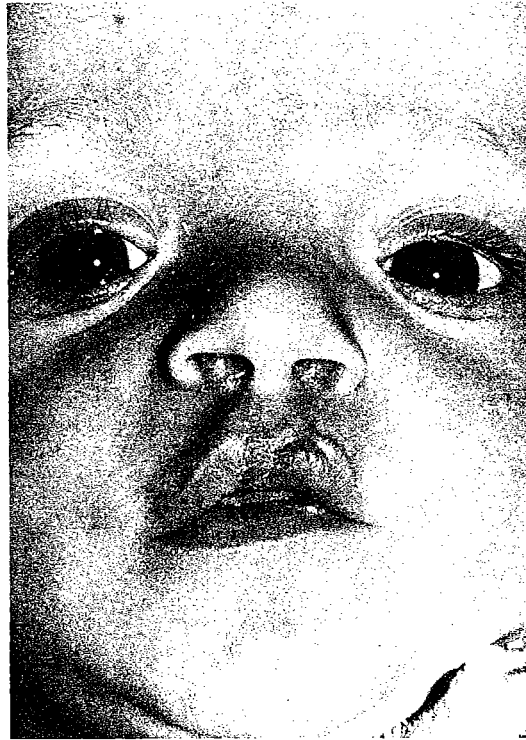
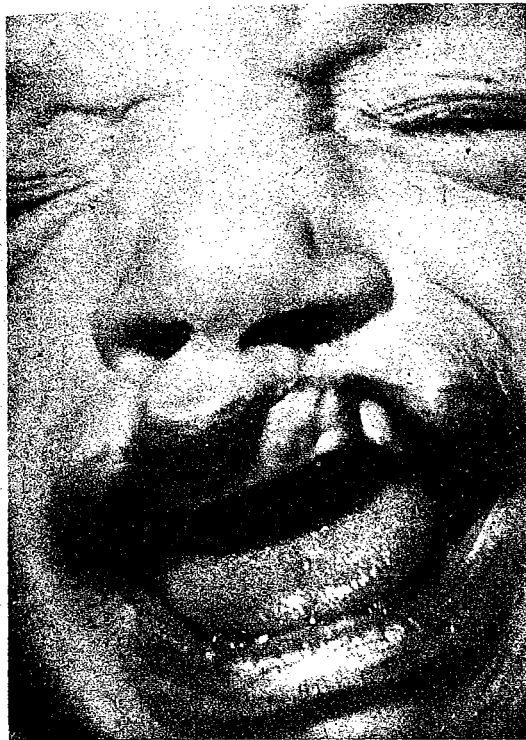
If nasal floors are too wide, wedge excisions can be used.

Columella lengthening without lip reentry.

PERSONAL CASES

Asymmetrical incomplete clefts

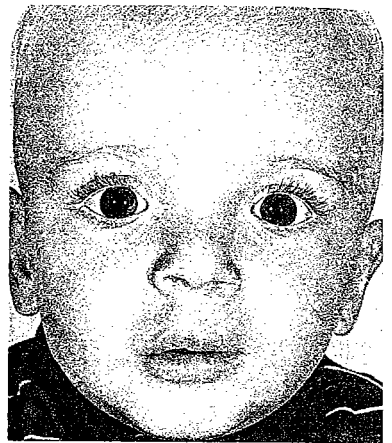
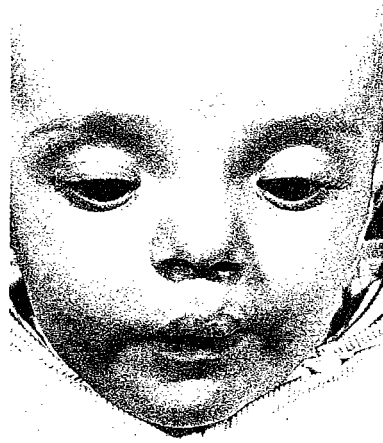
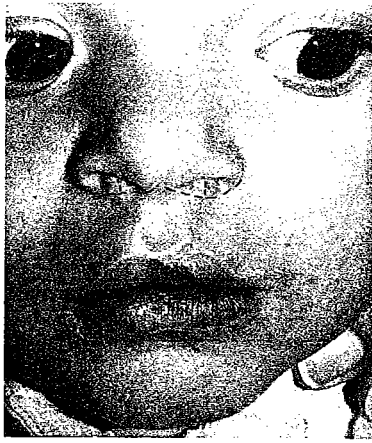B.D. 8-4-70
Wt. 3 lb.
12 oz.
F.H. Unknown
F.T. Uneventful
O.C.A. None

12-21-70

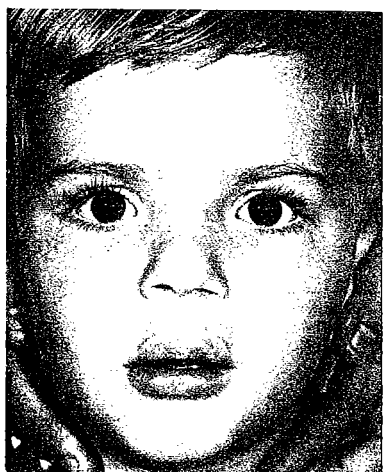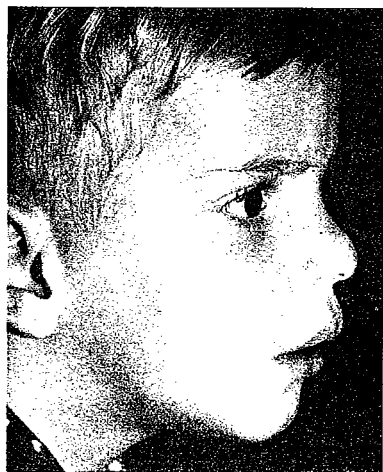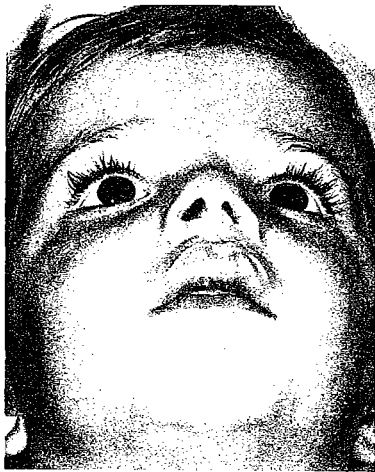At four and a half months of age, one-stage lip closure was undertaken.

1. The prolabium was freed from the premaxilla, and the lateral lip elements were freed from the maxillae.
2. A forked flap was pared from the sides of the prolabium.
3. Lateral mucosa and muscle were joined behind the prolabium.
4. A dimple stitch was made.
5. Lateral vermilion flaps carrying the mucocutaneous ridge were used to overlap the prolabium vermilion.
6. The forked flap was banked with the alar base flaps in "praying hands" pyramids.

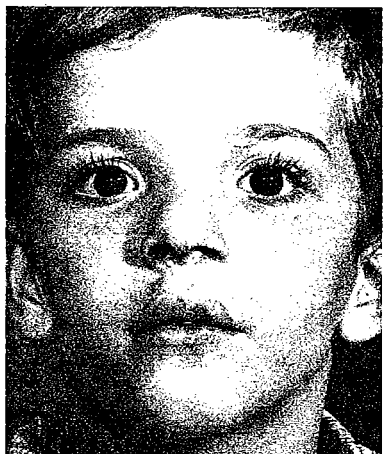

4-6-61

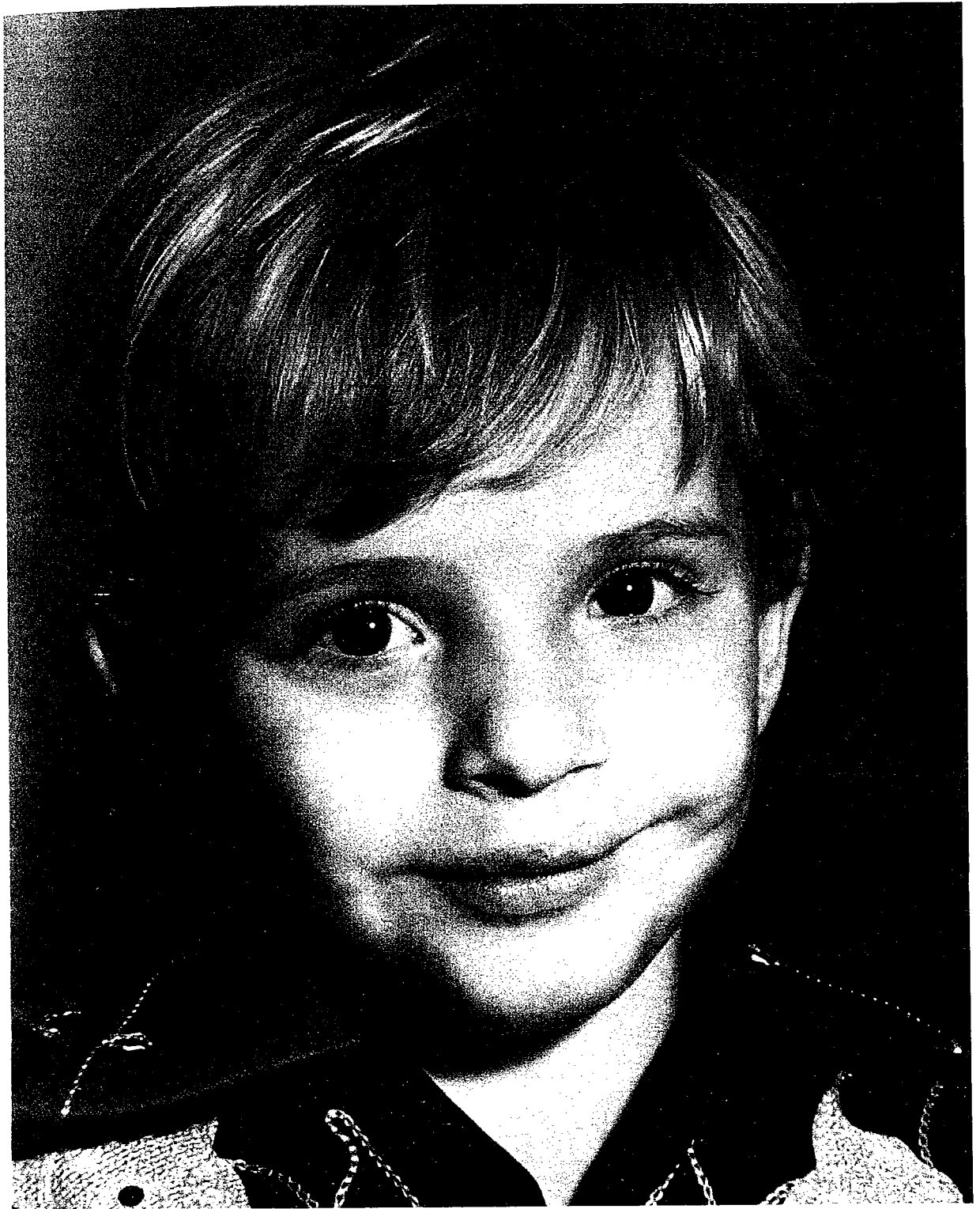
Three and a half months later, at age eight months, the forked flap was advanced into the columella with nasal tip release and alar base advancement.



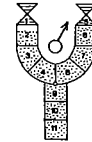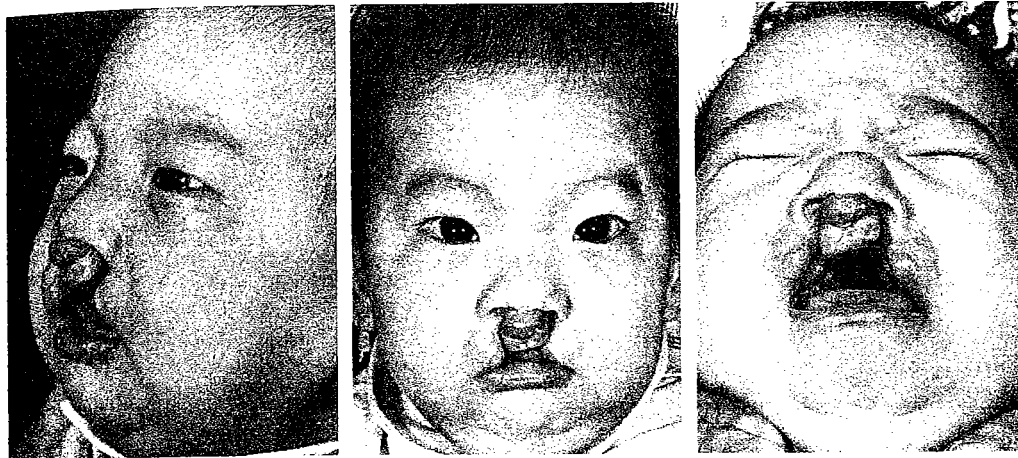3½ years old



4 years old



Asymmetrical incomplete and complete clefts



B.D. 3-17-73
 F.H. No clefts
 F.T. Uneventful
 O.C.A. None

At three months Fred Pullen performed myringotomy with insertion of ear tubes. This was followed by soft palate closure and first-stage lip closure with banking of forked flap.

1. The alar bases were freed from the maxillae by dissection, and further release was achieved by incisions in the lateral vestibular lining. Lateral vermilion flaps 1 were used to fill the vestibular defects and allow the nose to come and stay forward.

2. A forked flap was pared from the sides of this tiny prolabium, and the prolabium was freed from the premaxilla up to the nasal spine.

3. The lateral prolabium vermilion was left attached to the premaxilla to cover its raw surface.

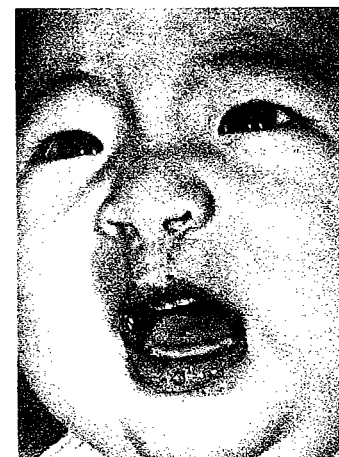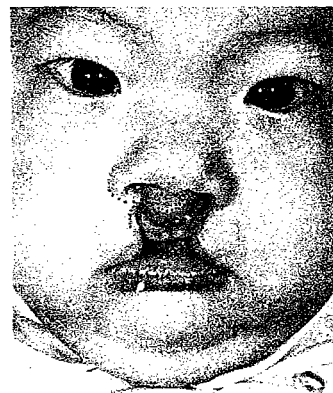4. The lateral lip elements were brought together in the midline, with suturing of the posterior mucosa and the muscles.

5. The prolabium was brought back into the center of the lip, and a dimple stitch from prolabium dermis to the muscles fitted it in position.

6. Lateral vermilion flaps carrying the mucocutaneous junction ridge were brought together under the inferior border of the prolabium overlapping the turndown flap of prolabium vermilion.

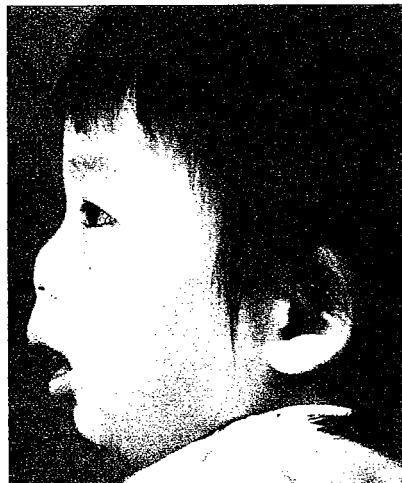7. The alar bases freed by circumalar incisions were divided into a deep subcutaneous flap and a skin flap. The subcutaneous

6-21-73. Ear tubes, soft palate closure, first-stage lip closure

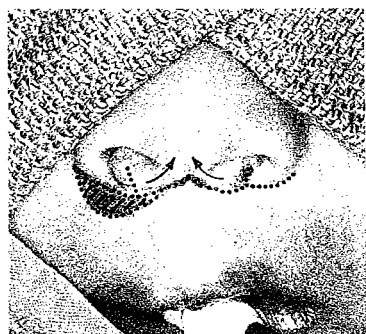
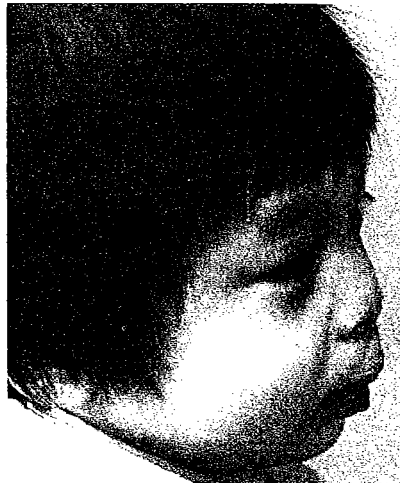
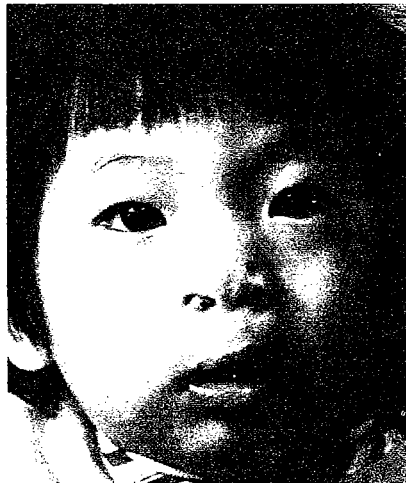
flaps were sutured to each other at the septum to correct the alar flare.

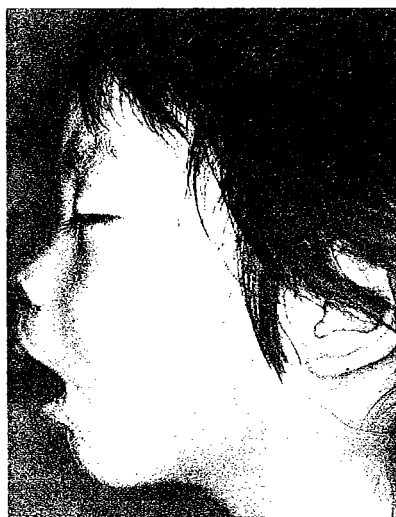8. The forked flap was sutured to the alar base skin flaps in "praying hands" pyramids.



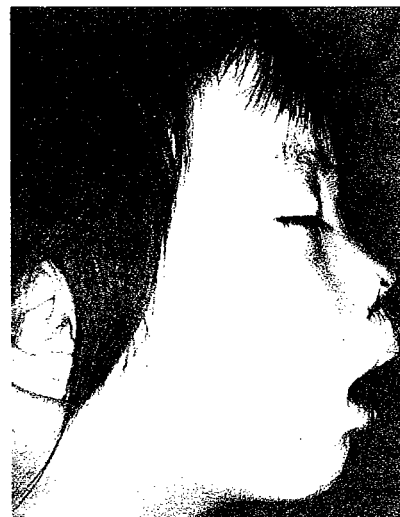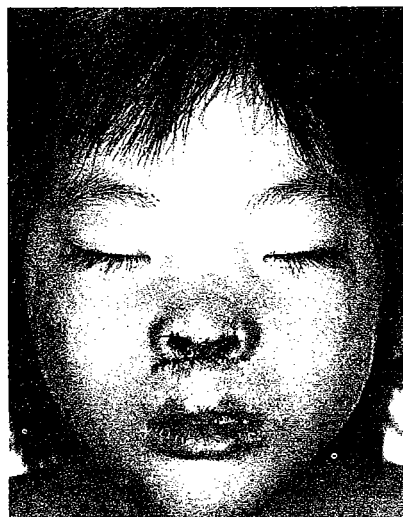18 months



At 3½ years the patient was brought back from Japan for the banked fork to be shifted into the columella for tip release and for right-sided lip lift.

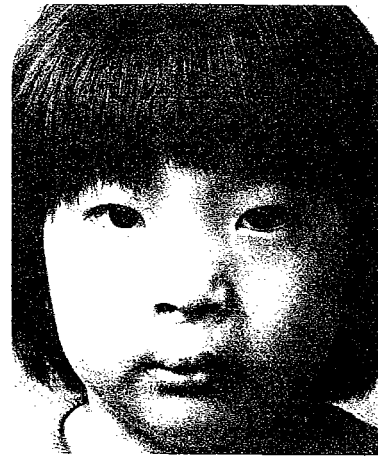

3½ years



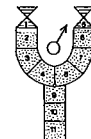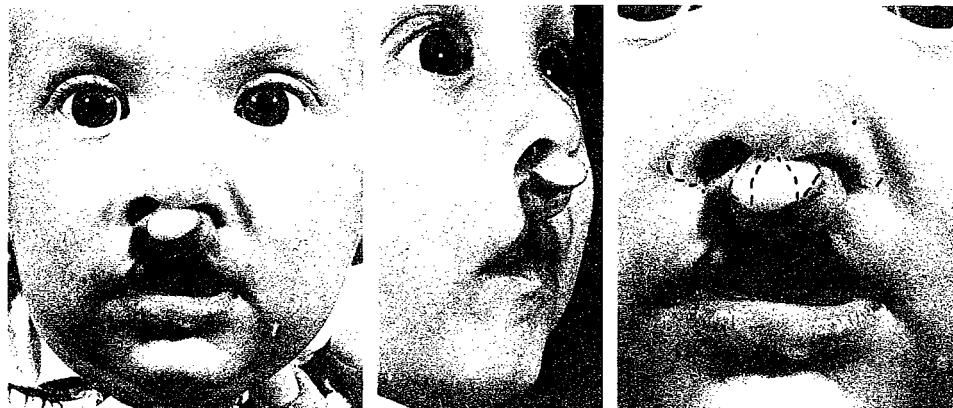A disadvantage of the praying hands banking, besides slight shrinkage of the flaps, is that little additional tissue can be added to the fork at the time of columella lengthening.

Lip will require further lift on the right side when final scar and nasal revisions are done.



4 years

Complete clefts except for tiny right Simonart's band



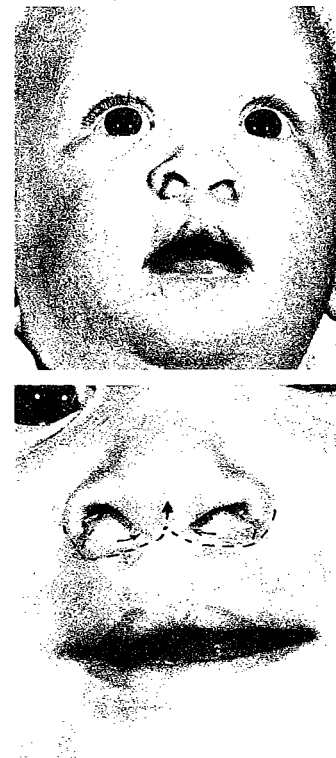
B.D. 8-10-69
 F.H. No clefts
 F.T. Uneventful
 O.C.A. None

1-8-70. Lip closure

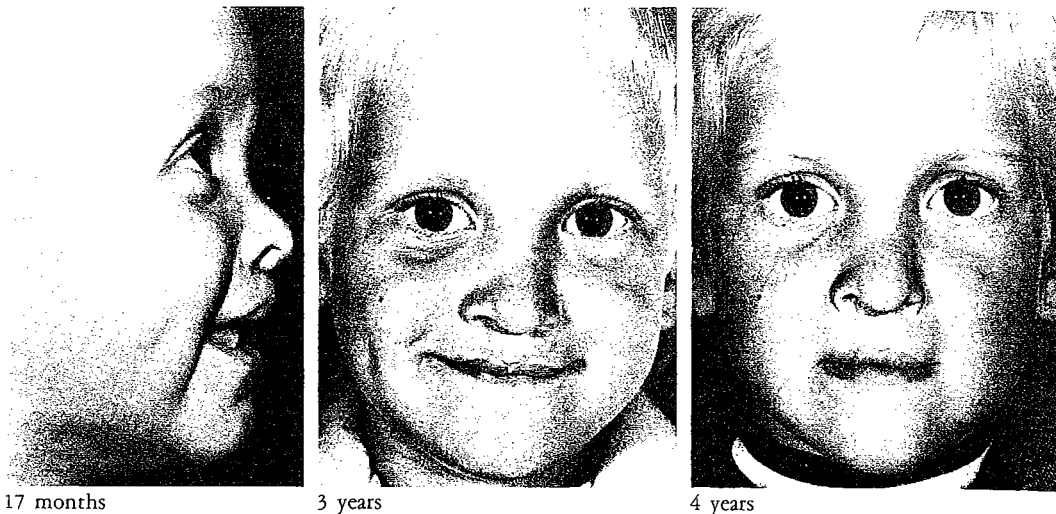At five months of age one-stage lip closure was performed.

1. The prolabium was freed from the premaxilla, and the lateral lip elements were freed from the maxillae.
2. A forked flap was pared from the sides of the prolabium.
3. Lateral mucosa and muscle were united behind the prolabium.
4. Lateral vermilion flaps carrying the mucocutaneous ridge were used to overlap the prolabium vermilion. The prolabium mucocutaneous ridge was vague.
5. The forked flap prongs were tubed slightly and then let into the incision between lip and alar base in whisker position.

Three months later, at eight months of age, the forks were advanced into the columella with the aid of a membranous septal incision. The alar bases were advanced medially.



4-14-70. H.P., S.P.
 11-17-70. Push-
 back closure of
 palate



17 months

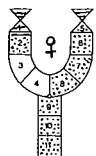
3 years

4 years

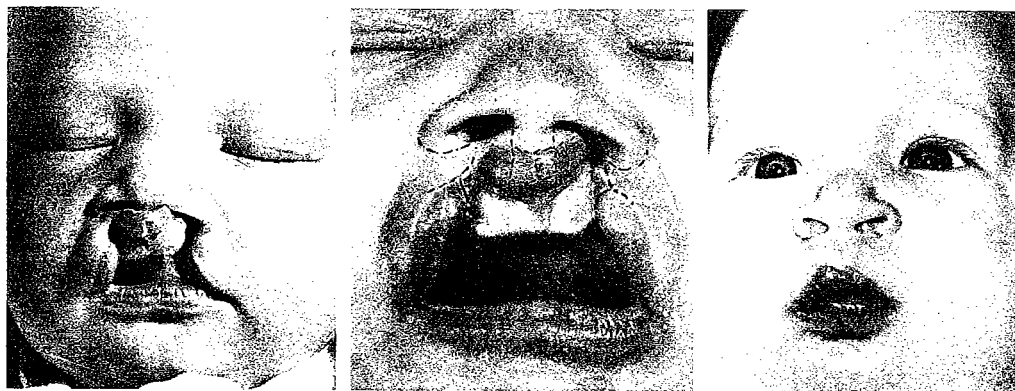Comment. In spite of early columella lengthening, lip did not lengthen too much in vertical dimension.

Again, an early cartilage strut would have offered a supportive advantage.

Asymmetrical incomplete and complete clefts



B.D. 9-13-70
 F.H. No clefts
 F.T. Uneventful
 O.C.A. None



11-6-70. Lip closure

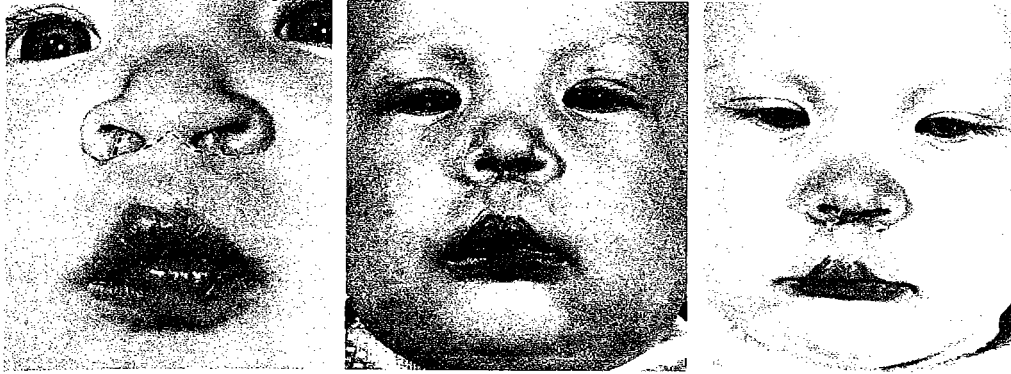Elastic band traction from headcap was used to restrain the premaxilla. At two months of age one-stage lip closure was done.

1. The prolabium was freed from the premaxilla, and the lateral lip elements were freed from the maxillae.
2. A forked flap was pared from the sides of the prolabium including some Simonart's band on the right.
3. Lateral mucosa and muscle elements were sutured together in the midline behind the prolabium.
4. A dimple stitch was made in the prolabium.
5. Lateral vermilion flaps carrying the mucocutaneous junction

tion ridge were used to overlap the prolabium vermillion.

6. The forked flap was sutured to the alar base flaps in a "praying hands" pyramid.

At four months of age the forked flap lengthened the columella.

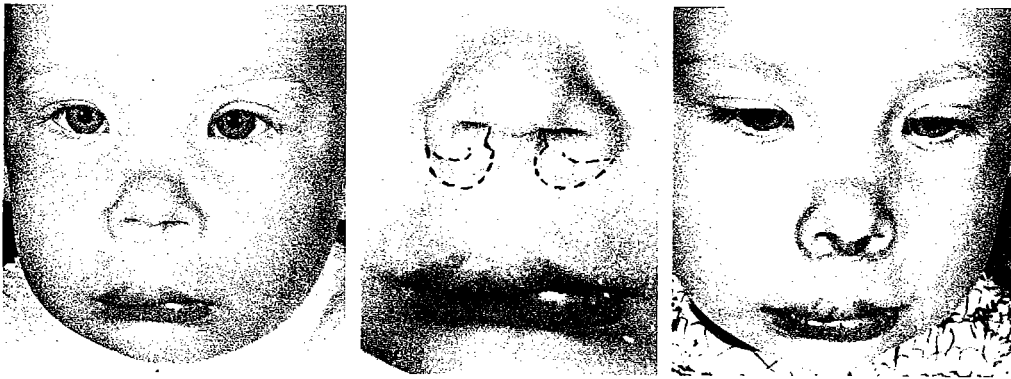

1-26-71. Forked flap

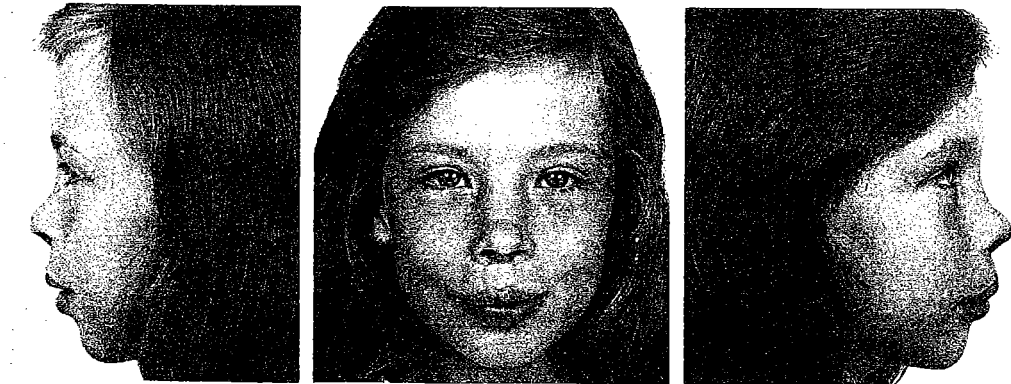H.P. and S.P. 10-21-71. Vomer flap and Langenbeck flaps closed palate cleft

Columella lengthening was effective, but early action in this regard ended up with a lip too long vertically and some retraction of the columella. This result stimulated the use of transverse upper lip flaps based on the alar bases and transposed behind the columella into a membranous septal releasing incision with correction of columella retraction and lip length.

3-28-73. Lip flap behind columella

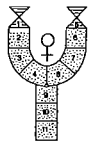

Comment. Early columella lengthening at 4 months resulted in long lip. Time and growth should improve the nose.

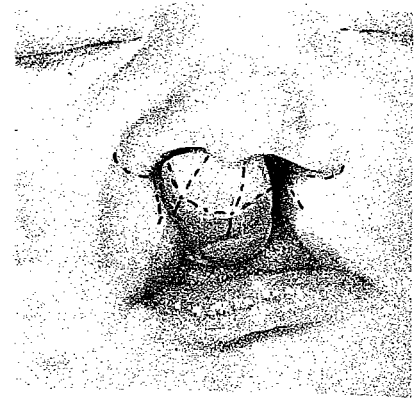
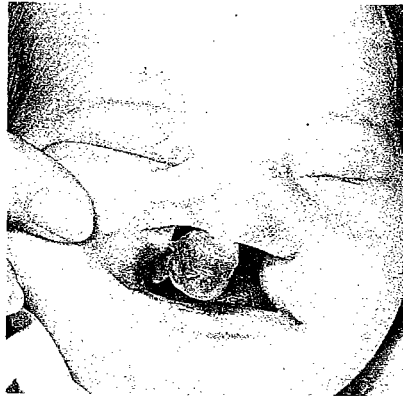

7 years old and improving

Complete clefts (except for tiny Simonart's band)



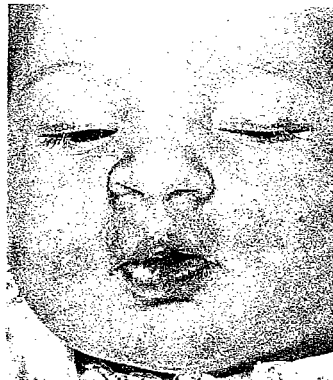B.D. 12-29-71
 F.H. No clefts
 F.T. Uneventful
 O.C.A. Hydrocephalus



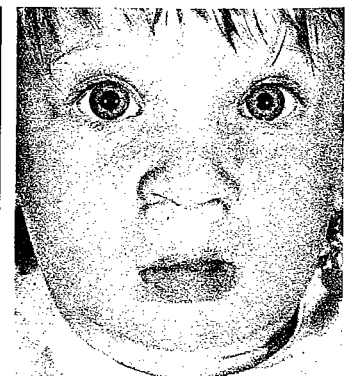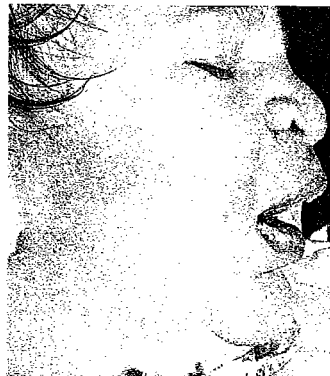Rubber band traction from headcap was used against the projecting premaxilla. At six weeks of age one-stage bilateral cleft lip closure was carried out.
 2-10-72

1. The prolabium was freed from the premaxilla, and the lateral lip elements were freed from the maxillae.
2. A forked flap was pared from the sides of the prolabium.
3. Upper mucosal flaps from the lateral cleft edges were inserted into the vestibular alar base releasing incisions.
4. Lateral mucosa and muscles were united in front of the premaxilla behind the prolabium.
5. The alar bases were freed from the lip elements, denuded of epithelium at their tips and sutured to each other on the septum behind the columella with Mersilene.
6. A dimple stitch of Mersilene was made in the prolabium.
7. Lateral vermilion flaps carrying the mucocutaneous ridge were used to overlap the prolabium vermilion.
8. The forks were rolled on themselves and set into incisions between the alar bases and the lip as a whisker-style banking.

10-6-72. Myringotomy, suction and tube insertion by F. Pullen; soft palate closure

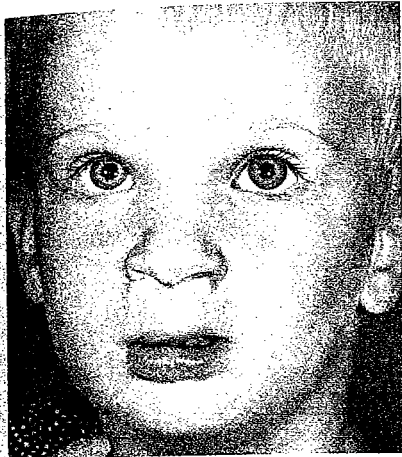

2 weeks postoperative

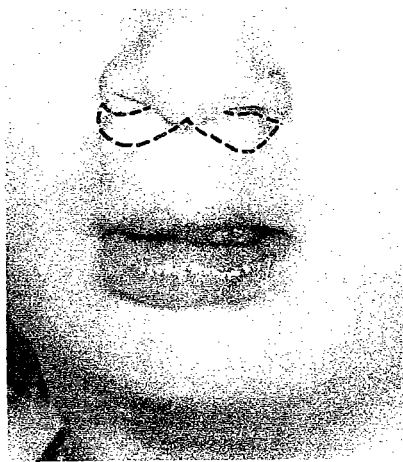

1 year old

Lip healed with good muscle continuity and forked flap remained banked as whiskers until four years.

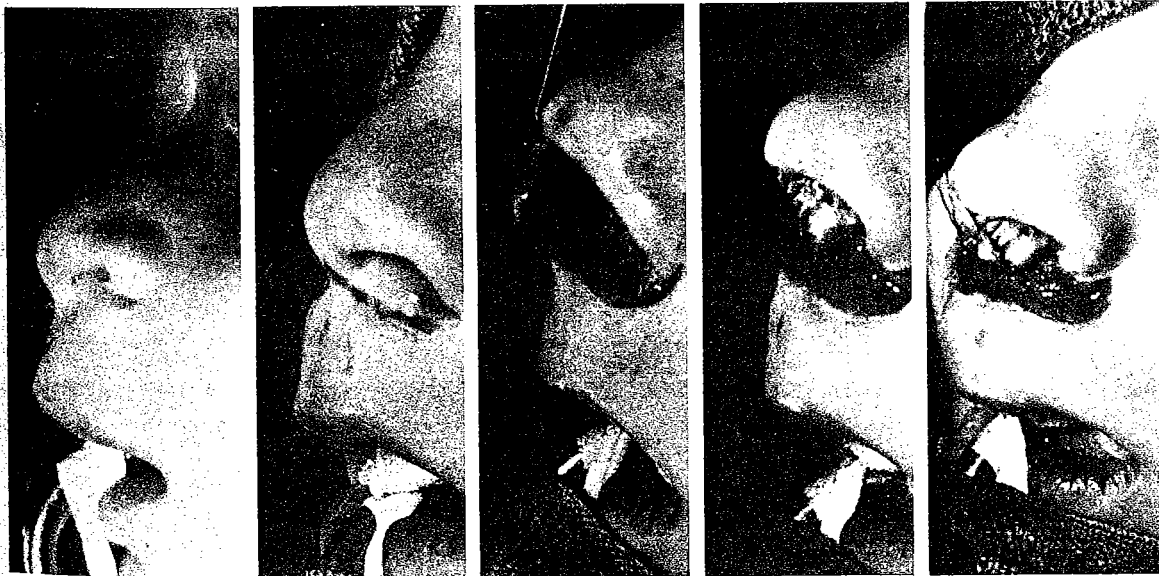


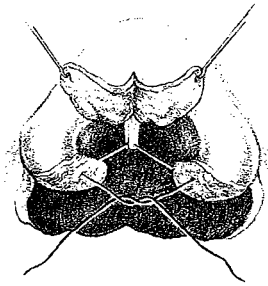
2½ years



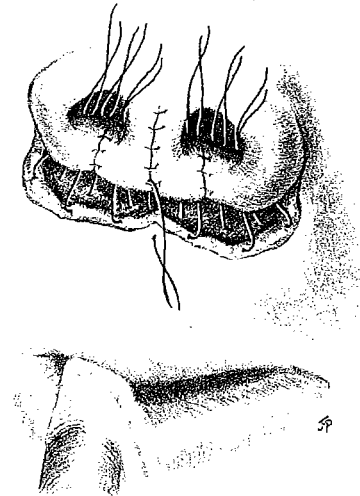
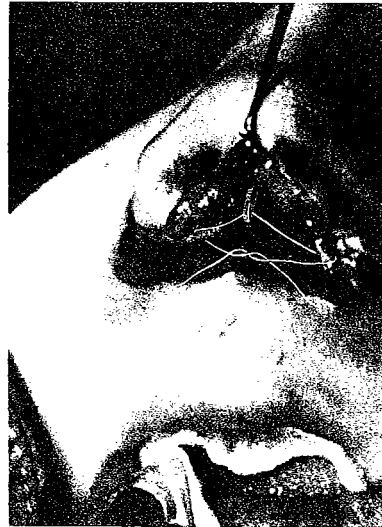*A 1976 shift of forked flap
from whiskers to columella*

At four years, and at the same time as the hard palate closure, the forked flap was shifted into the nose. A semi-cine of the profile action shows the forked flap marked, elevated out of the whisker position in the lip, united in front with 6-0 silk, rolled into a column behind with 4-0 chromic, rising free with release of the snubbed tip by a membranous septal incision and advanced into the columella with its tips splayed at the base.

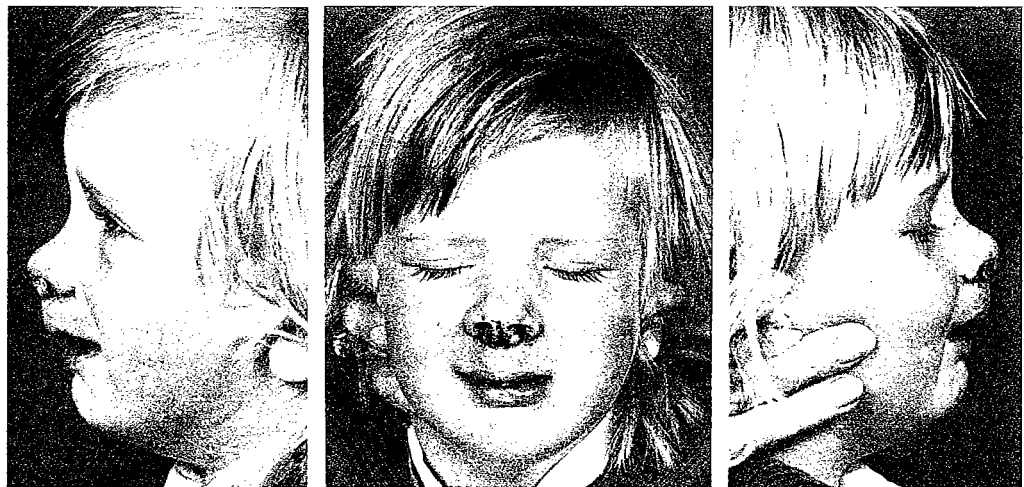



Subcutaneous extensions of the freed alar bases were sutured to each other on the septum at the nasal spine with 4-0 Mersilene to correct the alar flare. This action so reduced the width of the nasal base as to leave a discrepancy with its longer matching edge along the defect in the upper lip. It has been found, however, that the discrepancy can be accommodated as the lip is lifted back up to the nose and the airways can be maintained at the same time.



The use of 4-0 chromic catgut mattress sutures passing from inside the floor of the nose out to pick up the muscle of the lip and back again inside the nose can force a matching of edges which 6-0 sutures in the skin can finish neatly.

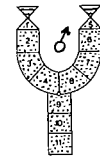
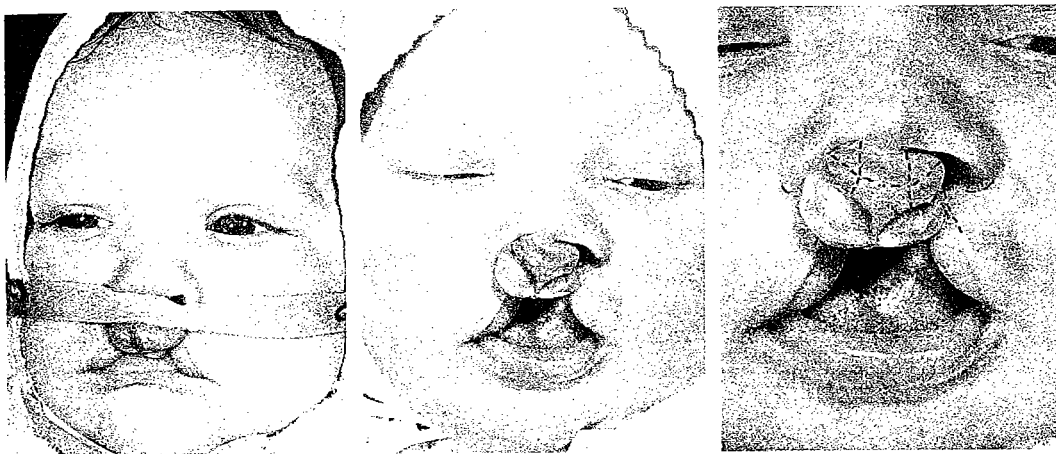


5 days after advancing fork



3 weeks after advancing the fork

Complete clefts



B.D. 1-20-72
 F.H. Paternal uncle has two boys, one with bilateral, the other with unilateral cleft lip.
 F.T. Uneventful
 O.C.A. None

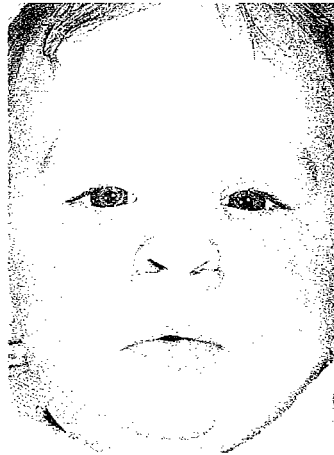3-16-72

Elastic traction on headcap was used for positioning the premaxilla. At six weeks of age bilateral cleft lip closed in one stage.

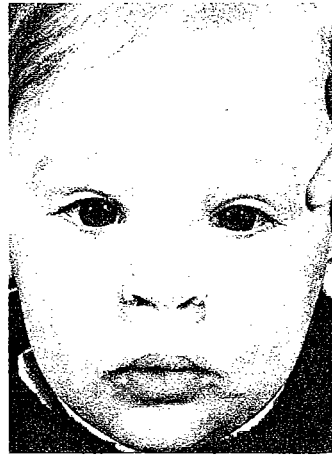1. The prolabium was freed from the premaxilla, and the lateral lip elements were freed from the maxillae.
2. A forked flap was pared from the sides of the prolabium.
3. Mucosa and muscles were united behind the prolabium.
4. A Mersilene dimple stitch was made.
5. Lateral vermilion flaps carrying the mucocutaneous ridge were used to overlap the prolabium vermilion.
6. The forked flap was banked in subalar whisker position.

11-21-72. Myringotomy, suction and tubes inserted, soft palate closed

Comment: Good lip with continuity of mucocutaneous ridge



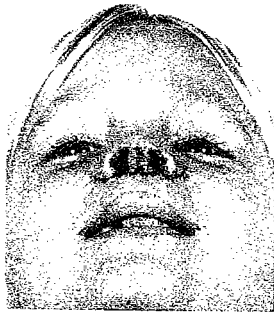3 months postoperative



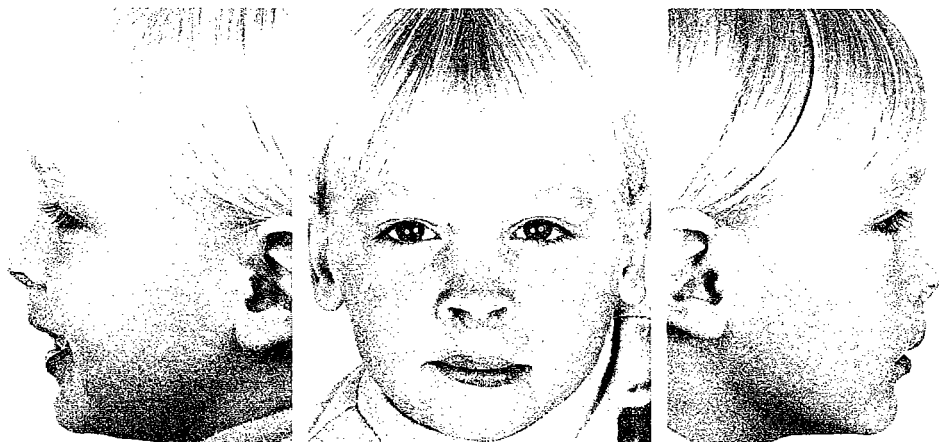10 months of age



3 years



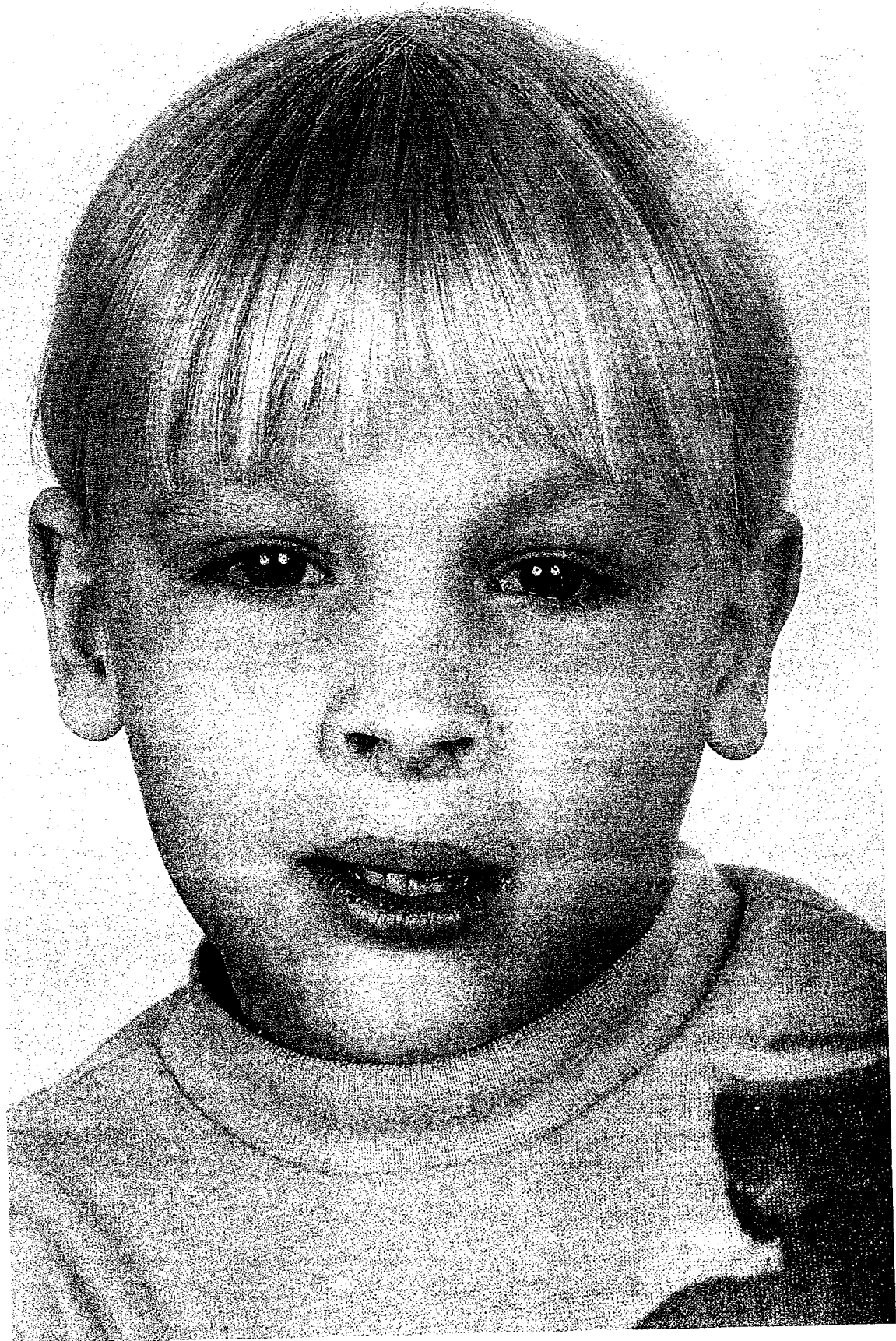
At age 4½ years, forked flap was advanced from whisker banking position into the columella to release the nasal tip. This patient started with no columella and only a moderate sized prolabium. The early postoperative pictures and the later color page vindicate this compromise of sharing the prolabium as he now has a good philtrum and plenty of columella.



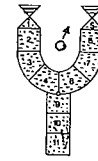
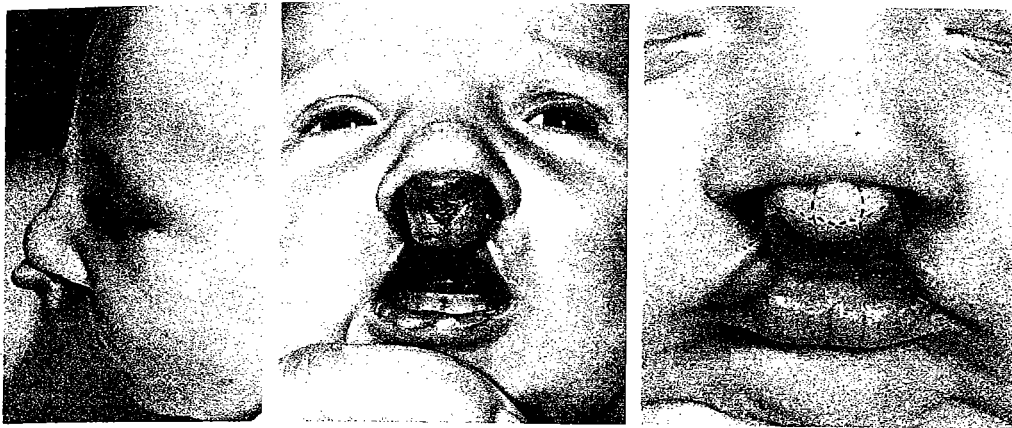
Comment: Note continuity of the mucocutaneous ridge.

5 months after advancing fork

An advantage of the whisker banking, besides preservation of the fork, is that extra tissue can be incorporated secondarily in the fork if necessary at the time of the advancement.



Complete clefts

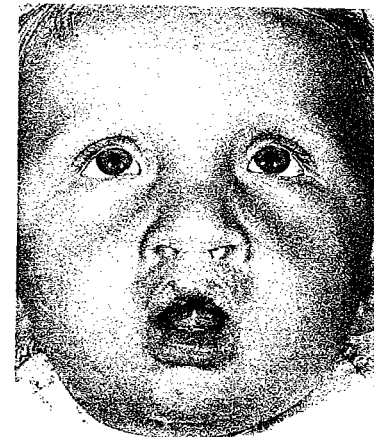

B.D. 6-16-71
 F.H. No clefts
 F.T. Severe
 flu
 O.C.A. None

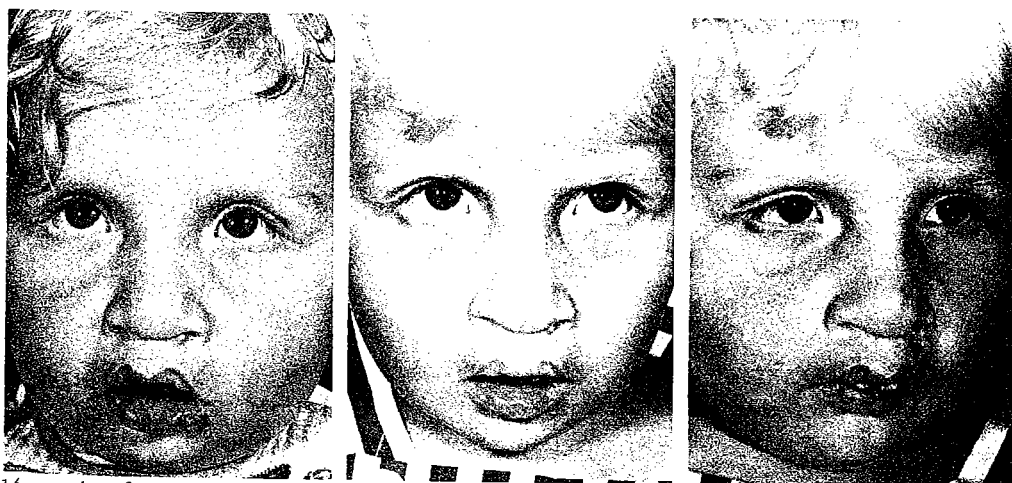Elastic restraint from headcap was used against the premaxilla. At age three months, one-stage lip closure was accomplished.

9-14-71. One-stage lip closure

1. The prolabium was freed from the premaxilla, and the lateral lip elements were freed from the maxillae.
2. A forked flap was pared from the sides of the prolabium.
3. Lateral mucosa and muscles were joined in the midline behind the prolabium.
4. Lateral vermilion flaps carrying the mucocutaneous ridge were used to overlap the prolabium vermilion.
5. The forked flap was sutured end to end with the alar base flaps in "praying hands" banking.



7 months postoperative



14 months of age

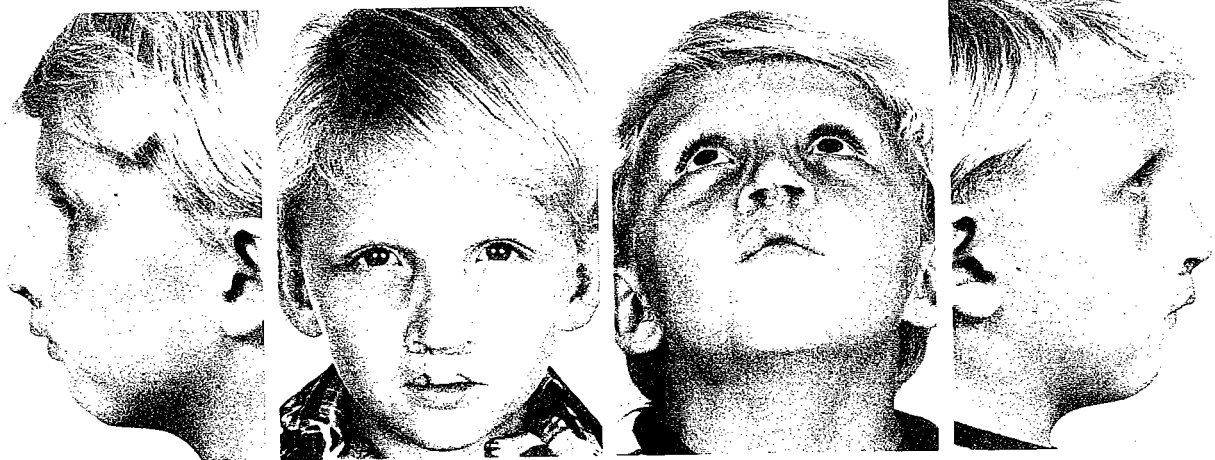
2 years old

S.P. 5-9-72, Soft palate closure.

Comment. Cupid's bow is too wide.

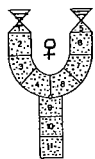
At 5 years of age the premaxilla was set back by subperiosteal block wedge resection of the vomer and fixation with a Kirschner wire and tray splint by Berkowitz.

Six months later the forked flap banked in praying hands position was redeveloped by parallel incisions, opened for lengthening and advanced into the columella with the aid of a membranous incision. The alar bases with subcutaneous extensions followed in the wake of the forks and were sutured to each other at the nasal spine to narrow the nose and elevate the tip.

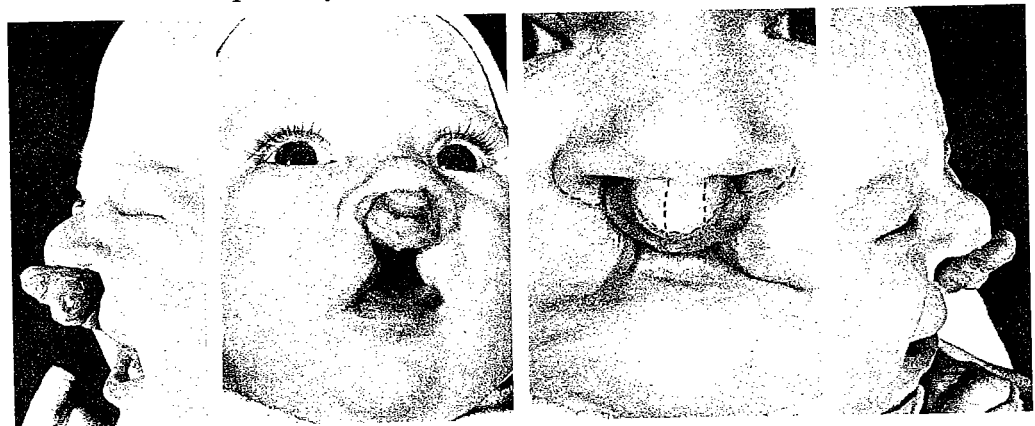


5½ years

Complete clefts



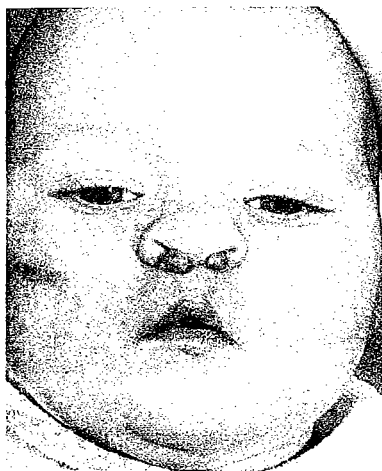B.D. 12-2-71
 F.H. Father unilateral CLP and uncle also had cleft
 E. T. Uneventful
 O.C.A. None



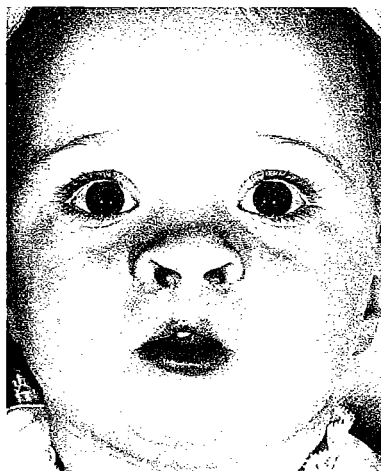Rubber band traction from headcap was used against the premaxilla for two months. At age two months one-stage lip closure was undertaken.

2-3-72. Cleft lip closure

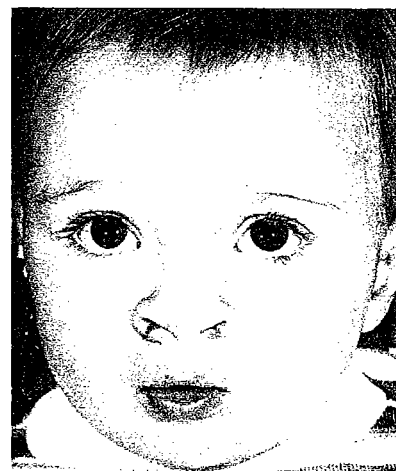1. The prolabium was freed from the premaxilla, and the lateral lip elements were freed from the maxillae.
2. A forked flap was pared from the sides of the prolabium.
3. Lateral mucosa and muscles were united across the cleft in front of the premaxilla behind the prolabium.
4. A Mersilene dimple stitch was made in the prolabium.
5. Alar base flaps were freed from the lip elements, denuded of epithelium at their tips and sutured to each other on the septum behind the columella to reduce and prevent alar flare.
6. Lateral vermilion flaps carrying the mucocutaneous ridge were used to overlap the prolabium vermilion.
7. The forks were rolled on themselves and sutured tip to tip in front of the columella.



2 weeks postoperative



8 months postoperative



1 year old

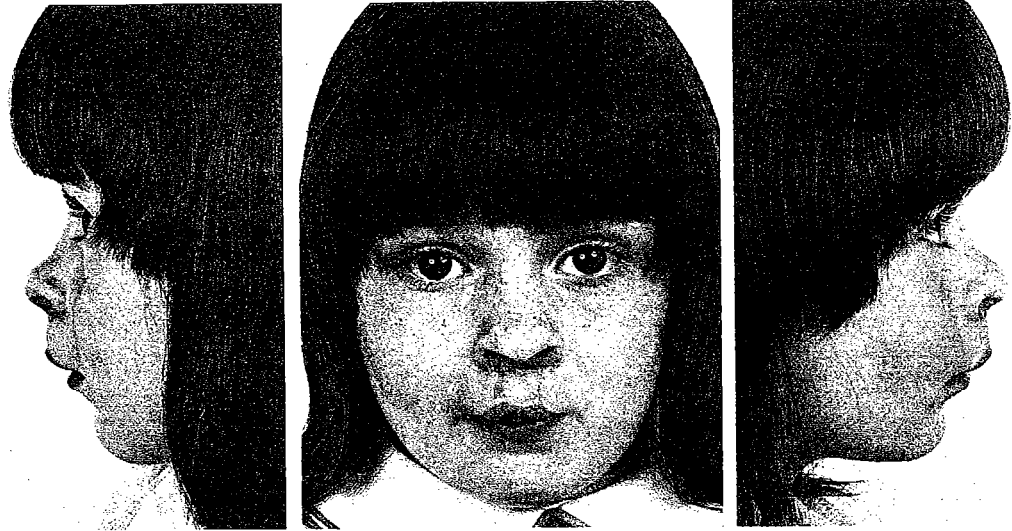11-28-72. Soft palate closure

At one year of age the soft palate was closed, and at the same time the fork polyps were opened and sutured to the alar bases in the "praying hands" position. After one other such case, the polyp-like banking was discontinued and the "praying hands" or whiskers type preferred.

At 4½ years the banked fork was advanced into the columella.



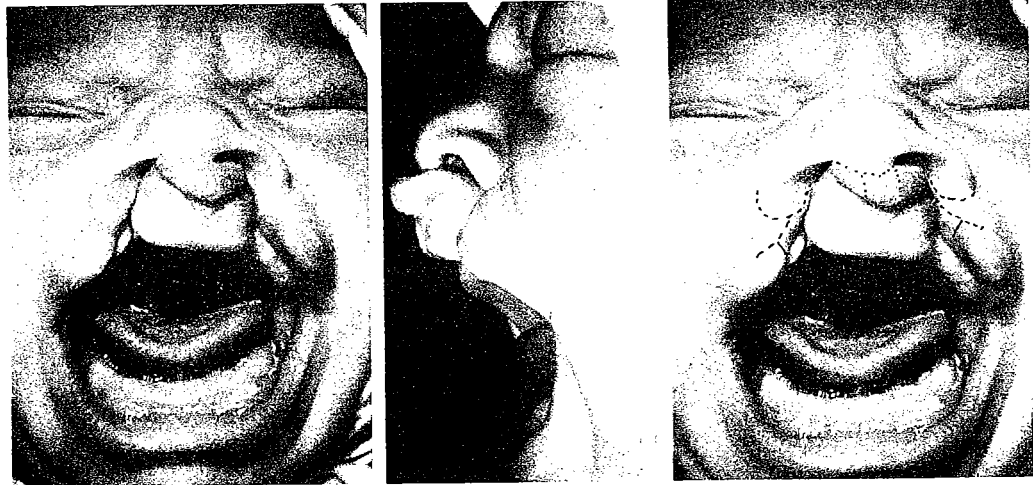Comment. Note good lip, continuity of mucocutaneous ridge, position of alar bases and columella length.



4½ years

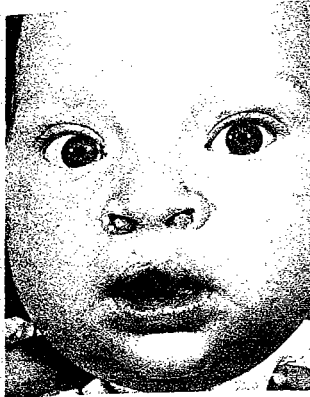Complete clefts

B.D. 1-7-70
 F.H. No clefts
 F.T. Uneventful
 O.C.A. I.Q. 53

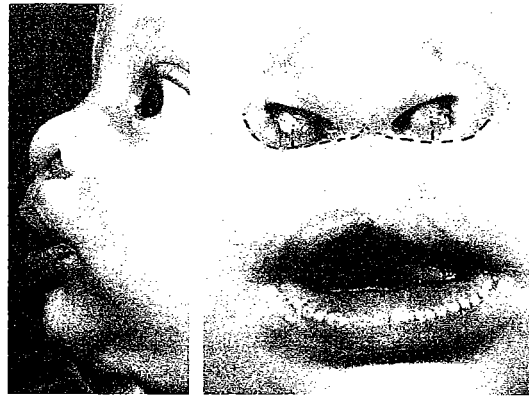


3-4-70. Lip closure done. Elastic band traction from headcap was used against the projecting premaxilla. At two months of age one-stage lip closure was done.

1. The prolabium was freed from the premaxilla, and the lateral lip elements were freed from the maxillae.
2. A forked flap was pared from the sides of the prolabium.
3. Lateral mucosa and muscle were joined behind the prolabium.
4. Lateral vermilion flaps carrying the mucocutaneous junction ridge were used to overlap the prolabium vermilion.
5. The forked flap was sutured to the alar base flaps in "praying hands" pyramids.



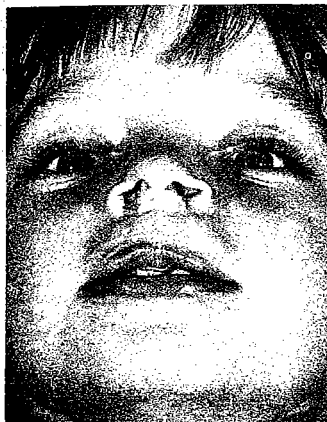3 months postoperative



7-29-70. Forked flap and dimple stitch

10-14-70. H.P., S.P. Closure of palate cleft

Five months later, at age seven months, the forked flap was advanced into the columella with release of the nasal tip. At this time prolabium skin was elevated from above, and deep tissue was removed from the center of the philtrum and a dimple stitch placed.



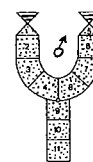
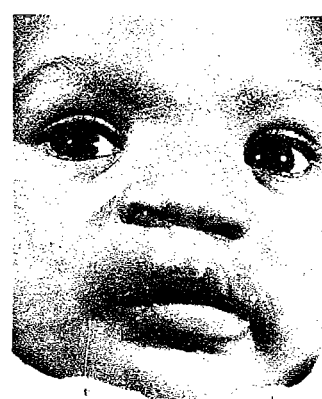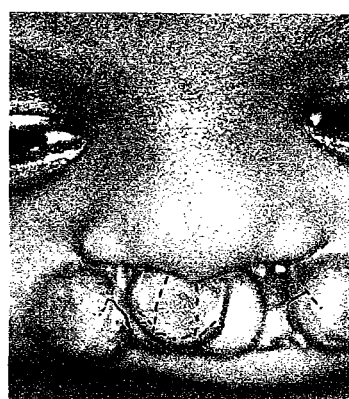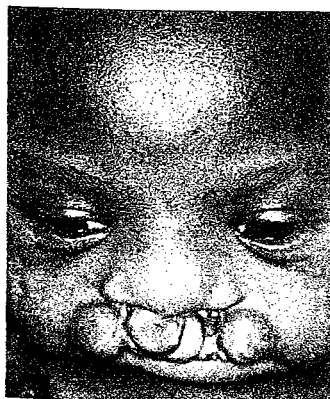3 1/2 years old



Comment. Forked flap in columella broadened and pulled back into lip. Will require secondary thinning and re-advancement before school age.

A temporary homologous septal cartilage strut inserted behind the forked flap into the nasal tip would have maintained better support. An autogenous strut will be used at 15 to 16 years.

Complete clefts



- B.D. 6-14-70
- F.H. No clefts
- F.T. Uneventful
- O.C.A. Slightly bifid nose

Rubber band traction from headcap was used against the projecting premaxilla. At two months of age one-stage lip closure was carried out.

8-26-70. S.P. closed; lip closure

1. The prolabium was freed from the premaxilla, and the lateral lip elements were freed from the maxillae.

2. A forked flap was pared from the sides of the prolabium.

3. Lateral mucosa and muscle were joined behind the prolabium.

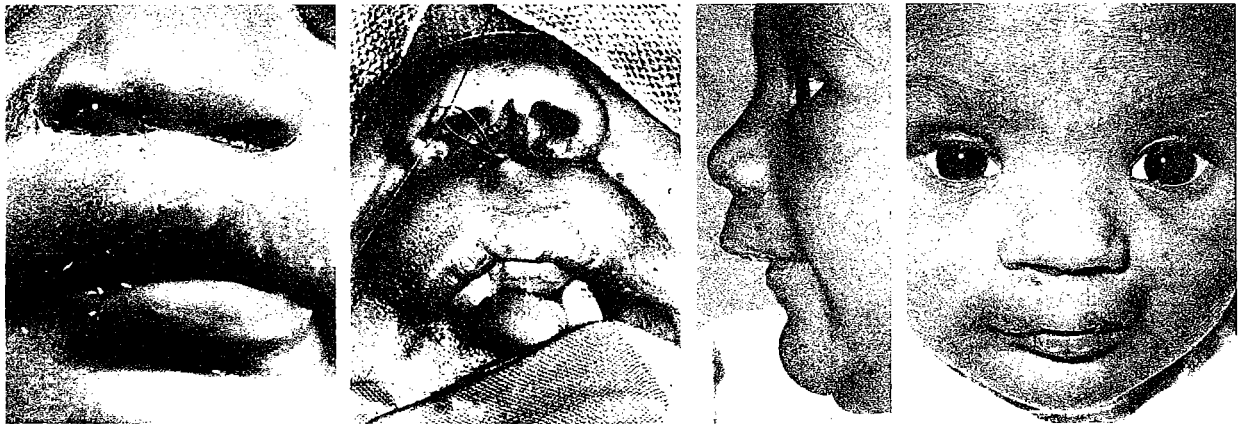
4. Lateral vermilion flaps carrying the mucocutaneous ridge were used to overlap the prolabium vermilion.

5. The forked flap was sutured to the alar base flaps in "praying hands" pyramids.

6. The soft palate was closed.

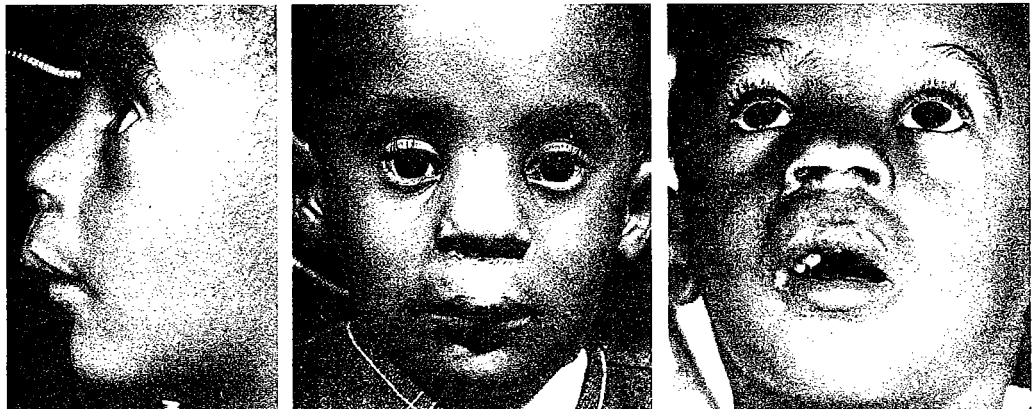9-23-70. Forked flap

At three and a half months of age the forked flap was used to lengthen the columella.

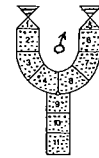
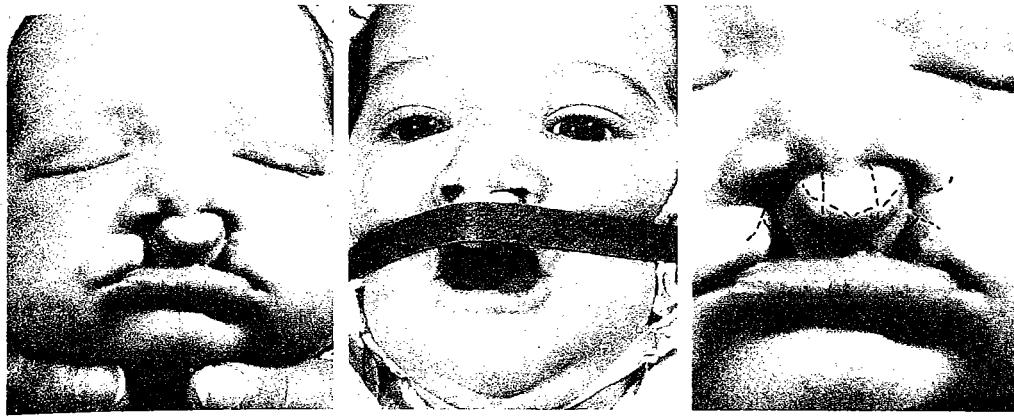

1 year

Comment. 1. Very early columella lengthening with only slight lip lengthening.
2. Bifid nasal tip still needs corrective surgery.



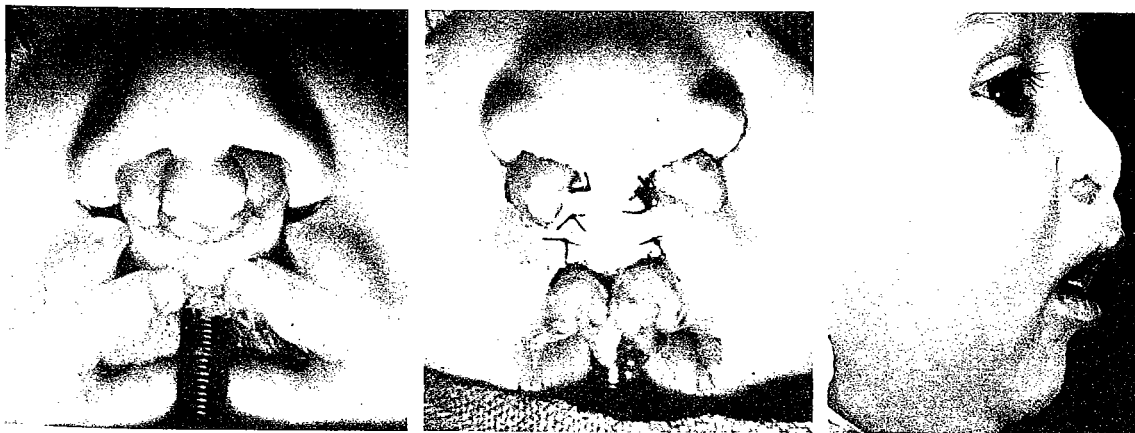
Complete clefts



B.D. 11-12-69
 F.H. Mother had bi-lateral CLP
 E.T. Uneventful
 O.C.A. None
 2-3-70. Lip closure

At three months of age one-stage lip closure was done.

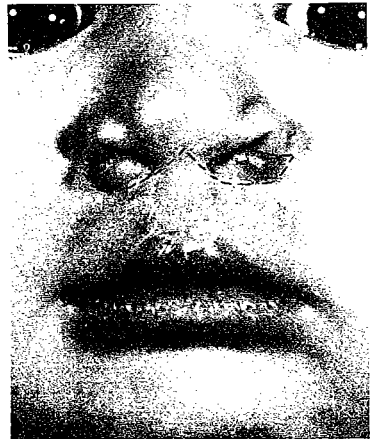1. The prolabium was freed from the premaxilla, and the lateral lip elements were freed from the maxillae.
2. A forked flap was pared from the edges of the prolabium.
3. Mucosa and muscle of the lateral elements were sutured to each other behind the prolabium.
4. Lateral vermilion flaps were used to overlap the prolabium vermilion. The mucocutaneous ridge of the prolabium was retained.
5. The forked flap was banked whisker fashion between lip and alar bases.



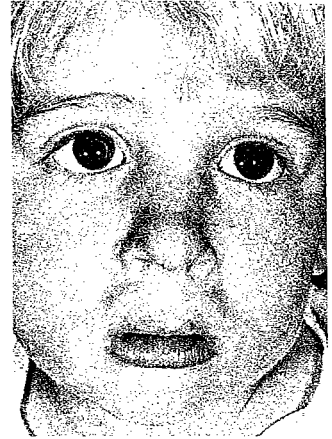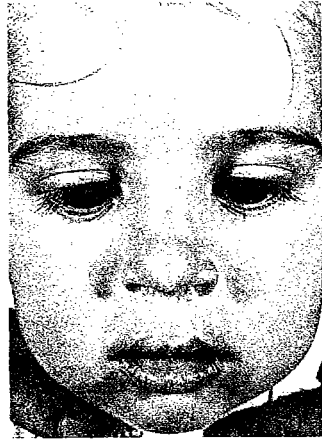4-23-70. Forked flap

At five months of age the forked flap was advanced into the columella.

H.P., S.P. 12-10-70
 H.P.
 Vomer flap
 S.P.
 Pushback with island flap



14 months

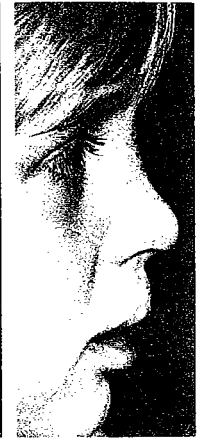

2 years

Comment. No attempt at primary medial advancement and fixation of alar bases resulted in final flare requiring later reduction. Early forked flap without getting long lip.

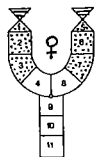


4 years



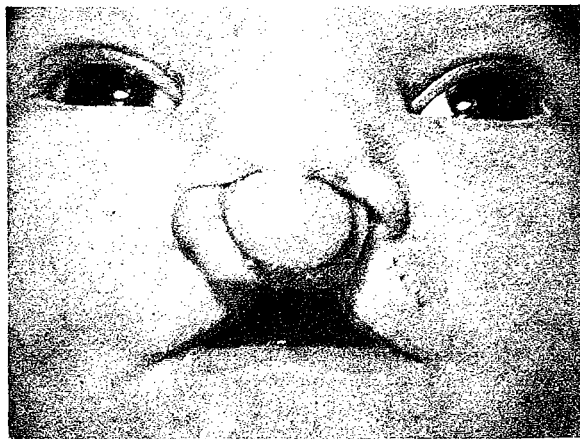
An autogenous septal cartilage strut in the columella will eventually perfect this result.

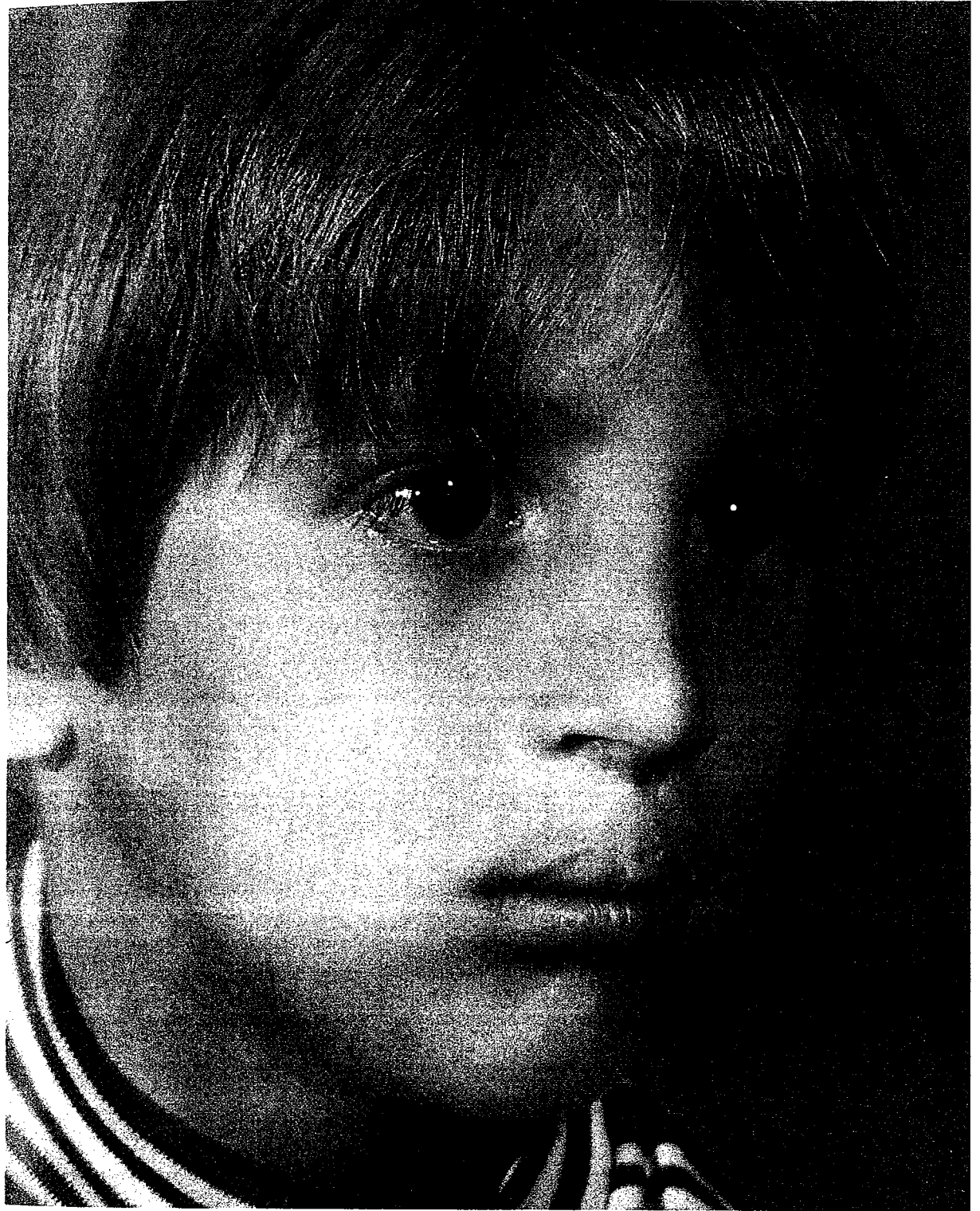
Complete clefts




B.D. 11-2-70
 Premature
 F.H. No clefts
 F.T. Uneventful
 O.C.A. Mental retardation

1-26-71







At three months of age one-stage lip closure was carried out.

1. The prolabium was freed from the premaxilla, and the lateral lip elements were freed from the maxillae.

2. A forked flap was pared from the sides of the prolabium.

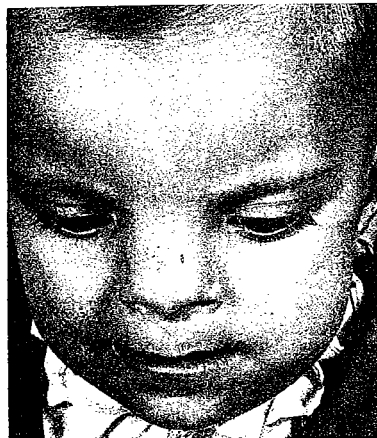3. Mucosa and muscle of the lateral elements were united behind the prolabium.

4. A dimple stitch was placed.

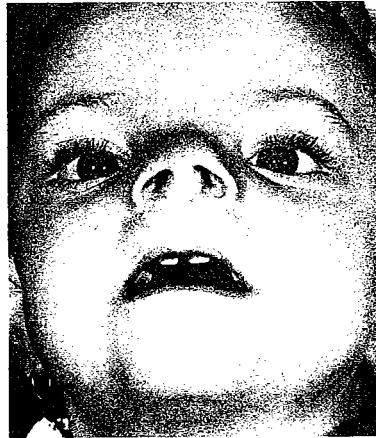5. Lateral vermilion flaps carrying the mucocutaneous ridge were used to overlap the prolabium vermilion.

6. The forked flap was banked with the alar base flaps in "praying hands" pyramids.

At six months of age the forked flap and alar bases were advanced 5-5-71. Forked flap to columella to lengthen the columella and position the alar base.



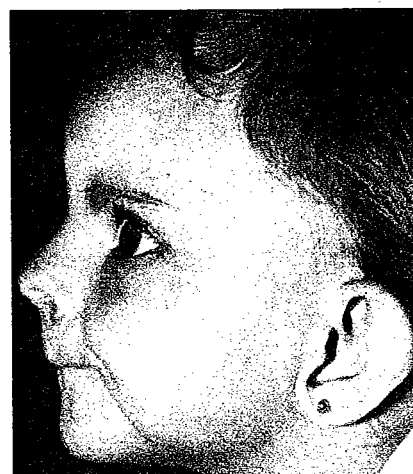2-14-73



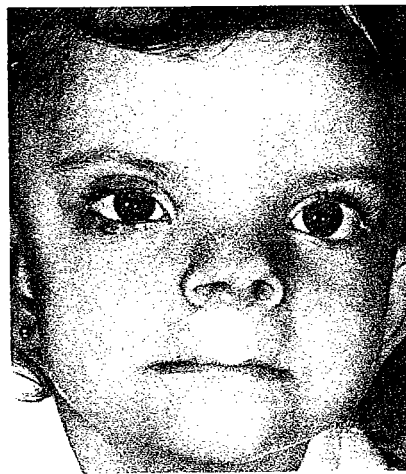2 years 3 months



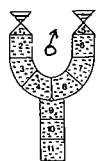
The columella was thinned by a vertical diamond excision.



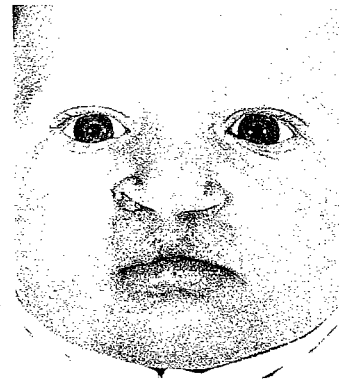
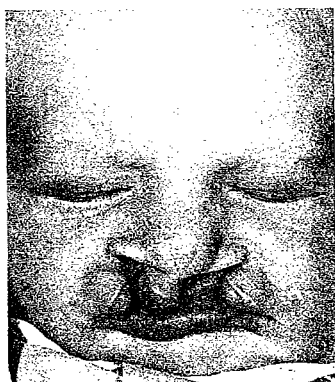3 1/2 years



Complete clefts



B.D. 8-5-71
 F.H. No clefts
 F.T. Uneventful
 O.C.A. None



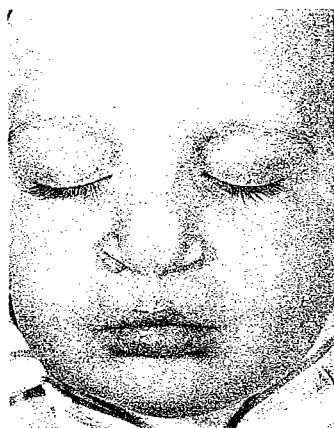1 month postoperative

9-21-71. Bilateral cleft lip closure

Rubber band traction from headcap was used against the projecting premaxilla. At six weeks of age one-stage bilateral cleft lip closure was accomplished.

1. The prolabium was freed from the premaxilla, and the lateral lip elements were freed from the maxillae.
2. A forked flap was pared from the sides of the prolabium.
3. Lateral mucosa and muscles were united in front of the premaxilla behind the prolabium.
4. A dimple stitch of catgut was made in the prolabium.
5. Lateral vermilion flaps *carrying the mucocutaneous ridge* were used to overlap the prolabium vermilion.
6. The forked flap was sutured to alar base flaps in "praying hands" pyramids.

S.P.
 5-10-72. Soft pal-
 ate closure

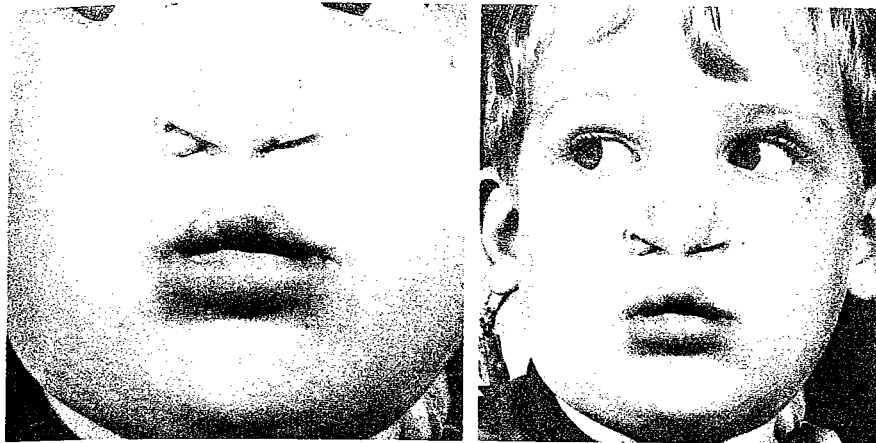

7 months postoperative



2 years old





3 years old

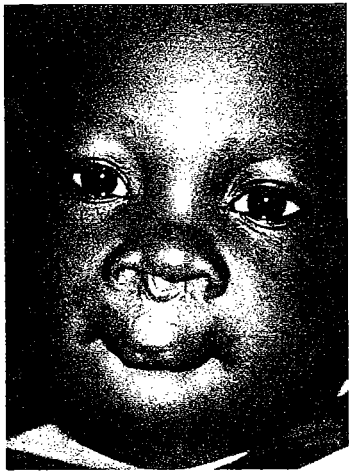
Comment. Note good lip, cupid's bow and the white roll of the continuous mucocutaneous ridge.

At 5 years of age forked flap banked in praying hands position revealed right fork but the left fork had faded into the floor of the nose. Parallel incisions and development of the forked flap-alar base strap with the aid of a membranous septal incision allowed some release of the nasal tip and lengthening of the columella without lip re-entry.



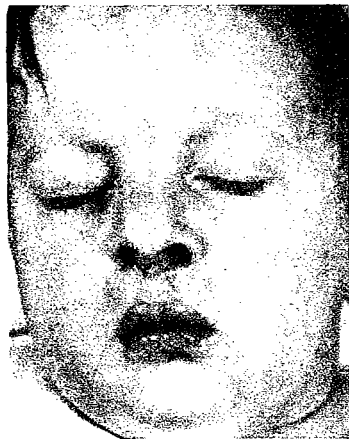5 years of age

Comment. Further columella lengthening will be required later.



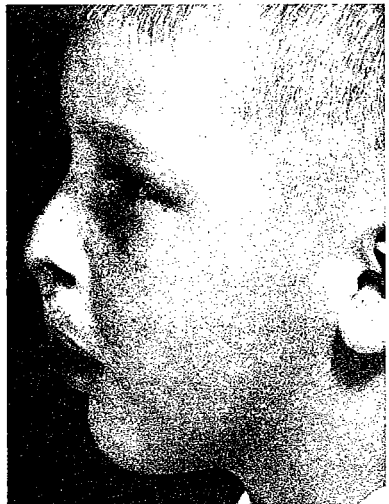Revising the early fork

When the forked flap was advanced into the columella during the first year of age, often (but not always) there was a tendency for it to be dragged partially back down into the lip and spread in width. At the same time and probably because of the same principle of muscle pull, as the child tugs the freed prolabium over the projecting premaxilla the lip increases in vertical length. A child successfully carrying out this action is shown. Although not the ideal situation and to be avoided if no other aspects of progress are lost, these minor deformities can be corrected quite easily when the child is older by simple revision. Here is a case in point.



1 month postoperative

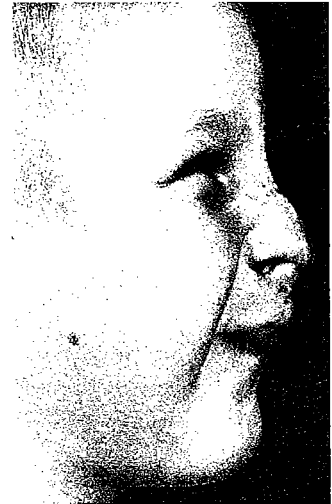A baby boy born in 1959 with bilateral CLP and protruding premaxilla had a complete cleft on one side and an incomplete cleft on the other. At three months of age a one-stage straight-line closure of both sides was obtained with lateral vermilion flaps overlapping the prolabium vermilion. Three months later, at age six months, a forked flap was advanced into the columella. Then followed the rather typical spread of the columella and partial drag of the forked flap back down into the lip along with some vertical lengthening of the lip.



1964



4-22-1966



1965

On June 24, 1966, at age six and a half years, the forked flap was thinned and repositioned and the lip shortened by high transverse excision and suture including one midline wire suture of lip to septum.



Cartilage support for the forked flap

Since the skin flaps advanced into the columella in front of and above the septum for release and elevation of the nasal tip are only soft tissue, maybe it is not surprising that they have a tendency to sag. Of course, the vigorous muscle pull of the lip is no ally. A septal cartilage strut would support and maintain the raised nasal tip, but to take the septal cartilage in infancy or childhood is unwise. For this reason I had accepted the slight sag of the tip, widening and retraction of the columella and sliding of the tails of the forked flap back into the lip. With the anticipation that these little problems could be corrected without difficulty at age 16 years and then safely maintained with an autogenous septal strut at that time, I had postponed early support.

Oneal's suggestion of temporary homologous cartilage support during the primary columella lengthening makes good sense. It would seem that banked uncarved but sliced homologous septal cartilage would serve exceptionally well as a temporary supporting strut during the primary columella lengthening and tip elevation at preschool age. This effect would last for years and possibly until autogenous septal cartilage could come to the rescue if that were ever necessary.

CONCLUSION

In an attempt to avoid the columella drag and lip lengthening following early forked flap advancement, the forked flap is now banked until school age and then shifted into the columella and sometimes supported with a banked septal cartilage strut. Long-term experience with various banking maneuvers at present has made the *whisker position* the favorite because of less shrinkage over the years and ultimately easier recutting and shifting of the fork under direct vision. It is too soon to tell whether the same secondary deformities will occur, but they probably will not. Should they appear, however, revision is not difficult and concern about it in no way justifies retaining a flat nasal deformity into school age.

Mersilene
suture is
seldom used
now because
of frequent
infections.
4-0 Vicryl
(Ethicon - 494G)
at the moment
is our favored
substitute.