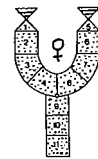
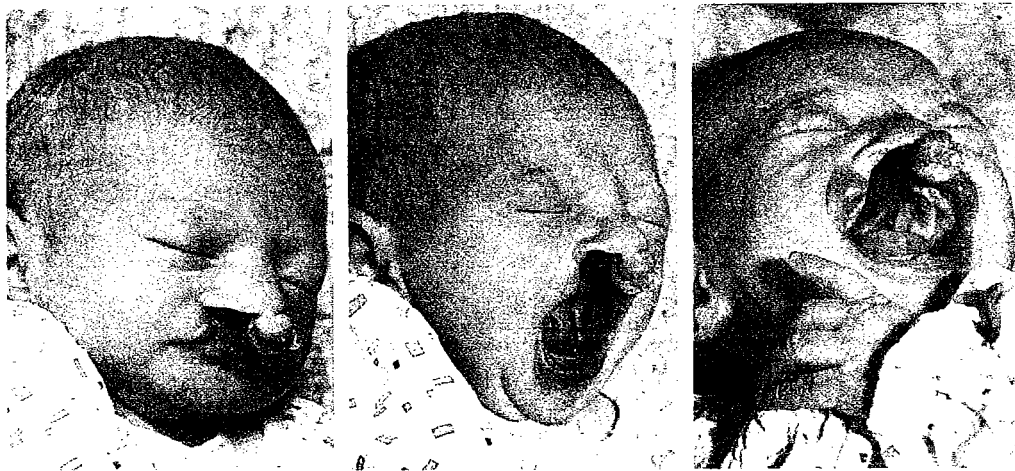
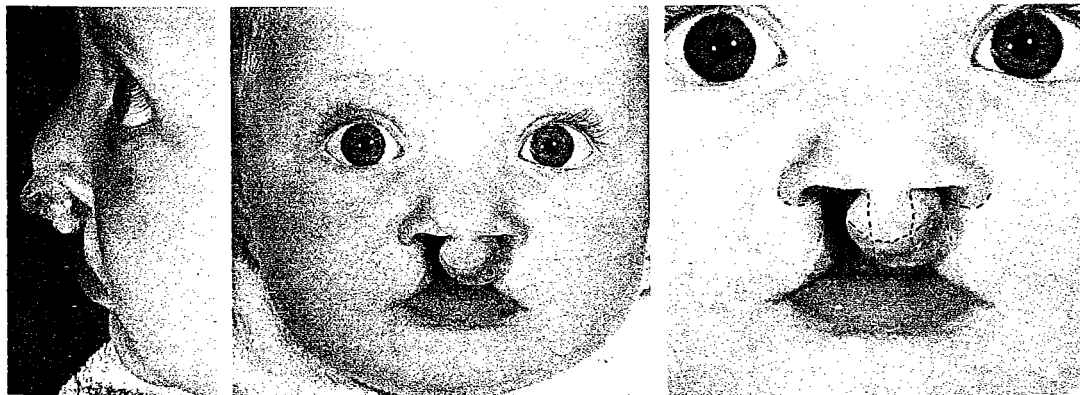
30. Personal Cases of Complete Cleft Lip Closure and Fork Banking

POLYP BANKING SHIFTING TO PRAYING HANDS



B.D. 1-31-72
 F.H. No clefts
 F.T. Uneventful
 O.C.A. None

At six months of age this baby came from Italy after having used rubber band traction from a headcap on the premaxilla.



Age 6 months

8-31-72.

1. Myringotomy. 2. Suction. 3. and tubes inserted by F. Pullen. 4. Cleft lip closure

One-stage cleft lip closure was done at age six months.

1. The prolabium was freed from the premaxilla, and the lateral lip elements were freed from the maxillae.

2. The upper mucosa of the cleft edges of the lateral lip elements was taken as flaps bilaterally and inserted into lateral releasing incisions in the vestibules behind the alar bases.

3. Forked flaps were pared from the sides of the prolabium.

4. Lateral mucosa and muscles were joined in the midline across the cleft behind the prolabium in front of the premaxilla.

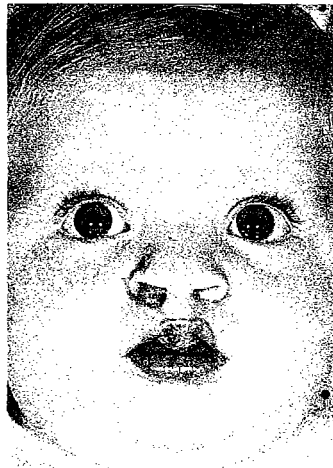5. Lateral vermilion flaps carrying the mucocutaneous ridge were used to overlap the prolabium vermilion.

6. The alar bases were freed from the lip elements and had their tips denuded of epithelium so they could be sutured to each other with 4-0 Mersilene behind the columella with reduction in the alar flare.

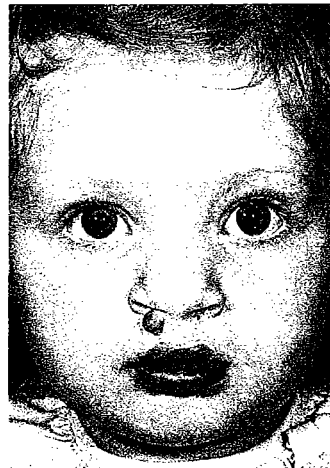7. There was no place for the forks, so they were rolled into tubes and tucked into the nasal floor.

H.P. 7-25-73.

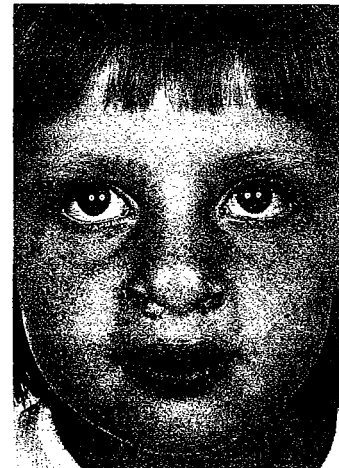Vomer flaps used in closure of cleft in palate; tubes reinserted in ears



2 weeks postoperative



18 months old



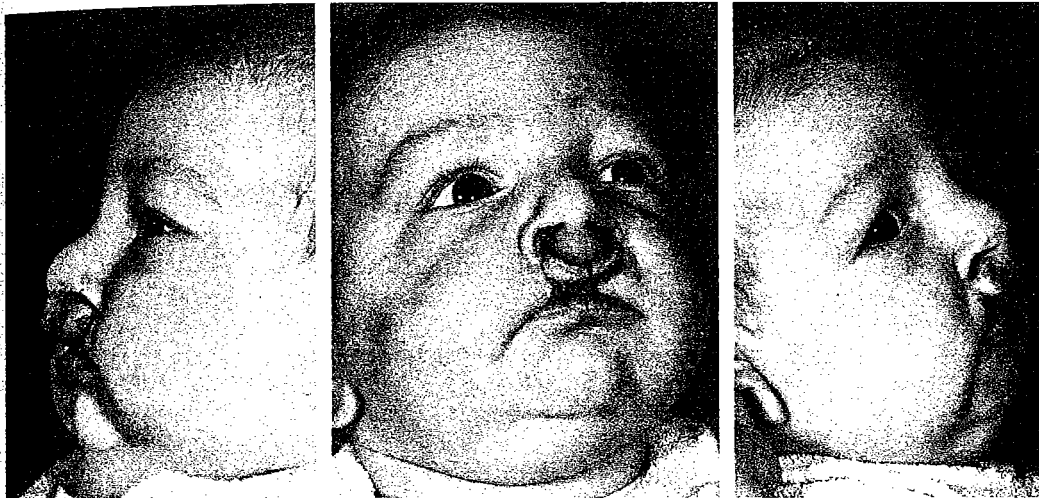5 years



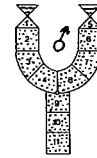
One fork was content to hide within the nostril, but the other (right) persisted in hanging out polyp-like. When the hard palate was closed, the fork polyps were opened up and joined to alar base flaps in the delayed "praying hands" position in preparation for columella lengthening before school age. *This ended the polyp-type banking* in the primary procedure. Forked flap advanced one week ago.

COMPLETE CLEFT, FIRST STAGE; FORK BANKED AS PRAYING HANDS

The patient was first seen at two months of age with premaxilla firm and forward.



2 months

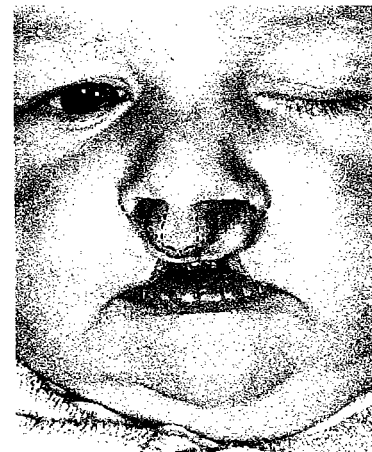


B.D. 12-8-73
F.H. Paternal
aunt had
cleft lip
F.T. Unevent-
ful
O.C.A. None

Elastic traction was used for one month. Then myringotomy was done with bilateral tube insertion, soft palate closure and first-stage lip closure with banking of forked flap.

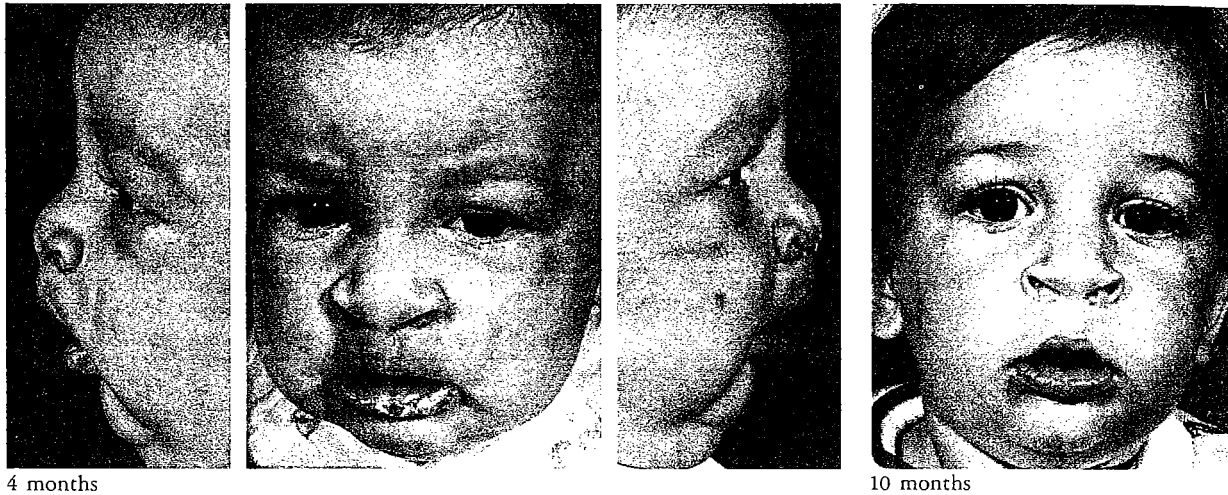
1. The prolabium was pared laterally as a forked flap and freed from the premaxilla up to the nasal spine.
2. U-shaped vermilion of the prolabium was left attached to the premaxilla to cover the raw anterior area.
3. The lateral lip elements were freed from the maxilla. The alar bases were further freed by incisions in the vestibule extending up and medially along the intercartilaginous line.
4. Upper lateral edge vermilion flaps I were sutured into the vestibular defects.
5. The lateral lip elements were brought together in the midline joining both mucosa and muscles.
6. The prolabium was set between the lateral lip segments with a dimpling stitch.
7. The remaining lateral vermilion flaps carrying a mucocutaneous junction ridge were sutured over the turndown flap of vermilion along the inferior edge of the prolabium.

3-12-74. Ear tubes, soft palate closure and first-stage lip closure



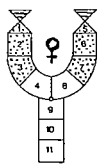
8. The alar bases were freed from the lateral lip elements by circumalar incisions. Then subcutaneous flaps were dissected from under the alar base flaps and sutured to each other at the septum, reducing the alar flare.

9. The alar base skin flaps were sutured to the forked flap as a banking procedure.

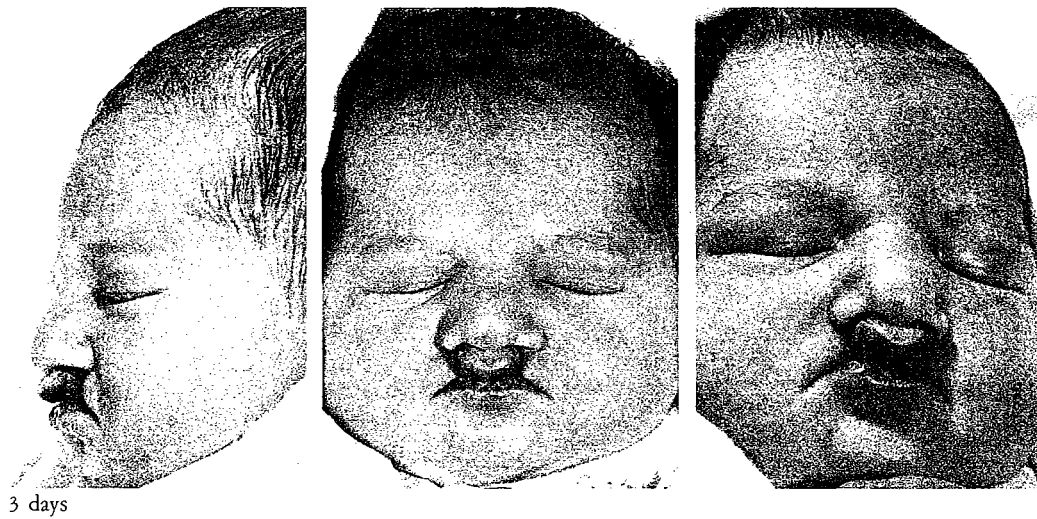

Advancement of the banked fork into the columella and reduction of alar flare will be done at about five to six years.

PREMAXILLA SETBACK, LIP CLOSURE, AND PRAYING HANDS BANKING



B.D. 10-13-74
 F.H. No clefts
 F.T. Mother thrown from horse
 O.C.A. Mucous pits of lower lip



Like the first case in Chapter 17, this infant shows bilateral complete clefts of the lip and projecting premaxilla with no cleft of the hard or soft palate.

1. A longitudinal incision was made in the mucoperiosteum covering the septovomerine stalk with subperiosteal dissection and resection of a 0.5 cm. square block of bone between the premaxilla and the swelling in the vomer. The mucoperiosteum of the sides of the premaxilla and the maxillae was turned as flaps. Then the premaxilla was set back in undercorrected position with a 3-0 chromic catgut suture between premaxilla and vomer, followed by suturing of the mucoperiosteal flaps of the premaxilla and the lateral maxillae for total closure.

2. Forked flaps were pared from the sides of the prolabium.

3. The lateral lip elements were freed from their attachments to the maxillae.

4. Excess mucosa along the cleft edges was turned as flaps to fill releasing incisions in the vestibule used to free the alar bases.

5. The prolabium was elevated from the premaxilla.

6. Lateral vermilion of the prolabium was used as flaps to cover the raw anterior surface of the prolabium.

7. The lateral lip elements were sutured to each other behind the prolabium.

8. The lateral muscles were sutured together.

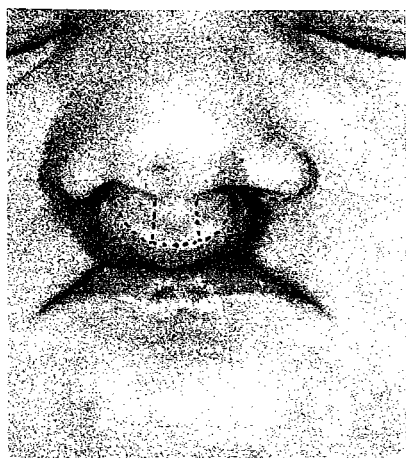9. The prolabium was replaced as philtrum with a dimple stitch.

10. Lateral vermilion flaps carrying the mucocutaneous ridge were used to overlap the turndown vermilion flap of the inferior prolabium.

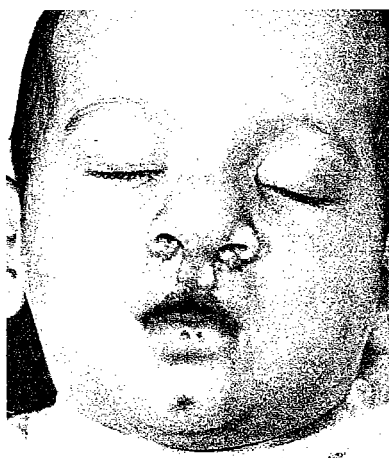11. The alar bases were cut as flaps.

12. The forked flaps were sutured to the alar base flaps in a handshake type of "praying hands" banking.

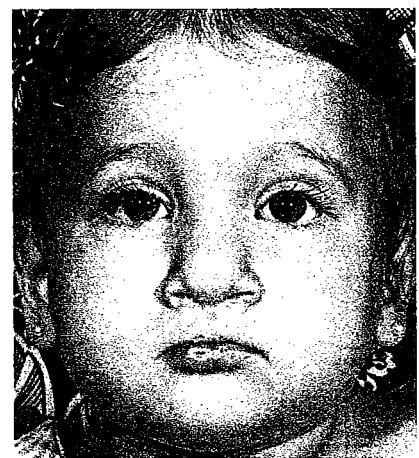1-2-75. (Age 2½ mo.) Premaxillary setback and lip closure with forked flap banking



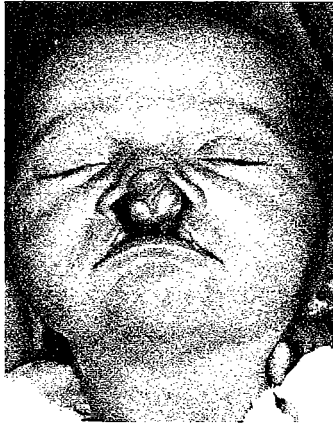3 days old



6 days postoperative



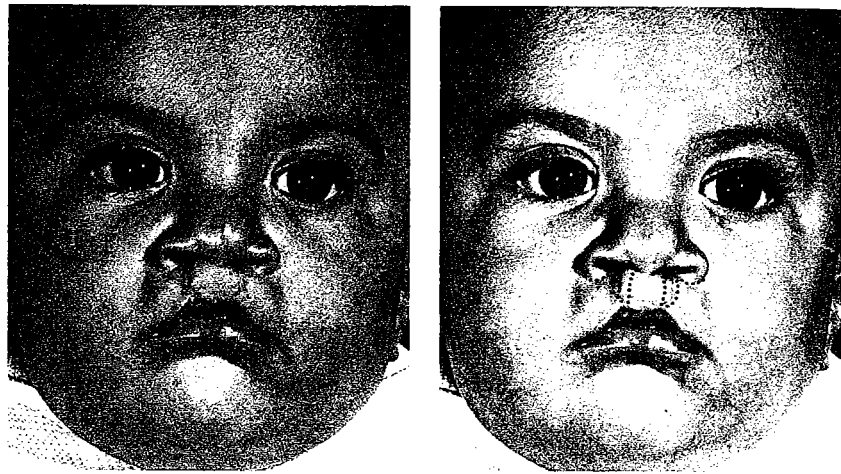10 months postoperative



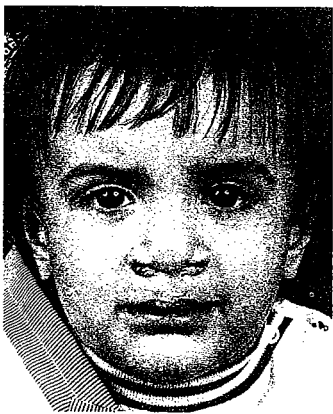6 days

STRETCHING THE PROLABIUM FOR SECONDARY BANKING

Here is a baby boy born with the bilateral cleft of the lip and palate too late to be included in my regular statistics. Because of the pea-sized prolabium, it was decided to attach the lateral lip elements to the sides of the prolabium in a glorified adhesion using the standard lateral vermilion flaps edged with the mucocutaneous ridge to overlap the prolabium vermilion. By not joining the muscles to each other across the midline, they were free to tug and stretch the tiny prolabium.



18 months



20 months

By 18 months of age, there was enough tissue to spare a forked flap that was banked in whisker position. The tailored prolabium was elevated, the lateral lip musculature joined in the midline and the prolabium replaced with a dimpling stitch. At age 4 to 5 years, the forked flap will be advanced into the columella.