

## *26. Detailed Closure of a Bilateral Incomplete Cleft Lip with Banking of the Fork*

### INCOMPLETE CONDITION

NATURE has left some strings attached to its incomplete clefts which fortunately restrict the severity of the deformity. Usually the premaxilla is united to one or both sides of the maxilla and seldom protrudes. There may be some upper labial sulcus. The clefts in the lip are not complete, and the bridges may be wide enough to have passed some muscle into the prolabium. The integrity of the nasal floors, being intact, reduces the amount of alar base flare, but these floors are usually wider than normal. The nasal tip is less flattened, and the columella can be nearly normal although usually it is shorter than ideal.

### WHAT TO DO

If the columella is adequate, the latest rendition of the pure rotation-advancement method is preferred. It has been described in detail at the end of Chapter 15.

If the columella is inadequate, the ultimate result should eventually be about the same but the means of accomplishing it become complicated. All the latest rotation-advancement actions adapted to bilateral clefts are involved.

At first consideration there may seem to be a lot of flaps going in helter-skelter direction like the proverbial Keystone Kops, but actually each action is logical and quite simple in itself. The

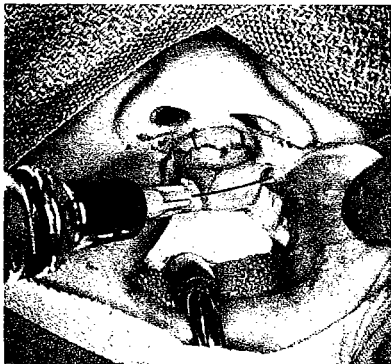
necessity in bilateral clefts of doubling each procedure may cause temporary confusion, but the demand for symmetry renders the second side merely a replay.

To facilitate the execution of the basic philosophy of taking what is available that is not needed where it is and shifting it in order to create what is wanted, the surgeon must superimpose in his mind's eye the ultimate ideal normal result over the original deformity. This vision will not only clarify the problem but project the solution. Prior to the actual surgery, it is well to run a replay elucidating the reason for each specific action. Then, on the final forward rerun, the surgical sequence will be economical, effective, symmetrical and correct.

John Homans of Harvard, a general surgeon with insight beyond his time, said in 1940:

The difficulty with plastic surgery is that it requires imagination. . . . The expert must have an ability to visualize an end result against a most unpromising background and patiently, often in a multitude of steps, work toward the fulfillment of his vision.

No deformity makes this demand more than a bilateral cleft of the lip and palate. To understand one completely we have to do one, and it is logical to start with the incomplete type.


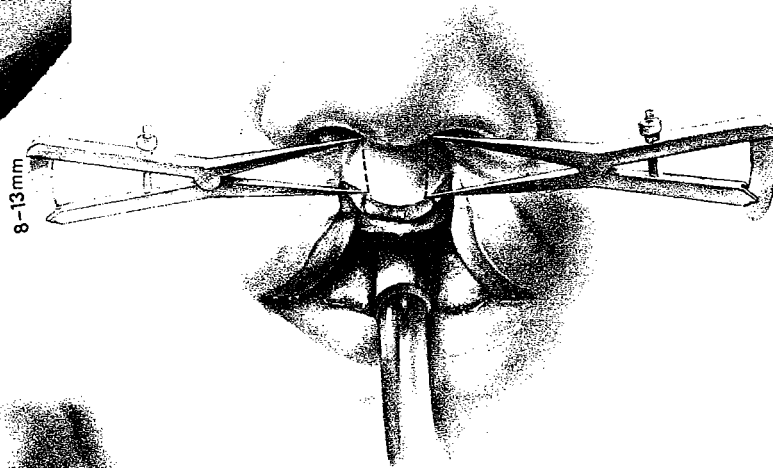
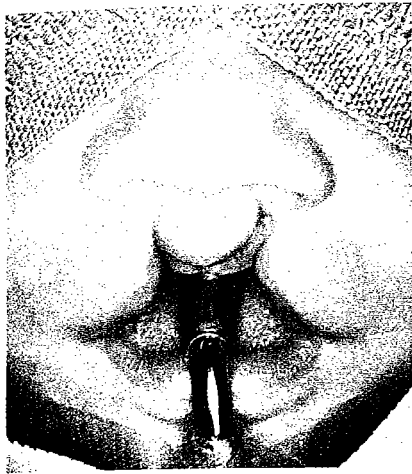


Adrenalin in local anesthesia for hemostasis.

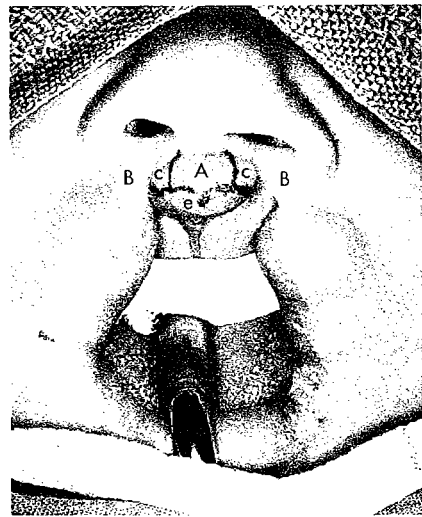
#### MEASURING AND MARKING THE PROLABIUM

In the usual bilateral incomplete cleft of the lip, the vertical height of the prolabium is shorter than the lateral lip elements but is usually long enough. On the other hand, the tissue in the upper portion of the longer lateral lip elements is often attenuated, lacking in muscle and contour. The prolabium is usually wider than a normal philtrum, but the columella is shorter than ideal. These four conditions suggest that the prolabium should set the vertical height of the lip, that the upper portion of the lateral elements are expendable and that the sides of the wide prolabium are available for eventual lengthening of the short columella.

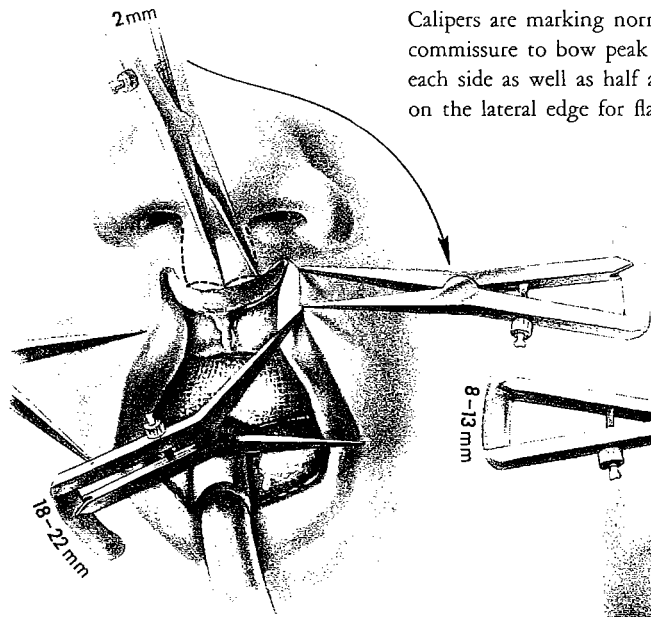
If a vertical line is dropped straight from the lateral base of the columella on each side to the inferior mucocutaneous junction of



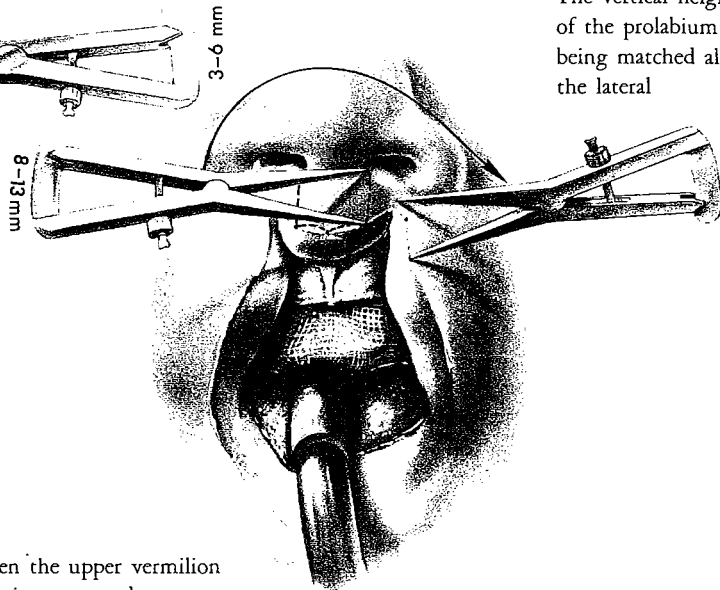
The double arch of the cupid's bow is marked on the inferior prolabium which from peak to peak will be 4-10 mm. or 2 to 5 mm. an arch.



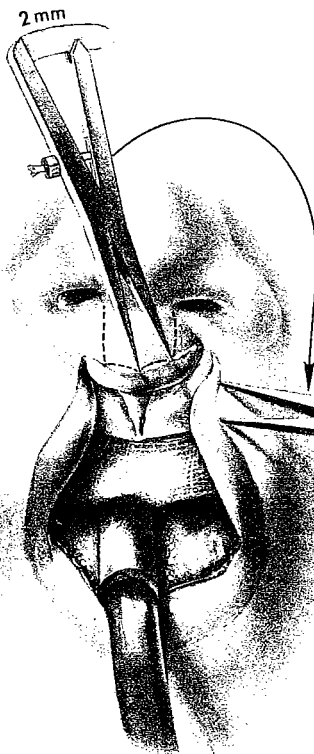
Vermilion below the bow is turned down for lining.



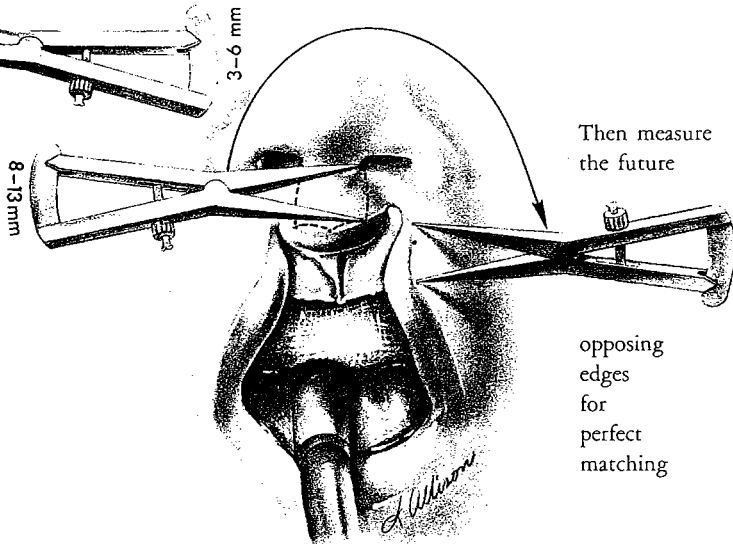
Calipers are marking normal and equal commissure to bow peak limit point on each side as well as half a bow distance on the lateral edge for flap b.



The vertical height of the prolabium is being matched along the lateral



When the upper vermilion edge is attenuated move laterally as far as possible out to the limit point.



Then measure the future

opposing edges for perfect matching

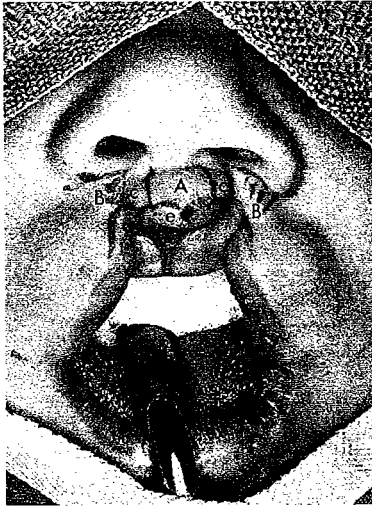
the prolabium, the distance will average from 8 to 13 mm., which is a normal upper lip length. The width between these lines should be from 4 to 10 mm. (preferably 6 mm.), or the size of a normal philtrum. The midpoint along the inferior prolabium mucocutaneous junction marks the center of the cupid's bow with the potential peak of each arch 2 to 5 mm. (3 mm.) lateral along this junction line. All prolabium tissue lateral to that marked off for a normal central philtrum is to be pared and preserved for a future forked flap.

The double curve of the cupid's bow is marked along the inferior mucocutaneous junction of the prolabium, and vermilion beneath this will be turned down as a lining flap. If the mucocutaneous junction on the prolabium is well differentiated, it should be preserved. If not, it can be taken in the turndown flap of vermilion.

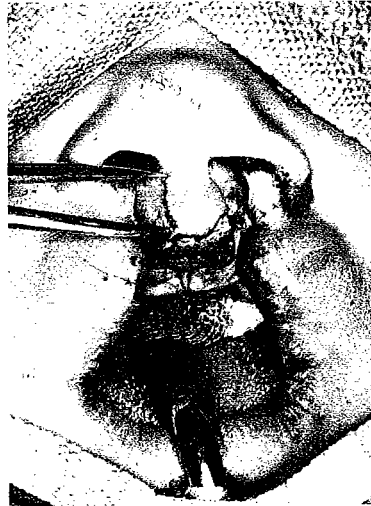
#### MEASUREMENT MATCHING OF THE PROLABIUM TO THE LATERAL LIP ELEMENTS

The length relationship of the prolabium to the lateral lip elements varies in each case and even on each side. In the normal lip the distance from the commissure to the peak of the bow along the mucocutaneous junction line can be 18 to 22 mm. or more. Once this normal distance is determined for a specific case, a point is made on each side to mark the limit of allowable lateral paring.

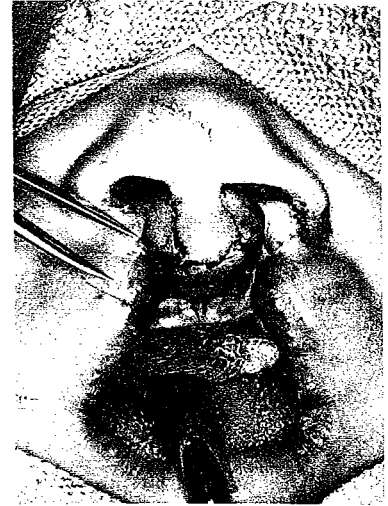
Above this point, the lateral lip edge is measured the exact length of the vertical height of the prolabium. When the lateral lip element is longer than the height of the prolabium, however, it is better to de-epithelialize the excess in the upper portion and retain it as a dermal extension on each lateral lip element to be used as a tether during the medial advancement of these segments. During the paring of the edge of the lateral element, a full-bodied vermilion flap topped with a "white roll" ridge should be cut slightly longer than the length of one arch of the cupid's bow as it will, in fact, be creating half of the bow.



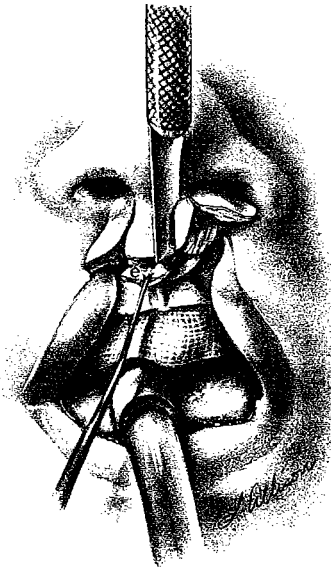
Skin bridges marked for de-epithelialization.



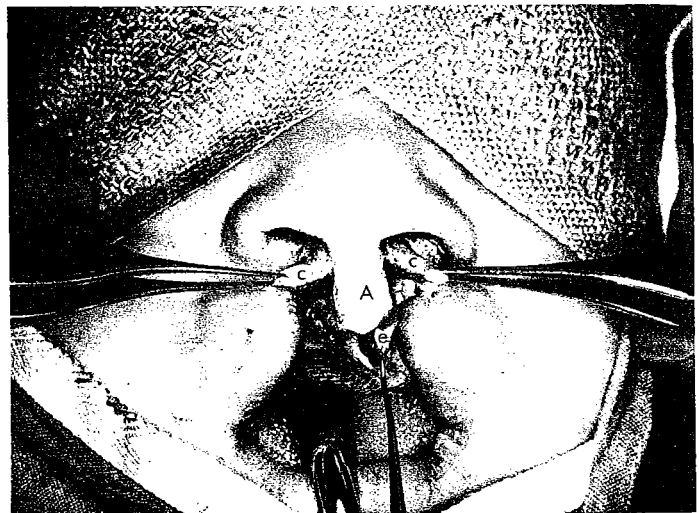
Prolabium marks scored.



Bridges divided through the nostrils.



Philtrum has been pared of its side forks. Inferior vermilion being turned down.

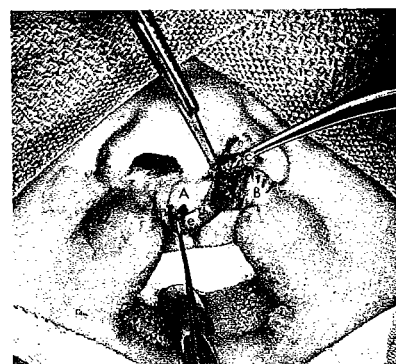


Shaped philtrum with side wings free for first stage of fork banking and vermilion lining flap drooping but ready for backup of tubercle.

## SCORING AND CUTTING THE PROLABIUM

All three elements of the lip have been measured and marked. The muscleless bridges of the longer lateral elements have been cross-marked for de-epithelialization, which will produce two leading dermal handles. The main part of this dermal extension is left attached to the lip elements and can be used to pull and tether the lateral elements upward and inward to each other and the septum, bringing the lateral muscles into better position.

The prolabium is scored to delineate the philtrum, the forked flaps and the inferior vermilion turndown flap. The skin bridges have been divided all the way through into the wide nostrils. The philtrum is shaped by stabbing along the scoring with a No. 11 B-P blade to pare off the lateral forks. Then the inferior vermilion cuff is dissected as a turndown flap based on the distal end of the prolabium. Thus the prolabium has been "drawn and quartered" into a central philtrum, the two side wing forks and a vermilion turndown flap (e).

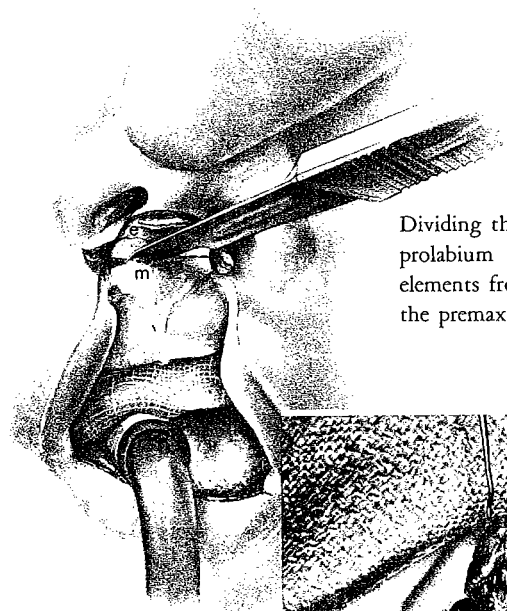


Paring one fork from the prolabium up to the columella base.

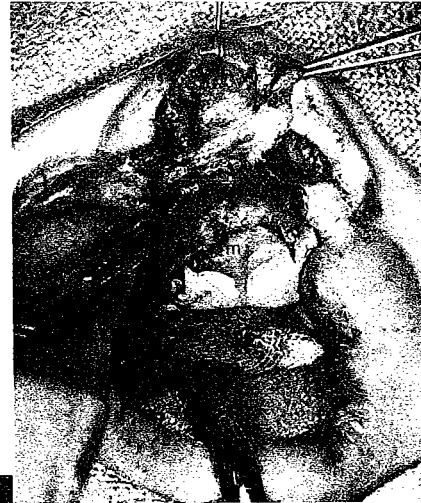## FREEING THE PROLABIUM AND THE LATERAL LIP ELEMENTS

Once the prolabium has been divided into its various flaps, the entire ensemble is dissected free from its attachments to the premaxilla right up to the nasal spine. The incision across the inferior attachment must leave enough pedicle for vermilion flap to remain viable on the end of the prolabium. All other mucosa in this area should be left attached to the premaxilla for covering its raw area and lining the posterior wall of the upper labial sulcus. The same economy is used for the forked flaps. A narrow cuff of vermilion is preserved along each lateral side of the fork to add body and cover during the banking, and when finally advanced into the columella this red rim will be hidden inside the nostril and sutured to the septum. Any remaining lateral vermilion running up on the sides of the front of the premaxilla again should be spread and used to cover as much raw area as possible to help in the sulcus lining. Thus the mucosa left on the anterior surface of the premaxilla is shaped somewhat like an M and is capable of creating at least a good part of the posterior side of the upper labial sulcus. The lateral lip elements are then dissected by undermining from their attachments to the maxilla to ease the lip closure.

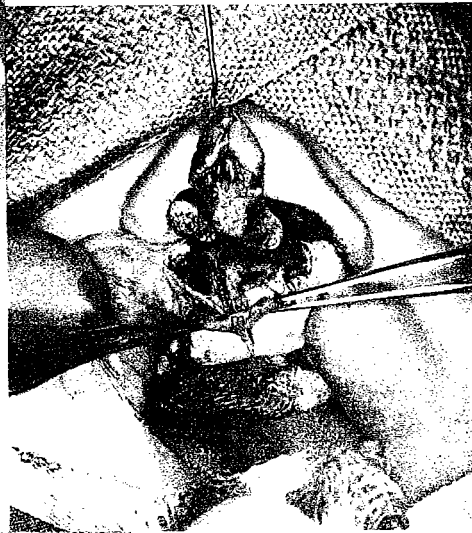




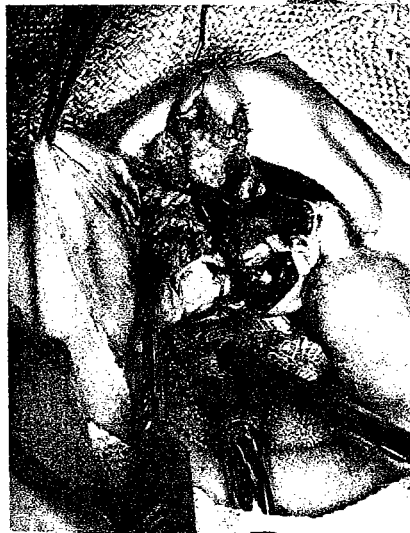Dividing the prolabium elements from the premaxilla



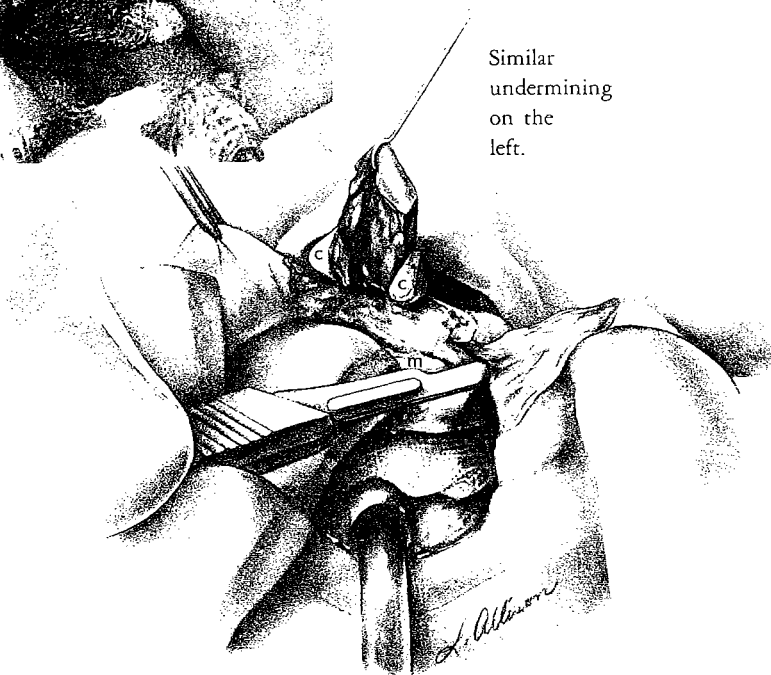
while leaving as much mucosa M as possible on the premaxilla and still keep inferior vermillion flap E viable.



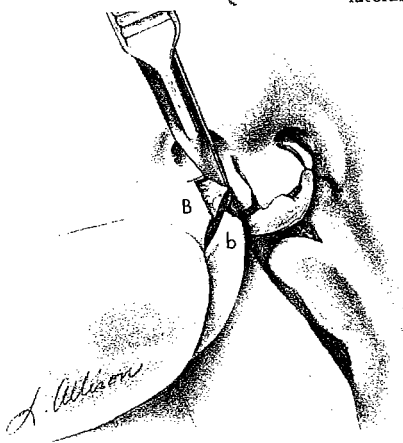
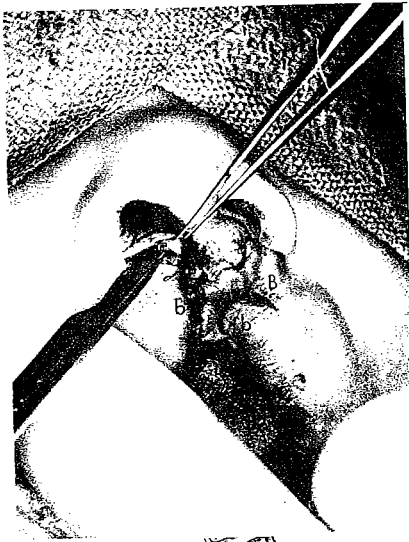
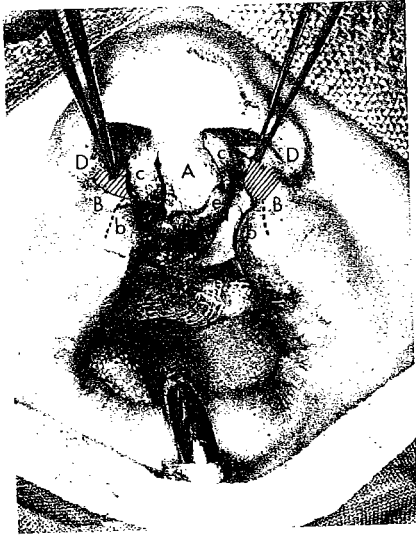
Lateral lip element (Rt) being freed from the maxilla



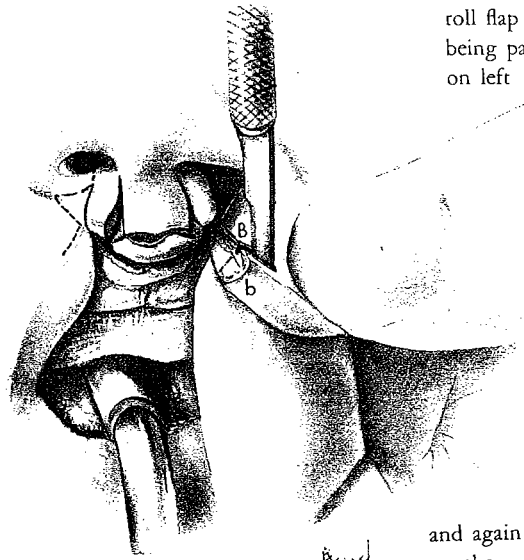
edge starting upward from the lateral limit point.



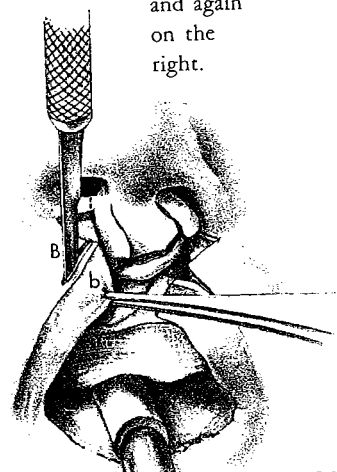
Similar undermining on the left.



De-epithelialization of the attenuated bridge portion of the upper lateral lip elements shortens these long segments and provides dermal tips for lifting and tethering the lateral lip elements.



Vermilion-white roll flap b is being pared on left



and again on the right.




## PREPARING THE LATERAL LIP ELEMENTS

The lateral lip elements hang longer than the vertical length of the prolabium, but their upper portions are attenuated, lacking in muscle and contour, and their true muscle bulges are positioned more laterally and inferiorly. The crosshatch markings of the deficient upper bridges indicate the zones for de-epithelialization. These raw dermal tips will be advanced medially and upward and suspended with 4-0 Vicryl sutures to each other and to the septum at the nasal spine. This lift will take the tension off the closure and set the ideal stage for lip construction and healing.

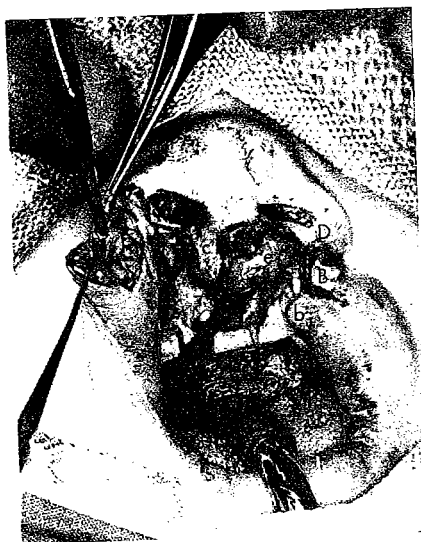
The lateral lip elements are pared of full-bodied vermilion flaps edged with a white roll ridge. The paring is limited, of course, by the normal distance already marked at the potential bow peak from the commissure.

## PREPARING THE LATERAL SKIN EDGES

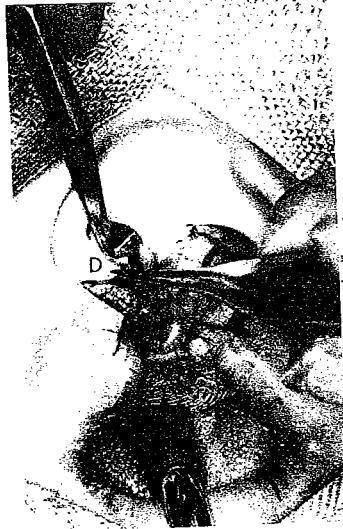
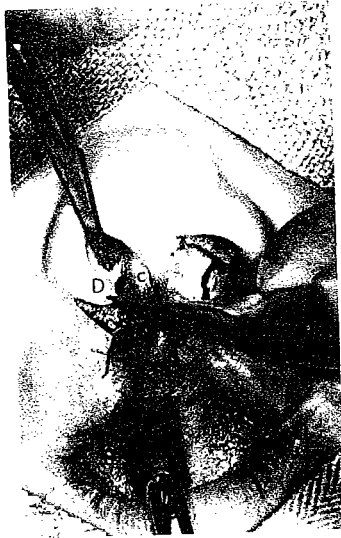The skin of the cleft edges of the lateral lip elements is trimmed carefully to fit and approximate exactly the sides of the pared prolabium. The skin is also undermined 2 to 3 mm. from the orbicularis oris muscles along the lateral lip edges to ensure eversion in the closure.



Lateral skin edges trimmed

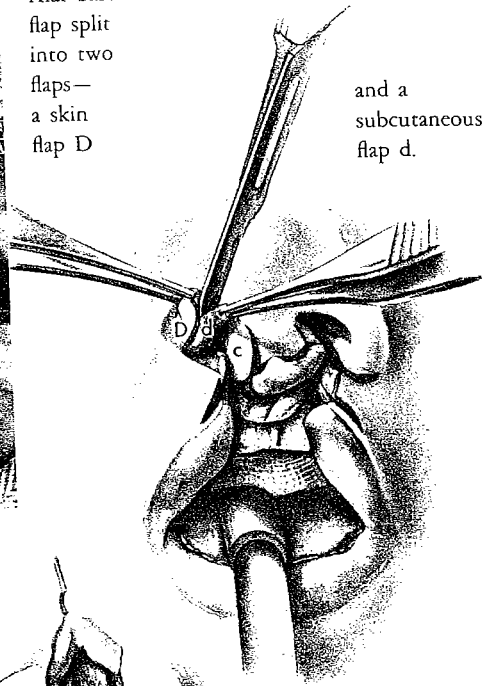


and undermined 2-3 mm.




Alar base flap split into two flaps— a skin flap D

and a subcutaneous flap d.



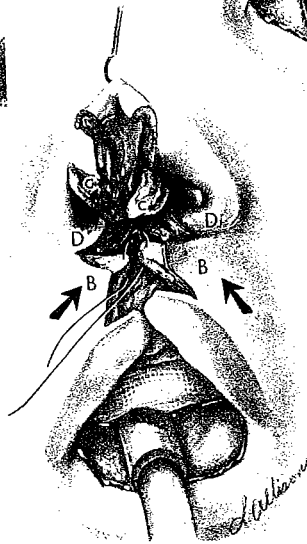
Total alar base flap being developed.



Deep alar base and lateral lip suspension being achieved.



The alar base subcutaneous d flaps are being sutured to each other on the septum.



The dermal tips of the lateral lip elements are being sutured to each other and the septum at the nasal spine just below the d flap union.

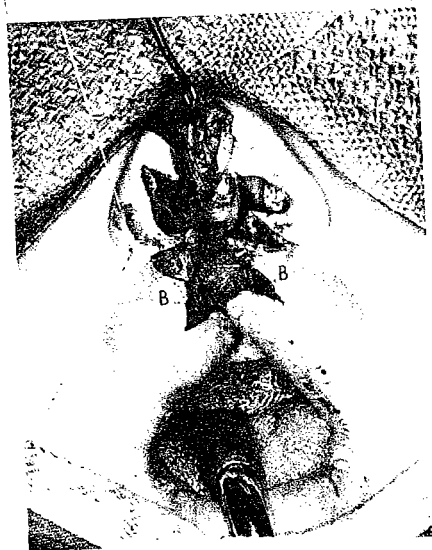
## PREPARING THE ALAR BASES AND PLACING THE SUSPENSION SUTURES

The alar bases have been divided from the lateral lip elements in the usual manner with a No. 11 B-P blade. They are also incised within the vestibule to form full-bodied flaps. Each flap is then dissected into two components—an alar base skin flap D and a subcutaneous-muscle flap d. A 4-0 Vicryl suture is used to join the two d flaps to each other and to the septum, reducing the alar flare and narrowing the wide nostrils. After this suture, a similar suture is placed in the two dermal tips of the lateral lip elements to bring them together and hang them on the septum at the nasal spine just below the fixation of the d flaps.

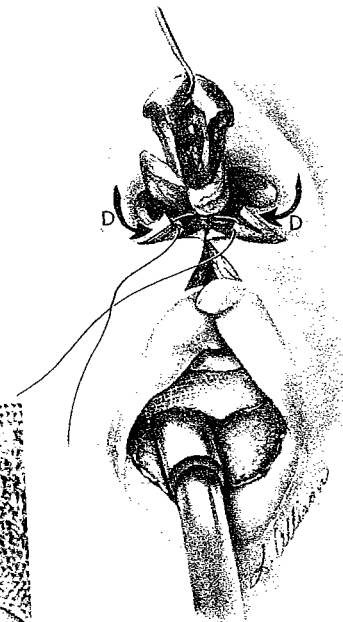
Probably the most logical order of suspension suturing will first bring the dermal tips of the lateral lip elements together and to the septum and then bring the alar subcutaneous flaps to each other and to the septum just above the lip fixation suture.



First suture the dermal tips of the lip elements together and to the septum at the nasal spine.



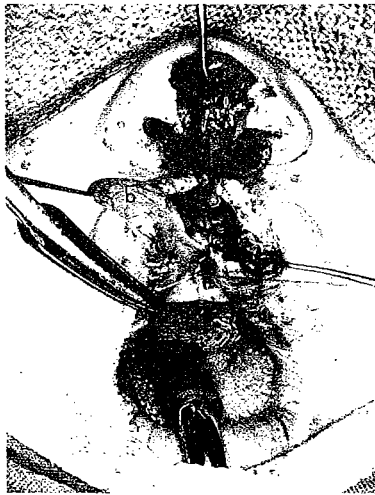
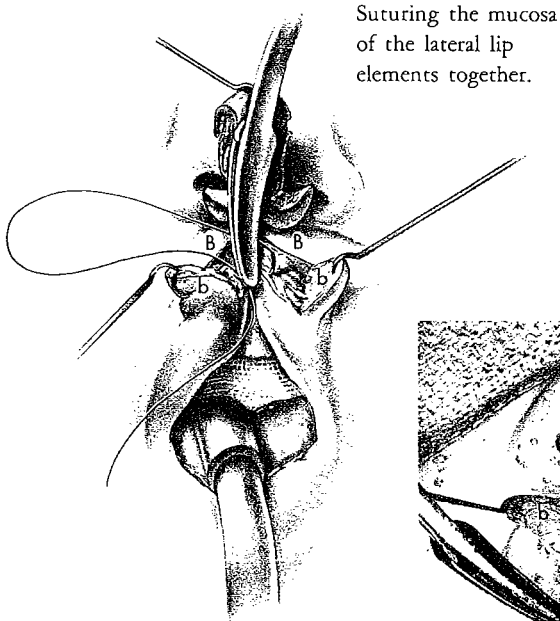
Reversing the order.



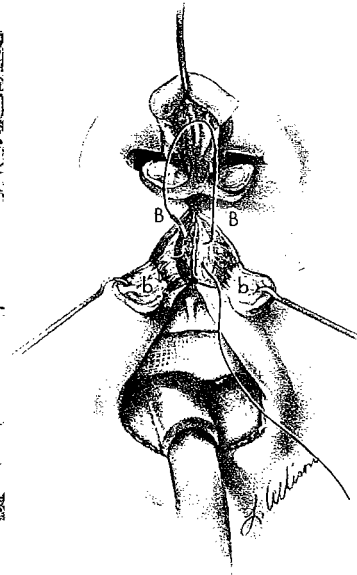
Then suture the alar subcutaneous flaps to each other and to the septum above the lip stitch.

## SUTURING THE LATERAL LIP ELEMENTS TOGETHER

First the posterior mucosa of the lateral lip elements are sutured together with 4-0 chromic catgut (Ethicon #752G) in front of the premaxilla and behind the prolabium to form the anterior side of the upper labial sulcus. Then the orbicularis oris muscle fibers are approximated with 4-0 Vicryl (Ethicon #V-494G) mattress sutures.

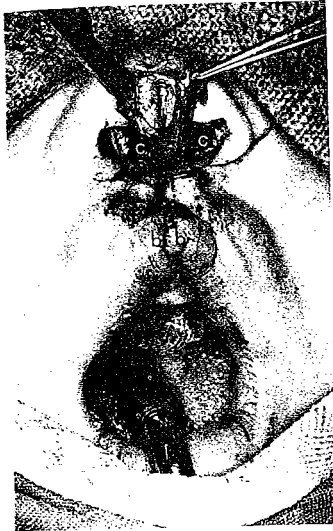

Then the muscle fibers are brought together with Vicryl mattress sutures.

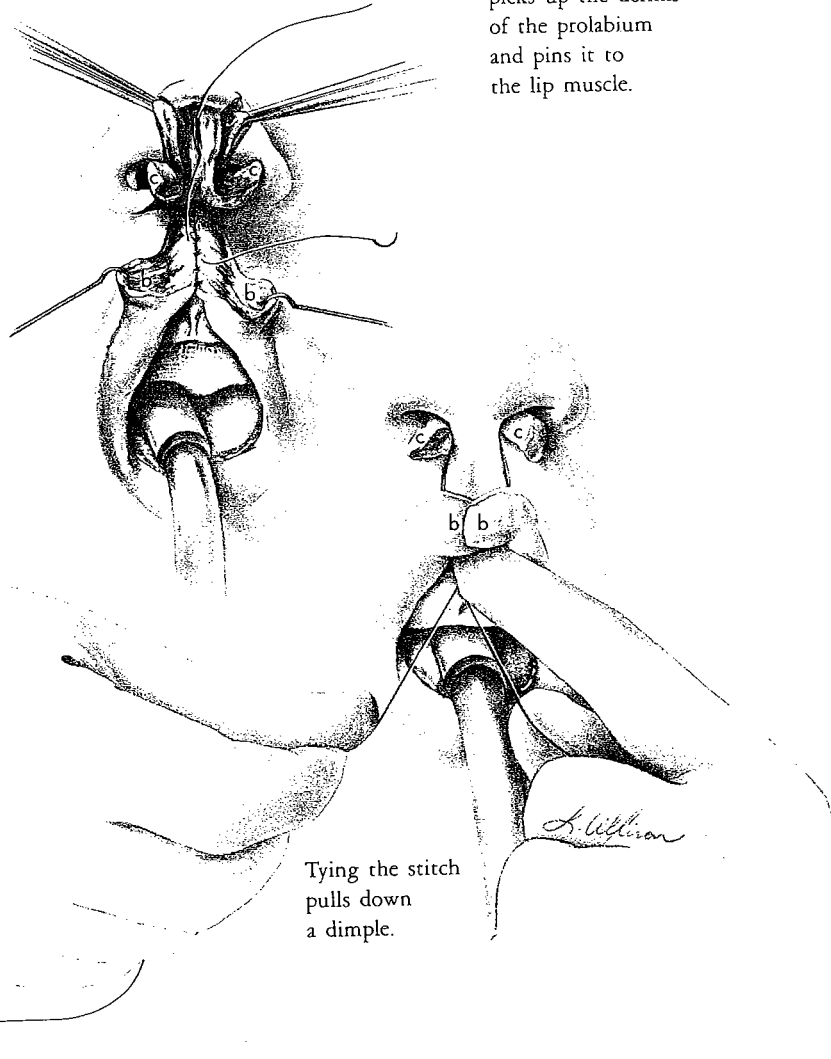


## DIMPLING THE PHILTRUM

A midline vertical slit is made in the subcutaneous tissue of the philtrum deep to dermis. A 4-0 Vicryl suture picks up the dermis in the inferior depth of the slit and fixes it to the under muscles of the lip. As the suture is tied, the philtrum dimple is depressed.



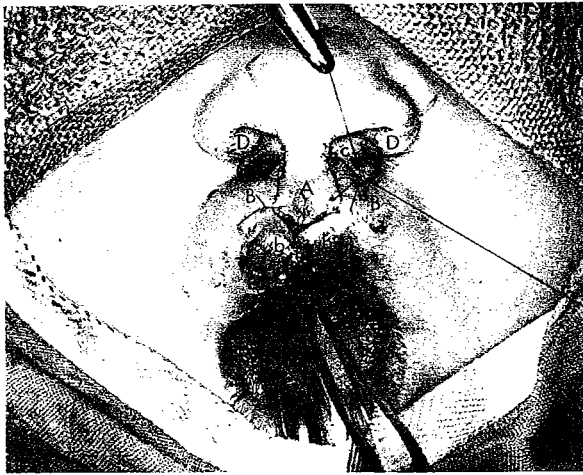
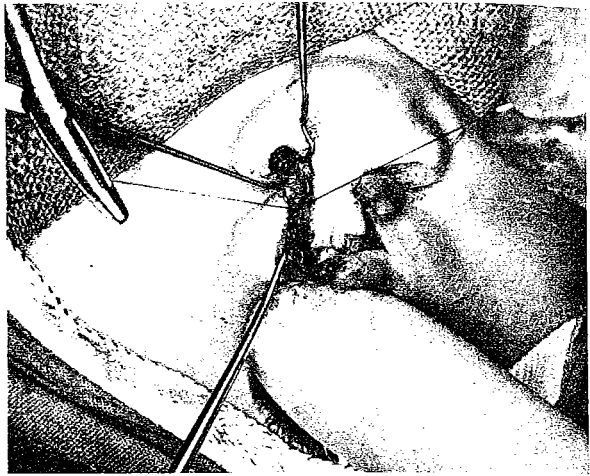
A midline vertical slit is made in the subcutaneous tissue of the prolabium to the dermis.



A 4-0 Vicryl suture picks up the dermis of the prolabium and pins it to the lip muscle.

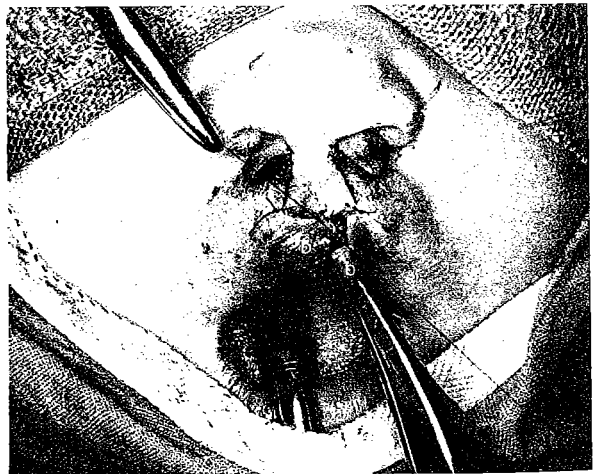
Tying the stitch pulls down a dimple.

Suture of subcutaneous tissue of prolabium to subcutaneous layer of lateral lip element with 5-0 and 6-0 catgut emphasizes the dimple and improves the apposition of the skin edges.



Closure of mucosa and muscle of lateral elements behind the prolabium relieves all tension. 6-0 silk sutures bring the skin edges together with ease.

Overlap of the lateral vermilion flap b with its mucocutaneous ridge over the prolabium vermilion turndown flap to form half of the cupid's bow. The opposite flap b will complete the bow with a midline tubercle.

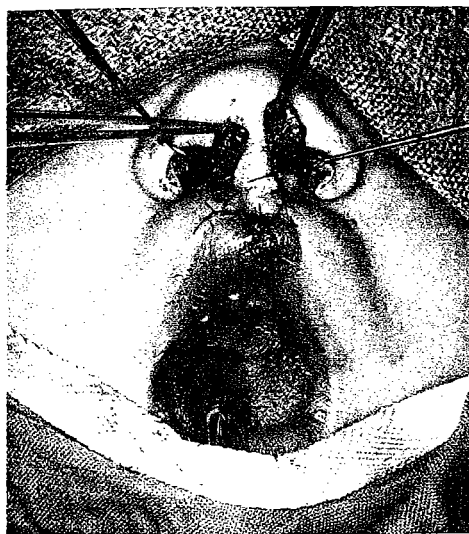



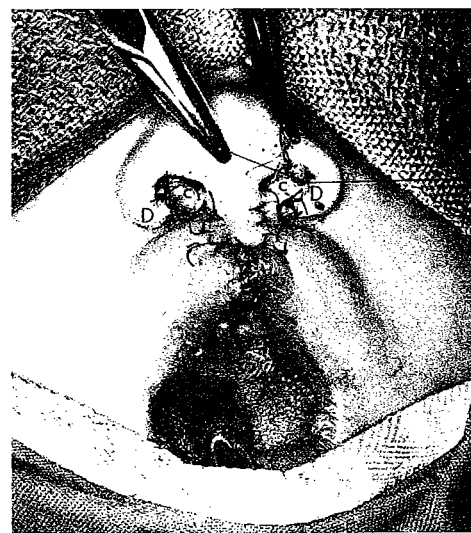
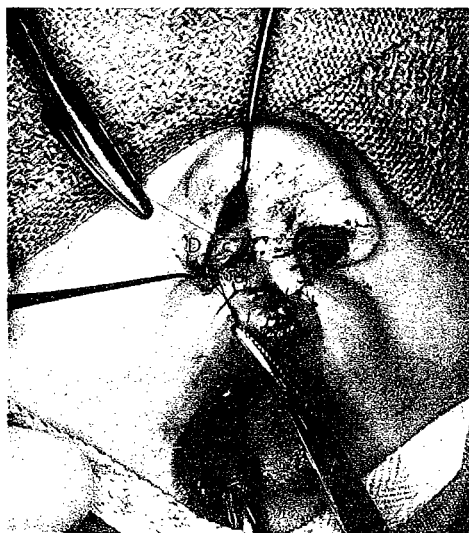
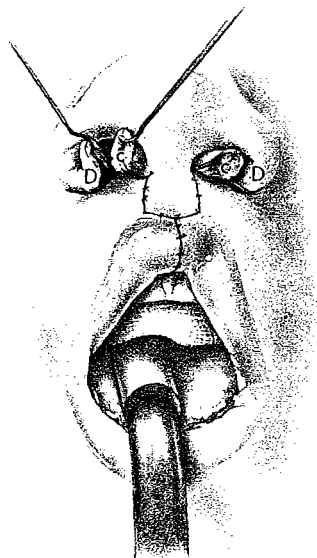
## BANKING THE FORKS

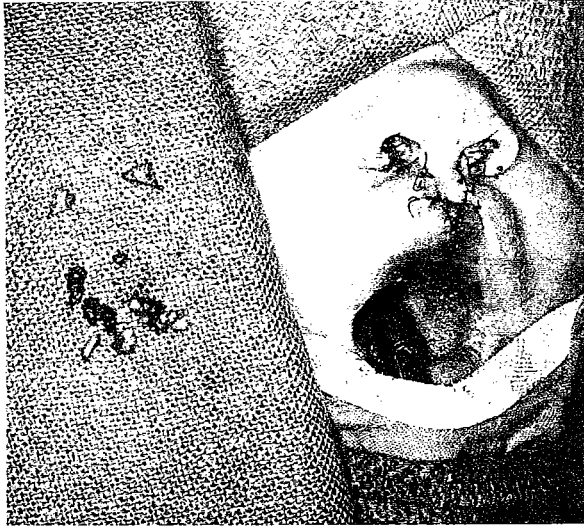
The prolabium forks are banked by approximation with the alar base D flaps, tip to tip and raw area to raw area like the clasping of "praying hands" to form two pyramids, one in each nasal floor.

Another method of banking, which I prefer particularly in complete clefts although it can also be used in the incomplete clefts, is the subalar whisker position between alar base and lateral lip element. This maneuver was described in Chapter 23 and will be described again in Chapter 28, with examples shown in Chapter 30.

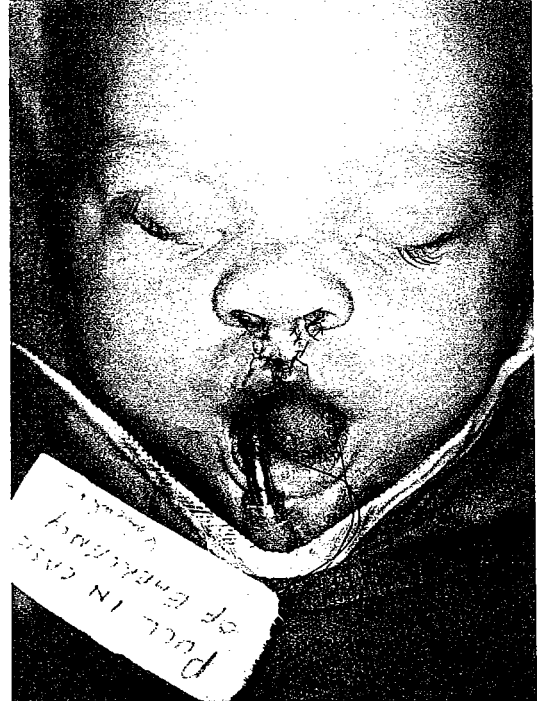


Alar base being sutured to fork on each side in banking maneuver.

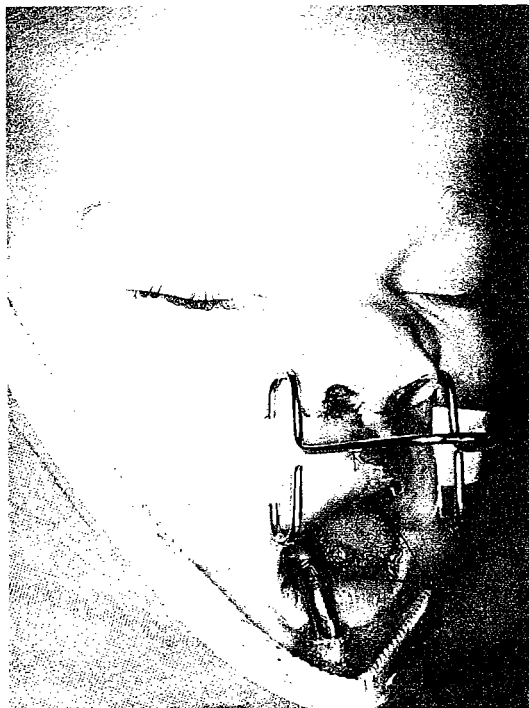



This is indeed an economical design with minimal discard of tissue.



Tongue stitch is placed as a safety precaution.



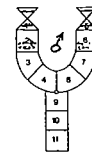
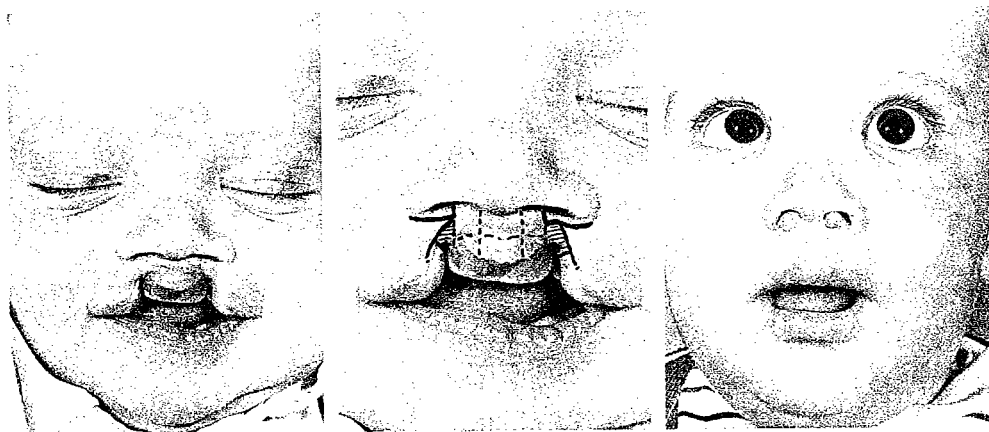
Logan bow assists in initial relief of tension and leaves the wound open for application of antibiotic ointment and eventual suture removal.

## SECONDARY FORKED FLAP ADVANCEMENT

Secondary advancement of the forked flap into the columella for release of the nasal tip can be carried out as soon as three weeks later or preferably at the preschool age of five to six years.

If the ends of the forked flap are hanging free, with the aid of a membranous septal incision they can be advanced into the columella and sutured to each other and to the septum. The alar bases then can be advanced medially and their denuded ends sutured to each other and to the septum under the ends of the forked flap to reduce the alar flare and create nostril sills. If the forked flap has been banked in "whisker fashion," the same maneuver is available. If banked as "praying hands," then the attachments are unclasped except the tip-to-tip union of the forked flap ends to the alar bases. The elongated straps thus produced are advanced medially and rotated upward into the columella. A septal cartilage strut should be used to support the tip and fork; if in childhood, it can be banked cartilage, but after 15 years it should be autogenous septal cartilage.

## PERSONAL CASES



B.D. 7-1-71  
 F.H. Maternal  
 aunt had  
 son with  
 unilateral  
 CL  
 F.T. Unevent-  
 ful  
 O.C.A. None  
 10-26-71

At three and a half months one-stage lip closure was carried out.

1. The prolabium was freed from the premaxilla and the lateral lip elements were freed from the maxillae.

2. A short forked flap was pared from the prolabium. (Microscopic sections of the prolabium revealed skeletal muscle fibers, as might be expected in an incomplete cleft.)

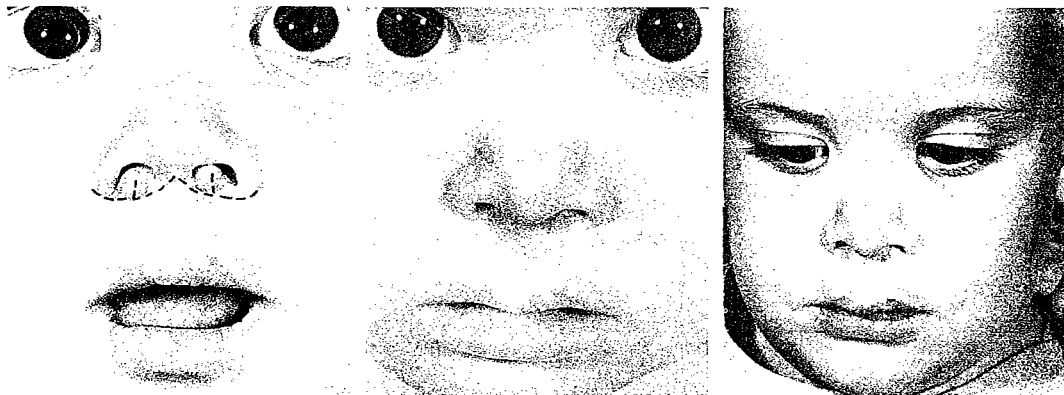
3. Lateral mucosa and muscle were joined behind the prolabium.

4. Lateral vermilion flaps carrying the mucocutaneous junction were used to overlap the turndown of the prolabium vermilion.

5. The forks were sutured to the Simonart's bands in the nostril floor for banking.

Six months later columella lengthening was accomplished by the forked flap, and the alar bases were denuded at their tips, advanced and sutured to the septum.

4-18-72. Forked flap at age 9 months.

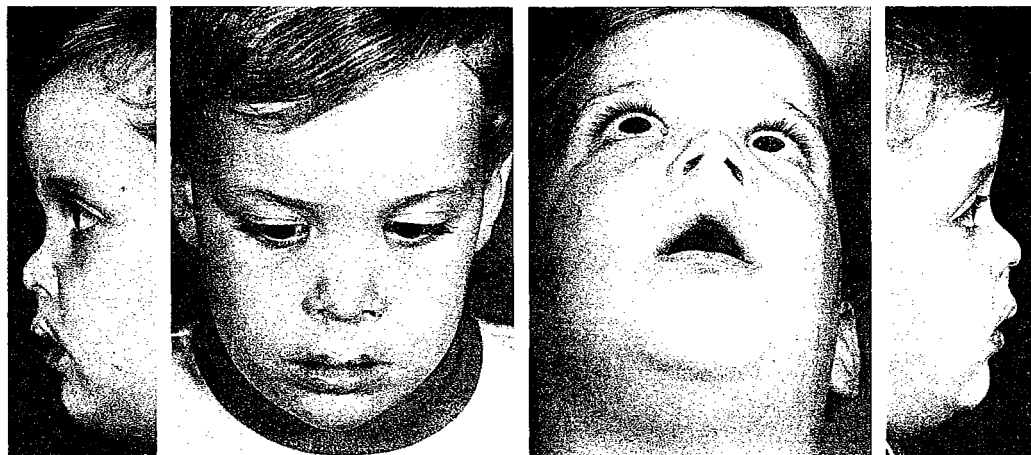

2 months postoperative

22 months old

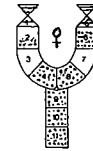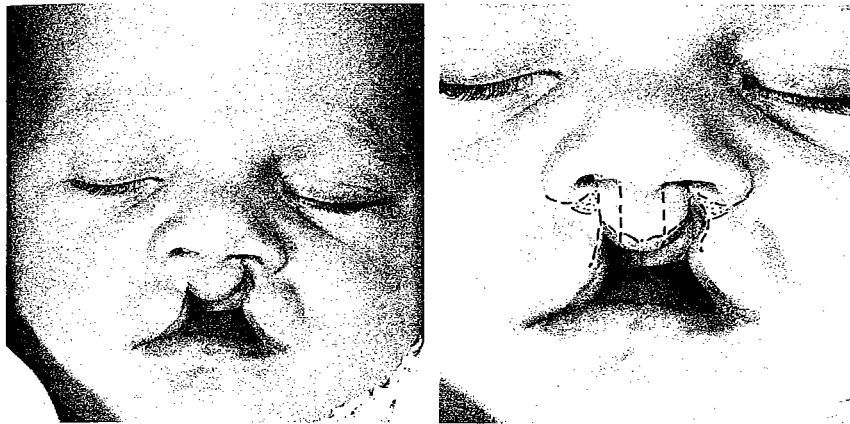Note increase in vertical length of short prolabium after joining of lateral muscles.

*Comments.* 1. Columella lengthening at 9 months did not lengthen lip excessively. 2. Mucocutaneous junction ridge brought in with lateral vermilion flaps gives interesting effect.



2 years and 2 months

Here is an example of a bilateral incomplete cleft treated as just described with the second-stage columella lengthening of the banked forked flap postponed until just before school age.



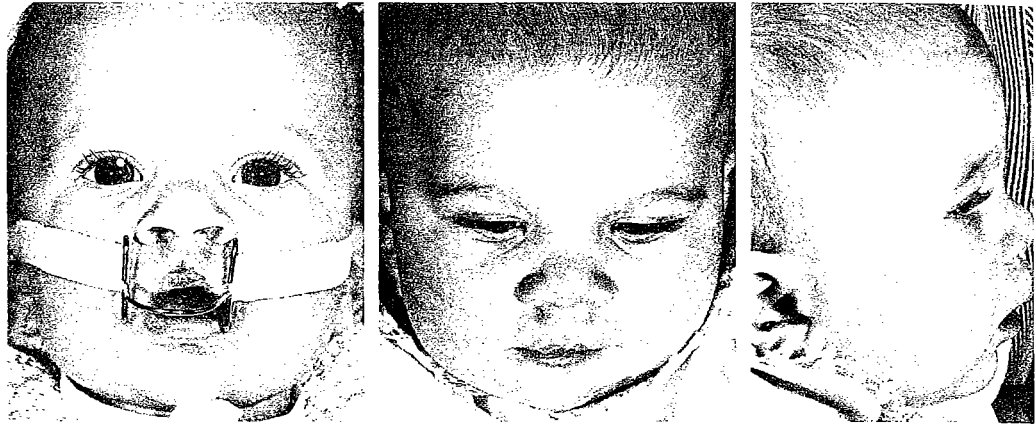B.D. 7-22-72  
 F.H. No clefts  
 F.T. Uneventful  
 O.C.A. None

10-27-72. Ear tubes. S.P. Lip Closure

At three months of age:

- A. Bilateral myringotomy, suction and insertion of tubes by F. Pullen.
- B. Soft palate closure.
- C. One-stage closure of bilateral cleft lip.
  1. Prolabium freed from premaxilla and lateral lip elements freed from maxillae.
  2. Bilateral forked flap pared from sides of prolabium.
  3. Posterior mucosa of prolabium used to cover raw anterior premaxilla.
  4. Skin bridges with or without muscle denuded of epithelium, advanced to each other and sutured to the septum behind the columella, relieving tension of lip closure and reducing alar flare.
  5. Mucosa and muscle of lateral elements sutured to each other behind the prolabium.
  6. Prolabium dimple created with Mersilene suture.
  7. Lateral vermilion flaps *carrying mucocutaneous ridge* used to overlap the inferior prolabium vermilion.
  8. Forks sutured to alar base flaps in "praying hands" pyramids.

Comment. Note alar base positioning.



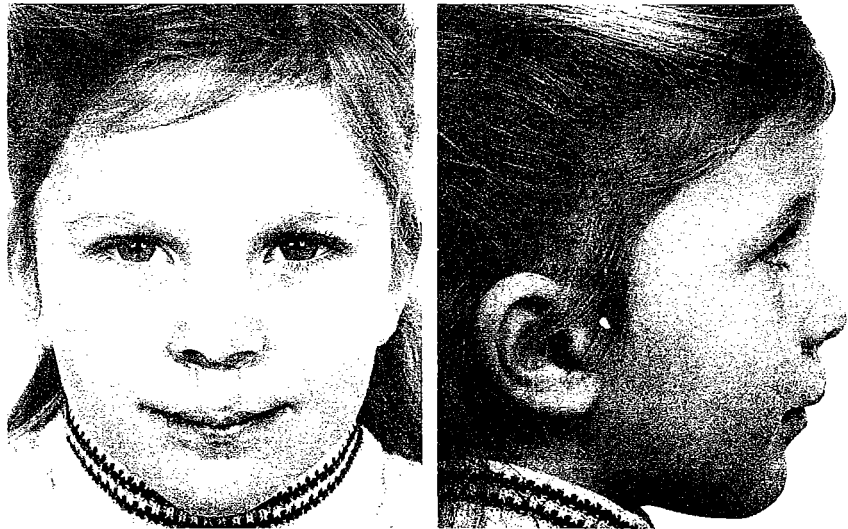6 days postoperative

4 months postoperative



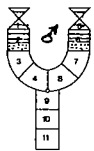
3 years

Patient returned from Virginia at age three years for hard palate closure and minor lip revision. At 4½ years she returned for "unbanking" of the forks to lengthen the columella before starting school. Here she is soon after the elevation of her tip.

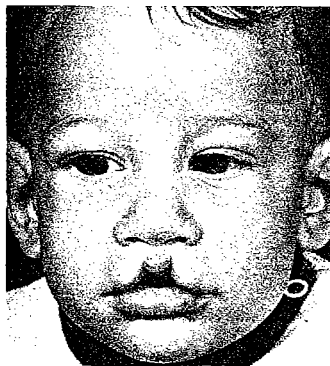

*A short prolabium*

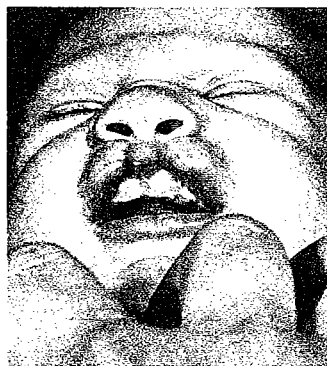Here is a primary case that has been added too late to be included in the statistics. It is important because it presents the solution to



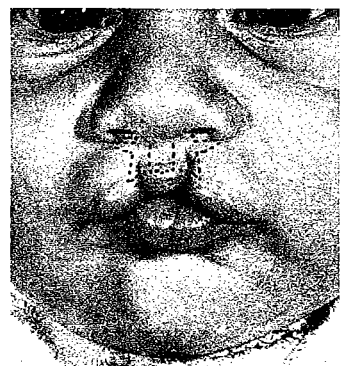B.D. 3-17-75  
 F.H. No clefts  
 F.T. Uneventful  
 O.C.A. None



4 months



Vertical skin length of prolabium 7.5 mm. Lateral elements 9 mm.



the problem of the short prolabium which has been adjusted to form an adequate philtrum without introduction of skin flaps from the lateral lip elements either above or below.

At 7 months of age:

1. Forked flap as marked was taken from the sides of the prolabium including Simonart's bridges and a portion of the lateral lip elements with upper horizontal extensions to shorten the long lateral elements.

2. The prolabium was freed from the premaxilla, some of the vermilion being kept to cover its raw surface.

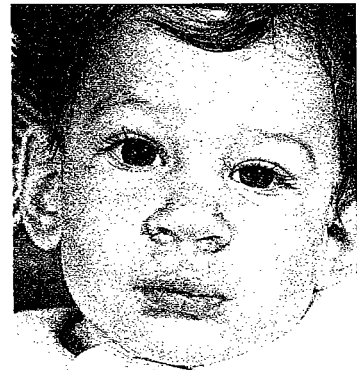3. The mucosa and muscles of the lateral lip elements were brought together behind the freed prolabium, which was replaced in philtrum position with a dimpling stitch.

4. Lateral vermilion flaps carrying a mucocutaneous ridge were used to overlap the prolabium vermilion to form a cupid's bow.

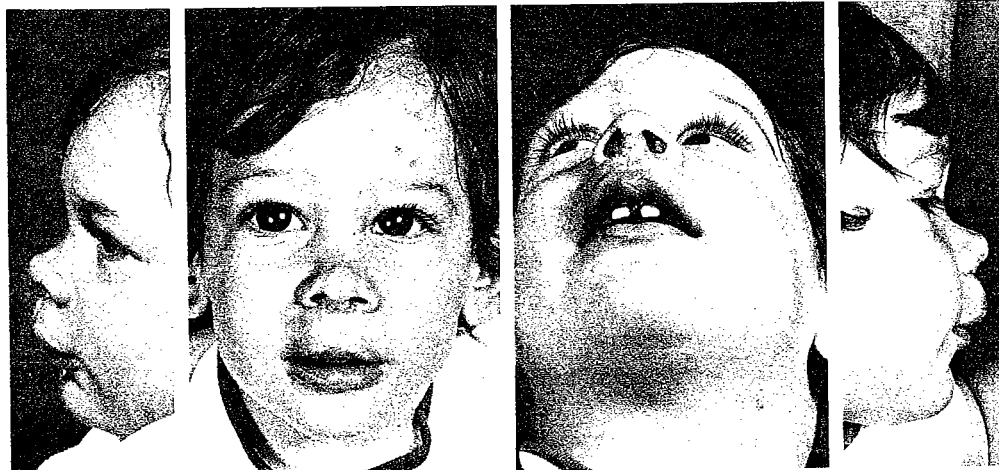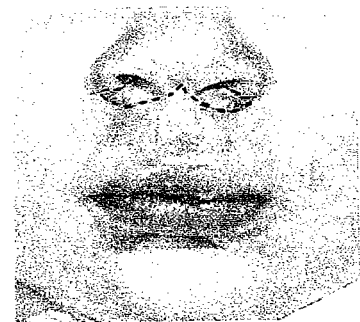5. The forked flap was banked in whisker position.

Introduction of muscle and mucosa behind the prolabium, addition of vermilion-mucocutaneous ridge flaps inferior to the prolabium and matching the sides of the lateral lip elements to the sides of the prolabium succeeded in increasing the effective length of the short central element into good balance.

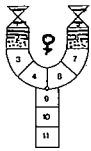
EARLY COLUMELLA LENGTHENING. Because of the incomplete extent of the clefting, the intact alveolus and a short prolabium, early advancement of the banked forked flap into the columella was considered justified and less likely to produce a long lip in vertical dimension. At age 11 months, or 4 months after banking of the fork, it was advanced into the columella.



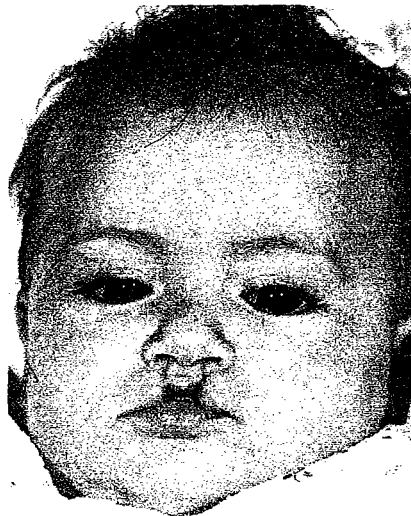2 weeks postoperative



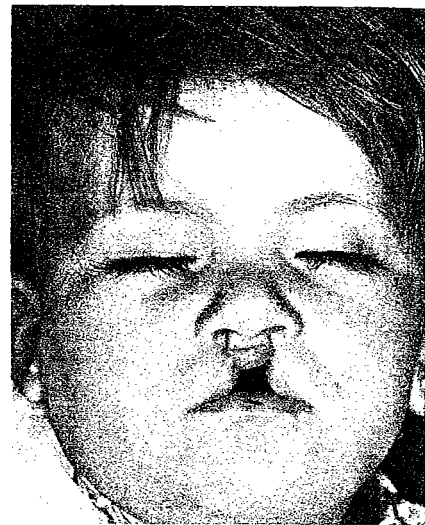
Here is another late case not included in the statistics but important because it demonstrates again how to handle the short prolabium without paying the exorbitant price of introducing lateral skin flaps below or even above the prolabium and without dividing the prolabium from the nose primarily.



B.D. 11-3-74  
 F.H. Brother with severe  
 unilateral CL&P  
 F.T. Uneventful  
 O.C.A. None

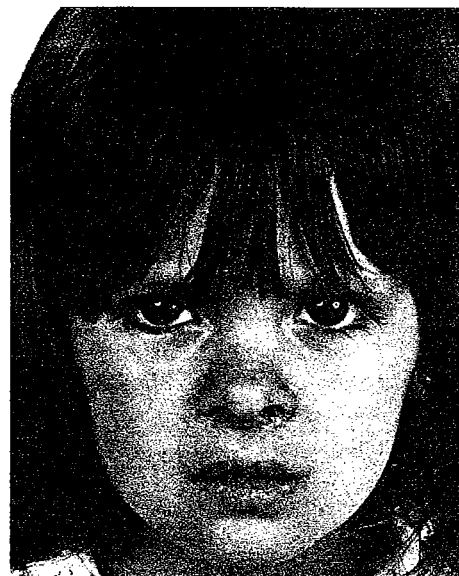

2 weeks



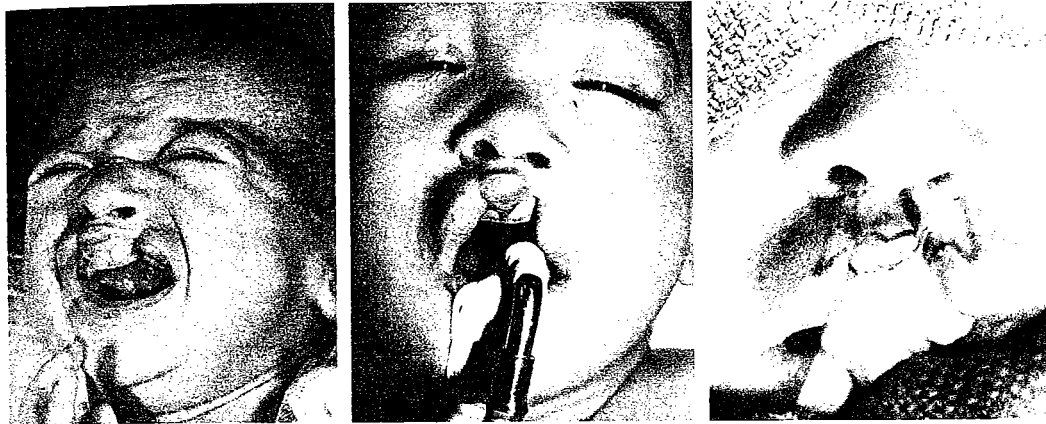
1 year

At the time of lip closure, the forked flap was banked in whisker position. Then as this was an incomplete cleft, the forked flap was moved out of the banked position into the columella with nasal tip release at 2½ years. She is shown 2 weeks after surgery.





The lack of palatal cleft, absence of premaxillary protrusions and severe shortness of the prolabium (6 cm.) stimulated postponement of soft tissue closure in this case. Time did not improve the relative length of the prolabium, so primary definite surgical lip closure was designed at 13 months to correct this discrepancy also.



1. A forked flap was marked taking as much prolabium as was expendable from the philtrum. It also included the pared edges of the lateral lip elements and high transverse wedge triangles to shorten these too long elements.

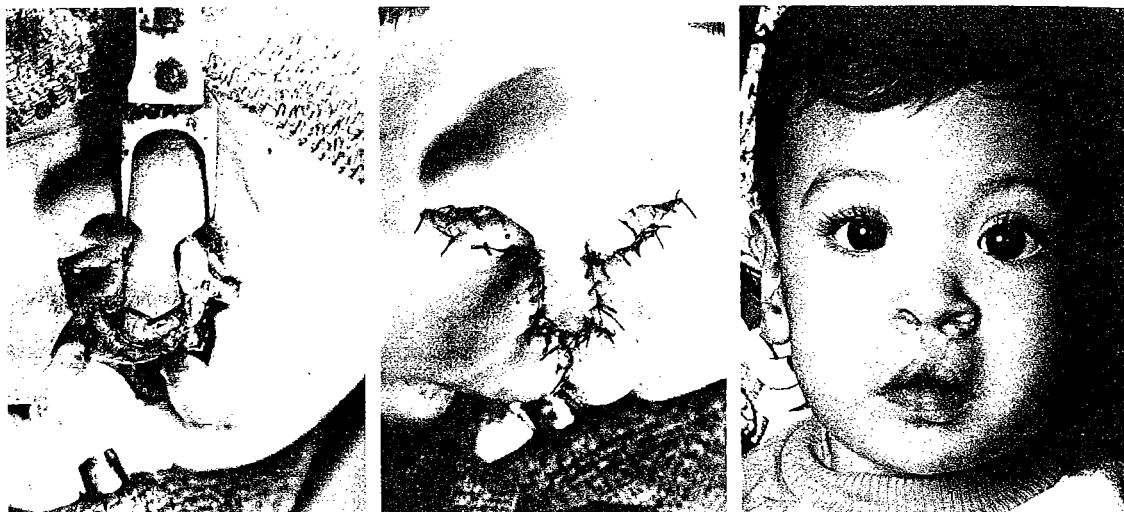2. A turndown cuff of inferior vermilion of the prolabium still allowed most of the posterior mucosa to be dissected from the backside of the prolabium. Based on the premaxilla, this mucosal flap was used to cover the denuded anterior surface of the premaxilla once the prolabium had been freed up to the base of the columella.

3. The usual lateral vermilion flaps carrying mucocutaneous ridge were cut from the sides of the lateral lip elements.

4. The mucosa and muscles of the lateral lip elements were advanced and sutured to each other across the midline. The prolabium was split on the undersurface and then replaced into philtrum position with a dimpling stitch. Small transverse incisions at the top of the prolabium allowed the skin tips of the lateral advancement flaps to fit in at the base of the columella.

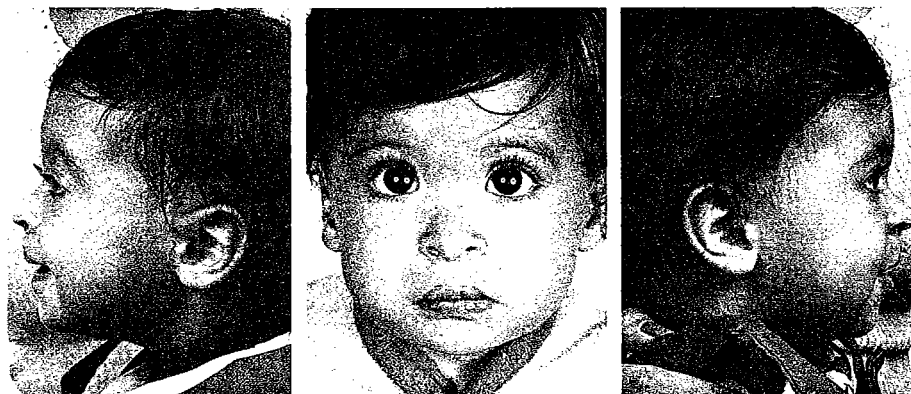5. The lateral vermilion flaps then overlapped the turndown of the prolabium vermilion to form a cupid's bow and to add slight length to the central component.

6. The prongs of the forked flap and lateral wing extension were folded together and then banked in the subalar incision in whisker position.



Again a relatively short prolabium was cut to match the relatively long lateral lip elements by the design of the forked flap, which simply is banked at this stage. Introduction of mucosa and muscle behind the prolabium and overlap of lateral vermilion carrying a mucocutaneous ridge below the prolabium bring more fullness to the forlorn philtrum component. In fact, these actions negate the necessity of dividing the prolabium from the nose at this early age or of introducing lateral skin flaps below the prolabium at any age!!

**EARLY COLUMELLA LENGTHENING.** As in the previous case, the incomplete clefting, intact alveolus and short prolabium seemed to justify early shifting of the banked fork into the columella. At age 16 months, just 3 months after the fork was banked, it was used to release the nasal tip.



Although these incomplete clefts have more columella than do complete clefts, they are still short of tissue and if not lengthened will partially snub the nasal tip in adolescence and adulthood.

Another late case not included in the statistics but a good example of a bilateral incomplete cleft with short columella. Family history was impressive with father having a bilateral cleft lip and mother's first cousin a cleft lip and palate. At six months of age, first stage of the forked flap was banked and mucosa and muscle of the lateral lip elements were united behind the columella. Cupid's bow was created with lateral mucocutaneous ridge and vermilion flaps transposed below the inferior border of the prolabium in front of the turndown of prolabium vermilion. The forks were banked in praying hands position in apposition with the freed alar bases and are readily available for advancement into the columella at about 4½ years of age.

