

## 20. *No Lip Muscle Union and Delaying the Forked Flap for a Year or Years*

EXPERIENCE with early columella lengthening with the forked flap as a secondary procedure at three to six months of age had suggested several points:

1. Lengthening the columella benefited the nose.
2. Giving up the forked flap benefited the prolabium.
3. But total division of the prolabium from the columella so early, especially in complete clefts, tended to produce a long lip in vertical dimension.

It raised the question: Is all this early hurry to help the flat nose worth the effort or indeed worthwhile?

There not being an obvious answer, I relaxed a bit in my pressure to correct the nose early.

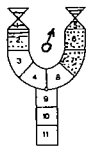
Here is a small series of cases treated mostly in the early 60's by a conservative routine. "Straddling the fence" and the premaxilla meant that more radical action was required eventually. The general plan was as follows:

1. *Closure of both sides of the lip cleft was to be done in one stage but without joining the lateral muscles to each other in the midline behind the freed prolabium. The muscleless prolabium was then at the mercy of the stretching action of the lateral lip musculature. This widened and flattened the prolabium but in some instances did not mold the premaxilla enough.*

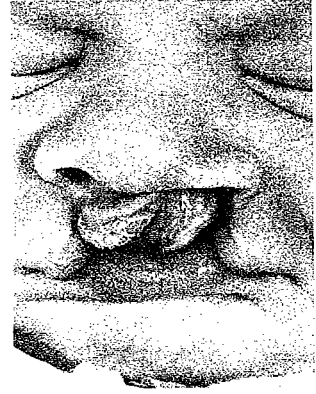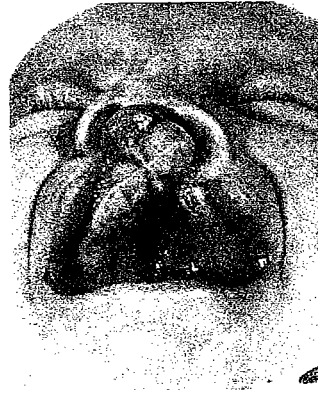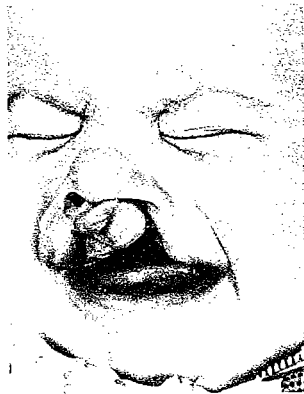2. In some cases *vomer resection* was necessary to set back the *premaxilla*. This was postponed to about four to five years of age.

3. In the absence of early columella lengthening, the columella remained short, dragging the nasal tip flat. Thus a *secondary forked flap in one stage*, usually at about five to six years of age, was planned to incorporate the bilateral lip scars and some of the stretched prolabium. This made reentry into the lip necessary with loss of the lovely lip scars of infancy. The "five points" of the one-stage forked flap at this age did not make such nice scars.

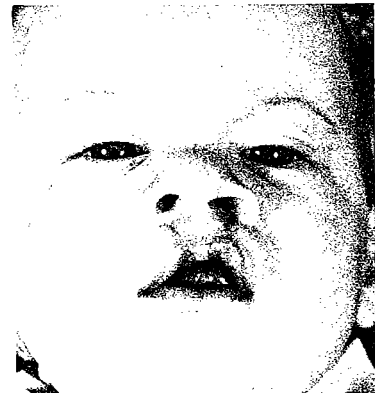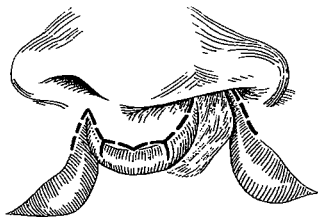
### NO MUSCLE UNION AND FORKED FLAP AT ONE YEAR



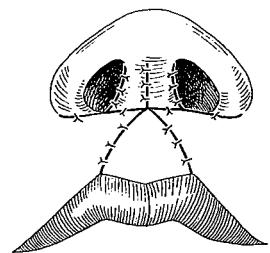
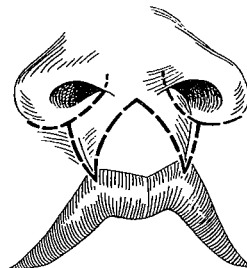
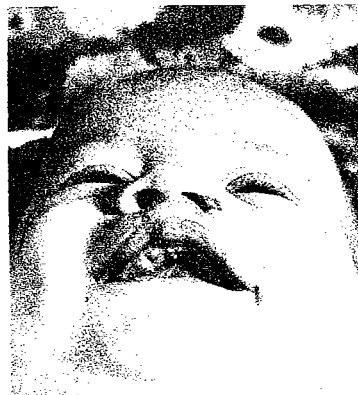B.D. 2-20-60  
 F.H. No clefts  
 F.T. Unevent-  
 ful  
 O.C.A. None



5-26-60. One-stage bilateral lip closure with lateral vermillion overlap of prolabium vermillion.



1-12-61. Forked flap for columella lengthening.





9-21-61



2-1-65



The patient returned nine years later revealing a philtrum and cupid's bow that was too wide, noticeable skin scars, lack of lip muscle continuity, a flared left ala and a retracted columella with a hooked, bulbous nasal tip.



14 years

Some of the surgical procedures which had to be used at age 15 years for secondary correction are now being used in the primary closure to bypass predictable problems.

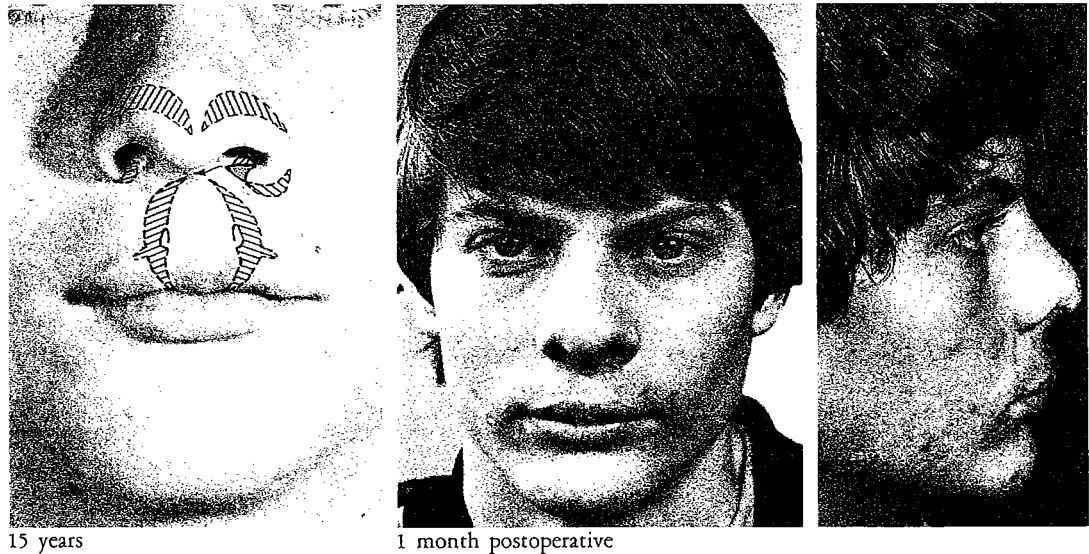1. During the bilateral scar revisions the prolabium was reduced to philtrum dimensions.
2. The lateral lip element musculature from each side was

dissected free and advanced into the prolabium to within 2 mm. of its counterpart and held with buried 4-0 Mersilene mattress sutures. This slight modification introduces muscles into the prolabium, but it was hoped that if the vertical center of the prolabium was left intact the bulges of the muscles up to this strip on each side would create the effect of philtrum columns flanking a central philtrum groove. Medial white roll flaps were transposed laterally.

3. The left alar base was cut free with a subcutaneous extension, which was advanced and sutured to the septal base. The right alar base was reduced by wedge resection.

4. The bulbous alar cartilages were reduced.

5. A submucous resection of the obstructing septal cartilage produced struts which were used to improve the contour of the retracted columella.

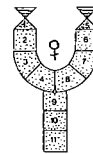
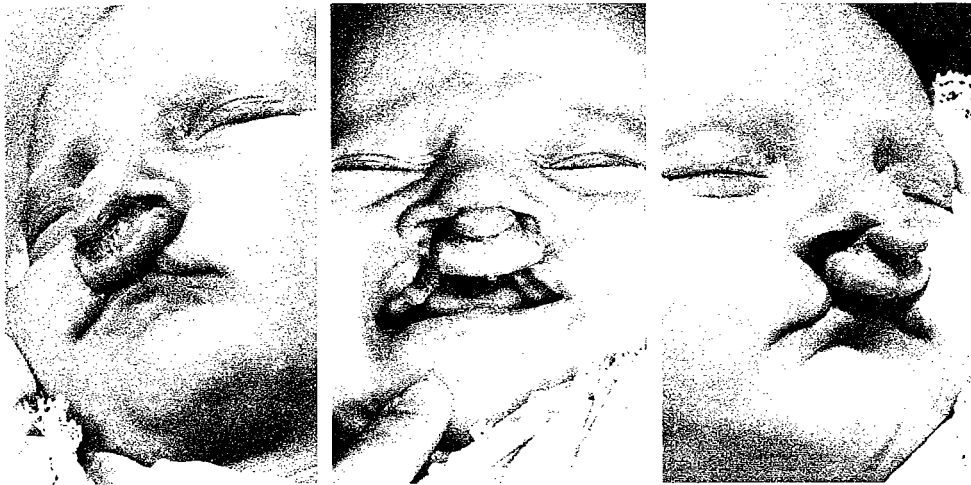

15 years

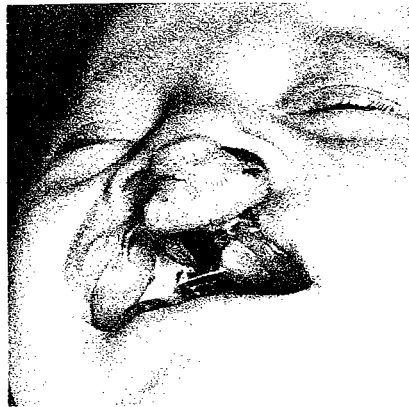1 month postoperative

It is encouraging that, in spite of the late forked flap and late lateral lip muscle advancement toward the midline, by 15 years of age a fine final functional and aesthetic result is possible.

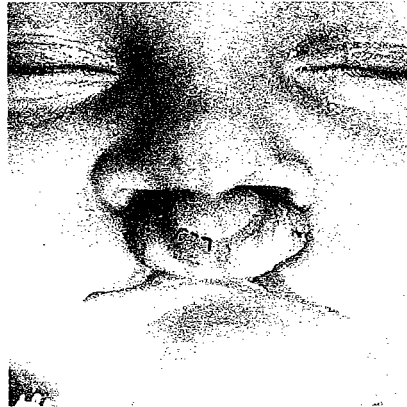NO MUSCLE UNION AND FORKED  
FLAP AT SIX YEARS



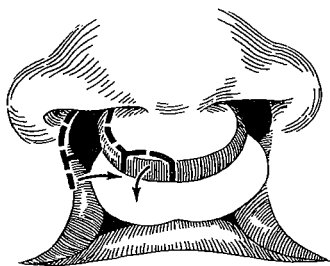
B.D. 3-20-63  
 F.H. Father  
 bilateral  
 CLP  
 with  
 project-  
 ing pre-  
 maxilla  
 F.T. Unevent-  
 ful  
 O.C.A. None



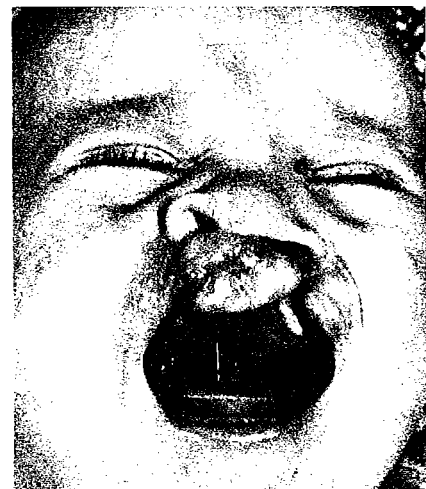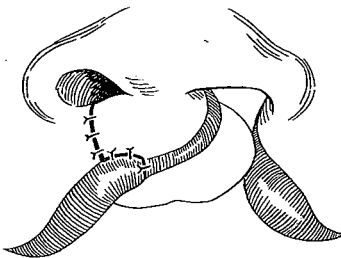
Balber's device



5-17-63. Balber started spreading  
 device.  
 6-21-63. Right side approximated  
 to prelabium with usual inferior  
 vermillion overlap.

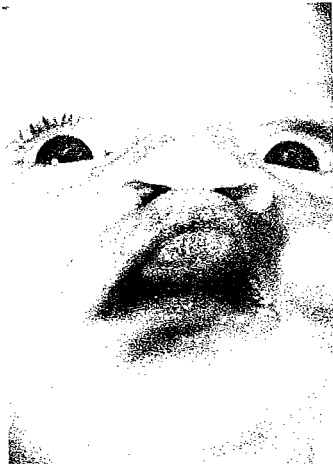

Right side first



7-8-63

8-12-63. Similar procedure on left. S.P.  
 2-22-66  
 Palate closed except vomer premaxillary component.



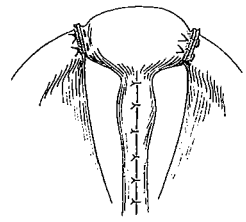
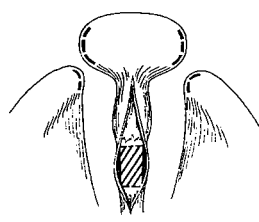
8-26-63



3-9-64



7-14-67. Vomer resection 1 cm. and setback.



1-30-68. Bilateral bone grafts to the alveolus.  
 2-21-69. Forked flap.



4 years

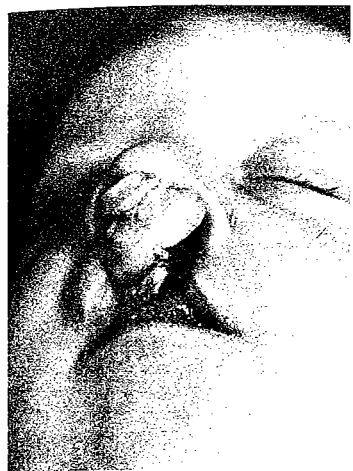

2-28-69

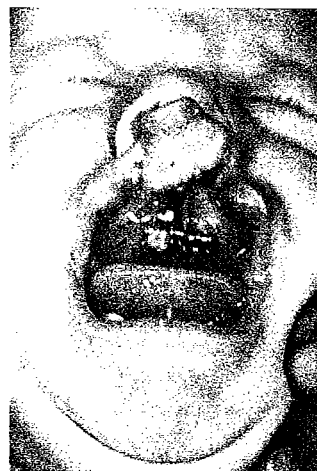
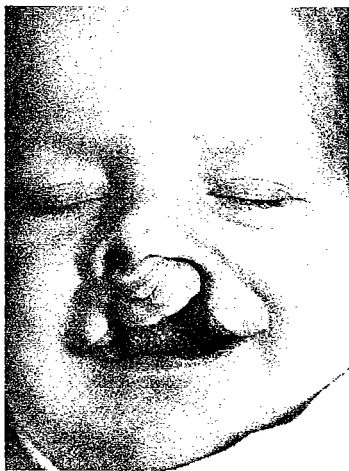
12 years

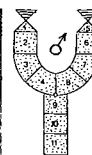
NO MUSCLE JOIN AND FORKED  
FLAP AT NINE YEARS



Deviated premaxilla with maxillary components approximated behind the premaxilla



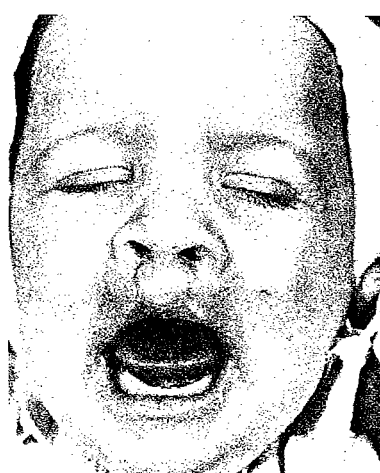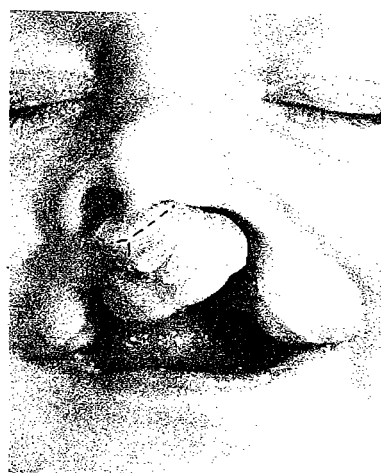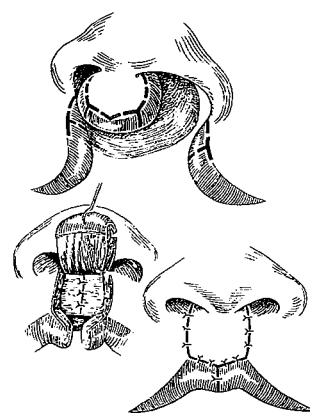
Balber device spreading the maxillae



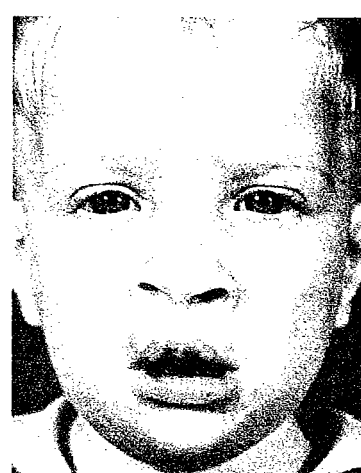B.D. 7-23-62  
F.H. Brother with unilateral CLP  
F.T. Uneventful  
O.C.A. None

At three and a half months the mucosa of the lateral lip elements was brought together and sutured behind the prolabium, which had been freed from its attachments to the premaxilla. The muscles of the lateral lip elements were brought to the sides of the prolabium with two chromic catgut sutures passing through the subcutaneous tissue of the prolabium. In other words, the lateral muscles were not sutured to each other across the cleft. Lateral vermilion flaps were used to overlap the turndown flap of prolabium vermilion.

11-5-62. One-stage bilateral lip closure.



2 months postoperative

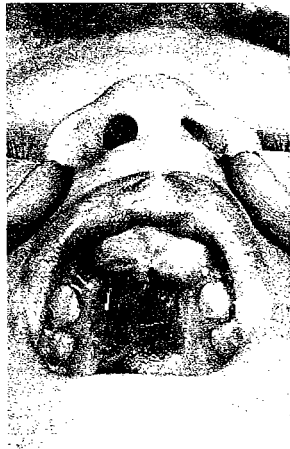

18 months postoperative

S.P.  
10-9-63  
H.P.  
8-6-69

The projecting premaxilla continued to be a problem. The soft palate was closed with pushback and island flap at 14 months of age. The hard palate was closed at seven years of age, and the following year, on June 3, 1970, a fistula in the hard palate was closed.

7-14-71. Forked flap at 9 years.



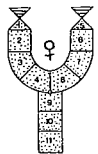6-12-70



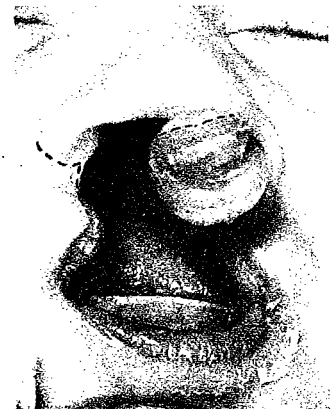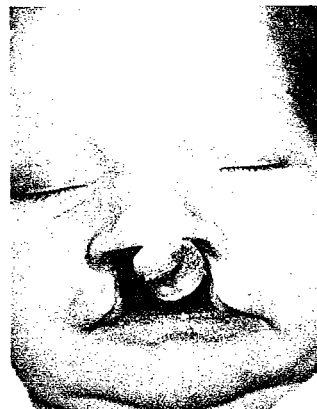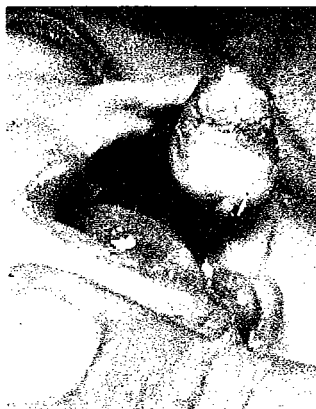11 years

The premaxilla needs further orthodontia, the columella and lip scars need revision and the lateral muscles must be brought together better.

MUCOSA BUT NO MUSCLE UNION  
AND FORKED FLAP AT  
SEVEN AND A HALF YEARS



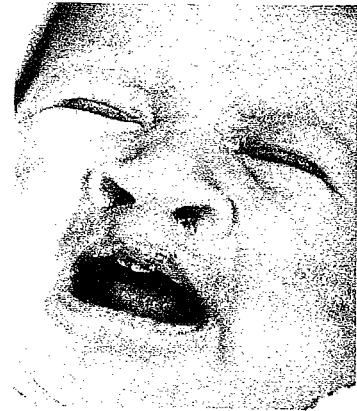B.D. 2-22-64  
F.H. Paternal grand-  
father and  
uncle  
with CL  
F.T. Unevent-  
ful  
O.C.A. None



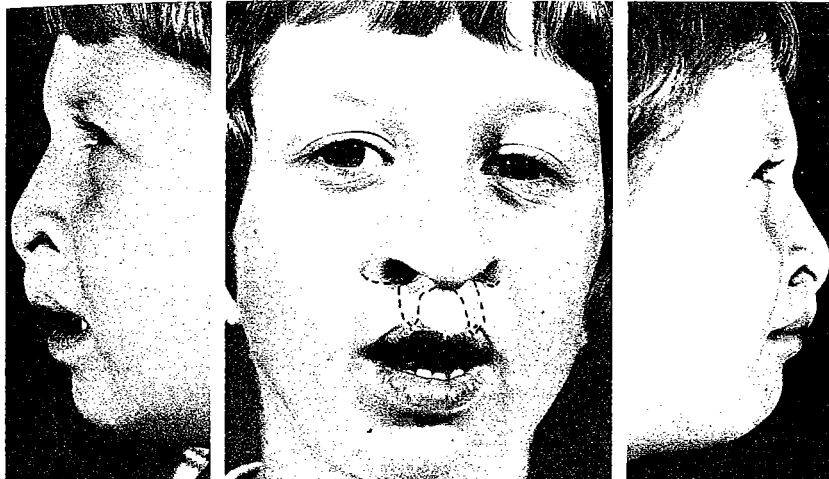At one month the prolabium was freed from the premaxilla, and the lateral lip elements were freed from the maxillae. The



lateral mucosa was sutured together under the prolabium, but the *muscles* were not joined. The lateral vermilion flaps were used to overlap the turndown of prolabium vermilion.



3-26-64



6 years

The forked flap was delayed because of the projecting premaxilla until seven and a half years of age. It is a shame to have to leave a child like this so long.

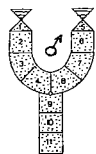


11 years

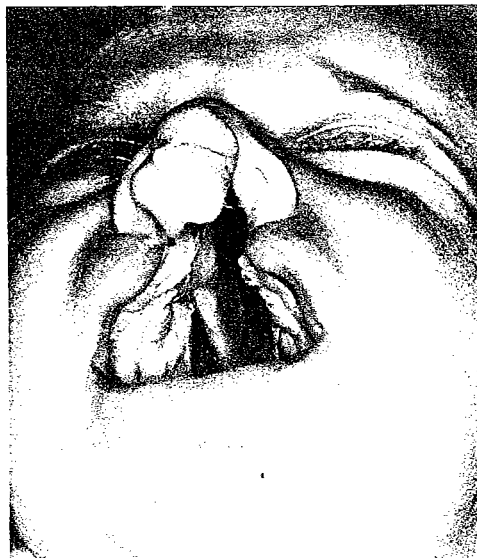S.P.  
8-19-65. Modified  
Langenbeck soft  
palate closure.  
H.P.  
2-26-69. Closure  
of hard palate.  
7-9-71. Forked  
flap.  
12-12-72. Iliac  
bone grafts to  
premaxilla.

Reentry into the lip at this age does not get good scars and takes a long time to heal. Lip revision and reduction rhinoplasty are planned at 16 years.

## NO MUSCLE UNION AND FORKED FLAP AT NINE YEARS

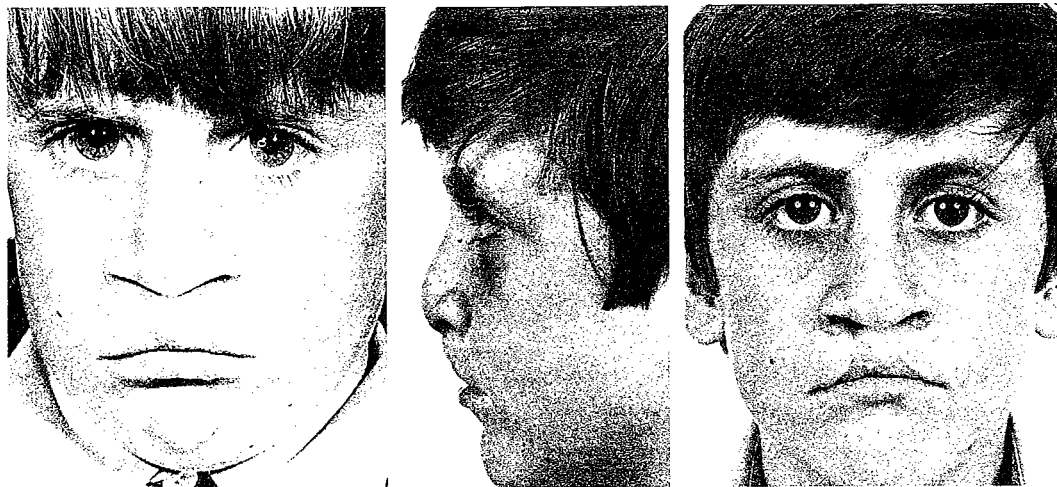


B.D. 4-10-67  
 F.H. Unknown  
 F.T. Urinary infection  
 O.C.A. None



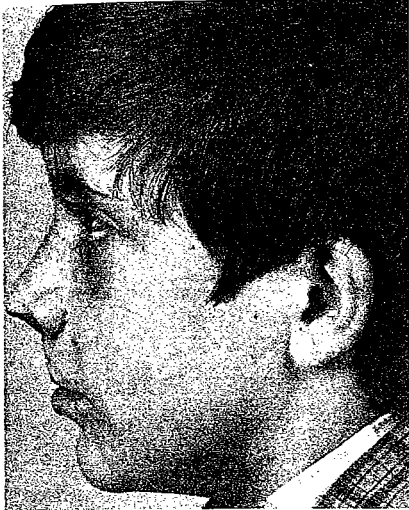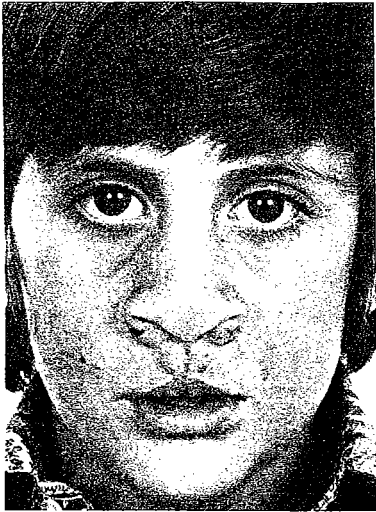8-24-67. Lip closure.  
 S.P.  
 3-4-68. Soft palate closure.  
 5-8-69. Maxillary expansion device inserted.

At four and a half months of age, one-stage lip closure was accomplished. Because of excessive protrusion of the premaxilla a "conservative" straight-line closure was obtained on each side with no effort to join the lateral lip mucosa or muscles behind the prolabium. The lateral vermilion flaps were used to overlap the turndown of prolabium vermilion.

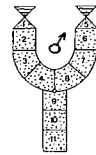
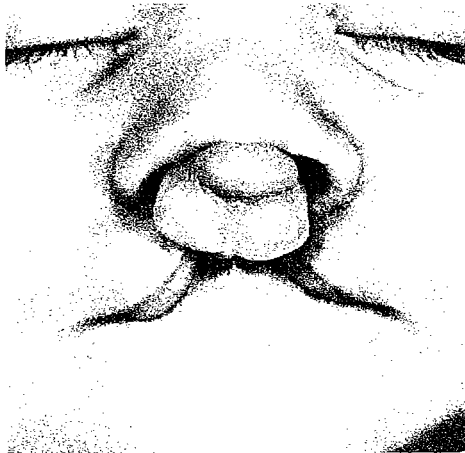
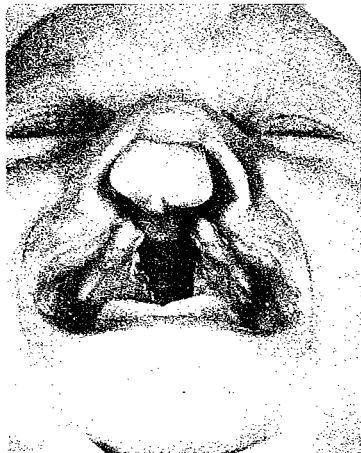


At four and a half and later at nine years of age the lip was not too long *but* the prolabium and certainly the cupid's bow were too broad, the nasal tip was flat, the alar bases were severely spread and the columella was nonexistent.

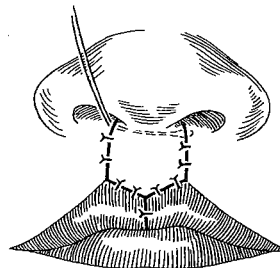
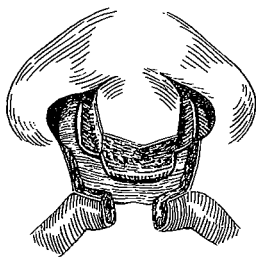
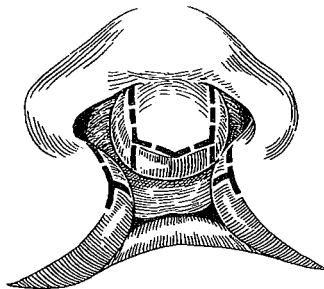
At 9 years the fork was stored in whisker position. The lateral lip mucosa and muscle elements were united behind the prolabium and dimple stitches placed. Six weeks later, the forked flap was advanced into the columella and the alar bases advanced medially. Time will smooth this result and final minor corrections will be made at 16 years.



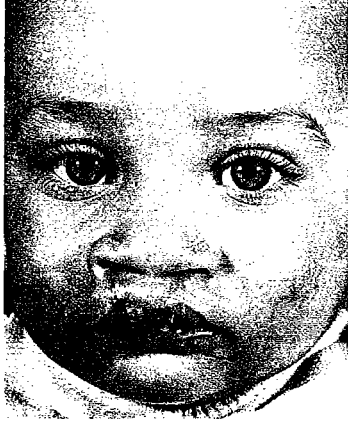MUSCLE UNION AND FORKED FLAP AT SEVEN YEARS



B.D. 3-2-68  
 F.H. Paternal first cousin with bilateral CLP  
 F.T. Uneventful  
 O.C.A. None



5-20-68. Lip closure.



At two and a half months of age, one-stage lip closure, without undermining of the lateral lip elements from the maxillae, was used to try the C-W approach. There was a gradual partial separation on the right which after three weeks required approximation. The failure to join the lateral muscles together behind the prolabium and the persistent forward projection of the premaxilla caused a gradual stretching of the prolabium to unnatural breadth. Finally, at five years the premaxilla was set back moderately by resection of a portion of the vomer, and orthodontics was carried out by S. Berkowitz.

S.P.

2-23-70. Soft palate closure.

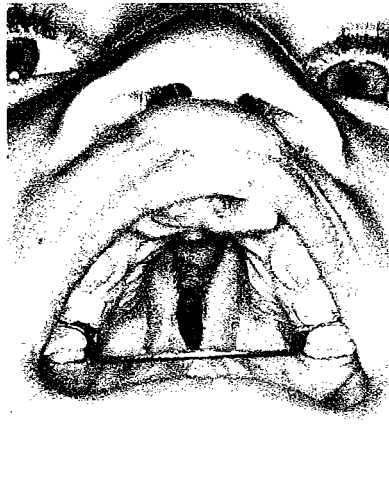7-26-73. Premaxillary setback.

H.P.

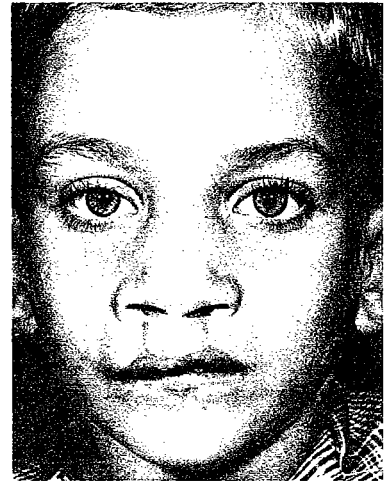11-28-73. Hard palate closure with vomer flap.



Before setback;  
age 4½ years



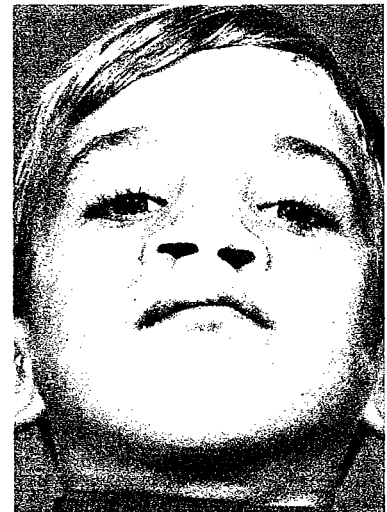
2 months after setback



Age 5½ years; still needs forked flap to columella and reduction of prolabium



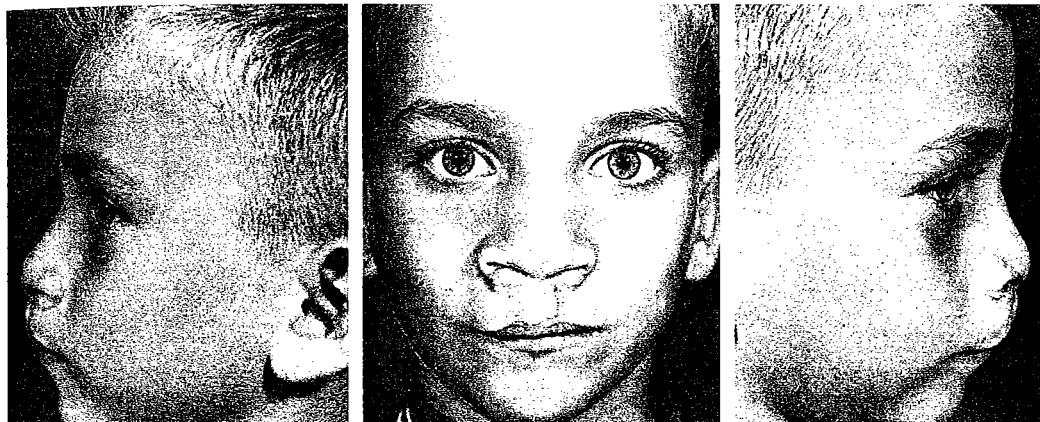Age 6½ years



Already past school entry age, the patient had a flat nose and wide prolabium which forced secondary action in spite of the fact

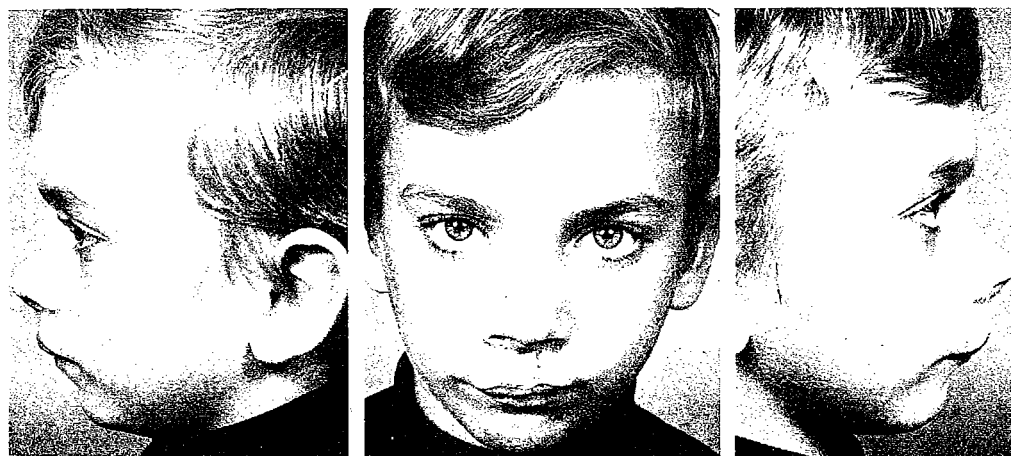that the premaxilla was still a projecting obstacle.

In May 1975 the prolabium was reduced by a forked flap which was banked in whisker position. The lateral muscles were joined together behind the prolabium.



7 years

Six months later, the forked flap was advanced into the columella to release the nasal tip, and the alar bases were advanced medially.



7½ years

As the nasal bridge grows, this over-projection of the tip will be accommodated.

*Note:* It must be admitted that in this type of case, as the prolabium was small and the premaxilla severely projecting, there may be some justification for postponement of a forked flap and lip muscle union primarily. This allows stretching of the prolabium and setback of the premaxilla if such maneuvers are necessary.

THIS TYPE OF CONSERVATISM CAN  
RESTRICT PROGRESS OF PRINCIPLES

*This approach  
for me is  
now*

**OBSOLETE**

As it turned out, this type of "conservative" approach did not join the lateral muscles across the cleft, did not mold the premaxilla as well, allowed the prolabium to be stretched thin and, by postponing columella lengthening with the forked flap, left the nasal tip flat for years. Then when the forked flap finally was taken out of the lip, the resultant "five points" scarring at this age was not as satisfactory and took years to soften. It is hoped that the ultimate results will be quite satisfactory, but the number of operations and the delay in time seemed too much. The exception, of course, is when the prolabium is too small and the premaxilla too projecting. There had to be a better way and the *search* continued.