

## 17. *The Forked Flap*

I N 1956-1957 I designed a secondary forked flap for columella lengthening which was shaped like an inverted V and split like a serpent's fangs. The flaps incorporated the bilateral lip scars and any prolabium not needed and were taken deep enough to give body to the columella construction. These flaps which were continuous with the nasal tip, were cut out of the lip. Then with the aid of a membranous septal incision carried up over the tip, the forks were folded together and slid up along the septum. They were sutured to each other and then to their new and exalted position on the septum. The midline seam in the columella was unnoticeable. Actually, the two flaps mold into a columella with greater facility than does one larger flap, which tends to resist being forced into a hemi-column. The distal extremities of the forked flap are splayed laterally as columella base flowing into the nasal floor as nostril sill. Closure of the donor area with the aid of alar base incisions is similar to a rotation-advancement action. The forked flap cured a few ills. It afforded:

1. Release of depressed nasal tip.
2. Lengthening of the short columella.
3. Reduction of an unattractively wide prolabium to more natural proportions.
4. Revision of bilateral lip scars.
5. Reduction of the flaring alar bases.

Although the forked flap was carried out originally as a secondary procedure, its value as a delayed primary procedure was soon to become evident.

## DELAYED PRIMARY FORKED FLAP

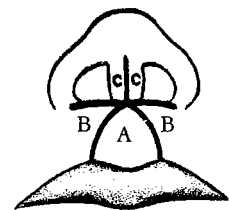
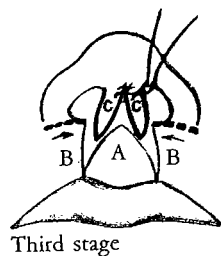
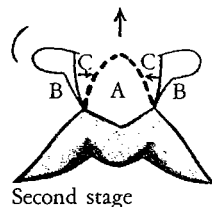
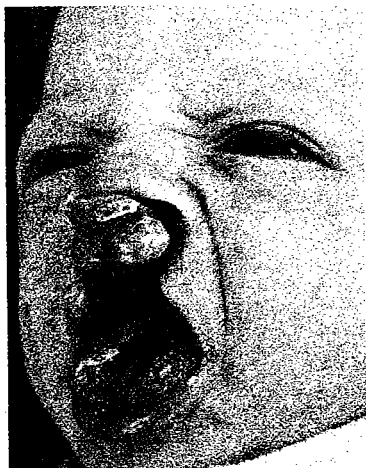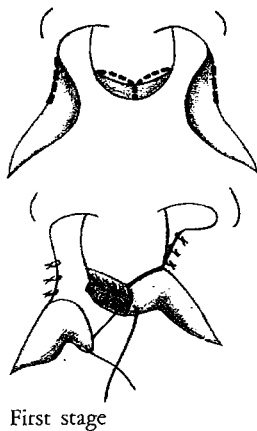
It seemed logical that if the forked flap was effective secondarily, it should be called into action sooner. In fact, it was predicted in 1958:

In severe bilateral clefts, when the columella is extremely short but the prolabium of reasonable size, a modified forked flap may be used primarily.

### FIRST CASE

In 1959 the Second International Congress of Plastic Surgery met in London amidst great and colorful pomp and ceremony at the Royal College of Surgeons and at Guildhall. During this meeting and subsequently in the 1960 *Transactions* of the International Society it was my privilege to present the design diagrams and the early result of a 1958 case in which the rotation-advancement method had the forked flap added in the third stage at five months of age to give a delayed primary columella lengthening.

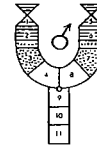
In the first stage, at two months, lateral vermilion flaps were used to overlap the turndown of vermilion from the prolabium to create a full-bodied cupid's bow. This procedure also brought in blood supply to the inferior edge of the prolabium in preparation for a delayed forked flap. In this case the premaxilla was inset at the same time into the alveolar arch, but as there was no palate cleft the problem was unusual. This was one of the first examples of early adhesion and, of course, served to mold the position of the premaxilla in the arch. At *five months of age* the delayed forked flap was elevated and advanced into the columella with release of the nasal tip.



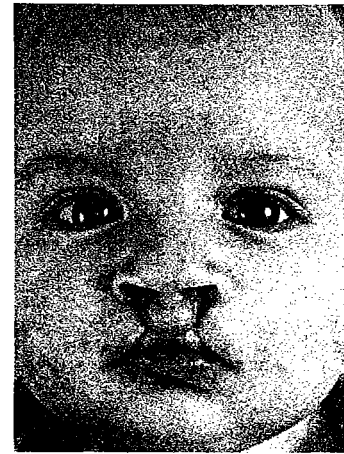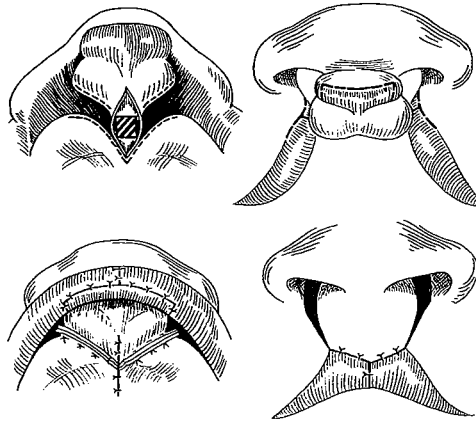
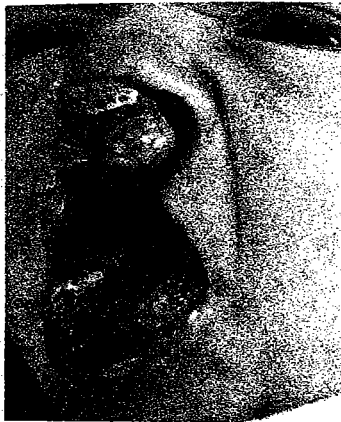The specific details of this initial case are interesting. The patient was born with a bilateral complete cleft of the lip and alveolus (primary palate) with projection of the premaxilla but

no cleft of the hard or soft palate and almost no columella at all.

On November 5, 1958, at about two months of age the mucoperiosteum of the area in front of the vomer swelling was split and the "overgrowth" was rongeured away. The mucoperiosteum of the cleft edges and premaxilla was dissected and approximated with sutures so that, when the premaxilla was pushed back into the notch in the alveolus and wired, union could follow. The lateral vermilion flaps were used to overlap an inferior prolabium vermilion flap to create a cupid's bow and bring in blood supply to the prolabium for subsequent surgery. This was also an early type of preliminary adhesion.

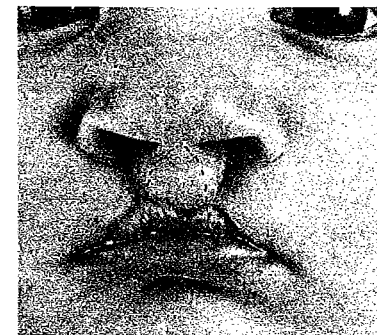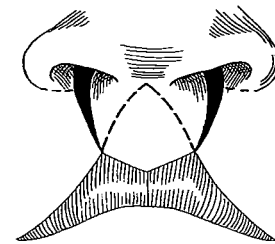


B.D. 9-6-58  
 F.H. No clefts  
 E.T. Unevent-ful  
 O.C.A. None

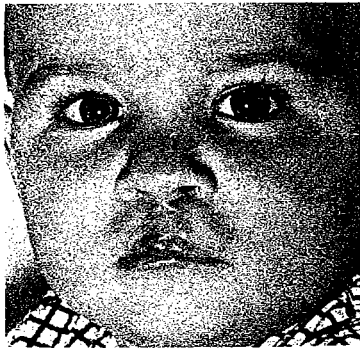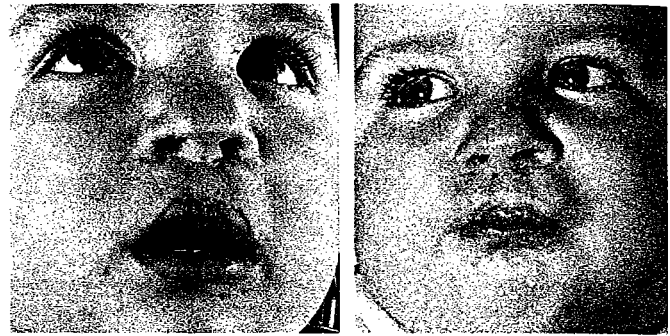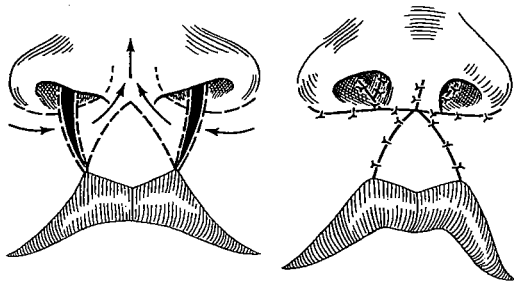


2 weeks postoperative

My concern for the blood supply of the forked flap caused me to diagram the delay incisions on the prolabium and cut them two months after the initial surgery. In the first few cases the forked flap was used even before the cleft edges had actually been approximated. Thus the amount of tissue available was reduced, of course, as the scars of union were not present to contribute to the bulk of the forks. Two weeks later, on February 3, 1959, the delayed forked flap was cut from the lip and with the aid of a membranous septal incision was advanced along the septum elevating the nasal tip and creating a columella. The lateral lip



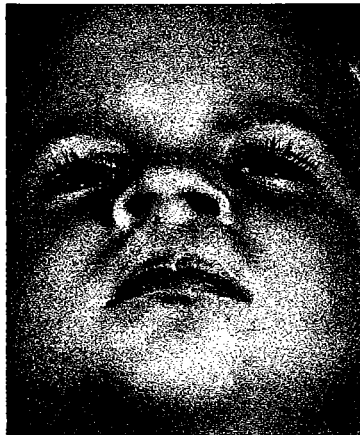
elements were brought together tip to tip and then sutured in layers to the sides of the remaining prolabium.



The last sentence of my operative note is of interest and turned out to be a prophecy:

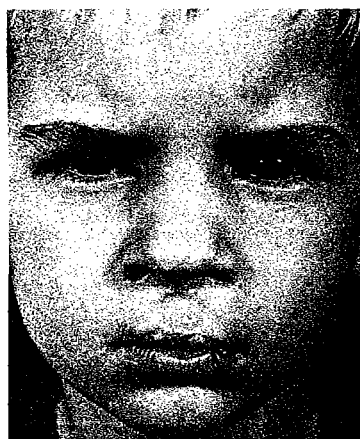
The difficulty here was focused on the *five points* closure where the two prongs of the fork, the two tips of the advancement flaps and the upper point of the prolabium all come together. Time alone will tell.

Four months postoperatively the scars at the five points were unsatisfactory, but as the months passed the scars improved. Nevertheless, this is a disadvantage in the original design and only years later was modified.



1961

Sporadic minor scar revisions and lip shortening produced as reasonable a lip as can be achieved without joining the muscles across the cleft. The early design of the staged primary columella lengthening marked the ends of the forked flap pointed and thus too short for the total need. The immediate result was promising, and over the years the gain had been maintained and the growth of the nose benefited by the early tip release. Then in 1970 editor Frank McDowell requested proof of the value of early columella lengthening to justify pursuit of this principle in my *Plastic and Reconstructive Surgery* article "Closure of Bilateral Cleft Lip and Elongation of the Columella by Two Operations in Infancy" and a 12-year follow-up was published.



1962

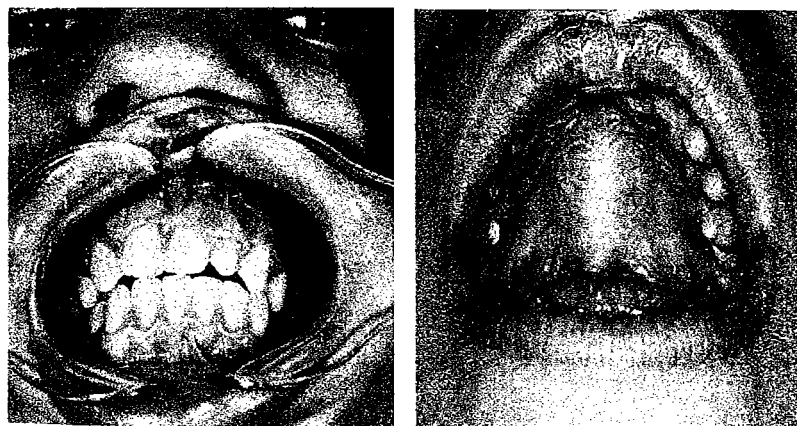

12 years

Finally, on July 5, 1972, at age 14, this outstanding young man had a slight columella lengthening with advancement of his alar bases and nostril floors in a V-Y fashion. A subcutaneous flap was carved from the center of his prolabium to create a hollow and turned down to give more fullness to his tubercle.



Another aspect of this case of particular interest to dentists and surgeons is the 14-year follow-up of the upper dental arch. At age two months the projecting premaxilla had its edges freshened, anterior "overgrowth" of the vomer resected, pushback and wiring of the premaxilla into the alveolar notch. Today the teeth are excellent and in reasonable occlusion and growth seems to be progressing normally.

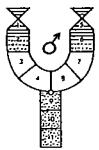


Two years later, at age 16, scar revision, lip shortening, muscle approximation, nasal tip tailoring and columella bolstering finally achieved correct labial and nasal proportions. When the scars have healed and softened, the appearance and function should be within normal limits.



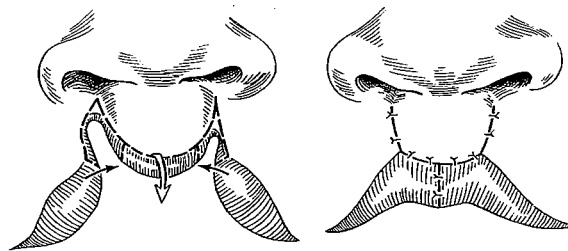
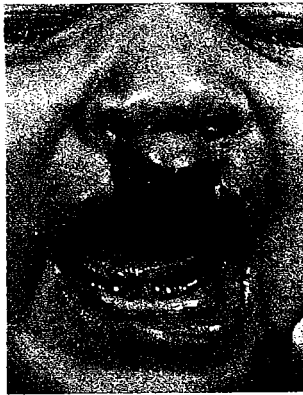16 years

### SIMILAR APPROACH IN BILATERAL INCOMPLETE CLEFTS

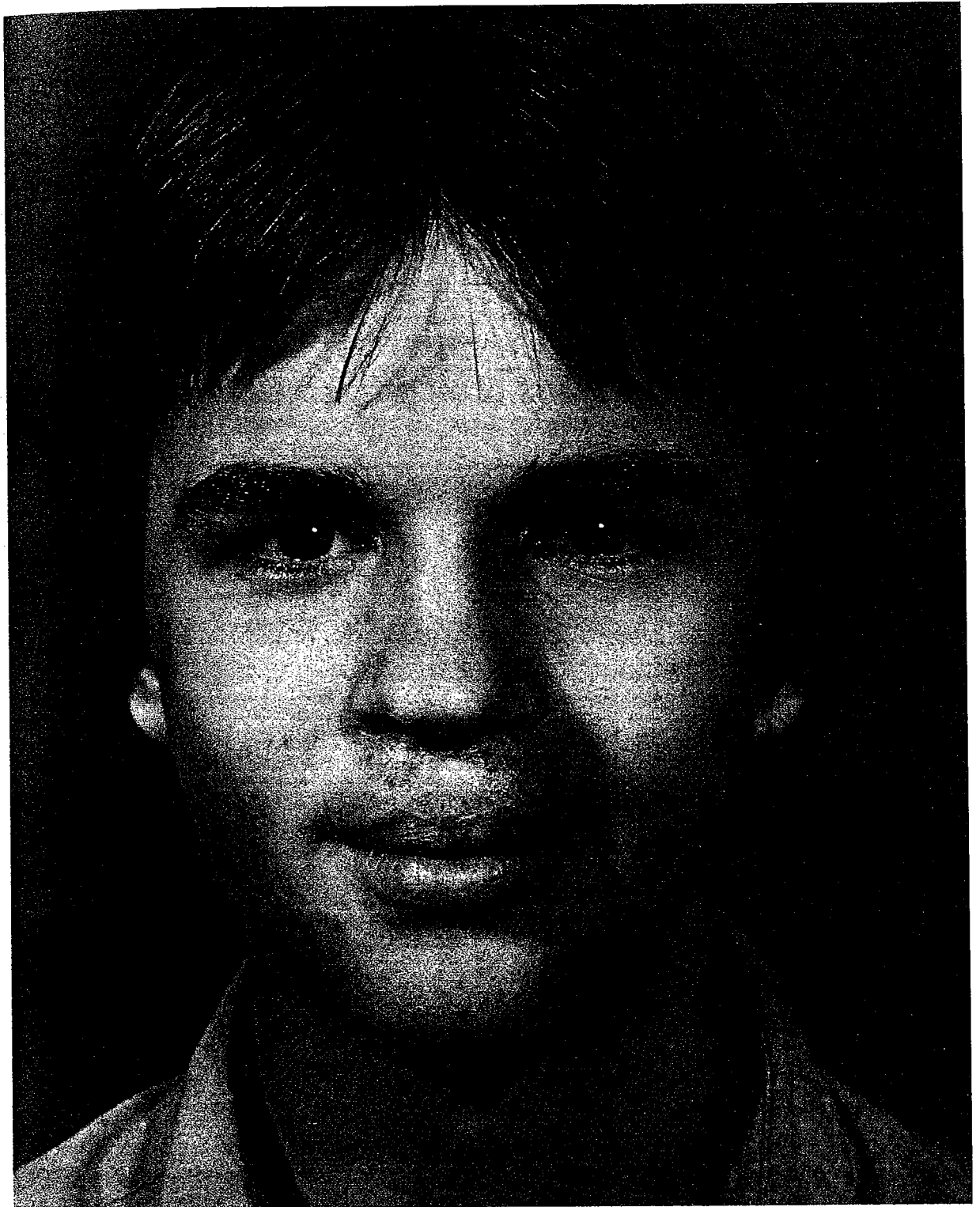


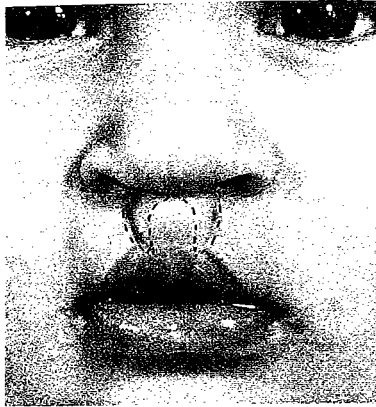B.D. 2-22-60  
 F.H. Brother with incomplete unilateral cleft lip  
 F.T. Uneventful  
 O.C.A. None

This patient was born with bilateral incomplete clefts of the lip, short columella and a cleft of the hard and soft palate posterior to the incisive foramen. On June 7, 1960, at three and a half months of age, lateral vermilion flaps were used to overlap the turndown of inferior prolabium vermilion, but the freshened edges of the lateral lip elements were sutured to the freshened sides of the prolabium in this first stage.



Six weeks later, on July 19, 1960, at five months of age, a forked flap was taken out of the lip incorporating portions of the prolabium, lateral lip and the joining scars. These flaps were advanced along the septum to form an adequate columella and simultaneously release the depressed nasal tip.





H.P. closed at 14 months with vomerine flap. Pushback with island flap at 18 months.

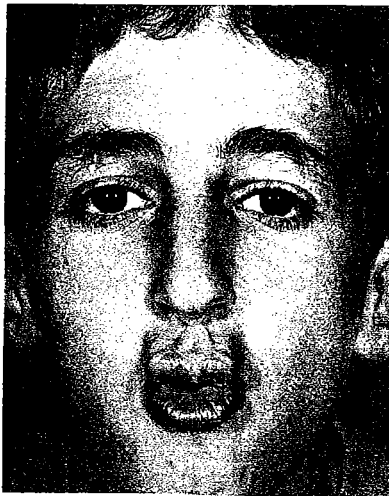
On February 22, 1962, at two years of age, scar revision was undertaken, prolabium skin undermined, subcutaneous tissue removed and a through-and-through suture tied over the bolus to create a dimple in the philtrum.



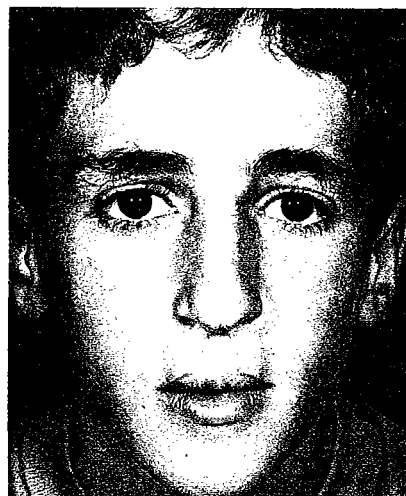2 years



6 years



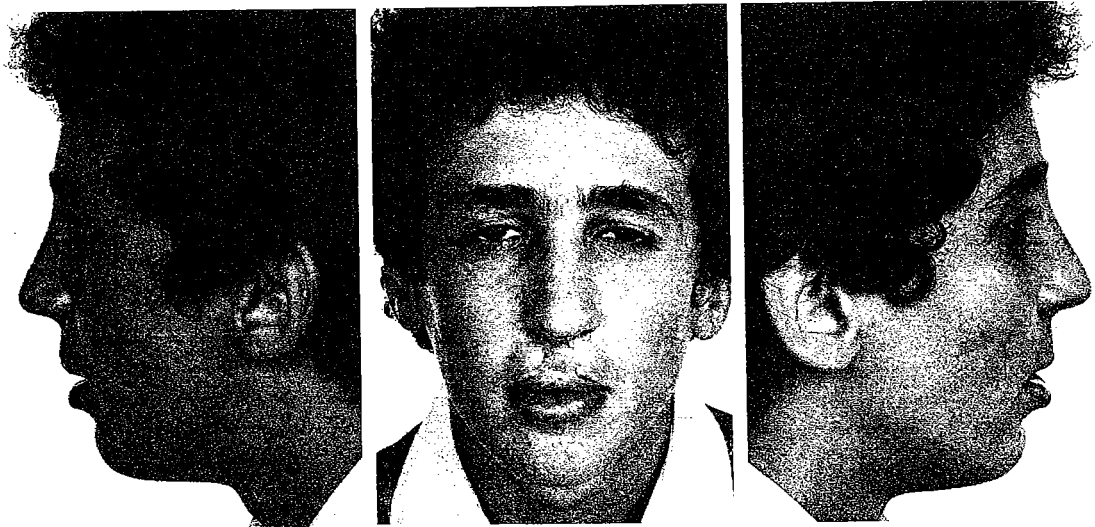13 years



At 16 years of age minor lip scar revision and corrective rhinoplasty were carried out. Alar cartilages were reduced, bridge



straightened, septum shortened, alar bases denuded and advanced to each other, submucous resection to improve airway and septal cartilage inserted into the columella for nasal tip lift and definition. It was exciting to be completing a case which had no columella and had a forked flap release at 5 months of age!

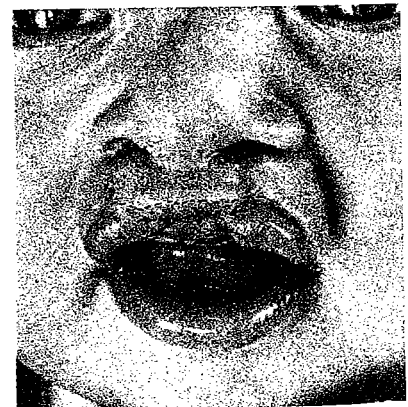
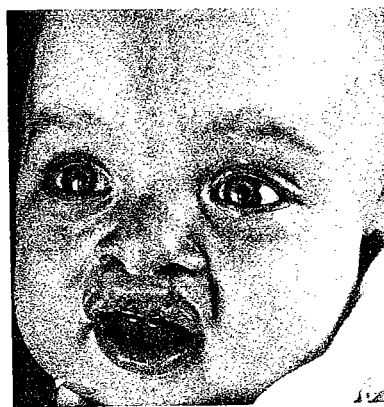
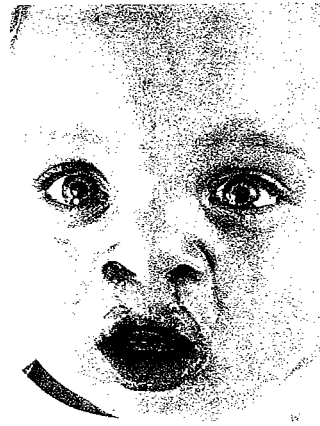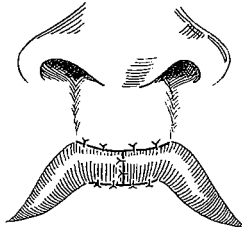
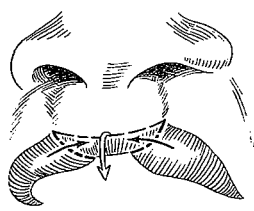
16 years of age and 3 weeks after rhinoplasty

#### A LATE START

Of course, it is easier when the surgeon gets the case from the beginning. Here is an example of starting late. The patient was born with bilateral cleft lip and palate with protruding premaxilla which was closed at one month on one side and two weeks later on the other. The present surgeon first saw the patient at six months, with lateral elements attached to the sides of the prolabium, the prolabium vermilion intact, the columella absent and the premaxilla protruding. What to do now?

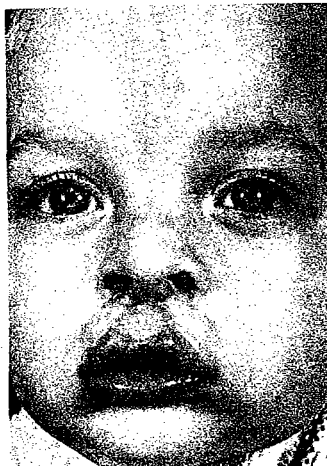B.D. 9-14-58  
 F.H. No clefts  
 F.T. Ovarian cyst removed  
 O.C.A. None





5-13-59. Premaxilla set back and small vomer resection. Lateral vermilion flaps maneuvered to overlap prolabium vermilion.

On August 8, 1959, the premaxilla was still prominent so Gillies' reduction was used—anterior plate and tooth buds of the premaxilla were removed and the posterior plate was maintained. A forked flap was incised for a surgical delay and later advanced into the columella.



18 months



10 years



11 years

11-11-59. Forked flap lengthened columella.

H.P.

1-18-61. Vomer flap.

S.P.

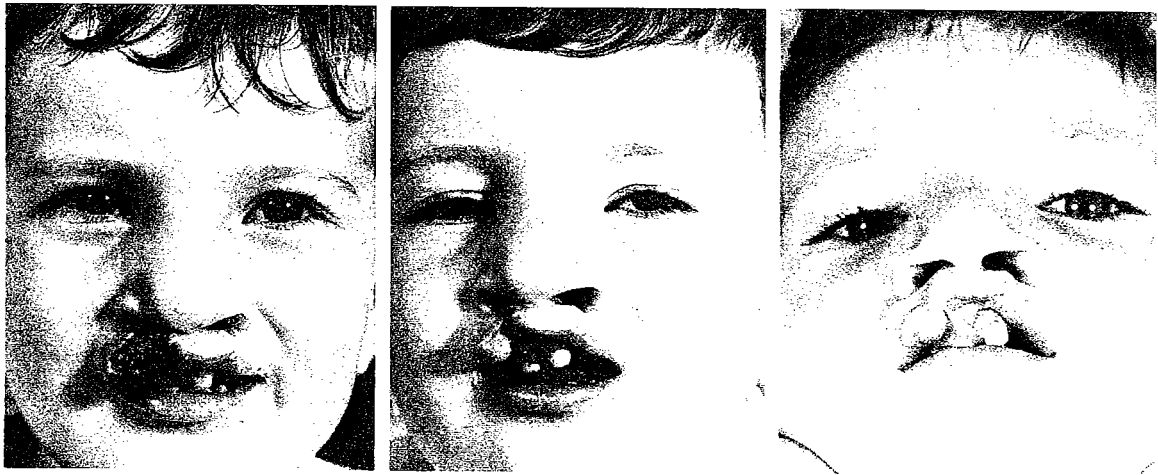5-31-61. Pushback with island flap.

On August 7, 1969, important lip revisions were done. The width of the prolabium was reduced and in the process "white roll" flaps became available to be introduced between skin and vermilion along the entire lower border of the prolabium. The columella was revised.

#### A LATE AND UNUSUAL PROBLEM

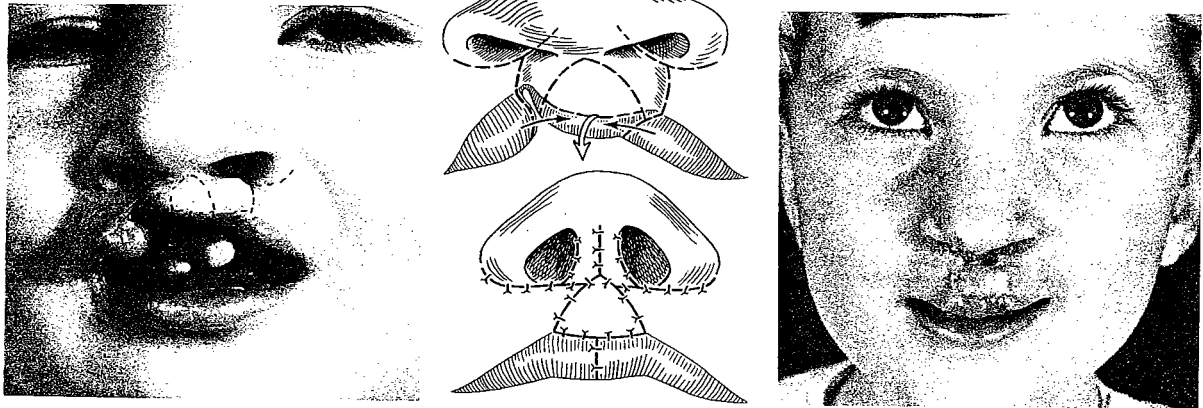
A two-year-old bilateral cleft lip and palate patient had, from the vague history, had both lip clefts approximated and subsequently the palate closed. A secondary LeMesurier procedure had been done on the right and the patient discharged with sutures in

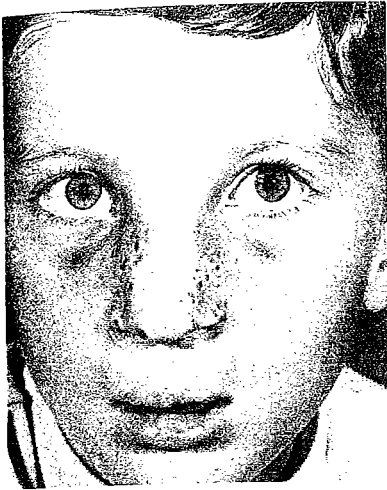place. As he proved later with me, this patient was rambunctious and proceeded to strike his lip, with total wound disruption. The other surgeon was so upset that somehow I inherited the problem. On April 2, 1965, the child presented an open wound with eschar, shortness of the columella and a wobbly premaxilla ununited on the left and projecting in front of the maxilla. The patient was left to heal his wound, the process taking about three weeks, and in this interim he managed to lacerate his nose, requiring a suture for hemostasis!



During the next 18 months no surgery was done, but William Silver continued orthodontic care. Then a forked flap which had long been in his future, as marked, was advanced into the columella.

10-28-66. Forked flap





5 1/2 years

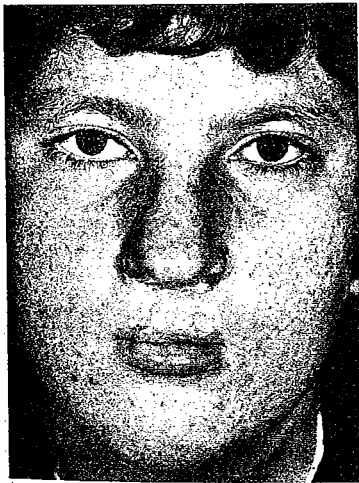

6 years

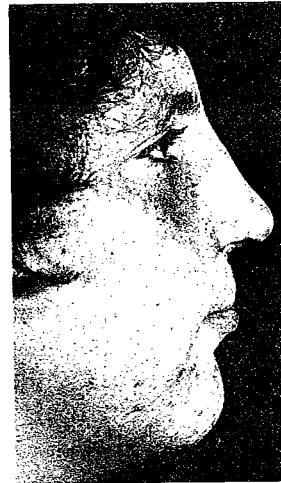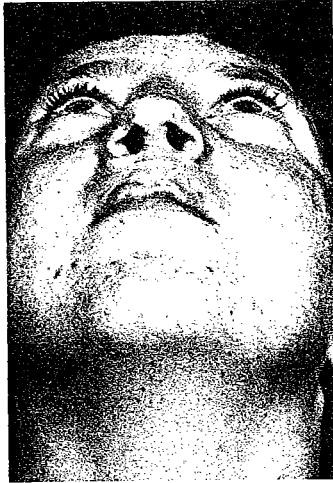


8-15-69. Pharyngeal flap.

It was planned that at age 16 years a septal cartilage strut would be inserted to support the fork. When the patient was seen again at 12 years, as he expressed concern about his columella retraction and airway obstruction, a modified submucous resection of the deviated septal cartilage supplied a strut. This was fashioned to the shape of a Bowie knife as suggested by Dibbell and inserted for columella correction and tip support. A subcutaneous flap cut from the center of the prolabium and based superiorly was split, and the prongs were advanced into upper deficiencies in the lateral lip elements.



12 years



6-5-75. S.M.R. and cartilage strut to columella.

Final revisions including a corrective rhinoplasty will be postponed until the patient is 16 years of age.