

## 15. Adaptation of the Rotation-Advancement Principle in Bilateral Incomplete Clefts

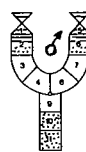
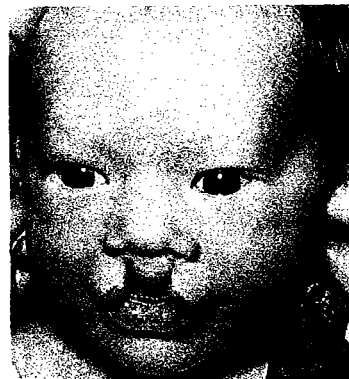WHEN the rotation-advancement principle was being developed in unilateral clefts in Korea, it did not occur to me that the same principle might be of value in bilateral clefts because there was no vestige of a cupid's bow. Once the method caught on in unilateral clefts, surgeons began to ask about its application in the bilateral problem and I turned my attention to the possibility. This is its evolution.

My original adaptation of rotation-advancement in bilateral incomplete clefts included a design lengthening the short prolabium. In 1960 in *Surgery, Gynecology and Obstetrics* I wrote:

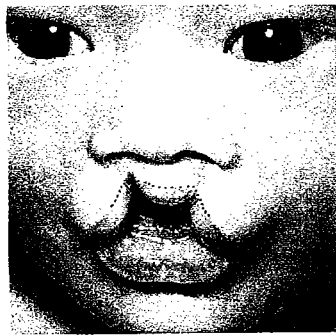In bilateral incomplete clefts the columella is usually of adequate length and the nasal tip is in normal position. The discrepancy in vertical frontonasal length lies in the shortness of the prolabium. . . . A logical approach would seem to be division of the short prolabium from the normal nose component so that it can be moved down into the natural philtrum position in the lip. Maintenance of this correction can be achieved by advancement of lateral lip flaps into the gap between columella and prolabium.

### IN FOUR STAGES

The first incomplete bilateral cleft case in which the rotation-advancement principle was used was published in the *Transactions of the 2nd International Congress of Plastic Surgery*. It was not ideal

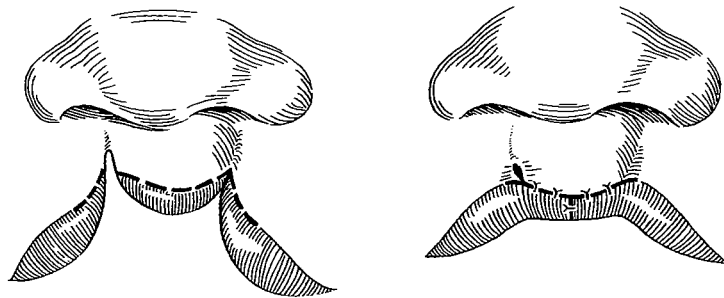


B.D.	11-11-56
F.H.	No clefts
E.T.	Uneventful
O.C.A.	None



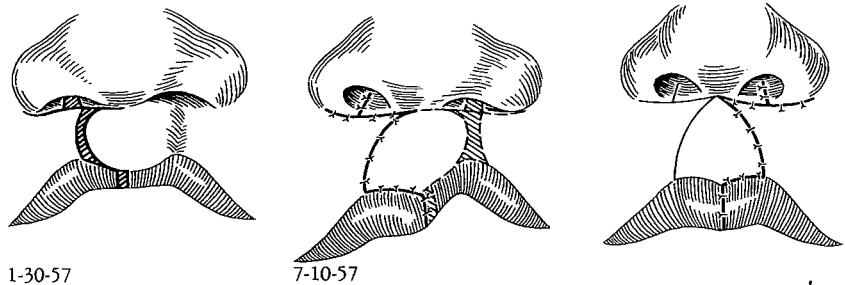
as the columella was moderately short. Being experimental, the surgery was staged conservatively in multiple steps.

On November 27, 1956, the lateral vermilion flaps were used to overlap the turndown flap of inferior prolabium vermilion. This procedure created the effect of a cupid's bow and ensured a tubercle but, as I wrote in my operative note at the time, it was most important to give a blood supply to the prolabium for later work.



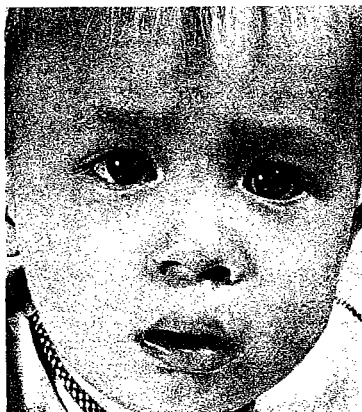Evidently I had some concern about the vascularity of the prolabium if it were cut completely off from the nose by bilateral rotation-advancement incisions.

Two months later a right-sided rotation-advancement procedure was carried out, and five and a half months later the left side was treated identically.



1-30-57

7-10-57



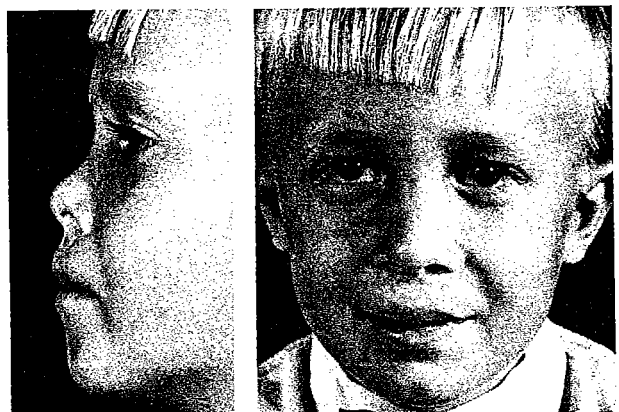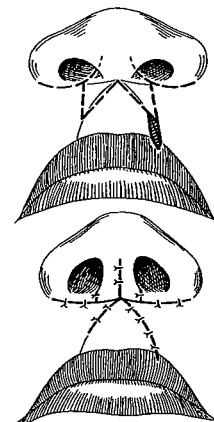
1 year

H.P. 11-1-57

Vomerine flap closure

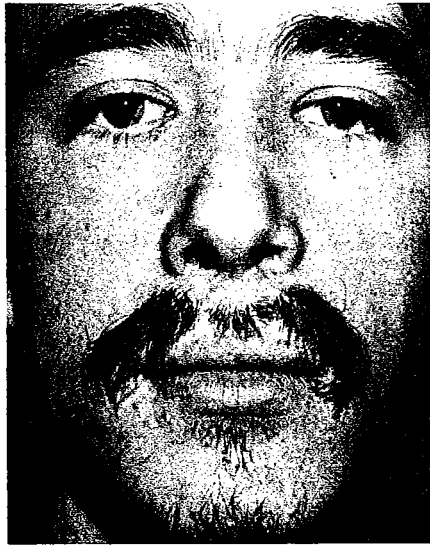

S.P. 1-8-58

Wardill V-Y pushback



4 years

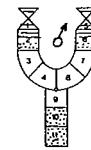
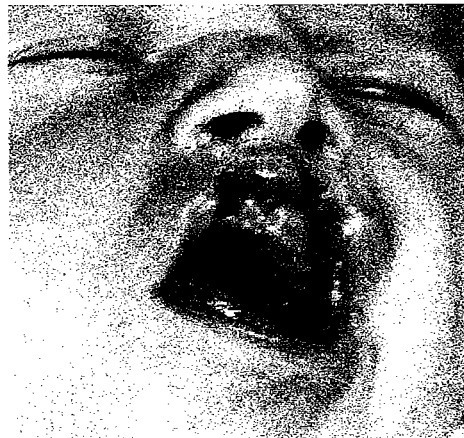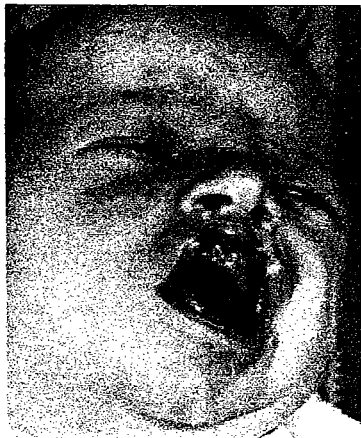As could be predicted, the nasal tip continued to be flat and the alae wide so that on March 12, 1959, a modified forked flap lengthened the columella moderately and reduced the alar flare.



18 years

### REDUCED TO TWO STAGES

In a case published in *Surgery, Gynecology and Obstetrics*, November 1960, the columella was closer to normal length so the patient was a more nearly ideal candidate for bilateral rotation-advancement. Since the separate primary stage of overlap of lateral vermilion flaps over the inferior prolabium vermilion was no longer considered necessary, at least in incomplete clefts, this aspect was incorporated in each rotation-advancement maneuver. The closing of one side at a time reduced the bilateral closure to two stages.

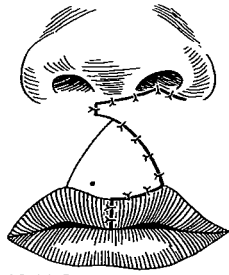


B.D. 7-1-57  
F.H. Cousin with cleft lip  
E.T. Uneventful  
O.C.A. None

10-3-57

At three months of age a right lateral vermilion flap was used to overlap the turndown flap of the right half of the prolabium vermilion. A triangular wedge was excised from the nasal floor

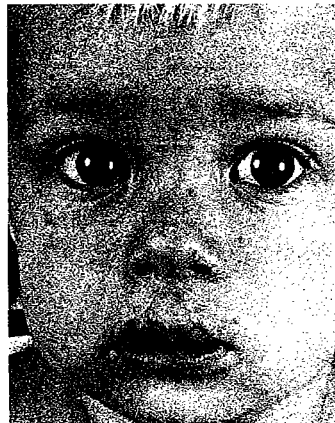and the lateral lip element advanced into the rotation gap between the prolabium and the columella base. The little patient then proceeded to strike his lip during a fall, separating the upper incision so the scar healed wider than normal.



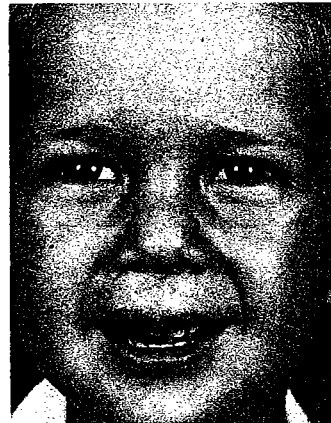
12-11-57

Two months later the left side was rotated and advanced in the same manner except that excision of the traumatic scar area made it necessary for the left advancement flap to cross the midline, introducing more tissue than was ideal above the prolabium. This discrepancy was reflected in the later development of this lip.

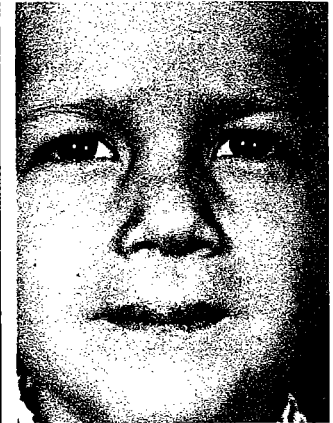S.P. 6-18-58  
Wardill V-Y  
pushback



14 months



3 years

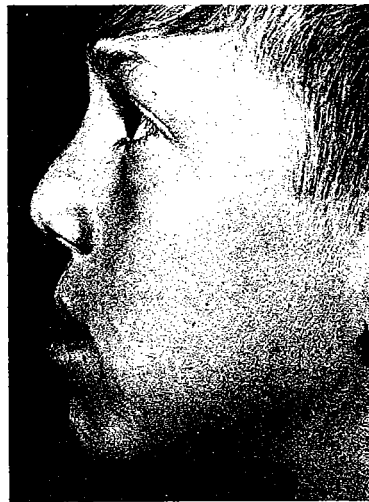

5 years

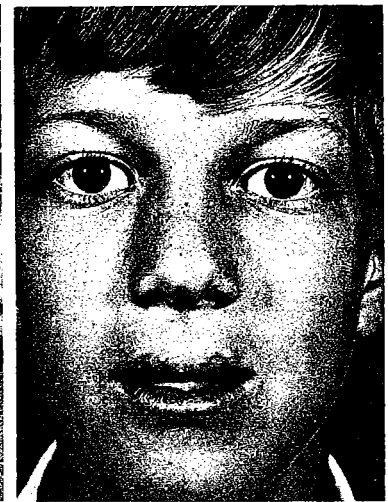Several minor revisions were subsequently carried out including deep tissue excision from the center of the prolabium and insertion of a dimple stitch which was more impressive early in the postoperative period than after a few years. As was predicted, the columella is almost long enough.



8 1/2 years



13 years



At the International Congress in London in 1959 I suggested that the rotation-advancement principle was applicable in bilateral clefts of the lip:

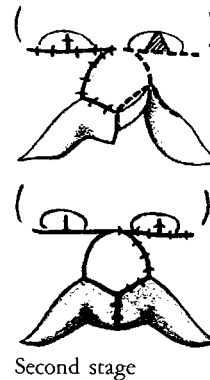
Yet placement of normal tissue in normal position does not pertain to the cupid's bow in as much as bilateral clefts have no residual bow. The normal element rather is the prolabium which belongs in the center of the lip as a philtrum and can be kept there by the same rotation type incisions. . . . The key factor in the approach to the bilateral cleft lip closure is the original length of the columella. In bilateral incomplete clefts, the columella is usually of adequate length while the prolabium is diminutive.

Thus:

Lateral triangular lip flaps can be advanced across the cleft, one side at a time, until they touch tip to tip above the prolabium and in fact completely separate the columella from the prolabium.

The turndown of each lateral lip vermilion to overlap one-half of the turndown flap of prolabium vermilion was suggested to *preserve but hide* the questionable prolabial vermilion and at the same time create some semblance of a cupid's bow.

This adaptation of the rotation-advancement principle offered certain advantages. The prolabium was maintained and shaped as a natural philtrum, advancement of the lateral elements reduced the alar flare and the scars of union were placed along philtrum column positions. However, complete division of the prolabium from the columella and introduction of lateral lip tissue between them added unwanted vertical length to the prolabium. Vigorous muscle tugging on the prolabial "bobbin," which had been cut free from its mooring, eventually was responsible for excessive vertical upper lip length. Even in incomplete bilateral cases the columella, although not so drastically short, invariably will be found to have some inherent shortness. The transverse division of prolabium from columella theoretically burned any bridges to a secondary forked flap. Actually it was found that a forked flap with the aid of a surgical delay can be taken across scar lines as well as along them. Here is a case to prove it.

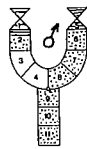

## FIRST CASE OF ASYMMETRICAL CLEFT CLOSED IN THREE STAGES

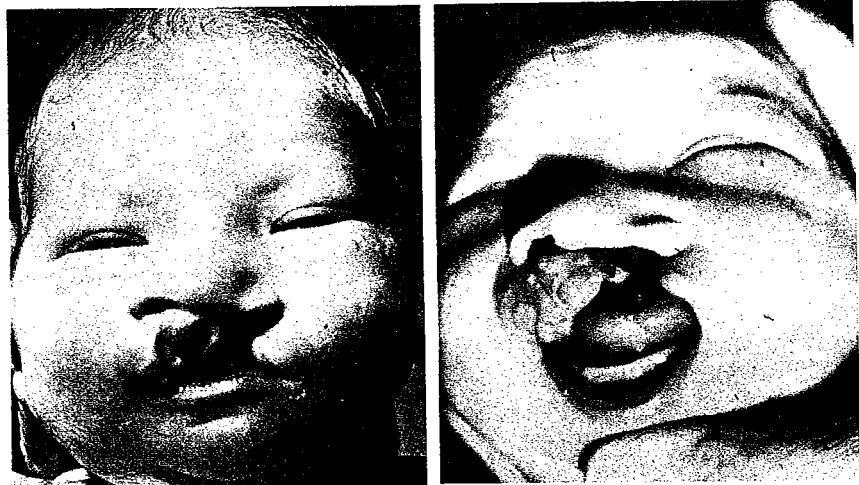An asymmetrical and difficult case came to me in 1958, and the early results were published in the *Transactions of the 2nd International Congress of Plastic Surgery*. Even though the columella was short on one side, the rotation-advancement design was planned. *Closure of the complete and worse cleft side first was logical.*

1. It maintains blood supply from the incomplete bridge.
2. Cleft closure gives molding to the wayward premaxilla on the complete cleft side.
3. When there is a deviation of the premaxilla, it usually leans away from the widest cleft, and by closure of this one first, the premaxilla is pulled toward the midline, correcting the deviation and bringing some symmetry to the maxillary arch components.

When the columella in the original deformity is short, it will eventually require lengthening. In this case a forked flap was fashioned finally.



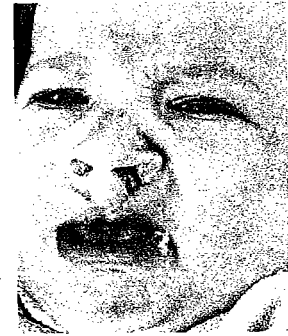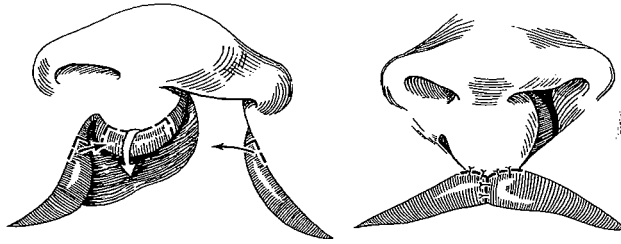
B.D. 7-13-58  
F.H. No clefts  
E.T. Nausea  
O.C.A. None



Here was an asymmetrical cleft with one side complete so the precaution was taken to attach lateral vermilion blood supply to the inferior prolabium. Later this safety measure was found unnecessary. At three months of age a first-stage procedure was done in which vermilion flaps from the cleft edge of the lateral lip elements were used to overlap the turndown of prolabium vermilion.

10-23-58

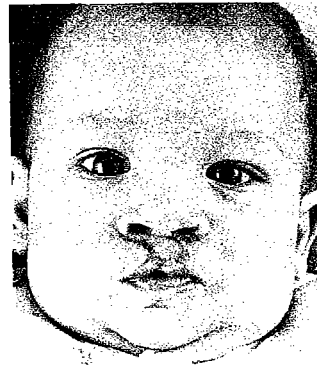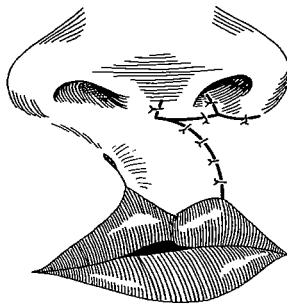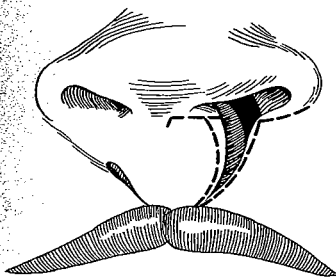
Lateral vermilion flaps overlapped  
prolabium vermillion.



12-2-58

Left R-A

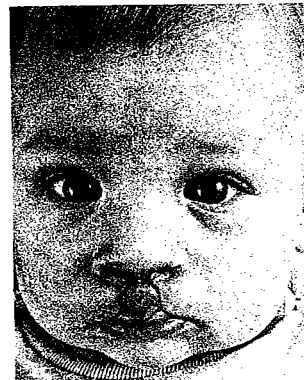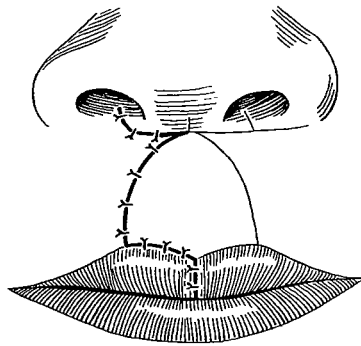
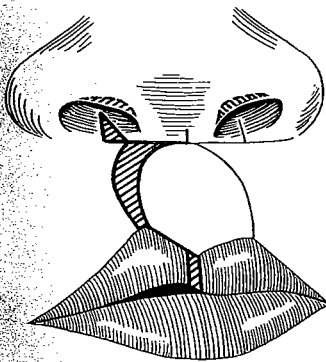
One and a half months later the more severe cleft was rotated  
and advanced and flap c was used in the nostril sill.



12-16-58

Right R-A

Two weeks later the right incomplete cleft side was rotated  
and advanced with a wedge resection of the nostril floor.



5-6-59

(age 10 months)

4-flap

Wardill

palate

closure

4-20-61

Forked flap

At two and one-half years of age a forked flap was used to  
lengthen the short columella.

One week later the little patient was thrown to the floor of the car while his parents were driving home to North Carolina and the forked flap was disrupted. The baby was brought back to Miami, and the flaps were resutured. Then in 1963 at St. Joseph's Hospital, Asheville, North Carolina, the forked flap was modified to improve the columella and shorten the lip. A photo was sent from North Carolina dated January 10, 1964, at age five years.

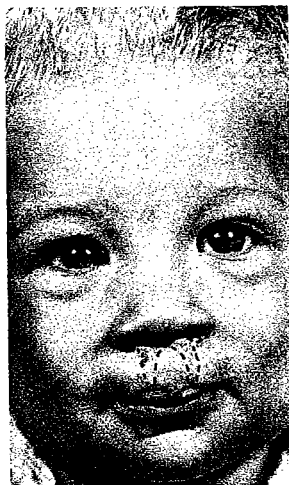*Comment.* Forked flap following bilateral rotation-advancement *proved* that forks could survive even after total division across their columella base!



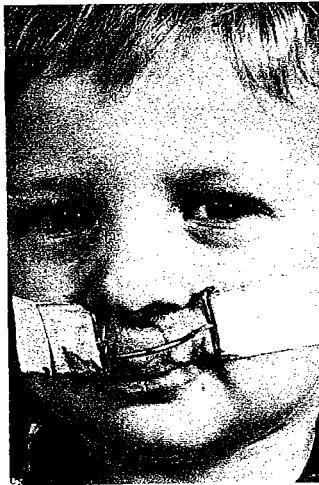17 years



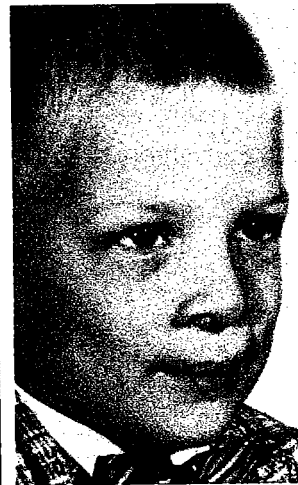18 years



5-16-60



4-26-61



5 years

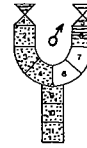
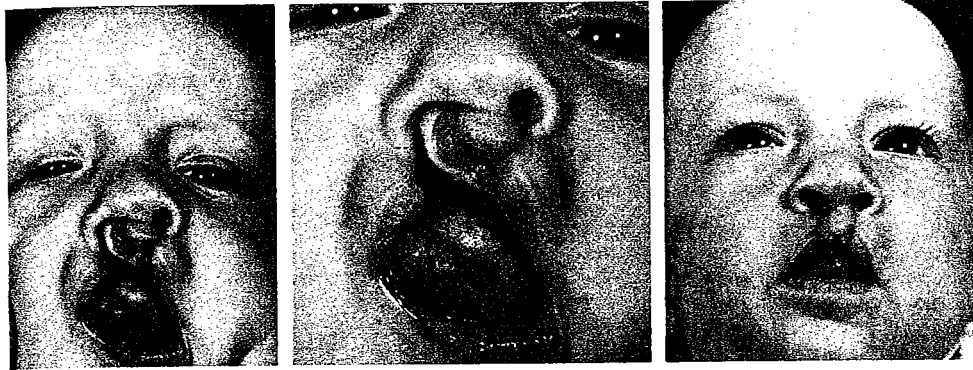
Then in 1975, another follow-up photo revealed the excellent development of this young man at 17 years. He was recalled in 1976 and had both secondary nasal and labial corrections. The skin scars were excised and lateral muscles joined across the midline under the prolabium. Corrective rhinoplasty included hump removal, septal shortening, alar cartilage reduction with lift on the cleft side, submucous resection, and septal cartilage strut grafts into the columella for tip and alar support.

#### ANOTHER ASYMMETRICAL CLEFT CLOSED IN TWO STAGES

A baby born in the Bahama Islands had bilateral clefts, incomplete left, complete right, shorter columella on the right with



moderate protrusion and outward rotation of the premaxilla also on the right.



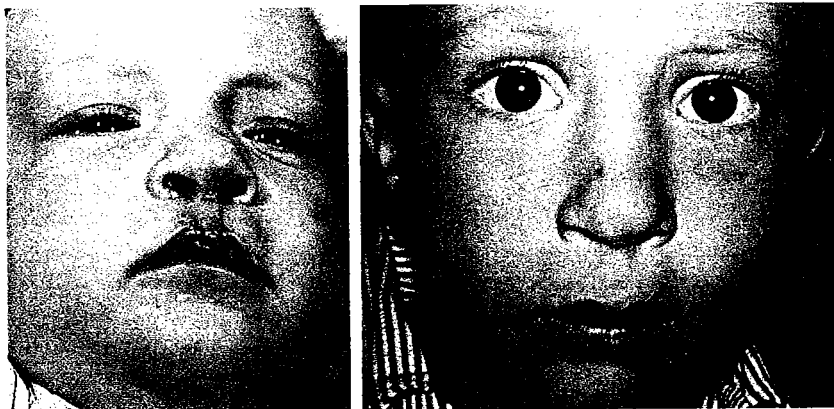B.D. 6-2-64  
 E.H. No clefts  
 E.T. Viral infection  
 O.C.A. None

At two and one-half months of age, the right complete cleft was rotated and advanced and the lateral vermilion flaps were used to overlap the right half of the inferior prolabium vermilion. Closing the complete cleft side first made it possible to preserve the bridge blood supply from the incomplete cleft, and once it was closed, there could be molding of the rotated premaxilla.

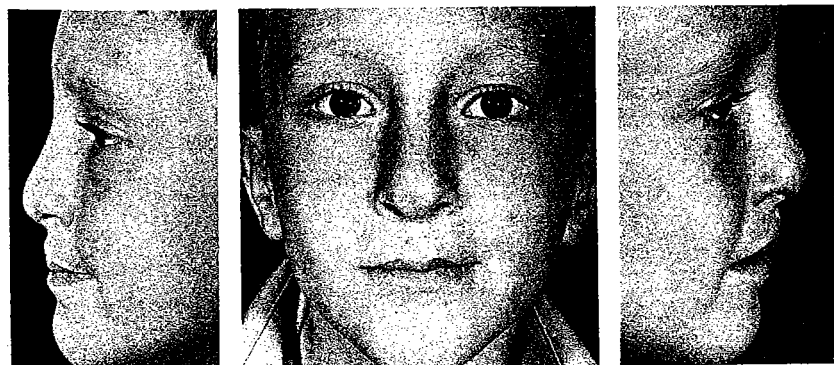
8-28-64  
 Right R-A

One and a half months later the left incomplete side was rotated and advanced and vermilion was overlapped to complete the closure.

10-2-64  
 Left R-A



H.P., S.P. at 1 year  
 Pushback with island flap.

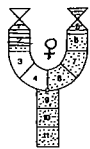

*Comment.* Short fork will be necessary eventually.

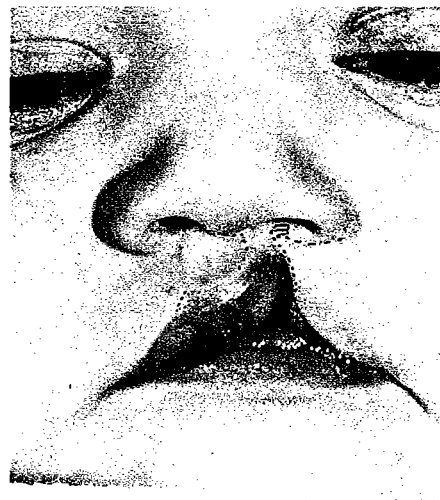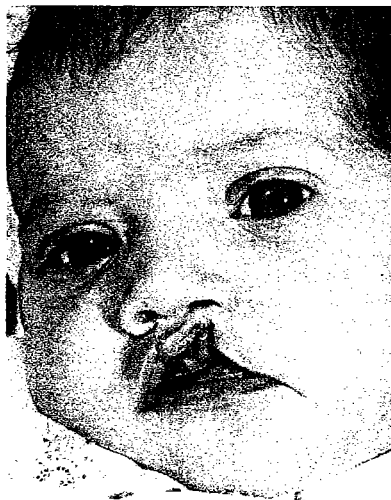7 years

This example reveals the method's ability to fashion the probium to philtrum shape but also proves that any shortness in the columella persists and eventually will require surgical correction.

AND ANOTHER



B.D. 9-23-68  
 F.H. No clefts  
 F.T. Uneventful  
 O.C.A. None

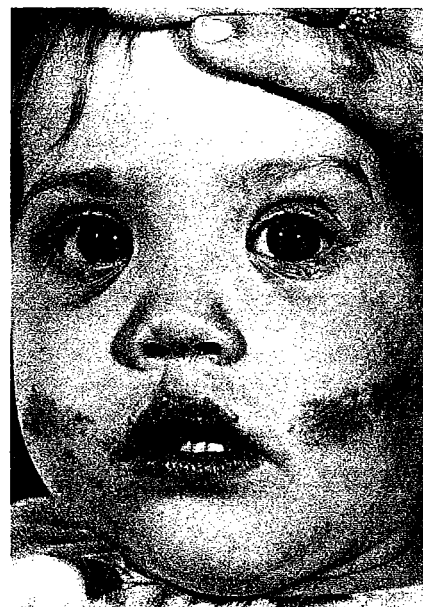
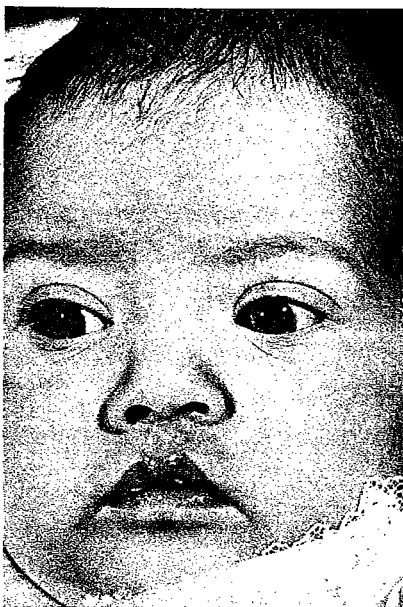
11-7-68  
 Bilateral lip closure

Rotation-advancement closure of the incomplete cleft was done on the left, and minor revision of the vermilion notch and mucocutaneous discrepancy was made on the right.


2-12-70

Lip revision and closure of the palate cleft were carried out with pushback and island flap.



Last seen by Frederick Remark, at four and a half years of age this little girl required vermilion revision and hearing evaluation.

In 1974 Miroslav Fara of Charles University, Prague, visited Miami. During our many enlightening discussions he mentioned that he had used the rotation-advancement principle in bilateral clefts but had interdigitated the tips of the advancement flaps one on top of the other across the midline in an attempt to get some muscle across the cleft. As would be expected, he soon found the vertical length of his lips after this was far too long!

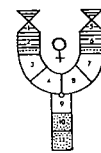
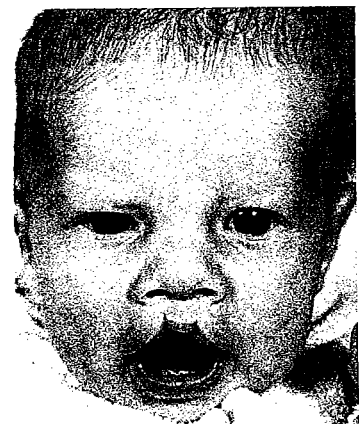

## A CONCLUSION

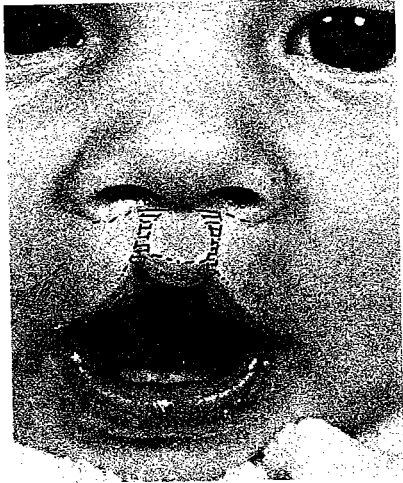As experience increased, it was realized that at least a narrow bridge of original connection between prolabium and columella base should be maintained at least during the early years and the lateral flaps not advanced quite tip to tip. In other words, most prolabiums are long enough or will be, even though they may appear short at first. If at five years the columella must be lengthened, then it is probably safe to go ahead with the forked flap.

## BILATERAL R-A REDUCED TO ONE STAGE

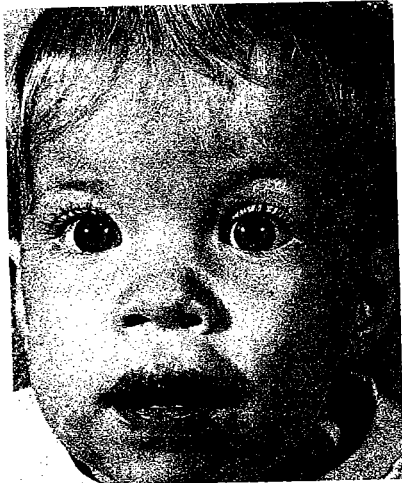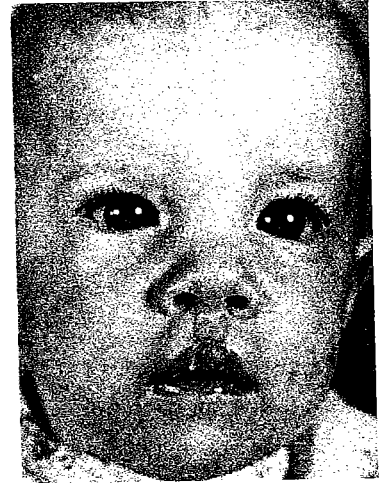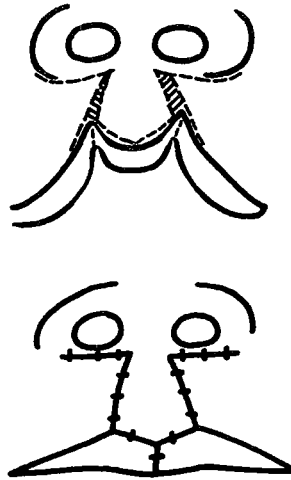
A symmetrical bilateral incomplete cleft with columella of only slight shortness presents the best type of case for rotation-advancement. At this time the lateral lip mucosa and muscles were not being joined routinely behind the freed prolabium. Thus it was possible to complete the bilateral rotation-advancement by *not dividing completely through the prolabium join with the columella base*, and one of the important improvements in this approach was realized. Maintaining some original attachment between columella and prolabium prevented the unnatural early vertical stretching of this upper lip. As would be expected, this lip has developed well during the years of growth.



B.D. 1-26-68  
 F.H. No clefts  
 F.T. Infection  
 O.C.A. None



6-20-68  
at 5 months  
Bilateral R-A

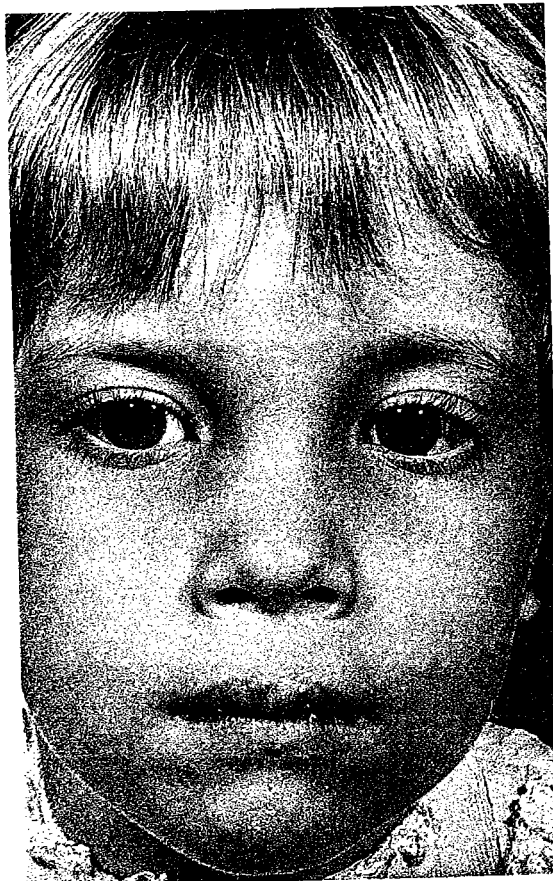


14 months

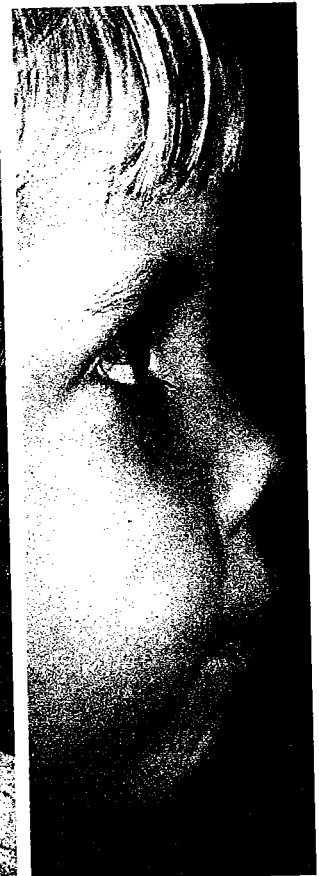Because of the incompleteness of the cleft there was little lateral vermilion available for overlapping the prolabium. Thus, the lateral vermilion flaps were extended up posteriorly and vertically along the lateral side of the cleft to pick up extra length and, as seen, adequate vermilion was obtained.

*Revision.* 2-21-69  
at 8 months  
Minor vermilion  
trim

S.P. 6-4-70  
Pushback with  
island flap



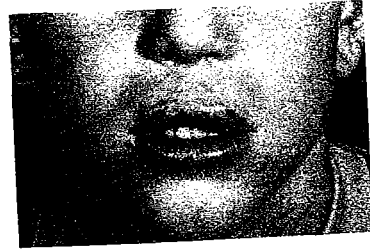3 years



3 years

## BEWARE THE HYBRID

Here is an example of an incomplete bilateral cleft lip treated by what might be loosely called a rotation-advancement approach. The shortcomings of this result are not the fault of the method but are due to the failure of correct execution. The lateral advancement flaps join above the prolabium over too great a distance, giving a stuck-on appearance and preventing the prolabium from imitating a philtrum. The prolabium vermilion has been retained in visible position, resulting in an uncraftsmanlike free border with a whistling deformity. Revision is difficult.



## A SELECTIVE GAIN

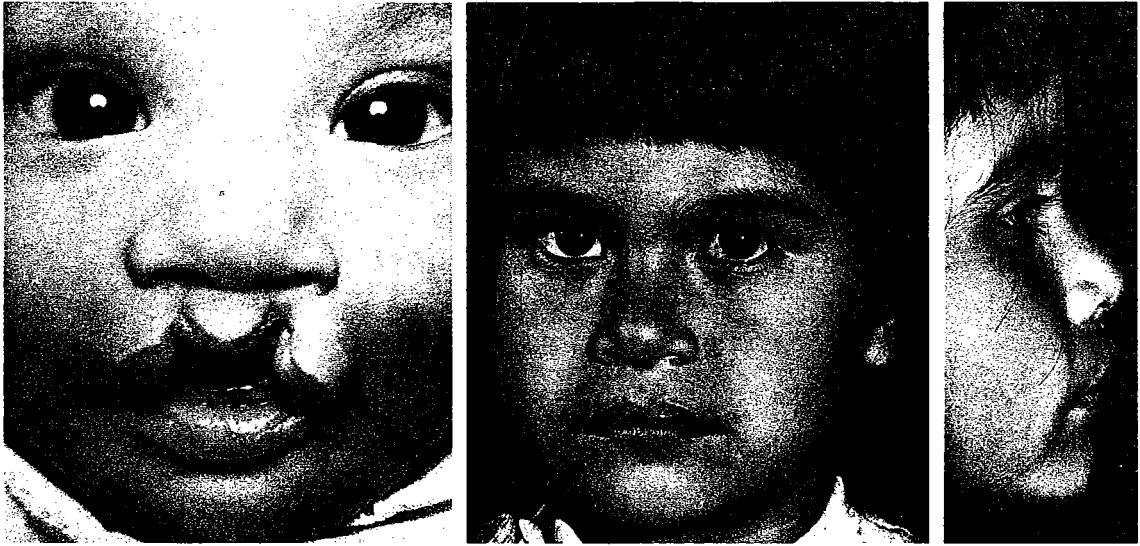Meanwhile, the pure rotation-advancement method, having caught on in unilateral clefts and having been proposed for certain bilateral cases, was gradually gaining selective popularity even in the camps of the opposition.

In 1971 from Houston, Texas, Thomas Cronin with James Penoff agreed with limited use of the rotation-advancement and reported having done 7 out of 71 bilateral clefts. They wrote an honest appraisal:

The Millard rotation-advancement was used exclusively for the incomplete cleft with very small prolabium. The prolabium was rotated downward in two stages to fit the lateral segments and the prolabial vermilion was augmented with a vermilion muscle flap from the lateral lip segment. . . . Six to eight weeks should elapse between stages to allow for recovery. . . . Care should be taken to avoid advancement flaps as this tends to result in a long lip vertically.

In 1974 Cronin forwarded to me this lovely example of his bilateral incomplete cleft, which, as he said, has been corrected by a rotation-advancement (Millard) repair.

The case was presented in Boston during the 1970 Kazanjian honorary lecture and in 1971 was published in the *Cleft Palate Journal*.



Ray Broadbent and Robert Woolf of Salt Lake City gave their evaluation in 1972:

A bilateral repair with Millard's design, done simultaneously, seemed far too precarious for the central prolabium. There were, however, theoretical and actual advantages to this type of repair—but for safety, we staged it one side at a time. A better scar pattern on the lip resulted, and these scars could be placed out of the mid-nasal floors. This positional change, with a flap threaded across each nasal floor, went a long way toward avoiding the grooved nostrils and their persistent “dirty nose” appearance. The flat nose was somewhat improved, but still flat. However, these changes constituted improvement—but the prolabium remained attached to the premaxilla, and it was associated with an inadequate labial sulcus and a deficient central tubercle.

They did end with:

A Millard design could be used when the operator thinks the lip should be closed one side at a time.

Of course, the rotation-advancement method was not designed originally as a one-stage procedure anyway. The present redesign makes this possible and at the same time corrects all of Broadbent's objections except the flat nose. The pure rotation-advancement method has never been and still is not advocated for patients with a *short columella*. Yet in too many instances the principle *was being used without selection* even when the columella was very short. As noted, I had been through this phase and

discontinued indiscriminate use of pure rotation-advancement about 1965. Yet the trend continued, and evidence of it has come to my attention from time to time. As Bruce Williams wrote in 1973:

If the cleft is not wide or is incomplete, a bilateral rotation advancement is done at the first operation.

Having thus painted himself into a corner, the surgeon is forced into one of three undesirable choices: be content with a columella short of normal, return to the lip for adequate tissue or advance the nasal floors and alar bases for a slight gain. Consequently *too many nasal tips were remaining depressed.*

A 1968 paper by Tabuya Onizuka, then of the Department of Plastic Surgery, Central Hospital of the National Railway Company, Japan, is of interest. Onizuka stated that in addition to the merits he had previously noted with Millard's method for unilateral clefts there were the following advantages in bilateral clefts, which evidently tempted him to use it even in the presence of a short columella:

1. Upper lip is pouting.
2. The "form" of the upper lip is near normal.
3. Cupid's bow is easily reconstituted.

He compared the results with other methods, presenting actual cases to prove his deductions.

1. *Straight-line closure* produces results in which the upper lip is tight, the lower lip protrudes and the V-shaped scar is opposite to that of the normal philtrum.

2. *Triangular method* may be able to get pout, but there is a tendency for concavity in the mid-portion of the upper lip, there is bulging under the columella and the scars are ugly and complicated.

3. *Millard method* gives beautiful pout, and scars run along the philtrum.

As was predicted, and as would be expected, Onizuka noted certain difficulties he encountered, most prominent of which were in the nasal area.

1. It is difficult to get a beautiful nose without a second operation.
2. Doing two operations on the nostril floor tends to cause hypertrophic scars in this region.
3. In young children the base of the columella slides down with growth.
4. The upper lip has a tendency to appear relatively long as a result of narrowing the alar portion of the nose.

### TIMING

Onizuka's plan of surgery closes the bilateral cleft in two stages at three and six months because the premaxilla blood supply is safer, complications are less and, after first-stage improvement, the form of the side operated on can be observed.

Onizuka finds the columella too short after this first-stage procedure. He sometimes uses what he calls

Millard's intermediate skin flap (flap c or one fork) which is transferred to the columella base by the transposition of Skoog. Unfortunately, all incisions gather in the nostril floor making suture difficult and sometimes resulting in delayed healing and hypertrophic scarring.

It is possible that this modification of columella lengthening may be sufficient for the Oriental nose.

### HIRSHOWITZ



*Bernard Hirshowitz*

Gentlemanly Bernard Hirshowitz of Abba Khoushi School of Medicine, Haifa, was trained by Jack Penn in Johannesburg and in 1951 joined a team led by Penn to provide plastic surgical treatment in the newly established state of Israel. In 1952 Hirshowitz set up a plastic surgery service at Rambam Government Hospital, Haifa, which treated the wounded soldiers during three Arab-Israeli wars. In between hostilities he established the S.E.D. cleft palate center at this hospital. Pleased with the adaptation of the rotation-advancement principle in bilateral clefts, he developed his rendition in two stages. In the 1973 Copenhagen Congress abstracts he described two modifications that employ



the cleft edge mucosa. The vermilion of the lateral edge of the prolabium is cut as a flap based on the premaxilla, which is folded medially under the elevated prolabium over the raw front surface of the premaxilla to form half a sulcus. He claimed:

The under surface of the prolabium is initially unlined but re-epithelialization rapidly restores its mucous membrane surface. Almost no ensuing untoward effects by scarring follow this method.

The vermilion of the cleft edge of the lateral lip element is cut as an inverted V flap which is inserted into the deficient inferior prolabium vermilion leaving the intact vermilion skin border of the prolabium undisturbed. Hirshowitz summarized:

The curved medial skin incisions correspond to the philtrum lines, the rolled vermilion border is intact, the vermilion itself is full, and the nostril bases are rotated inwards. A short upper lip is ensured by not joining the two rotation-advancement incisions across the midline at the columella base.

Yet he must return into the lip later for, as he wrote,

Ample tissue enables columella advancement to be subsequently performed.

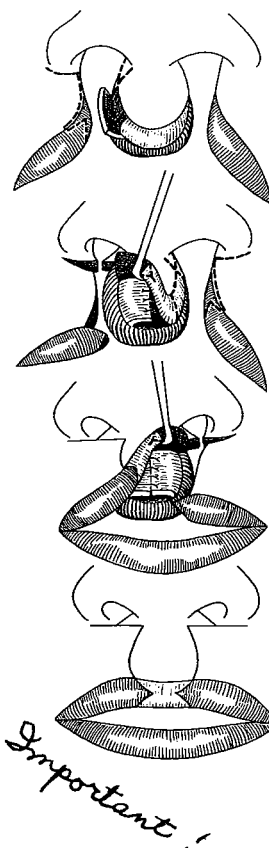
#### MERVILLE

Maxillofacial surgeon L. C. Merville of Foch Hospital, Paris, comprehends the importance of the columella in planning rotation-advancement. He wrote in 1971:

Millard technique—the operation is done differently according to the degree of the cleft: incomplete or complete, according to the degree of hypoplasia of the columella.

#### A DEY IN SYDNEY

Another surgeon who understands this columella aspect is David Dey of the Royal North Shore Hospital, Sydney. He trained primarily as a pediatric surgeon at Great Ormond Street, London, but exposure to Mowlem, Matthews and even Denis Browne caused him to become infatuated with plastic surgery. One cleft is born a day in Australia, and Dey gets one-quarter of the total. Evidently a percentage of his 90 clefts a year have a prolabium



David Dey

with vertical shortness which is slightly more than one-third of the height of the lateral elements. Thus in a paper for the *Australian-New Zealand Journal of Surgery* in 1973, entitled "An Important Contribution of the Millard Flap to Cleft Lip Surgery," he argued:

It has been stated on numerous occasions that the central "prolabia" element grows in a remarkable fashion following closure of lip clefts, particularly if it is freed posteriorly from the "premaxilla" and a gingivolabial sulcus established. . . . However, I have yet to see this expectation realized to an acceptable degree in these incomplete clefts following a simple-type closure, and the children all tend to be left with an upper lip in which the lateral elements sweep upwards and inwards in an unnatural fashion.

In 1968 Dey turned to the rotation-advancement principle to lengthen the short prolabium and, being a perfectionist, ran the gamut that I stumbled through, including the primary forked flap (without the forks) isolating the prolabium solely on the premaxillary blood supply. He suffered as, he said:

The isolated segment of prolabial tissue was alarmingly blue for two or three days, but eventually recovered completely without tissue loss and the final outcome proved satisfactory.

This scare caused Dey to turn to two stages, which in turn enabled him to slide lateral vermilion behind the prolabium for half a sulcus at each stage. He explained the details of his technique:


The medial curved Millard incision is then inked in, conserving skin by a wide sweep and reaching the midpoint of the columella where the latter joins the lip. It does not transgress the midline at this point, and is carried downwards directly for a short distance to allow the lip to lengthen to the proper degree. . . . A wedge of skin is removed from the nasal floor. . . . The red edge of the prolabium is retained and turned forward, reinforced by the red skin from the lateral lip.

*the back-cut  
ugh!*

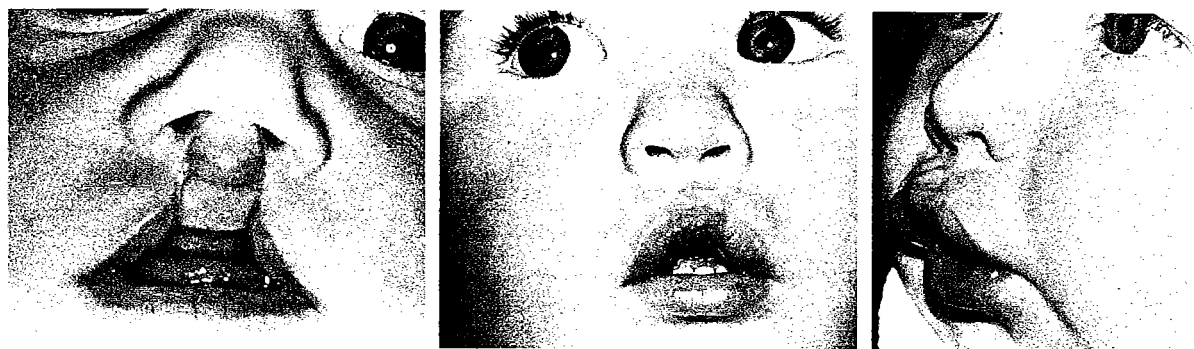
In November 1973, when forwarding requested bilateral incomplete cleft cases to me, Dey added:

This procedure does seem to deal adequately with the uncommon bilateral incomplete cleft with a short prolabium. I personally find a lip with the two

lateral lip lines running upwards very ugly—and this was all too common before I read your article!



His results appear quite good, and except for his keeping prolabium vermilion visible the method checks out. This retention of the Manchester vermilion roll-out principle can perhaps be attributed to a loyalty to his friend and neighbor “down under.”



In 1974 Raymond Brauer admitted almost painfully:

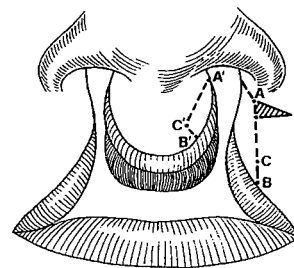
To fit the longer vertical length of the lateral segments into the short prolabium, it is sometimes necessary to use the downwards rotational principle as recommended by Millard.

Over the years I have become less concerned with the need to lengthen a short prolabium. Most prolabiums are of sufficient length particularly when it is realized that the normal lip at rest should expose the lower one-fourth of the upper incisors. Often it is better to shorten the lateral segments and there are ways of using this extra tissue that will be described later.

In 1964 Cronin acknowledged his preference:

If the lateral lip segment is too long, a wedge consisting of the full thickness of the lip is removed.

Then too, early division of the prolabium from the nose tends to produce a lip that is abnormally long in the vertical axis, and this



can be worrying. There is, however, a rare prolabium that deserves help. This fact is emphasized by two cases at the end of Chapter 26 where a short prolabium was rendered normal vertical length merely by introducing lateral mucosa and muscles behind it and lateral vermilion-mucocutaneous ridge flaps over its inferior vermilion.

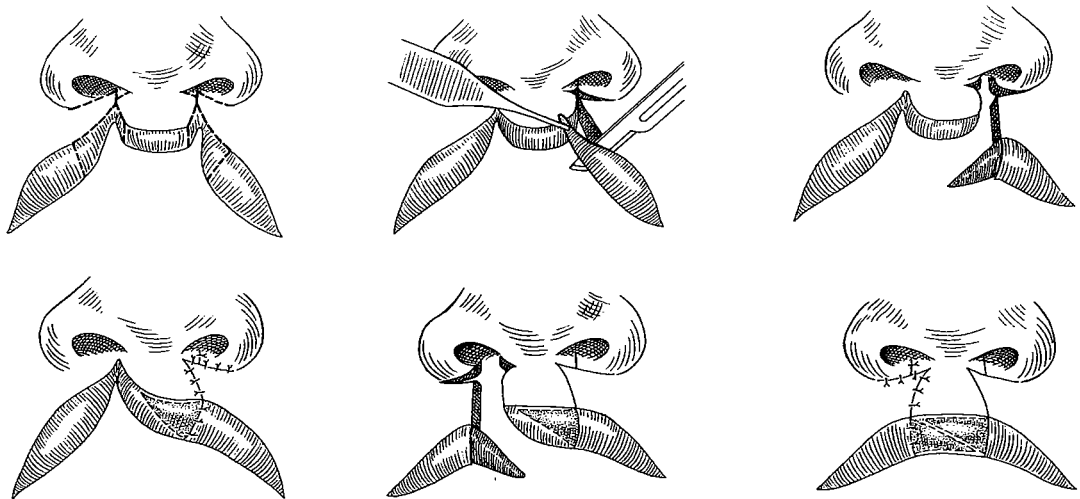
#### A MEXICAN MODIFICATION

A variation in the design has been developed by José Guerrero-Santos, who wrote from Guadalajara in 1973:

The Tennison procedure was abandoned by us several years ago, and as a rule in most of the cases, both my associates and my residents as well as myself are using the rotation-advancement technique.

When the lip is very wide, close one side; usually, if it is asymmetrical, the less-wide cleft, trying to change the lip into a unilateral cleft; and for the second stage we close it with the rotation-advancement method, combining it with the denuded and buried flaps.

I elongate the columella after the first year, and I do the incomplete clefts like the complete ones, using rotation-advancement combined with a denuded flap.



#### MODIFYING THE ADVANCEMENT

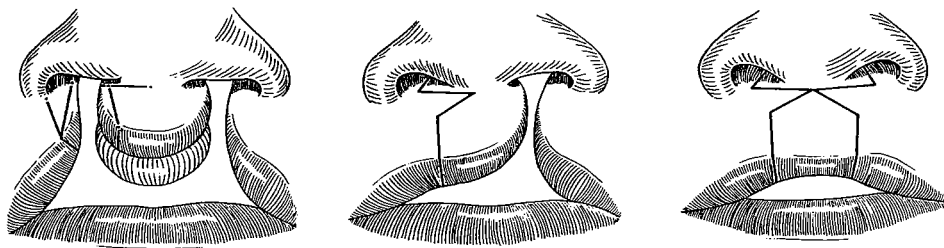
In 1958 in the *American Journal of Surgery* while discussing primary rotation-advancement in bilateral clefts I noted a possible modification in the advancement flap for severe clefts.

In extremely wide bilateral clefts the [lateral] triangular flaps are sometimes better transposed from a vertical position along the cleft to a horizontal position between columella and prolabium.

Actually this variation was never used because as experience progressed the smooth flow of pure rotation and advancement offered more natural action and scars than an abrupt transposition.

#### W Y N N

In 1960 Sidney Wynn of Milwaukee presented his vertical flap taken from the lateral lip element and transposed across the cleft high in the medial lip near the columella base. He also adapted this principle to bilateral clefts, accomplishing primary closure in two stages.

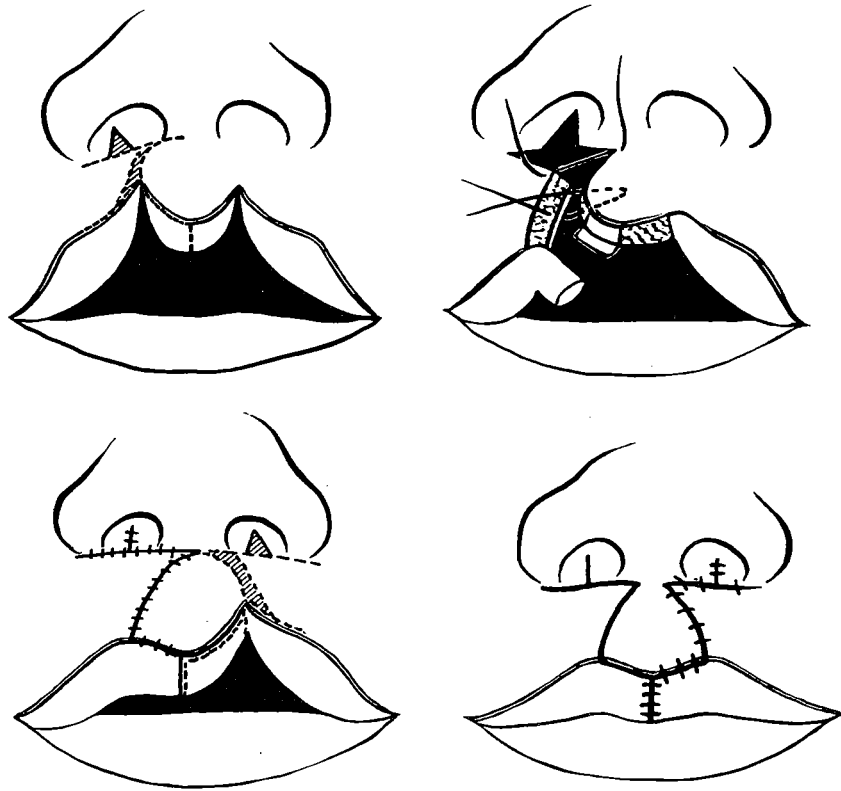


Of course, there are the advantages of high medial release and lateral advancement, but the kink of a 90-degree transposition not only leaves a pig's-ear in its wake but results in a square philtrum and fails to achieve the natural curved effect of the true rotation-advancement action and scar placement. Like the rotation-advancement, transposition, by introducing tissue well below the columella, tends to lengthen the prolabium rather than the columella.

#### THE STANDARD TWO-STAGE

In 1968, for Grabb and Smith, I described what in my opinion is the best two-stage method of closing an incomplete bilateral cleft, but *only* if the *columella* is definitely of *normal length*. Two important changes in the original design were added: (1) Muscle and mucosa were introduced behind the prolabium a la Meyer-

Schultz, but in stages, in the manner of Bauer, Trusler and Tondra. (2) Prolabium-to-columella continuity was not divided completely, for the lateral flaps do not meet each other across the lip, maintaining the original vertical length in the midline.



#### ONE STAGE IS PREFERABLE

If, during bilateral cleft lip closure, tension can be controlled and adequate blood supply preserved, one stage is better than two because of the merits—economy of time, facilitation of surgery and maintenance of symmetry. Much effort is warranted to develop a one-stage procedure, but it must be fundamentally sound.

A one-stage rotation-advancement for a bilateral incomplete cleft was presented in my Chapter 20 in *Cleft Lip and Palate*, edited by Grabb, Rosenstein and Bzoch. Here a procedure was diagramed which in general has possibilities, but the specific rendition suffered a touch of surrealism. The skilled artist Fred Harwin was given the unenviable task of improving drawings submitted to him. My failure to police this work resulted in

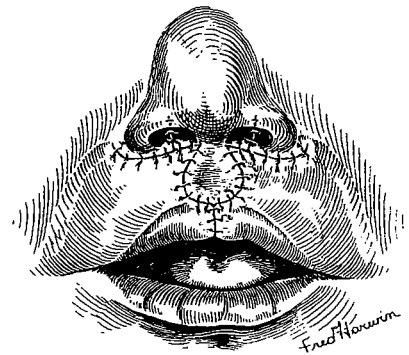
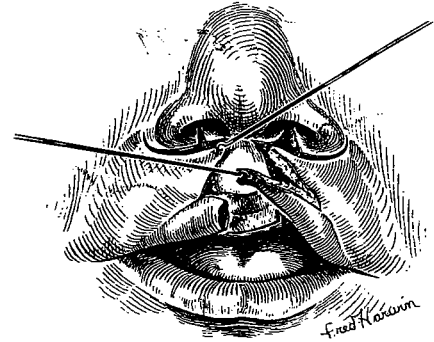
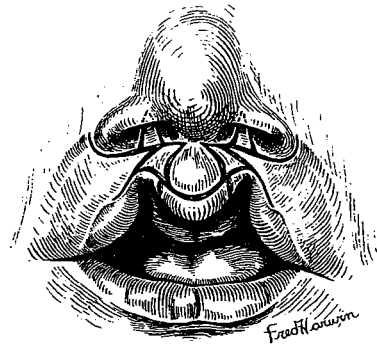


sketches that revealed artistic excellence but plastic fantasy. It was my responsibility to spot faults prior to publication but only when writing the present chapter did I actually focus on these discrepancies, and I now hasten to warn the inexperienced.

The first mistake, which is also made by many surgeons, was to use a rotation-advancement approach when the columella is *short*. The second was to treat the lateral prolabium as excess *to be discarded* when the columella is so short. This is throwing away a "forked flap," but then surgeons are guilty of the same mistake. The third had to do with vascularity. In a procedure that introduces lateral lip muscle and mucosa behind the prolabium across the premaxillary vascularity, it is hazardous to advance the lateral skin flaps almost across the remaining prolabium blood supply at the base of the columella. To have these flaps come within 2 to 3 mm. of tip to tip in one stage produces a vascular "cliff-hanger." Harwin did recover by drawing the stitched stage with an adequate base at the columella. Finally, his last stitched sketch places the circumalar scars too far down in the lip and portrays a convex prolabium turned into a philtrum dimple *without* the stitch to do it.

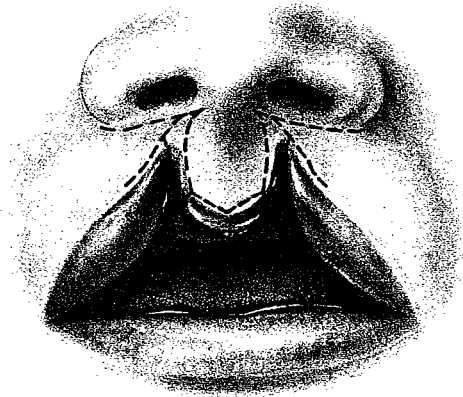The general rotation-advancement principle is applicable in all bilateral clefts but its application *in pure form* should be limited to incomplete clefts with *adequate columella*. This is an exceedingly rare occurrence. Certain bilateral incomplete clefts, however, do have a columella that is only slightly short. These can be closed by the pure rotation-advancement with the bilateral refinements in one stage and subsequently have the columella elongated slightly by the Carter-Cronin principle if necessary.

Here is the modern design for this special group of cases after an evolution influenced by my experience and the experience and suggestions of others.

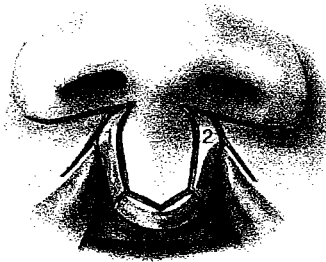


# Bilateral One-Stage Rotation-Advancement

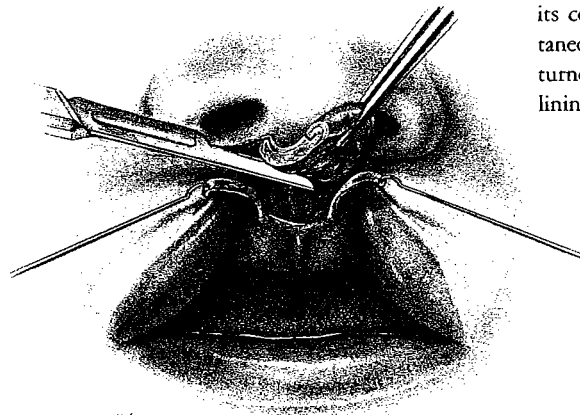
Columella near normal.



Bilateral upper rotation-advancement incisions do not meet across the midline.




Lateral paring flaps (1 and 2) of the prolabium used to cover raw anterior premaxilla.




Cupid's bow incision on inferior prolabium placed above its convex vague mucocutaneous junction and turned down with vermilion lining flap.

Prolabium freed from premaxilla.



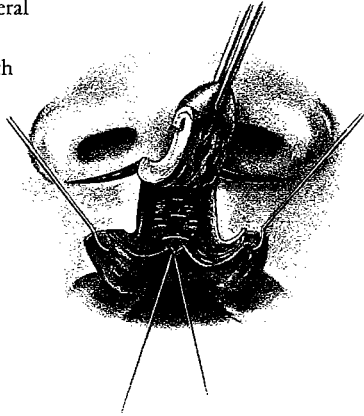
Lateral fullbodied vermilion paring flaps retain mucocutaneous junction ridge to accentuate the new cupid's bow.



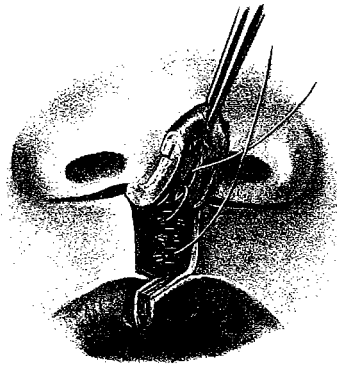


# Mucosa and Muscle Joined Behind the Prolabium

Mucosa of lateral lip elements sutured to each other in the midline.



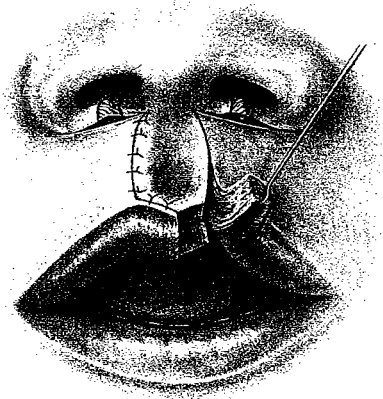
Then muscles sutured together firmly!



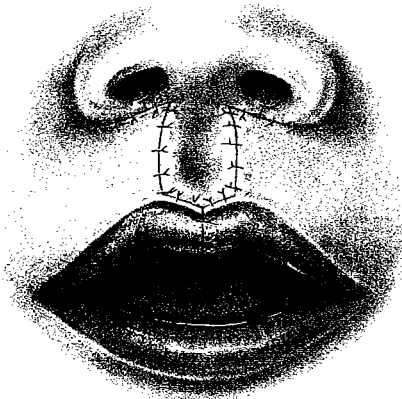
Midvertical incision in prolabium to dermis made from behind.

Dimple stitch placed.

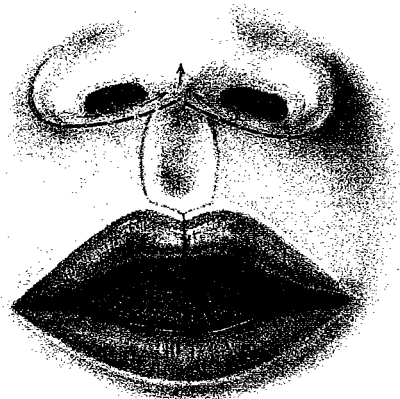
If columella of normal length resect wedges from wide nostril floors.



Lateral vermilion paring flaps carrying "white roll" used to overlap turndown of inferior prolabium vermilion.



or



Then suture closure after tying dimple stitch.

If columella slightly short keep wide floors for later advancement.