

11. *Joining Portions of the Lateral Elements Behind the Prolabium*

THE RE has been a school of sporadic surgeons who, although they agreed that the prolabium should form the entire vertical skin length of the central portion of the upper lip, called upon some portion of the lateral lip elements to back the prolabium. A German named H. Meyer was first. In 1929 he freed the prolabium from the premaxilla, turned vermilion flaps back from the cleft edges of the lateral lip elements and advanced and sutured them together posterior to the prolabium.

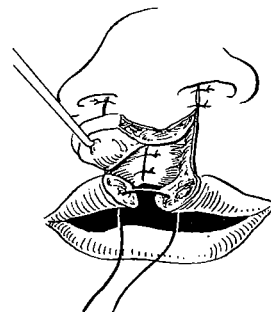
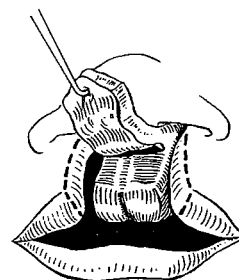
JOINING THE MUSCLES

Louis W. Schultz, Professor of Plastic Surgery, Children's Memorial Hospital, Chicago, was a pioneer in bilateral cleft lips. Although the general plan had been described almost 20 years before by Meyer, Schultz added the retention sutures to approximate the muscle across the cleft. As he stated in 1946:

Not being satisfied with the results obtained in most bilateral cleft lip operations performed by various operators including myself, the author searched diligently for a method which would produce a more nearly perfect effect.

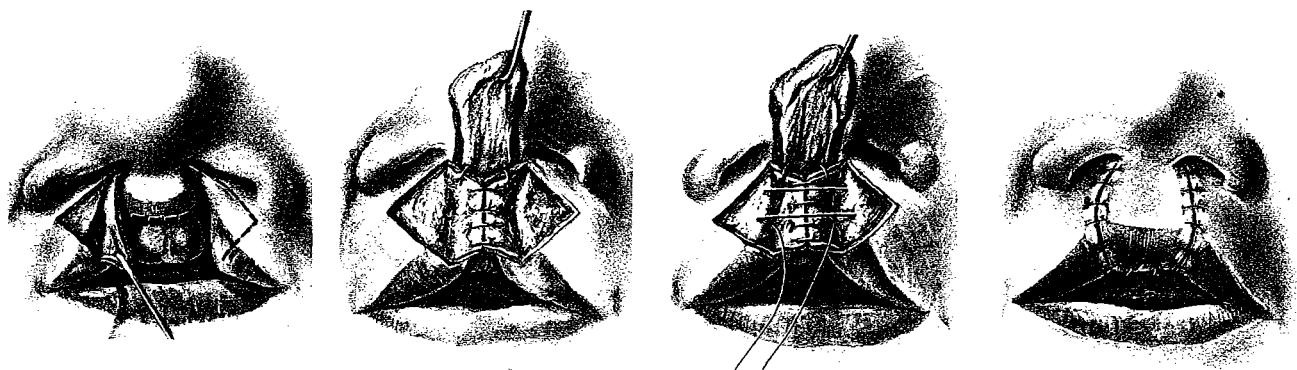
As he explained, an important prerequisite to success is the understanding that

all the normal parts are there. All you have to do is unite them.



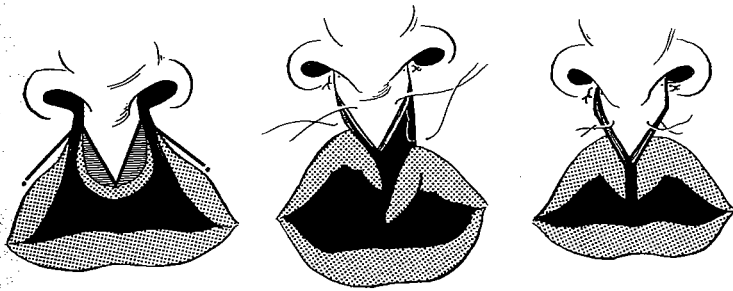
Louis Schultz

In a patient one month old, Schultz retroplaced the premaxilla by V section of the septum and, after denuding the opposing cleft edges of the maxillary and premaxillary segments, approximated them with 4-0 nylon sutures to get what he referred to as "bony union." One month later he achieved a one-stage closure of the lip by elevating the prolabium from the premaxilla and turning flaps of skin and mucosa from the lateral lip elements to be sutured together behind the prolabium in the midline. He placed retention-type sutures across from muscle to muscle and then set the prolabium into the defect so that it formed the skin and vermilion of the central external portion of the upper lip.



This approach emphasized an important principle and subsequently was responsible for influencing the surgical treatment of bilateral clefts. In the cases presented by Schultz, however, there were two glaring discrepancies: the unnatural look of the prolabium vermilion and the persistent shortness of the columella.

The Australian pediatric surgeon Denis Browne of the Hospital for Sick Children, Great Ormond Street, London, in 1949 redescribed his method of bilateral cleft lip closure. This eccentric surgeon chose a 2 mm. ophthalmic trephine and a half-inch chisel to punch and carve the infant's lip against a slip of soft wood more the way a leather cutter would than a plastic surgeon. His design discarded much tissue but shaped the prolabium to a point and used it to construct the entire central vertical skin segment of the lip, adding only the lateral mucosal flaps to the inferior border of the prolabium.

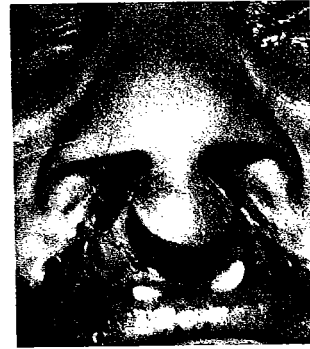


To this orthopedic-oriented surgeon the most important part of the operation was the muscle closure, which he described:

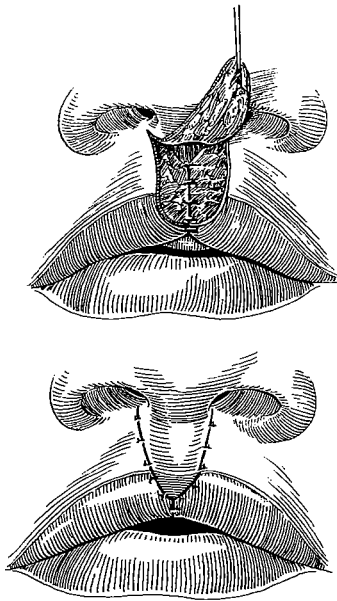
The joining of the muscles is done by deep vertical mattress sutures of 000 chromic catgut, inserted so as to bring together the whole thickness of the lateral portions with the exception of the already sutured skin. The first of these is put in opposite the trephine holes, and two others usually are enough to join the entire undersurface of the lip. The effect of these sutures is triple: to join the muscles, to join the mucosa, and to make the lip pout. There is no need to dissect the muscles free and suture them as a separate layer. One knows exactly where they are, and the less they are injured the better.

Donald M. Glover, general, pediatric and plastic surgeon at Case Western Reserve University, Cleveland, gained his early interest and training in clefts under William Ladd at Boston Children's Hospital. With the same tenacity that won him the U.S. Army's Legion of Merit, Pacific Theater, in World War II, Glover has clung to the principle of joining the lateral lip musculature across the clefts in front of the floating premaxilla. In 1961, with M. R. Newcomb, he first published his stand. From his Adirondack hideaway island in Seventh Lake he wrote his unchanged 1974 views on bilateral lip clefts:

Close the lip in front of the premaxilla. This is almost always possible in one stage; only about one in ten requires secondary closure. The functioning lip, with orbicularis united behind the prolabium and in front of the premaxilla, provides the best restraint upon the premaxilla. To force it backward or reposition it by sectioning the vomer affects the growth of the premaxilla by interfering with its blood supply. The lateral maxillary processes should be allowed to grow forward and meet the premaxilla. There may never be complete union and early appearance may not be ideal but later orthodontia will make up the deficit.



Donald Glover



The technique of the lip closure is not too critical, but the simple methods we have described removes the mucosa from the prolabium, preserving the vermilion border, and uniting the orbicularis and the mucosa from the two sides in front of the premaxilla. If the orbicularis repair does not hold (about one in ten) it should be re-united after several weeks. . . . These conclusions are based upon follow-up from five to fifty years.

This use of the entire prolabium in the central vertical length of the lip does not provide for the inevitable columella lengthening. Maintaining a triangle of prolabium vermilion with color and texture not identical to the lateral vermilion tends to set it apart rather than blend it into the lip red. In spite of these details it must be recognized that pioneers in uniting muscles across "no-muscle-land" were responsible for a major step in the progress of bilateral cleft surgery. Even today there are surgeons who do not appreciate or incorporate this fundamental principle.

For instance, Fara of Prague, who has made such a precise histological stand for getting the orbicularis oris muscle fibers in unilateral clefts lined up and joined end-on in a horizontal direction, strangely takes a rather loose position in bilateral clefts.

In 1967 he and Smahel reported sections taken from the prolabium and lateral lip segments through a posterior horizontal excision after surgery and summarized:

In the first weeks or months after the suture of the lip, there is marked regeneration and proliferation of the muscular fibers into the tissue of the original prolabium. Later on, the major part of these fibers is gradually replaced by connective tissue. But some muscular fibers always remain in the tissue of the central segment, which, together with the collagenous fibers newly formed chiefly along the longitudinal axis of the lip, make a suitable connecting link between the two ends of the musculus orbicularis oris.

Suitable?

Thus, they are saying that after simple, direct suture of the lateral lip segments to the central prolabium there is a heroic fight of the lateral muscular fibers, frustrated embryologically by the clefts, to accomplish a delayed invasion of the prolabium. Then after establishing a substantial "beachhead," the muscle fibers tire and retreat, leaving only a few stragglers to hold the line:

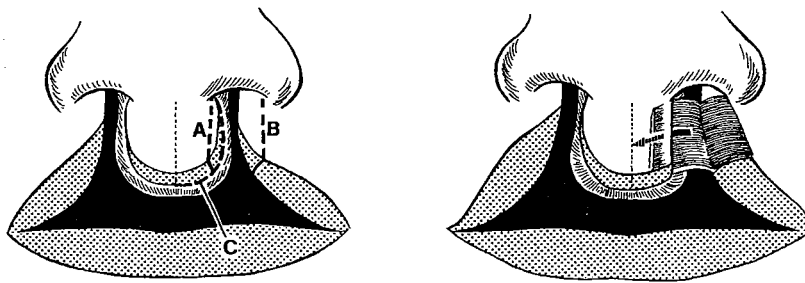
This reconstitution of the circle of the sphincter oris which is functionally suitable plays a valuable part in the linking of the prolabium to the reconstructed lip.

?!

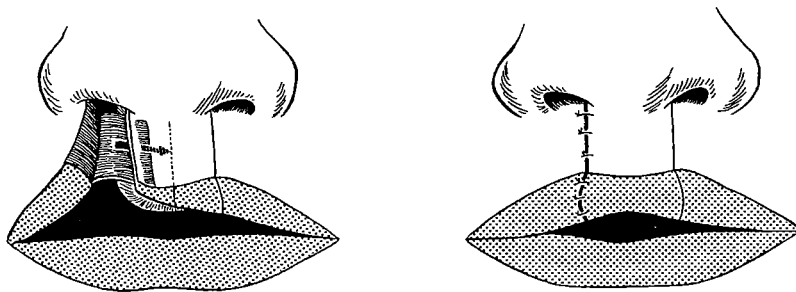
It seems ridiculous to me not to help the struggling lateral muscle fibers across the "no-muscle-land" of prolabium so that they join each other. It is easy, has been done by many surgeons and means advancing each side only a few millimeters farther.

MORE MUCOSA AND LESS MUSCLE

The Indianapolis team of Trusler, Bauer and Tondra has closed a lot of bilateral clefts. In 1955 they described a two-stage procedure in which one lateral cleft edge was turned as a flap of skin and mucosa to be introduced behind half of the prolabium after it had been freed from the premaxilla.



The opposite side was done in the second stage in similar fashion, creating a labial sulcus.



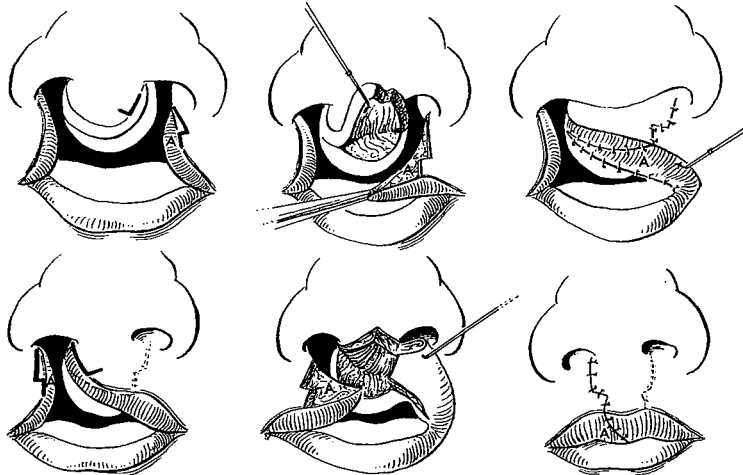
The bombastic Harold M. Trusler, senior surgeon and motor force of this Indiana unit for years, had been using Barrett Brown's premaxillary retroplacement followed by the Brown-McDowell bilateral triangular flap lip closure in one stage. He began to find the late results disappointing since in Indianapolis,



Harold Trusler

at least, the vertical length of the lip became too long and the horizontal length too short. Many lips had to be shortened at the time of columella lift and an Abbe flap inserted for relief in the side-to-side tightness. Insufficient thickness of vermilion in the center was producing what he referred to as the "whistle deformity."

True to his motto "Progress is our most important product," Trusler was willing to reevaluate bilateral cleft surgery. The first change that he, Bauer and Tondra made was in avoiding premaxillary retroplacement, which resulted in improved face development but because of extra tension ended up with wound disruption or, at best, poor scars. Finally, in 1959 Bauer, Trusler and Tondra adapted their 1955 bilateral design, which was a modification of a design they had described for unilateral clefts in 1953. The first side was closed at two weeks of age with a small triangular flap from the lateral side of the cleft fashioned to fit into a notch incised into the prolabium. Half of the prolabium was freed from the premaxilla, and the mucous membrane flap from the lateral side carrying a small amount of muscle fibers was brought beneath the prolabium.



Two months later, the second side was done, creating a moderate upper labial sulcus and part of a muscle sling.


In 1965 in Bratislava, Professor Stefan Demjen of Comenius University invited John Tondra to demonstrate the Indiana procedure for bilateral clefts. We witnessed his precise execution of a one-sided closure of a bilateral cleft demonstrating the introduction of the lateral flap behind half of the prolabium.

Along with Bauer and Trusler he published a favorable 10-year progress report of the method in *Acta Chirurgiae Plasticae* in 1966.

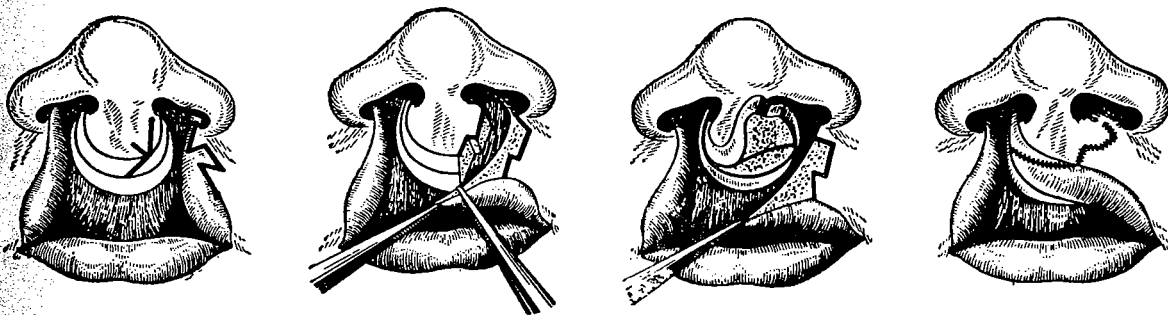
Finally, in 1971, in *Cleft Lip and Palate*, edited by Grabb, Rosenstein and Bzoch, the team of Bauer, Trusler and Tondra discussed their results as "encouraging," with more normal face growth, normal upper lip length with eversion, good balance, a good labial sulcus and no need "for an Abbe lip-switch procedure." They noted several problems including a common notching of the central vermilion requiring secondary muscle plication and the tendency to dryness of the prolabium vermilion. Then there was the lack of nasal tip development:

However, in most cases this development is not sufficient to obviate the necessity for some type of columellar-lengthening procedure.

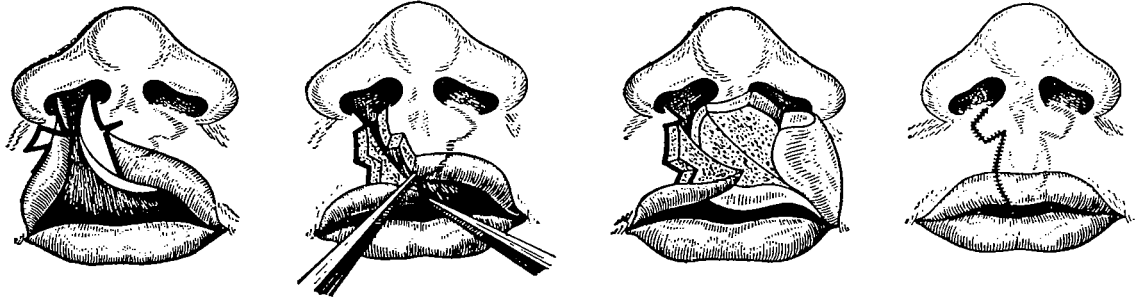
In the Division of Pediatric Stomatology of the Moscow Medical-Stomatological Institute, A. A. Kolesov has developed a method which combines several principles. In 1970 he described this two-stage closure with the skin incisions similar to those of Tennison, Limberg and Obukhova and the vestibular sulcus created in the manner of Bauer, Trusler and Tondra. Kolesov described dissecting the prolabium from the premaxilla with particular attention to freeing the columella to the tip of the nose. The Tennison-type incision along the side of the prolabium freed a lateral mucosal flap, which was either excised or folded to cover the raw premaxilla. The lateral lip element was incised into flaps in the style of Limberg, Obukhova and Tennison with a portion for the nostril floor and a turnover flap of mucosa and skin as used by Bauer, Trusler and Tondra to line the backside of the undermined prolabium.



Alexander Kolesov

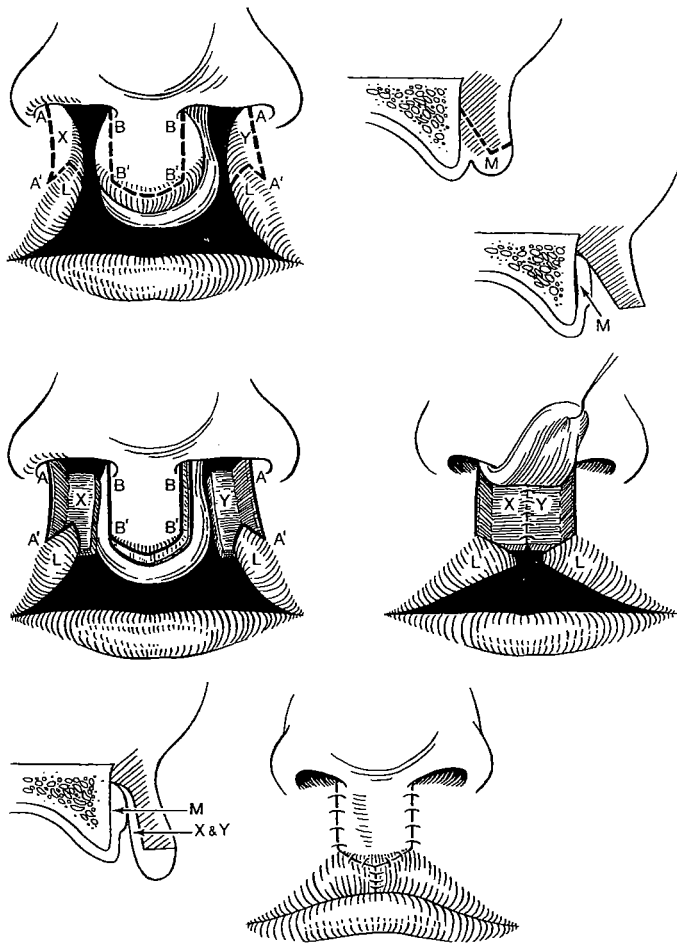


Kolesov operates on the first side very early and the second side two months later.



LATERAL MUCOSAL FLAPS BEHIND THE PROLABIUM

Clayton R. DeHaan of St. Luke's Hospital, New York City, prefers to close bilateral clefts in one stage and demonstrates ingenuity in creating an upper labial sulcus. He described with illustrations the details in his section of Stark's 1968 book:



The two-stage operation is less satisfactory, in our opinion, for several reasons. . . . When one side only is corrected, the premaxilla rotates toward it, widening the cleft on the other side and twisting the prolabium; thus the second side is technically more difficult to correct. . . . We prefer a straight linear repair of both sides of the lip in a single stage. . . . Prolabium vermilion surfaces the premaxillary side of a deepened alveolar sulcus, while vermilion from the lateral lip elements is advanced to the midline beneath the prolabium.

a good point!

DeHaan notes that the definite landmarks present in unilateral clefts are lacking and warns:

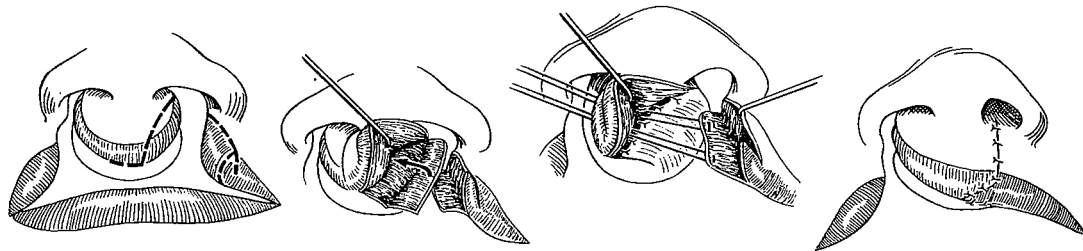
All points on which the repair is based depend upon the surgeon's judgment and experience. A small prolabium makes the correction relatively more difficult but it may still form the entire central lip since under tension the growth potential of this tissue is phenomenal.

He is, alas, willing to reenter the lip for columella lengthening:

The prolabial segment is often too wide following repair and lacks the desired normal appearing philtral ridge with dimple. No attempt should be made to narrow it at this time, as this segment will later furnish ample tissue for lengthening the columella.

A VARIATION IN TWO STAGES

The indefatigable Charles Horton, with Adamson, Mladick, and Taddeo of Norfolk, in 1970 advocated preservation of vermilion parings for covering the raw surface of the premaxilla. Then in 1974 Richard Mladick, with Horton, Adamson and Carraway, repropoed this principle along with introduction of lateral mucosal flaps behind half of the prolabium in a two-stage primary procedure. This achieves lining for both sides of the labial sulcus and frees the prolabium from the premaxilla.





William Manchester

MUCOSA ONLY BEHIND PROLABIUM VERMILION

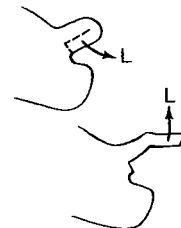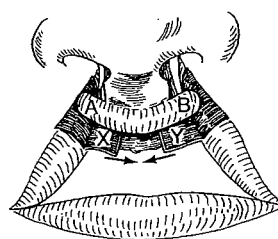
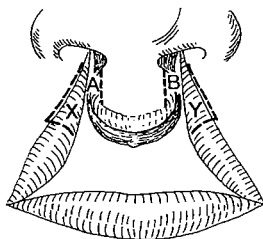
The droll and wiry William M. Manchester of Middlemore Hospital, Auckland, New Zealand, has developed his own modification of a "down-under" approach to bilateral clefts. He refers to himself as "a rather 'square' sort of a person," but this description is not upheld by the facts. He has been active in postgraduate surgical education, has achieved renown from his stories about the exploits of the New Zealand All Blacks Football Team and is building a country house in a natural New Zealand forest filled with native plants and birds. As he recalled sympathetically,

I remember Sir Harold Gillies once telling me that what he yearned for most in England was the smell of wet New Zealand bush.

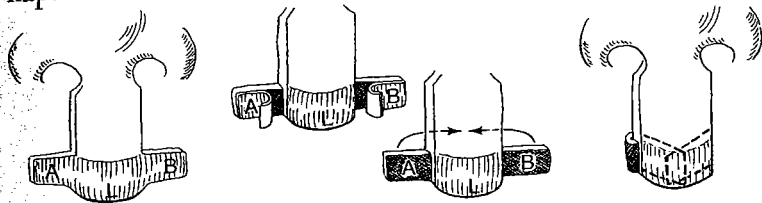
His analysis of his own philosophy gives the truest picture of Bill:

I am not a rebel but I am a great believer in people getting on with their job without unreasonable complaint, conscientiously and without too much thought of "what's in it for me." In other words the job being an end in itself.

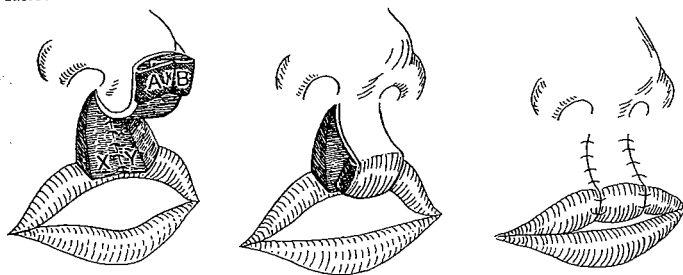
In 1970 and again at the Melbourne Congress in 1971 Manchester described his approach to bilateral clefts, an approach which limits the amount of lateral lip elements introduced behind the prolabium as the prolabium is not freed from the premaxilla and the lateral muscles are not joined together. After lateral manipulation of the maxillary segments by his orthodontist, he accomplishes closure of both lip clefts and hard palate in one operation. He trims the lateral vermilion of the prolabium as a pair of flaps based inferiorly on the mid-vermilion, which swing out like wings A and B "à la Axhausen."



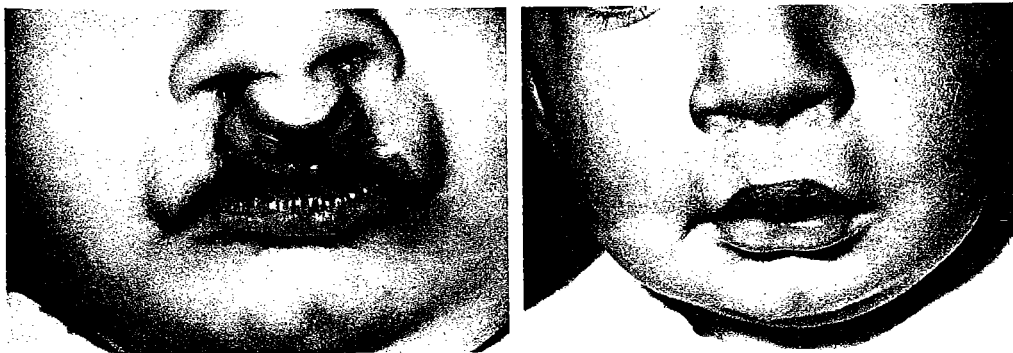
Then he unrolls the inferior vermilion of the prolabium trapdoor fashion so that the entire prolabial component unfurls. The wing portions, which come from the lateral sides of the prolabium, are denuded of epithelium and fold onto each other under the central vermilion to give more body to the mid-tubercle area. Manchester leaves the prolabium attached to the premaxilla but advances the turnover mucosal flaps X and Y from the lateral elements "down-under" his central unrolled vermilion flap.

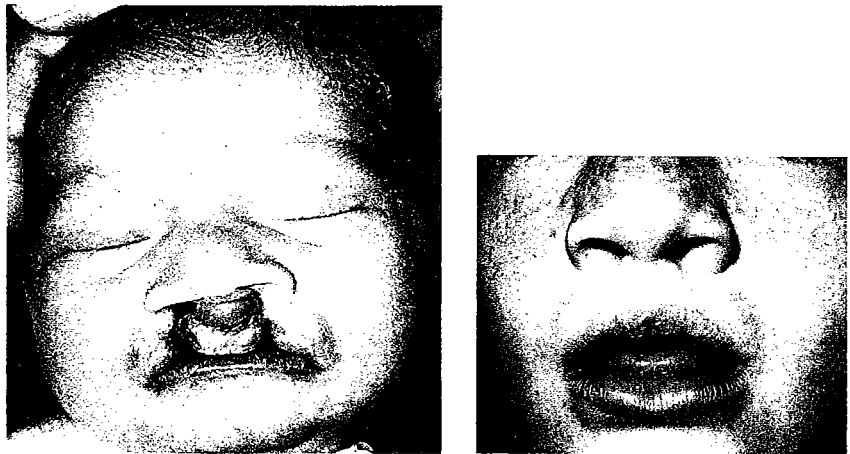
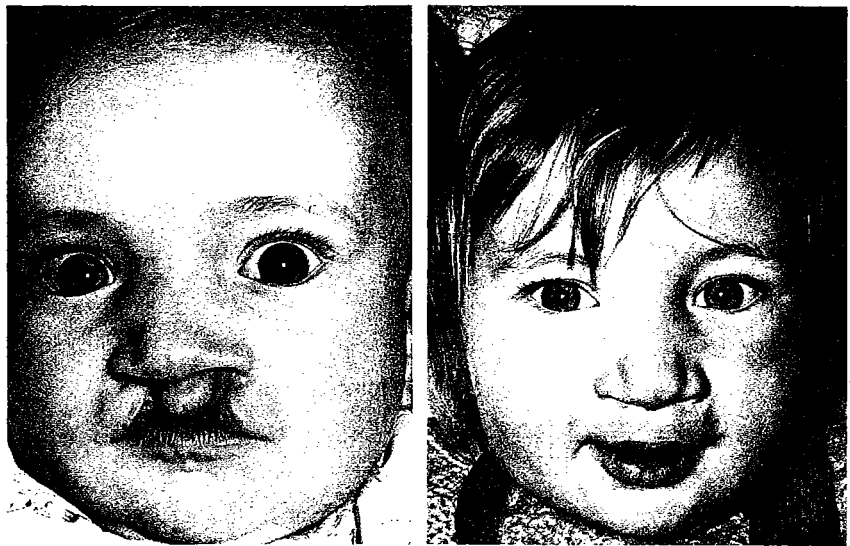
The lateral lip elements are joined in a straight line to the sides of the prolabium with the scar of union ending bilaterally in the nasal floor.



These actions provide extra mucosa to the central tubercle but do not free the prolabium, line it or bring the lateral orbicularis oris muscle fibers together behind the prolabium. This approach produces a good lip but results in a wide prolabial component with an ample but stuck-on looking central vermilion segment. The nose shows some alar flaring and a short columella with the usual depression of the nasal tip.

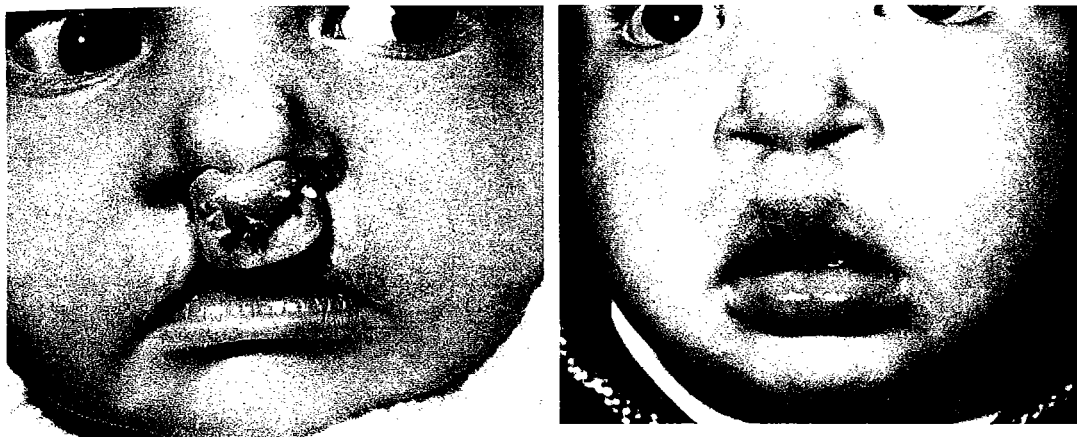




Manchester discounted any concern for the short columella, wide prolabium and broad cupid's bow, advising correction of the one with the other by a forked flap when the patient reached 16 years of age. Apparently he had no hesitancy in reentering his lovely lip to cut out a forked flap.

Evaluation of these shortcomings, stimulation by modifications of his method in the literature and weariness with wrestling with the secondary surgery probably led Manchester to change his plan slightly. In August 1973 he cited this case 11 months

postoperatively as representing the procedure at its present state of development.



He pointed out:

You will note that the prolabial part of the lip is narrower in her case as I am no longer preserving material for use in elongating the columella later. I no longer believe that this is the right way to lengthen the columella and we are developing other methods at present.

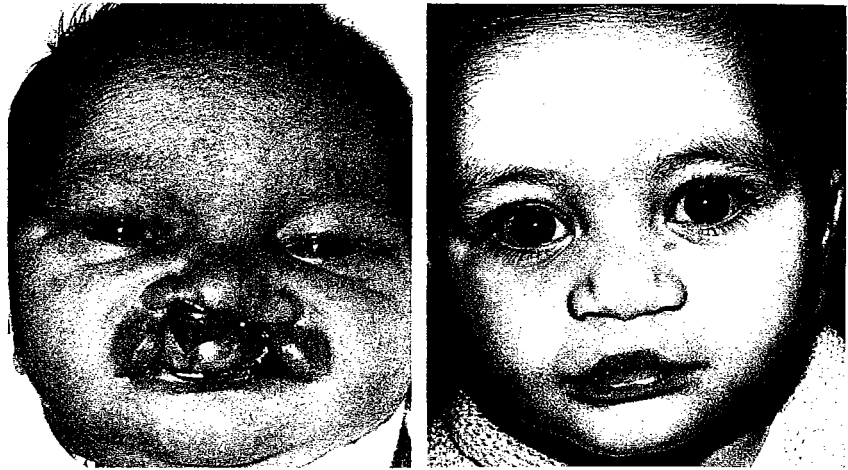When challenged further he wrote back in September 1973:

I have fairly strong views about the nasal tip, for example, the timing of the repair and the method of doing so. . . . I happen to believe that the junction between the columella and the upper lip is about the only normal part of the nose and that this part of it should remain inviolate. Even in the best of hands, this part looks unattractive and to me is a real disfigurement . . . and I am concerned that infancy is not the best time to do it for a whole variety of reasons.

This is an interesting shift of focus, but there is no great problem to getting a fine final nose in adult bilateral clefts. It is the years of suffering with the flat nose during childhood that cannot continue to be ignored.

Then in November 1973 Manchester sent another nice lip but

still with wide alae, short columella, wider than normal philtrum, straight-line scars but full tubercle.



IMPROVING THE SCAR LINE


T. Ray Broadbent of Salt Lake City is a giant among plastic surgeons not only in height, offices held and contributions but also in his philosophy:

We are common children of a Father in Heaven who looks at the worth of an individual soul as being of more value than anything else.

When not engrossed in his first hobby—work—he enjoys going up in the mountains and doing a little farming and working with horses, including breaking in colts to ride. Fascinated with the challenge of bilateral clefts, concerned about the lack of an upper sulcus and the tendency for a whistling deformity, and disenchanted with the Christmas tree effect of the bilateral Z, he turned to the method of Manchester. It was not long before he was modifying Manchester's wide prolabium and straight scars with what he loosely called "a Millard scar pattern" along the rotation-advancement line with circumalar extensions and reduction of the prolabium. Broadbent and Woolf reported their results in 1972 with this modified Manchester approach, claiming

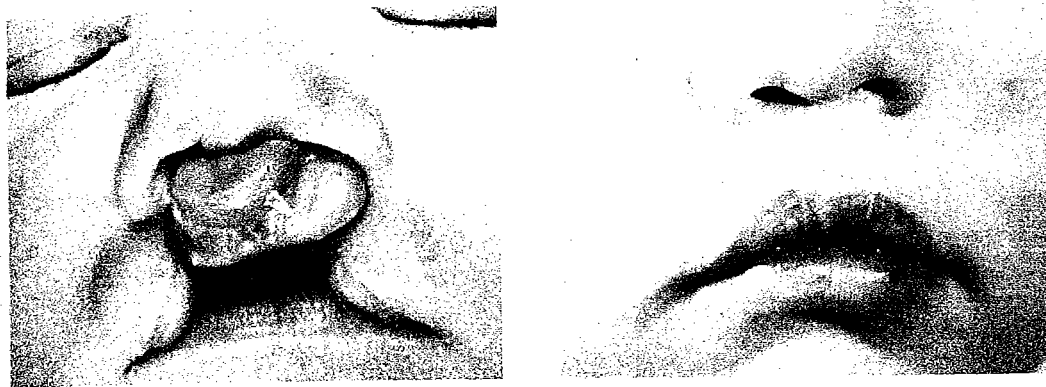
a lip with satisfactory length, a cupid's bow, a full central tubercle, an acceptable scar pattern, a free prolabium and an adequate superior labial sulcus.

Indeed they presented lovely photographic results of the lip at least at rest, and there was no question that when they used the



Ray Broadbent

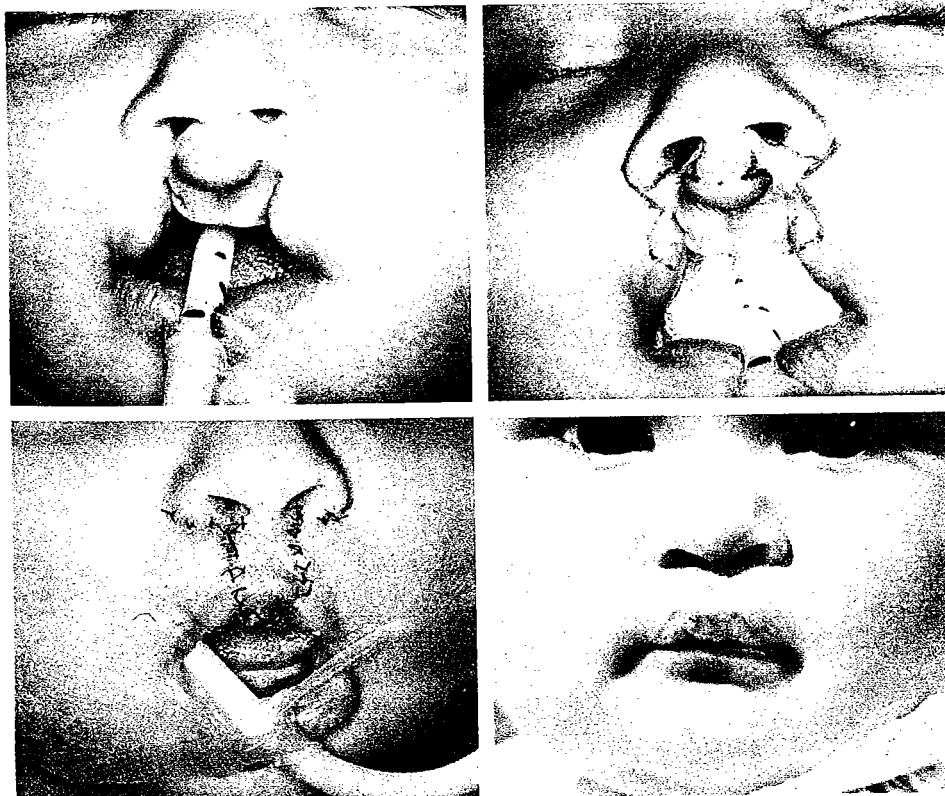
rotation-advancement scar line the effect was more natural. This is particularly well exemplified in one of the cases published in *Plastic and Reconstructive Surgery* in July 1972 which had a rare dimple in the prolabium and a longer than usual columella in the original deformity.




Late in 1973, upon request, Broadbent forwarded, besides the above case, some examples of his bilateral clefts, stating:

You may use any or all of these as you see fit. They will demonstrate two or three points that I would like to make:

- 1) The best scar . . . is the first one. . . .
- 2) The prolabium should always be narrowed to be no longer than





6 mm. from peak to peak or three from the center to each peak of the bow. Otherwise the bow is too wide and the lip does not look normal.

3) . . . The sketch that is enclosed, though the lines do not match in length, show in dotted line a wide prolabium saving everything and in the solid lines the narrowed prolabium as we would do it. Further I think the line should be curved and tucked closely to the base of the columella to keep the incision and scar out of the floor of the nose. The scar on the floor always looks like a dirty, runny nose.



Micheline Viale-Gonzalez

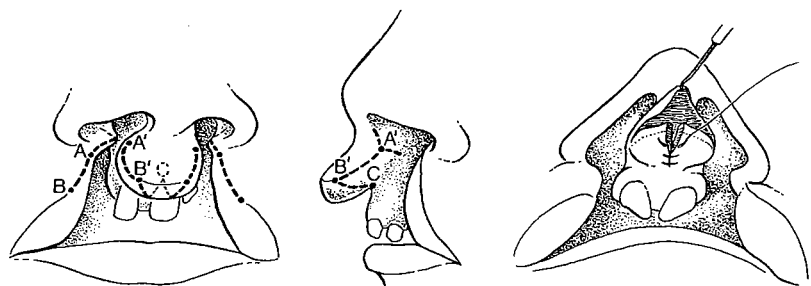
A MEXICAN MANCHESTER

Another variation of the Manchester theme was described in *Plastic and Reconstructive Surgery* in 1973 by Micheline Viale-Gonzalez, Felipe Barreto and Fernando Ortiz-Monasterio of the Graduate Division of the School of Medicine of the Universidad Nacional Autonoma de México.

The senior author of this modification is a Franco-Italian lady with *joie de vivre* who began her study of medicine when her daughter started school. Thus she is prompted to say:

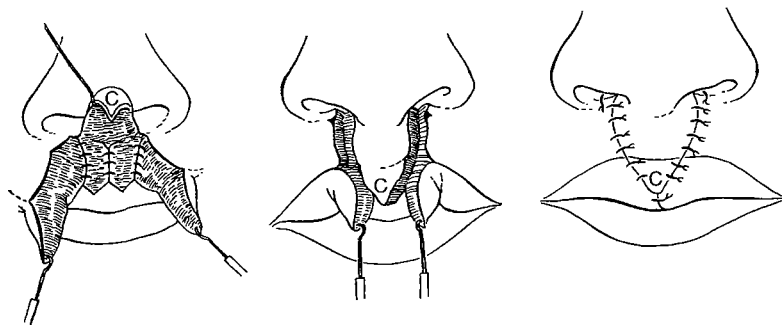
I am a middle aged doctor with all the anguish and ambitions of a very young one. . . . I don't "enjoy" bilateral clefts, I only react to the challenge. They are difficult, so, I like them.

In their design these authors first unroll a V of posterior-inferior prolabium mucosa (C) in the spirit of Manchester. Cutting the lateral mucosa free from the sides of the prolabium but leaving it attached to the premaxilla forms two flaps, A' B' C, which are sutured to each other over the front raw area of the premaxilla and then are folded back on themselves to form lining to the prolabium and a partial labial sulcus.



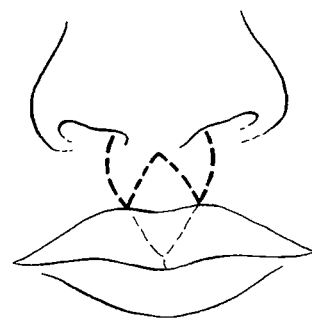
The sides of these flaps are sutured to the mucosa of the lateral lip elements. The only muscle approximated is that in the lateral

vermilion flaps, which are sutured together below the prolabium just behind the inferior central V of prolabium vermilion to form an exaggerated tubercle.



This action provoked the authors' claim that "the whistling deformity belongs to the past." Yet here again a lot of fancy maneuvering has taken place without provisions for lengthening the persistently short columella. Violation of the original lip scars is justified with:

Although we agree with Millard and Broadbent that the best scar is the first one, we feel that secondary elongation of the columella is imperative in most of these patients—and a good secondary scar can be obtained with careful technique. . . . Preservation of all the prolabium skin makes elongation of the columella relatively easy by the forked flap technique, several months after closure of the lip.

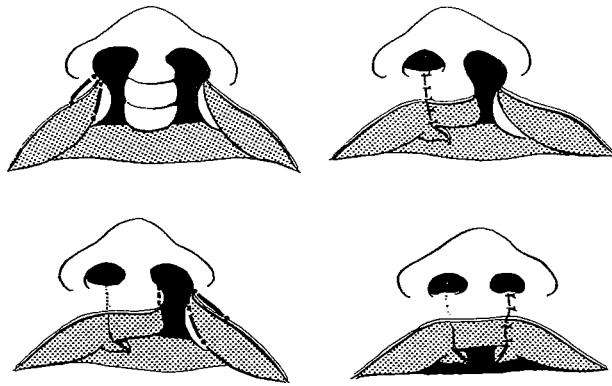


BOLSTERING THE CENTRAL VERMILION

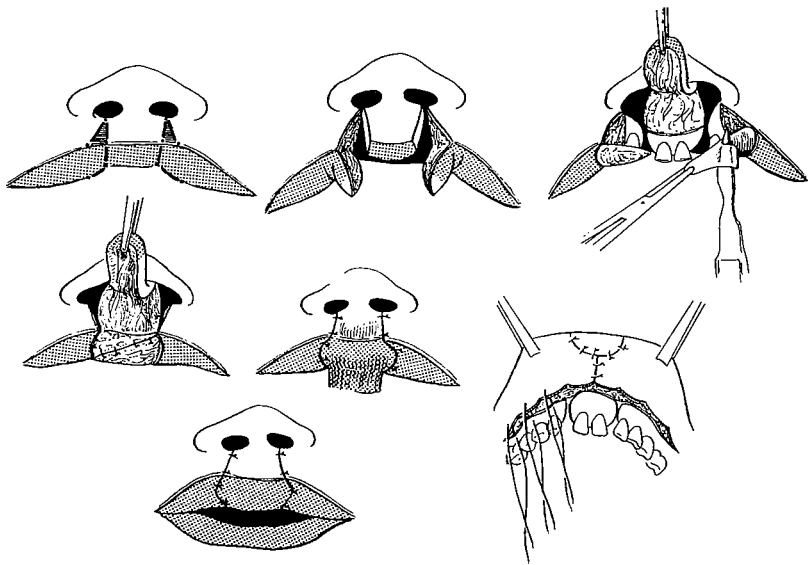
A variation in the principle of introducing the lateral segments behind the prolabium was devised in 1963 by Brazilian Victor Spina, a strong man of São Paulo. He seems less concerned with muscle continuity across the clefts than with bolstering the prolabium vermilion to avoid a whistling deformity. In 1966 he readvocateed his approach in three stages. The first two operations, two to three months apart and completed by one year, merely transformed bilateral complete into bilateral incomplete clefts.



Victor Spina



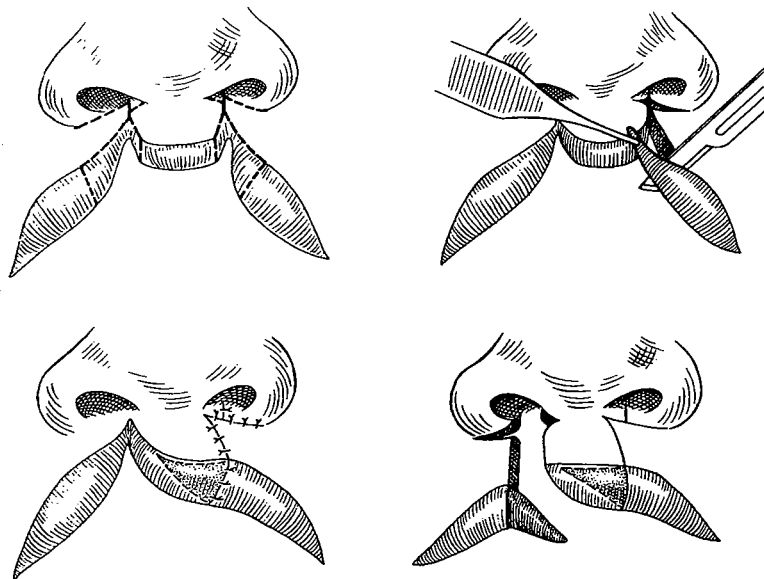
Then, at five to seven years of age, the closure is reopened but with maximum preservation of the lateral vermilion, which is de-epithelialized. As a matador might tuck two swords under his cape before the kill, Spina slides denuded lateral vermilion flaps side by side under the prolabium vermilion. The lateral lip elements are reattached to the sides of the prolabium.



Staging the procedure means that more operations are required and more tissue is discarded. And, in spite of all this effort, there is still the problem of the short columella and depressed nasal tip—and less tissue available now to deal with it.

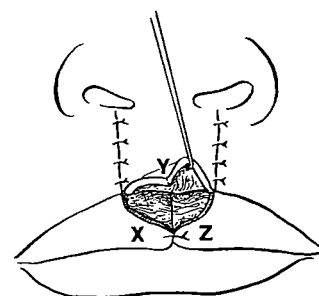
In 1970 José Guerrero-Santos and Marcos Ramirez described a procedure denuding the lateral paring flap and introducing it across the cleft to bolster the prolabium tubercle. At this time they interrupted the vertical closure with a type of Tennison interdigitation and treated one side at a time.

In 1973 Guerrero-Santos wrote from Guadalajara that several years earlier he had changed to the rotation-advancement method and combined his denuded lateral flaps buried behind the prolabium vermilion.



BACK ACROSS THE BORDER

A type of bolstering of the central vermilion by lateral elements was conceived early by Thomas A. Cresswell while in Texas. Cronin, in his 1957 double cleft paper in *Plastic and Reconstructive Surgery*, included a diagram of Cresswell's modification which denuded the vermilion of flaps X and Z for introduction beneath the "lift up" triangle of prolabium vermilion Y. Cresswell recalls,



When I was with Tom Cronin back in 1956, Tom was interested in reviewing his cases of bilateral cleft lip repair. As his preceptee, it became a part of my assignment to assist with this review. It did not take much of a discerning eye to note that all of these bilateral cleft repairs, despite Tom's admitted technical skill, had one thing in common, namely, that the central portion of the free margin of the lip was notched, due to a lack of substance in this central portion of the vermilion. . . . At that time I suggested the procedure Tom credited me with.

A LITTLE OF BOTH

Remembering that Cresswell had shown this ability to fly on his own in bilateral clefts, I was inquisitive as to where his flights



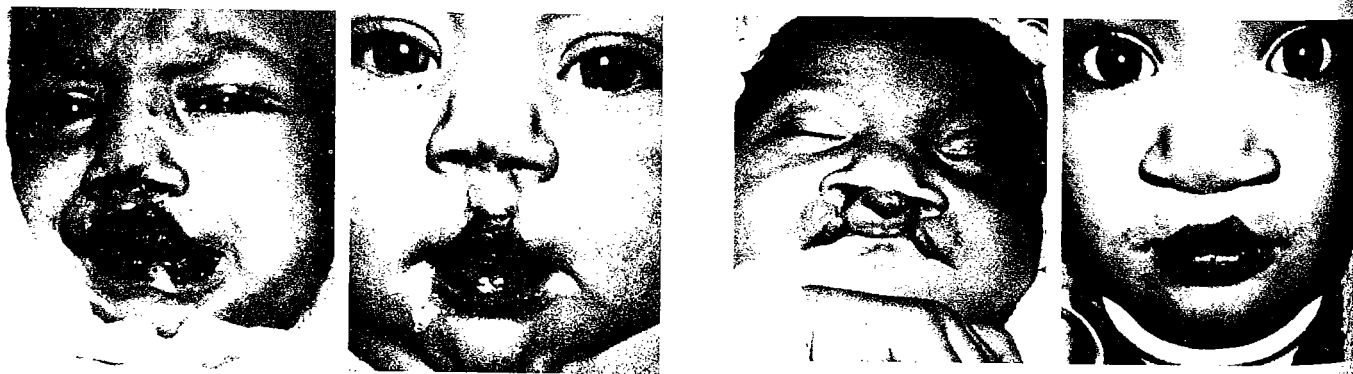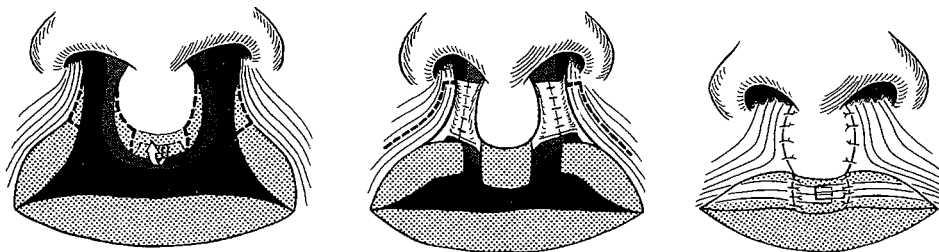
Thomas Cresswell

had carried him in the 16 years since he flew from the Cronin-Brauer nest.

He was trailed to Saginaw, Michigan, and the "game" proved worth the tracking. He wrote me his unpublished thoughts in August 1973:

*Pennisi
or
Fara*

My subsequent reading about the lack of any form of musculature in the prolabium itself, as evidenced by electromyographic studies, coupled with the reading of information concerning the deployment of the muscle fibers in the lateral lip masses, started me thinking. As I recall, these fibers come transversely across the lip margin and extend upward to the area of the alar bases on either side, curling somewhat in this area. After seeing this particular illustration in a text which I have now long since forgotten, it occurred to me that a logical procedure would be to actually go up and cut into this lateral mass at the root and take down a rather long segment of heavy muscle fibre on each side and bring this across the mid-line under the elevated portion of the prolabium vermilion and attach it to its opposite member, overlapping them slightly to provide not only continuous musculature across the upper lip margin, but to add some fullness to this central part of the lip. . . . I have followed this procedure now for quite a number of years and have a series of cases.



A GOOD LIP

The general plan of uniting the mucosa from the lateral lip segments behind the prolabium offers several advantages. When

the tension of the closure is taken in the hidden posterior scars, the skin scars are usually superior in quality. The prolabium backed by mucosa also has a natural sulcus. This leaves an inanimate, somewhat flattened prolabium. When the muscles of the lateral elements also are joined to each other behind the prolabium, all the previous advantages are enjoyed, possibly to even a greater degree. In addition, the upper lip becomes an animated, functioning unit that can mold the premaxillary-maxillary arch effectively and will not let the central prolabium stretch out flat like saltwater taffy. Full-length vertical joining of both *mucosa* and *muscle*, it would seem, offers a sounder lip construction than is obtainable with strips of muscle or flaps of the subcutaneous tissue. There is, however, one side-effect that is a disadvantage in reverse. The columella is still short, but with the lip so soundly constructed its refusal to stretch reduces the amount of tissue available for a secondary forked flap. If a forked flap has not been banked, it must be taken out of the lip, and the resultant scars will usually be of inferior quality when compared to those following the original lip closure.

*but no
Columella!*

COLUMELLA FROM NASAL FLOORS

When the lip has been well formed, with muscle continuity from side to side and without flat unnatural spreading of the prolabium, one will have difficulty taking a flap or pair of flaps out of it. It is then that tissue from elsewhere may be of value. The medial and upward rotation of skin from the nasal floors in continuity with the alar bases can shift a limited amount of tissue into the columella. This principle was first described by Carter but perfected and popularized by Cronin. It has the advantage of not reentering the lip for nasal revision, but its effect in the severely depressed nasal tip is less than dramatic.

