

9. *Conscientious Objectors*


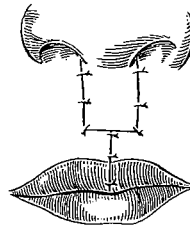
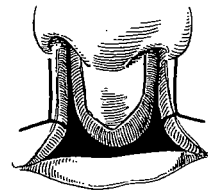
A year before I was born, George V. I. Brown had the good sense to object to the principle of sticking lateral flaps of skin and vermilion below the inferior edge of the prolabium. He noted in 1918 that incisions as advocated by Von Langenbeck, Mirault, Maas and others were undesirable:

This method of operation creates an ugly deformity by making the lip too long, and should be avoided.

At least he had the courage to speak out against methods that were popular among surgeons of his day. In spite of his early stand this principle continues to have sporadic popularity among the unenlightened even of today.

ANOTHER HEATED DISSENTER

Then in Chicago in 1951 the fiery Milton Adams of Memphis in his inimitable style pulled the pin on a grenade labeled "The Misuse of the Prolabium in the Repair of Bilateral Cleft Lip" and tossed it into the meeting of the American Association of Plastic Surgeons. The main blast of the explosion was aimed at primary surgical procedures wherein the prolabium is shifted up to build the columella and the upper lip is formed wholly or in part by suture of the lateral labial segments in the midline—or Maas, König, Rose, Thompson and Hagedorn. Unscathed were the methods of G. V. I. Brown, Vaughan, Axhausen and Warren Davis, wherein the prolabium alone is utilized for the total vertical lip. This presentation, co-authored by the Adams brothers



Milton Adams

Milton and Lorenzo from Tennessee, was published in 1953 and became a classic.

Milton Adams admitted that 14 years earlier he had first shifted an infant's prolabium into the columella to avoid the flat-tipped nose and had closed the lip side to side beneath it. The Memphis fireball blamed being tempted into this trap on his happier experiences with the same principle in adult cases.

True to his mottoes "It is often as necessary to know what not to do as to know what to do" and "A good surgeon should always be his own severest critic," Milton pointed out his findings:

It is difficult to explain why the upper lip of an adult repaired by suture of the lateral segments together in the midline will remain as constructed while in an infant it will be followed by practically twice the normal lengthening of the lip.

*good
Common
sense*

The Adams boys conjectured:

Perhaps, the extra length in the infant is developed by repeated drawing of the lip down over the premaxilla, whereas in the adult, the teeth support the lip.

They admitted:

The prolabium is often small, even rudimentary and one may thus be tempted.

But they hastened to reassure:

Indeed, the development which takes place in even a rudimentary prolabium is amazing.

They advised staging the repair rather than sectioning the vomer and advocated correction of the nasal deformity after the child acquired an adult facies.

In 1973, more than 20 years later, Lorenzo Adams reconfirmed their previous stand:

It is my impression now that the information in the article presented by Milton and me on the misuse of the prolabium in repair of double cleft lip in infancy is valid. It is now my impression that in cases of double cleft lip and palate after attaining maturity of the facial features in postadolescence, flaps from the lateral segments may be utilized above or beneath the



Lorenzo Adams

prolabium without resulting in excessive elongation in the vertical dimension of the lip. This is in contrast to the results of the same procedures in infancy.

A CHECK

Whether this 1951 Adams stand started a trend or put a brake on previous trends, it brought to the fore what many surgeons were beginning to realize. Here is an example. In 1954-1955 while I was at "A Med" with the First U.S. Marine Division, Korea, Sten Stenstrom of Sweden was down at the Swedish Hospital in Pusan. During his time there, he used the LeMesurier quadrilateral flap to introduce skin and mucosal tissue beneath the prolabium on 18 Oriental bilateral cleft cases. He stated in his 1957 preliminary report:

Only by long observation can the procedure be fully evaluated.

Whereupon Bromley Freeman of Houston, Texas, responded in 1958:

About seven years ago, I tried this combined LeMesurier technique on a small number of patients for bilateral lip repair and have been able to follow them a little longer than Dr. Stenstrom. I have found that the lip grows entirely too long, as typical of the older methods of repair. . . . While I was doing a secondary repair, it occurred to me that I should bring this to your attention, so that the younger men could be apprised of the fact. . . . In informal discussion with several of my colleagues I find that they have met with similar difficulty.

*We don't
have to
wait years
to see what
other surgeons
have already
seen. Time
and time again*

A MASTER'S SECOND THOUGHTS

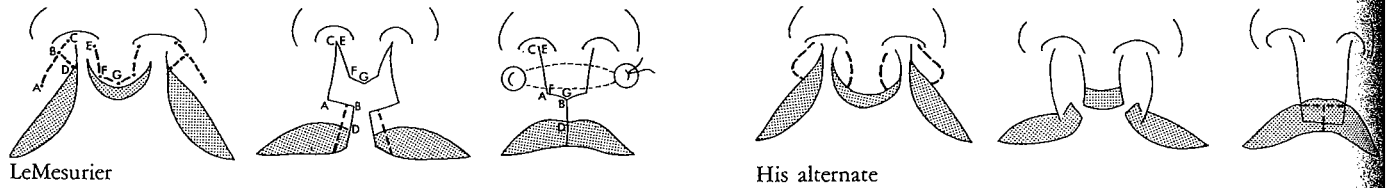
LeMesurier had adapted his modification of Hagedorn for the treatment of bilateral lip clefts and was sliding two quadrilateral flaps along the lower border of the prolabium. He began to realize from follow-up observation that when the prolabium was long primarily, his approach could only produce *longer* upper lips. Thus, in his 1962 book, he outlined his selective plan:

If the prolabium is long enough to make the central part of the lip of decent length and if there is enough mucous membrane available to make the vermilion border thick enough, it is probably better to bring the prolabium

down and use its lower edge to form the central part of the lower border. . . . In bilateral cases in which the prolabium is too short to make the central part of the lip sufficiently long, or if its mucous membrane is extremely thin, it is better to turn down flaps from both sides and suture them together in the midline below the prolabium.

Then he charted the design for each general category of bilateral lip clefts and included an alternative approach incorporating the whole length of the prolabium as the central component of the lip.

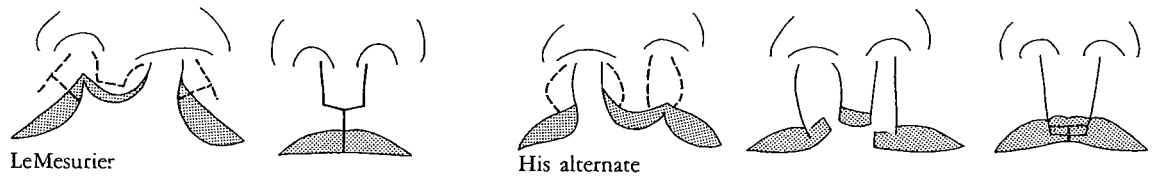
Complete bilateral clefts



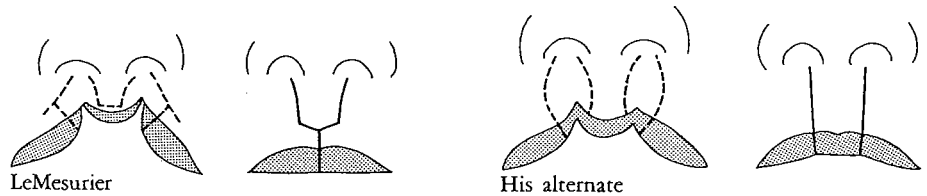
LeMesurier in typical candor stated:

It must be admitted that no matter which operation is done, the results obtained in the complete bilateral cleft of the lip are always far from perfect.

One complete cleft, one incomplete



Both clefts incomplete



LeMesurier's comment on his results of incomplete type of bilateral clefts was:

No matter which operation is done, the results are usually better than in the other types of bilateral hare-lips.

A SALTY CRITICISM

In 1972 Broadbent and Woolf of Salt Lake City evaluated the use of the LeMesurier method in bilateral clefts and reported unimpressive results whether done in one or two stages, disappointingly long lips, a false and irregular cupid's bow, a prolabium still adherent to the premaxilla, a whistling deformity and a flat nose. The length of the two sides of the lip were often unequal, and

At times, the scar pattern resembled a sketch of a Christmas tree more than a normal philtral ridge.

OBJECTIONS FROM TEXAS

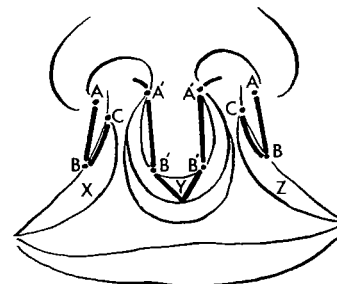
Tom Cronin of Houston, Texas, joined the Adams swing in 1957 and retold the story:

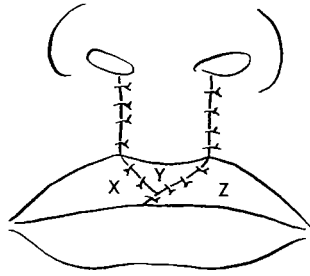
Adams and Adams, at one time, used all of the prolabium in the initial repair for lengthening the columella, but they found that within a year, such lips were becoming entirely too long vertically and that this tendency continued with the growth of the child. They now strongly advise against this procedure and I agree with them completely.

In reference to previous methods which turned flaps of skin from the lateral lip elements beneath the prolabium to increase its vertical length, Cronin explained:

This practice has obviously arisen because the prolabium appears to be shorter than the lip fragments on each side. All prolabia, in their isolated position, appear smaller than their actual potential when incorporated in the lip. In the first place, the prolabium actually is thinner than the lateral lip tissue and, secondly, as there are no attachments to stretch the prolabium out, it shrinks down to the smallest area possible.

Cronin went on to describe his premaxillary setback and a rather simple bilateral lip closure in one stage with the prolabium used





to form the full vertical length of the middle of the lip. This procedure of course left the columella short and the nasal tip depressed and merely set the lip groundwork for his later columella lengthening.

By 1971 Cronin was even more decisive against inferior skin bolstering and even lateral interdigitations of the prolabium. With Penoff, he fired some broadside shots:

The Veau II. or Barsky type operation is an obsolete procedure resulting in a lip which is too long vertically and too short from side to side. The tightness contributes to retrusion and lingual tilting of the incisor teeth. . . . The Barrett Brown procedure removes all of the prolabium vermillion bringing the vermillion of the lateral segments together in the midline, thereby tending to constrict the prolabial skin in a circular manner, as well as making the lip a bit tight from side to side. . . . Only one adaptation of the LeMesurier operation was done. This procedure was wasteful of tissue, tended to result in side to side tightness and noticeable scars.



Ernest Kaplan

THE HORIZONTAL VERSUS VERTICAL LIP GROWTH OBJECTION

Ernest N. Kaplan of Stanford Medical Center has measured horizontal length of unilateral clefts in the newborn and the adult and found that the lip length doubles its original horizontal dimension (100 percent). Similar measurements of vertical philtrum height in the newborn and the adult indicated a proportional growth of the prolabium, with only 50 to 75 percent vertical growth potential from the newborn to the adult. He noted in 1974:

When the 50-75% vertical growth is compared to the 75-100% horizontal growth, we can appreciate that a cleft lip can grow twice as much in the horizontal direction as it can in the vertical direction. Therefore, any operative procedure taking tissue that is horizontally arranged and transferring it in the vertical direction must account for this potential growth differential. This, we believe, explains why the Asensio and the LeMesurier repair can grow too much on the cleft side when the procedure is performed in a newborn, but little or no discrepancy is seen when the procedure is applied to young children and adults.

A CAUSE OF INCREASED VERTICAL LIP LENGTH

Although Kaplan's studies have been confined to the unilateral cleft, of course they also apply to the bilateral cleft, and doubly so. Thus, any vertical flaps transposed horizontally, as so often noted, usually will be responsible for abnormal increase in vertical lip length; this is another sound *contraindication* to the use of such flaps.

In spite of these wise warnings by experienced surgeons for over half a century, operations are still being done in which lateral flaps are introduced below the prolabium. The invariably unacceptable results being seen in many cleft clinics and the severe difficulties encountered during their secondary correction warrant stamping these actions OBSOLETE and DANGEROUS and having their use outlawed.