

## 7. *Prolabium as the Full Length of the Upper Lip in Straight-Line Closure*

IN bilateral clefts without premaxillary protrusion it does not take much imagination to think "lip" for the prolabium. It is sitting demurely between the lateral elements, and to join the three seems quite logical. If the premaxilla protrudes in front of the maxillary elements, carrying the prolabium farther away from its lateral counterparts, the solution is not so obvious. And when the prolabium is actually projecting off the tip of the flattened nose, it is easy to sympathize with those surgeons who, in desperation, used it as a columella to satisfy the nose and were willing to pull "like hell" to get the lateral elements joined to each over the premaxilla.

Of course the early surgeons merely chopped off the premaxillary knob in an expedient ruse to facilitate lip closure. This was Franco's approach in the sixteenth century, but he had the ingenuity to undermine the lateral lip elements and to incorporate the prolabium in the lip.

Georges de la Faye of the Royal Academy of Surgery, Paris, whose portrait has been obtained by courtesy of the Boston Medical Library in the Countway Library, wrote about his operation for bilateral cleft lip in 1743. Translation of his work by Mary McDowell for *The Classic Reprint in Plastic and Reconstructive Surgery*, 1976, indicates that his second operation was a more classical design incorporating the prolabium as the center of the reconstructed lip. He noted,

I did not remove any of the jaw, because none projected

and proceeded to attach the lateral lip elements to the sides of the prolabium and transfix them with pins wrapped with silk in



*Georges de la Faye*

figure-of-eight fashion and reinforced with linen bandage. He bled the boy postoperatively several times for fever and reported

Twenty days later the lip was all perfectly healed; the scar was in the shape of a Y.

The accompanying commentary by editor Frank McDowell as always was interesting.

By de la Faye's time surgery, even plastic surgery, had come in out of the streets and become a respectable occupation—one suitable for gentlemen who wore powdered wigs and truffles and had portraits made. Moreover, the elite knew each other, then as now, and on occasion they watched one another operate.

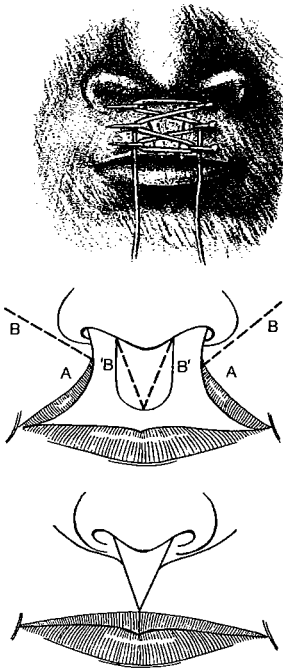
In 1842 in New York, J. Marion Sims also removed the premaxilla but preserved the prolabium for the central portion of the lip. At a second operation five weeks later, he pared the lateral lip and prolabial edges, brought all elements together, and fixed them for one week with a single interrupted suture across each cleft, further stabilized with a through-and-through needle.

In 1844 Joseph Pancoast of Philadelphia expressed preference for use of the prolabium as the full length of the lip.



*Joseph Pancoast*

The patient is to be seated in a good light, with the arms and feet well secured, and the head pressed against the chest of an assistant, who with his hands compresses the facial artery of each side under the edges of the jaw, and with the thumb pushes the cheek in toward the midline. . . . If the intermediate substance be a larger dimension it must be preserved, as it will be of great importance in the reconstruction of the lip. . . . The operation may be completed at once . . . by detaching the frenulum, paring the edges of the middle portion . . . excising the margins of the two lateral portions—and introducing the pins so as to bring fairly together the four raw surfaces, causing one or more of them to traverse the middle portion.



In 1877 Francis Mason of Grosvenor Square, London, described the method of Sedillot, which, aided by removal of the premaxilla, incorporated the prolabium as a V in the full length of the upper lip, bringing only the mucosa of the lateral lip elements together in the midline. William Rose stated in 1891:

I cannot but think . . . that the nasal distortion is less easily remedied by this plan.

It required both insight and courage for early surgeons to save the obstructing premaxilla and still incorporate the prolabium into the central portion of the lip.

In 1897 Julius Wolff realized the importance of pressure from the united lip to retropose the premaxilla. He also advocated use of the entire prolabium for the full length of the central upper lip.

In 1844 Joseph-François Malgaigne of Paris wrote *Du Bec-de-Lièvre*, which was translated from the French by Robert H. Ivy and published as a classic reprint for *Plastic and Reconstructive Surgery*. His portrait from F. H. Garrison's *History of Medicine* shows him as a young man.

Using the standard approach of his day, Malgaigne pared the edges of the cleft and used pins to approximate them but was constantly disappointed by the resulting notching. He wrote

For double harelip the atrophy is still more striking; generally, the median lobe of the lip is shorter than the other sections, and it cannot contribute to reconstruction of the labial border; the median notch is, therefore, much deeper than in unilateral cases.

He was first to conceive and publish the cutting of flaps off the edges and using these to prevent notching.

As he said,

In a word, the freshening of the harelip should only be done by cutting from the skin a few parings—and it is the utilization of these lost cuttings that constitutes the new method. I say *method*, with the understanding that the harelip operation which is now classified as chielorrhaphy becomes so transformed that it enters the classification of cheiloplasty. Instead of becoming a seam, it adds a piece. . . . If one were dealing with a double harelip, it is easily understandable how one could, for the creation of a median tubercle, take advantage of these two floating flaps which will always offer more than the necessary amount of substance.

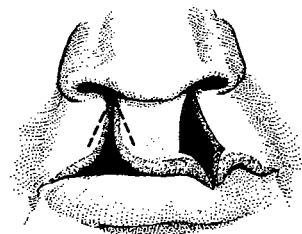
It later was brought to Malgaigne's attention by Roux that M. Clemont of Rochefort had described to him a similar operation. As explained by editor Frank McDowell, there had been no illustration in Malgaigne's classic article and the diagram shown here labeled "Clemont-Malgaigne procedure" was published later in a book by Broca.



Julius Wolff



Joseph-François Malgaigne




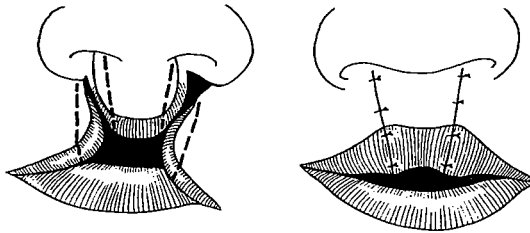
## BROWN VERSUS FEDERSPIEL



*George Brown*

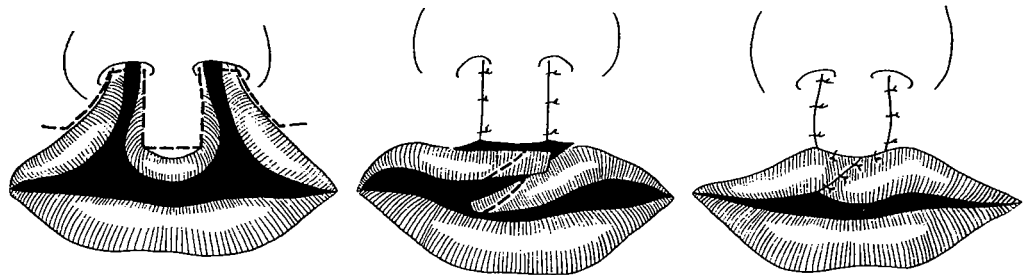
Two champions of the general principle of incorporating the prolabium in the full vertical length of the upper lip were George Van Ingen Brown and Matthew Federspiel. Both held M.D. and D.D.S. degrees, both wrote books, both worked in the Milwaukee area—Brown at Children's Free Hospital and Federspiel at Marquette University. They were keenly competitive, each jealously guarding his own variations in technique to the extreme of barring the other from his operating room.

G. V. I. Brown's air of pomposity led followers of Federspiel to refer to him as "God vainly imitates" Brown. He designed a simple bilateral lip closure in 1918 that maintained the entire vertical length of the prolabium including its vermilion and incorporated it into the central upper lip.



*Matthew Federspiel*

In 1927 Matthew Federspiel published his method, which incorporated the entire prolabium into the center of the upper lip. Also, he modified the method by discarding the prolabial vermilion and transposed lateral vermilion flaps across under the prolabium to form the free border. He interdigitated these flaps in an attempt to create a cupid's bow.

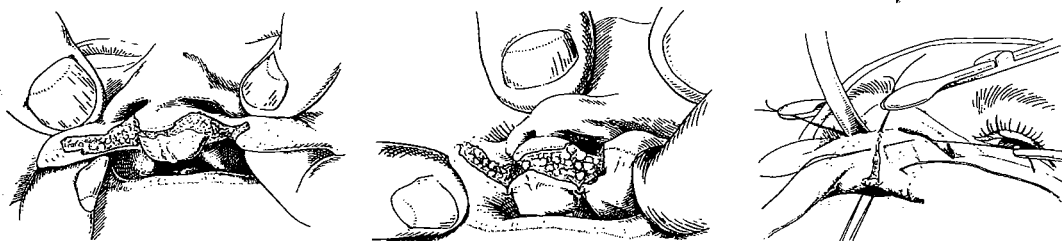
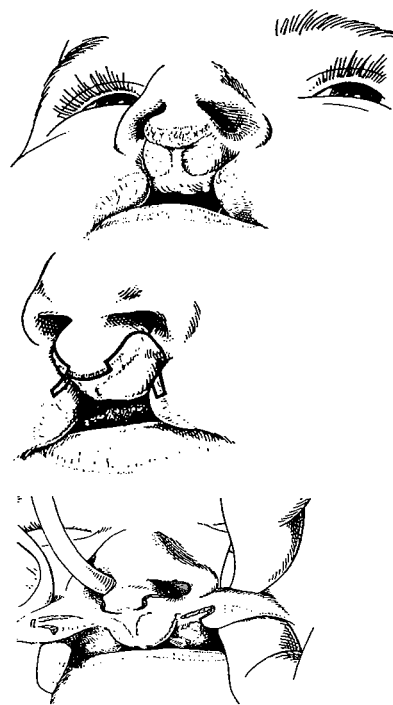


Too few cases were published to allow evaluation of his method, but the principle of his variation has merit. In the past, Federspiel has been maligned unjustly by some surgeons, including myself, as it had been taught that he was a prime advocate of

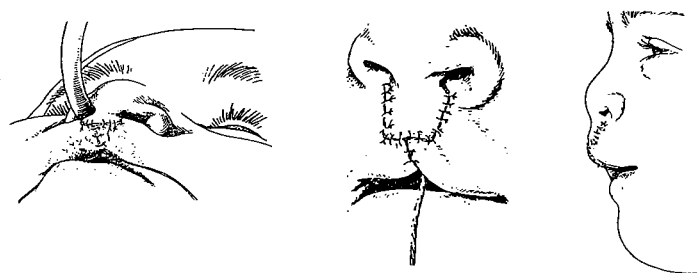
the miserable principle of introducing lateral flaps *including skin* beneath the inferior border of the prolabium. Actually, his flaps were only mucosa, and an apology is herewith offered for this misunderstanding.

### VEAU III

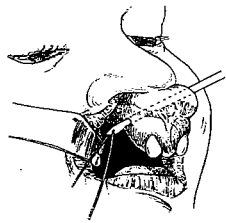
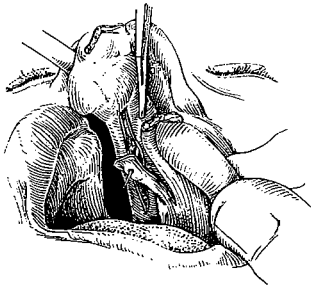
During his time, Victor Veau had a greater influence on lip and palate surgery than any surgeon before him. He was the "big name" among the surgeons who incorporated the entire prolabium as the central vertical component of the upper lip. In his 1938 book, *Bec-de-Lièvre*, Veau described in detail the application of his unilateral closure in bilateral clefts. In the incomplete bilateral cleft he maintained the mucocutaneous junction plus a small cuff of vermilion on the inferior border of the prolabium and brought lateral vermilion flaps together below it. He used a wire retention suture to encompass the muscle of each lateral lip element, passing it through the muscleless prolabium and tying it posteriorly without freeing the prolabium or bringing the muscles together.



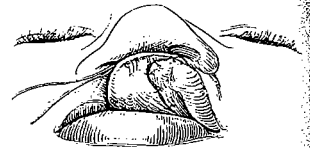
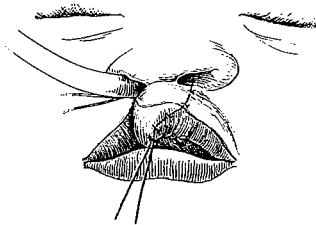
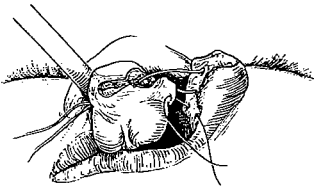
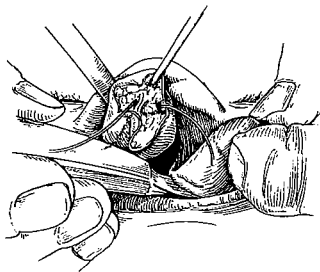
Incorporation of the total prolabium in the lip caused the nasal tip to be dragged down by the short columella.



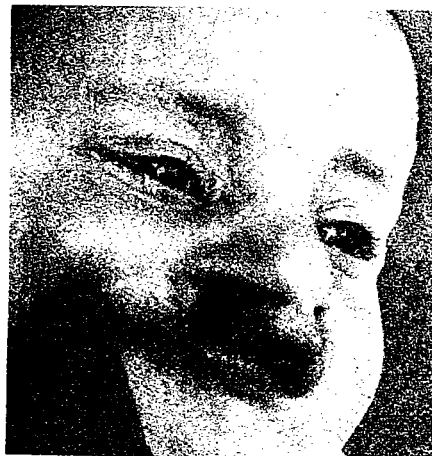In complete bilateral clefts Veau operated first at from two to five months of age and closed one side at that time, including the anterior palate cleft, with his method. This involved turning a



flap off the vomer like the leaf of a book and suturing it to the freed mucosa of the lateral edge, then overlapping this closure with a mucoperiosteal flap for a partial second layer. Three months later he closed the second side. Other points of interest in his method were that he did not section the vomer, he did not free the prolabium from the premaxilla and he placed great emphasis on his "métallique suture musculaire," which passed over the anterior premaxilla, picked up the lateral lip muscle and, when tied, relieved the tension of the closure. Of course, the volume of his cases was fantastic, and the results shown in his book revealed a reasonable lip with an occasional "whistling



deformity." Yet, invariably, the short columella had resulted in an extremely depressed nasal tip.




When I visited him in 1948, I confirmed these same observations.

Here is a similar case treated along the same principle by Milivoj Perko of Zurich. First orthodontia was instituted by Margaret Hotz. Then a Celesnik adhesion of the alveolar area and nasal floors was followed by a second-stage Veau-type lip closure.

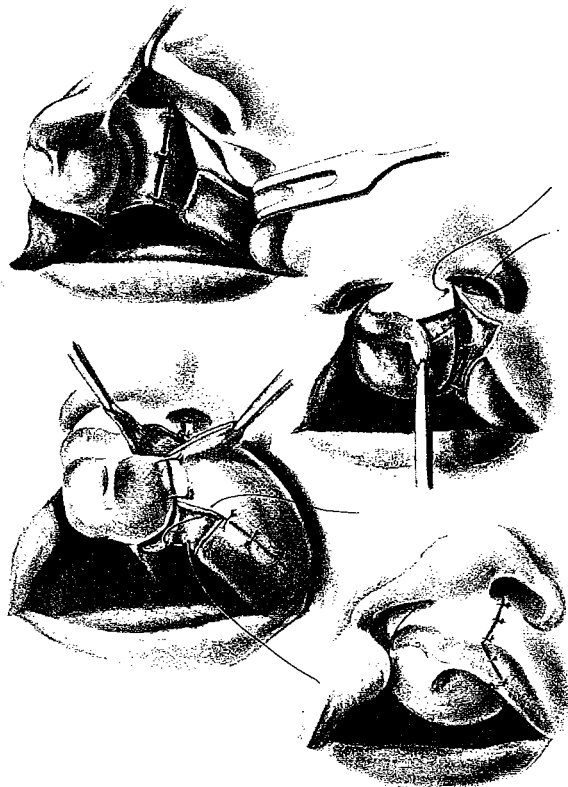


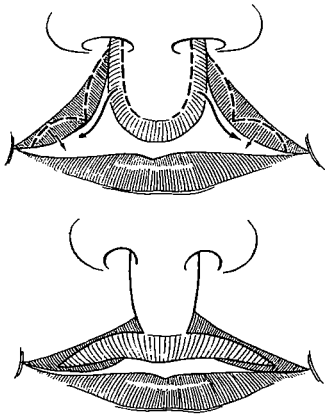
## AXHAUSEN

About the same time, in 1941, the great German surgeon Georg Axhausen also used the entire prolabium for the center of the lip. After sectioning the vomer and retroposing the premaxilla, he closed the lip in one or two stages. His technique emphasized closure of the nasal floor and constructed no upper sulcus by avoiding freeing the prolabium from the premaxilla. He maintained the inferior prolabium vermilion and, in a variation from other methods, conserved as well the lateral prolabial vermilion as flaps based distally which he used to bolster the lateral segments. This bilateral operation gained some popularity in certain parts of Europe.



*Georg Axhausen*





It is interesting that the first to describe this lateral transposition of mucosa from the prolabium was an Englishman named Smith. In the December 28, 1867, *Lancet* Thomas Smith presented a method for bilateral clefts of the lip in which he pared mucosal flaps from the sides of the prolabium based inferiorly and inserted them into mucosal releasing incisions along the lateral lip elements. Rose commented on this approach in 1891:

Evidently it can only be of use where the soft tissues are abundant.



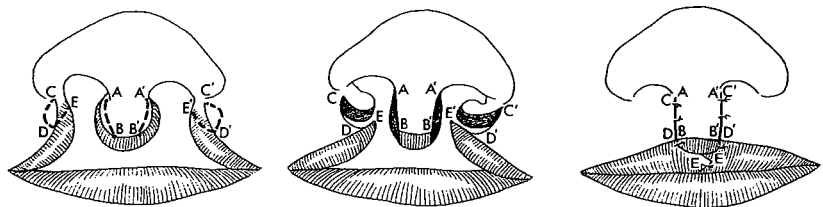
Harold Vaughan

### VAUGHAN

Harold S. Vaughan, who came to the United States from Nova Scotia in 1889, preceded Ivy at the University of Pennsylvania School of Dentistry by two years, received his M.D. from the College of Physicians and Surgeons of Columbia University and lived for an active 93 years. A note to Ivy from Vaughan's granddaughter Catherine is enlightening:

Grandad was a man of genius and eclectic interests. A rugged individualist and Nova Scotian through and through, he succeeded at whatever he undertook—painting, etching, horticulture, the study of business and finance. . . . He understood profoundly the human character. . . . His sense of humor was subtle and extremely teasing. . . . He loved arguing . . . did not believe in idle flattery . . . a very human human being.

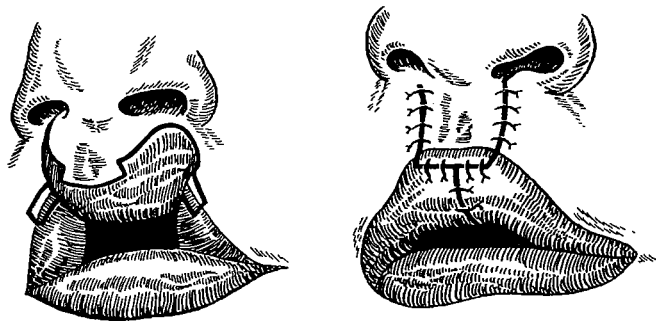
This Harold Vaughan of Columbia University in his 1940 book agreed with G. V. I. Brown and Warren Davis of Philadelphia that the lower prolabium vermilion should form the central border of the lip. His method incorporated the prolabium vermilion in part but overlapped lateral vermilion to fill out the tubercle. This is a general approach that is still popular in many clinics today.





## TERNOVSKY

An early Russian surgeon, S. D. Ternovsky, in the spirit of Veau, Brown and Vaughan included the prolabium, its inferior mucocutaneous junction and a small cuff of vermilion as the central portion of the lip. He brought the vermilion of the lateral lip elements together in the midline below the fringe of prolabium vermilion.



## THROUGH-AND-THROUGH STRAIGHT-LINE CLOSURE

In all of these early bilateral clefts in which the prolabium was used to form the full length of the upper lip a through-and-through straight-line closure was used bilaterally. The scars are unimaginative, unnatural and partly responsible for some of the well-known secondary stigma of bilateral clefts. Yet as late as the early 1970's two plastic surgery giants with impressive bilateral cleft track records have come to opposite conclusions.

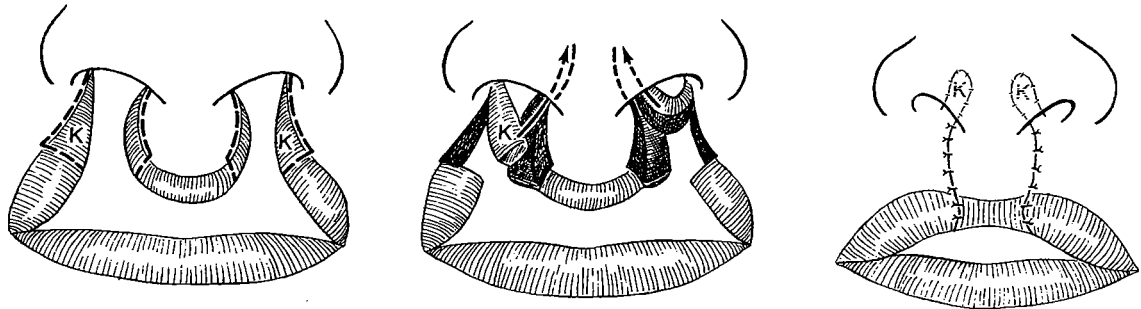
Tom Cronin with Penoff in Texas in 1971 emphatically stated his preference for the Veau III or straight-line closure with preservation of the prolabium ridge, claiming:

It is simple, forms a cupid's bow, and is not difficult to revise. There is a tendency for lack of protrusion of the vermilion border.

Ray Broadbent with Woolf in Utah in 1972 enumerated the disadvantages of the standard straight-line closure:

Additional experience with the straight line repair (20 cases) reaffirmed the old problems of a straight scar—often associated with a grooved nostril floor (presenting the dirty nose appearance), a whistling deformity with an adherent prolabium.

As late as 1974 Donald Kapetansky of Southfield, Michigan, advocated simple, total incorporation of the prolabium in the center of the lip. His one modification was preservation of cleft edge parings, including vermilion and skin, as lateral flaps based superiorly. During the side-to-side approximation of the freshened lateral lip elements to the prolabium these side flaps (L) were inserted bilaterally into a membranous septal incision "to relieve tension of the upper lip."



Kapetansky is not concerned that the result of such an operation will present a short columella, flaring alae, spread prolabium with bulging lateral lip elements, lack of muscle continuity, absence of an upper sulcus, visible preservation of bizarre prolabium vermilion and a whistling deformity.

He is content to wait until five years of age, at which time he advocates his effective muscle transfers by bilateral pendulums followed

with a columella-lengthening procedure and nostril correction, either by Millard flaps or by Cronin nostril-floor pedicles.

#### AN ANATOMICAL ARGUMENT FOR THE PROLABIUM IN THE LIP

The vomeronasal organ was first described by Ruysch in 1703 and finally in 1811 by Jacobson, a Dane, for whom the organ was named. It has been claimed that phylogenetically and embryologically the prolabium represents the rudimentary organ of Jacobson, and, as the latter is part of the nose, the prolabium belongs at the lower septum to aid in the formation of the columella. In New York Stark and Ehrmann proved otherwise when they found, out of six embryos with cleft lip and palate,

only three with the organ of Jacobson, and even in those three it was 1.0 to 1.5 mm. posterior to the cutaneous surface of the lip. Thus the conclusion was that neither prolabium nor premaxilla is the seat of Jacobson's organ in bilateral clefts. Coexistence of a well-defined Jacobson's organ far posterior in the nasal septum to the well-defined prolabium precludes such a possibility, and the absence of the organ in the prolabium of embryos further vitiates the claim. In 1958 Stark with Ehrmann confirmed use of the prolabium in the lip program:

The prolabium is a lip structure. It should be used in its entirety as the central lip element in repair of bilateral cleft lip. If the prolabium alone is used a normal philtrum will develop. If the prolabium is placed onto the nose as columella, the columella will be hirsute in the male, and the lip will be greatly elongated and will develop bereft of its philtrum.

In general principle, use of the prolabium as the central figure of the lip is sound as far as it goes and is the basis of most modern methods today. Yet to insist that it be used in its *entirety* and *only* in the lip and that it form the *total* central vertical portion of the lip is shortsighted! Eventually the columella must be lengthened, and the prolabium, which may be too wide originally or as a "muscleless blob" later stretched too wide, can share in the columella lengthening either primarily or secondarily. Then, too, in order to form the entire vertical length of the lip, the prolabium's inferior vermilion and mucocutaneous junction must be preserved as such and this often leaves much to be desired.