

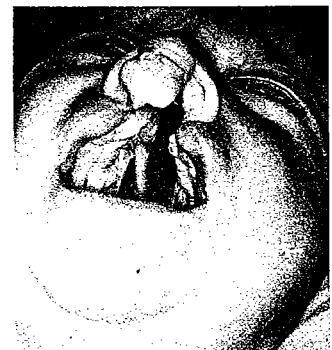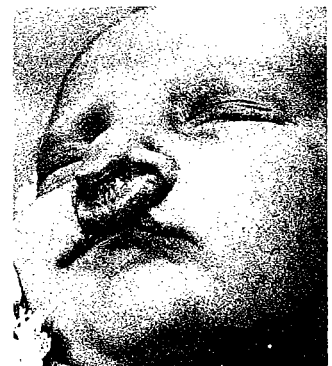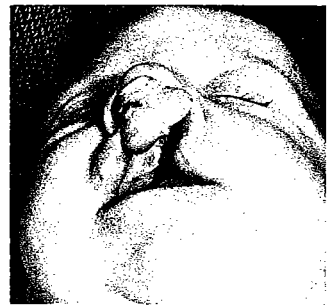3. What "To Do or Not To Do" About the Projecting Premaxilla

H A M L E T, Shakespeare's Prince of Denmark, having lost his father, seen a ghost and discovered a heinous crime, cried out in anguish with what might well become a plastic surgeon's ode to the projecting premaxilla:

The time is out of joint: O cursed spite,
That ever I was born to set it right!
Nay, come, let's go together.

No apologies are offered for the size of this chapter. Without a doubt the ominous shadow cast by the projecting premaxilla over its flanking maxillary segments and the obliteration of this shadow by the ultimate alignment of the "triplet" is the number one problem in cleft lip and palate surgery today. A review of the literature reveals what appears to have been and still is a frantic effort to equalize a giant and two dwarfs of the same age with anything available—mallet, rubber bands, chisel, saw, scalpel, plates, mechanical squeezers, muscles, growth and time. Yet it is essential to know what has been tried in order to know not only what to do and not to do but what is left still to be tried.

In bilateral clefts the position of the premaxilla is the *keystone* to the reconstruction. If it rests within the maxillary arch, closure of the lip clefts offers no great problem. This is the usual situation in incomplete bilateral clefts. In complete bilateral clefts, however, the premaxilla invariably extends in front of the premaxillary elements, and the projection can vary from insig-



nificant to almost insurmountable protrusion often associated with deviation. This projection has been treated in numerous ways over the centuries.

PRIMARY EXCISION

Pierre Franco, a pioneer in cleft lip surgery, was the first to describe discard by primary excision of the projecting premaxilla in bilateral clefts. He also advocated surgical freeing of the lip elements off the maxilla to aid in the closure. In 1556 he wrote:

There is another type of cleft lip which is commonly called hare's tooth because there are teeth which protrude from the mouth in front of the maxilla, sometimes only one, more often two. And sometimes [they are] also accompanied on both sides by clefts of the maxilla. As for the method of treatment . . . when these teeth or mandibles are so large that they cannot be covered, there is no danger in cutting off the excess with a cutting forceps or with a small saw, leaving the flesh over them [prolabium] if there is enough: for it will be possible to sew the margins to it [the prolabium] on each side. And if the distance between the margins was so great that they could not be joined, it would be necessary to use incisions within the mouth [to undermine lip elements from their attachments to the maxilla].

In 1661 Hendrik Van Roonhuzze of Amsterdam advised cutting away with pincers the projecting premaxilla in "hare-mouth" so as to permit suturing of the bilateral cleft lip.

Georges de la Faye of Paris in 1733 removed the projecting premaxilla with scissors which had

long blades and were made like a watchmaker's chisel.

Dupuytren

Guillaume Dupuytren of Paris, known by some as the Napoleon of surgery, was also a pioneer in plastic surgery. He was 130 years ahead of Moyer with nitrate of silver in burns, 20 years ahead of Langer with lines of skin tension, 10 years ahead of Curling with his gastrointestinal ulcer and ahead of almost everyone on the contracture of the palmar aponeurosis. He also enjoyed self-aggrandizement, allowing his name to be attached to a powder to reduce "itch" and an ointment against baldness and even managing to get King Louis XVIII to make him a baron in 1816. Yet even his jealous enemies had to admit he was a hard worker. As Goldwyn noted, Monsieur le Baron would be seen still



Pierre Franco



Guillaume Dupuytren

making rounds on the wards at nine in the evening, "sloppily attired in an old green frock and socks over the tops of his boots," followed by an entourage of students and visitors from all parts of the world.

His contributions in bilateral cleft lip surgery were less remarkable for he showed the same impatience with the projecting premaxilla that he did with a troublesome patient. According to Dupuytren's American student, Jonathan Mason Warren:

If his orders are not immediately obeyed, he makes nothing of striking his patients and abusing them harshly! A favorite practice of his is to make a handle of a man's nose, seizing him by it and pulling him down on his knees, where he remains, half in sorrow, half in anger, until he is allowed to rise and describe his symptoms.

Like many a surgical pioneer, Baron Dupuytren was not only baffled but frustrated by the problem of the projecting premaxilla. By 1829 his exasperation had risen to such an extent that he took hold of this "malpositioned knob" and twisted it off, utilizing the prolabium to construct the columella. He did acknowledge later:

M. Malgaigne . . . thinks that this is liable to objections. The most serious, according to him, is the removal of the germ of two, three or even the four incisors.

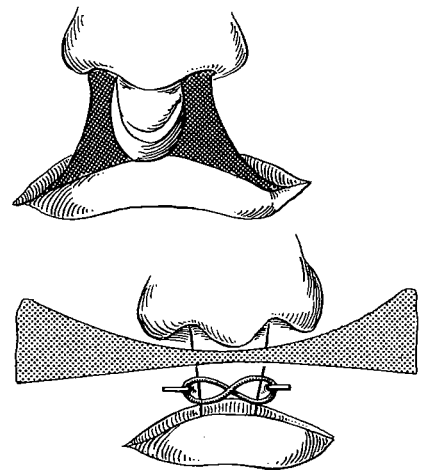
Sims

J. Marion Sims of New York, deservedly better known for his "position" on vesicovaginal fistula than on premaxilla, removed this structure in "a most horrible case of harelip," preserving the prolabium. Thirty-seven days after premaxillary excision, he trimmed the cleft edges and the prolabium with scissors and approximated the wound edges with a single through-and-through needle and with several interrupted sutures which were later reinforced by a type of tape support.

Rose

William Rose of King's College Hospital, London, wrote in 1891:

To my own mind the disadvantages of the retention of the incisive bone so clearly outweigh the *prima-facie* advantages, that in my practice I have



followed the usual course adopted by the majority of British surgeons in removing the bone at the earliest opportunity. By this removal the operation of the lip can be more successfully accomplished, and as regards the profile effect the later introduction of a dental plate with artificial incisors will greatly improve the appearance, and enable the patient to bite in a satisfactory manner, far more so, in fact, than with the mobile os incisivum.

Objection to removal

Yet, as early as the latter part of the eighteenth century, Chorin showed remarkable insight by objecting to the primary excision of the premaxilla. Obviously by observation he recognized that the ultimate result was a tight lip, dish face of the middle third of the face and relative mandibular prognathism. He wrote:

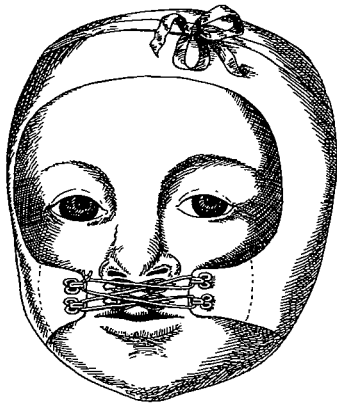
It will leave a considerable space between the maxillary bones; it will deprive the lip of its point of support at the place where it is divided; and if the reunion takes place, in spite of the disadvantages of such an arrangement, the action of the muscles will soon lessen the space between the maxillary bones, and the upper jaw will become contracted enough to fall within the under one, a circumstance which, at the same time that it renders mastication very difficult, will occasion a fresh deformity.

An astute fellow

What Franco, Dupuytren, Sims and others did on purpose and out of desperation, some surgeons do inadvertently. The results are still loss of the premaxilla and a central deformity of the face.

POSTERIOR TRACTION BY VARIOUS TYPES OF EXTRAORAL APPARATUS

Following dissatisfaction with primary excision, ingenious methods of external compression were devised. It seems to have been a tug-of-war between the Germans and the French as to who could tug the hardest on the premaxilla.



In 1686 German Johan Philip Hofman presented a headcap with cheek extensions armed with corset hooks at the sides of the lip. When laced with tension, this apparatus could serve both to press on the premaxilla and to relieve the tension of the bilateral cleft closure.

By 1768 Louis, a French surgeon, blamed the clefts on lack of muscle retraction rather than loss of tissue and advocated "a

uniting bandage" with the aid of a bonnet. Chaussier, another French surgeon, in 1776 designed a cheek compression bandage for cleft lip to obtain a greater number of cures "despite the continuous movements of the little patients."

Desault

In 1790 P. J. Desault devised a rather elaborate cloth compression bandage which he applied against the projecting premaxilla for 11 days preoperatively to exert steady backward pressure. This is a description of Desault's bandage on a five-year-old bilateral cleft lip by his junior surgeon, Chorin:

In order to bring the protuberance to a level with the lip, and to depress the projecting portion of the maxillary bones, M. Desault, who as the principal surgeon of the Hôtel Dieu, Paris, undertook the treatment of the case, had recourse to a linen bandage, which passed over the upper lip and was fixed at the back part of the neck. The good effects of this bandage in compressing the parts in question were so obvious, that its use was continued until the operation was performed.

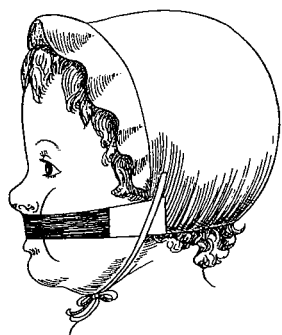
Malgaigne and Hullihen

Malgaigne used a similar type of cloth compression bandage in about 1844. Simon P. Hullihen, American dentist of Wheeling, West Virginia, was another to use external retraction in bilateral clefts, also in 1844. As noted by Robert Goldwyn in *Plastic and Reconstructive Surgery*, September 1973, Hullihen urged "preparatory treatment" in all cases, especially when the lip deformity was accompanied by a "cleft of the alveolar and palatine arches." His initial treatment, like that of Thiersch, was an "adhesive strap" from one cheek to the other, but he advocated cinching it constantly:

The strap should be kept perfectly tense. It is therefore necessary to tighten it every day or two, which may be done by cutting a small portion out of the narrow part, and then sewing it together, without disturbing its adhesion to either cheek. . . . The time generally required to close a cleft of the alveolar arch, depends more upon the age of the infant than upon the size of the cleft. It generally requires from four to six weeks to close the cleft in infants under five months old. . . . As soon as the cleft edges of the alveolar arch are brought together so as to touch each other in the slightest manner, the operation for the cure of the harelip may be properly performed.



The Germans and others



Then the Germans began to tug again. In 1868 Von Bardeleben used a compression bandage with a bonnet as shown. In 1875 Karl Thiersch of Leipzig, better known for his thin split-skin grafts, used rubber bands stuck to the cheeks with an adhesive. This course of events not only reveals the participation of famous general surgeons in the treatment of clefts in the nineteenth century but points out the value of their sound logic turned toward cleft correction in the early days.



Karl Thiersch

By 1892 Von Esmarch and Kowalzig were employing an elastic band attached to a headcap, which is beginning to get quite modern.

The Americans joined the ranks again, and in 1907 oral surgeon G. V. I. Brown used adhesive tape pressure across the premaxilla. Needless to say, the skin did not take this too well. By 1922 Federspiel was using the elastic band, and Cronin advocated it still in 1964.

Hans Derichsweiler, at the 34th Congress of the European Orthodontic Society in Copenhagen, claimed that the bilateral cleft "premaxilla could be fused with the prevomerine segment by extraoral traction alone." This assertion stimulated Merton Griswold and Willis Sage of New Jersey in 1966 to develop an ultramodern bonnet of stout muslin on which a lip traction band made of a woman's Playtex girdle (!) was hooked to exert 8 ounces of tension in babies and up to 14 ounces in older children. The apparatus was applied for six weeks to three months depending on the effect. To offset the maxillary collapse behind the premaxilla, they held the premaxilla in alignment while traction devices attached to the teeth were expanding the arch. With variations this general approach is probably the most popular preoperative treatment in use today.

CONTROLLED FIXED EXTERNAL TRACTION

In 1968 the Duke University Medical Center team of Georgiade, Mladick and Thorne suggested passing two Kirschner wires

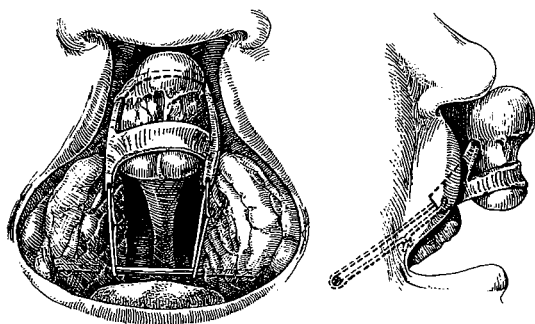
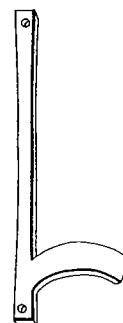
horizontally through the cheeks, one through the premaxilla and the other through the posterior maxilla. The ends of the wires were bent into hooks, and rubber bands were applied to achieve controlled posterior traction. Subsequent experience revealed that wires tended to cut through the soft bone of the premaxilla.

Then in 1970 Nicholas Georgiade, part Greek, part Austrian, armed with dental and medical degrees, cunning and as capable in a casbah as on a college campus, devised a Dacron halter for his controllable traction. I watched him place one on a projecting premaxilla at Duke in 1971.

Five days before closure of the bilateral cleft lip, under local anesthesia, Georgiade passed one 0.054 Kirschner wire through the cheek just distal to the maxilla near its junction with the pterygoid plate of the sphenoid bone and distal to the tooth bud follicles. The wire was thrust across the cleft and through the opposite side of the maxilla until palpable under the cheek skin. A later improvement in his design was the fashioning of a premaxillary halter from a half-inch strip cut from Dacron arterial material. This Dacron strip was split into a lopsided Y with one prong extension several times the length of the other. The longer extension was passed under the prolabium to hug the premaxilla while the wider shorter extension was brought around in front of the premaxilla and fastened by sutures to the other end coming from under the prolabium. Thus the halter was complete, its two bands encompassing the "head and nose" of the premaxilla and leaving the two ends as restraining reins through which standard rubber bands were threaded. The rubber bands were then looped around Georgiade's posterior transverse Kirschner wire exerting the required tension to cause retropositioning of the premaxilla.



Nicholas Georgiade

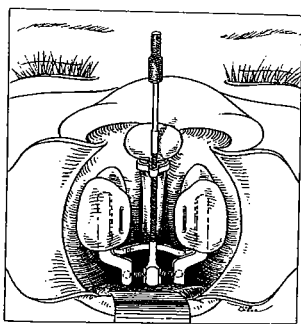


Five days later the clefts of the lip were closed, and the intraoral traction was maintained another two weeks following the lip surgery. This contraction interfered with surgery and was not completely controllable so a better traction device was sought.

The value of a combined dental and surgical effort in the treatment of clefts is not new to Nicholas Georgiade, who nearly 30 years ago, having completed dental school and oral surgery training at Kings County, started medical school at Duke University. During the summer and holidays he joined the team of Dunning and McCaffrey in New York City. Henry Dunning, M.D., D.D.S., was a charter member of the Board of Plastic Surgery, and McCaffrey, D.D.S., was an ex-all-American football player from Fordham. Georgiade, who fitted into this team well as he was a medical student and had played a little football at Fordham, found himself involved in the surgical treatment of two to three lip and palate clefts a day.

Duke-Carolina game

So important are the premaxillary and other cleft problems that arch-antagonists have buried gridiron rivalries and joined oral and plastic forces against a common enemy, the projecting premaxilla. Georgiade of Duke and Latham of Carolina have developed what they refer to as the Mark III coaxial arch alignment appliance, with two concentric knobs protruding from the mouth, one for arch expansion and the other for premaxillary retraction. The expansion component is composed of a prosthesis fitted on each maxillary element and pinned in position with a cross wire attached to a gearbox so that a turn of the thumbscrews spreads the segments of the maxillary arch apart. The retraction component is a saddle attachment straddling the anterior vomer and fixed with a pin through the area posterior to the dentition of the premaxilla. This attachment is operated through a hollow tube by a screw device passing posterior to a gearbox (jackscrew) on the center of the cross wire of the prosthesis. One millimeter of posterior movement of the premaxilla is achieved by every turn of this second thumbscrew, and a turn in the morning and



Mark III

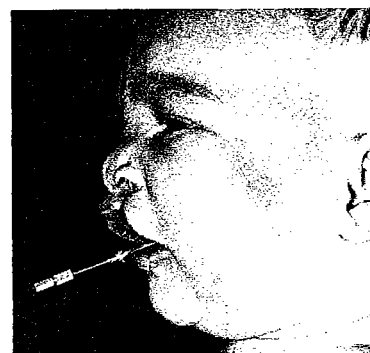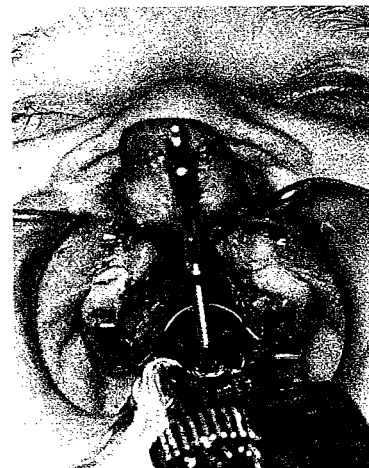
evening gains 2 mm. a day theoretically. Actually there are two to three days with no evidence of change, but the cumulative effect by four to five days begins to show measurable reduction in the distance between the premaxilla and the maxillae. In addition, the vomer, rather than deviating or anteflexing, seems to telescope at the prevomerine suture line with actual bulging in this area. In 9 to 10 days the premaxilla is close enough into the maxillary arch for Georgiade to remove the prosthesis and accomplish a gingivoplasty using alveolar edge mucoperiosteum for his nasal layer and labial-buccal mucoperiosteum for his oral closure. At the same time he accomplishes his bilateral straight-line lip closure, described in Chapter 8.

In 1974 Georgiade sent me photos of an infant with his apparatus in action showing the retropositioning within a period of nine days. He wrote:

I am not sure we have all the answers yet as to how to handle the premaxilla but certainly when I review my past 25 years of experience in dealing with these infants, who received the best treatment according to our standard, and who are now adults with collapsed maxillae, and flat upper lips, I cannot help but hope that we have learned something. . . . I certainly believe this rather simple appliance . . . must be a step in the right direction to prevent those horrible maxillary deformities. . . . Certainly this method of expanding the maxillary segments is a lot better than what the orthodontists have tried to force us to use with oral appliances that had to be turned in a screaming unhappy infant. The use of the cumbersome McNeil technique is not even in the same ball park as this simple apparatus.

Latham wrote me on June 15, 1973:

Dr. Georgiade and I are satisfied with the cable-screw premaxillary retractors and the gear controlled expansion appliance as used in a bilateral cleft infant at Duke University Medical Center last week. Dr. Georgiade managed to do the gingivoperiosteoplasty as well as the lip although vertical relationships were poor. The anterior ends of the maxillary segments will have to be controlled in the vertical plane as well as in the horizontal—i.e. the usual expansion-collapse problem. . . . I hope that it will soon be accepted that an effort should be made to close the alveolo-gingival cleft at the same time as lip closure.



*Neck Georgiade
has promised
to send me
a Mark III
and Berkowitz
will be
challenged
to try it.*

By late October 1973 Latham reported:

We have now used this appliance three times with considerable success. In all three, to my great satisfaction, an attempt was made to put downward traction on the maxillary segments. This worked well on the first and not so well on the other two—but I'm dealing with some of the difficulties and I'm sure this is going to be a big part of the treatment.

Latham's reasoning:

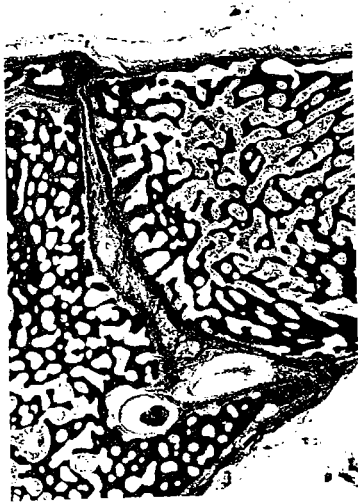As the brain grows the cranial vault sutures are put under tension and osteogenesis occurs as required. You have two sutural surfaces separating and new growth occurring to keep the bone edges the same distance apart—say 0.2 mm. . . . In my work toward a Ph.D. in Liverpool in 1966 I found that in the rapidly growing facial skeleton of the fetus osteogenesis was not a feature of the sutures around the maxilla. It was obvious that at that time skull growth was most rapid. Then I came to what I regard as my most important observation: the bones were sliding past one another at the sutures, they were aligned in the direction of bone movement and bone formation was not necessary for this movement. The factor that would control such sliding would be the adjustment of the collagen fibres holding the bones together at the joint. It seems that such adjustment of the collagen fibres interlacing across the suture could allow much more rapid movement of the bones than if such movement were dependent upon the rate of bone deposition at a separating suture. Think of the continuously erupting incisor tooth of the rodent. The tooth is moving or sliding out of the socket all the time, while collagen peridontal ligament adjusts in the intermediate plexus where the fibres from the bone and tooth divide into a fine intermeshing network. Put the palms of your hands together with elbows outward. Now slide one hand over the other with elbows moving out. The hands may move in opposite directions for a great distance before contact at the inter-palmar surface is lost. Now to maintain that contact growth needs only occur at the finger tips. Such is the economy of bone formation in the rapidly growing skull.

Here is a coronal section of the zygomatic-maxillary suture from a three-week-postnatal infant offered by Latham to demonstrate the five layers which he says are indicative of the suture adjustment mechanism.

He noted:

The suture uniting the two bones shows five tissue layers: The periosteal, osteogenic and fibrous capsular layers of each bone respectively with a

Maxilla



Zygomatic bone

middle loose vascular layer. The collagen fibers of the capsular layers are oriented mainly parallel to the bone margins and this facilitates the movement of one bone in relation to the other since adjustments occur mainly in the middle zone and at the periphery of the suture where uniting layers of fibers pass directly from one bone territory to the other.

Latham adds:

This means that sliding is a normal mechanism between two bone surfaces and this is what is being required of the vomero-premaxillary suture as retraction force is placed on the premaxillae. So we have to exploit this mechanism, work within its limitations. And that's mainly why I didn't like Dr. Georgiade's rubber bands. The screw mechanism allows us to do this job in a series of steps; at each step we would push the collagen as far as it would adjust and stretch within the bounds of normal physiology.

Maybe you will begin to see why I am keen to put the maxillary segments exactly where we want them, because I'm confident that they will move—when given some reason to move!

Latham and Workman in the 1974 *Symposium on Management of Cleft Lip and Palate and Associated Deformities* further justified the Mark III positioning of the premaxilla by rapid compression:

The columella cartilages are covered and obscured by the alveolar process of the premaxillary segment. The position of the medial crura is probably correct and should be preserved. The close relationship between the medial crura and the bony alveolar process is one of gradual acquired approximation. They are not firmly united one to the other and may be readily separated by posterior traction. The premaxillary segment may be moved to

a more normal position, at the same time uncovering the columella cartilages. . . . It is to be hoped that this rationale will tend toward the manifestation of normal relationships and appearances in the lip and columellar region with later growth.

Finally in July 1975, Georgiade and Latham again promoted their pinned coaxial screw appliance.

Because the protruded premaxillary segment may be retracted rapidly in 7 to 10 days, and this may be scheduled at the same time as lip surgery, orthopedic management of this formidable malformation is now practical and, therefore, available to all such infants as a routine procedure.

SIMPLE EARLY CLOSURE OF LIP CLEFTS TO SERVE AS MOLDING ACTION

The reconstitution of the normal restraining muscle band gives satisfaction in a good percentage of cases. In fact, when the premaxilla, in addition to the projection, is rotated to one side, the closure can be staged to advantage. By closing the lip cleft across the widest gap, one can pull the premaxilla into a straight position in preparation for lip closure on the second side. DeHaan admitted, in Stark's 1968 *Cleft Palate*, that surgeons disagree on whether the premaxilla should be recessed primarily but concluded:

We have not found the prominent premaxilla a serious problem; once the lip is closed it usually exerts sufficient pressure for the desired retrodisplacement. We feel that operative recession of the premaxilla may well interfere with growth of the central third of the face.

Bauer, Trusler and Tondra in Indiana in 1959 and Glover and Newcomb in Ohio in 1961, all as a result of long-term reviews, decided against surgical setback of the premaxilla as their best results were with simple soft tissue closure.

As early as 1954, there appeared an interesting report. Slaughter of Loyola University and the University of Wisconsin, and Pruzansky of the University of Illinois College of Dentistry realized the importance of muscle closure across the cleft.

Accompanying the cleft lip repair is the simultaneous reestablishment of the prime function of the orbicularis oris muscle—that of a sphincter-like action, plus the accompanying changes of the accessory muscles of the immediate vicinity. This is the prime motivating force responsible for favorable reconfiguration of the bony skeleton of the middle one-third of the face.

Slaughter and Pruzansky's main theme was that the surgery should not be allowed to have an adverse effect on the future growth patterns. They acknowledged:

Since the cosmetic results immediately following repair of the bilateral lip cleft may be less than desired, it is significant to note that serial studies have indicated that the differential processes of facial growth tend to minimize the deformity and provide a more desired end result. In some children such spontaneous correction of the premaxillary protrusion may occur rather early and in others at a later age. Of course, there are rare exceptions in which there is no such improvement in facial profile. In such instances section of a portion of the nasal septum may be required but only as a last resort . . . and based on documented serial observation (cephalometric roentgenograph) over a period of at least five to six years.

In 1972, from the Center for Craniofacial Anomalies at the University of Illinois Medical Center, Hans Friede, D.D.S., and Samuel Pruzansky, D.D.S., summed it up with cephalometric radiographs and dental models in a longitudinal study of 54 complete bilateral cleft lip and palate cases. Their conclusions were:

1. The common denominator that characterizes this cleft is the marked protrusion of the premaxilla, resulting from an overgrowth at the premaxillary-vomerine junction.
2. Considerable in-group variation existed, in the extent to which the premaxilla protruded ahead of the palatal shelves.
3. The degree of premaxillary protrusion first observed in the unoperated infant is a useful prognostic indicator of later changes in his profile.
4. In cases operated by closure of the lip without premaxillary setback, the facial profile approximated the averages for the non-cleft population by the time the children reached early adolescence.

5. The amount and direction of mandibular growth is a significant factor in the ultimate improvement of the facial profile.

Twelve years after their switch from surgical setback Bauer, Trusler and Tondra reported candidly in 1971:

Surgical retropositioning of the premaxilla in our hands has consistently resulted in severe growth disturbance of the middle third of the face. Since excellent results with surgical retropositioning of the premaxilla in selected cases have been reported by Cronin and Monroe, it may be assumed that our technique was in error. If the lip is repaired in two stages, it is our belief that surgical retroposition is unnecessary. The motor force of the repaired lip will eventually bring the premaxilla into proper relationship with the mandible. Recent articles on this subject by Berkeley, Glover and Skoog have been in agreement with this approach.

It is interesting that the Indiana group closed the first side at *two weeks* of age and the second side two months later.

Skoog of Sweden in the same 1971 tome summarized:

Surgical correction of bilateral clefts is accomplished by operating upon one side at a time, the first operation being done at the age of 3 months. . . . In asymmetrical deformities the most severe cleft is repaired first. Three months later the other side is operated upon.



Tommy Kilner

EXCISION OF THE PREMAXILLA SECONDARILY

Professor Kilner of Oxford closed the lip of his bilateral clefts in two stages, trusting the pull of the united muscle to reduce the prominence of the premaxilla. Actually this muscle pull was responsible for the swinging in of the maxillary processes which trapped the premaxilla in front of the alveolar arch and necessitated its removal in about 90 percent of cases. He did not approve of a wedge osteotomy of the septum, explaining that it was dangerous to the growth of the premaxilla, which he preferred to maintain as a lip rack during facial development. At the age of five to seven years, however, if it was wobbly and useless, he removed it and substituted a denture.

A PARTIAL PREMAXILLARY EXCISION

In 1957 a compromise was suggested by Gillies, who was familiar with the premaxilla, which often fails to gain union and becomes a wobbly prow with abnormal teeth deserving discard. He posed the possibility that

the anterior mucous membrane be peeled back from the premaxilla and the anterior bone and tooth-buds be rongereured away. This leaves a posterior strip of bone sandwiched between two layers of mucosa. If this bone strip is now moved back and introduced snugly into the cleft, the edges of which have been freshened to bone, there is the better chance of bony union across the gap and preservation of the full arch.

In 1968 in the *British Journal of Plastic Surgery* John Potter explained his change to a more radical handling of the premaxilla somewhat like that of Gillies. In 1959 he had been faced with twins each having bilateral clefts of the lip and palate. In the girl he had used the standard closure over the projecting premaxilla, retaining the prolabium in the lip. The boy twin, who had developed a tumor of the premaxilla in the first few weeks of life, underwent excision of the tumor. A pathological report by Professor R. Willis is of interest:

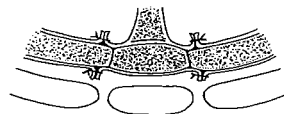
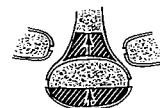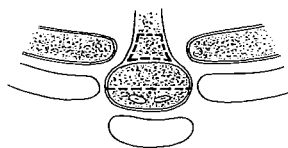
This is a typical specimen of the pigmented epulis of infancy. The upper incisor region is its commonest site; but your specimen is of special interest in that it came from this site in a case of cleft palate. In spite of its extent and infiltration, it is essentially a benign lesion, which is readily cured by local excision and which has not metastasized in any of the reported cases.

Subsequent surgery involved a two-stage union of the lip to prolabium. The result of this forced reduction of the anterior premaxilla impressed Potter with its better nasal tip, columella and lip. In fact the twins' mother remarked that she wished the girl had had this type of repair instead of the boy! After three years' observation, Potter decided:

It was worth making further efforts in an attempt to obtain a better nasal tip at the original repair.

In fact, 14 years later he was still pleased with the nasal tip.

In 1968 he presented a report on the twins and a third case



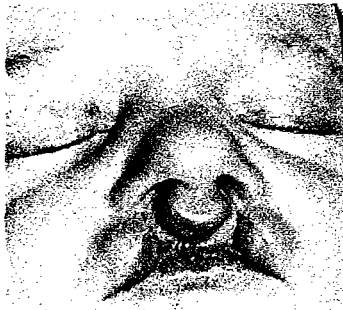1959



1973



1973

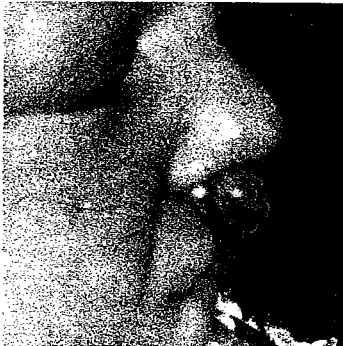

which was handled in a manner greatly influenced by his experience with the twins. He started out:

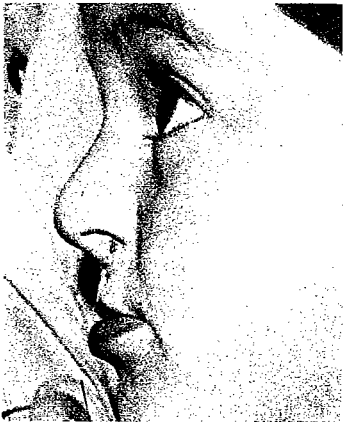The problem is that before the repair there exists a flattened nasal tip with a short columella and wide nostrils, because the pre-maxilla bulges into the nostrils.

He then explained that no matter what the surgery this condition "leads to obstruction of the airway and a chronic catarrh." His surgery involved elevating the premaxillary mucosa, and he continued:

The anterior plate of the premaxilla was exposed and removed in the upper two-thirds, the tooth sacs were removed, the central septum was leveled back, in order to get it into what was thought to be its normal relationship with the nasal spine. . . . The soft tissues were allowed to settle for eight weeks and then the floor of the nose and the lip were repaired in one stage. . . . The procedure gave a good nasal tip, a good airway, and no chronic nasal discharge. The lip is good but may need an Abbe flap.

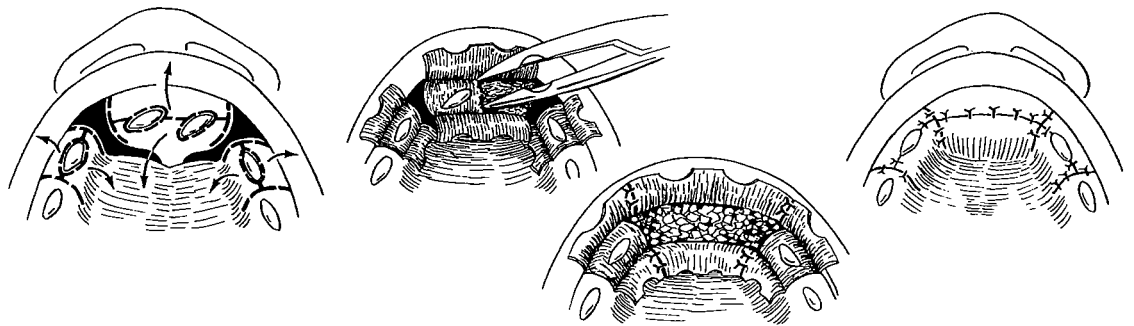


Potter mentioned loss of the upper incisor teeth, and three years later the profile was already showing definite retroposition of the premaxillary area. He did use a small Abbe flap eventually. In 1974 Potter wrote:



I have a new case to begin and I hope to save the teeth.

A secondary rendition of this rather radical approach was presented in 1973 at Duke University by Frank Masters of Kansas City and published with D. B. Apfelberg in 1974. When the premaxilla is otherwise useless because of malposition, mucoperiosteal flaps of the premaxilla and maxillae are opened on each side of the clefts and sutured together to form one long trough into which bone from the premaxilla is packed as cancellous



chips. Then the flaps are closed to form a reduced alveolar ridge on which a dental plate can be fitted.

PROSTHODONTIC ASSISTANCE

It was the experience of lip closure followed by maxillary arch collapse that led to the 1954 work of C. Kerr McNeil, who advocated delicate but continuous forces to influence the direction of the growing bone. Burston soon joined these forces. They proposed as an ideal approach

the prosthodontic techniques of early stimulation of the maxillae by a changing prosthesis until they are in alignment with the protruding premaxilla and thus alleviate the necessity to section the vomer.

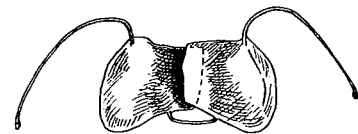
The elaborate setup that Burston has in his anatomy department in Liverpool cannot be duplicated many places in the world. Thus, Hagerty and Mylin improvised pinning in a screw plate which, if fitted in the early days of life, can be maintained with relative ease and can have a great influence in positioning the maxillary elements. The jutting premaxilla still poses a problem.

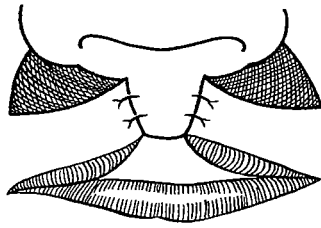
Spring plate and rubber band

In 1967 William M. Manchester of Middlemore Hospital in Auckland, New Zealand, in his typical direct manner crowned the bilateral cleft the most difficult modern surgical problem, not excluding cardiac surgery, and blamed the premaxillary protrusion on lack of muscle restraint and abnormal tongue pressure. To combat this deformity he enlisted the services of orthodontist J. H. Peat, who developed an upper dental plate divided in two halves joined by a spring. The plate has two segments which overlap each other so that when the apparatus spreads, under its own slight spring tension, there is still an effective roof to the mouth. This plate is used in conjunction with rubber band traction and prevents the tongue from counteraction. After five months in a case with a protruding premaxilla, "the alveolar arch forms a continuous horseshoe and the premaxilla is acting as a stable keystone between the maxillary segments."



Kerr McNeil





LIP ADHESION

In a frantic attempt to obtain some kind of closure over the projecting premaxilla in bilateral clefts, Simon in 1864 cut two lateral cheek flaps, transposed and sutured them to the sides of the prolabium in what was probably one of the first adhesion procedures ever done. Once the pull of the flaps had partially repositioned the premaxilla, Simon proceeded with his second-stage definitive lip closure.

The next examples of adhesions were more sophisticated. In 1955 Johanson of Göteborg used a type of adhesion to create a tissue bridge for the insertion of bone grafts. By 1958 I was using early lateral vermilion attached to the inferior prolabium for blood supply to that component, but in the process, of course, some premaxillary molding occurred. By 1961 Johanson had become suspicious of primary bone grafting but intrigued by the beneficial effect of the early adhesion. In 1963, encouraged by the effect of the early adhesion in bilateral clefts, I used a high mucosal adhesion in a severe cleft specifically as a stalling tactic and a molding device. My report was published with other refinements in 1964.

In 1965 Randall advocated a modification of this adhesion with more sacrifice of lip skin expendable only in his type of cleft lip closure. Takahashi of Tokyo in 1970 diagramed both the "Millard" and the Randall adhesions and published some interesting bilateral cases in which he had used lip adhesion procedures in two stages prior to a forked flap columella lengthening.

In 1971 Hamilton, Graham and Randall reported the "lip adhesion" in 14 complete bilateral clefts and on the complete cleft side in four cases with the incomplete cleft on the opposite side. In the complete clefts one side was joined at a time and at the average of 3.5 months of age, the opposite side being joined about 1.2 months later. The adhesions were maintained for approximately six months, and then a definitive lip closure was performed.

A few extracts from Randall and Graham summarize their use of the adhesion procedure:

Broad-based rectangular flaps [were] constructed from tissue that is ordinarily discarded. . . . Extraoral traction on protruding premaxillae has not

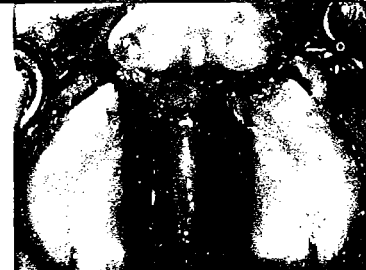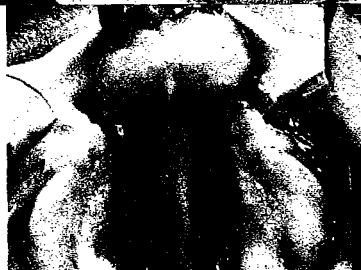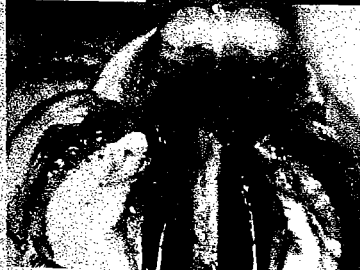been necessary. Osteotomy to reposition a protruding premaxilla has seldom been needed. Any lateral soft tissue undermining has been rare and minimal. . . . For two years the lip adhesion operation has been carried out on all complete unilateral and bilateral clefts at the Children's Hospital of Philadelphia. . . . When considerable separation of the lip margins is present, particularly when associated with bony distortion . . . the operation seems to have merit.

Finally, in 1973 Randall incorporated early columella lengthening with a primary forked flap during one side of an adhesion procedure at three months and three months later created an adhesion on the other side of the lip.

Highest

A variety of adhesions have been advocated over the past 20 years. In 1962 Celesnik of Ljubljana proposed simple closure high up in the nasal floor on each side as a first stage. This approach was presented in Copenhagen in 1973 by his previous student M. Perko of Zurich. After orthodontist Margaret Hotz creates alignment of parts, Perko makes a Celesnik I nasal floor adhesion at six months and one month later carries out a bilateral Veau or Manchester definitive lip closure. Here is one of their cases followed through an impressive orthodontic and adhesion staged premaxillary alignment, later published in the 1975 *Scandinavian Journal of Plastic and Reconstructive Surgery*.

with orthodontia like this, who needs adhesions?



Pre-everything

Postorthodontia

Postadhesion

Lowest

Since 1967 K. Hollmann of Austria, in a desire to avoid the chances of maxillary growth retardation by mucoperiosteal dissection, has been carrying out a one-stage inferior lip adhesion almost identical to the one I used for several cases beginning in 1958. Hollmann attaches mucosal flaps from the cleft edges of the lateral lip elements to the inferior prolabium vermillion. His variation is a tucking of the tips of the lateral flaps under the central prolabium rather than overlapping it. He postpones his definitive lip closure until two years of age.

Personally, since my earliest cases I have not been particularly interested in using the adhesion procedure for traction in bilateral clefts. Usually there is not the problem of asymmetry—in which I find an adhesion most beneficially equalizing. The definitive lip surgery is relatively easy as soon as the rubber band traction has adjusted the premaxilla. I prefer to skip the adhesion and close both clefts in one operation. In those rare cases in which the rubber band is ineffectual, I would favor a bilateral mucosal flap adhesion to a surgical setback.

Two-stage adhesion without undermining

In 1966 Walker, Collito, Mancusi-Ungaro and Meijer of East Orange, New Jersey, advocated the ultraconservative combination of elastic extraoral traction followed by lip closure without undermining:

In effect, the elastic band substitutes for an intact lip and creates the antagonistic forces of a normal orbicularis oris muscle. In the absence of lip surgery and intraoral appliances, elastic traction decreases the severity of the lip and palate defects. . . . Thus, the bony foundation is established for lip closure with minimal or *no* undermining of the soft tissue.

They feel that undermining the lip elements from their attachments to the maxilla changes the muscle environment and that the scarring produced is deleterious to the growth of young bone. A far greater number of surgeons seem to be concerned for the freeing of the abnormal attachments of the muscles so that the tension of lip closure will be reduced.

In 1971 Dutchman Robby Meijer of the Peer Group and dentist Michael Collito of East Orange, New Jersey, reported on



Robby Meijer

a five-year follow-up of the use of the C-W technique with a series of 20 unselected, consecutively treated cases. The preliminary lip adhesion was carried out from two days to over five and one-half months of age, while the definitive lip closure was completed between ages two months and one and one-half years. The original alveolar gap averaged 10.2 mm., but following the adhesion alveolar process approximation with contact occurred in 65 percent of the cases. The remaining 35 percent showed approximation without contact. In no instance was there overlapping of the segments. Comparison of these results with those published in 1964 by Pruzansky is of interest. The latter found 42.4 percent achieving favorable approximation without contact and 39.5 percent showing overlapping of the segments or collapse. As noted by Meijer and Collito:

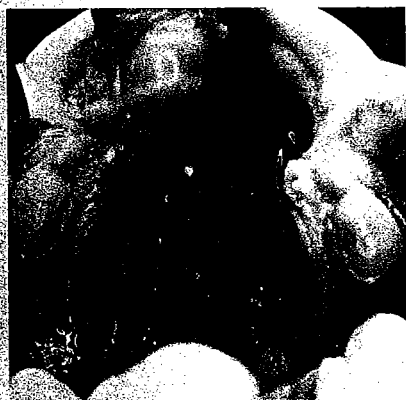Of special significance, however, is that in our group all cases continued developing into a favorable arch form while 60 percent of the Pruzansky cases deteriorated.

Here is a case sent by Meijer in 1974 which had a preliminary lip closure on the right 3-19-65 and on the left 6-23-65. A definitive lip closure was done on the right 11-5-65 and on the left 12-21-65. The soft palate was closed 6-1-66.

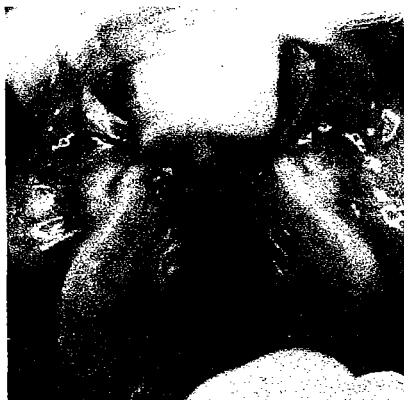

Michael Collito

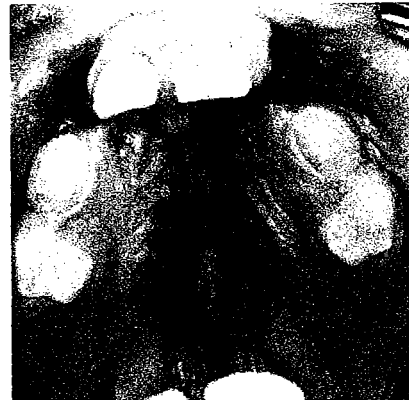that's 4 lip operations but no undermining



Original
3-19-65



After preliminary surgery
11-5-65



After definitive surgery
6-29-67

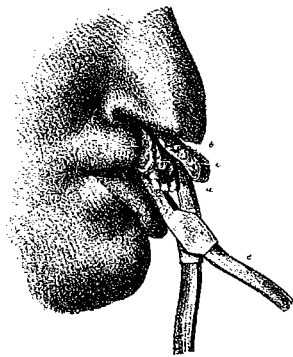
SHORTENING THE SEPTOVOMERINE STALK

Compression fracture

In 1833 Gensoul in Paris is reported to have seized the projecting premaxilla with a strong forceps and forced it back with sufficient

strength to fracture the vomer.

In 1844 Pancoast of Philadelphia illustrated his method of positioning the premaxilla. He explained his sketch in the following manner:

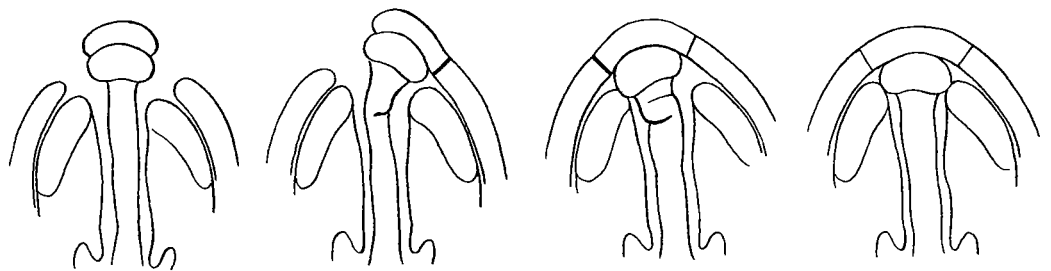


This represents the forcing backwards with a pair of flat-bladed forceps of the prominent portion of the jaw, in which the two incisor teeth are lodged. This attempt to bring the teeth down to their proper level is commonly attended with slight fracture of the bone.

In 1961 Cyril O. Innis, off in North Borneo and faced with two projecting premaxillae in nine-year-old Chinese children, revived the idea of compression fracture of the vomer. He then wedged the mobile unit back between the lateral alveolar segments and closed the lip on both sides using no further fixation. He concluded:

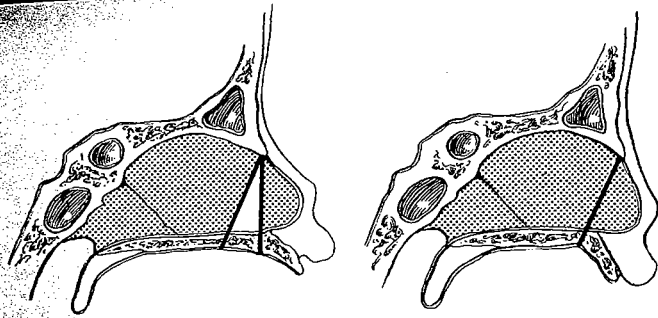
This method has, I feel, the advantage of simplicity [agreed]. There is minimal disturbance with growth centres of the premaxilla [?]. . . . The disadvantage probably lies in that by this method, obstruction of the nasal airway might result and it is difficult to correct excessive downward displacement in relation to the rest of the alveolar arch of the premaxilla.

According to Fomon, about 1873 Drachter was nicking the neck of the premaxilla, forcing the bone into contact with the alveolus and repairing the corresponding side of the lip. At the second stage he repeated the process on the opposite side. This maneuver not only tilted the fragment backward, causing the teeth to erupt lingually, but displaced the septum backward, flattening the alae and retracting the columella.



Full-thickness resection of vomer

In 1842 Blandin retroposed the protruding premaxilla by resect-



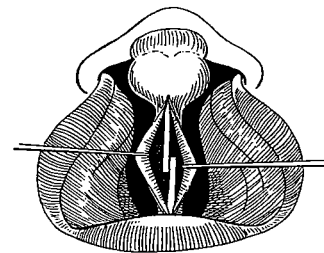
ing a triangular piece of vomer bone and mucosa in a rather unsophisticated setback.

Subperiosteal section of vomer

Adolf Von Bardeleben of Germany was the first to section the vomer subperiosteally, in 1865. Through a 1 cm. incision along the free border of the vomer behind the premaxilla the mucoperiosteum was elevated on both sides so that scissor section of the septum as high up as possible allowed the sectioned septal ends to glide past each other without buckling as the premaxilla was repositioned. There have been many modifications of this design but Von Bardeleben's approach remains the basis of the operations in use today.



Adolf Von Bardeleben



Another backward overlap


John F. Binnie of Kansas City, Missouri, in his 1916 edition (the seventh) of *Operative Surgery* noted:

Some surgeons advise that the misplaced intermaxillary bone be entirely removed. . . . Undoubtedly it is wise to retain the bone and replace it in its proper position. . . . Sometimes instead of excising a wedge from the septum it is sufficient to make a vertical cut through it and slide that portion of the septum anterior to the cut back alongside the posterior portion.



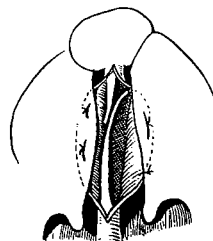
John Binnie

Binnie used a drawing from Von Esmarch and Kowalzig to demonstrate this method of overlapping the septum.



Pichler

In 1918 H. Pichler of Austria dissected the mucoperiosteum from the vomer, divided the denuded vomer 2 cm. behind the premaxilla and, during the premaxillary setback, slid the septal fragments side by side. Instead of closing the mucoperiosteum over the sectioned and overlapping septum, Pichler ingeniously



turned these flaps laterally and tucked them under the palatal mucoperiosteum which he had elevated from the hard palate.

Federspiel

Matthew N. Federspiel, Professor of Oral Surgery and Orthodontics at Marquette University in Milwaukee in 1927, described a variation of premaxillary "set-back." He freshened the edges of the alveolar cleft, then through a longitudinal incision in the mucoperiosteum over the vomer achieved an oblique sectioning



of the vomer so that with a slide back there was overlapping but reduction in premaxillary protrusion.

Vaughan

Vaughan described a similar method of premaxillary positioning in 1946. Through a submucosal dissection, beginning 1.5 cm. posterior to the premaxilla, an oblique section of the vomer was achieved with a chisel. This cut was extended upward into the cartilaginous septum in an area where the premaxillary blood supply was in no danger. The premaxilla was then slid posteriorly and overlapped without rotation on its transverse axis and without blocking the nasal passages. The vomer overlap was fixed with a silver suture and the mucosa closed.

Schultz

In 1946 Louis Schultz of Chicago set back the premaxilla and mentioned the numerous problems faced, such as time involved, lip scarring from tension, lack of bony union, fistulae and poor bite if setback was not done.

All these undesirable factors are avoided if the intermaxillary bone is brought to its normal position when the child is about one month old.

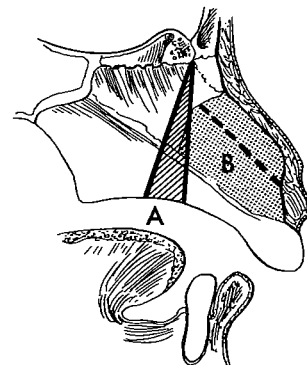
He suggested two ways to mobilize the premaxilla, one by V resection of the vomer and the other by diagonal sectioning and

sliding of one vomer segment over the other in a manner described originally by Federspiel and by Vaughan only two months before his own presentation.

Subperiosteal resection of the vomer


In 1868 Guerin retroposed the premaxilla by subperiosteal resection of a triangle of vomer bone combining the principles of Blandin and Von Bardeleben.

In 1911 Reich supplemented the vertical wedge resection of the vomer (A) with horizontal septal cartilage division (B) to reduce the premaxillary prominence but at the same time prevent septal and nasal tip collapse and avoid what he referred to as "a blunt and bull dog nose." This general approach is similar to what Cronin advocated later.



Veau

In 1922 Veau described resection of the neck of the premaxilla as a prelude to displacement of the bone, "as one would close a drawer." To promote union at the alveolus, the bone ends were freshened and sutures were used for stabilization.



Yet in 1938 Veau reviewed 208 cases of bilateral clefts which he had treated surgically in different ways and decided against operation on the premaxillary prominence.

Veau's final feelings are expressed more poignantly in French, I guess:

Le malheur de cette chirurgie est que nous ne pouvons tirer un enseignement de notre operation que plusieurs années après l'avoir pratiquée.

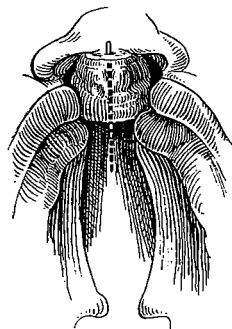
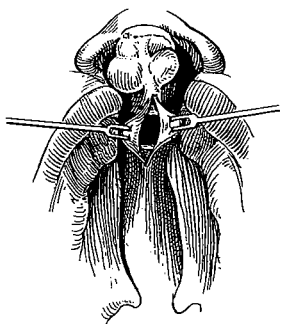
second thoughts!

St. Louis soundness

Most surgeons today still agree with the wise words of Brown, McDowell and Byars of 1947:

Briefly, the problem of the premaxilla is that it is nearly always too far forward in the newborn baby, but only with considerable effort can it be kept from being retruded too far backward in the adult.

They set forth a sound plan:



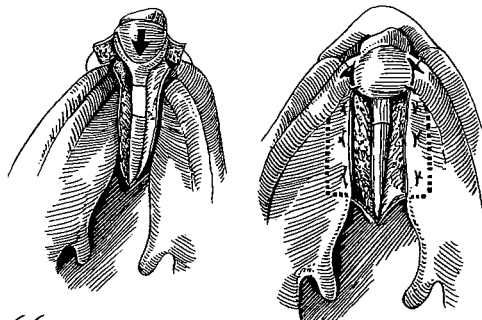
As a rule, the premaxilla is not disturbed or set back if the lip can be closed with it in its original position unless: (a) it is badly tilted or rotated or (b) it is so far forward that the elastic pressure of the closed lip might bend the septum and occlude one or both nasal airways. If the premaxilla is to be set back, it is set back the least possible amount necessary to allow successful closure of the lip. This is done by splitting the mucosa over the bottom of the vomer and resecting a block of the vomer just back of the premaxilla. The premaxilla is set back until it is in contact with the vomer again and immobilized by a wire suture through both fragments, or better by nailing a straight Keith needle directly backward through the center of the vomer. . . . Bony union between the premaxilla and vomer is rarely obtained but the fibrous union helps a good deal in keeping it centered.

Twenty years later McDowell, having reviewed the cases over those years, stated that the situation with the premaxilla continued as predicted. He recalled their advice to set back the premaxilla surgically the minimum amount to make immediate successful closure of the lip possible and concluded:

Various surgeons expressed fears that this would be followed by various types of disaster, but these have not occurred when the work was carefully executed.

Huffman

In 1949 Huffman and Lierle at the State University of Iowa repositioned projecting premaxillae by quadrilateral resection of vomer. At the same operation they attached the already elevated vomerine flaps to the medial incised palatal flaps in a first-stage palate closure, a feat not always possible, which leaves the sectioned vomer in the open.



Cronin


Other forms of quadrilateral resection followed. Thomas D. Cronin of Baylor University College of Medicine, Houston, thoughtful and always searching for a better way, was a promoter of the vomer resection. In 1957 Cronin reported that, out of five early cases of triangular wedge resections of vomer, in one the premaxilla was loose and displaced posteriorly, in another there was tooth removal and two showed surgical displacement and slight movability. These findings led Cronin to his rectangular sliding pushback of the premaxilla, similar in principle to Reich's approach. He described the method as follows:

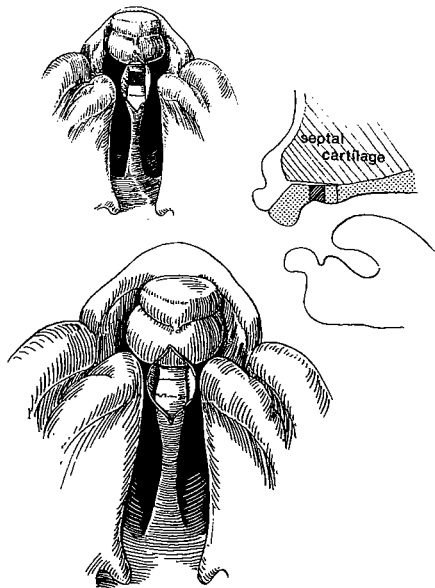
A 2 cm. incision is made over the inferior free border of the vomer about 1 cm. posterior to the premaxilla. The mucosa is elevated from each side of the vomer. . . . The amount of protrusion is measured and 3-4 mm. less than this amount of vomer is removed as a rectangle, using a sharp osteotome to get clean cut surfaces. . . . With a right angle palate knife a horizontal cut is made in the septal cartilage toward the bridge of the nose, so the premaxilla can be slid straight back without tilting of the teeth. . . . The prolabium is lifted up with a hook and a .035 Kirschner wire is drilled through the premaxilla and vomer out through the cut surface. The two vomerian fragments are lined up carefully and the wire is driven into the posterior portion with a mallet. . . . The resected piece of vomer is cut into small chips and packed around the junction to help insure bony union. Six to eight weeks later the wire is removed and the lip is repaired over the solid premaxilla.

In 1964 Cronin called attention to two important anatomical aspects pertinent to projecting premaxillae that had been noted by Scott. The lower edge of the septum lies in the vomerine groove where it is separated from the bone by a mass of fatty fibrous tissue. On the inferior margin of the vomer there is a bulge about 1.0 to 1.5 cm. posterior to the premaxilla. This is the site of a suture between the vomer and the prevomerine bone and is, doubtless, where forward growth of the premaxilla occurs. Cronin points out that surgical procedures should avoid damage, not only to this suture, but to the all-important growing septal cartilage. He advised the setback only for marked protrusion that seriously compromises repair of the lip. He also noted that a modification suggested by Burston and Kernahan of Liverpool in 1961 might possibly be less likely to cause any disturbance in



Thomas Cronin





growth of the septal cartilage. Instead of making the Cronin horizontal incision in the cartilage, they advocated freeing the septum from the groove in the prevomerine bone with a septal elevator and sliding the premaxilla backward after making an oblique cut through the prevomerine bone. The premaxilla is then skewered onto the vomer with a Kirschner wire.

In 1960 Kahn and Winsten, from New York Mount Sinai Hospital, advocated the Cronin type of premaxillary retropositioning, stating:

If properly performed, no growth retardation of the nose, nor instability of the central section of the lip will occur. We set back about 50% of the cases.

Yet they cited only a three-year follow-up of the cases.

In 1971, for *Cleft Lip and Palate*, Ray Brauer gave the latest Texan reflections for the Cronin surgical setback.

Cronin and Brauer have relied on this procedure in the past, and though some degree of retrusion has appeared in these patients, it has been no more than that seen in patients in whom no operative setback was done. In those patients in whom retrusion and collapse have appeared, response to orthodontia has been excellent. . . . The mucosa is carefully elevated off the septum, and a rectangular segment of bone is removed . . . usually 5 mm. less than would be required for a complete setback. A right-angle knife is used to make a horizontal cut through the septal cartilage from the side of the resection toward the tip of the nose, to allow the premaxilla to move straight back. It is then fixed by a longitudinally placed 0.035 inch Kirschner wire.



Clarence Monroe

Monroe

In 1965 Clarence Monroe published a report on "Recession of the Premaxilla in Bilateral Cleft Lip and Palate." He has remained a staunch but conservative defender of this action ever since and at many a meeting has been called to the rostrum to justify or explain his stand. He has since been joined at Chicago's Children's Memorial Hospital by suave orthodontist Sheldon Rosenstein, and in the spring of 1973 at the Foundation Symposium at Duke University they presented their combined approach. Rosenstein advocated "doing something early to improve the late results" and expressed conviction that a prosthesis, arch molding

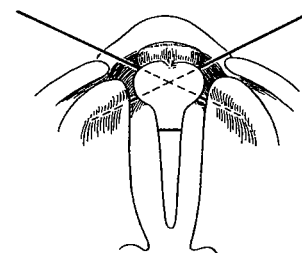
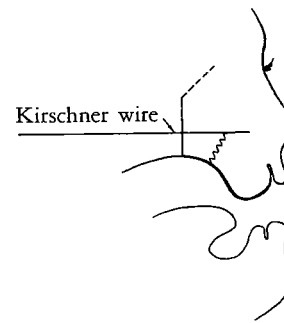
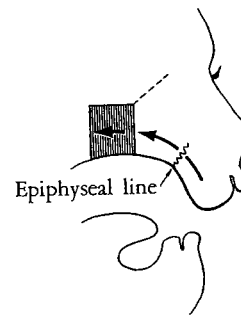
and bone grafting with maintenance of the prosthesis until palate closure at 15 to 18 months produce "occlusion and arch form better than before." Monroe repeated his belief that, when necessary at three weeks to three months, primary recession is not harmful if done correctly. He proposed the rectangular resection of septum posterior to the enlargement suture combined with horizontal incision in the septal cartilage to allow premaxillary pushback and fixation with a Kirschner wire. The setback should undercorrect, and as an example he mentioned a case of 18 mm. protrusion which received a recession of 13 mm., or 5 mm. short of complete inset into the maxillary arch. Monroe reported in his quiet unpretentious manner that 15 out of 19 cases of early surgical setback showed good occlusion but admitted that in spite of this 75 percent with good results he rarely does one today. Since 1964 he has set back only three premaxillae: (1) a severe projection in a mentally retarded patient; (2) a 15 mm. projection which use of a prosthesis and cleft closure failed to affect, so a 6 mm. setback was executed; (3) one with so much protrusion that recession was required for lip closure.

Monroe, who as early as 1959 proposed recession of the premaxilla, in the October 1974 follow-up clinic summarized:

Even though we do not have evidence that our operative procedure appreciably alters the growth pattern in these children, we are no longer doing the operation in the newborn. Our orthodontists have been able to guide the position of the premaxilla better with a prosthesis in the mouth than we were able to do it by surgical means. . . . After closure, the muscular lip will usually restrain the premaxilla and the prosthesis in the cleft will usually maintain the width of the maxillary arch until the premaxilla comes back into it. If the premaxilla does not come back properly by the time of palate repair (one to two years)—and it occasionally does not—we then recess the premaxilla before repairing the palate.

N. John Wilde of Valley Children's Hospital, Fresno, California, in 1960 expressed preference for removing a quadrilateral section of vomer but advocated fixation of the premaxilla using bilateral transpalatal cross-needles. He noted that

the position of the premaxilla in relationship to the vomer and to the lateral palatal processes, is readily maintained. . . . The use of two needles prevents



rotary displacement [and] does not permit the premaxilla to slip. . . . The only disadvantage is the possibility of damage to tooth buds in the premaxilla.



Sir Denis Browne

Prevomerine bone excision

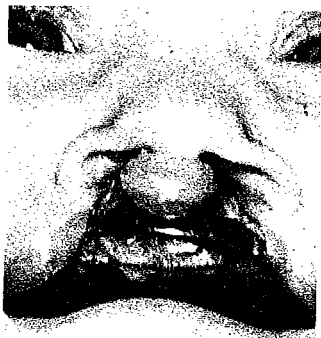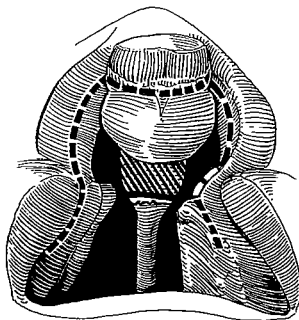
A more anterior quadrilateral resection was used in London. Sir Denis Browne, a pediatric surgeon, was orthopedic in his thinking. His reasons and design for setting back the premaxilla are interesting. As he wrote in 1949:

For some mysterious reason, when there is a cleft of the gum, new bone begins to form in front of the vomer, between it and the premaxilla, so drawing the latter forward. The vomer itself does not grow, and the division between it and what may be called the prevomerine bone is marked by a cartilage-filled suture line.

He felt that if the premaxilla were not moved into normal position and fixed firmly there would be great difficulty closing the lip over it, a very ugly profile like that of an animal snout would occur and it would be extremely hard later to fit a denture over a wobbly gum. He refused to accept the claim of others that closure of the muscle in front would position the premaxilla. He admitted:

Replacing the premaxilla has got a bad name because of the erroneous way in which it has been carried out. For instance, if a wedge is taken from the vomer, as usually advised, the foundations of the nose are ruined and it goes flat on the face.

To get a good result, he explained:



1. Cut the soft tissues of the lip away from the premaxilla right back to the nasal septum.
2. Make a longitudinal cut over the prevomerine bone and remove it submucously with narrow biting forceps. This should allow the premaxilla to be forced straight backwards into the normal line of the gums. It is preferable to leave it a little too far forward rather than to force it too far back.
3. With an awl carry a stitch of very strong suture through the alveolar ridge on either side of the gap. Bring this through the holes in the spiked bar, force this bar into the narrow upper part of the raw surface of the premaxilla and tie it so that this is fixed firmly in position.
4. Cut the mucosa off the posterior and lateral sides of the premaxilla. This is to give a raw surface to receive mucoperiosteal flaps cut from the

anterior ends of the hard palate. These flaps are sutured with linen.

5. Leave the plate in position for a fortnight.

One disadvantage of the method, he admitted, was possible damage to the tooth germs by the sutures through the alveolar ridge.

The dynamic and articulate David Matthews, also of the Hospital for Sick Children, London, and in a position to make an unemotional evaluation of Browne's approach, stated in 1952:

Denis Browne now has a very large number of children who have grown up without any secondary distortions appearing and the excellence of his results has convinced me that premaxillary reposition is a satisfactory procedure and is indicated in the more severe cases of protrusion.

Matthews' setback was similar to Browne's except that he used a bayonet-shaped pin rather than the bar and carried out the nasal floor and anterior palate closure of Veau on one side at the same time. Three weeks later the opposite side was closed similarly. His 1973 comments are of interest:

In answer to your question about Denis Browne's push-back of the premaxilla in bilateral clefts, I have seen a good many of his cases and of mine and there is no doubt at all that if the swelling on the septum a centimeter behind the premaxilla, which Denis Browne described as the prevomerine suture line, is encroached upon, there is retardation of subsequent development of the premaxilla. I have not, however, seen this happen if this prevomerine suture line is undamaged. If one restricts the operation to the very severe cases of protrusion, septal resection in front of the prevomerine suture does bring the premaxilla back far enough to produce a good arch alignment with the lateral segments. It is, therefore, my invariable rule to put a primary rib graft between the premaxilla and the lateral segment on both sides in the case in which I set the premaxilla back. With the stabilization of the premaxilla obtained in this way, not only does the premaxilla seem to grow satisfactorily but the "dog-mouth" deformity is avoided and the arch remains reasonably good. On occasion, as you know, the tooth buds migrate along the line of the bone graft.

Prevomerine bone graft

In 1960 in Munich, Oberniedermayr advocated surgical repositioning of the premaxilla, stabilization with Kirschner wire transfixation and the use of the resected prevomerine bone for grafting. Although this was an economical maneuver, evidently it



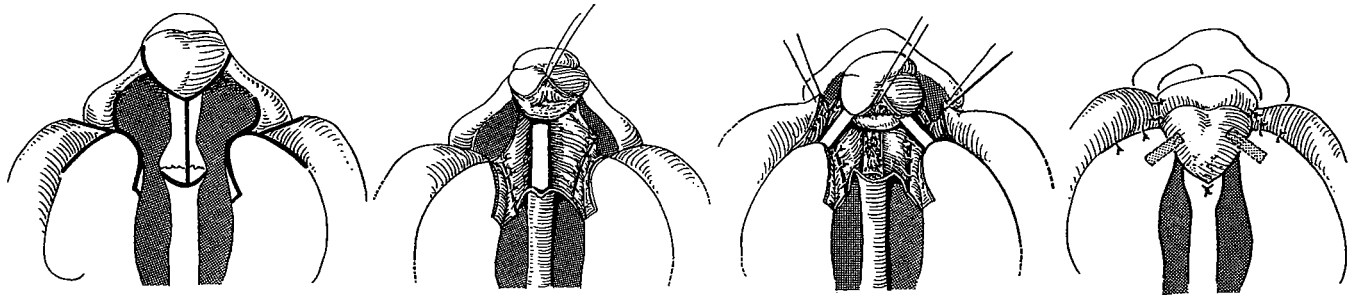
David Matthews



Gerhard Pfeifer

was in vain as most of this bone was reputed to be lost from infection.

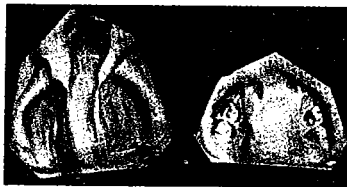Then in 1962 Gerhard Pfeifer of Hamburg, while working under Professor Schuchardt, developed a method of triple osteosynthesis for exceptional cases of bilateral cleft with extreme protrusion of the premaxilla. Mucosa was turned to form a bed for the transplants. A cylindrical piece of prevomerine bone was taken, split into two pieces and inserted into both alveolar clefts to fix the alignment of the retroposed mobile premaxilla.



Pfeifer claimed a stable union with symmetry. Yet to get enough bone for effective grafting there might be overcorrection of the premaxilla. Including the septovomerine suture in the bone graft certainly increases the chances of retardation of central facial growth. When enough prevomerine bone, however, is available to supply sufficient graft and still undercorrect the premaxillary projection, this operation has some appeal.

Absence of cleft palate makes a difference

There is a projecting premaxilla that offers an unusual problem. As noted by Antia of Bombay in the *British Journal of Plastic Surgery* in 1966:



Clefts of the lip associated with cleft alveolus but not of the hard or soft palate represent a common type of cleft in India. The premaxilla in this case may vary from a small, grossly inadequate element to an excessively large bony prominence. The general development of the alveolar arch is not affected by paring of the excessive premaxillary element due to the normal fusion of the hard palate behind the incisive foramen. It is recommended that bony excision of redundant premaxilla be undertaken.

I agree with the recommendation as I did exactly this excision

in November 1958, and alveolar alignment and tooth development are excellent today, as shown in Chapter 18.

To push or not to push

Despite the many frantic, conservative and ingenious methods of dealing with a projecting premaxilla, it is still *well out in front* as the most controversial and difficult problem in lip and palate work.

Early and late disapproval of setback

In 1916 Binnie noted:

Lane thoroughly disapproves of all these attempts to replace the intermaxillary bone.

This comment is interesting as Sir Arbuthnot Lane's treatment of cleft palate by turning large mucoperiosteal flaps and leaving huge raw areas was by no means conservative otherwise.

After 15 years' experience with bilateral cleft lips using the methods of Vaughan and Brown for premaxillary setback, Bauer, Trusler and Tondra decided:

There should be no surgical repositioning of the premaxilla because of interference with growth and development of the face.

LeMesurier used his orthopedic logic in his 1962 *HARE-LIPS and Their Treatment*:

Except in the few cases where the premaxilla is too prominent to allow the clefts to be closed over it, it is much better to leave the septum intact; if any resection has to be done, it should be only of the amount necessary to allow the clefts of the lip to be closed.

Various methods for sectioning and repositioning the vomer, in Georgiade's experience at Duke University, have led to an unstable premaxillary segment in some patients and eventual "tilting" of the premaxilla lingually with resultant malposition of the permanent incisor teeth in others:

Decreased growth of the premaxillary segment has also been a consideration following wedge resection of a portion of the vomer.

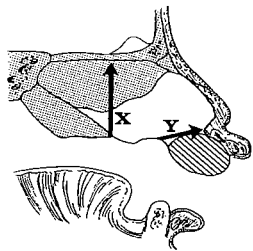
Fara and Hrivnakova noted in 1965 in *Acta Chirurgiae Plasticae*:

A total of 506 patients have been treated for bilateral total cleft at the Prague University Department of Plastic Surgery. In 31 out of 317 cases with marked protrusion of the premaxilla, surgical retroposition was undertaken, mostly as a secondary operation. In most patients this led to damage to the growth of the premaxilla either alone or together with developmental retardation of the entire maxillae. Marked signs of atrophy often develop many years after the operation, in some cases up to 11-13. We must, therefore, regard surgical retroposition of the premaxilla as a risky procedure which should, as far as possible, be made unnecessary by conservative treatment. We consider osteotomy of the vomer as a primary operation in infants to be harmful without exception.

They mentioned their interest in Karfik's suggestion of study of the blood supply of the central segment of the maxilla to consider restriction in development of protrusion of the premaxilla by

palliative operations on the arterial network with slight disturbance of the growth zone in its neck.

Bill Holdsworth of St. Thomas' Hospital, London, and Queen Mary's Hospital, Roehampton, in his 1970 edition of *Cleft Lip and Palate*, set two lines, X and Y, for division or resection of the septum in the surgical reduction of the prominent premaxilla. He then summarized rather well:




Among patients who have had the operation [surgical setback of the premaxilla] early in life flat faces abound, and its protagonists are a diminishing band. Matthews uses it only for extreme protrusion. Barsky reported its use in some 50 percent, and in most hands it is reserved for gross and neglected cases. When a child with a double cleft and a prominent premaxilla is not seen until late, closure of the soft tissues, even if possible, may be insufficient to bring the premaxilla into line, and there may be no alternative to surgical reposition.

Experiments in the hare

Clinical concern about the middle-third growth of the face is fortified by experimental evidence.

Bernard G. Sarnat of Cedars-Sinai Medical Center, Los Angeles, studied growth of the rabbit snout with A. J. Selman following extirpation of the frontonasal suture in 1957, and with M. R. Wexler after dislocation of the nasal septal cartilage in 1965 and after resection of the septal cartilage in 1966. They



Bernard Sarnat

reported growth arrest of the upper face in rabbits after resection of the septovomerine region at four to five months of age and the cartilaginous nasal septum alone at 21 to 48 days of age. Their 1967 report from 18 to 131 days after cartilaginous nasal septum resection revealed a significant early deceleration of growth of adjacent bones. This growth arrest of the upper face leads to a relative mandibular prognathism with malocclusion of the incisors. The deformities become more pronounced in the postoperative survival period.

At the Rome Congress in 1967 Sarnat summarized:

Although it was found that the frontonasal suture was a site of active growth, extirpation of it did not affect grossly growth of the snout. Dislocation of the cartilaginous nasal septum likewise did not affect grossly growth of the snout. In contrast, however, resection of cartilaginous nasal septum produced a severe and striking growth arrest of the snout.

From these experiments it is concluded that the frontonasal suture is a secondary or accommodating site of growth whereas the cartilaginous nasal septum is a primary site of growth. This conclusion has important implications and applications in relation not only to the basic problem of the growth of bones but also to the clinical problems of surgery of the nose and palate.

INHIBITION OF GROWTH BY STAPLING

The dapper John Curtin, from the Center for Craniofacial Anomalies, University of Illinois, with Pruzansky, noted at the Melbourne Congress in 1971:

Longitudinal growth studies on more than 50 patients with complete bilateral cleft lip and palate have indicated that *overgrowth* of the premaxillary-vomerine suture contributes to the characteristic deformity of the mid-face.

Borrowing from the orthopedic surgeons' technique of stapling across the epiphyseal plate to retard growth of long bones, they devised an instrument and a method of stapling across the premaxillary-vomerine suture. A mucosal flap designed to wrap around the stapling was based laterally on one side with its distal end on the other side. It was elevated without disturbing the



John Curtin

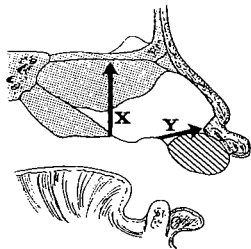
Pruzansky first mentioned this stapling plan to me on a bus in Bratislava in 1965

A total of 506 patients have been treated for bilateral total cleft at the Prague University Department of Plastic Surgery. In 31 out of 317 cases with marked protrusion of the premaxilla, surgical retroposition was undertaken, mostly as a secondary operation. In most patients this led to damage to the growth of the premaxilla either alone or together with developmental retardation of the entire maxillae. Marked signs of atrophy often develop many years after the operation, in some cases up to 11-13. We must, therefore, regard surgical retroposition of the premaxilla as a risky procedure which should, as far as possible, be made unnecessary by conservative treatment. We consider osteotomy of the vomer as a primary operation in infants to be harmful without exception.

They mentioned their interest in Karfik's suggestion of study of the blood supply of the central segment of the maxilla to consider restriction in development of protrusion of the premaxilla by

palliative operations on the arterial network with slight disturbance of the growth zone in its neck.

Bill Holdsworth of St. Thomas' Hospital, London, and Queen Mary's Hospital, Roehampton, in his 1970 edition of *Cleft Lip and Palate*, set two lines, X and Y, for division or resection of the septum in the surgical reduction of the prominent premaxilla. He then summarized rather well:




Among patients who have had the operation [surgical setback of the premaxilla] early in life flat faces abound, and its protagonists are a diminishing band. Matthews uses it only for extreme protrusion. Barsky reported its use in some 50 percent, and in most hands it is reserved for gross and neglected cases. When a child with a double cleft and a prominent premaxilla is not seen until late, closure of the soft tissues, even if possible, may be insufficient to bring the premaxilla into line, and there may be no alternative to surgical reposition.

Experiments in the hare

Clinical concern about the middle-third growth of the face is fortified by experimental evidence.

Bernard G. Sarnat of Cedars-Sinai Medical Center, Los Angeles, studied growth of the rabbit snout with A. J. Selman following extirpation of the frontonasal suture in 1957, and with M. R. Wexler after dislocation of the nasal septal cartilage in 1965 and after resection of the septal cartilage in 1966. They



Bernard Sarnat

reported growth arrest of the upper face in rabbits after resection of the septovomerine region at four to five months of age and the cartilaginous nasal septum alone at 21 to 48 days of age. Their 1967 report from 18 to 131 days after cartilaginous nasal septum resection revealed a significant early deceleration of growth of adjacent bones. This growth arrest of the upper face leads to a relative mandibular prognathism with malocclusion of the incisors. The deformities become more pronounced in the postoperative survival period.

At the Rome Congress in 1967 Sarnat summarized:

Although it was found that the frontonasal suture was a site of active growth, extirpation of it did not affect grossly growth of the snout. Dislocation of the cartilaginous nasal septum likewise did not affect grossly growth of the snout. In contrast, however, resection of cartilaginous nasal septum produced a severe and striking growth arrest of the snout.

From these experiments it is concluded that the frontonasal suture is a secondary or accommodating site of growth whereas the cartilaginous nasal septum is a primary site of growth. This conclusion has important implications and applications in relation not only to the basic problem of the growth of bones but also to the clinical problems of surgery of the nose and palate.

INHIBITION OF GROWTH BY STAPLING

The dapper John Curtin, from the Center for Craniofacial Anomalies, University of Illinois, with Pruzansky, noted at the Melbourne Congress in 1971:

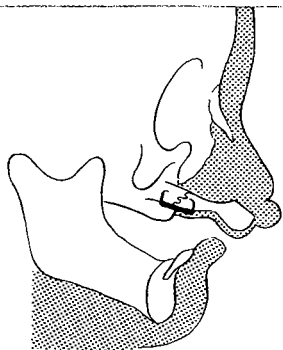
Longitudinal growth studies on more than 50 patients with complete bilateral cleft lip and palate have indicated that *overgrowth* of the premaxillary-vomerine suture contributes to the characteristic deformity of the mid-face.

Borrowing from the orthopedic surgeons' technique of stapling across the epiphyseal plate to retard growth of long bones, they devised an instrument and a method of stapling across the premaxillary-vomerine suture. A mucosal flap designed to wrap around the stapling was based laterally on one side with its distal end on the other side. It was elevated without disturbing the



John Curtin

Pruzansky first mentioned this stapling plan to me on a bus in Bratislava in 1965



periosteum, the staples were "seated" across the suture and the flap was replaced. Their animal experiments were inconclusive, and the number of infants was too few. Furthermore, the staple often acted as the foreign body that it is and tended to be rejected. Nevertheless, they propose stapling as a possibility, postulating these tempting advantages:

(a) Stapling inhibits growth at the premaxillary-vomerine suture reducing the severity of the deformity; (b) it is a reversible technique; (c) the staple can be removed without injury to bone or periosteum; (d) growth may continue following removal of the staple.

When I first heard of this stapling plan I was hopeful and must admit disappointment that the results so far are inconclusive. I wrote Curtin in June 1973 asking for the latest on his stapling in bilateral clefts, and he scribbled on the bottom of my letter,

Nothing new—still in research form awaiting maturation to substantiate results by "Pruzansky" documentation.

This principle seems to offer an appealing solution to a difficult problem, but as one thinks about it there emerges a major flaw besides the foreign body rejection phenomenon. Ideally, its use should be *intrauterine*. By the time of birth with the projection already developed it is too late to do much more than what can be done with elastic traction or muscle closure.

PERSONAL STRUGGLE WITH THE PREMAXILLA

My personal experience with the projecting premaxilla has been varied to say the least. At Boston Children's Hospital in the mid 40's, I observed MacCollum merely "tweak" the premaxilla with a forceps prior to joining the lip across it.

While still in the Navy in Nashville in 1946, I had the good fortune to scrub on two major surgical procedures a day with William Core, a large general surgeon with a huge practice. Every morning before the U.S.N. Recruiting Office required my services, we did hysterectomies, gastrectomies, cholecystectomies,

thyroidectomies and even an occasional bilateral cleft lip with protruding premaxilla. I was impressed with his speed and skill and, considering his limited plastic surgical training, amazed that he could get these little creatures' clefts closed. Still vivid in my memory, however, is the large round intestinal needle carrying a 0 chromic catgut suture which, having taken a bite through one maxilla and passed through the premaxilla, exited with a dejected tooth bud impaled on its point like a martini onion on a toothpick.

Then during 1948-1949 on Saturdays I visited Kilner at Alton, England. Here I observed bilateral lip clefts closed in two stages without premaxillary setback and a number of wobbly premaxillae excised and replaced with a denture at age five to seven years.

On Tuesdays during this same period I visited the Hospital for Sick Children at Great Ormond Street, London. It was only after several rather trying experiences in heavy fog that I finally located the hospital hidden just off Russell Square. On the eighth floor Denis Browne, renowned pediatric surgeon, was scrubbing for a bilateral cleft lip. He was so much taller than anyone else in the room that at first I thought he must be standing on a stool. His headlight was attached to a battery swinging from his hip so that he need not be plugged to the wall. He nibbled away the "bony overgrowth" between the septum and the protruding premaxilla and, after freshening the edges, set the premaxilla back in the alveolar arch and fixed it with an anterior toothed metal bar.

Between cases I cornered him to ask how he dared take this approach, when many considered the deformity in the underdevelopment of the maxilla rather than the overdevelopment of the premaxilla. He pointed out that in his opinion the vomer was of normal dimensions, but between it and the premaxilla new bone had formed, driving the latter forward. By removing this bone, he was able to replace the premaxilla and obtain union bilaterally in 70 percent of cases—on one side in 100 percent—which he claimed prevented shriveling of the premaxilla.

Then, during my training time in St. Louis, I had a chance to watch Barrett Brown push back a jutting premaxilla and pin it

with a Keith needle. The simplicity of this maneuver was impressive.

When I got to Korea, my first cleft case was a bilateral cleft in which the oral surgeon had already lost the premaxilla.

During my early years in practice in Miami I tried the Brown pushback and did one Gillies partial excision with less than partial success. I then used the Cronin approach or the Burston-Kernahan modification, either of which I favor today if the projection is tremendous. In 1960 my attitude toward the premaxilla was expressed:

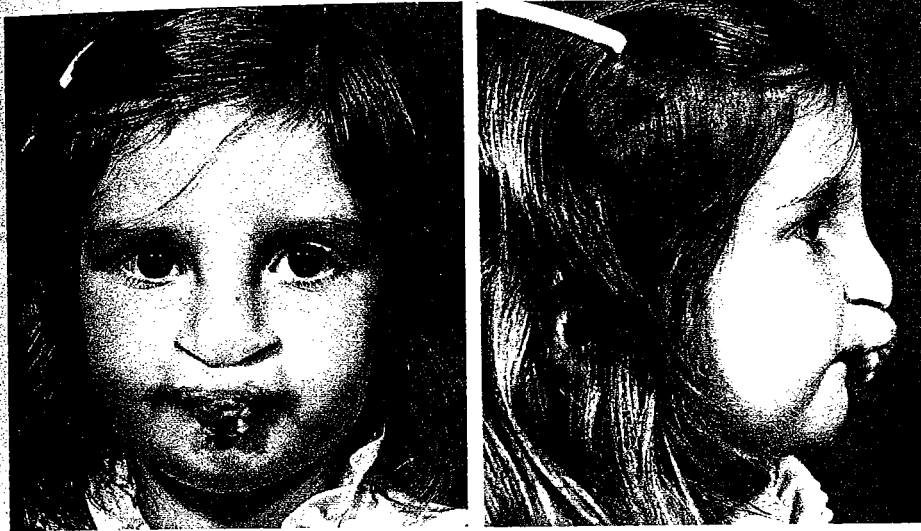There is justified controversy as to what to do with this jutting premaxilla. For the present a compromise is preferable. If the premaxilla is well in the arch, then by turning mucosal flaps a fibrous union can be achieved. If the premaxilla is jutting far out on the end of the nose, then a septal resection, which is designed to affect growth as little as possible and still let the premaxilla back in undercorrected position, seems warranted. Between these extremes are premaxillae protruding varying distances and many can be maneuvered successfully by lip moulding and orthodontics.

At this point our unit was honored by a visit from Burston, and our prosthodontist, George Balber, attempted to follow his directions and produce wedge plates to pound the maxillary elements forward, but without the proper facilities he was unable to duplicate Burston's results. Then, after a visit by Hagerty and Mylin, Balber began to construct and pin screw plates, which in certain cases, when inserted soon enough, seem to work well. The untimely death of Balber caused this approach to be discontinued.

Meanwhile, and for some time, I had joined forces with Samuel Berkowitz, a Pruzansky-trained orthodontist. He lulled me into a semicomatose state toward the premaxilla by promising that if I closed the lip over the premaxilla he could spread the maxillary elements later for its reception and bone graft fixation. The buckling of the vomer and the anteflexion of the premaxilla did not seem to cause him great concern. An occasional severely projecting premaxilla has not gone back, and here Berkowitz has been quite amenable to a setback at about five years of age.

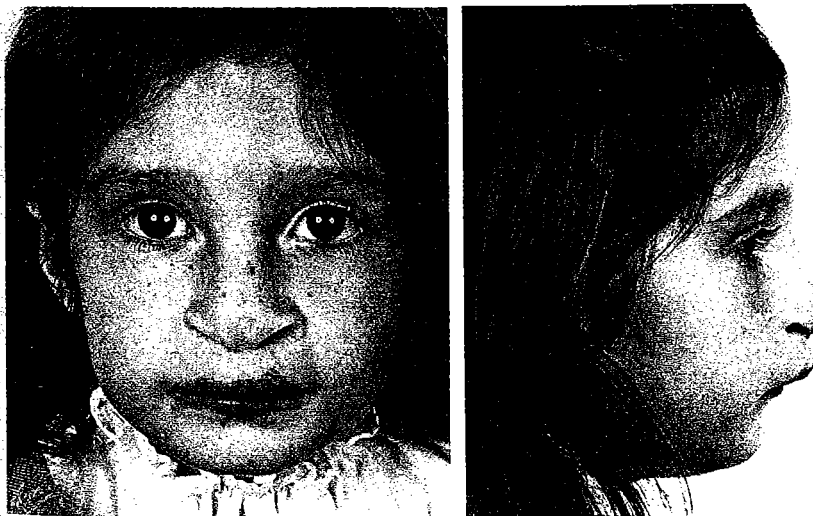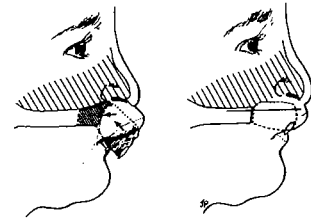
AN OUTSTANDING EXAMPLE

Bilateral cleft of the lip with *protruding premaxilla but without cleft of the palate* was treated in infancy in Alabama with approximation of the lateral lip elements to the prolabium. As we mentioned earlier in this chapter vomer resection was indicated early here to place the premaxilla into normal position. The patient was first seen at 4 years with this frightening projection.



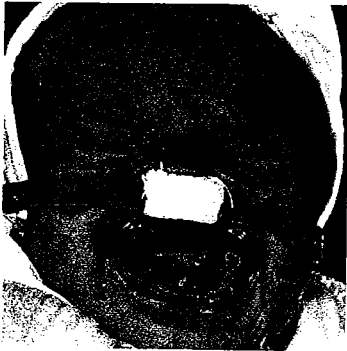4 years

The mucoperiosteum of the vomer stalk was incised and dissected so that a quadrilateral block of bone could be resected from the vomer. Then mucoperiosteum was turned from both lateral edges of the premaxilla and each cleft edge of the maxilla



so that these flaps could be sutured after the premaxilla had been set back. Bone chips from the vomer were used to fill the alveolar gaps between the mucoperiosteal flaps and a Kirschner wire was run from high up in the midline of the premaxilla back to fix it to the vomer.

Patient now needs forked flap medial advancement of the alar bases and lip revision.



Yet to condemn children to suffer with a projecting proboscis, looking not unlike a dog's mouth or a wolf's snout, during their early years seems cruel. Determined to bypass this phase, we finally changed our general approach to bilateral clefts in favor of immediate elastic traction to the baby's headcap. This has been dramatic in some cases and of moderate value in others, but adequate in all so far when seen soon after birth to allow primary lip surgery without the necessity of surgical setback.

When the extreme protrusion of the premaxilla persists and muscle-to-muscle approximation is forced over this projection, it can be accomplished but the ultimate attenuation of the prolabium and stretching of the scars are discouraging. It might be better in such severe cases to bypass this non-profit process with a bilateral mucosal adhesion maintained until better premaxillary alignment facilitates lip closure.