

## 50. Intranasal and Marginal Incisions for Correction of Nasal Tip, Alar Rim and Base

### INCISIONS FOR CARTILAGE SHIFTING


SOME surgeons have tried for the same effect of upper rotation of the slumped half but, to avoid the external tip scar, have resorted to marginal and intranasal incisions for exposure of the alar cartilages. This is an attempt to achieve the corrective action by independent maneuvers without moving the entire half of the nose as a composite unit.

### MARGINAL FLYING BIRDS AND BATS

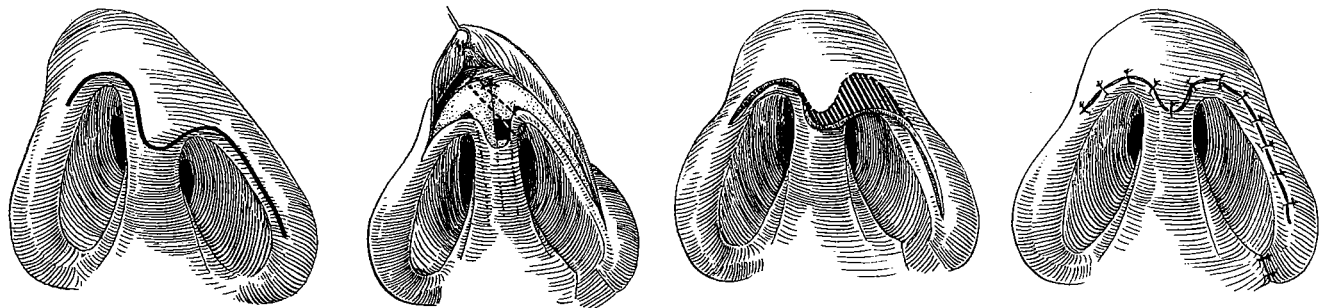
*Erich*

There is another direct exposure to the tip cartilages with more subtle external scarring. The quiet, reserved and dignified John B. Erich, who started in Gordon New's first group of plastic surgery residents at the Mayo Clinic, in 1953 described a unilateral cleft lip nose correction through a "listing sea gull" incision. He then independently divided the medial crus of the cleft side alar cartilage and lifted it into balance with the opposite side and sutured it there. The excess alar rim skin on the cleft side was tailored, which leveled the "list of the gull."

After 40 years Erich is still a most dextrous surgeon but remains as conservative as ever, seldom changing his techniques

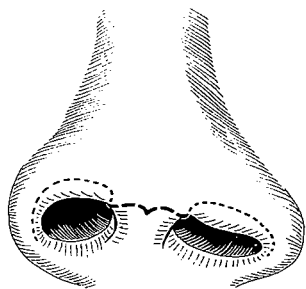


*John B. Erich*



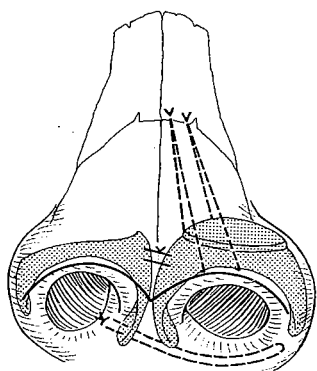
and never appearing at meetings. In 1974 he reported still using the cleft lip nose technique exactly as originally described. However, he admitted that the value of this approach is limited in situations where there is a short columella.

*Figi*

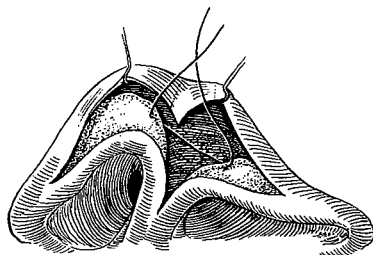


Fred A. Figi, also at the Mayo Clinic, in 1952 designed a flying baby bird incision across the upper columella with extensions in the vestibule under the alar arches which actually hid the scars better than the standard "flying bird incision." This approach never became popular but has advantages.

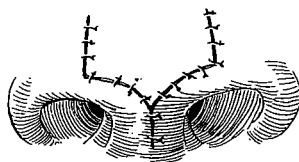
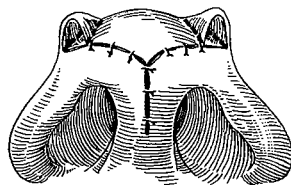
*Stenstrom*



Sten Stenstrom, of the University of Umea, Sweden, with Oberg, pulled a unilateral deformity in a number of cadaver noses to show that the basic pathogenesis of the cleft lip nose is the pull of the lateral facial muscles unopposed by an intact orbicularis oris. In 1961 they concluded that through a modified Rethi "flying bird" incision, similar to Erich, the slumped alar cartilage should be freed and sutured to its opposite medial crus and to its own upper lateral cartilage. They admitted that in certain underdeveloped alar cartilages it was necessary to transplant a small cartilage taken from the normal ala in the Musgrave spirit to "redress the balance between the two." In 1975 Stenstrom added a tiny skin incision high on the dorsum through which to lift the alar cartilage with multiple suture loops.



*Gelbke*



Heinze Gelbke of Gottingen, Germany, in 1956 used a similar transverse "flying bird" or "bat" incision across the tip with the point of the V extending down into the columella. This presented excellent exposure of the deformed alar cartilage, which he sutured up to the normal side. The skin closure advanced the V to a Y out of the columella into the tip, with bilateral "pig's ears" perking up at the sides of the tip, requiring triangular excisions and more external scarring. Since facial dueling scars were a mark of honor in old Germany, this approach may have been found more acceptable there than elsewhere.

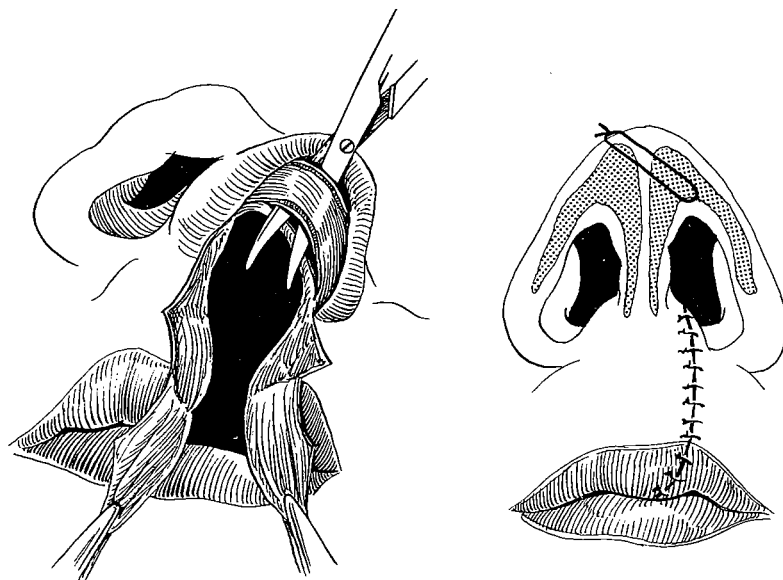
## INTRANASAL INCISIONS

### *McIndoe*

In 1938 the adroit New Zealander, Archibald McIndoe, while still in association with Gillies in London, evidently became disenchanted with the external scars of the hemi-rotation that Gillies and Kilner were using. He turned to intranasal incisions and started the shift in the opposite direction, clockwise for a left cleft and counterclockwise for a right, with parallel vestibular incisions that formed a chondromucosal bucket-handle flap, which when freed could be advanced upward and medially. McIndoe sutured the apex of his strap to the normal cartilage of the opposite side in a lateral to medial action.



*Archibald McIndoe*



In principle, this approach promises advantages, but its maintenance of a lateral tethering probably explains why in practice the ultimate results were less than dramatic.

### *Potter*

Big John Potter, quiet and sincere student and friend of Wardill in Newcastle-upon-Tyne, continued the cleft work in Stockton-on-Tees. In 1954 he discussed the unilateral cleft nose deformity:

. . . the height of the medial (columellar) crus on the affected side is lower than the normal side. The lateral crus on this side, therefore, joins the medial crus at a lower level, compared to the normal side and passing laterally forms a lower flatter arch on this side. . . . It has been frequently

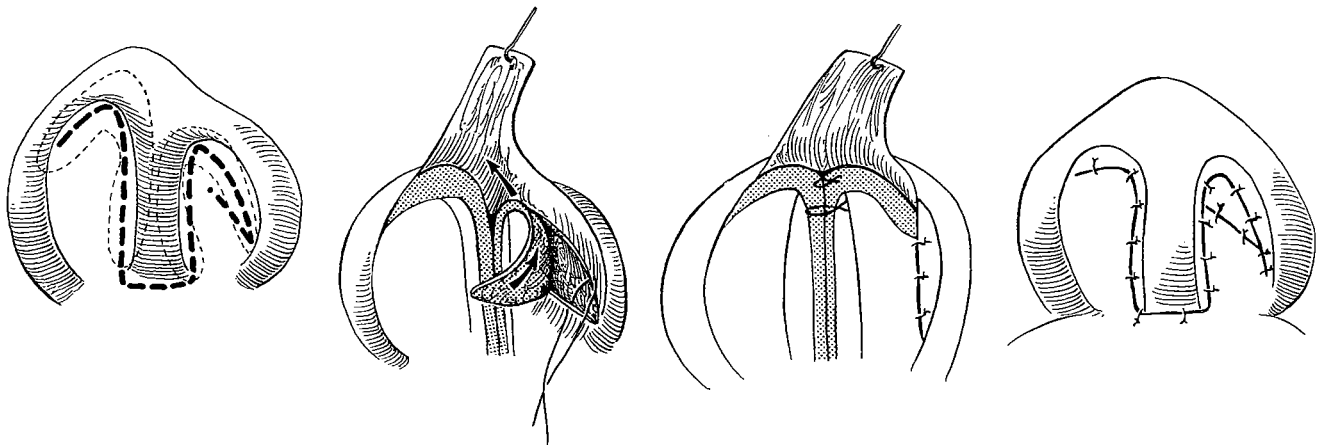


*John Potter*

noted during the operations when the cartilages are exposed, that the height of the medial crus is  $\frac{1}{4}$  inch lower on the affected side. The lower flatter arch formed by the lateral part of the alar cartilage is the cause of the unilateral flattened nostril. The lateral part of the alar cartilage is frequently distorted into the lumen of the nose, the outer surface of the cartilage, which is normally immediately beneath the skin, is rotated inwards towards the nasal cavity. It there presents as a ridge, covered by nasal mucosa and causes varying degrees of obstruction to the nasal airflow.

To obtain a balanced nasal tip the cartilage must be put into its correct position to balance with its fellow of the opposite side.

On this basis Potter designed an operation in which he elevated the skin of the columella and extended the vestibular incisions to expose the entire alar cartilages. He then freed up the entire lower lateral cartilage laterally on the cleft side and advanced it medially, suturing it to its normal mate and closing the lateral defect intranasally in a V-Y fashion. He reports today that he is still happy with the results of this procedure.

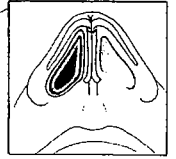
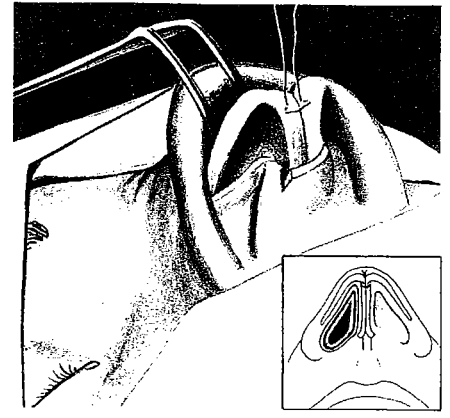
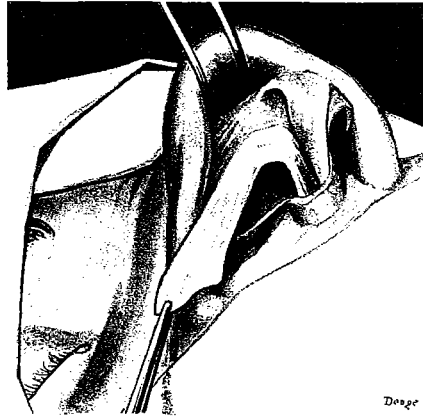
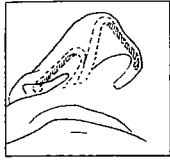


*An example is  
the technique  
of Polish Surgeon  
Janus Bardach*

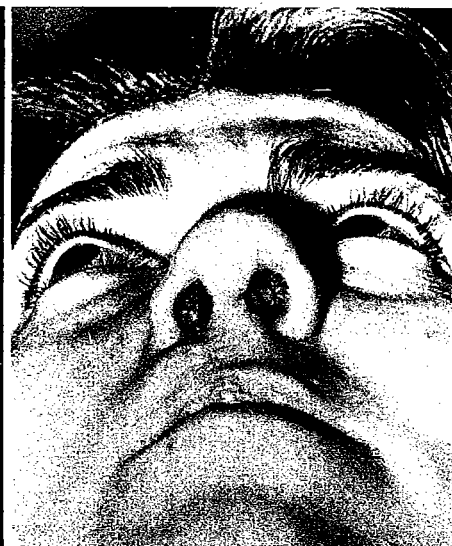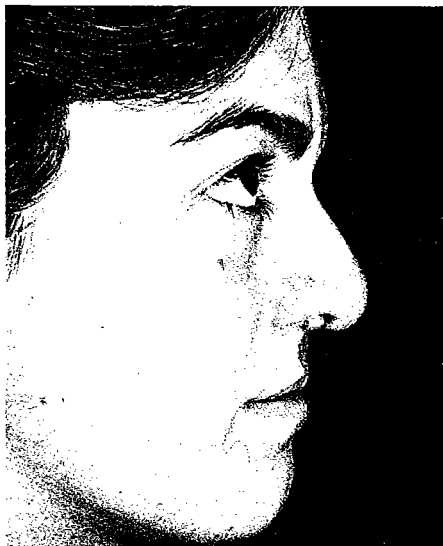
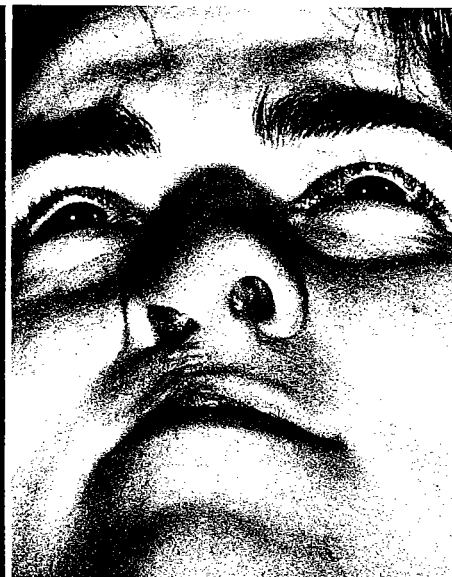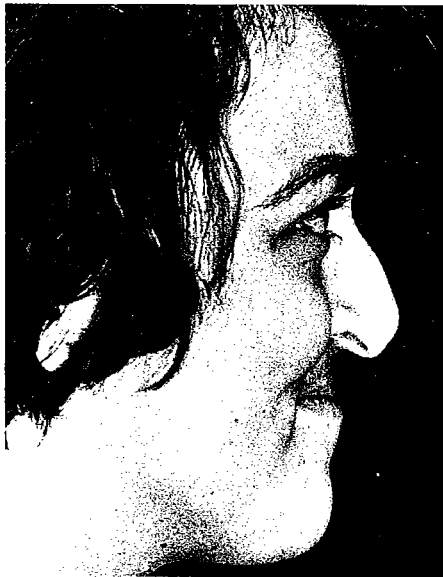This principle is sound, and although it does not offer the complete answer to the problem, it offers advantages which have been used in modified form by many surgeons and included as one component in the total nasal correction approach used by numerous other surgeons.

#### *Merville*

In 1961 L. C. Merville of Foch Hospital, Paris, presented at the Seventeenth French Congress of Stomatology, his marginal incisional exposure for the cleft lip nose. Complete freeing of the lateral wing of the cleft side alar cartilage facilitated its lift and



suture to the opposite side under direct vision. The nostril was then splinted with an endonasal prosthesis for three months. Merville kindly forwarded to me this example published in *Revue de Stomatologie*, 1962.

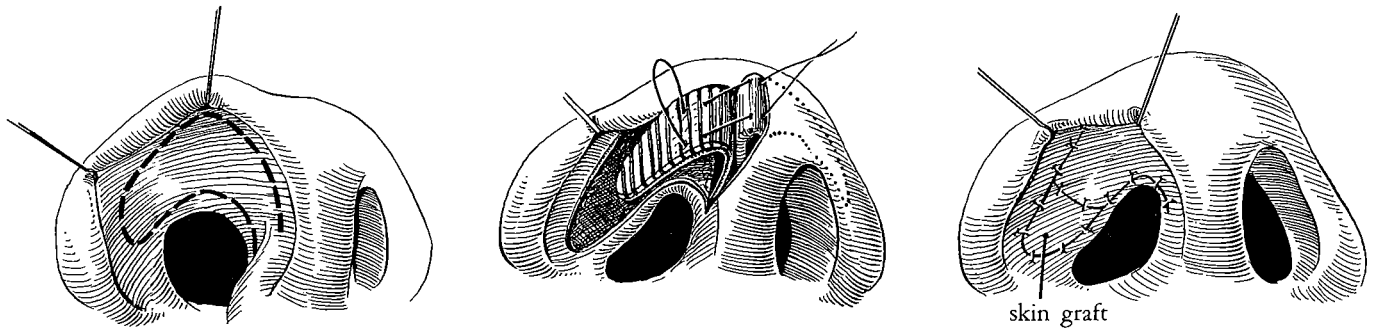




Thomas Rees

*Rees*

The suave Thomas Rees of New York University, with Converse in 1966 added an addendum to McIndoe and his synchronous lip-nose repair. A Potter-type chondromucosal flap was elevated, the cartilage scored on its superior surface and the entire flap advanced medially and sutured to its mate. The lateral vestibular defect was not closed in V-Y fashion, as proposed by Potter, but additional tissue as a full-thickness retroauricular skin graft or composite chondrocutaneous graft was added with the aid of a stent mold for one week and splinted several weeks later with an acrylic mold.

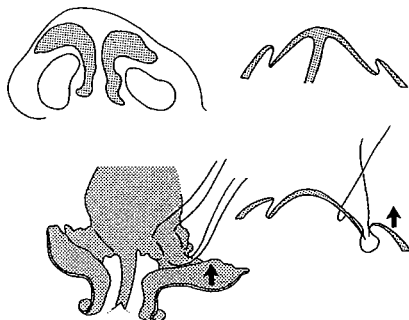


*Takahashi*

In 1963, at the International Congress in Washington, Takahashi and Yamazaki of Jikei University in Tokyo made a complicated study of the cleft lip nose, concluding:

It is necessary to raise, curve and rotate the lower lateral cartilage in an antero-medial direction, as well as to lengthen and lift the medial crus antero-medially.

They outlined their surgery, which included wide undermining along the margin of the pyriform fossa, wide exposure of upper and lower cartilages through incision along the margin of the columella and anterior rim of the nares, freeing the nasal skin up to the root of the nose and freeing of the medial crus on the deformed side from the septum. The lower cartilage of the deformed side is repositioned and fixed to the upper cartilage, and the adjacent parts of the medial and lateral crura of both sides are approximated and sutured to each other.

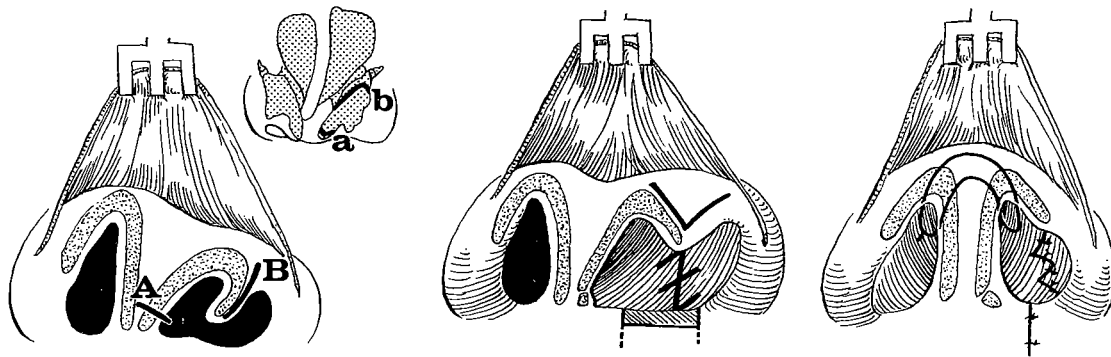


*Uchida*

A somewhat similar approach was described by the late Jun-Ichi Uchida of Tokyo in 1971, with freeing of the cleft side alar cartilage through a transcolumellar incision. An incision through the foot of the medial crus and between the alar and upper lateral cartilages along with undermining from the skin achieved sufficient freedom of the alar cartilage so that it could be lifted equal to the normal side and fixed with sutures. The shortness of the plica vestibularis along the rear wall of the vestibule was relieved with a double Z-plasty. Reduction of the wide nasal floor with a skin excision completed his nasal correction except for surgery of septal deviation several months later.



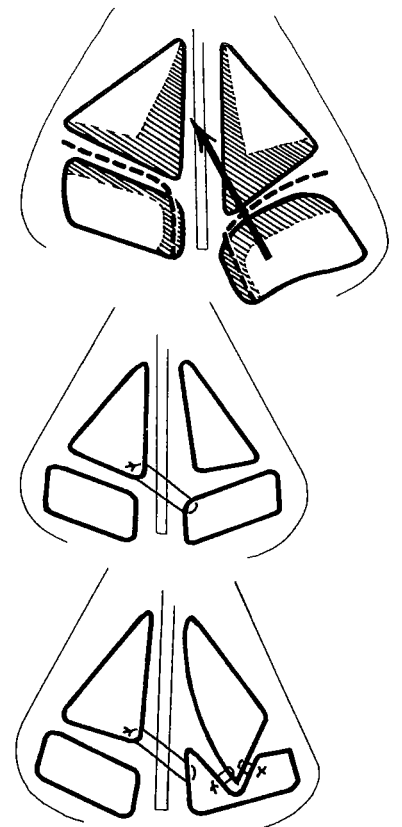
*Jun-Ichi Uchida*




*Reynolds and Horton*

Those suffering the concern about skin scars must have found the method described by the Virginians appealing. Charlie Horton, of Norfolk, modified the alar lift operation, and in 1965 he and Reynolds published their design. Access was obtained by intercartilaginous incisions in the vestibule along the dotted lines. Portions of the upper and lower cartilages were reduced somewhat as indicated by the cross-hatching. To lift and rotate the cleft side alar cartilage, a 4-0 chromic catgut suture was placed in its upper medial tip and then across and through the anterior medial tip of the normal upper lateral cartilage as indicated by the arrow. Tying this suture lifts the involved side into more normal position:

After the fixation suture is in place, if the airway is compromised by webbing or deficient mucous membrane, the redundant inferior tip of the



abnormal upper lateral cartilage, with its lining is not discarded but is inserted into a relaxing incision in the lower lateral cartilage.



*John Reynolds*

Variations of this general design have enjoyed some popularity. At least there is no gamble on the happy healing of external nasal scars. Interested in senior author John Reynolds' current thoughts on this method, I wrote him in 1973 in Chattanooga, Tennessee. He answered,

Initially, Charlie and I were not satisfied with the results we were obtaining by former methods. . . . At that time, we were working essentially with young adults in the Navy and there were literally dozens of young boys walking around with a nicely repaired cleft lip and a flat unsightly nose. However, since 1967, I have not seen near the volume of this type of problem and have done perhaps no more than six or seven. . . . However, I can state that,

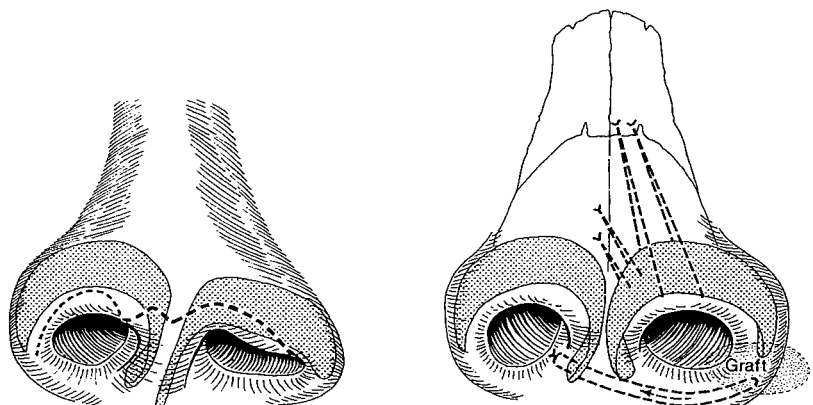
- 1) Yes, I am still using this procedure and am satisfied with it.
- 2) I still consider it one of many procedures that can be used, depending on the specific problem.
- 3) I am not as opposed to an external incision (transverse, and at the base of the columella) to gain direct access to the cartilages, as I was when this original article was written.

### *Spira*



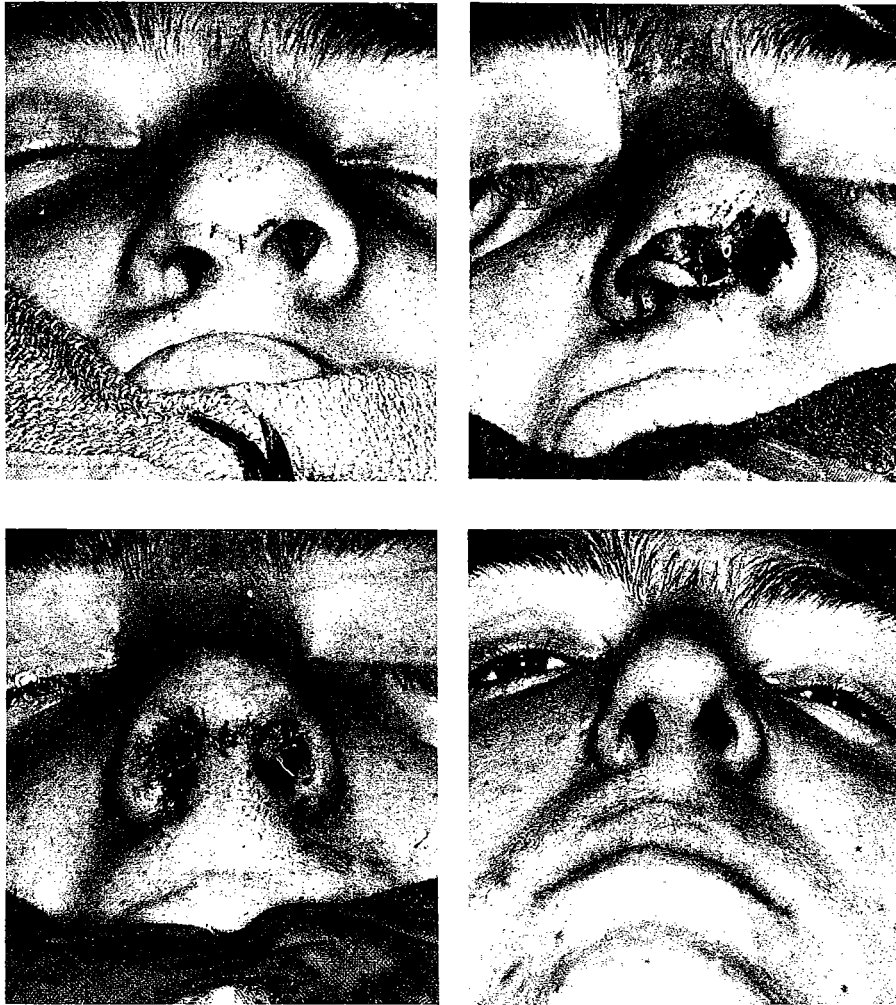*Melvin Spira*

Diligent Melvin Spira, with Baron Hardy and Frank Gerow of Baylor Medical College, Houston, in 1970 combined a nasal quinella. They used a modified Erich-Figi "flying bird" incision, suspension sutures of 4-0 Mersilene from the slumped alar cartilage and the upper lateral cartilage where it abuts the nasal bone on the same side, alar base retention suture to the septum and dissection of a pocket under the alar base over the maxillary hypoplasia for the insertion of an appropriately tailored implant of "soft silicone rubber, silicone gel, cartilage or bone."





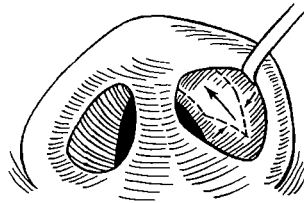
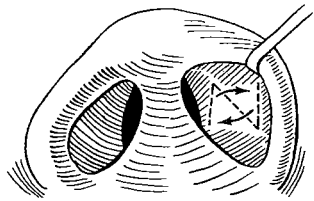
Here is an interesting step-by-step series of photographs of a case by Spira.



#### MID-COLUMELLA INCISION

Recently Gustavo Colon and Mel Abend of Tulane University advocated, along with the usual septal correction, normal alar cartilage reduction and onlay alar cartilage graft to the cleft side, a midline vertical columella incision with exposure of both domes of the lower lateral cartilages. The lateral crus of the cleft side alar cartilage is completely freed from lining and skin and is lifted and sutured to the remaining portion of the opposite normal dome.

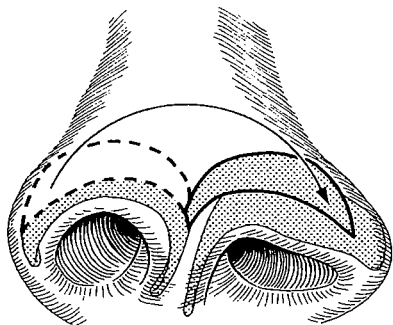
## LATERAL VESTIBULAR LINING SHORTAGE



In the original cleft deformity, the ala arches across the cleft, and the alar base is attached to the usually deficient cleft-side maxilla in flared and retroposed position. If, during the cleft closure, there is no release of the alar base from the maxilla or, if released, no extra lining is introduced, then there results a secondary deformity, described by Berkeley as a bowstring contracture of the interior of the nostril extending from the tip along the upper border of the lower lateral cartilage to the margin of the pyriform opening. Berkeley prescribes a primary Z-plasty for this discrepancy. This lateral shortness of vestibular lining is best corrected by the introduction of lateral vermilion paring of flap L during the primary lip operation. If this has not been done, then take your pick from the horde of secondary procedures. There is Uchida's double vestibular Z, O'Connor's or Borchgrevink's single Z, Potter's or Matthews' V-Y and Rees' free graft.

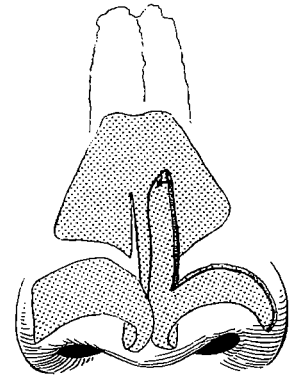
## SPLITTING AND SHIFTING PORTIONS OF THE ALAR CARTILAGES

Numerous surgeons have devoted much time and thought to ways of splitting and shifting portions of the cleft side alar cartilage in an attempt to correct the asymmetry by lifting the freed limb. Almost as many have tried turning portions of the normal alar cartilage over to build up the slumped side. Few, if any, of these methods have stood the test of time because the alar cartilages, certainly on the attenuated cleft side and even on the normal side, do not have the stiffness or body to lift and support the unilaterally flattened tip. Graham Humby of England, in *The Lancet* in 1938, described paring off the upper portion of the normal alar cartilage a flap which he swung over the cleft side cartilage to give additional contour.



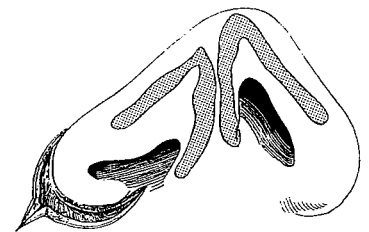
Arthur Barsky of New York in 1938 split off the upper half of the cleft side alar cartilage and transposed it with a lift up

along the nasal bridge, fixing it with sutures. Both this and the Humby procedures, when studied as diagrams, have appeal and are tried by each new generation. I had a swing at it but was disappointed. These methods have never become popular and, in my experience, just do not get the job done, except possibly in a minor deformity.

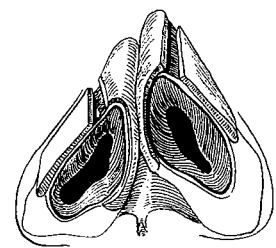


### DIVIDING AND TURNING UP ALAR CARTILAGES

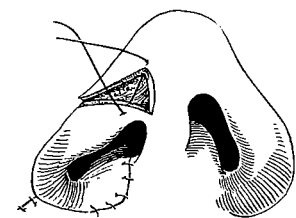
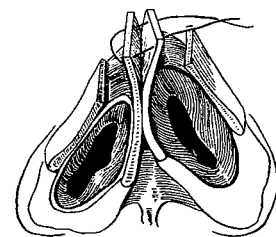
Varaztad Kazanjian of Boston in 1939 prescribed treatment for the unilateral cleft lip nose with its distorted flat nostril and bent nose. He, like others, advocated septal resection, nasal bone osteotomies, hump removal and cartilage grafts for general harmonious contour. He then stated:



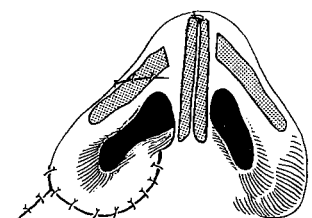
The most important step is the correction of the distortion of the nostril itself. . . . A curved incision freeing the wing of the nostril from the base of the nose . . . [is made and] a vestibular incision is now made bilaterally along the anterior border of each of the lower lateral cartilages . . . [and] is carried vertically down through the lower border of the septum. The skin over the tip and lateral cartilages and nasal bones is undermined . . . the tip of the septum and median crus are exposed.



The inferiorly placed lower lateral cartilage was carefully dissected from the septum, and both cartilages were trimmed and sutured together at an even level. If the nasal tip was broad, a pointed tip was constructed by cutting through each crest of the alar cartilages about 5 to 10 mm. from the median plane, dissecting these cartilage flaps from their mucosal lining and joining them together with catgut sutures. Advancement of the alar base was facilitated by triangular skin wedge excision of the lip side of the nasolabial junction. Here Kazanjian followed Blair and Joseph, in principle, with an external excision which he described thus:



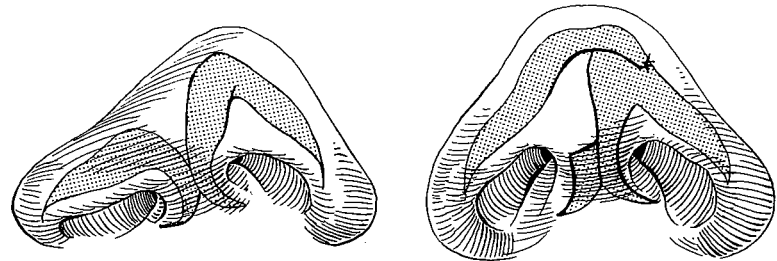
Excision of a semilunar piece of skin, about 3 mm. above the margin of the nostril is the most satisfactory method. The external scar on the tip of the nose is not conspicuous.





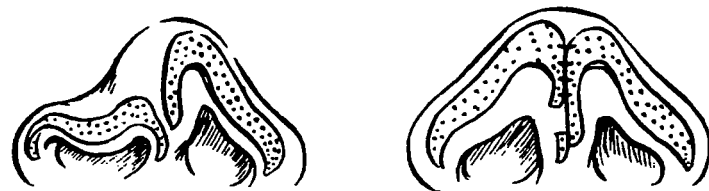
*Louis T. Byars*

Louis T. Byars, one of the Big B's of St. Louis, an A.O.A. and Regent of the American College of Surgeons, was a skilled, ambidextrous technician with a well-organized mind and a soft voice. Although better known for his work in hypospadias and parotid tumors, during the 40's "Bill" Byars also did a lot of noses. In 1947, he proposed utilizing the columella portion of the underdeveloped alar cartilage on the cleft side to restore symmetry of the nasal tip. It was divided near the foot of the medial crus and lifted up to overlap the opposite alar dome.

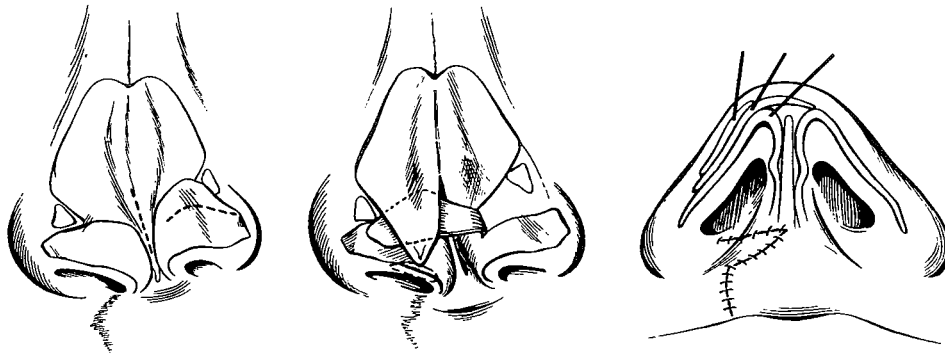


In 1952, Gillies suggested that the alar cartilage on the cleft side can be shaped, scored and lifted, and the normal alar cartilage reduced.

. . . so that when the depressed ala is brought up and sutured to it, the two will ride evenly together on top of the septal crest. At the same time the flared alar base can be moved in by reducing the wide nasal floor. One method is to transpose the alar base and the nasal floor as a Z plasty. . . . In late reconstructions when the nasal bridge is deviated the septum is freed from its vomerine groove and an osteotomy performed through the frontal process of the maxilla so that the entire nose swings around straight on the face.



Sidney Wynn of Milwaukee in 1974 modified the Humby principle of turning the upper half of the normal alar cartilage under the upper lateral but over the cleft side alar cartilage in an attempt to achieve nasal tip symmetry.



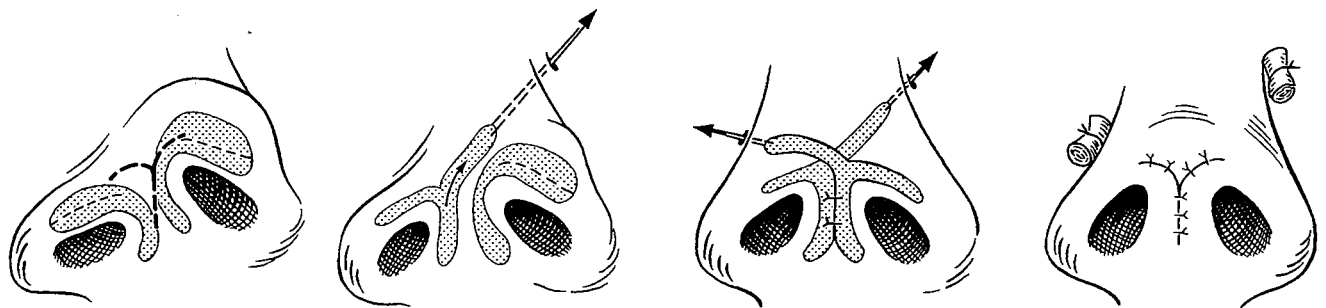
Dennis Whitlow, while still a resident, and John Constable of burn fame, from the Massachusetts General Hospital, wrote a paper on secondary unilateral cleft nose, a subject on which even the experienced hesitate to editorialize. In 1973 they published a design which on paper or to the inexperienced might have appeal. They refer to:

An upsilon-shaped incision ( $\Upsilon$ ) with its base in the anterior part of the columella and the limbs gently curving out over the alar domes.

Editor McDowell placed one of his notorious notes in their margin which recalled,

This incision is not totally unlike the "bat-wing incision" used a few decades ago. It was discarded because the resulting scar was objectionable in some cases.

Whitlow and Constable, through this incision, dissect and criss-cross cartilage flaps cut from the upper two-thirds of the lateral crura with their bases at the domes. Since the exposure is not adequate for permanent buried sutures, external pull-out stitches are used and maintained for two weeks.



Anyone who has had much experience with shifting deficient alar cartilage knows it is friable and not very effective either for lifting, support or contour. Even Whitlow and Constable noted:

Should the base of the flap be weakened at this narrow point, a non-absorbable mattress suture can be placed to reinforce the point of divergence.

They reported 10 cases, with photographic records of only one, which still required secondary nasal correction.

Harold McComb of Princess Margaret Hospital, Perth, Western Australia, in 1974 reemphasized the importance of the excess unilateral length of the nose on the cleft side and advocated shortening this side without external skin excisions. He uses intranasal bucket-handle strap flaps for exposure and excision of mucosa along with portions of the upper lateral and alar cartilages. By not dividing the upper lateral cartilage on the cleft side from the septum, support is retained for alar cartilage lift. He does not bury his lifting suture but depends on mattress sutures brought out through the dorsal skin and tied over a bolus for five days. McComb also advocates Humby's trick of turning the lateral crus of the normal alar cartilage to overlap the deformed cleft cartilage. To this he adds septal straightening, nasal bone osteotomies and alar base positioning, and he presents respectable results with this regimen.

#### SIMPLE MARGINAL EXCISION AND INCISION

There have been other surgeons who have been content to treat specific aspects of the total nasal deformity, and often these procedures have involved marginal incisions.

##### *Ombredanne*

Ombredanne of Paris in 1921 described nostril rim excision to correct the cleft lip nose overhang.

##### *Gillies*

In addition to their hemi-rotation of the columella with advancement of the alar base, Gillies and Kilner in 1932 offered other suggestions for the unilateral cleft lip nose:

There often remains an excess of nostril margin and lining which renders the result still imperfect. This can be corrected by excision of an ellipse

of the free margin of the cartilage . . . and lining, the broadest part of this excision is near the junction of the two crura . . . when the defect is closed, the suture line lies inside the nostril. . . . An unsightly kink in the nostril margin, caused by excess of lining, may be treated by excision of an elliptical area of vestibular skin at right angles to the margin and with its upper angle high up in the vestibule. The outside skin is not touched. Closure of the defect by sutures produces a pleasantly rounded nostril. This little operation is similar to that described by Ferris Smith for the treatment of collapsed ala.

### *Kilner*

The technique of crescent excision of lining under the alar web and in-rolling the alar skin margin was used by Kilner routinely and even became known as the "Kilner roll." This procedure is based on the premise that there is excess lining which actually is incorrect. There is a primary deficit of lining with possibly a slight relative excess of external skin. Although I have used a modified form of this approach, excising a crescent of external marginal skin, with reasonable success in many cases, a better plan has been evolved and will be described.

### *Brown*

Brown and McDowell in 1941 suggested a nostril rim incision to remove any forward roll of the lower margin of the deformed alar cartilage, and they combined this with the reduction of the normal alar cartilage.

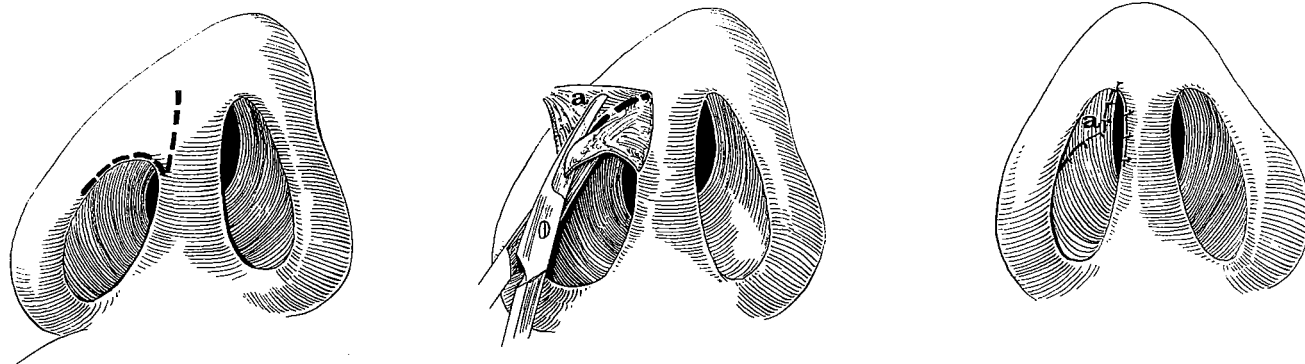
### *Straith's z-plasty*

Claire LeRoy Straith of Detroit did thousands of corrective rhinoplasties during his career and was completely at home with the nose. He organized the operation into steps one to ten and took an average of 20 minutes per nose, but his record for a reduction rhinoplasty and submucous resection of the septum was seven minutes!

In 1946 the indefatigable Straith described a Z-plasty of the alar web for the purpose of elongating the nasal columella. A piece of preserved cartilage was inserted into the area of flatness at the tip. It was typical of this efficient surgeon to design a simple, quick solution to a complicated problem. Although his



*Claire LeRoy Straith*



aspirations were often realized, the results with this approach often had a slightly unnatural effect.

### COMPOSITE EXCISION

Hoyt DeKleine of Buffalo in 1955 advocated marginal excision of skin and cartilage along the rim of the slumped ala together with advancement of the alar base.

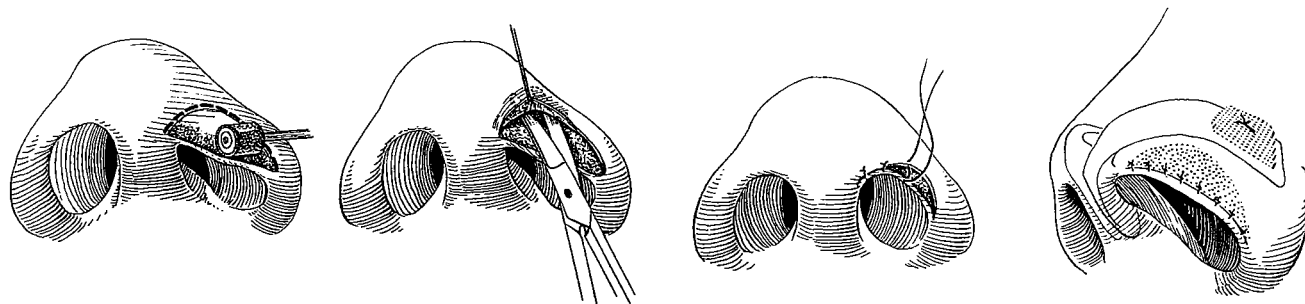
### MARGINAL OVERLAPPING



A Portuguese Bonaparte of plastic surgery, Ivo Pitanguy, short but powerful in stature, stands like the Sugarloaf of his city of Rio de Janeiro. He was once described by Simona Morini for *Vogue* as:

A brief neck supporting a round, proud head with huge black eyes that extend almost to his sideburns . . . reminding one of nineteenth-century German lithographs of Brazilian Indians.

In 1967 he approached the unilateral cleft lip nose at its alar margin. The characteristically flattened edge of the deformed nostril was abraded with a sanding machine over an elliptical area. Then an incision was made along the superior limit of the

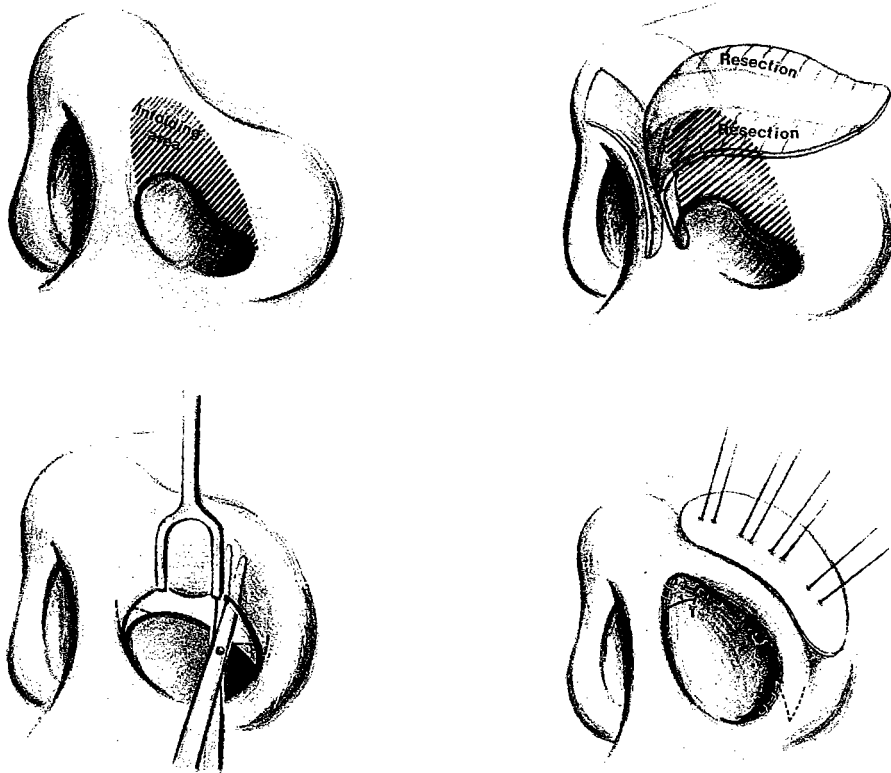




freshened area and a pocket dissected under the skin over the alar cartilage. The undermined alar margin overlapped the denuded area, which combined a lifting with a bolstering on the cleft side. When the cleft side alar cartilage was smaller, cartilage resected from the normal side was used as an onlay graft for additional contour as prescribed by Musgrave.

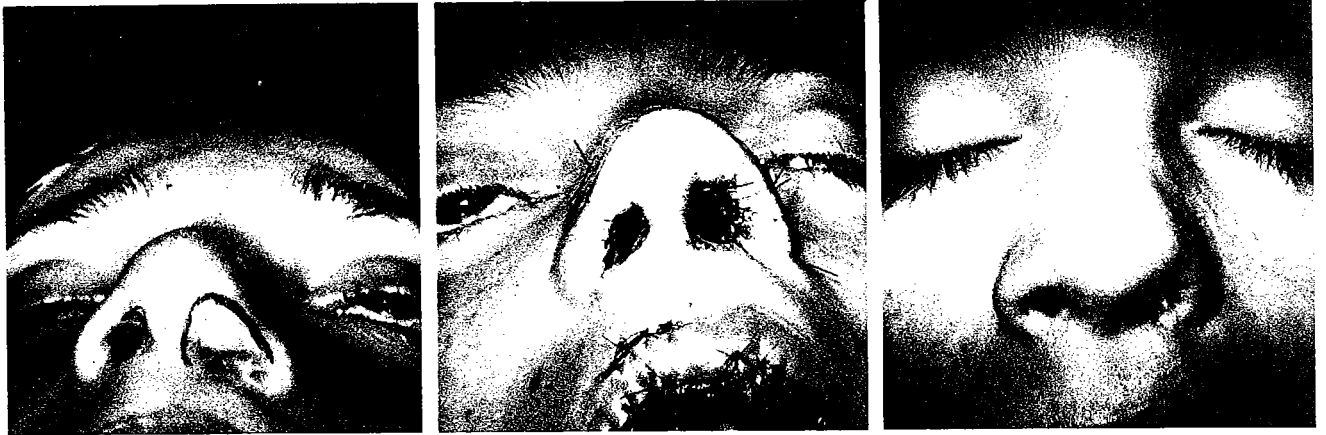### INFOLDING THE RIM

In 1973 Rodolphe Meyer of Lausanne refined the method of infolding the alar web in a modification of the method of Petralli. Avoiding an external incision but gaining access through a marginal incision, he thins the skin of this area, removing subcutaneous tissue and cartilage to facilitate infolding the edge to raise the margin of the nostril. A small Z-plasty is placed at each extremity of the marginal incision, and the vestibular lining is completed when necessary with a composite graft from the ear. Both the infolding and the graft are fixed with mattress sutures over a plate.



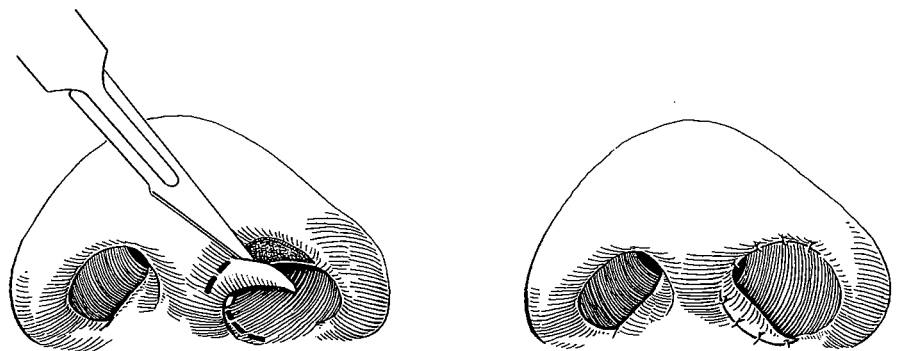


Meyer forwarded an example in 1974 of an extremely scarred unilateral cleft lip nose which had been corrected in a child by inrolling the margin and adding an auricular composite graft for extra lining and support, which he explained is barely visible as a "white corner" in the final photograph.



#### ALAR RIM TRANSPOSITION OR FREE GRAFT

The omnipresent Onizuka of Tokyo, constantly reappearing out of the blue in his relentless attack against the unilateral cleft, suggests kamikaze courage. In 1972 he advocated transfer of the excess alar rim web but this time to the underdeveloped medial crus area of the columella base on the cleft side to bolster its contour. He proposed a transposition flap from rim to sill as first choice. Yet he realized that after the flap takes a 140-degree shift, there may be either an objectionable "pig's ear" at the turn or the pedicle may have been cut dangerously narrow. He admitted making the flap into a composite graft on occasion and published a good case example.



## POSITIONING THE ALAR BASE

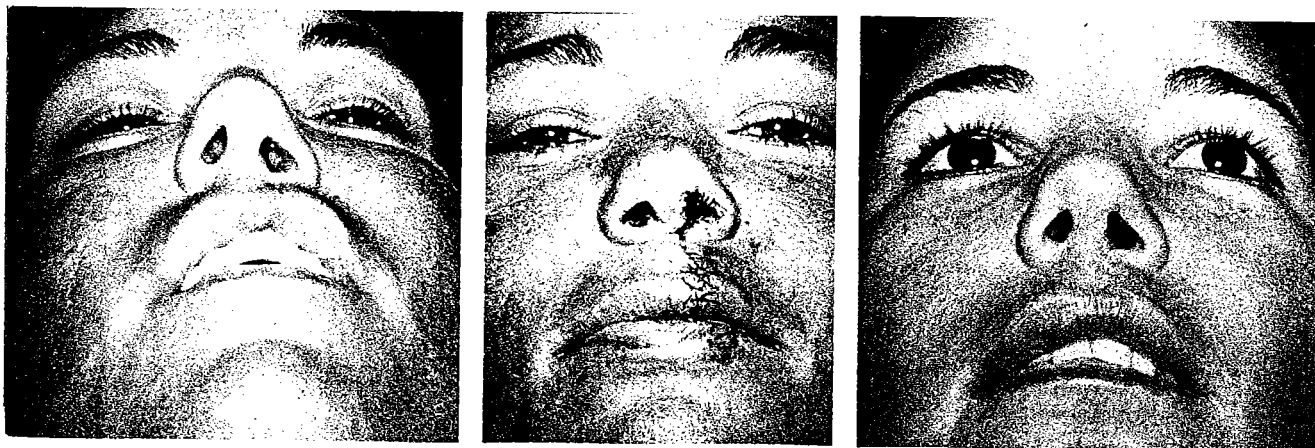
Not only do the nasal tip and columella show secondary deformities, but the alar base, beginning in flared position, unless effectively corrected primarily will remain flared. The most common method of dealing with this problem has been inartistic excision of tissue at the entrance of the nostril. Several more-sophisticated methods have been developed.

Collis swung lateral lip skin into the floor of the nose, which achieved some alar base correction. Blair utilized a similar principle as have others.

Trauner, of Graz, in an extension of the Collis flap, achieved alar base positioning with his vertical lateral lip flap transposition across the base of the columella. Mustardé exaggerated Trauner's approach by carrying the flap completely across the columella base well into the opposite side in an attempt to tie the ala and prevent lateral drifting.

Grignon, of Paris, devotes the major part of his energy toward disinsertion and forcible rolling up of the ala nasi, with a locking into a sub-columnar notch . . . for satisfactory positioning and fixation of the ala nasi and the nasal wall. . . .

The original design of the rotation-advancement principle had, as one of its prime advantages, the medial advancement of the alar base. The same action was found effective as a secondary procedure. Here is a case in which a secondary rotation-advancement corrected the lip, straightened the columella and advanced the alar base almost enough. An alar rim excision achieved reasonable nostril symmetry.



The occasional less than perfect medial advancement of the alar base or its secondary lateral drift precipitated other alar base maneuvers to "bring about and secure this flapping jib."

At the Rome Congress in 1967 and in the 1968 extensions of rotation-advancement, I advocated a circumalar incision and advancement of this alar flap on top of the lip flap in an advancement on an advancement. Although it achieved excellent alar base positioning, this correction was not always maintained perfectly. Thus, a further modification was added to the primary surgery to tie the alar base in once and for all.

When sufficient alar base is present, its distal end is denuded and advanced under the side of the columella to the septum at the nasal spine and fixed. Otherwise, a subcutaneous pedicle is dissected in continuity with the alar base and advanced in the same manner. If the alar base is too thick, it can be thinned by cutting a subcutaneous flap out of it and its sides sutured together for a slimmer base. The subcutaneous flap, still attached to the distal alar base, is used as a tether, which can be advanced subcutaneously under the side of the columella and fixed with nonabsorbable suture to the septum at the nasal spine.

Of course, these same tricks are available and effective for secondary alar flare when primary alar base positioning has been inadequate.

#### A POSSIBLE BACKFIRE

In the rotation-advancement procedure, there is always a chance of a novice advancing the alar base too far. It is even conceivable that an old pro can get a nostril too narrow in the incomplete cleft with an almost normal width of nostril on the cleft side.

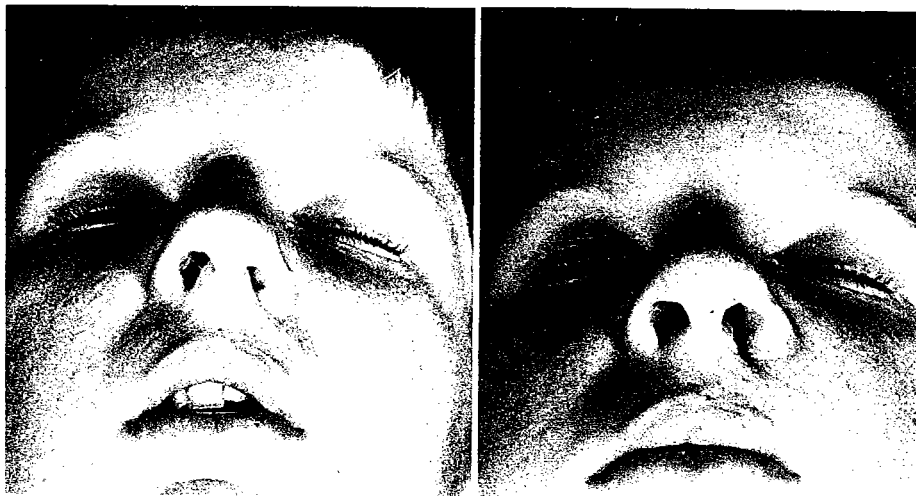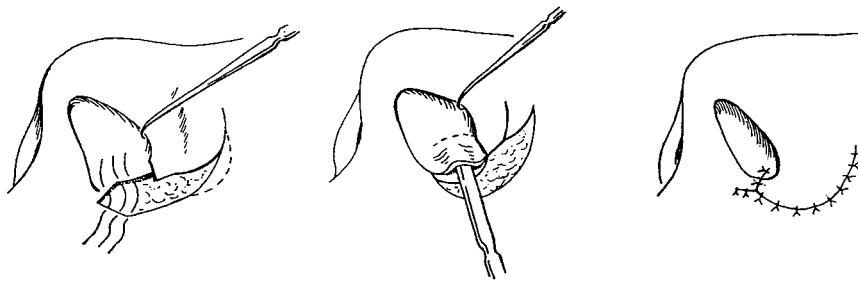
#### BACKWARD ADVANCEMENT

When the alar base had been advanced too far medially, the nostril size is reduced to a comparatively constricted opening. A reverse action is in order. A V-Y of the alar base will correct the constriction and open the airway. The eager and energetic E. N. T. surgeon, Richard Farrior of Tampa, published 60 pages



*Richard Farrior*

on secondary cleft lip nose correction in *Laryngoscope* 1962 with a great part devoted to shifting the alar bases medially. Evidently a few got shifted too far in, resulting in an abnormally narrow nostril. These must have stimulated Farrior to design his V-Y lateral advancement of the alar base, which quite effectively re-opened the nostril as demonstrated by his diagrams and one of his secondary cleft lip rhinoplasties.



#### FREE COMPOSITE GRAFTS

Another effective method of opening a comparatively small nostril is the use of a free composite graft from the helix rim. Still another possibility is a modification of the 1954 trick of Max Pegram of Beverly Hills, California, who advocated alar base composite free grafts to lengthen a congenitally short columella. When the normal nostril is quite wide, Pegram's principle could reduce the normal side and free graft the composite wedge into a releasing incision at the base of the narrow side. This would serve two purposes with one graft, provided the constriction was not too great.