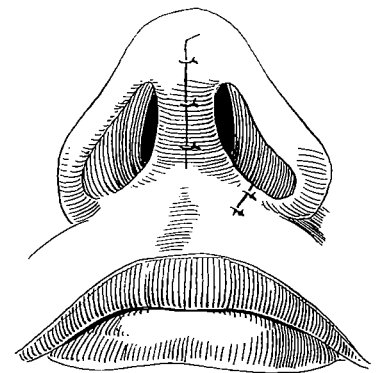
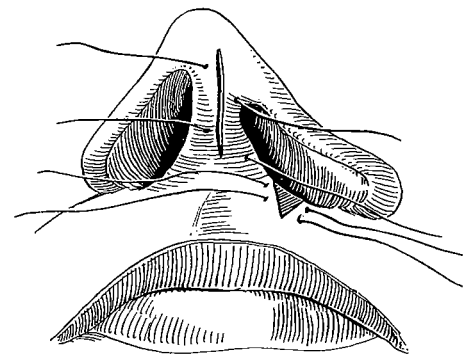


49. Cleft Half Rotation by External Tip Incisions and Excisions

TRUE to the principle of placing the normal into normal position, a number of surgeons have advocated variations of medial and upward rotation of the slumped composite half of a nose, including skin, subcutaneous tissue, cartilage and mucosa as one component, and advancing the flared alar base into the wake of the rotation. This was bold surgery since it necessitated external nasal incisions.

Erickson in 1885 devised a secondary nasal correction of the unilateral cleft lip nose which used a columella splitting incision that extended to the nasal tip. With the aid of sutures, he slid the down side upward and aided the whole maneuver with a triangular excision of skin and possibly scar from the floor of the nose on the cleft side near the base of the columella. This evidently was the original application of a general principle that later had many followers with almost as many modifications.

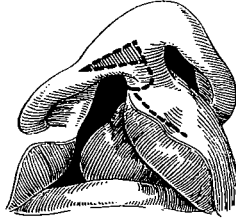
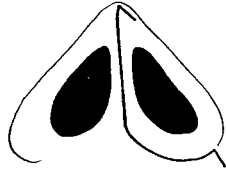
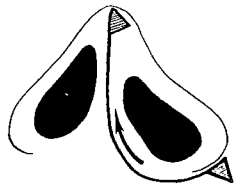


BLAIR

The homespun wisdom of Blair shines through the literature repeatedly and the more brightly when the dates are noted. In 1925 Blair admitted:

At first glance, the correction of the spread nostril would seem somewhat simple; but after some years of more persistent effort with very indifferent results, I concluded that it was not as easy as it seems.

Blair's basic approach to all problems probably explains his greatness as a pioneer. He concluded:



Until I came to appreciate that no change in the direction of the long axis of the nostril, rather than the real or apparent increase in the width of the floor was the key to the deformity, and until means were taken to correct this rotation of the axis, the operative results fell short of what they have since. . . . To correct the condition, the columella was split in the midline, the cut swinging outward along the line of the junction of the floor of the nostril with the lip, and the whole nostril with its broad ala was rotated into a more normal position.

Blair's design for primary nasal correction in unilateral lip clefts with rotation of half the columella was included in his 1930 article with Barrett Brown.

S H E E H A N



J. Eastman Sheehan

J. Eastman Sheehan approached the cleft lip nose correction in a manner similar to that of Blair. This flamboyant showman of plastic surgery, born in Dublin but practicing in New York, seemed to have a penchant for joining wars. He eventually was recipient of both the French and the Belgian Legion of Honor, Order of the British Empire, Military Cross of Spain after joining Franco for a time and the New York Police Department Legion of Honor. He served under Gillies at Sidcup during part of World War I and evidently also participated in World War II, if there is any authenticity to the story Lamont once heard while dining with Jack Tough at a quaint restaurant close by Lord Lister Hospital in Glasgow:

J. Eastman Sheehan had been a friend of Sir Winston Churchill, and had been brought into Scotland by submarine during the war to carry out some type of hush hush mission.

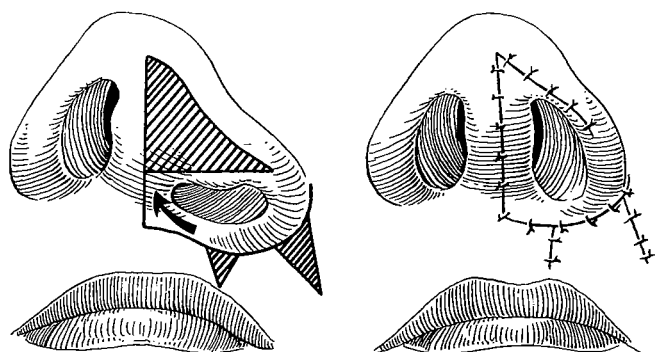
Neither did Sheehan shirk the battle of the cleft lip nose, for in 1925, he agreed with Blair's concern about

. . . the long axis of the nostril rather than the width of the nostril floor.

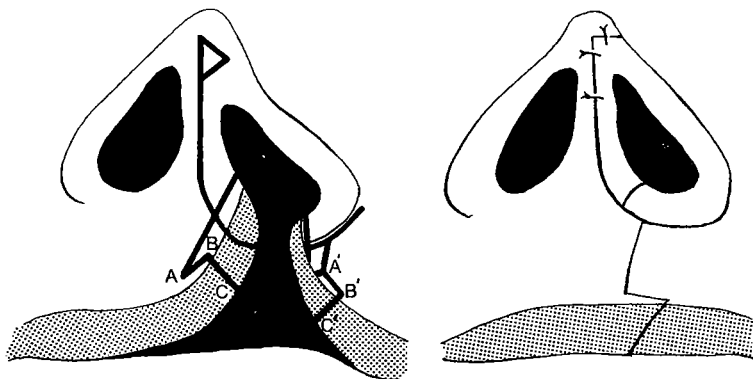
He resorted to rather drastic measures, as he described, to accomplish his purpose:

An incision is made around the ala and deepened to the bone. With a blunt scissors the tissues by which the ala adheres to the bone are separated

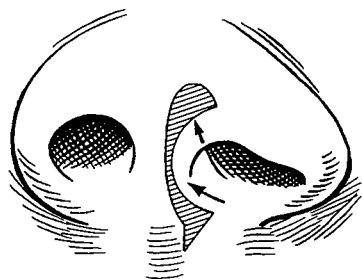from the bone, and on both sides of the incision. The incision is now carried across the floor of the nose; then upward, splitting the columella. . . . An excision is made from the tissues over the nostril of the affected side to admit the apex of the nostril to be drawn up level with its mate. A V-shaped excision from the floor of the nostril to reduce the width facilitates approximating the ala to the philtrum. The freed tissues of the ala and columella are now swung around, the aperture is conformed to the one on the other side and the base of the ala is established in its new position.



Ivy in 1932 diagramed the Blair rotation adapted to the primary nasal correction at the time of lip closure. In 1961 Royster readvocateed the Blair procedure in primary nasal correction.



Earl Padgett, one of the early students of Blair, in his 1948 book with Kathryn Stephenson, described his modification of Blair's hemi-rotation in the unilateral cleft lip nose.



GILLIES



Sir Harold Gillies

*the italics
are mine*

In 1930 King George V bestowed knighthood upon H. D. Gillies for his World War I reconstructive work. By 1932 Sir Harold Delf Gillies, the first knight of plastic surgery, was already writing, with T. P. Kilner in *The Lancet*, on an aspect of civilian plastic surgery, the flat ala in cleft lip:

Hitherto this has proved a stumbling block to all surgeons. Optimism in this connection, however, is justified, for the structural defects underlying the deformity are gradually being made clear and accurate diagnosis is therefore becoming possible. *Cure seldom anticipates diagnosis*, but is usually *quick to follow it*. Except from a viewpoint directly below the nostrils, one to which patients are seldom subjected except for the preparation of surgical textbook illustrations, the nostrils can be made to appear symmetrical.

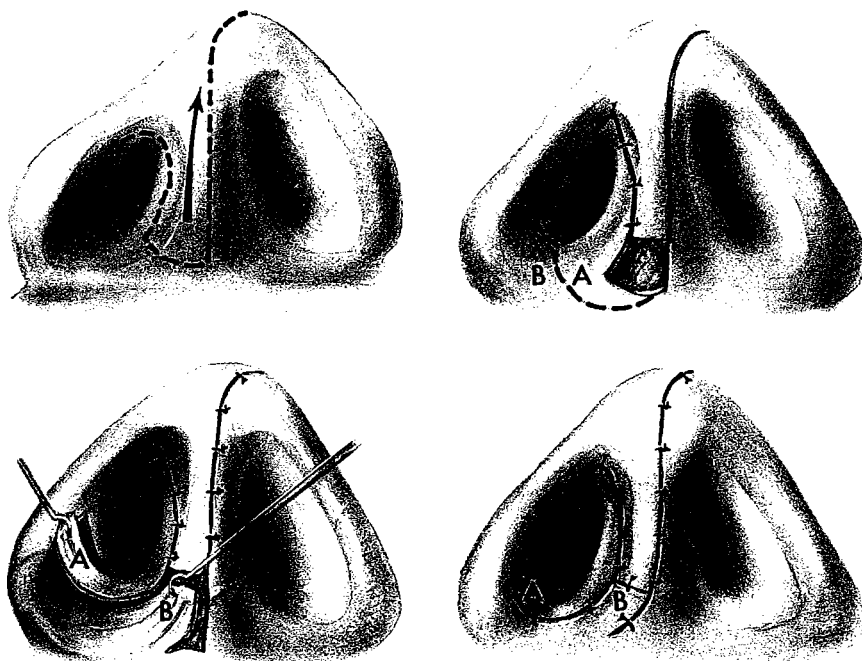
Gillies and Kilner pointed directly to the deviation of the septum and the underdevelopment of the maxilla as fundamental causes of the nasal deformity. They described septal correction and nasal bone osteotomies and then turned directly to the alar cartilages:

The distorted alar cartilage must be mobilized in order to allow it to slide forward into symmetry with its fellow, and it must be fixed in this new position by suture. When the distortion is mild in degree, incisions may be entirely intranasal.

This involved freeing the skin from the alar cartilage to allow better position and then fixing it with mattress sutures to the opposite cartilage through the medial crura. For more severe deformity a more radical shifting was designed:


In severe cases an incision must be made in the midline of the columella, separating one mesial crus from the other, and carried forwards into the tip of the nose curving towards the normal side. It is sometimes necessary to prolong the incision backwards, carrying it around the out-turned extremity of the mesial crus and coming out into the vestibule. In all cases the intranasal incision through membranous septum and arching around the skin of the vestibule, must be made in addition. The mesial crus, having been thus freed, is slid forwards into correct position and held there by skin sutures in addition to mesial crura mattress sutures. It is to be noted

that the sliding forward of the half columella in this manner in unilateral cases is comparable to the sliding forward of the whole columella in bilateral cases. . . . In cases in which the half columella has been advanced, care must be taken to free the alar base from the maxilla—in order to free the alar base still further it may be necessary to carry the incision into the alar groove. A deep catgut suture now approximates the deep tissues of the alar base to the tissue covering the septum and nasal spine. . . . The defect left on the outer wall must be covered by either a Thiersch graft or a small transposed flap usually found to be available in the floor of the nose.



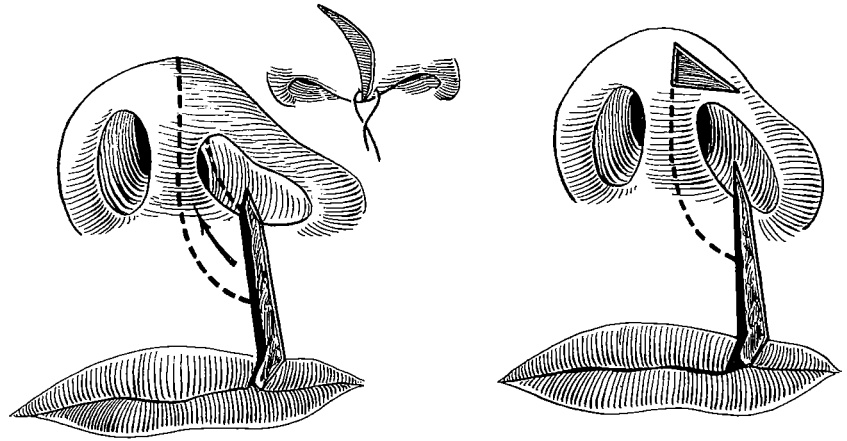
SCHJELDERUP

The precise Halfdan Schjelderup of Bergen, Norway, a devoted student of Gillies, in 1963 reported his satisfaction with the Gillies hemi-columellar shift after 13 years experience and 90 cases. Shifting the long skin edge of the cleft side along the short edge of the sound side produced an excess at the upper extremity of the incision which was accommodated by a crescent excision of dorsal nasal skin curving toward the normal side of the tip. In less severe cases the excess pig's ear of the shift was removed as a triangle in the tip just above the alar arch. Schjelderup wrote in 1963:



Halfdan Schjelderup

I once asked Sir Harold Gillies why he had not followed up this idea which in my hands had proved to be so useful. The reply was that he did not like making a scar on the nose. Although . . . in my experience this scar in the majority of cases is almost insignificant . . . I still try to avoid it if possible. . . .



In 1969 Tessier approved the hemi-nasal rotation principle when he wrote:

Gillies and Kilner have described an admirable procedure which has been taken up by Schjelderup and which can still be further simplified by preventing continuity between the labial and columellar incisions.

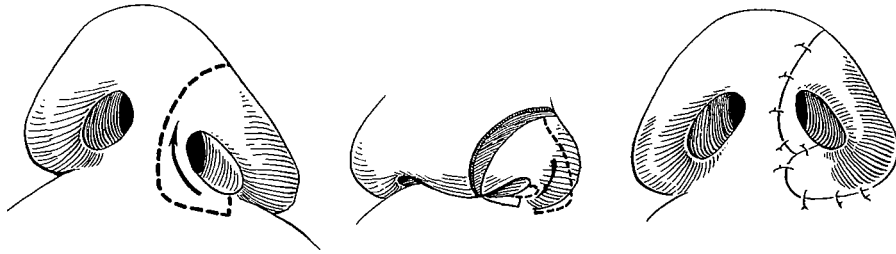
YOUNG



Forrest Young


Forrest Young of the University of Rochester also preferred the principle of hemi-nasal rotation in unilateral clefts. He was a plastic surgery maverick with a mustache and a rambling gait, reminiscent of Charlie Chaplin. Young loved to play the violin better than others liked to listen to him. One of his house officers recalls the winter of 1946, when the snow in Rochester was over 100 inches deep and the doctors got snowed in at the resident staff quarters and all had to listen to the screech of his violin for three days! Eventually Young became bored with plastic surgery, which for him was mostly reconstructive work, and eventually retired to California and went back to general surgery. In 1949, well after all strains of the snowstorm had faded, he published his version of a Blair-Gillies approach utilizing the

same medial and upward rotation of the short half of the columella and separately, into the wake of this shift, advancing the flared alar base. Execution of this action in one combined sweep, as Blair suggested, seems more logical unless the nostril floor is not well constructed. In that case Young's two-step action, like that of Gillies, could correct the floor discrepancy in the process.

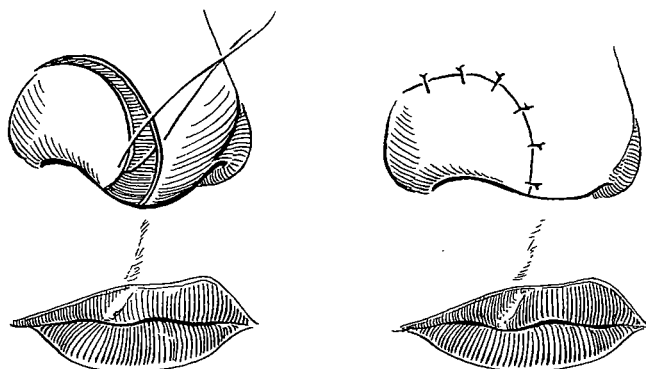


EXTERNAL CRESCENT EXCISION

In 1931 the incredible German, Jacques Joseph, father of modern rhinoplasty and pioneer in intranasal incisions, indicated the difficulty of the unilateral cleft lip nose by advocating, obviously in desperation, a contradictory midline columellar incision extending over the dome of the lower lateral cartilage in a curvilinear fashion. Joseph resorted directly to excision of an ellipse of skin, subcutaneous tissue and mucous membrane from above one dome in order to elevate the forward roll of the lateral alar cartilage. This was a bold solution at the upper extremity of the incision, being used previously for hemi-rotations of the slumped side in order to allow adequate shifting and to equalize the pig's ear discrepancy.



Jacques Joseph



CRIKELAIR

George Crikelair, with Ju and Symonds of Presbyterian Hospital and the College of Physicians and Surgeons, Columbia University, in 1959 concurred with Joseph's skin excision:

If there is marked abnormality, if the skin over the ala is thick and in great excess, or if an intranasal approach has been unsuccessful, then Joseph's method may be quite reliable. . . . The obvious objectionable feature to this approach to the "drooping ala" is the external scar. However, in all cases, the scar has been an even, soft, fine line, neither depressed nor elevated and has not been objected to by the patients, their families, or by the surgeons.

*Still present
nonetheless*

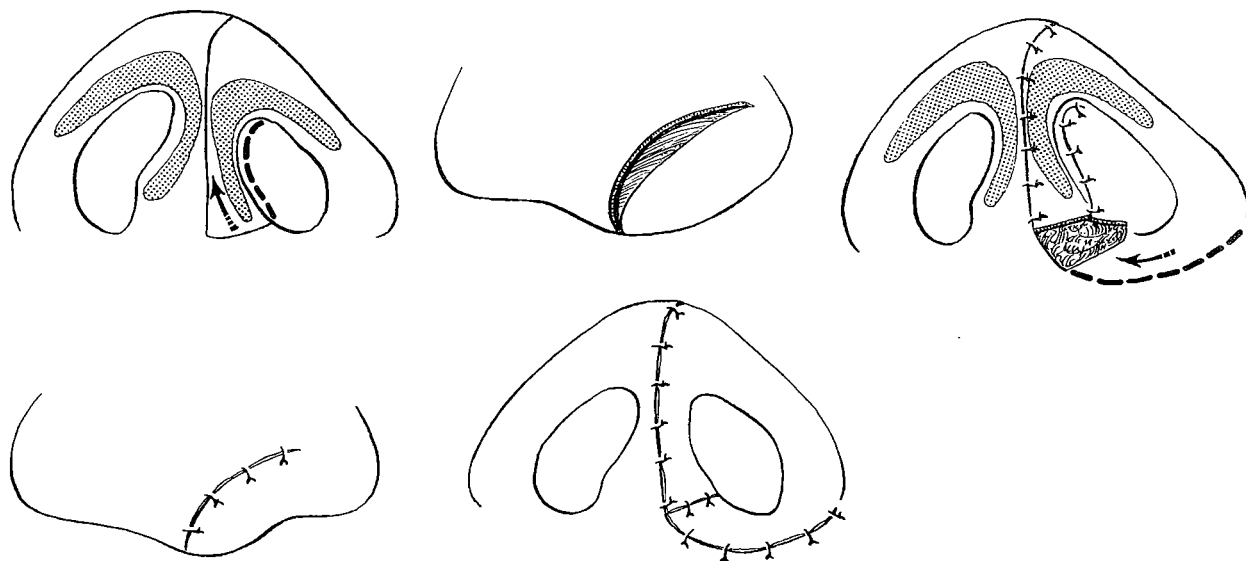
DINGMAN

In 1960 Reed Dingman, Chief of Plastic Surgery at the University of Michigan, published a paper on mandibular ostectomy for secondary deformities in the cleft lip palate syndrome. The overall results were quite dramatic, but Berkeley's jealous eye spotted the symmetry of the noses. As Berkeley subsequently wrote in 1971:

Although not mentioned in the paper, the nasal deformities were corrected according to the Joseph technique. Personal discussion with Dingman revealed that the curvilinear incision was at a level between the upper and lower lateral cartilages and extended into the mucous membrane fold in the interior of the nose. An ellipse of skin, and sometimes an even larger ellipse of mucous membrane was removed.

COMBINING THE COLUMELLA SHIFT WITH THE CRESCENT EXCISION

Evidently Kilner continued to use the Gillies alar shift operation but modified it by adding the Joseph crescent excision to facilitate the shifting of the ala in a circular and upward direction. He taught this to Peet, and in 1963 Peet and Patterson diagrammed the modification with the tip portion of the incision



curving over to the cleft side and including an elliptical excision of dorsal nasal skin.

WILKIE

In 1969 astute Theodore Wilkie of Vancouver revisited the alar shift operation, pointing out the possible reason for its fading into obscurity. He blamed the medical artist for carrying


... the upper end of the skin incision across the nose tip to the non-cleft side, so that many surgeons were no doubt led astray ...

and repeated it that way as did Barsky, Kahn and Simon in 1964 and Denecke and Meyer in 1967. Yet the original surgeons had designed it as diagramed, for in their text they stated plainly:

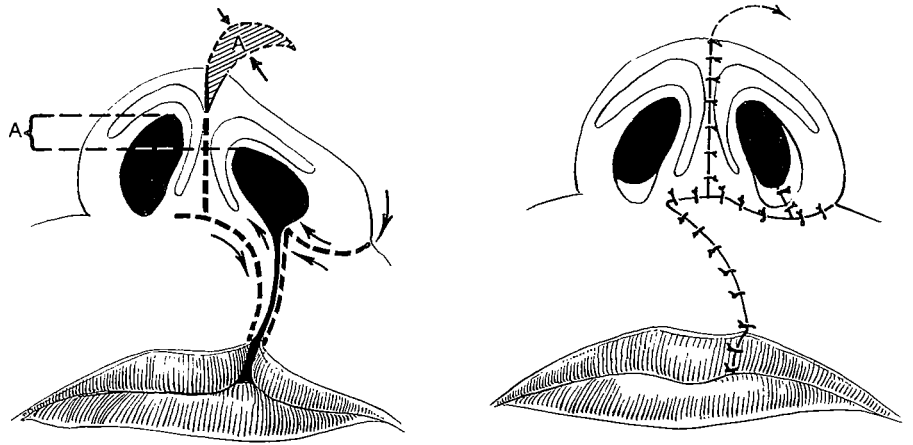
... and carried forwards into the tip of the nose curving towards the normal side.

I think I see the impish Puck in Gillies curving the incision away from the expected into the normal. It must have galled Kilner, for he informed Wilkie in 1961 of his regret at never having published his change. In fact, it is unfortunate for all of us that Kilner wrote so little.

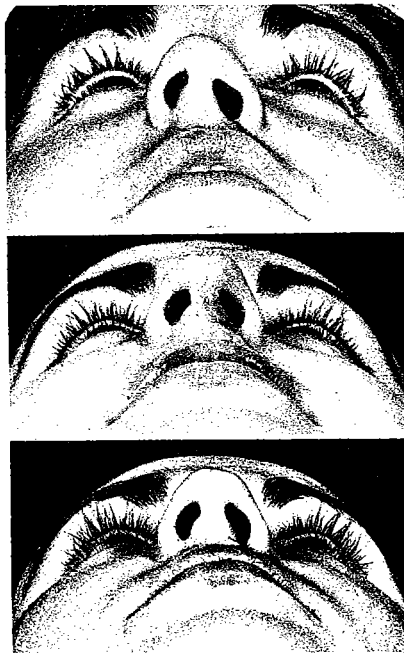
Intriguing points made by Wilkie were that the corrected design does erase the "hare look nose" and that



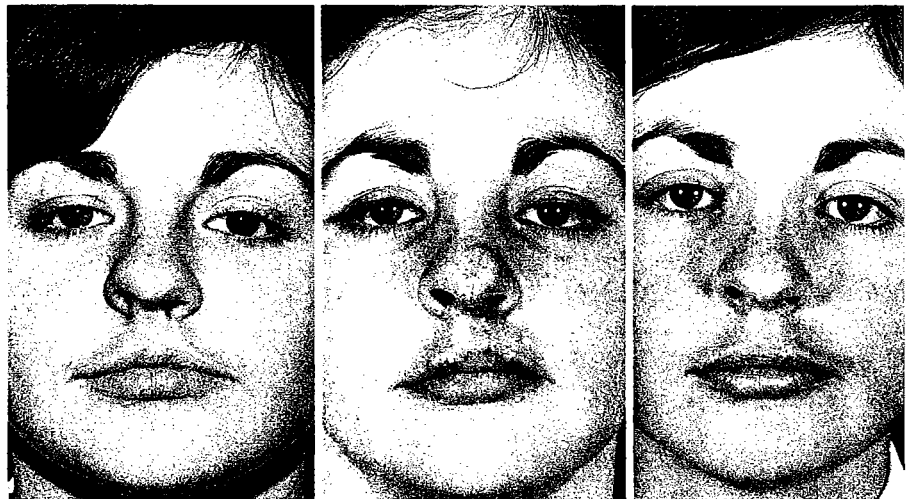Theodore Wilkie



Millard's operation is founded on the identical plastic principle as is Gillies and Kilner's alar shift, rotation of the medial component and advancement of the lateral component, utilizing all the tissues and placing them in their proper positions, with a minimum of interference with anatomical landmarks. It is a natural corollary that the two procedures can be combined in certain patients who need correction of both nose and lip deformities.



Wilkie forwarded this example of his combined operation on an 18-year-old student nurse with a cleft lip nasal deformity with a microform lip cleft which he published in January 1969 in the *British Journal of Plastic Surgery*.



After suture removal

Six months post-op.

Of course, the true hang-up for many surgeons, including myself, is, as admitted by Wilkie:

Against the procedure is the fact that an incision is made on the visible portion of the nasal tip.

Wilkie, like others who use the external tip incisions, argues:

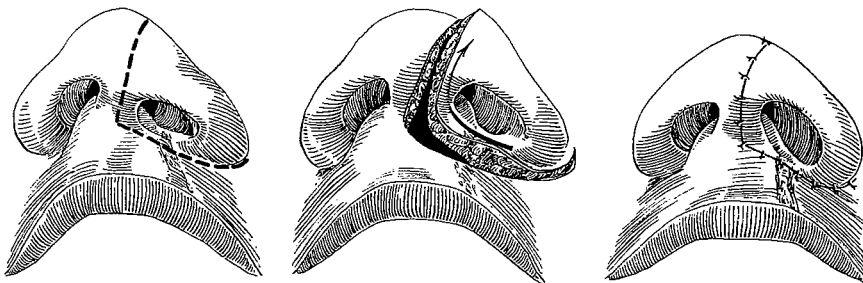
The improvement of form has more than compensated for the presence of a surface scar, which in any case usually fades nicely.

It is interesting that J. Manuel Velasquez and Fernando Ortiz-Monasterio of Mexico City more recently have begun using this similar combined approach. They advocate primary simultaneous hemi-rotation of the nose through an external incision and rotation-advancement of the lip adding Guerrero-Santos' denuded vermilion flap. They find the nasal scar unnoticeable but admit that two years is too soon to evaluate any effect on nasal growth.

BERKELEY

It would seem to me that Berkeley has put his heart and mind into cleft lip nose, and his 1971 article in Grabb, Rosenstein and Bzoch's book is the best yet written on the subject. As he admitted, Royster in 1961, with the Blair-type secondary correction, set him off in this direction, and he has now gone into orbit on the subject and from "up there" has combined what he sees as the best of all worlds:

To correct the lateral displacement, the entire ala is mobilized beginning in the midline of the columella and extending across the floor of the nostril at the junction of the floor of the nose and the lip, according to the technique introduced by Blair. A triangle of tissue is excised in the nasolabial region to adjust the long and short sides of the incision. As the cartilaginous septum is almost always displaced toward the normal side, it must be straightened. . . . As the nasal spine is usually present in the floor of the normal nostril, it becomes necessary to resect the nasal spine. . . . A submucous dissection is accomplished through the midline columellar incision. Vertical, parallel, partial-thickness cuts on the concave side of the exposed cartilage allow the cartilage to be brought to the midline without rebound action.



Thus has Berkeley combined Blair with Metzenbaum's septal straightening influenced by the cartilage work of Gibson and Fry. To this he added the method of Joseph:

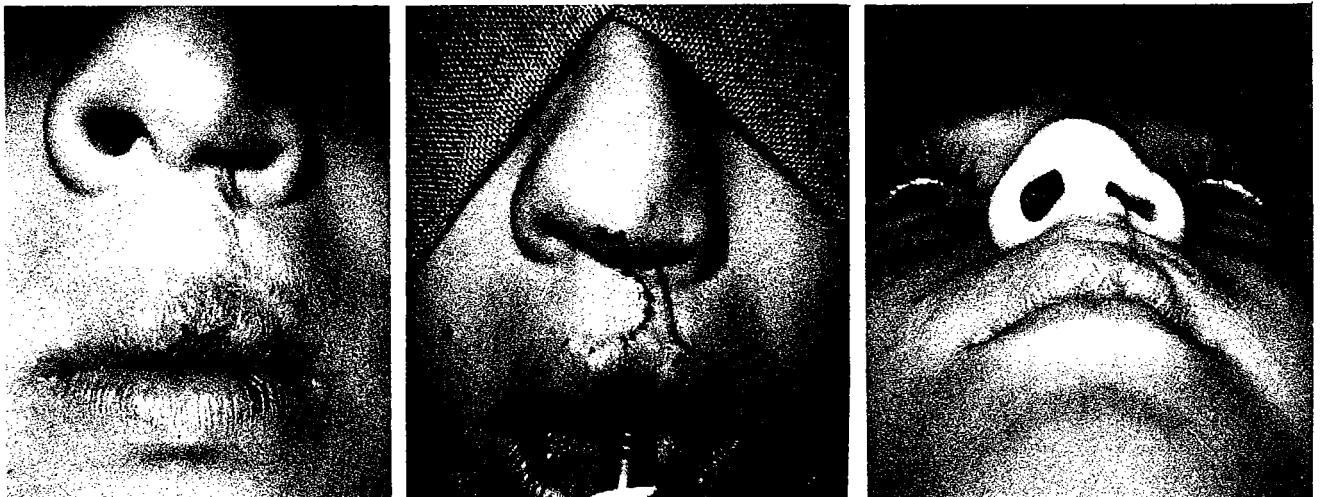When the cleft lip-nose deformity is severe, with a wide-set ala and extensive forward rolling, a combination of the Blair and Joseph techniques is indicated.

This, in fact, is the same as the description by Peet and Patterson of Kilner's design. Berkeley notes the importance of other corrective rhinoplastic procedures and winds it all up with the same defensive conclusion:

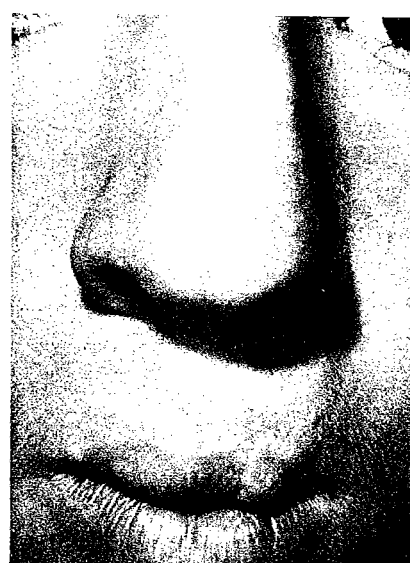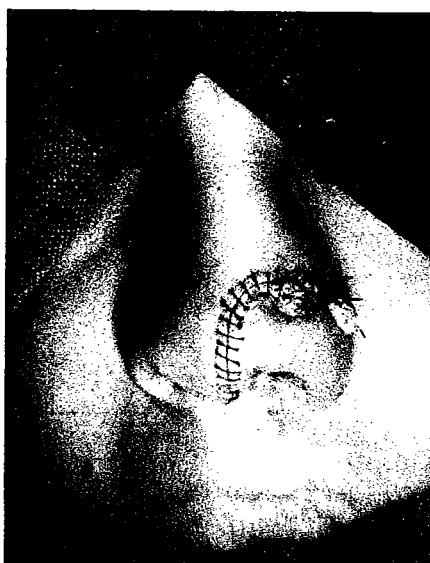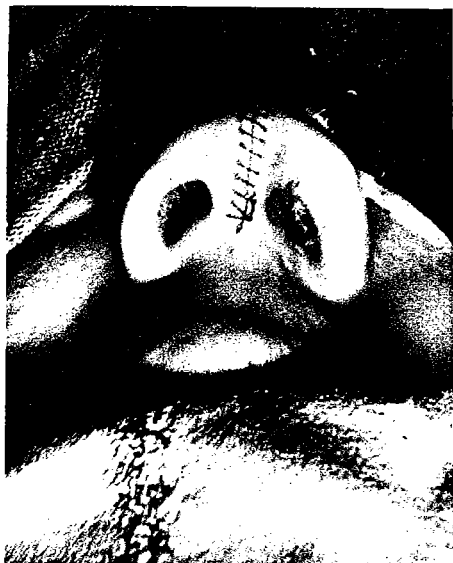The commonest objection that has been raised to the technique involving the external incision over the dome of the nasal tip is the resulting scar. This wound does mature in time without significant scar, so that it has not been necessary to resort to dermabrasion.

Even Berkeley admits that there are degrees of deformity which require variation in the extent of surgery. When there is severe distortion and the method chosen does not adequately place normal into normal position, the inadequate attempt has been well tagged by Berkeley as "another incident on the road to frustration."

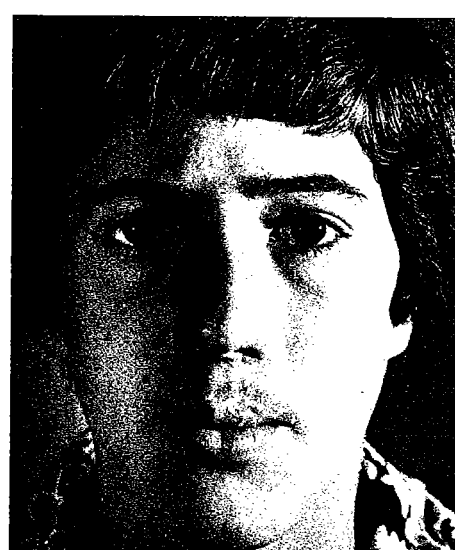
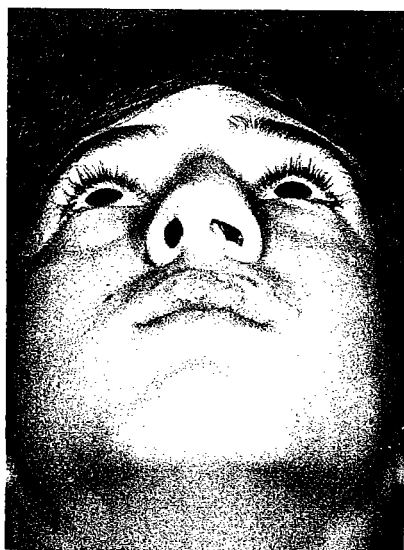
In preparation for Bill Berkeley's visit to Miami, a unilateral cleft which had had a straight-line closure was readjusted with a rotation-advancement procedure, positioning the alar base in symmetrical position. Special attention was directed toward leaving the remaining secondary nasal deformity intact.



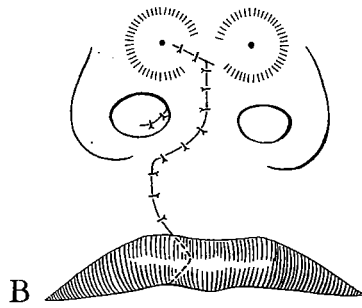
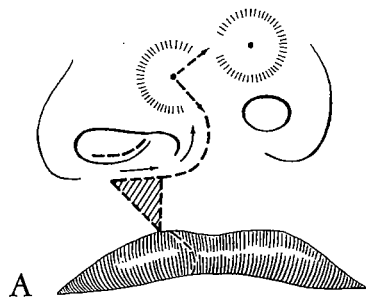
In 1971 Berkeley used the hemi-rotation of Joseph through a columella-splitting incision which extended up over the nasal tip curving around in the alar crease. No excisions were made, but the tissues were slid, lifted and sutured in more normal position.



The resulting conformity was good; the scar was quite visible when observed directly but by no means objectionable and hardly discernible in photographs.



A GRAPHIC EXPLANATION



Alexander Limberg of the Post-Graduate School of Medicine, Leningrad, in 1966 in *Modern Trends in Plastic Surgery* explained just what is happening to the skin surface during the hemi-rotation. With seemingly complicated sketches of models, he quite simply described the process of bringing together edges of angled incisions with coordinated movements of lateral shift and rotation of flaps, resulting in the closing and opening of angles. When a skin angle is closed, a standing cone or "pig's ear" is created, and when opened, a lying cone or wrinkle forms. Limberg then charted graphic application of this action in the hemi-rotation of the nose with evidence favoring the shifting toward closure of an angle on the cleft side nasal tip to form a *rising cone rather than crescent excision of that cone*. He accompanied his diagrams with this legend:

Pre- and post-operative stages of rotation-advancement of one half of the columella to correct the depressed ala deformity secondary to a harelip; the wound edges are equalized by excision of a triangular area from the lip scar.

TO SCAR OR NOT TO SCAR?

There is no question but that the total upward rotation and lift of the entire slumped half of the unilateral cleft lip nose as a composite unit is the easiest to perform and the truest to the principle of moving normal into normal position. To achieve this action effectively, the rotating incision must extend over the tip of the nose, resulting in a scar which usually heals well. When one pits *improvement in contour* against a *good scar*, there is a real temptation. Yet, if we reflect a moment on the scar, it may reflect back an oracle. At best the scar will be a line or a crease, but it may be discolored or show slight humping in contour or it may be smooth and shiny, catching and reflecting light. There are, at this time, these undeniable facts about scar: it is unpredictable, unnatural and, therefore, undesirable. Although Peacock predicts control of scar by 1980, until that time, in most unilateral cleft lip noses, I pass up the external tip scar and continue to search for an equally effective undercover method.