

46. *Shaping and Positioning the Lip-Switch Flap in Unilateral Clefts*

ALTHOUGH the need for a lip-switch flap is more common in bilateral clefts and was originally described by Robert Abbe of New York specifically for this condition, it also has value in unilateral secondary deformities. The lip-switch principle will be presented in Volume II on bilateral clefts, but its specific application in unilateral clefts is discussed here.

The shaping and the positioning of the Abbe flap are so closely interrelated that the surgeon should know where it is going before he tries to decide the shape to cut it.

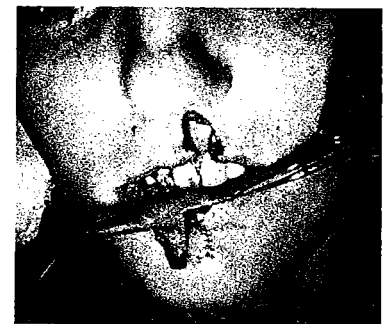Most surgeons, however, cut the Abbe flap to fill the defect they envision in the upper lip. Since the majority see it as a triangle, the usual shape of the flap has been a pie-wedge inserted unilaterally after excision of the scar. Some surgeons have seen the defect differently, and consequently some bizarre shapes have evolved.



Robert Abbe

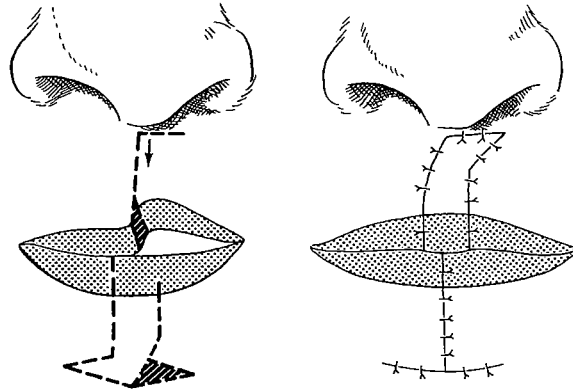
ODD-SHAPED ABBE FLAPS

An Abbe flap can be used for more than release of side-to-side tension or restoration of a philtrum. In 1963 a case with unilateral upper lip radiation scarring but attenuation of the entire vermilion free border inspired a three-pronged variation in the shape of the Abbe flap. The lower lip possessed comparatively voluminous vermilion, so an Abbe flap was designed with horizontal projections of vermilion taken not only to reduce the lower lip but to bolster the thin upper lip from behind. This



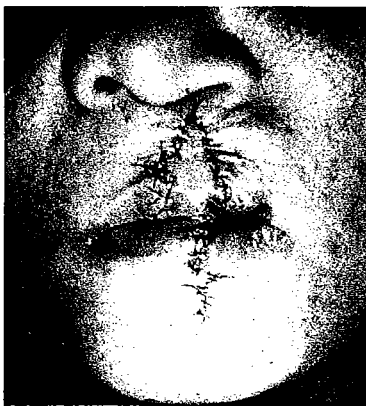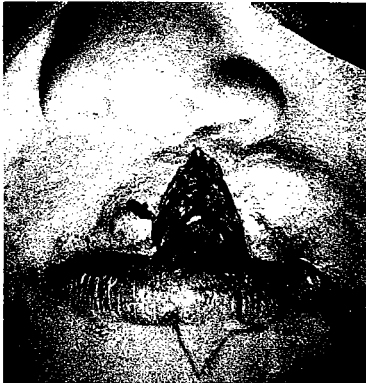fleur-de-lis-shaped flap was rotated on the coronary vessel, achieving the correction desired, and in 1964 I published the case in *Plastic and Reconstructive Surgery*.

Intrigued with the possibilities of other odd-shaped Abbe flaps, I reasoned that the Abbe could be cut in an asymmetrical skin pattern to correct a unilateral shortness at the same time it achieves release of tightness.



At Kingston Public Hospital, Jamaica, about 1963, a tight unilateral cleft lip with extensive crosshatch scarring required excision of much lip on one side. It was thought that if a small releasing incision was made on the medial side of the defect an asymmetrical Abbe flap sporting a corresponding unilateral triangular projection might create a cupid's bow in the spirit of LeMesurier. The pedicle was divided after my departure from the island, and the patient never returned to register her happiness or displeasure.

Although this specific patterned Abbe is a utilitarian space filler to replace missing tissue in specific areas, it has so little artistry in its patchwork effect that I became disenchanted, particularly because about this time the value of the central Abbe as a philtrum became clear. Usually unilateral local lengthening can be achieved during the midline splitting of the upper lip without the addition of side flaps. However, some secondary cleft deformities are so grossly scarred that the multi-pronged Abbe as a one-shot corrective measure has appeal.



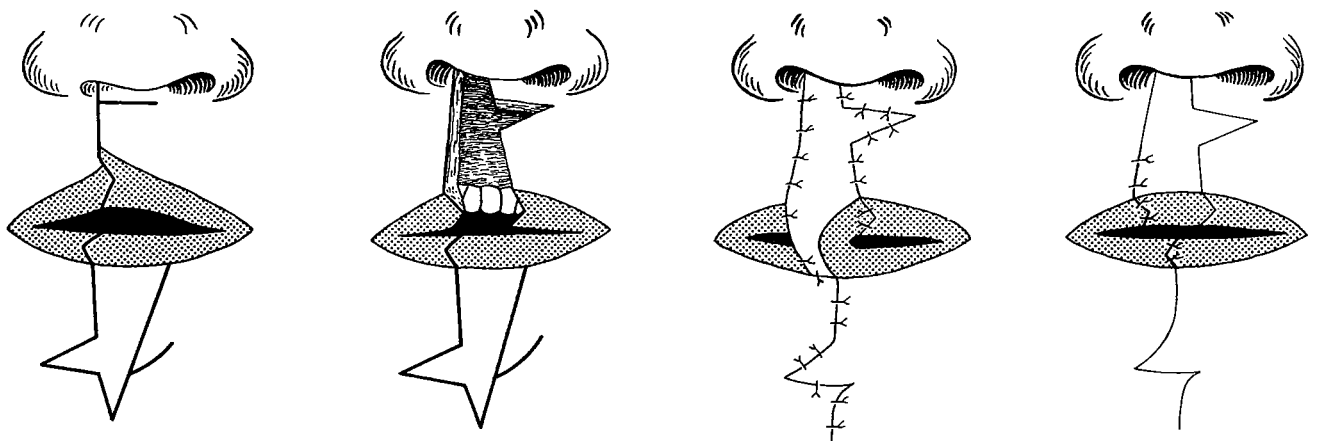
A SPARK OF FREEDOM

Genrikh Vladislavovich Kruchinskiy, professor at Byelorussian Institute for Physician Training and a prolific writer, in 1969 while at the Moscow Clinic of Stomatological and Reconstructive Surgery ingeniously extended the principle of the double-axis Abbe in 15 cases and presented one. He wrote:

Especially in patients with repeated surgery for congenital clefts of the upper lip and palate, the lip is often extremely sunken, diminished not only in the transverse direction but conspicuously shortened as well . . . is often accompanied by narrowing of the nostril on the side of the former cleft. . . . To make possible a simultaneous enlargement of the upper lip in both transverse and longitudinal direction it was proposed to cut out from the medial part of the lower lip . . . a wedge-shaped flap of skin, muscle and mucosa which had three opposite, transversely oriented tips. . . . Before cutting the flap it was necessary to measure accurately the size of the defect of the upper lip. . . . The basic mass of the flap was cut out in its entire thickness together with the mucosa, the lateral wedges comprised of skin and partially of muscle of the lower lip. The wedges on both sides of the basic flap were cut at different levels to a premeditated plan. . . . The wedge-shaped flap . . . was rotated 180° and the upper lip was cut in its entire thickness along the old scar . . . two horizontal non-penetrating incisions were carried out on both halves of the lip corresponding with the length and level distribution of the additional skin wedges on the wedge-shaped flap. . . . Observations confirmed that wound across the red was later on replaced by a scar pulling inward. It was usually possible to avoid this pull if the incision line in the red was broken . . . after 10–12 days the nutrient "pedicle" was cut off.



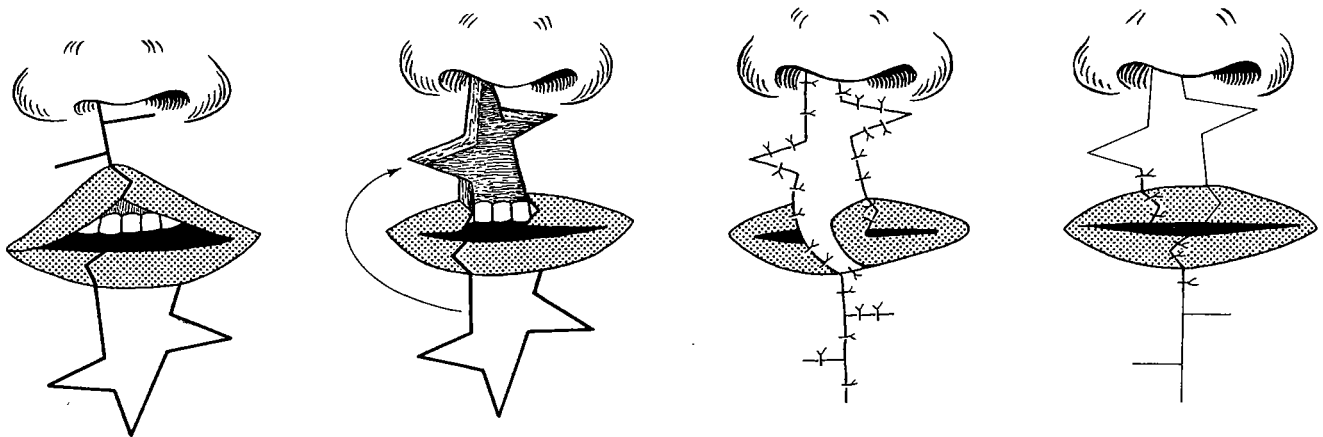
Genrikh Kruchinskiy



When the nostril was narrow on one side, Kruchinskiy directed the medial tip of the main flap into the nostril:

If the nose vestibule was narrowed, the nostril was cut through and, in order to form the nose vestibule, the flap was cut a little longer in the area of the chin.

Closure of his donor area varied with the pattern of the flap.



One cannot but be impressed by the intriguing designs of these flaps, suggestive of atypical stars cut by a special Soviet sickle. It is even possible to conjecture that Kruchinskiy enjoys his series of the world's most unusual Abbes much as he does his collection of rare and valuable stamps and postmarks.



UNILATERAL POSITIONING OF THE ABBE FLAP

For years expediency of flap placement has held more enchantment for the surgeon than the artistry of the lip construction. If the defect was in the left of the upper lip, the flap was simply taken from the left side of the lower lip and that was that. In fact, Hogan and Converse seemed to make good sense when they said,

The Abbe flap should come from a portion of the lower lip which corresponds to the defect in the upper.

Robert Chase of Stanford, accepting this premise, turns to higher mathematics and calculates his donor area according to the projected strategic position of the pedicle when the flap has

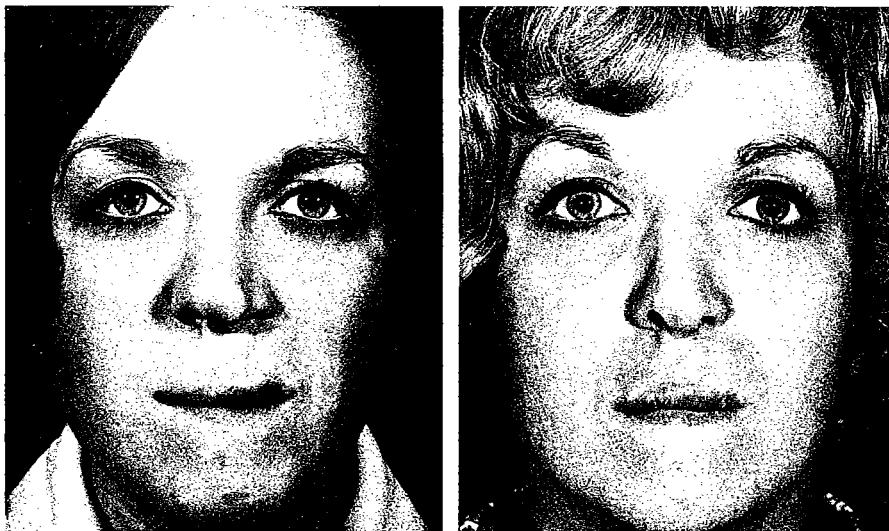been transposed. This solution would be brilliant if the first premise were true.

Ian McGregor comes closer, but not for the reasons I think are of prime importance. He said in his Scottish brogue,

It is usual to make the flap symmetrical about the midline of the lower lip. . . . Of course there is no theoretical reason why the flap need be made in the middle of the lower lip, but it does make it easier to match the thickness of its red margin when the two sides of the lower lip are being sutured together.

General acceptance of the automatic off-center positioning of the Abbe flap among the high echelon of plastic surgeons was further confirmed by Paul Tessier of Paris, who as late as 1969 wrote in *Annals de Chirurgie Plastique*,

With the bilateral, the result of the Abbe is better than with the unilateral, since the flap is midline and simulates a philtrum (even the scars give this illusion), and because it restores the appearance of a cupid's bow. On the other hand, with the unilateral, the symmetry of the lip remains mediocre.



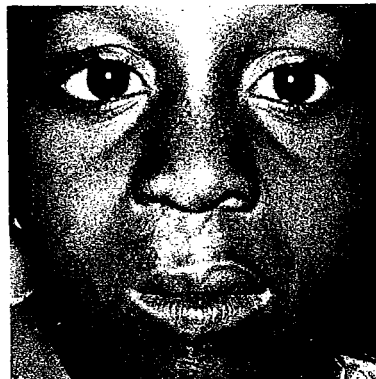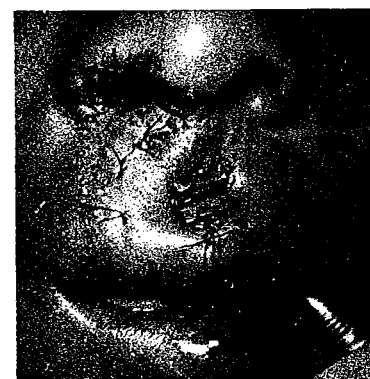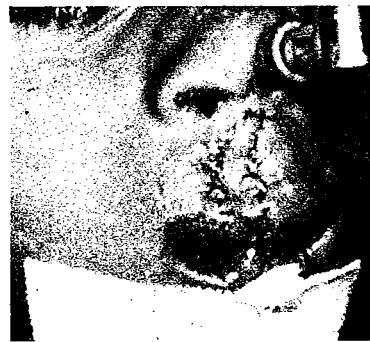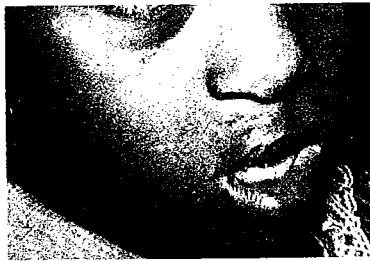A unilaterally placed Abbe flap, of course, will release tightness and form an adequate lip but without the slightest hint of artistry and with no construction of natural conformity; even after multiple minor revisions, including a cupid's bow procedure, it still probably will not create a curvacious lip.

A UNILATERAL BUT ASKEW POSITIONING

When there has been excision of the natural cupid's bow during the cleft edge freshening for a straight-line or a Blair-Brown closure, some tightening of the upper lip will take place, especially along the free border. Such a case is benefited by the introduction of a composite flap from the lower lip.

The off-center insertion of the flap seemed logical on account of the unilateral position of the original scar. Yet observation of cases treated in this manner had been universally disappointing. In one tight upper lip, described in the January 1964 *British Journal of Plastic Surgery*, the unilateral scar was excised and the medial lip component rotated, with the releasing incision extending under the columella base. The tail of the lower lip flap was transposed into the rotation gap and the vermilion border of the flap set at an angle to simulate the missing half of the cupid's bow. As often happens with midline lower lip flaps, there was a dimple, which is coveted for a midline position but abhorred off-center. Midline subcutaneous tissue and muscle were excised, and the skin was held for a time in depressed position by sutures tied over a piece of rubber.

The early result looked quite promising, but eventually, on account of the equal length of the two sides of the Abbe flap, the bow effect straightened out. If the lateral side of the Abbe could be made shorter than the medial to give a bow peak heist, the result would be better. The final result was an improvement, but the surgery was too complex to be practical. Nevertheless, I prefer this setting of the Abbe flap slightly askew to balance out the effect of a cupid's bow rather than use all or half of the Gillies cupid's bow procedure.



HALF OF A CUPID'S BOW ON TOP OF THE ABBE

Whenever an Abbe flap is introduced unilaterally, the results will be unnatural. A method of camouflaging the off-center insertion of the lip-switch flap is the one-sided use of the Gillies cupid's bow operation. Gillies used this principle for multiple problems. In 1963 the dour and diligent Ian McGregor of the Royal Infirmary, Glasgow, Scotland, specifically advocated unilateral insertion of the lower lip flap and secondary correction in this manner:

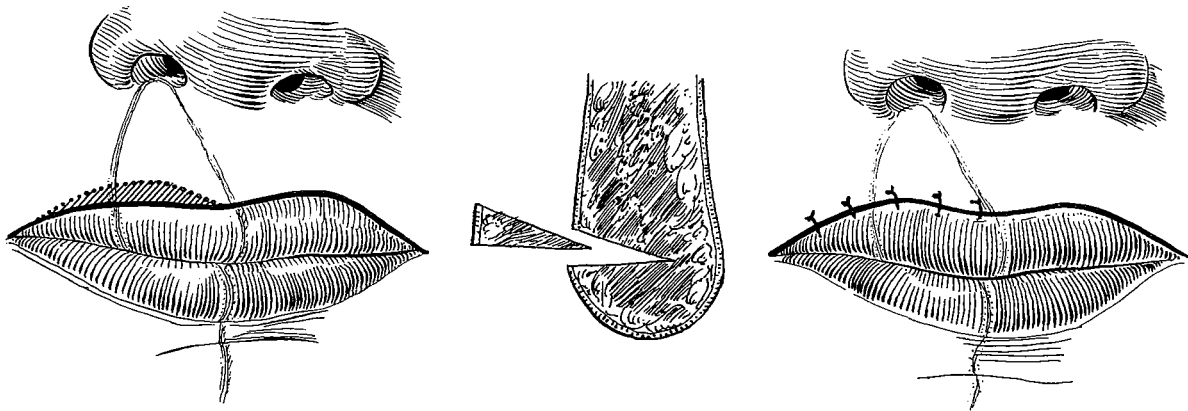


Ian McGregor

Usually half of a cupid's bow is present on the normal side of the lip and a cupid's bow type operation is then required to match the line of the flap with that of the remainder of the lip.

He emphasized:

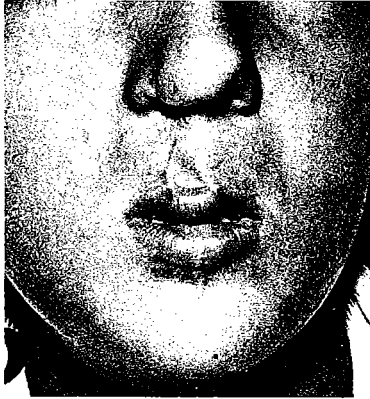The line of the cupid's bow is made in the usual way but instead of merely excising skin, the excision is carried deeply, including muscle down to mucosa. This enables the whole wedge of red margin to be brought up, moving like a door on the hinge of mucosa.



There are two modifications that can improve this operation. First, the white skin roll ridge should be preserved and the incision for lifting the vermillion placed parallel with but just above it. Second, the elliptical excision of skin and muscle should not actually be cut off but only denuded of epithelium, cut as a flap with its base medial and transposed as a dermomuscular flap into a tunnel along the line of the missing philtrum column.

MIDLINE ABBE IN UNILATERAL CLEFTS

Irritated into midline action



Utter unhappiness with off-center Abbe flaps stimulated my closer observation of the areas involved. Again, landmarks eventually crystallized the obvious direction of action. It was noted that quite often there is a semblance of a dimple or groove in the midline of the lower lip, and it was further noted that when the lip-switch flap was cut narrow this dimple seemed to become more obvious and persisted after transplantation. Its persistence made the flap unsuitable for unilateral duty but increased its value as a natural-looking midline philtrum. Thus, *the spell was broken* for me of the long-accepted off-center placement for all lip-switch flaps in unilateral clefts and it was suggested that

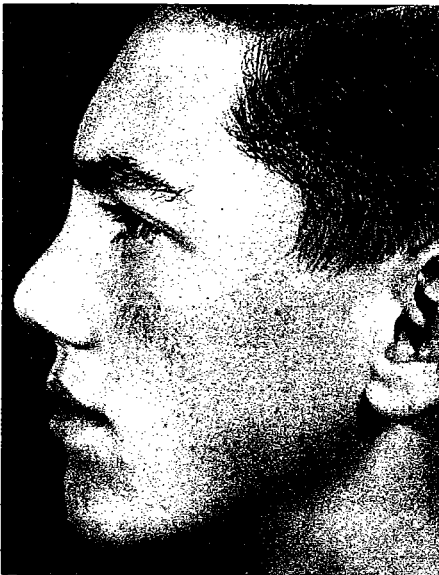the previous unilateral scar be ignored and the tight lip be split in the midline so that the dimpled flap can have a central inset.

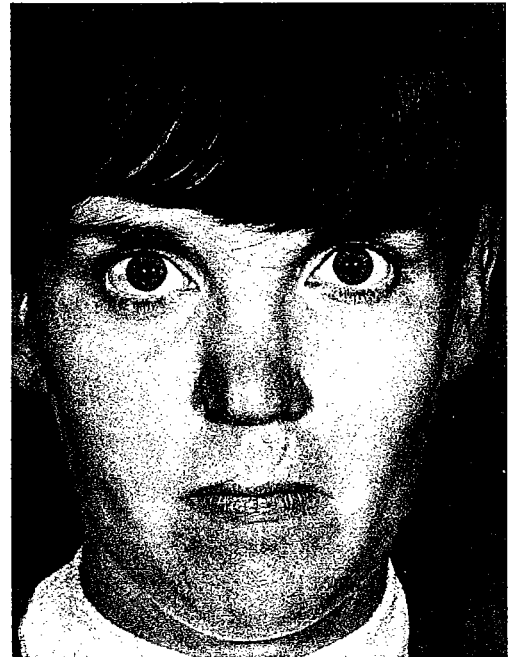
It is also important that the tail of the flap, when switched, be inset *all the way* up to the base of the columella, philtrum-like. If it is inset only partway, it will look like exactly what it is: a stuck-on flap.

And so early in 1962, ignoring the unilateral cleft scars, I inserted several philtrum-shaped Abbe flaps into the midline of lips that were slightly tight, particularly along the inferior free border because of Brown-McDowell inferior triangular flap primary closure.

The midline Abbe flap results were encouraging, with relief of tightness, achievement of lip balance, creation of a philtrum and often a dimple and a rather surprising improvement in the untouched unilateral lip scar. Of course, this scar revision after the insertion of a tension-releasing flap offered an even better prognosis as seen.

Midline placement of both flaps and grafts was described in detail and demonstrated by the above pair of cases in the article "Composite Lip Flaps and Grafts in Secondary Deformities," which was submitted to the *British Journal of Plastic Surgery* in





The patient returned 10 years later happy with her Abbe but requesting minor revision of her unilateral scar.

April 1963 but not published until January 1964. Subsequently, it came to my attention that in their book *The Essentials of Plastic Surgery*, which was published sometime in 1963, Peet and Patterson devote a short paragraph to this subject without photographs of results:

Independently

Some unilateral cases also require additional tissue in the upper lip to restore normal lip relationship. In these subjects it has proved best to divide the upper lip in the midline and not through the lateral scar line. The end result is a centrally placed flap with two vertical scars on the cleft side. Some months after the transfer, the narrow strip of skin between the two scars may, if necessary, be excised and the gap closed after adequate superficial skin undermining. This is the best way of producing a symmetrical upper lip.

I do not agree with this excision in most cases

As Peet preferred a straight-line closure of unilateral lip clefts, it is likely that he often had occasion to use an Abbe flap as a secondary procedure. This is not a popular method in this country, so there is little occasion to see straight-line closures and rare occasion to switch a lower lip flap into them. In the latter operation, the flap should be inserted in the midline.

Others concur with midline position

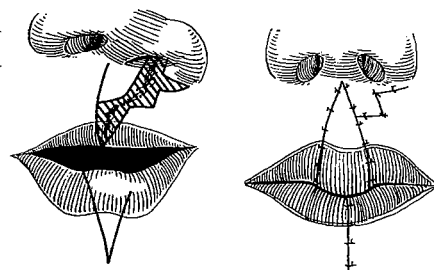
Professor J. Lachard of Marseilles also prefers the median placement of the Abbe flap in unilateral clefts. This fact was brought to my attention by the excellent 1970 medical thesis "Traitement Chirurgical des Séquelles du Bec-de-lièvre," by Raymond Gola, an astute young oral surgeon of Marseilles.

Recently, other surgeons have joined the bandwagon of the *midline Abbe in unilateral clefts*. In 1970, Schuh, Crikelair and Cosman reviewed 50 Abbe flaps used between 1940 and 1965 at the College of Physicians and Surgeons, Columbia University, New York, and concluded:

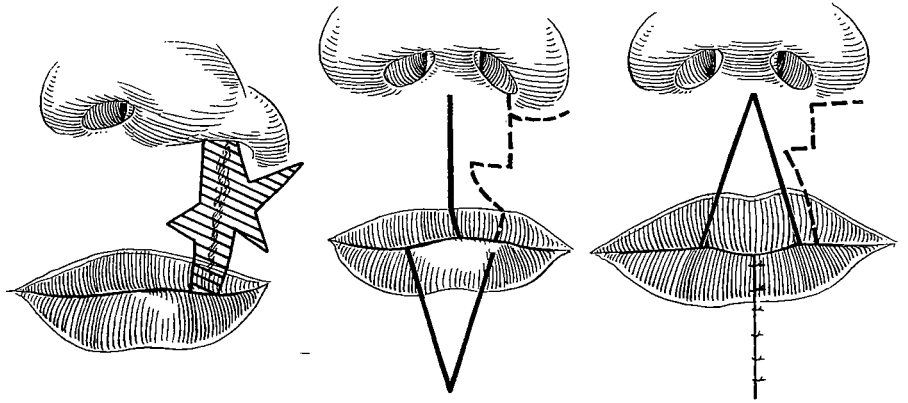
A majority of the problems have been associated with asymmetrical lateral placement which draws attention to the most minor irregularity. Many difficulties would be eliminated if all flaps could be placed centrally.

Amen!

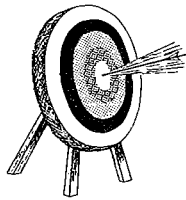
By 1970 Onizuka was also using a midline Abbe in unilateral clefts. He showed various unilateral scar revisions followed by



vertical midline division of the upper lip and insertion of a small philtrum-shaped Abbe flap.



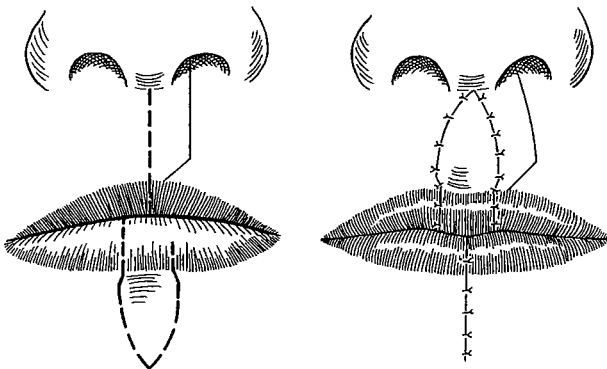
Hogan and Converse in 1971 devoted pages to the midline placement of the Abbe, repeating many of the points originally brought out in my first paper. They showed one early unfinished postoperative result.



A bull's-eye for Blair-Brown

The secondary cases that I began to find with tight upper lips had most often had a Blair-Brown triangular flap closure primarily. In these a small *midline* Abbe flap transposed from the middle of the lower lip has been a bull's-eye. Another aspect of the Blair-Brown result that lends itself specifically to a midline Abbe is the smooth convex "rainbow arch" of the mucocutaneous border without any remnant of a cupid's bow double curve. The typical asymmetry of the vermilion free border can be corrected prior to, during or after insertion of the Abbe flap.

This is the key to the midline Abbe design



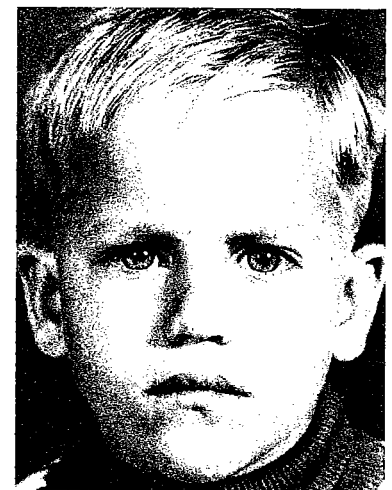
Shaping the flap

The actual shape of the normal philtrum with its central dimple, if marked along each crest of the philtrum column and along the mucocutaneous junction line of the cupid's bow, is a slender shield of King Arthur's court sitting upside down. To simulate the normal philtrum, the lower lip flap should also, when possible, be reasonably slender and similarly shield-shaped. Unfortunately, the lower lip does not have the central skin peak of the upper lip bow, but there is a trick that will suggest this effect. Cut the flap narrower at the vermilion border so that it measures the transverse width of a normal bow from peak to peak. The flap's midline point between the two lateral lip elements will be strongly suggestive of the cupid's bow.



Speaking of dimples

The advantage of taking the shield-shaped Abbe flap from the center of the lower lip is to incorporate its normal midline groove and transport it to re-create the midline philtrum dimple of the upper lip. For example, although the accommodating dimple in this case was never required, as the rotation-advancement method preserved the upper lip philtrum, it was certainly present and available.



Reducing the pedicle

The transposition of the lip flap 180 degrees out of the lower lip and its insertion almost completely into the upper lip is facilitated by the least amount of pedicle. The pedicle can quite easily be reduced to a slim band of posterior, superior mucosa of the free border including the labial coronary vessels and a few protective fibers of the orbicularis oris muscle. In fact, this unit is, in essence, an island flap.

Role of white roll

Several surgeons have asked about using the white roll flap for bilateral mucocutaneous interdigitation during Abbe flap insertion. Of course, it is a possibility and can always be called upon secondarily. Personally, I have not found it necessary as primary

alignment can be extremely accurate, particularly if all apposing mucocutaneous white rolls of the upper lip and Abbe flap are stab-marked with a needle dipped in methylene blue before the incisions are made.

Improving old scars

By mere introduction of the lower lip tissue, the upper lip is released. This relaxation often simultaneously improves the previous cleft scar. If not, it can subsequently be revised with optimism now that the upper lip tightness is less. Abrasion may give the polishing touch.

It may be argued that a centralized Abbe flap adds two extra scars to the upper lip and one in the lower. Right, but if the operation is done with precision so that the scars are reasonably unnoticeable, the gain in normal conformity is more than worth the price of scars.

Donor closure

The slender shield shape of the lower lip flap offers a double dividend because the narrower the flap, the less the lower lip suffers distortion. Even when the upper lip is quite tight and the lower lip excessively protuberant, a slender flap is doubly effective as it relieves one while tightening the other. The shield-shaped donor area is closed with slight lengthening to offset any tendency toward straight-line contracture. A Z-plasty of the lower lip closure is as unnatural as any other scar criss-crossing natural lines. If the flap was long enough to cause the donor scar to extend from the lip well down into the chin, a straight-line closure is still the best primary bet. If the scar pulls a web at the lip-chin junction, then a small Z-plasty, as suggested by Ian McGregor, may be of value, but only as a secondary procedure.

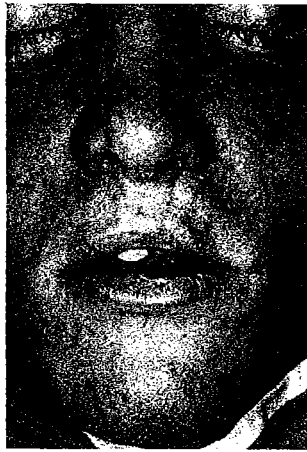Return of function

Investigators have reported that sensory, sympathetic and motor reinnervation of the flap occurs, requiring from nine months to two years.

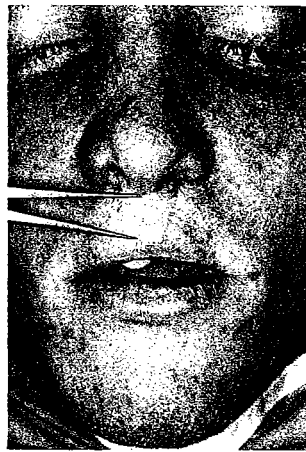Lights, camera, action

It would seem that the best way to explain my preferred method of shield-shaping and midline-placing of a lip-switch Abbe flap in a suitable secondary unilateral cleft lip is to do one and back it with cases. So here goes!

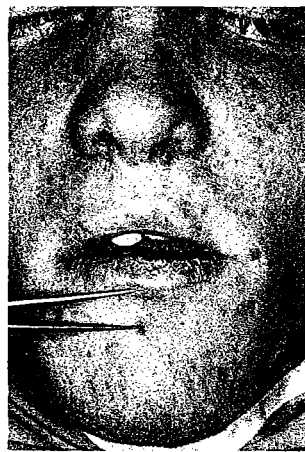The nasal correction has been completed. The upper lip with its unilateral almost straight-line scar has no cupid's bow, no dimple, no philtrum column on the cleft side and is relatively flat and tight as compared to the slightly protuberant lower lip. A perfect situation for a small shield-shaped Abbe flap placed in the midline. There is less danger if the Abbe flap is done under local anesthesia.



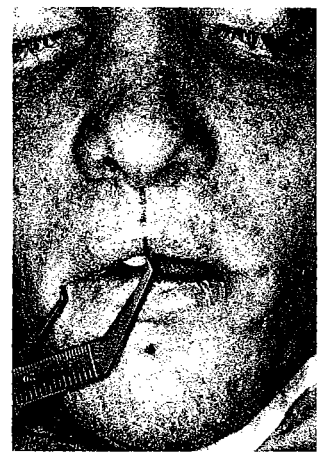Vertical length of lip seems good, so



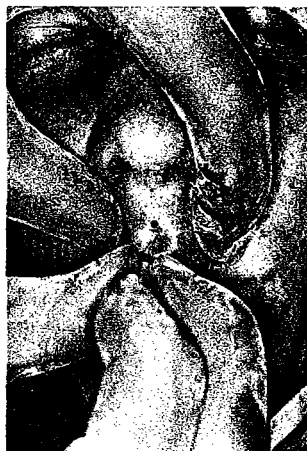measure it from columella base to mucocutaneous junction.



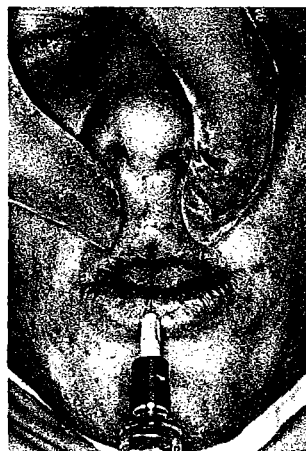Duplicate measurement in midline of lower lip.



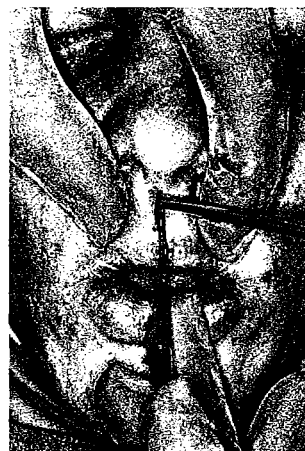Mark incision for release and check midline position.



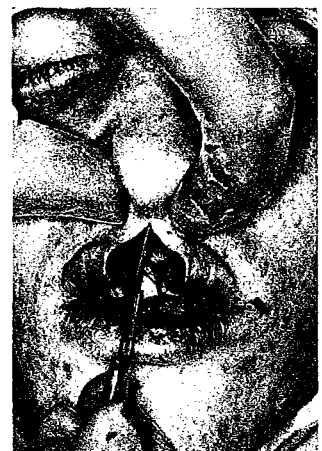Stab-mark midline M-C junction with methylene blue.



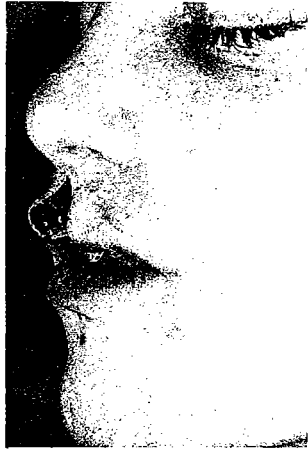Midline injection of Xylocaine-Adrenalin.



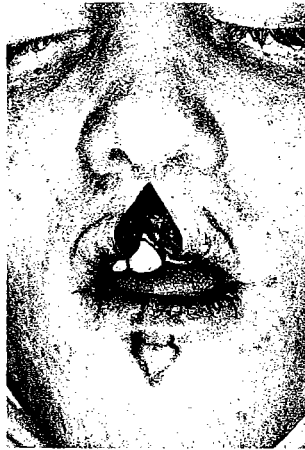Midline incision.



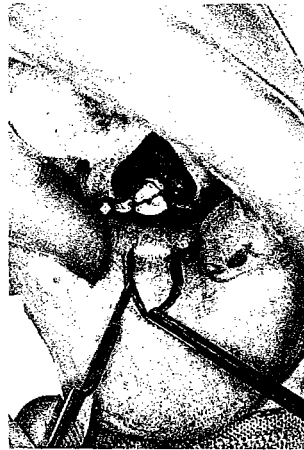Release with No. 11 B-P blade to columella.



Upper lip release shows eversion. Lower lip dimple to become philtrum.



Mark shield-shaped Abbe flap size of ideal philtrum, not size of upper defect.



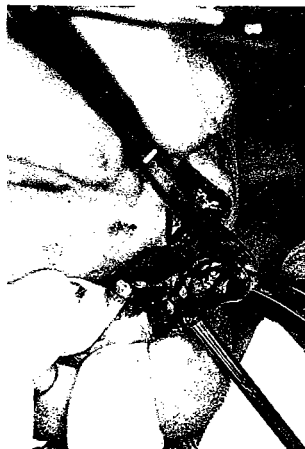Scoring the skin.



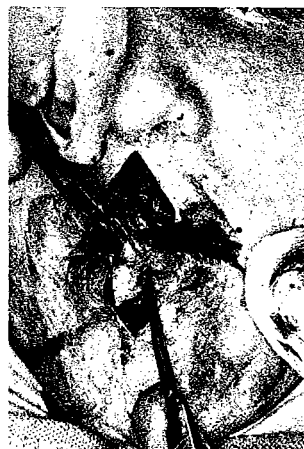Dividing the free side of the flap.



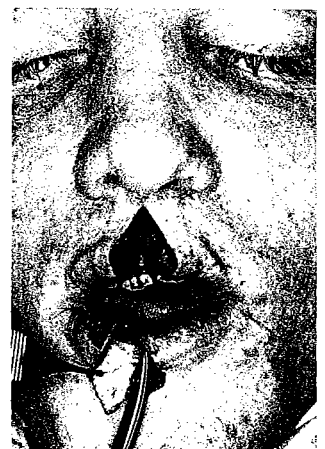
Position of main coronary vessel noted.



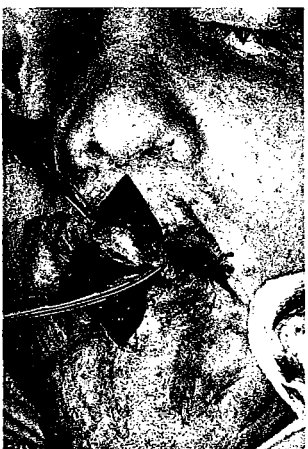Hemostasis obtained.



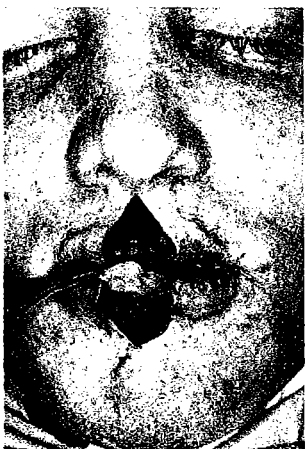Cutting the flap free.



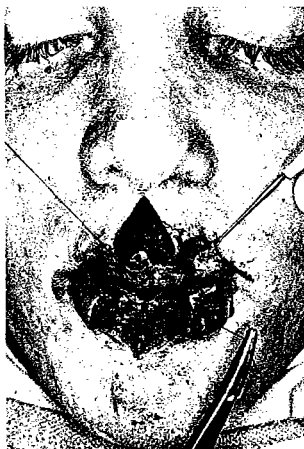Crossing the opposite mucocutaneous junction.



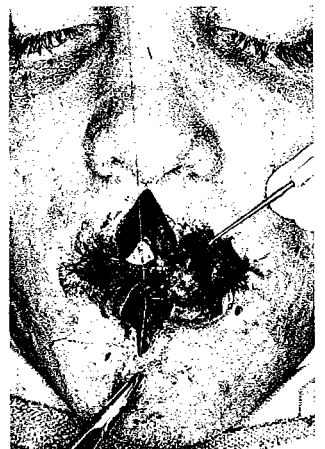Reducing the pedicle almost to the vessel.



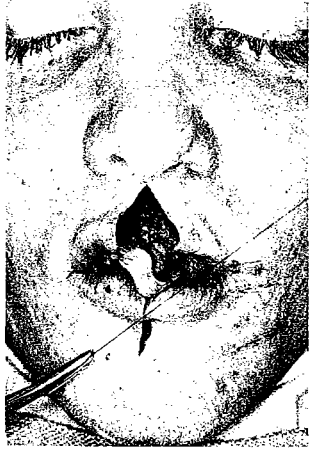Swinging the flap.



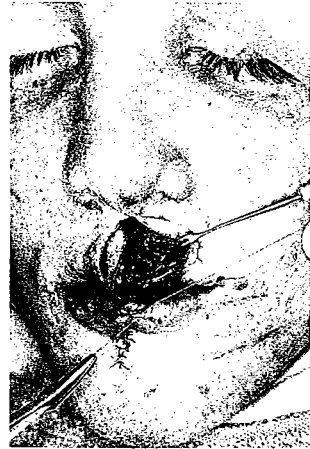Mucosal closure of donor area.



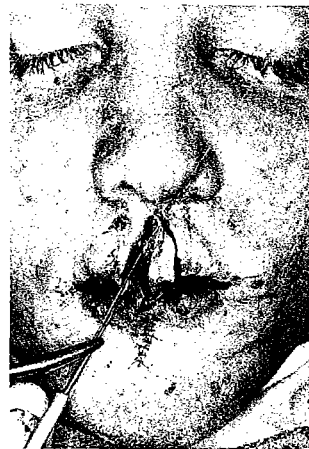Muscle closure with Mersilene.



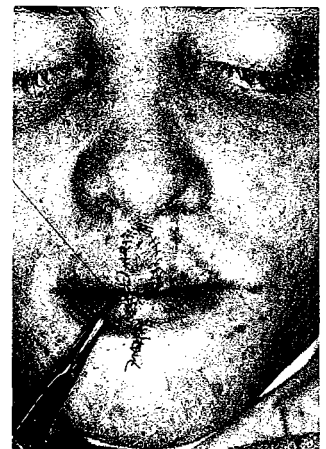Approximating landmarks in skin vermillion closure.



Suturing posterior mucosa of flap insert.



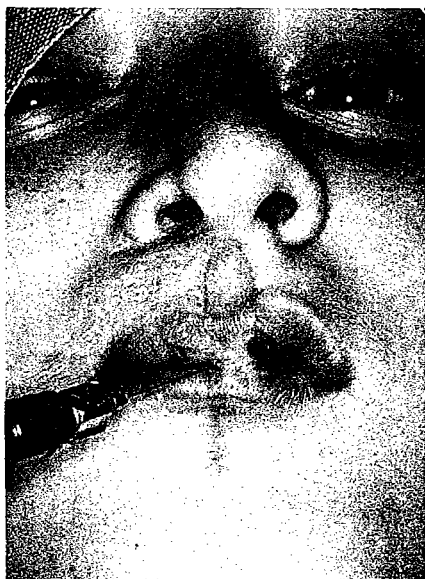Joining muscle to muscle.



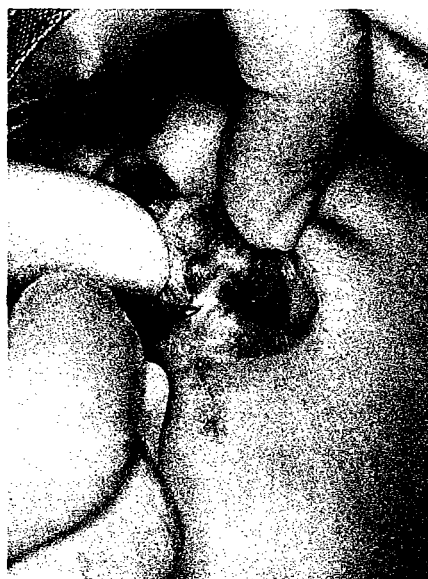Final skin suturing.

Division of the pedicle

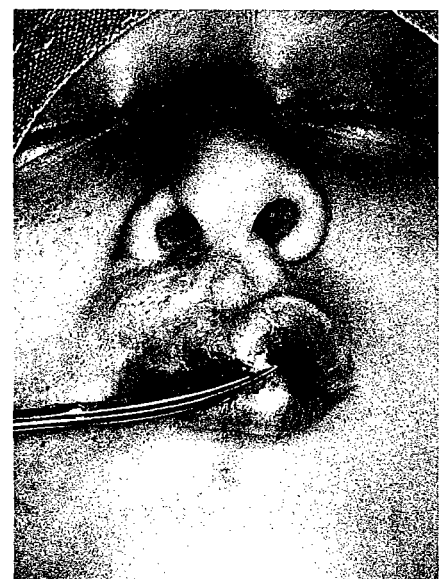Eight to ten days later, the pedicle is divided under local anesthesia as an office procedure. In the series of Abbe flaps shown in this volume, the average time of pedicle division was 11 days. Actually nine days is sufficient and safe, but when a weekend was involved, the division was delayed a day or two with plus and minus advantages.



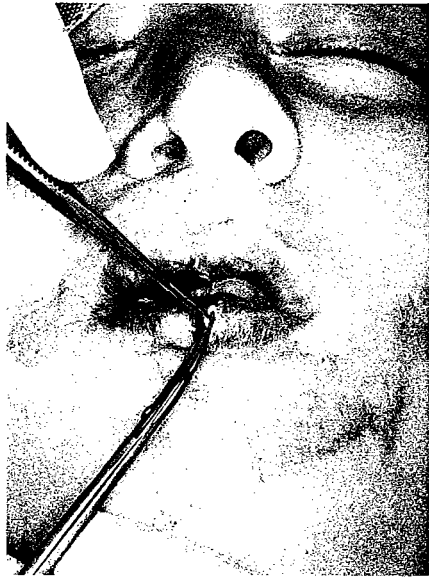Local injection of pedicle.



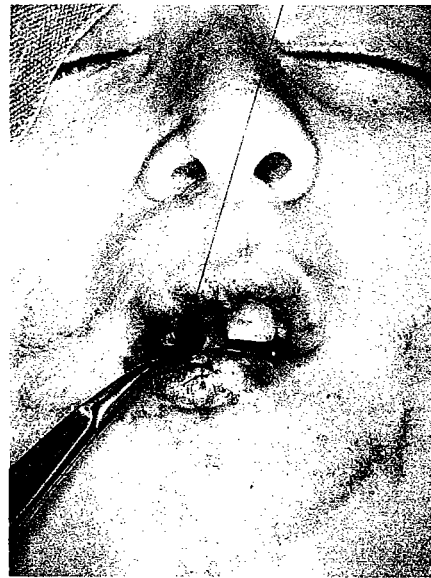
Transverse division of pedicle—scalpel



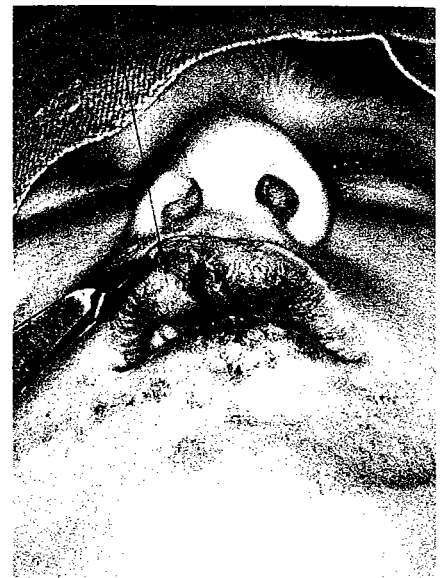and scissors.



Edges tailored.



Lower lip sutured.

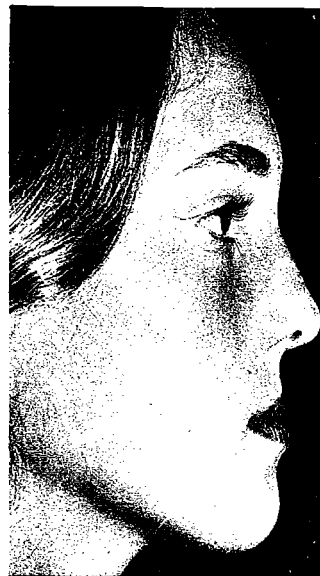
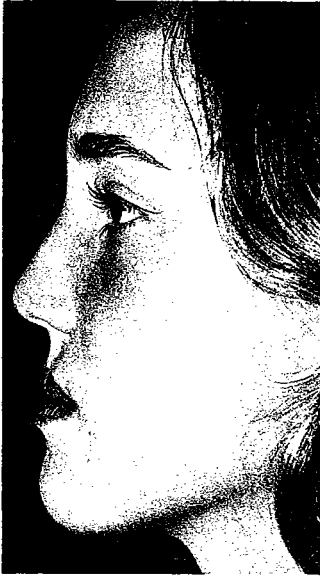
Upper lip sutured.

MIDLINE ABBES I HAVE KNOWN

Postoperative results—Mirault-Blair-Brown-McDowell closure

It is not always possible to distinguish a Mirault-Blair from a Brown-McDowell except that in the latter the inferior triangular flap is smaller and the results are better. Cases that come to secondary correction consistently have the angled, unnatural scar with its straight-line extension directly into the floor of the nose. The mucocutaneous ridge is usually interrupted and makes a single arc with no evidence of a cupid's bow, philtrum or dimple. The vermilion free border has a cleft side bulge and no midline tubercle. The lower portion of the upper lip is tight, exaggerating the relative protrusion of the lower lip. There is the asymmetrical nasal distortion.

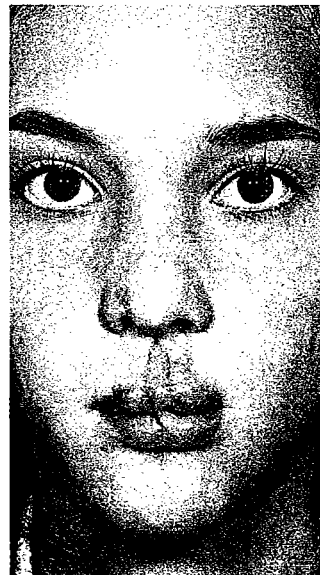
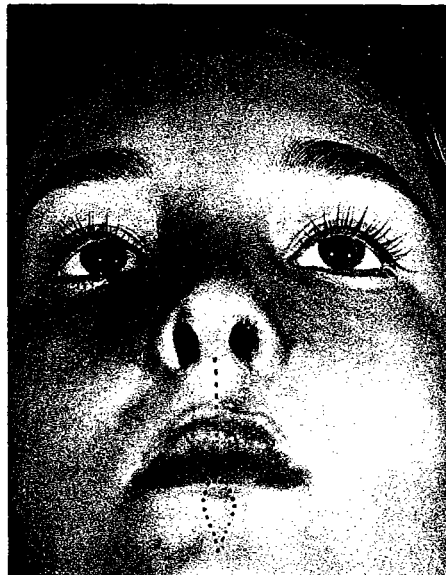
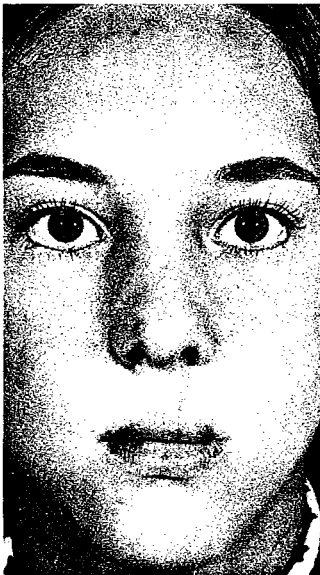
Result after Blair-Brown type closure.

6-7-73. CL rhinoplasty alar cartilage lift, septal straightening, alar base advancement, septal cartilage strut in columella to nasal tip.


20 years

Improvement in the nose caused lack of lip landmarks to become more objectionable.



8-9-73. Midline 1.4 cm. shield-shaped Abbe flap. Division of pedicle after 8 days.

20 years




12-12-73. Minor lip revision.

21 years

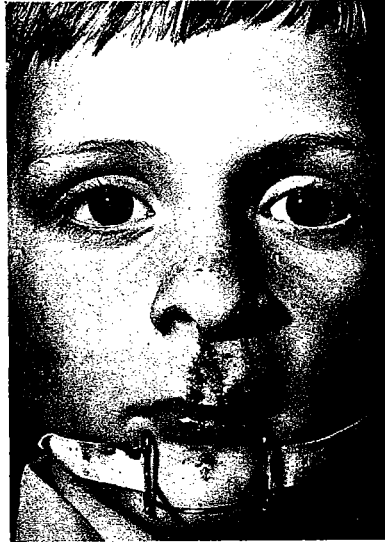This Georgia boy had an angled scar and tightness along the inferior border of the upper lip, no cupid's bow or philtrum and a flaring ala.

Result after Blair-Brown type lip closure.

2-26-69. Midline 2 × 1 cm. shield-shaped Abbe flap. Division of pedicle after 10 days. Lip revision to follow.



5 years



6 years



10 years

This 12-year old boy had a characteristic scar, relatively tight upper lip lacking natural landmarks and a typical cleft lip nose.

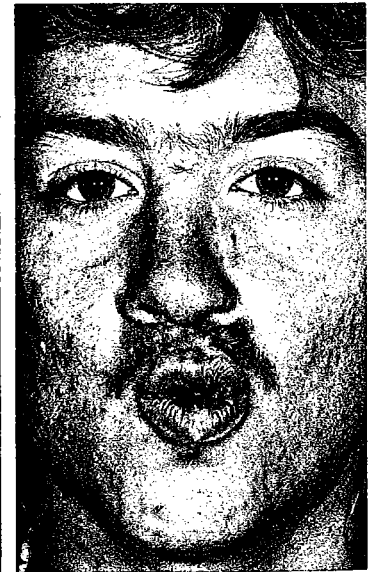
Result after Blair-Brown type lip closure.

6-8-72. CL rhinoplasty.

12-11-72. Midline 1.4 cm. shield-shaped Abbe flap. Division of pedicle after 9 days.



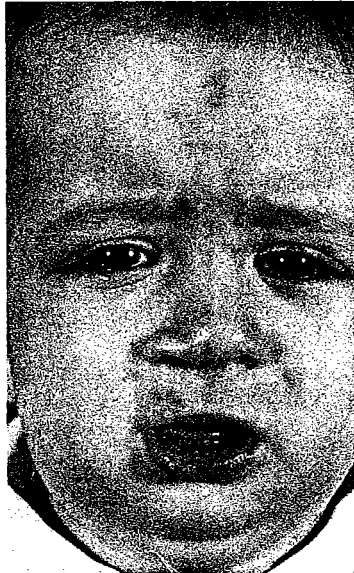12 years



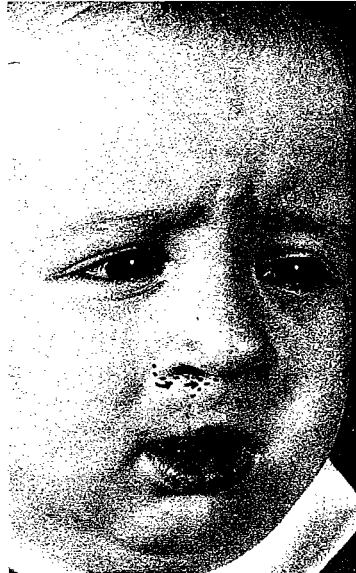17 years

Cleft lip rhinoplasty and midline Abbe flap, in spite of minor discrepancies, achieved balance, function and a pleasant quality.

The patient was first seen at 10 months of age presenting typical unnatural angled scar, loss of cupid's bow, philtrum and dimple, tightness along the free border of the upper lip with relative protrusion of the lower lip, wide nostril floor and flaring ala. At one year of age, a rotation-advancement revision of the upper scar with medial advancement of the alar base improved relations. The tightening action of the upper portion of the lip reduced the relative purse-stringing along the lower border. The



10 months

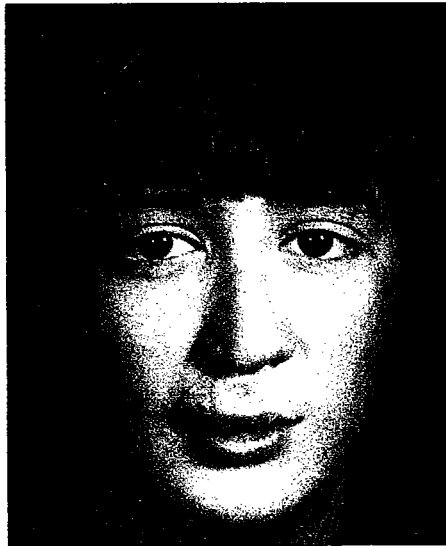
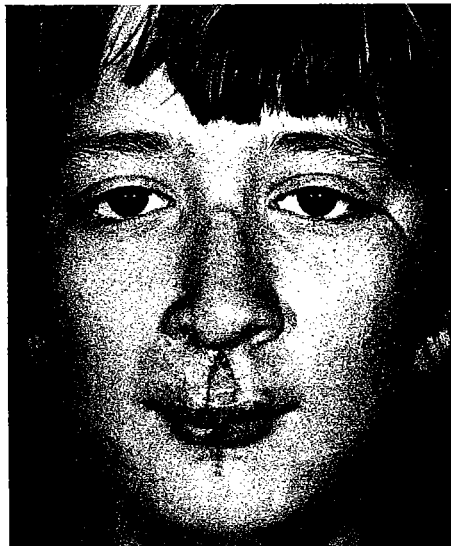
Result after Blair-Brown type lip closure.

1-3-61. At 1 year partial rotation-advancement.

14 years

early destruction of such landmarks as the cupid's bow and philtrum was still objectionable at 14 years so a midline Abbe flap was inserted to create a philtrum.



15 years

5-10-73. Midline 9 mm. wide shield-shaped Abbe flap.

Division of pedicle after 11 days.

12-5-73. V-Y mucosal roll-down to balance vermilion.


This 36-year-old man had a slightly tight upper lip with a single mucocutaneous arc and no residual cupid's bow, philtrum or dimple.

Result after Blair-Brown type lip closure.

CL rhinoplasty, alar cartilage lift to septum.

Midline shield-shaped Abbe flap.


Division of pedicle after 10 days.



Before Abbe



3 days after pedicle division



2 years later

This 27-year-old journalist and musician had his lip closed at one month of age in 1946 in Indiana when the Blair-Brown procedure was popular. Excerpts from the patient's letter to me are self-explanatory:

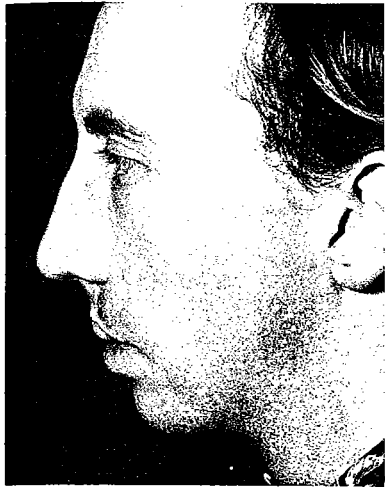My primary operation has left a number of irregularities and conspicuous scars of the lip. I have a tight upper lip of abnormal appearance which is unbalanced and unshapely with an excessively full lower lip, an irregular left nostril and an extremely deviated nasal septum. My upper lip will probably require reopening and the Abbe flap may be necessary.

I realize that there are a number of different adjustments possible and some of them are not easy, but if performed correctly they should improve the appearance tremendously.

This operation is likely to be a momentous, once-in-a-lifetime event for me even though I can't expect perfection.

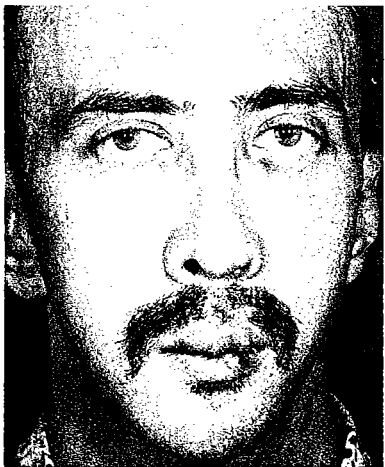
The patient arrived with the previously described secondary unilateral deformity of his lip and nose and in addition revealed protruding ears, a receding chin and a prematurely receding hairline sprinkled with healing hair grafts.

He only missed the midline positioning of the Abbe.

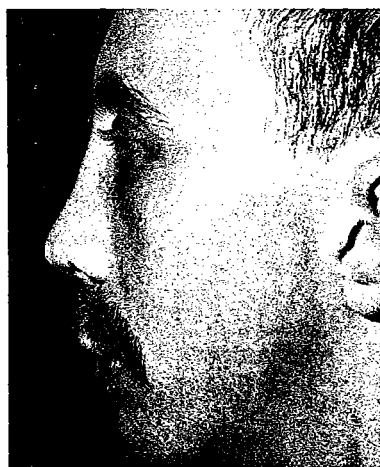

Result after Blair-Brown type lip closure.

The first surgery included a Silastic sponge implant to the chin and a cleft lip rhinoplasty, including reduction of the normal alar cartilage, piggy-back onlay graft of this cartilage to the cleft side, bridge lowering, bilateral osteotomy, submucous resection (SMR) and alar base advancement. Two months later a bilateral otoplasty and midline Abbe flap were done.




3 days after pedicle division



Midline shield-shaped 1.7 cm. Abbe flap.

Division of pedicle after 10 days.

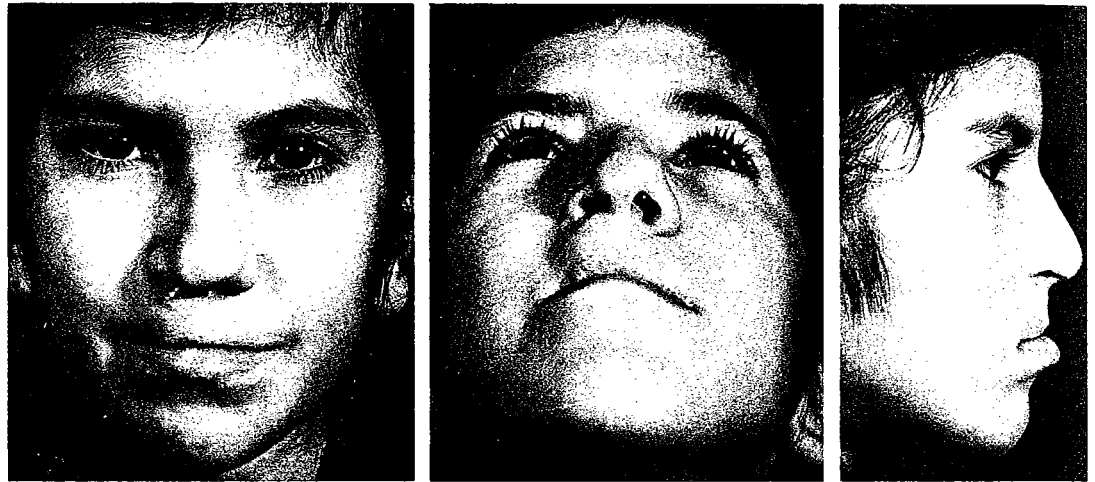


5 months postoperative



This 12-year-old girl's unilateral cleft had been closed by Ferris Smith of Grand Rapids, who as a pioneer did his own thing in cleft lip. It is difficult to type the method used, but it was probably a variation of the Mirault-Blair operation. Then, as Smith worked with Gillies at Sidcup during World War I, he must have been influenced to use the Gillies cupid's bow procedure in an attempt to re-create the cupid's bow lost during the primary surgery. This secondary procedure destroyed, with irreversible scarring, the mucocutaneous junction, justifying *in this case* Barrett Brown's criticism of the method.

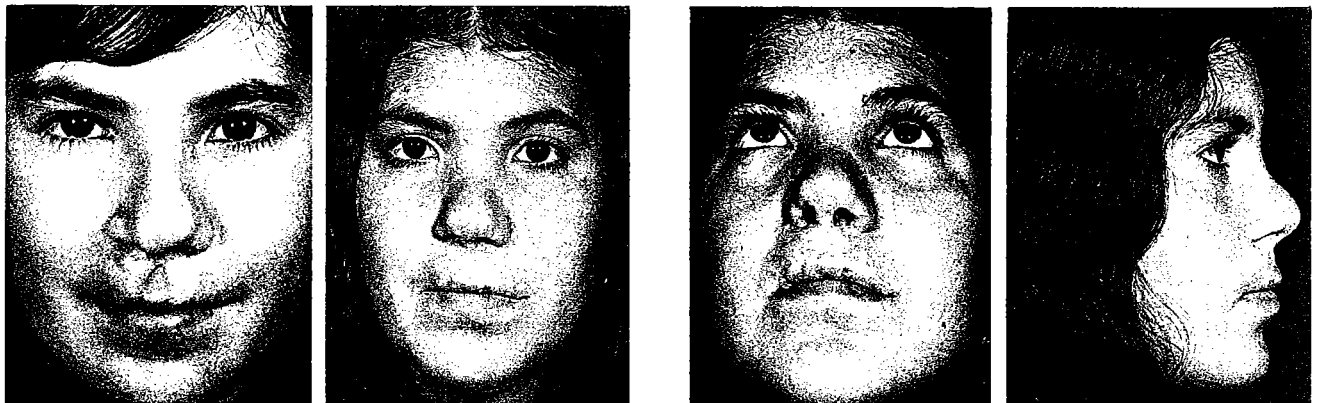Result after
Mirault-Blair-Gillies
procedures.



12 years

At 12 years. Midline, shield-shaped,
 2×1.5 cm. Abbe flap.
Division of pedicle after 14 days.

At age 13, normal alar cartilage was reduced and the cleft side alar cartilage lifted and fixed with a nylon suture to the septal bridge. At age 14, all lip scars were abraded. At age 17, reduction rhinoplasty, SMR, two septal cartilage struts inserted in the columella for nasal tip support and alar marginal sculpturing gave some further improvement.



20 years



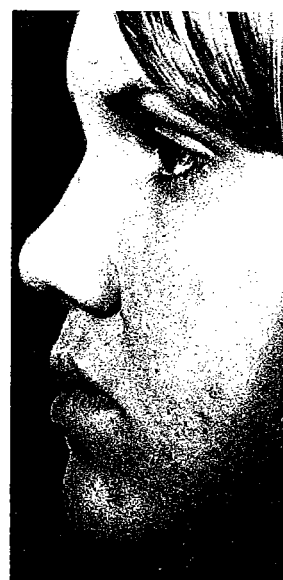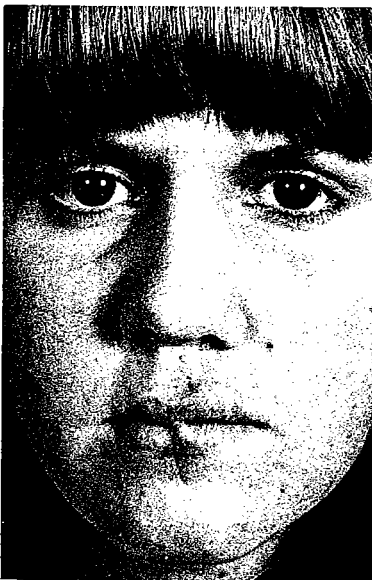This teenage girl with slight tightness of the upper lip and relative protrusion of the lower lip expressed particular consciousness of her lip scar. On closer study it was noted that the interruption of the mucocutaneous white roll ridge, the lack of a cupid's bow, philtrum and dimple, along with the relative tightness, rather than the scar, branded this lip abnormal.



Result after Brown-McDowell type lip closure.

15 years

It was decided that, although the patient was concerned about her *one* scar, release of tension and improvement in conformity with the creation of a cupid's bow and philtrum would justify the addition of *three* more scars!

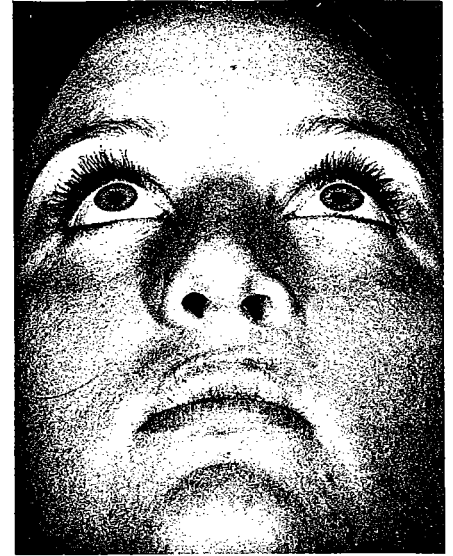


6-16-66. Midline 1.5 × 1 cm. shield-shaped Abbe flap carrying dimple! Division of pedicle after 11 days.
6-26-69. Abrasion of lip scars, nasal revision.

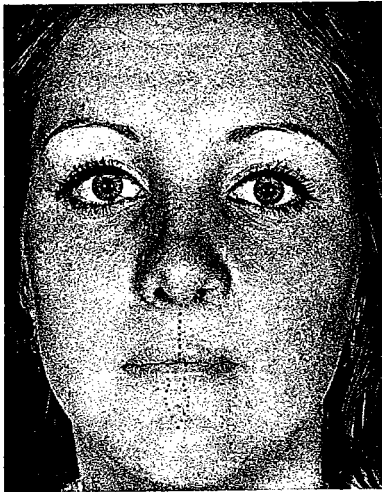16 years

18 years

Result after Brown-McDowell type lip closure.



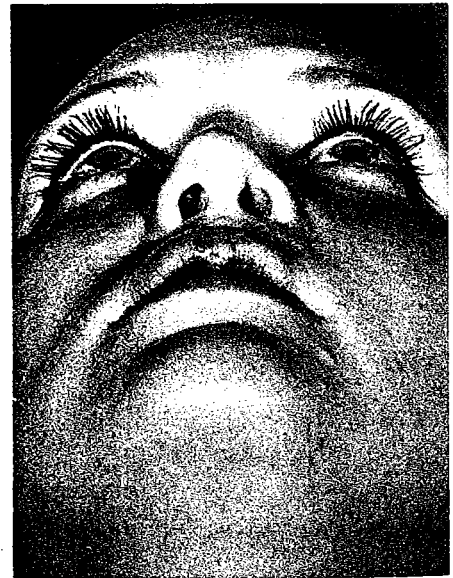
6-6-72. CL rhinoplasty.



18 years

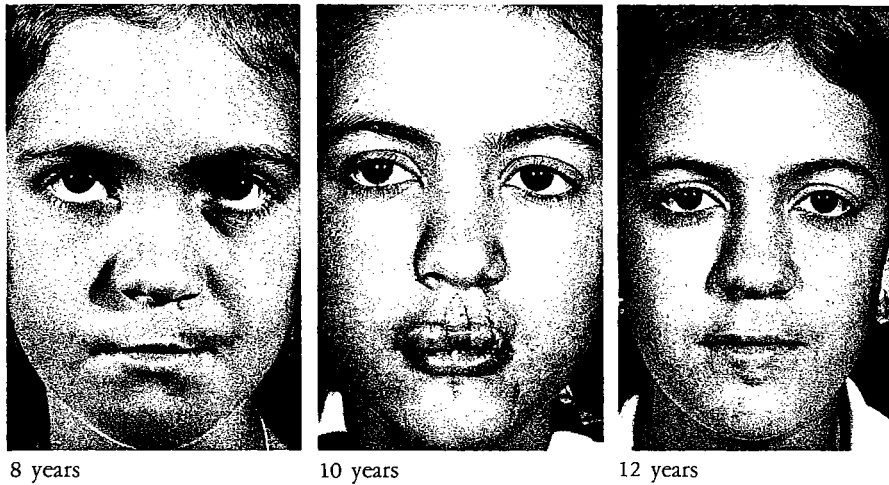
Cleft lip rhinoplasty reduced normal alar cartilage, lowered hump, narrowed nasal bones with osteotomy, released vestibular lining with Z-plasty, bolstered cleft side alar cartilage with onlay graft from normal side and denuded tip of alar base flap sutured to septum. An SMR was done, and two septal cartilage struts were inserted into the columella to support the tip. This set the stage for an Abbe flap.

10-17-72. Midline shield-shaped 1.5 cm. Abbe flap.
Division of pedicle after 11 days.
3-22-73. Old lip scar revised.



19 years

This patient had Brown-McDowell type lip closure at two months of age in Cuba, resulting at eight years in a tight lip without landmarks.



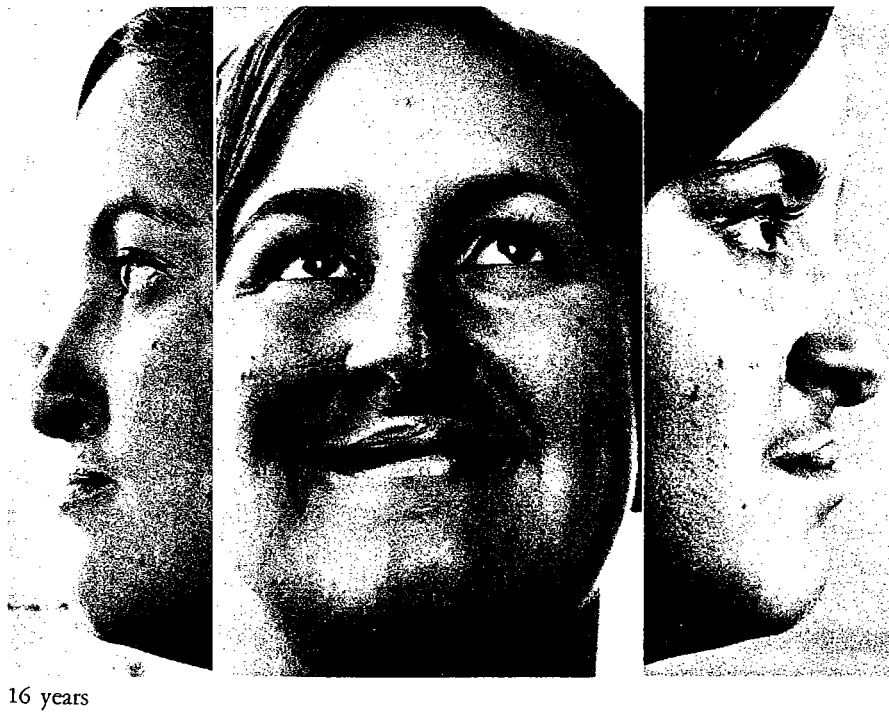Result after Brown-McDowell type lip closure.

8-23-73. Scar revision, mucocutaneous adjustments, midline 1.5 cm. shield-shaped Abbe flap.

Division of pedicle after 13 days.

Comment. Conformity more important than scars. Lower lip revision to follow.

A 21-year-old Australian girl who had had closure of a unilateral cleft lip in infancy is shown at a stage in her reconstruction.



When first seen in Miami, she had improved but still had a relatively tight upper lip, absence of landmarks and the asymmetry of a cleft lip nose.

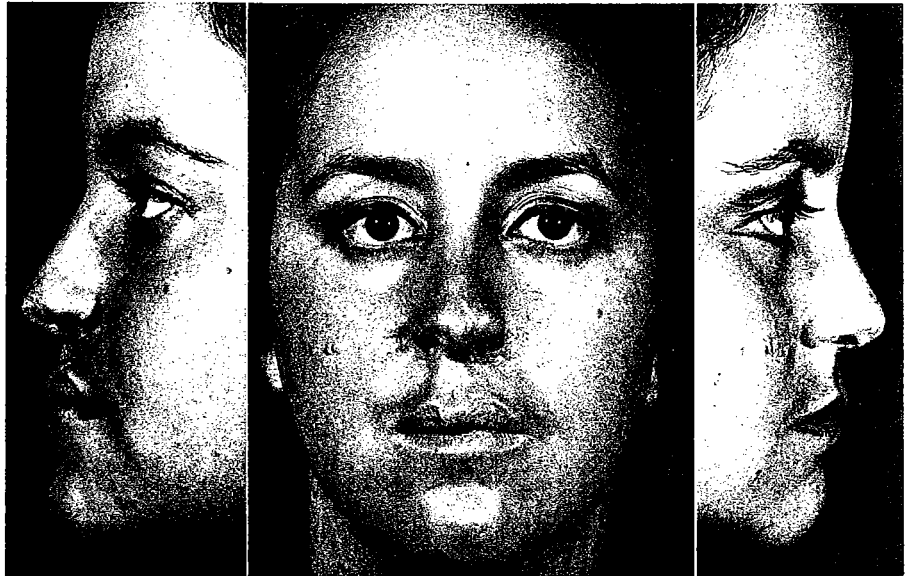Result after Brown-McDowell type lip closure.

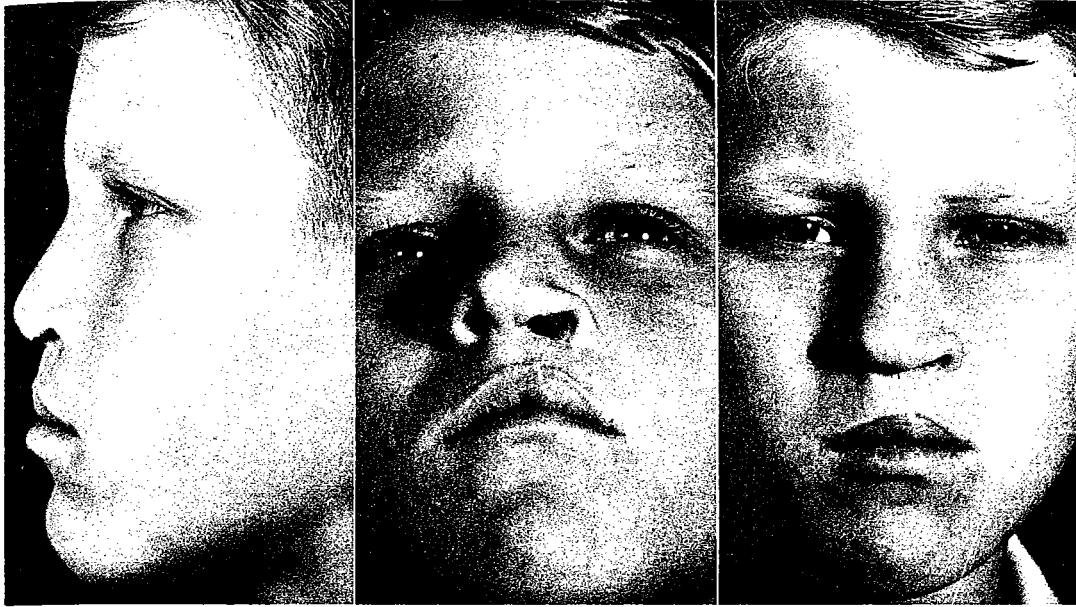At 21 years. CL rhinoplasty and midline shield-shaped 1 × 3 cm. Abbe flap.



At age 21 both nose and lip were corrected at the same time. Cleft lip rhinoplasty involved reduction of normal alar cartilage, septal shortening, rotation of cleft side alar base and SMR with cartilage struts into the columella to support the tip. A midline Abbe flap was inserted into the center of the upper lip.

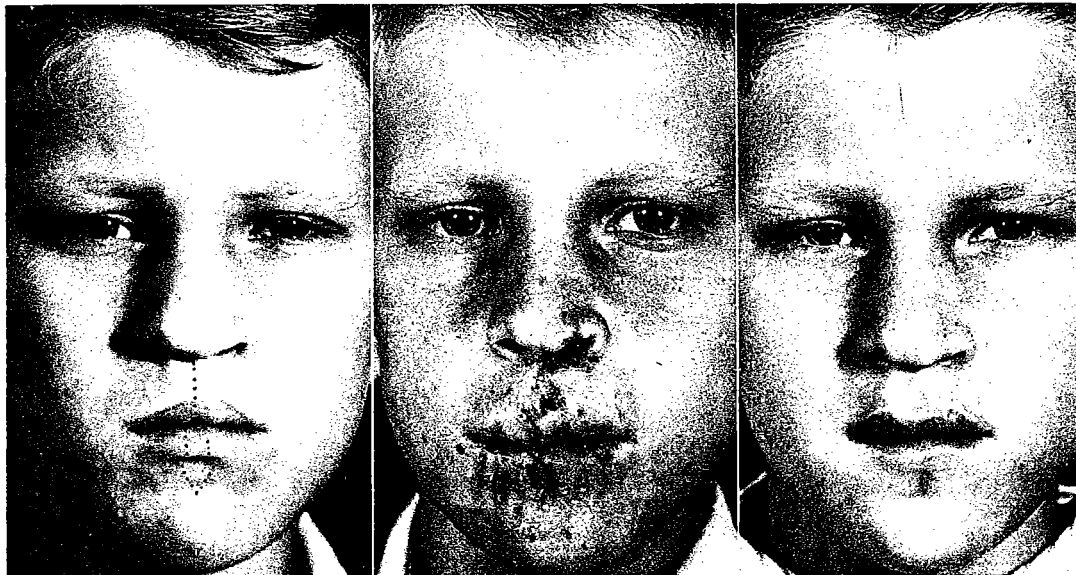Division of pedicle after 10 days.





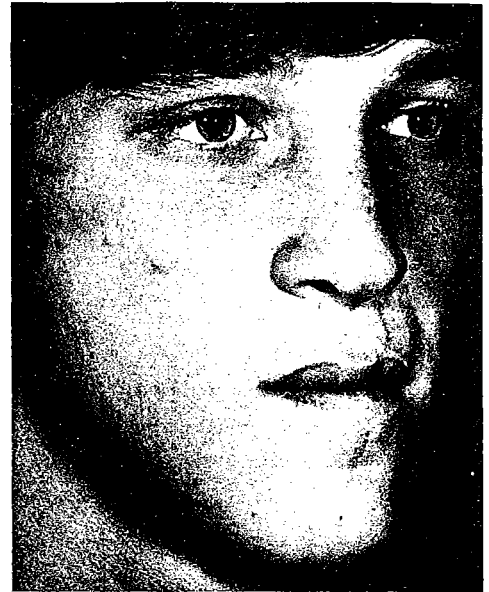
10 years

Result after Brown-McDowell type lip closure. Hemi-hooked nose, loss of lip landmarks, relatively tight upper lip.

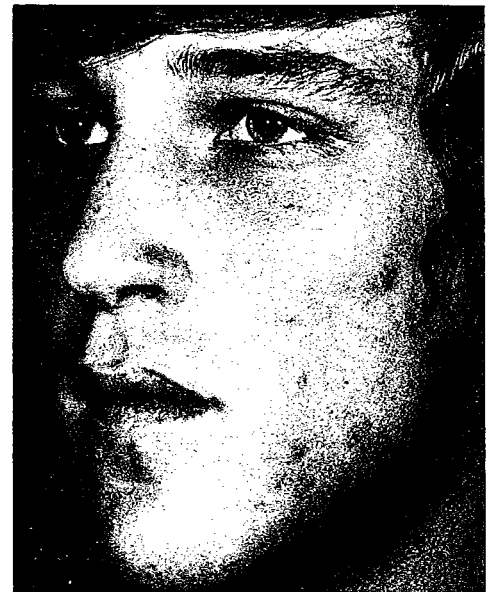



7-24-64. At 10 years. Scar revision, alar base and rim revisions, midline shield-shaped 1.5 cm. long Abbe flap. Division of pedicle after 13 days.

6-17-70. At age 16. CL rhinoplasty with alar lift and septal strut in columella to tip.

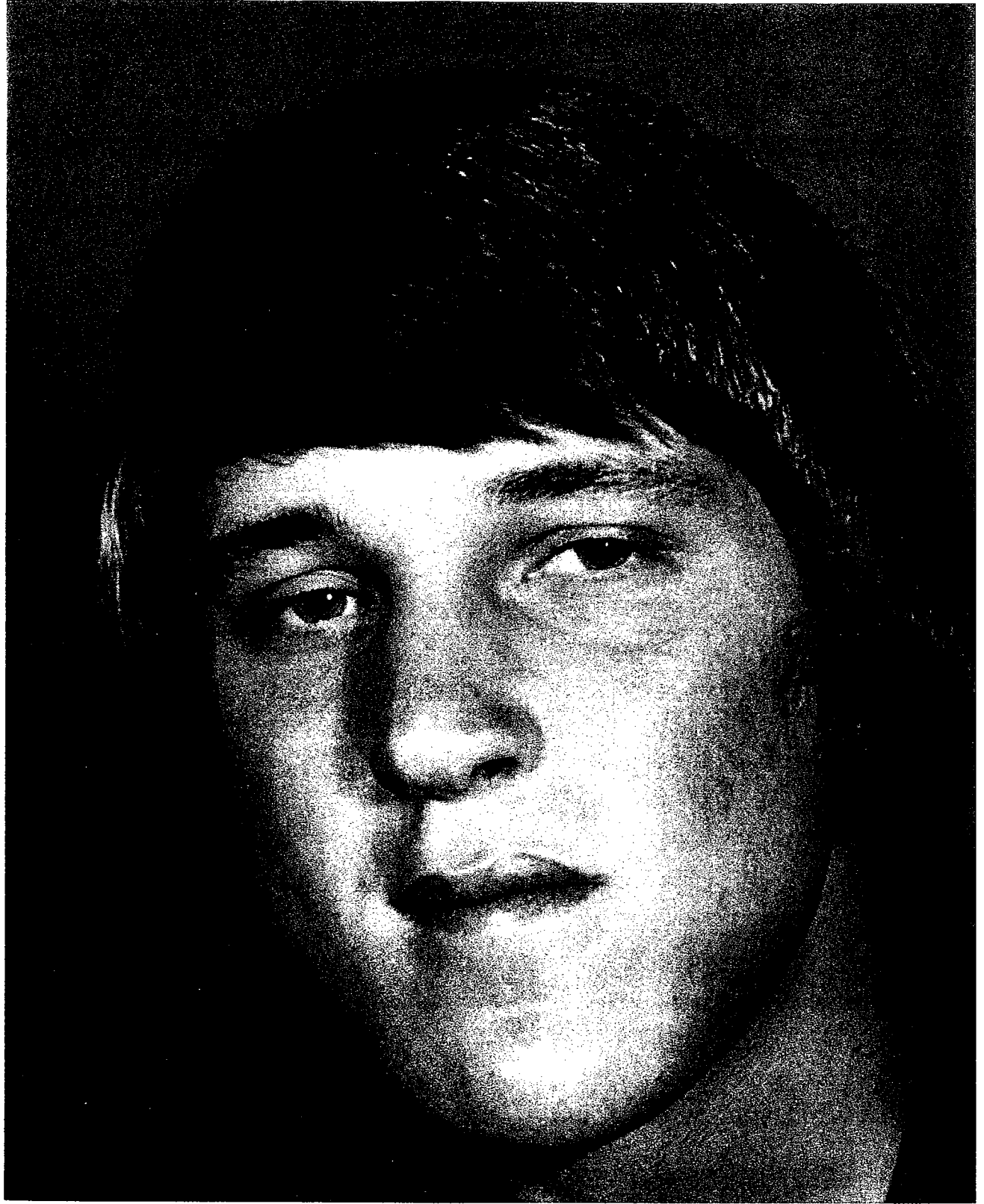


8-18-71. Abrasion of lip scars.
6-16-72. Mandibular osteotomy for class III malocclusion by University of Miami Professor S. Kline.

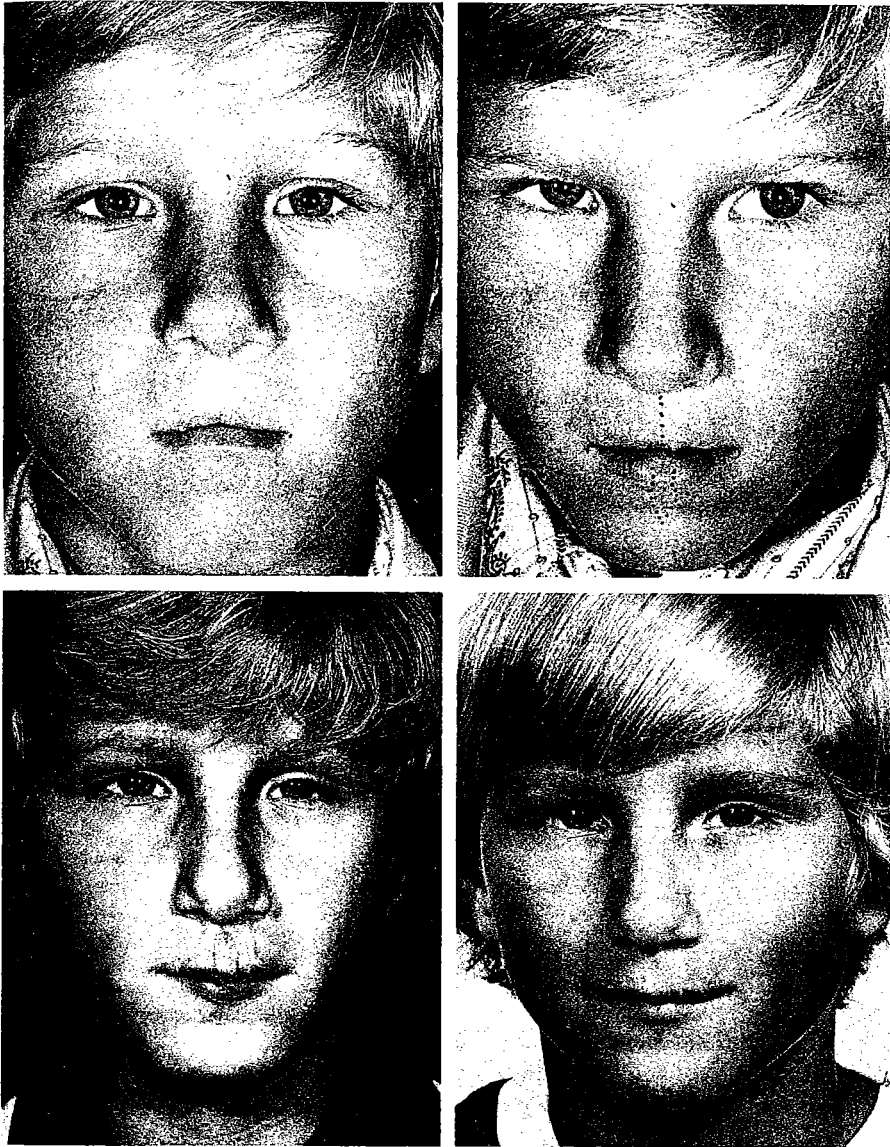

Comment. Scar excision at same time as the Abbe flap is unusual but seemed successful. Note new balance of the upper and lower lips with creation of a cupid's bow, philtrum and dimple. It is interesting that function of the lip is good except at the site of the original cleft closure, where the muscle fiber arrangement is still slightly askew.

20 years



This boy, one of twins, was born with a unilateral cleft while his twin had a bilateral cleft. A primary inferior triangular flap closure resulted in a central vermilion notch with a flattened lip lacking a cupid's bow, philtrum or dimple.



Result after Brown-McDowell type lip closure.

At 7 years. Midline shield-shaped Abbe flap.

Division of pedicle after 9 days.

Postoperative Hagedorn-LeMesurier result

The quadrilateral flap method presents an unnatural scar line, the lip has no evidence of a philtrum or dimple and, in some cases, the method fails to create a cupid's bow. The inferior border of the upper lip may be tight and compare unfavorably with the protuberant lower lip. There is the usual asymmetrical distortion of the cleft lip nose.

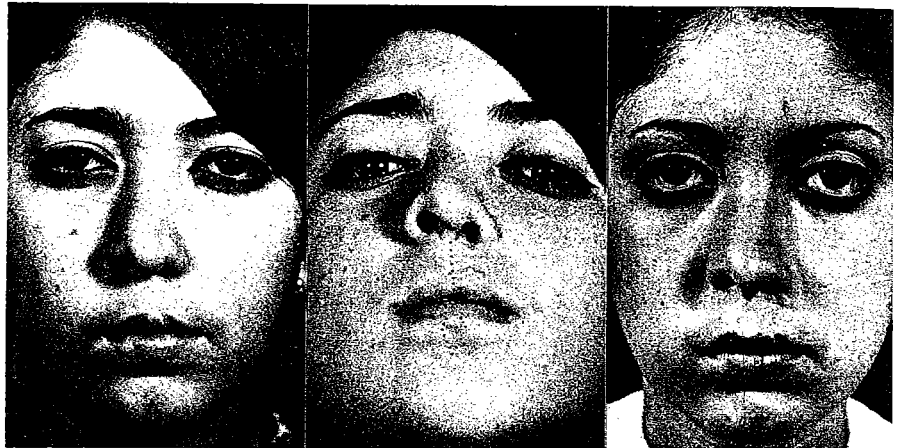This 18-year-old Cuban girl had a tight upper lip lacking natural landmarks and an asymmetrical cleft lip nose. At age 19, cleft lip rhinoplasty reduced normal alar cartilage, lifted the cleft side alar cartilage to the septum with nylon suture, reduced normal alar base and rotated flaring alar base. SMR supplied cartilage struts which were inserted in columella to support the tip, and Silastic sponge was implanted beneath alar base.

Result after LeMesurier type lip closure.

6-17-70. Midline shield-shaped 1.4 cm. Abbe flap.

Division of pedicle after 9 days.

3-31-71. Abrasion of lip scars.



18 years

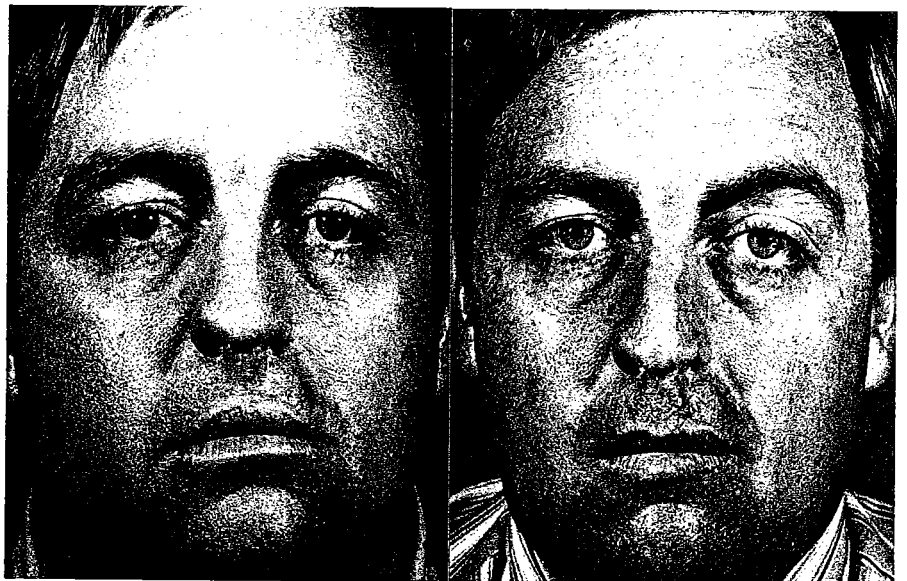21 years

The lack of the natural landmarks of cupid's bow, philtrum and dimple prompted a lip-switch flap which seemed to put the lip at rest in this 27-year old man.

Result after LeMesurier type lip closure.

12-9-69. Midline 1.5 X 1 cm. shield-shaped Abbe flap.

Division of pedicle after 10 days.



27 years

28 years

This 15-year-old girl had a LeMesurier primary lip closure resulting in a lack of natural landmarks and contour of the lip and asymmetrical distortion of the nose. A cleft lip rhinoplasty included normal alar cartilage reduction, lift of cleft side alar cartilage to septum, transposition of flaring alar base and reduction of the normal alar base. Then the Abbe flap was switched.



Result after LeMesurier type lip closure.



At 16 years. Midline shield-shaped 1.5 cm. Abbe flap.
Division of pedicle after 10 days.



12 years

24 years

Result after LeMesurier type lip closure.

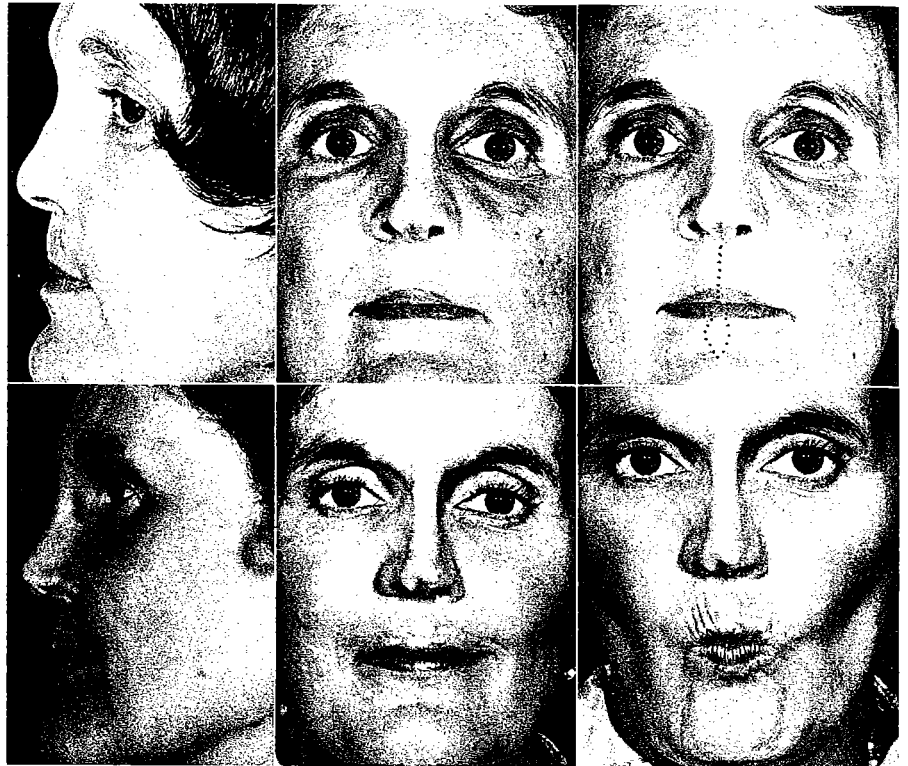6-12-63. At 13 years midline shield-shaped Abbe flap.

Division of pedicle after 13 days.

9-11-63. CL rhinoplasty, hump removal, septal shortening, bilateral osteotomy, SMR and septal strut in columella to tip.

At age 43 the upper lip was split in the midline and a shield-shaped Abbe flap inserted.

Division of pedicle after 10 days.



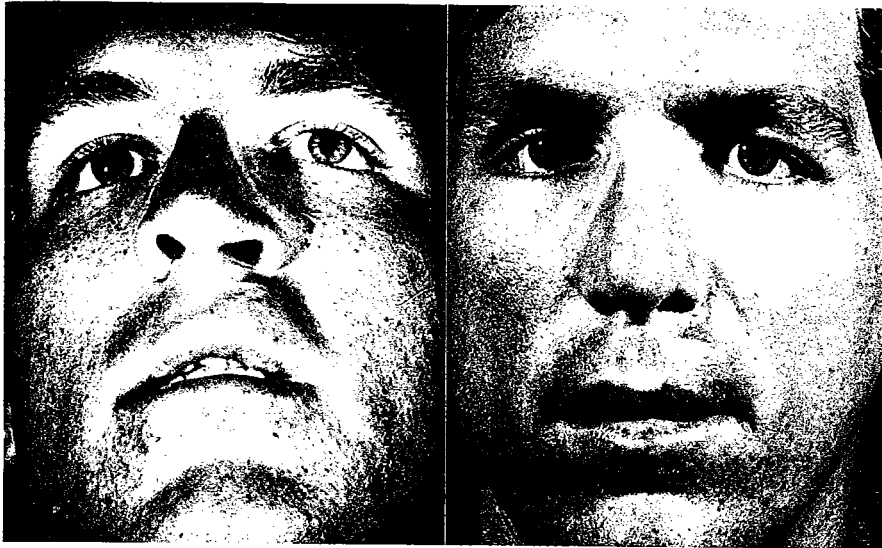This 42-year-old woman had her lip closed primarily in Chicago and later revised with a secondary LeMesurier procedure. The lip was slightly tight in transverse dimension, comparing unfavorably with the lower lip. In spite of the secondary quadrilateral flap, the mucocutaneous ridge spanned in a single arc with no suggestion of a cupid's bow, and, of course, there was no philtrum or dimple.

Insertion of an Abbe flap released the upper lip which improved its relationship with the lower. It also created a philtrum with dimple. Puckering of the orbicularis oris musculature of the upper lip seven months after operation revealed balanced wrinkling on either side of a quiet but natural central philtrum.

A Z-PLASTY PROBLEM

Z-plasty closures seldom require an Abbe flap, but when they do there can be problems. Here is an example:

This 17-year-old boy had had a type of Mirault-Blair closure in infancy and some sort of Z added to it later which resulted in the worst of both. He had a tight lower portion of the upper lip, unnatural scars zigzagging everywhere, no natural landmarks and a typical asymmetrical cleft lip nose.



17 years

18 years

5-28-70. At 17 years. CL rhinoplasty and reduction of lateral lip muscle bulge.

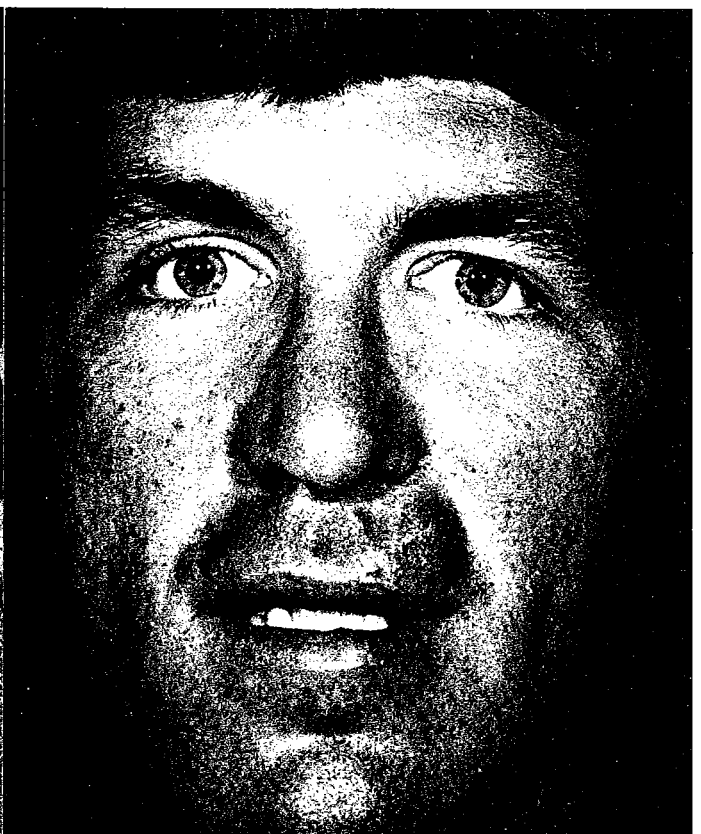
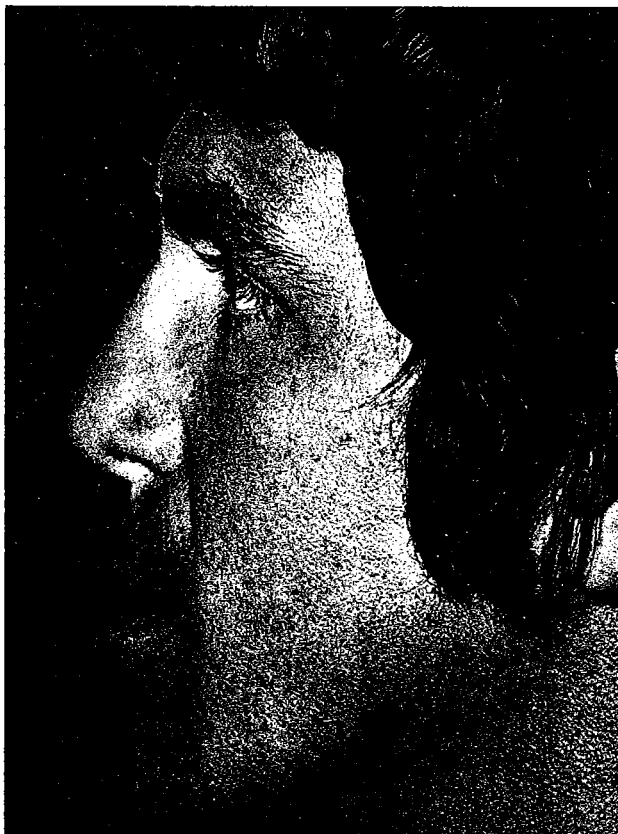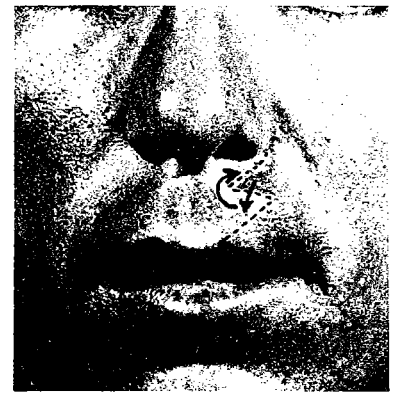9-15-70. Midline shield-shaped Abbe flap.

Division of pedicle after 10 days.

Insertion of an Abbe flap produced a natural-looking dimpled philtrum, but there was still something wrong! After repeated observation, it was realized that the lip Z-plasty had strangely disarranged the hair-bearing areas.

Less than a year after the Abbe flap operation a reverse Z-plasty redistributed the hair-bearing and non-hair-bearing areas without lengthening the lip. An expendable area of non-hair-bearing lip skin was used as a free skin graft to construct a mucocutaneous white roll ridge across a flattened interruption of the ridge.

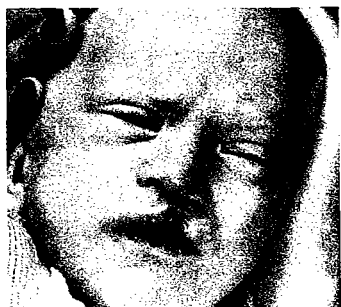6-24-71. Reverse Z-plasty.



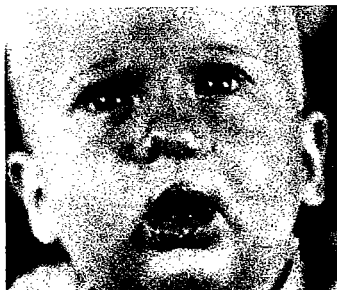A CASE OF SPECIAL INTEREST

This patient was born in Fairmont, West Virginia, on 9-10-44 with an incomplete cleft of the lip, and his pediatrician sent him straight to V. P. Blair in St. Louis. Blair, whom the mother remembers as being kind and charming, employed his inferior triangular flap. Ten years later J. B. Brown did a lip revision and the mother recalls how impressed she was with Brown who, when attending a convention, took the time to see her son. He told them that the boy should wait until he was 29 or 30 years old to have further work, and that it should be his own decision.

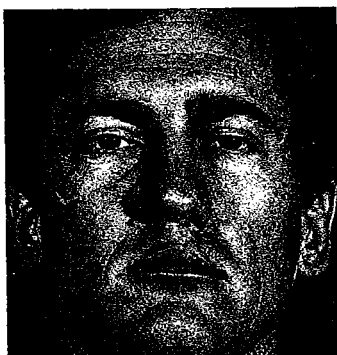
In 1974, at age 29, the patient revealed slight relative protrusion of the mandible and some asymmetry of the nose, and an inferior triangular flap constricting the free border of the lip, causing tightness.



11-15-44



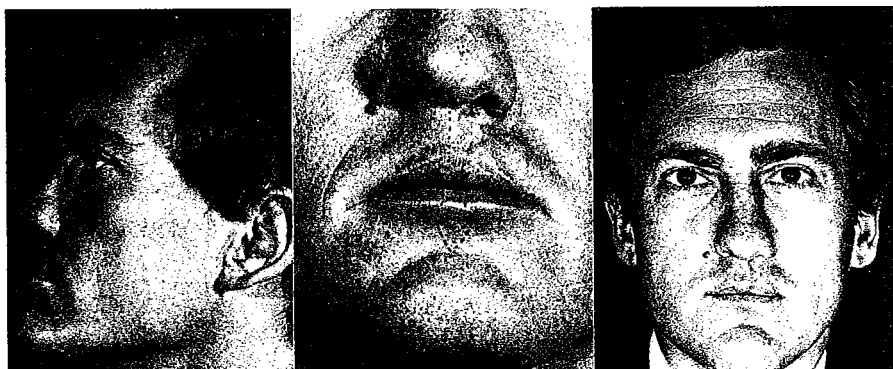12-12-44



1-28-75

1-28-75
Midline 1.5 cm. shield-shaped
Abbe flap.

Division of pedicle
after 10 days.



This is one of the rare times that it has been possible to *excise secondarily almost the entire cleft scar and intervening tissue*, and keep the Abbe in philtrum position. This was possible probably because the original cleft was incomplete.

6-20-75
Excision of cleft
scar. Normal alar
cartilage tiered as
onlay grafts to
cleft side. Revision
of vermillion.

