

41. Discrepancies in Muscle Continuity and Philtrum Contour


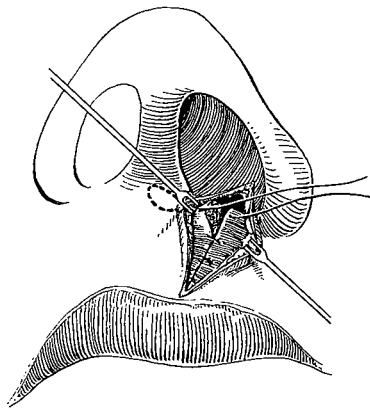
SECONDARY MUSCLE DEFORMITY

THE importance of accurate and complete muscle approximation across the cleft cannot be stressed enough. As noted by Pennisi and Fara, most cleft lip closures do not correct the alignment of the orbicularis oris muscle fibers, so that often vertically oriented fibers are sutured side to side. Then, as Pickrell has suggested, there is dysplasia of the orbicularis oris muscle itself, which can be responsible for later appearance of flatness in contour after surgery. In fact, there is often a discrepancy in muscle body in the actual edge of the lip element on the cleft side and a true attenuation with grooving horizontally of the upper portion of this element just below the alar base. This relative thinness is accentuated by an unnatural muscle bulge below and lateral to it. Thus, it is important that the surgeon expose good muscle structure on each side of the cleft and bring these together with authoritative suturing.

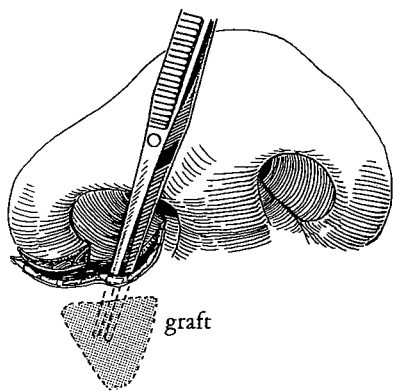
Merrill Climo of Falls Church, Virginia, as an alert resident at New York Hospital-Cornell Medical Center, repeatedly observed a diastasis of the orbicularis oris muscle in older patients returning to the cleft palate clinic. In 1968, before the New York Academy of Medicine, he proposed that if the surgeon does not succeed in his primary procedure, whether it be improper muscle apposition, dehiscence or gradual attenuation, an *orbicularis diastasis* occurs. For this defect he advised scar excision, reorientation of the orbicularis fibers and secondary suturing with the nasal spine as the suspension point. Climo was awarded the first



Merrill Climo



George Crikelair



J. P. Webster award for best resident's paper, and in 1969 this work was published in the *Cleft Palate Journal*. His chief, Herbert Conway, pleased with the simplicity and effectiveness of this approach, presented him with a trip to Italy. There he served as a teaching fellow at the Catholic University under Professor Litterio Maggiore who himself was inundated with secondary cleft lip cases from Sicily.

SECONDARY CAMOUFLAGE

The ambling but astute George Crikelair of Presbyterian Hospital, renowned for his devoted work in accident and burn prevention, was content to treat secondarily, rather than prevent primarily, the cleft side flatness after lip closure.

Cosman and he noted,

In forms of lip repair that fail to respect the philtrum, a flattening of the area beneath the nostril and extending down to the vermilion is to be noted . . . the result of the absence of the normal philtrum eminence on the cleft-side. Comparison between the cleft and normal sides makes the difference even more striking.

This flattening need not be blamed on the primary operation. As already noted, there is often a deficiency of contour in the lateral lip element above the muscle bulge which when incorporated into the closure will retain a flatness. Rather than discard this valuable tissue, it is better to bolster it. Cosman and Crikelair advocate a dermolipomatous graft:

Medially based turnover flaps of muscle and fibrous tissue from the lateral lip and rolled on themselves along the philtrum line did not produce satisfactory results. . . . The use of a dermal fat graft to create a philtrum eminence . . . and its placement via the incision in the nostril floor while rotating the ala seemed apropos.

This is a worthwhile secondary procedure.


A SWEDISH SCARRED MUSCLE SLING

Others have found interesting secondary uses of parts of the lip scar. For instance, the father of Swedish plastic surgery, Alan

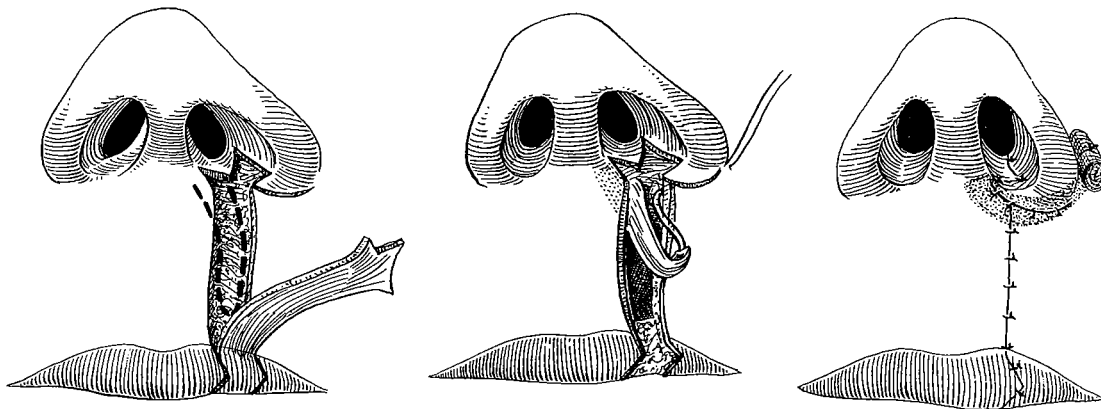
Ragnell of Stockholm, suave and as sly as a fox, had his early training in England. As Gillies once said,

I was flattered by Alan's devoted attendance to my surgery until I discovered he was courting my theatre sister on the side. What's more he took her back to Sweden with him and married her!

In 1946, with the same clever efficiency, Ragnell, concerned about the creeping alar base in unilateral clefts, excised the lip skin scar including the nasal floor and a dart at the columella base. He then cut a vertical flap of *muscle* and *scar*, based it medially and superiorly and used it as a sling to pull in and support the alar base, which was itself advanced into a dart in the columella base. Of course, a tertiary advantage of this sling now becomes apparent as it could be used simultaneously to fill any deficiency in the upper portion of the lip if its course to the alar base were directed accurately.



Alan Ragnell



As another example of his crafty efficiency, Ragnell, living on one island not far from another, had a wire strung between them. To save launching a boat daily he suspended a 60-foot net from the wire, which he hauled in twice a day along with several delicious one-pound perch fresh out of Scandinavian waters. Now retired in sunny Sicily, from his picturesque spot in Taormina on top of that sheer rock cliff covered with purple bougainvillea and with Mt. Etna at his back, he can look with contentment upon a vast expanse of teal Mediterranean sea. He can also reflect with pride on plastic surgery in Sweden, and the world-renowned cleft lip and palate centers at the Universities of Göteborg, Stockholm, Uppsala and Umea.

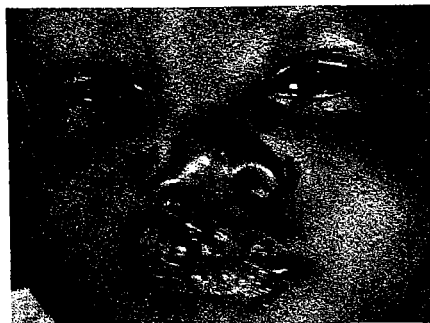MUSCLE READJUSTMENT

It is becoming more and more apparent that mere suturing of the muscles is not really enough, nor is the grafting of dermis. Dissection and positioning of the muscle fibers into a more transverse direction are essential. This procedure creates muscle defects which, in addition to the original congenital deficiencies, require the shifting of excess tissue. Muscle edge flaps transposed across the cleft can be inserted into tunnels in the deficient zones for contour and functional balance. These muscle flaps have been described in the primary cleft lip closure but can be employed as secondary procedures.

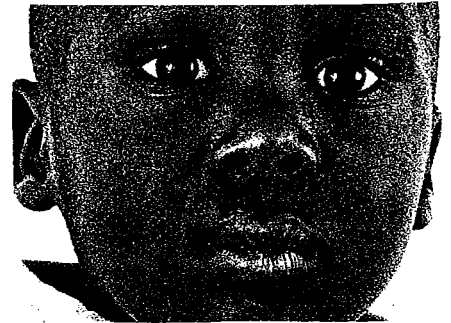
A COMMON DISCREPANCY IN EARLY ROTATION-ADVANCEMENT

The common secondary deformity in the orbicularis oris muscle shows up as a subcutaneous cleft or diastasis allowing distortions in the lip during puckering and whistling. At rest, a muscle bulge presents in the lateral lip element with a contour deficiency appearing between this bulge and the alar base. It is treated by de-epithelialization of the vertical lip scar, which is then elevated as a dermomuscular scar flap based superiorly. This provides access to the lateral muscle, which is dissected free from its skin and mucosa in the area of the bulge, released from above and brought down and stretched across for better end-to-end muscle fiber approximation. There is then an empty space left above in the lateral element into which the dermomuscular scar flap can be transposed.

Here is an example in which the unilateral incomplete cleft had been rotated and advanced without refinements at the age of three months in 1957. The balance of the cupid's bow and philtrum dimple were acceptable. At age two years the slight



3 months



2 years


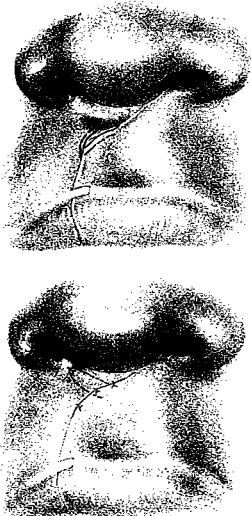
deficiency inherent originally in the upper part of the lateral advancement flap was noticeable.

By 16 years it was emphasized by the ridge of the upper part of the rotation scar. The upper, crinkled and ridged portion of the scar was de-epithelialized, and a flap was taken of the deeper tissue in this area including scar, dermis and muscle. With its base above, this flap was transposed across into a tunnel under the depressed area. A small wedge from the "normal" wider alar base was also de-epithelialized and used for extra filler. The muscle was reapproximated across the cleft with 4-0 Mersilene.



16 years

Even a three-quarter view from the cleft side now shows a natural philtrum hollow and bow and in no way impedes his life or his prowess in football at defensive back.



16½ years

PHILTRUM DIMPLE — PRESERVATION OR EXCAVATION

One of the practical difficulties in the construction of the philtrum hollow is the paradox the surgeon faces in trying for solid muscle continuity and, at the same time, gouging or removing a central portion of this muscle to create a dimple. Both are desirable, but the dilemma is to gain one without losing the other.

RECREATING PHILTRUM LANDMARKS

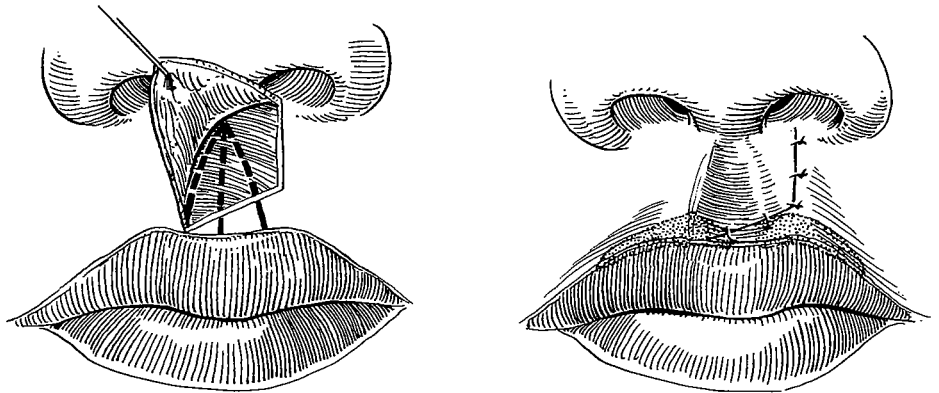
Although the medial component of a unilateral cleft lip has a philtrum dimple, a column and two-thirds of a cupid's bow, when these landmarks are ignored and destroyed during the primary surgery, the final result is a lip with no dimple and no bow.



Gerald O'Connor

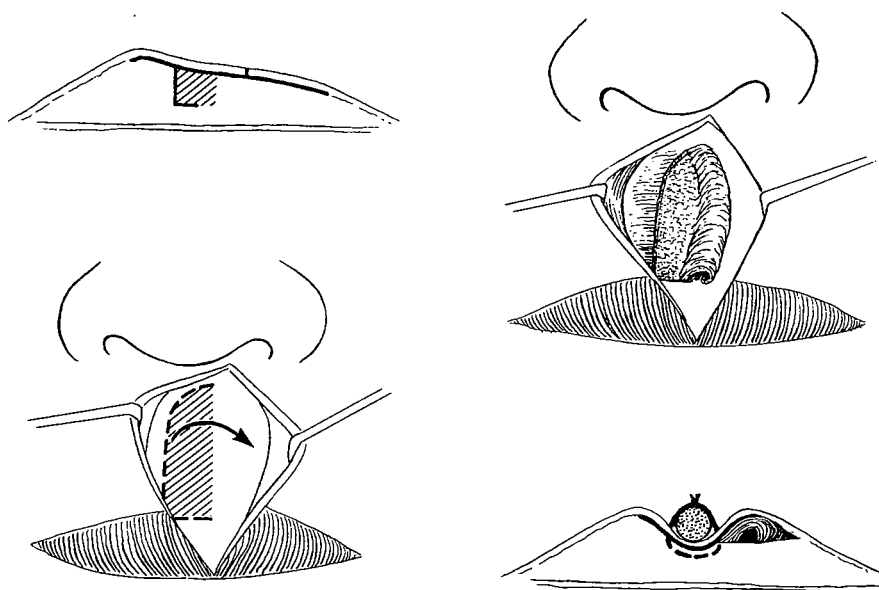
Gerald Brown O'Connor of San Francisco had enough of the fight of the Irish in him to win his boxing stripes at the University of California, to hang in there as a student with Gillies at his caustic prime and to try to correct one of cleft lip's most difficult deformities.

O'Connor, with McGregor, designed a method of creating a dimple in the prolabium of bilateral clefts and modified it to re-create a philtrum dimple in unilateral clefts. Through the old Blair-Brown incision, which, of course, did away with any dimple or bow, the skin of the center of the lip was undermined. A vertical flap of muscle tissue based inferiorly was gouged out of this area, split into two flaps and transposed bilaterally in tunnels along the mucocutaneous junction line. Tissue was thus shifted from the vertical center to the lateral horizontal plane in an attempt to create a philtrum hollow. There is a tendency for the lateral lip muscle pull to smooth out these excavations unless the skin in the area is well thinned, of sufficient amount to drape easily into the hollow and fixed with permanent buried sutures.



ORIENTAL DIMPLE AND COLUMN

Takuya Onizuka of Showa University, Tokyo, creates both a philtrum dimple and a column in secondary cases in which they have been destroyed. He advocates a W-plasty excision of the vertical scar or a positioning of the cupid's bow and alar base with the rotation-advancement principle. In combination with this he turns a roll-over flap of muscle tissue out of the central philtrum position with its pedicle on the vermilion and curls it on itself to form a philtrum column prominence. The maneuver is sound as it takes tissue from where it is actually *not* wanted and puts it where it is needed.



DIMPLED ABBE

Then there is the shield-shaped midline Abbe flap, which can transpose the lower lip *groove* into dead-center philtrum dimple position of the upper lip. There will be much more on this later.